



**Secteur des Sciences de la santé**

**Faculté de Médecine**

**Cours WMDS1311**

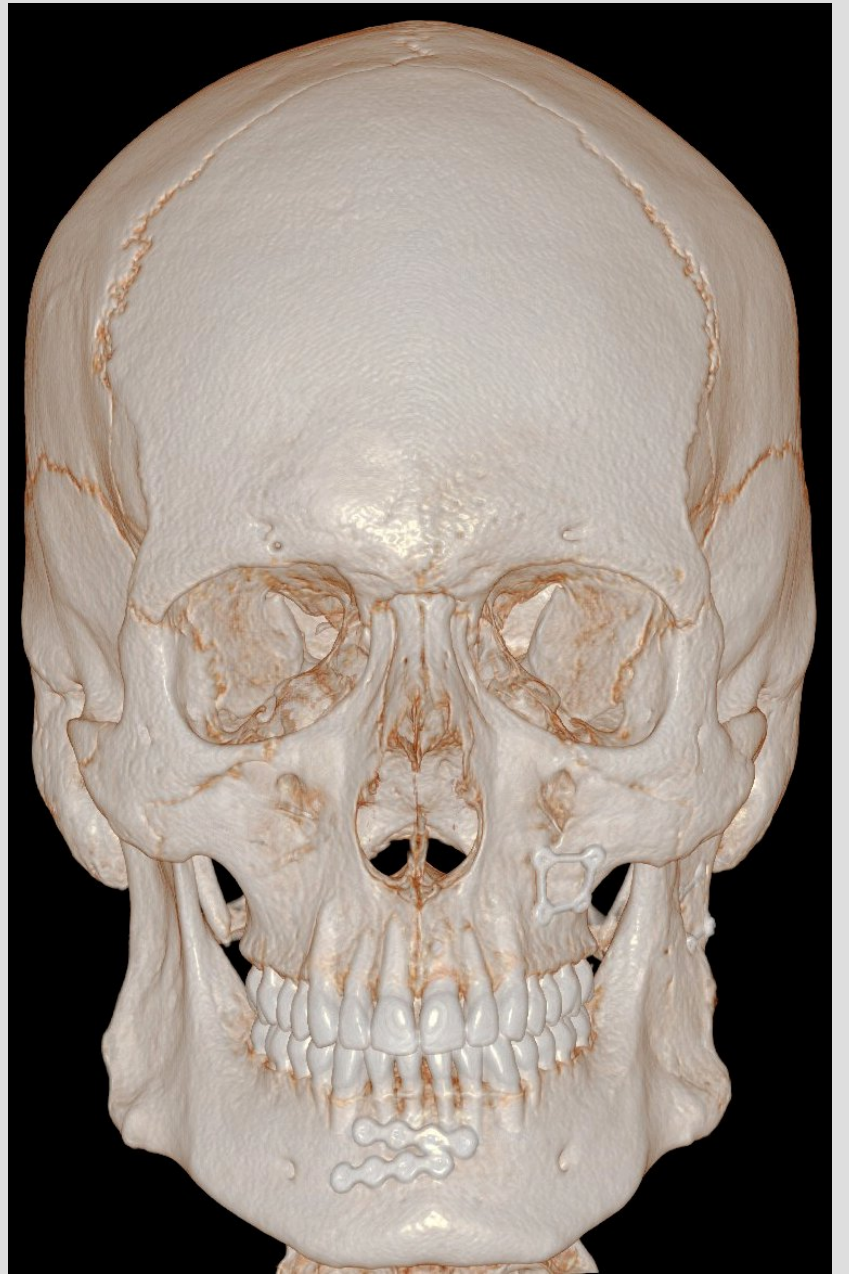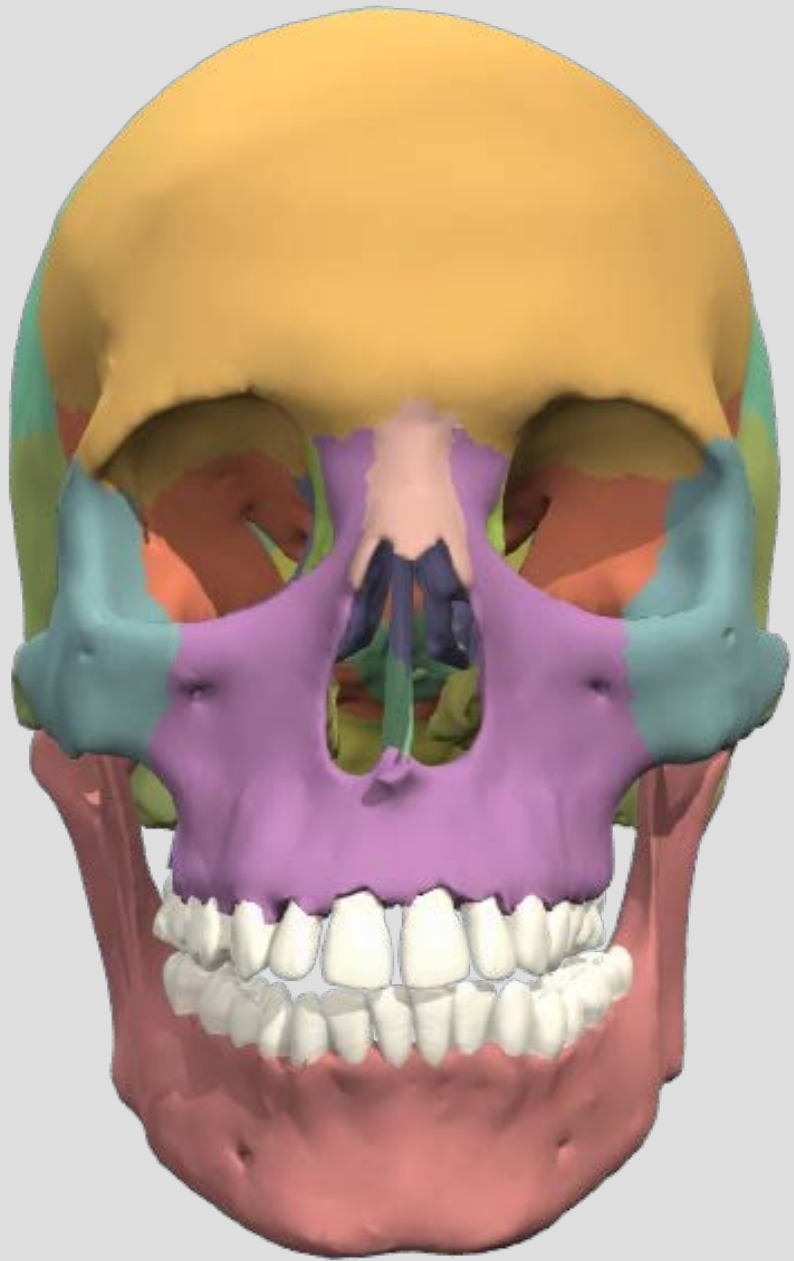
**Année académique 2017-2018**

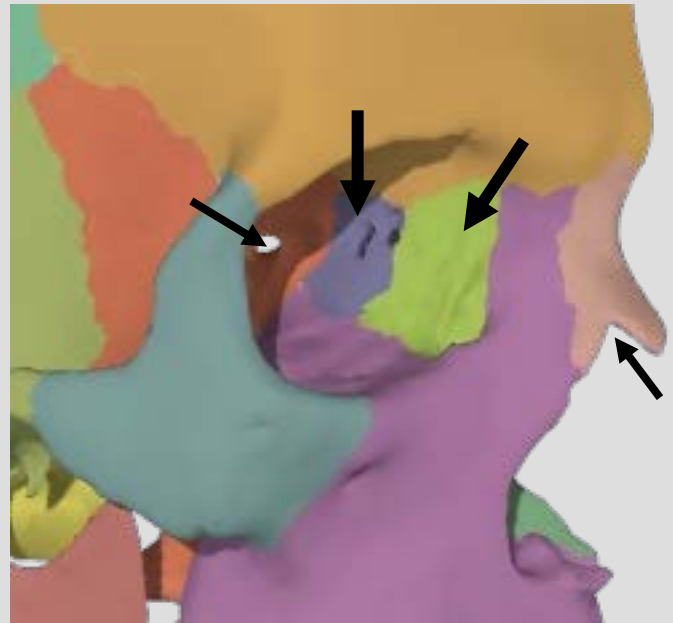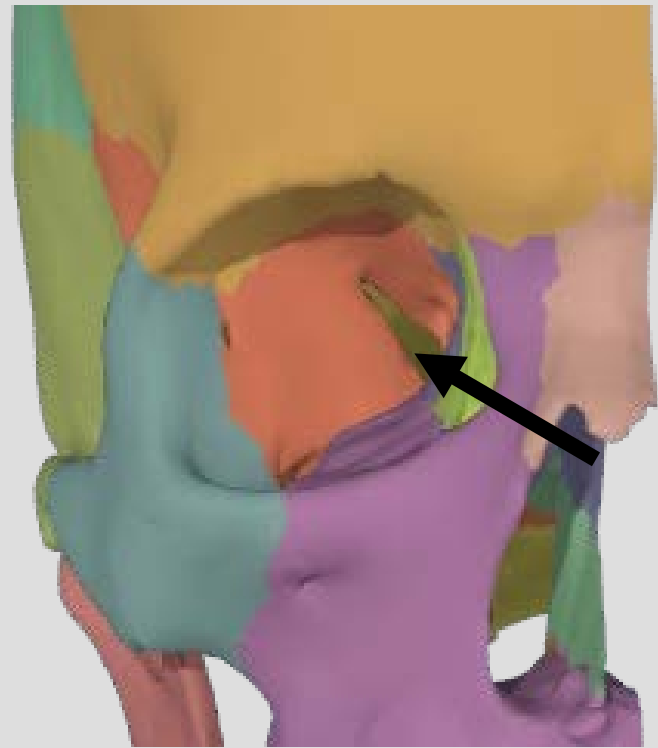
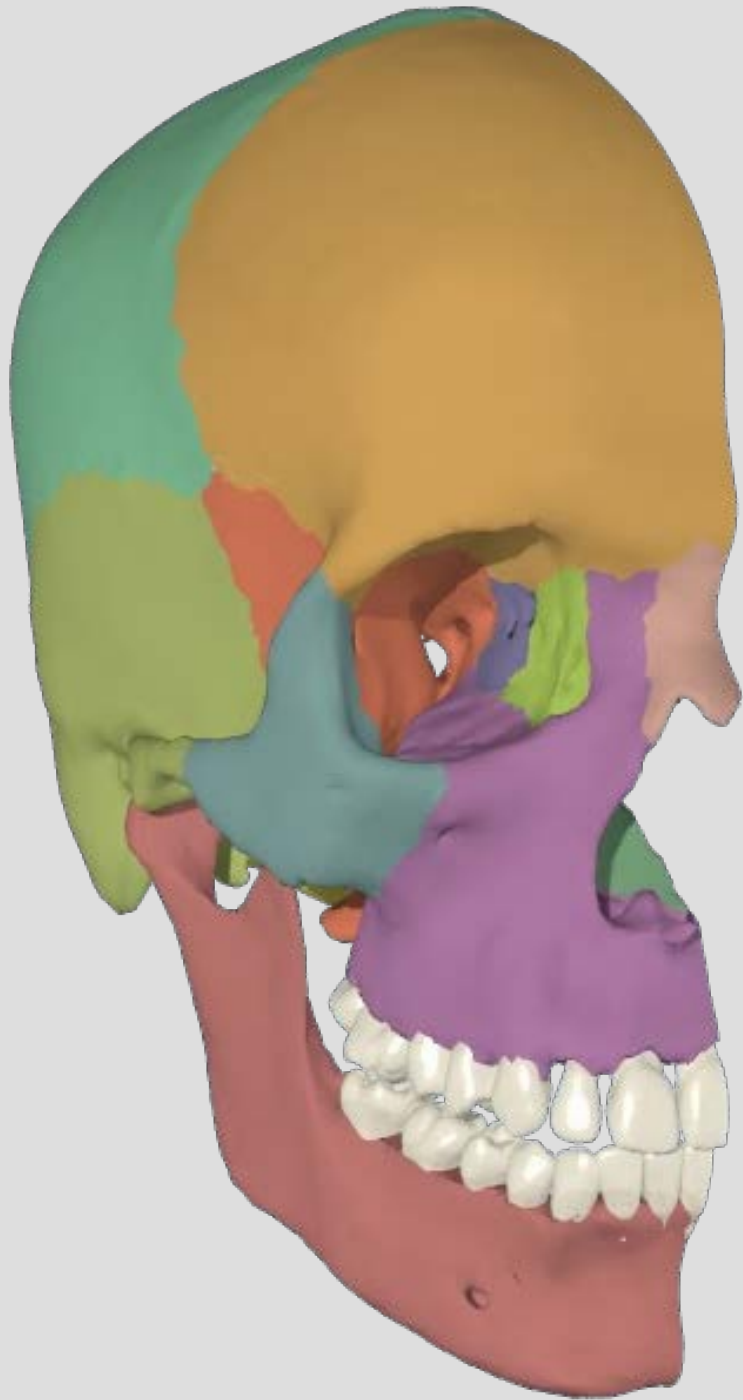
# Neuroanatomie neurologique

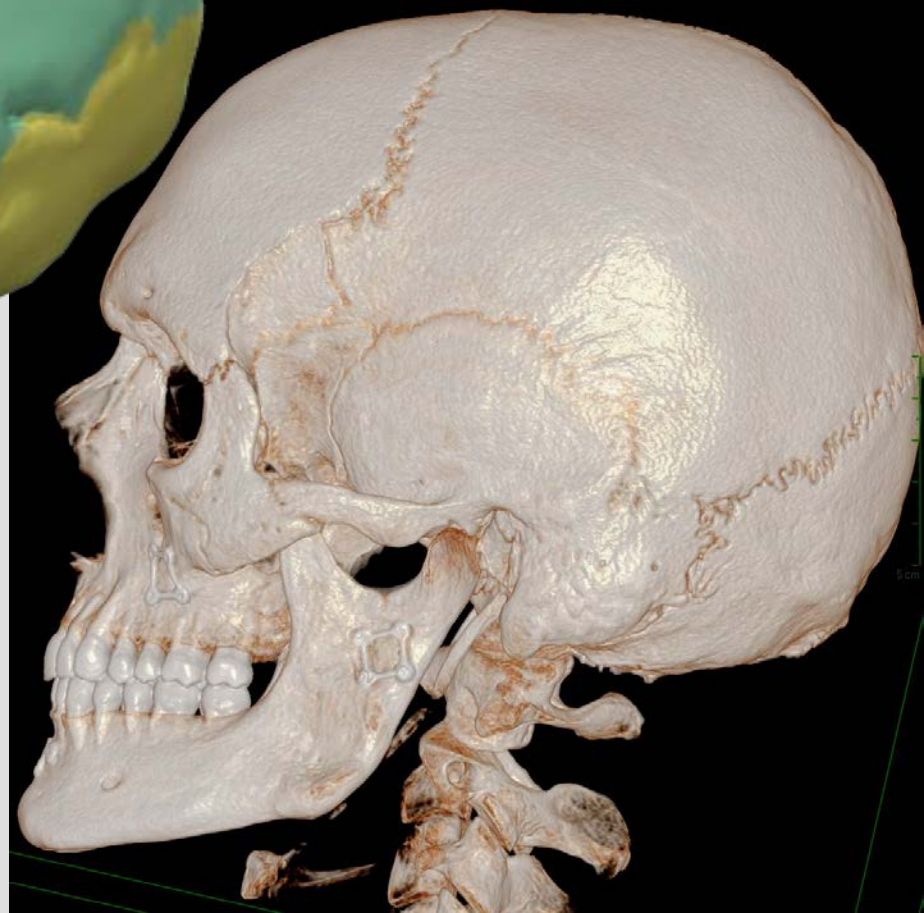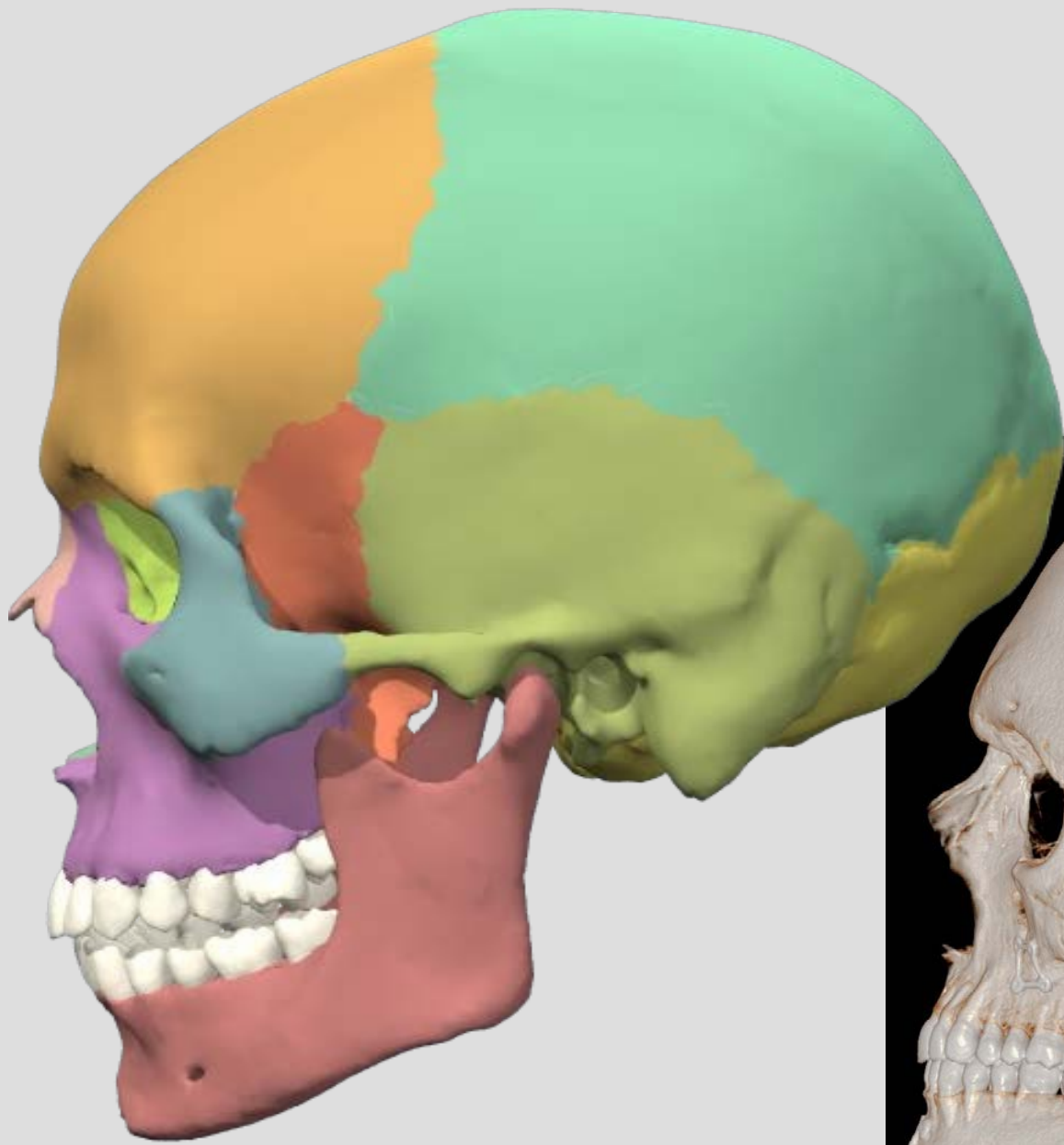
**BARE BONES VERSION**

**Pr. Thierry DUPREZ**

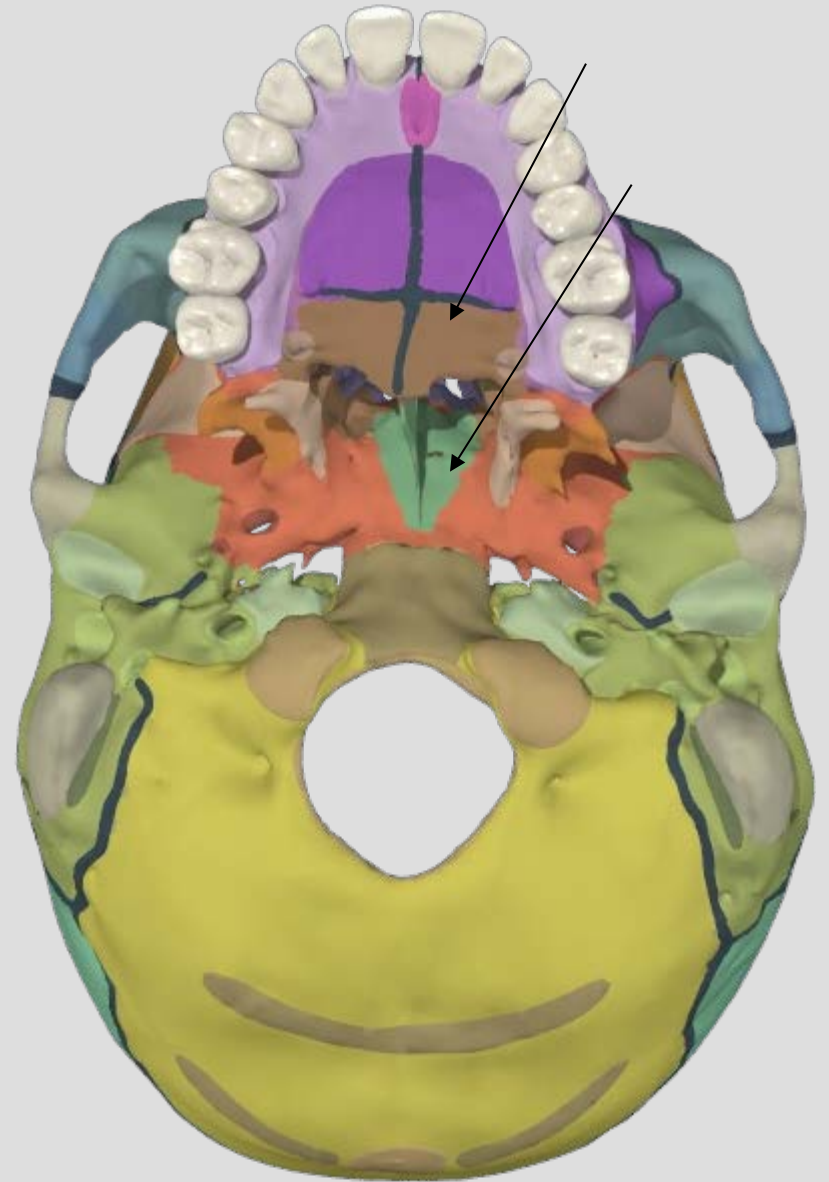
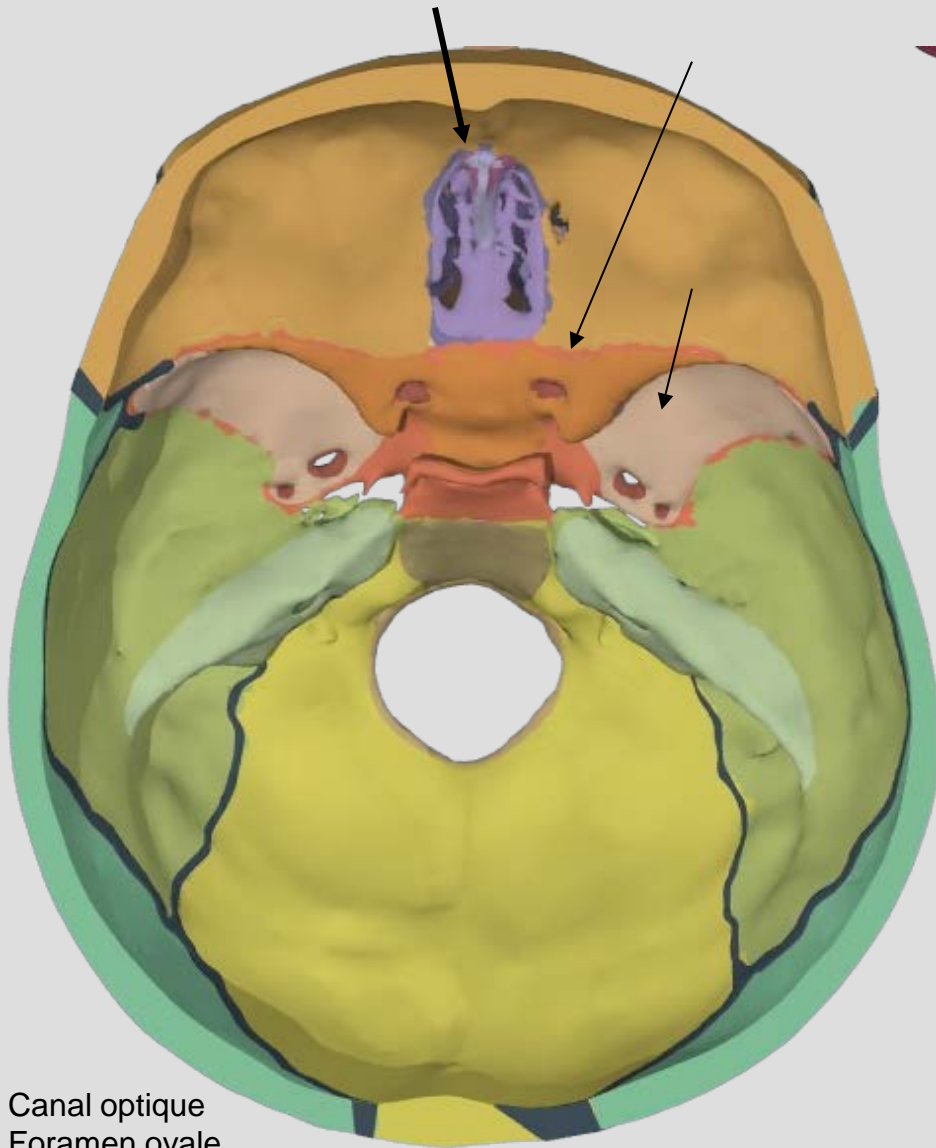
**Module 1: crâne et massif facial**



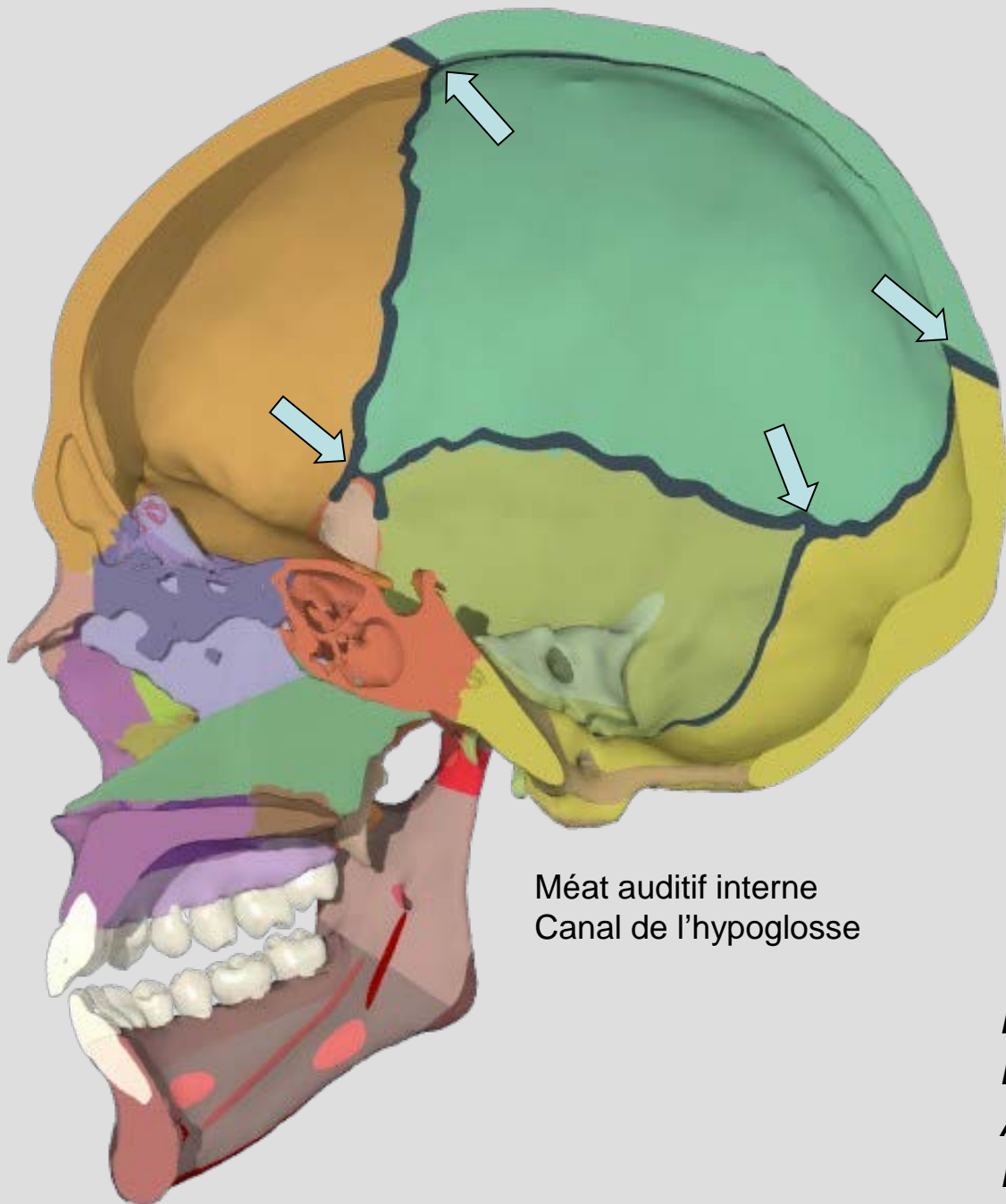






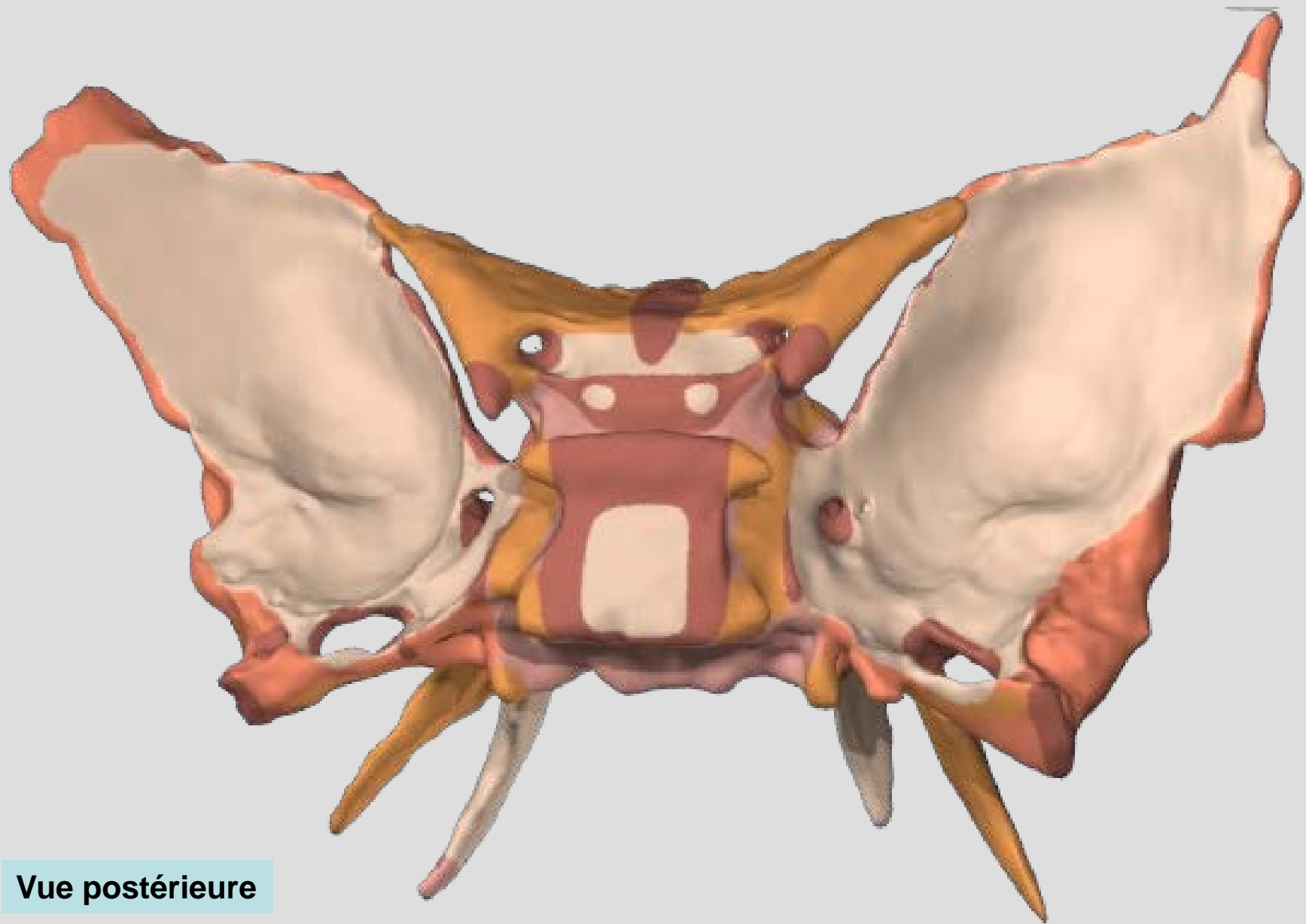


- Canal optique
- Foramen ovale
- Foramen épineux
- Canal carotidien
- Méat auditif interne
- Trou déchiré postérieur
- Lame criblée de l'ethmoïde



Méat auditif interne  
Canal de l'hypoglosse

*Bregma* = fontanelle antérieure  
*Lambda* = fontanelle postérieure  
*Asterion* = fontanelle mastoïde  
*Ptérion* = suture des 4



Vue postérieure