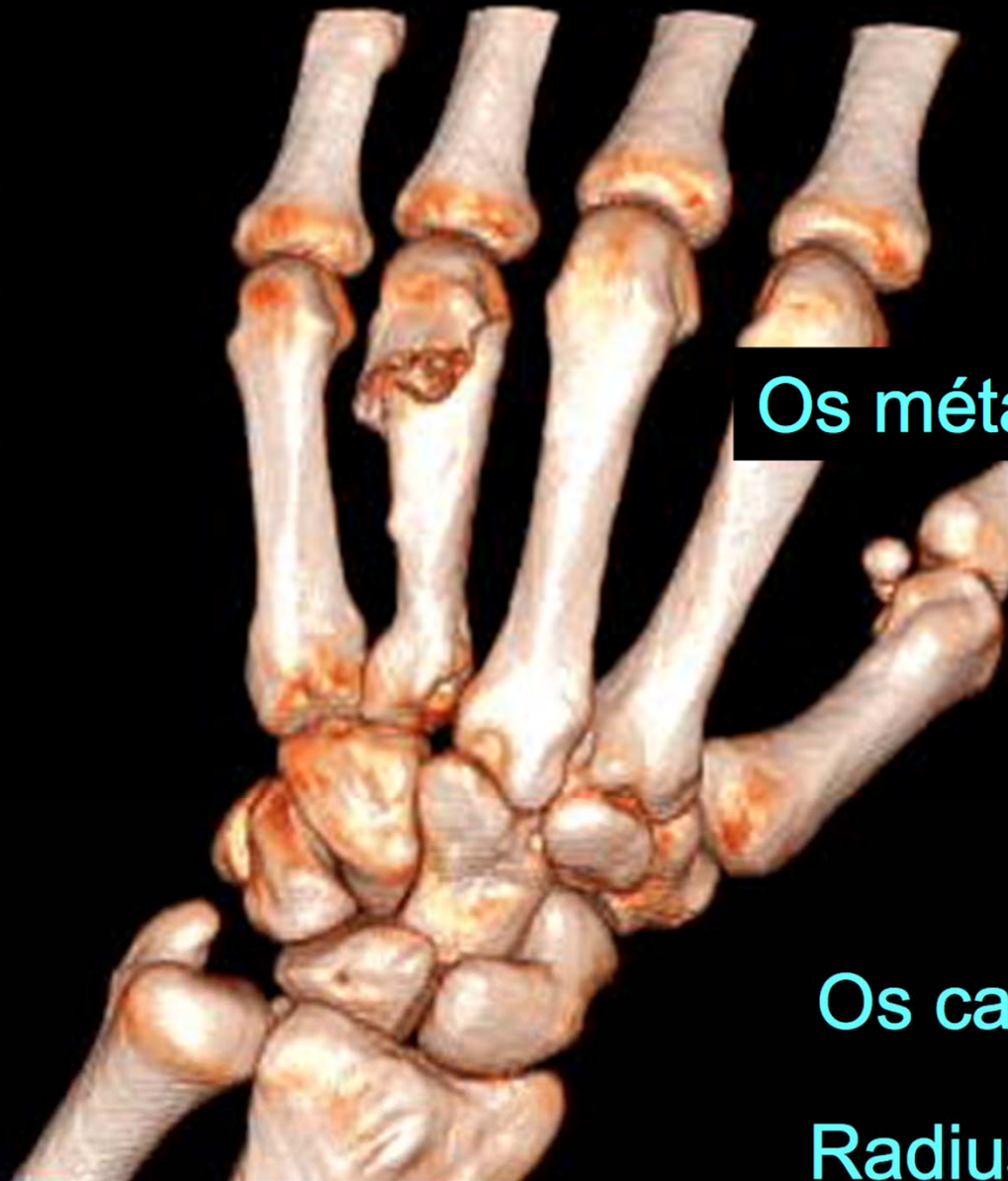


# Notions élémentaires d'imagerie du poignet

2019

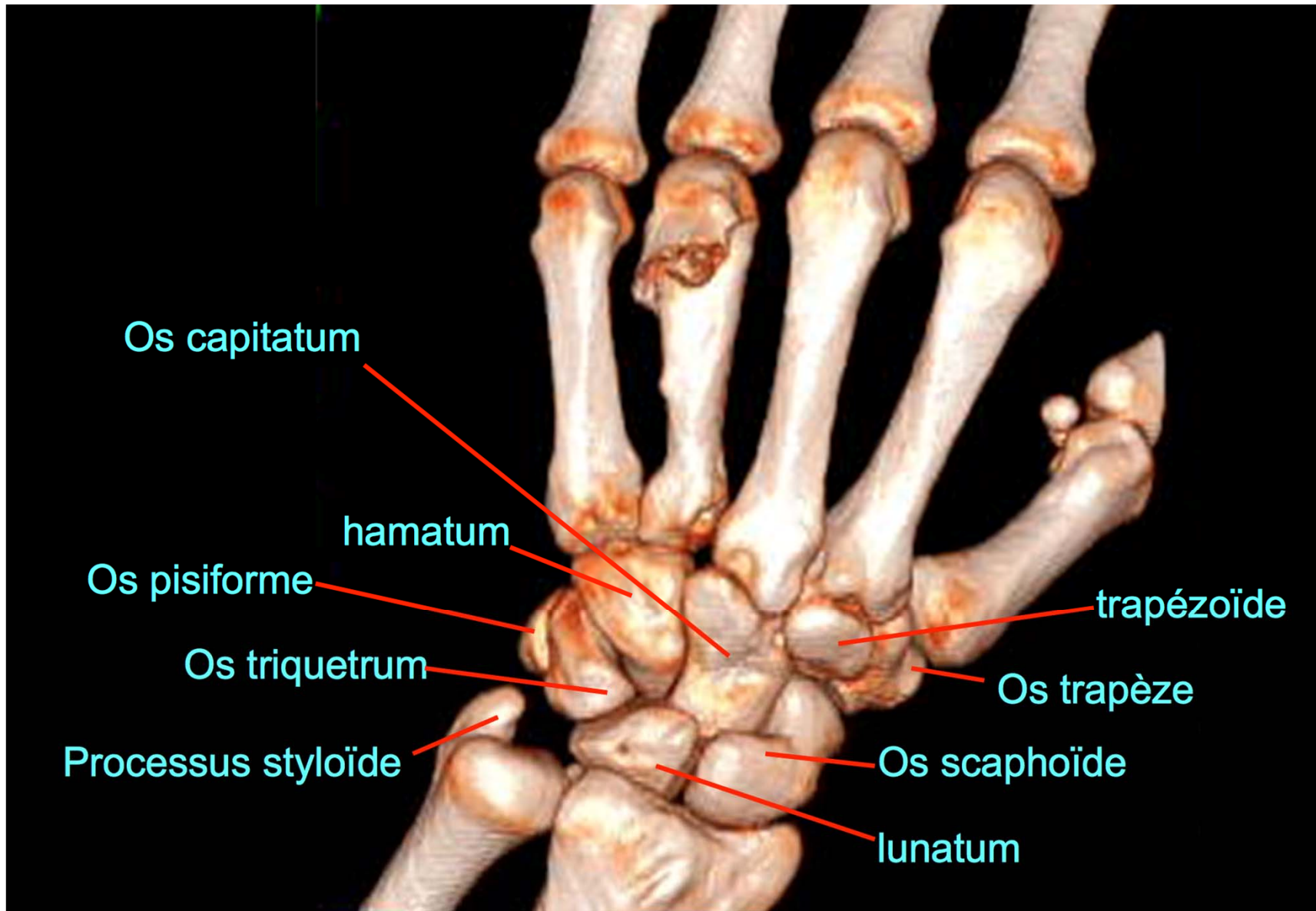
# Vue dorsale



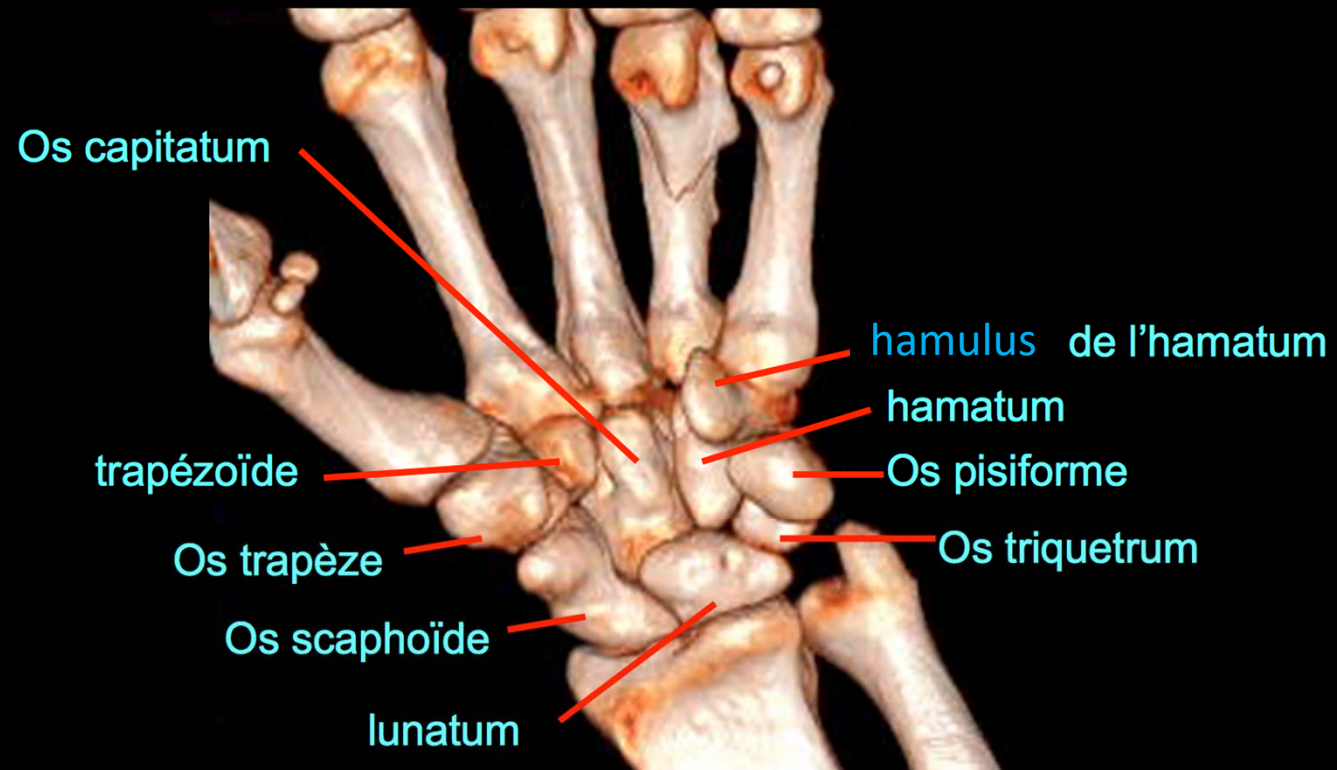
Os métacarpiens

Os carpiens

Radius - ulna

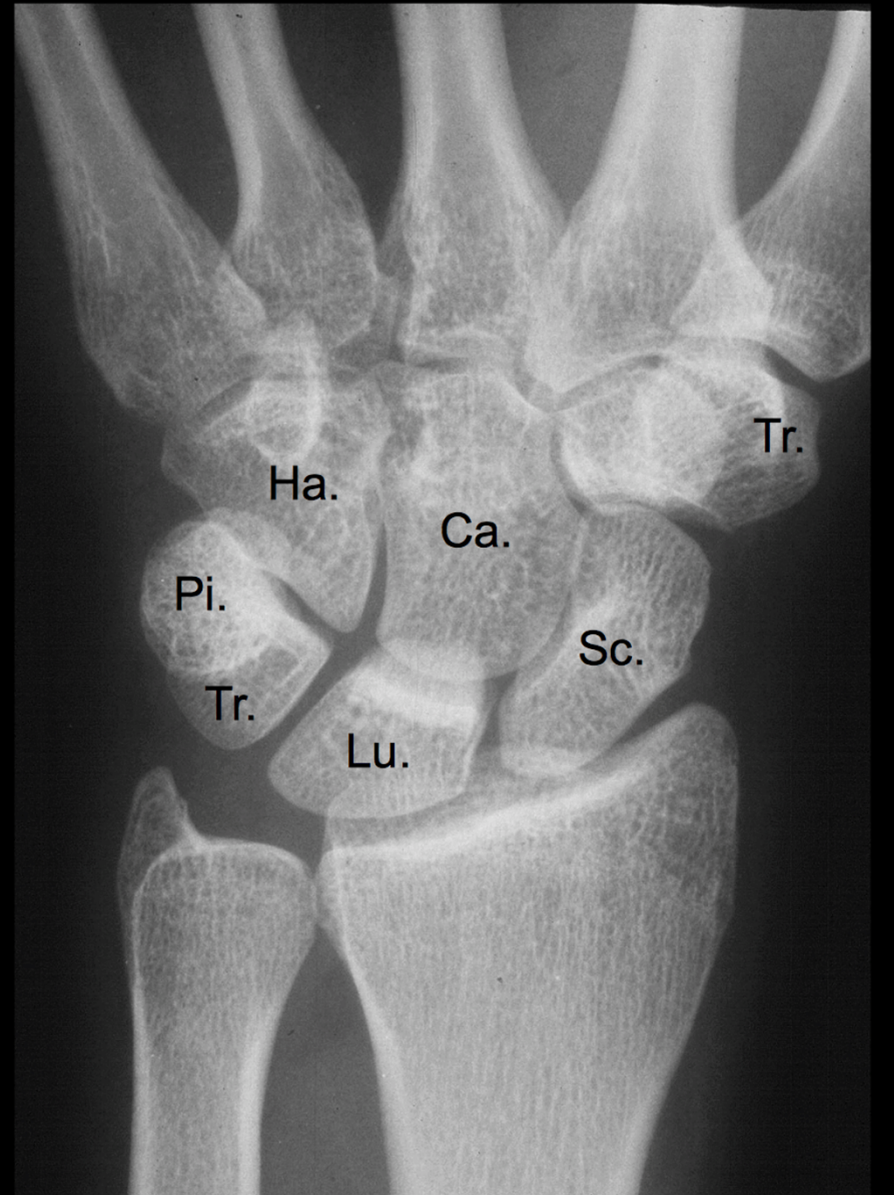
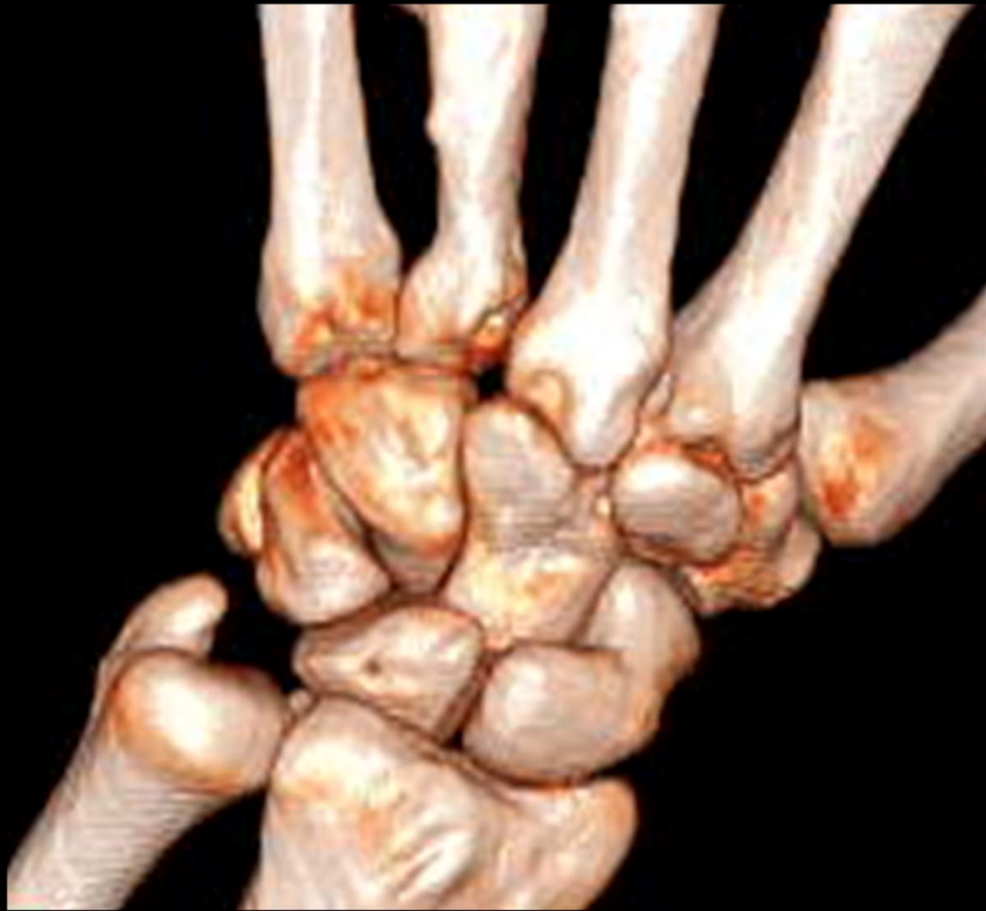

# Vue palmaire

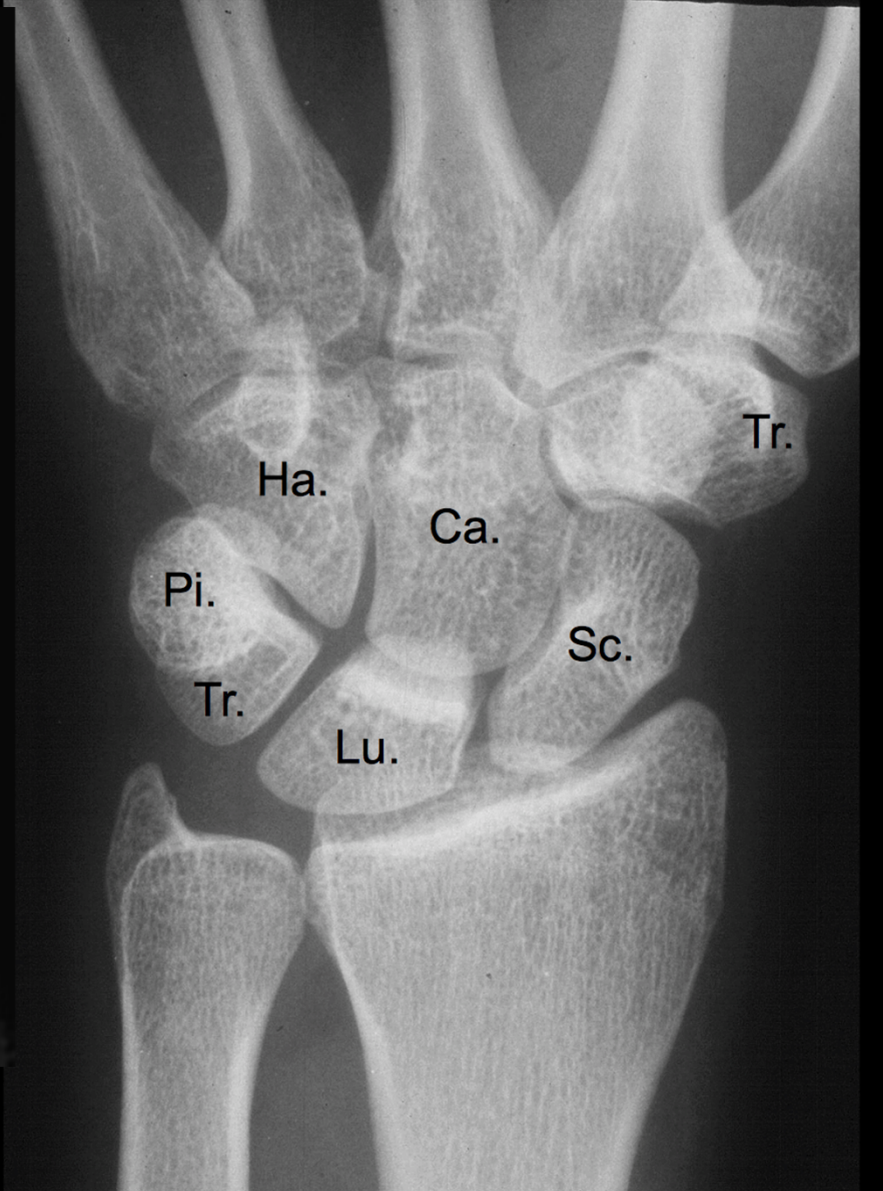
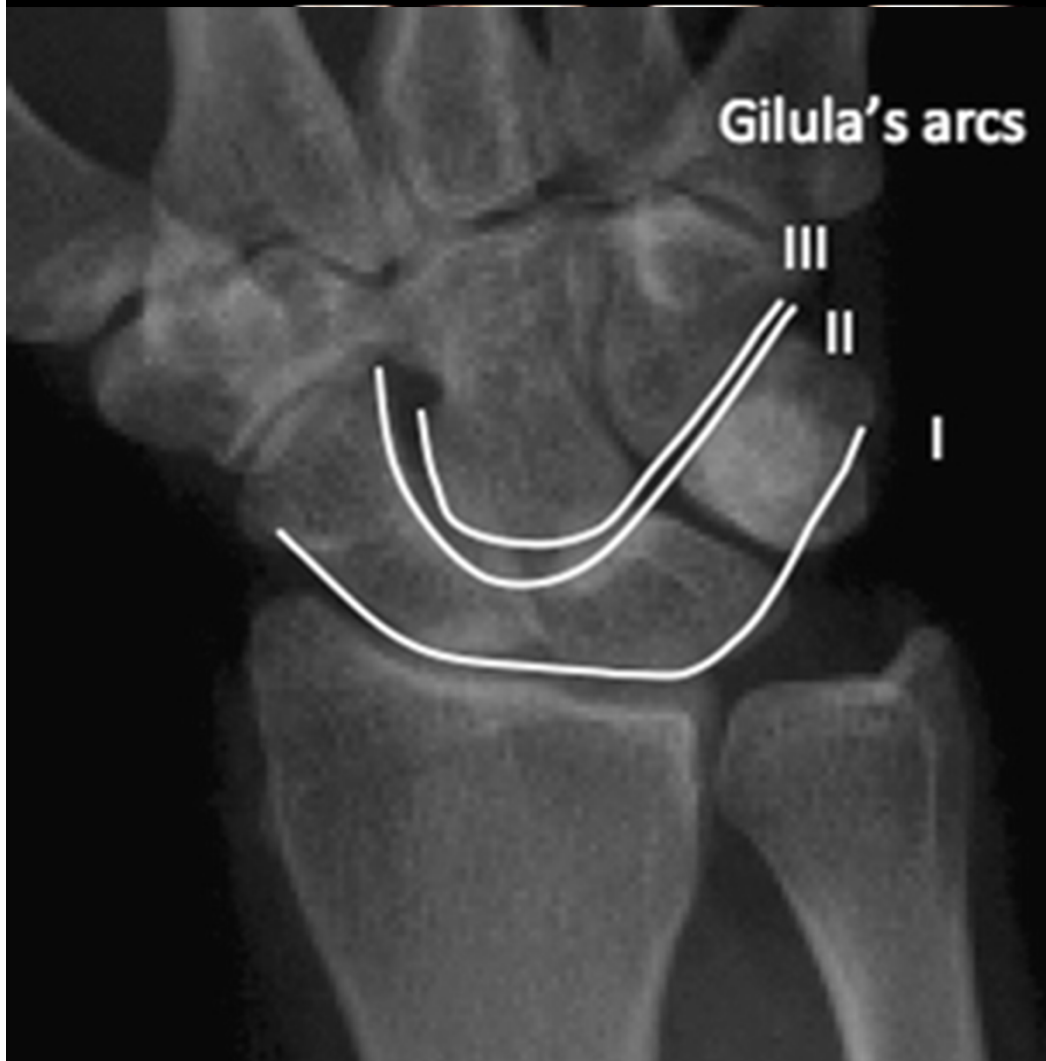



# Incidence radiographique de face

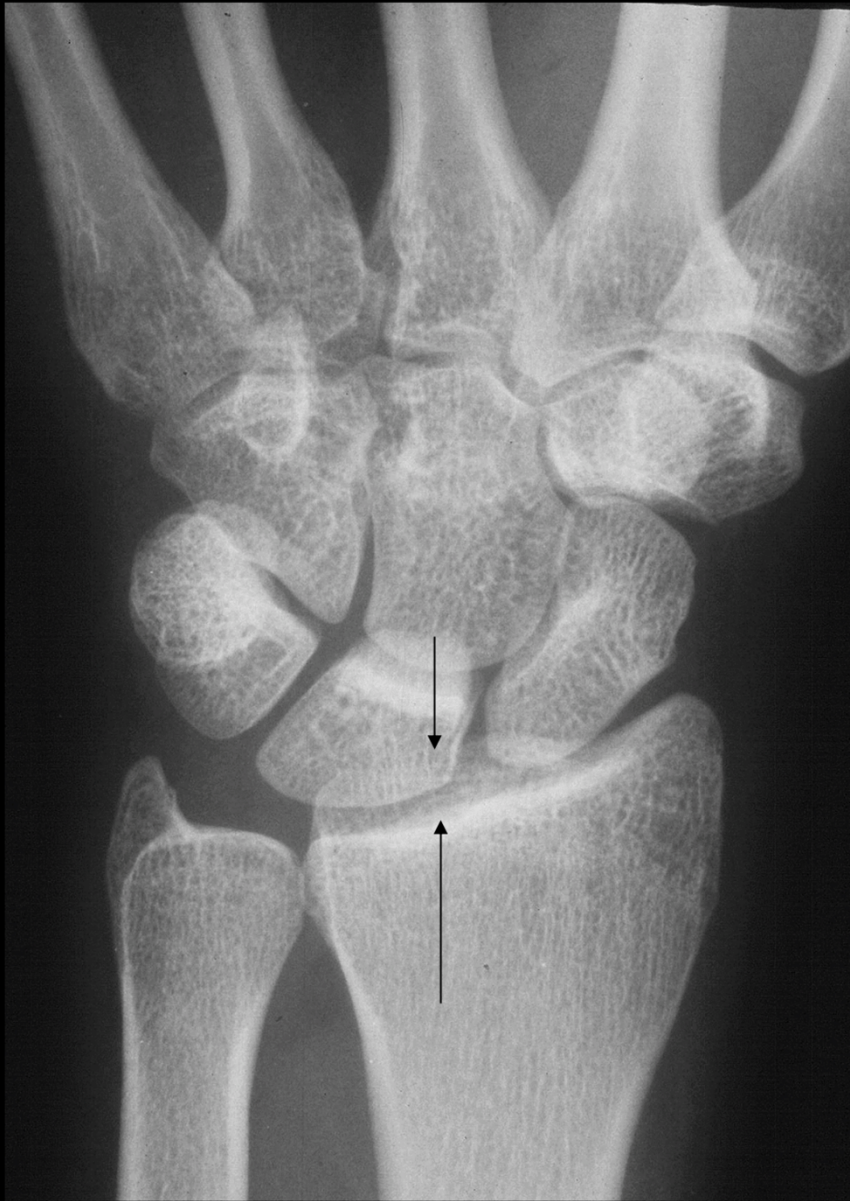

# Incidence radiographique de face

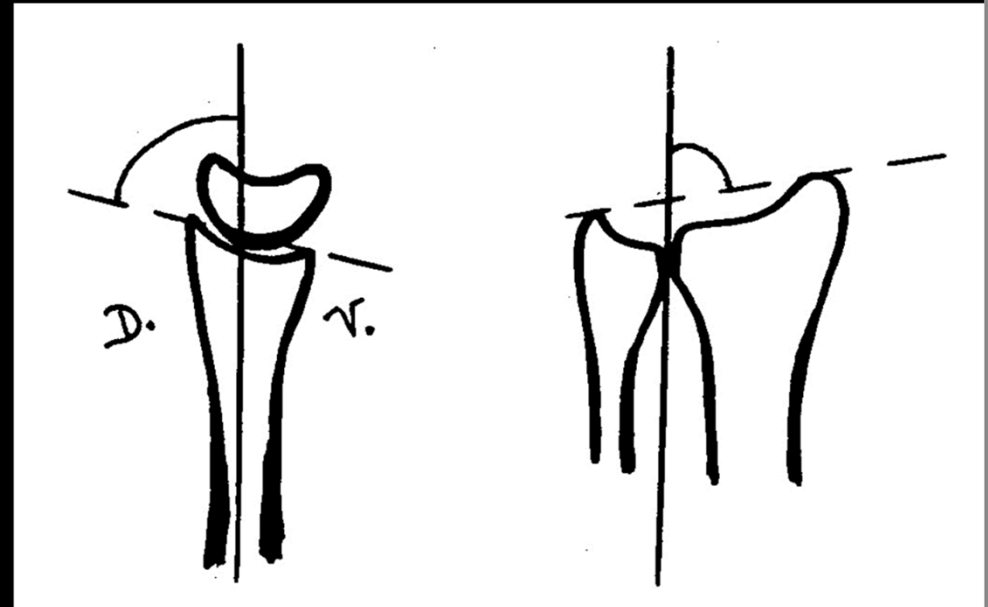


[https://www.researchgate.net/profile/Philip\\_Blazar/publication/26781722/figure/fig1/AS:202568669110280@1425307542693/Radiograph-showing-Gilula%27s-arcs-Three-smooth-arcs-normally-outline-proximal-arc-I-and.png](https://www.researchgate.net/profile/Philip_Blazar/publication/26781722/figure/fig1/AS:202568669110280@1425307542693/Radiograph-showing-Gilula%27s-arcs-Three-smooth-arcs-normally-outline-proximal-arc-I-and.png)

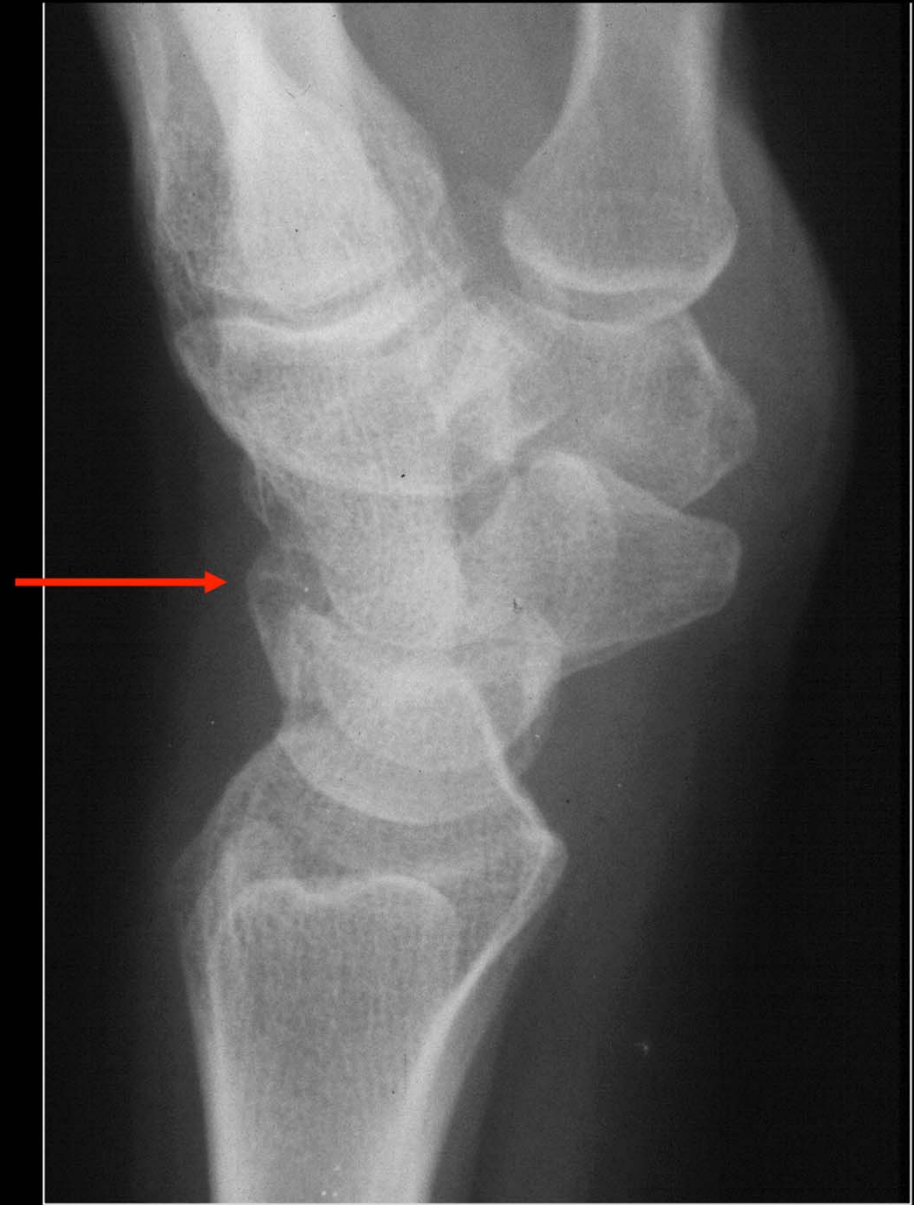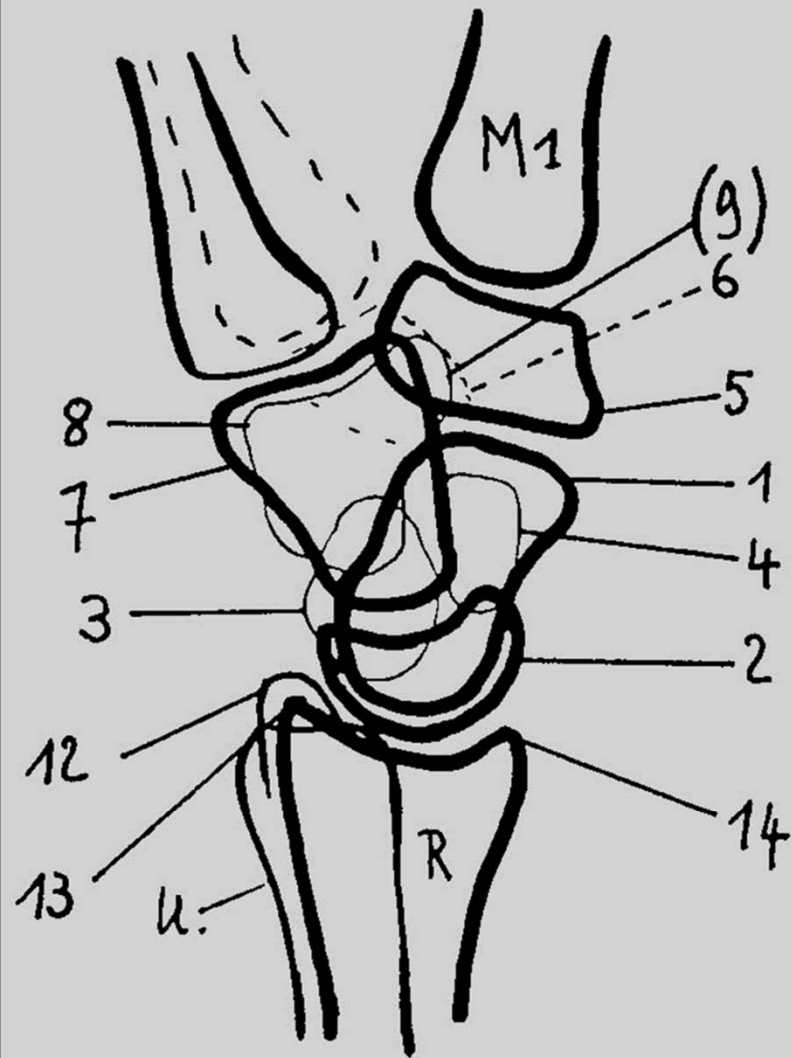




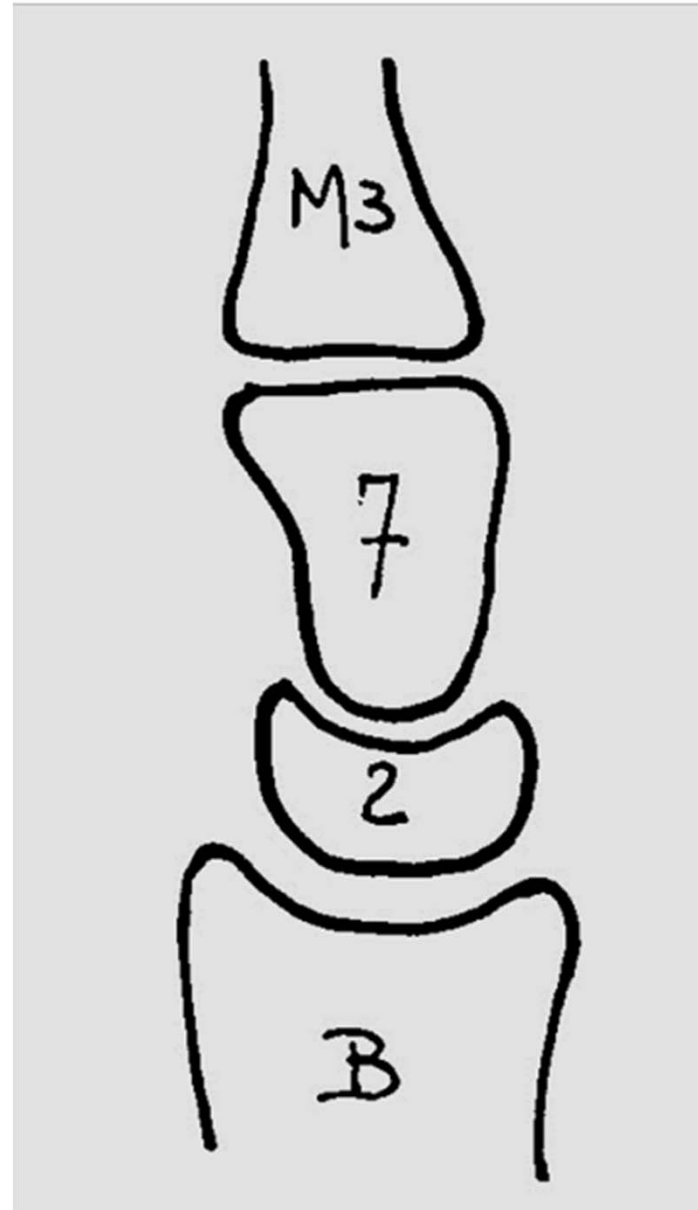
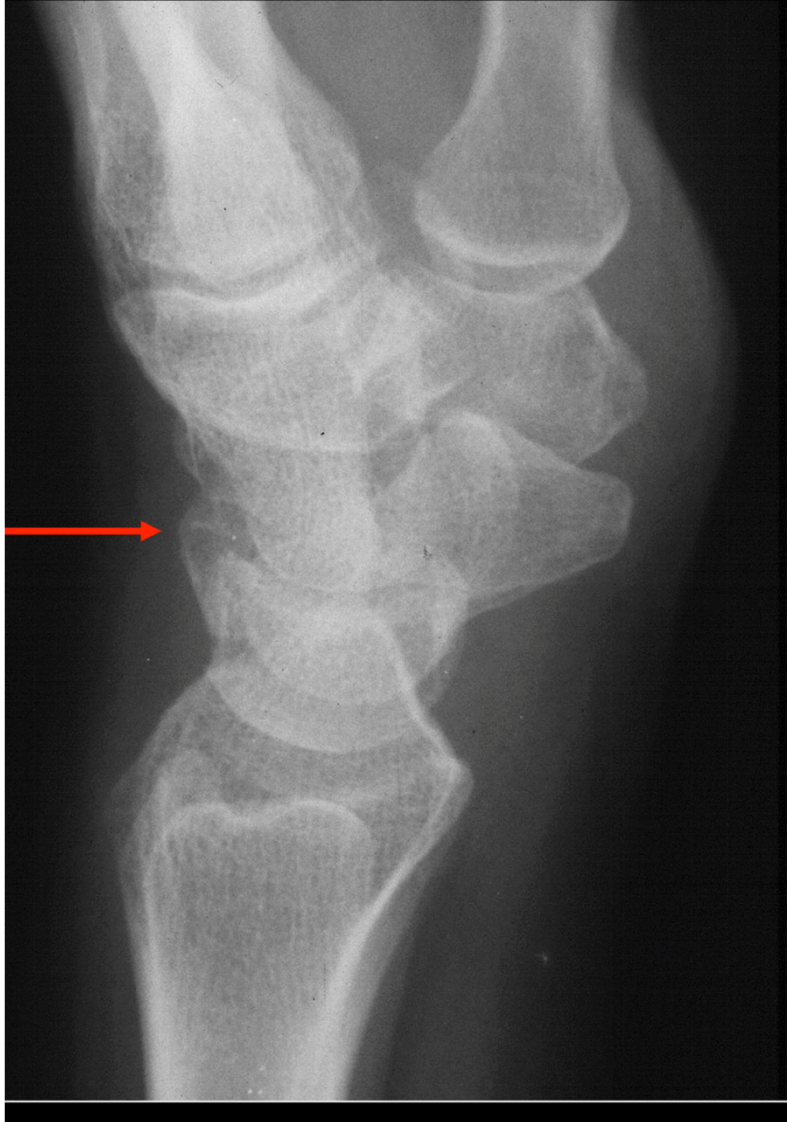Bascule ventrale  
de la surface articulaire  
distale du radius



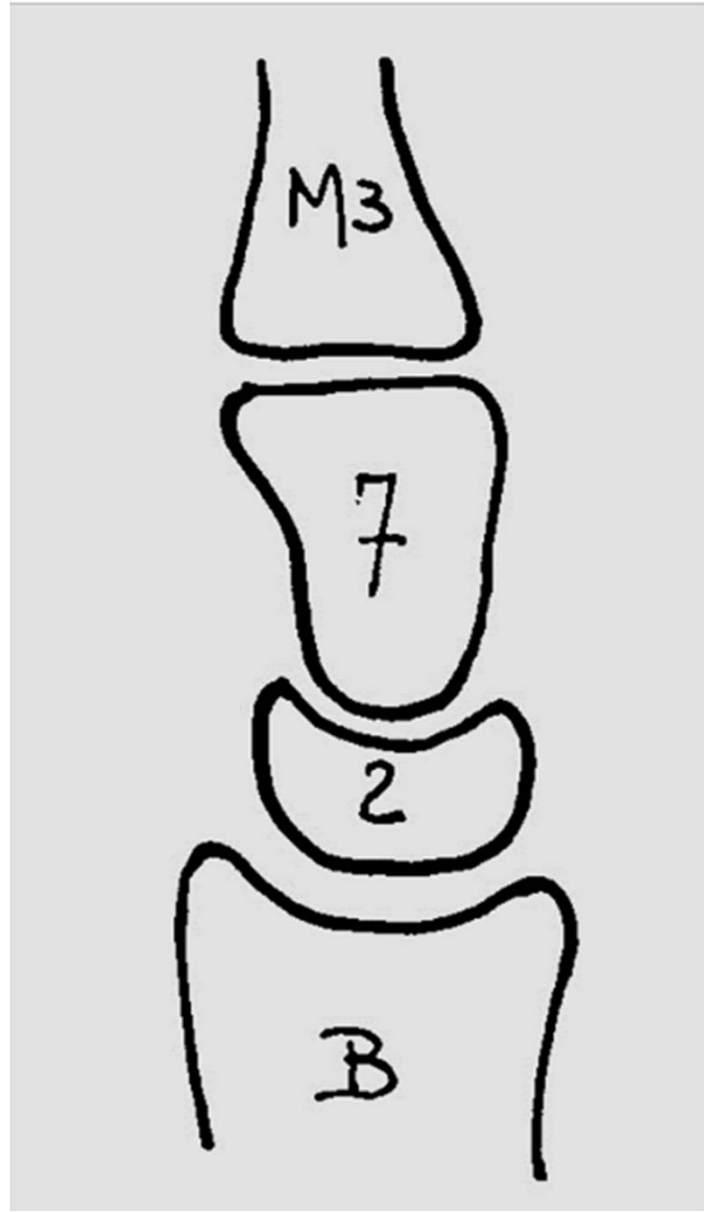
# Incidence radiographique de prof



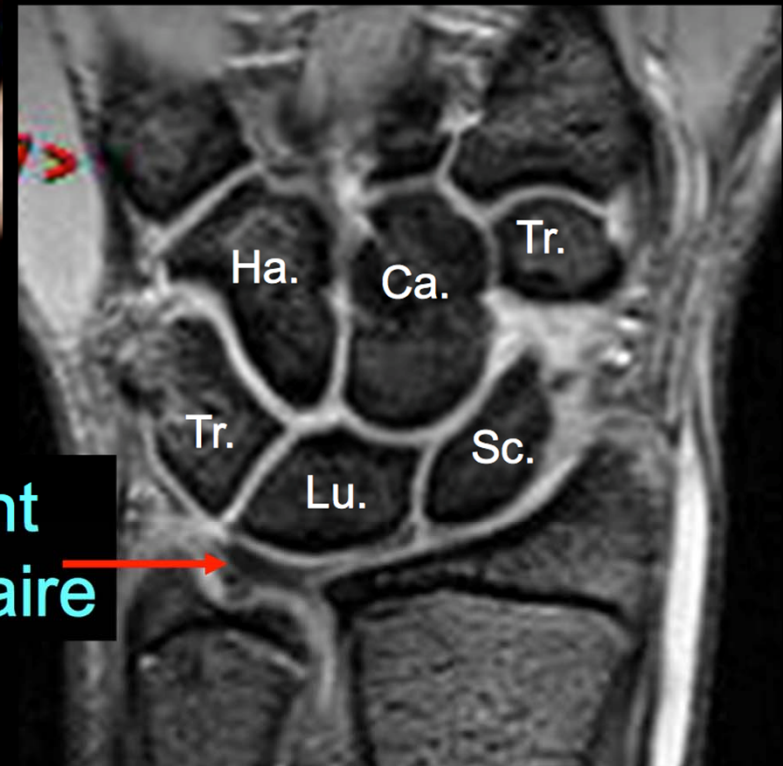
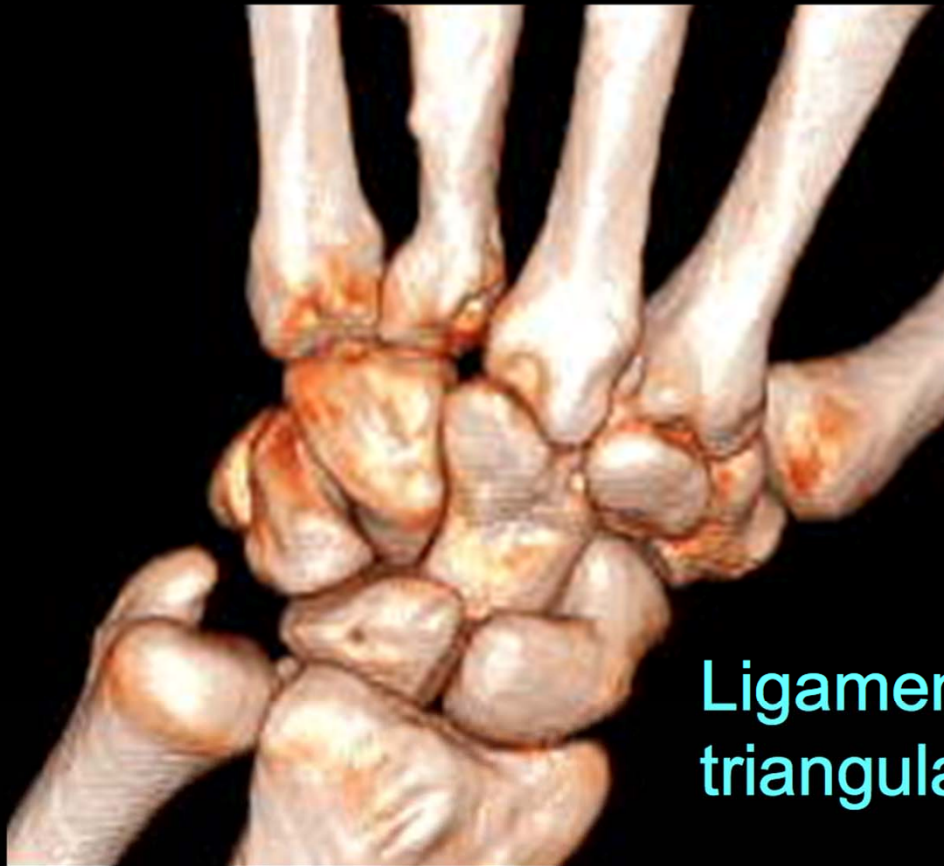
ence radiographique de prof

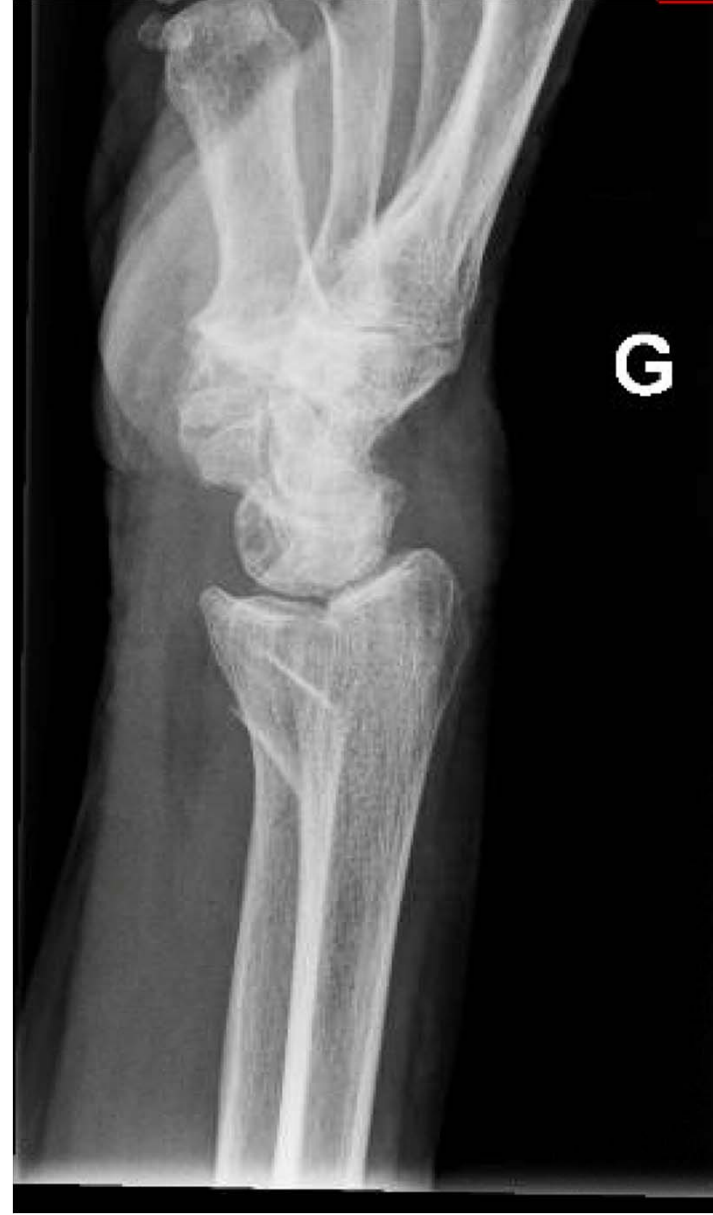
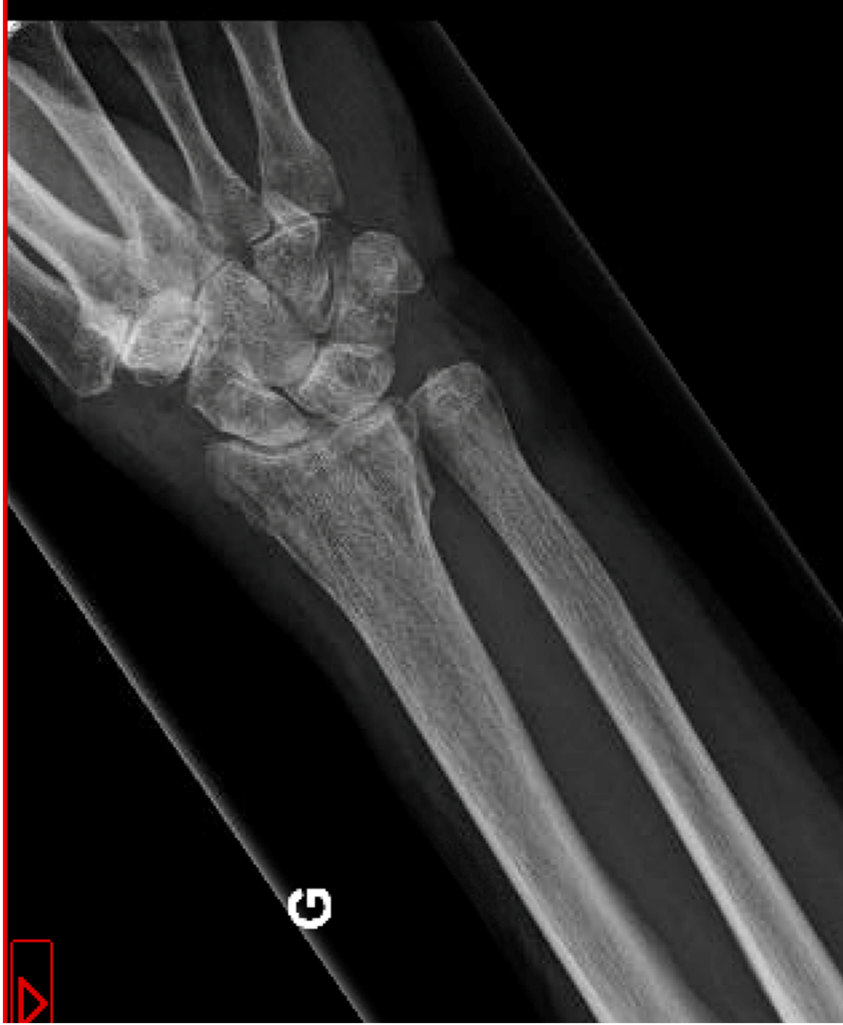


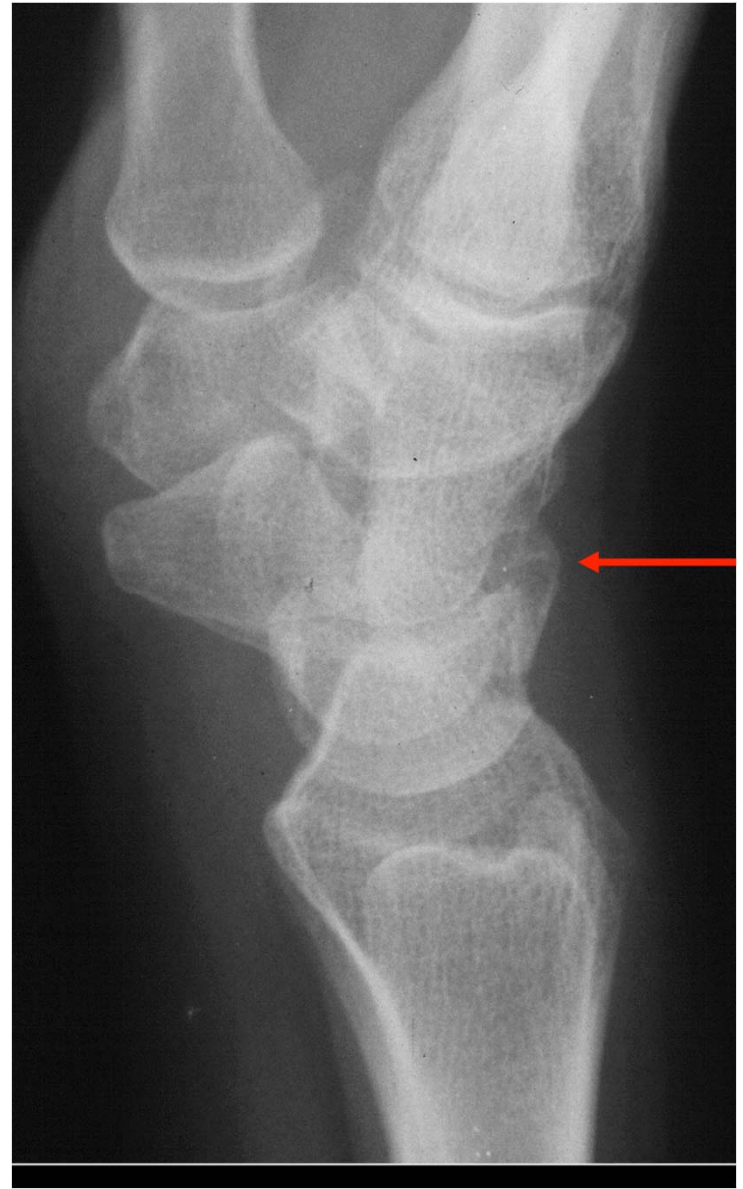
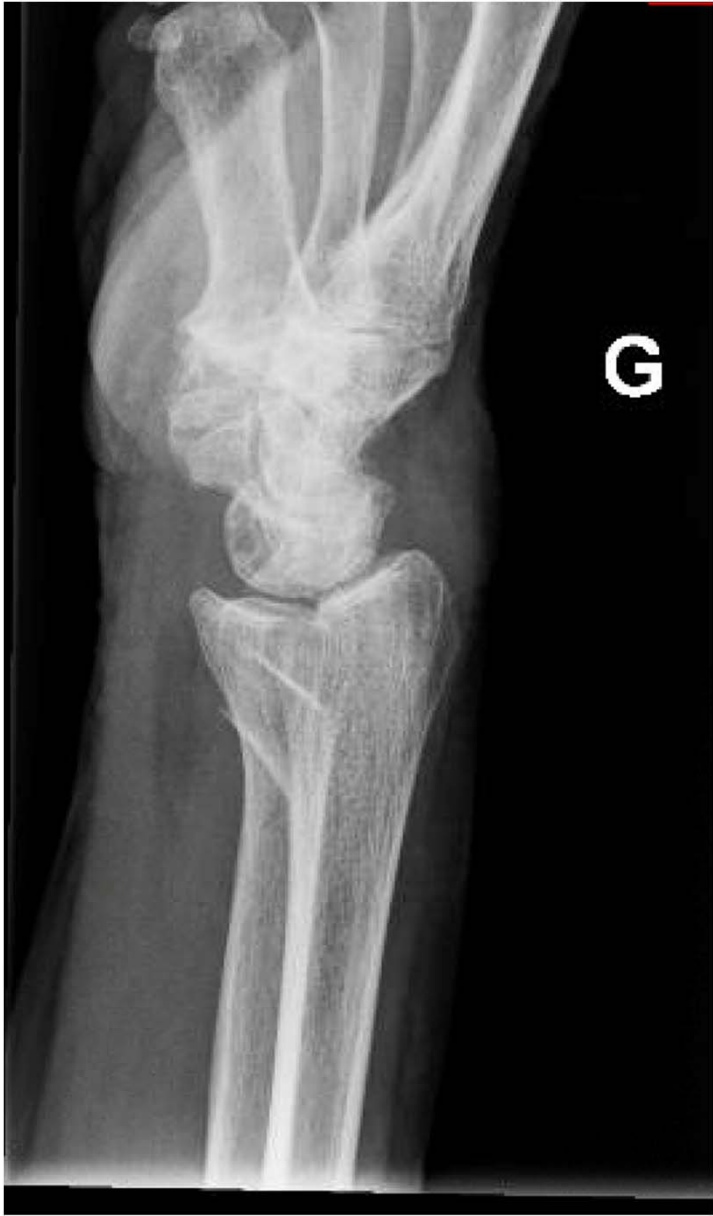
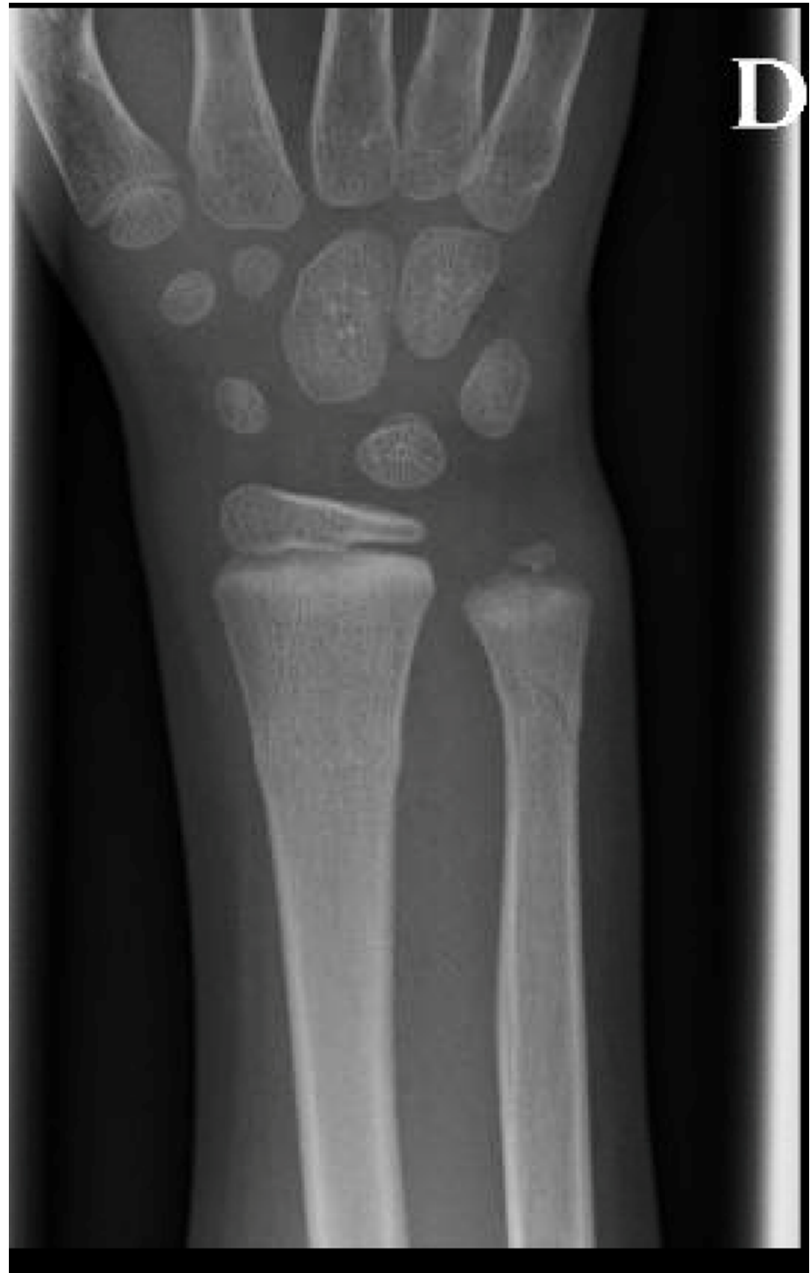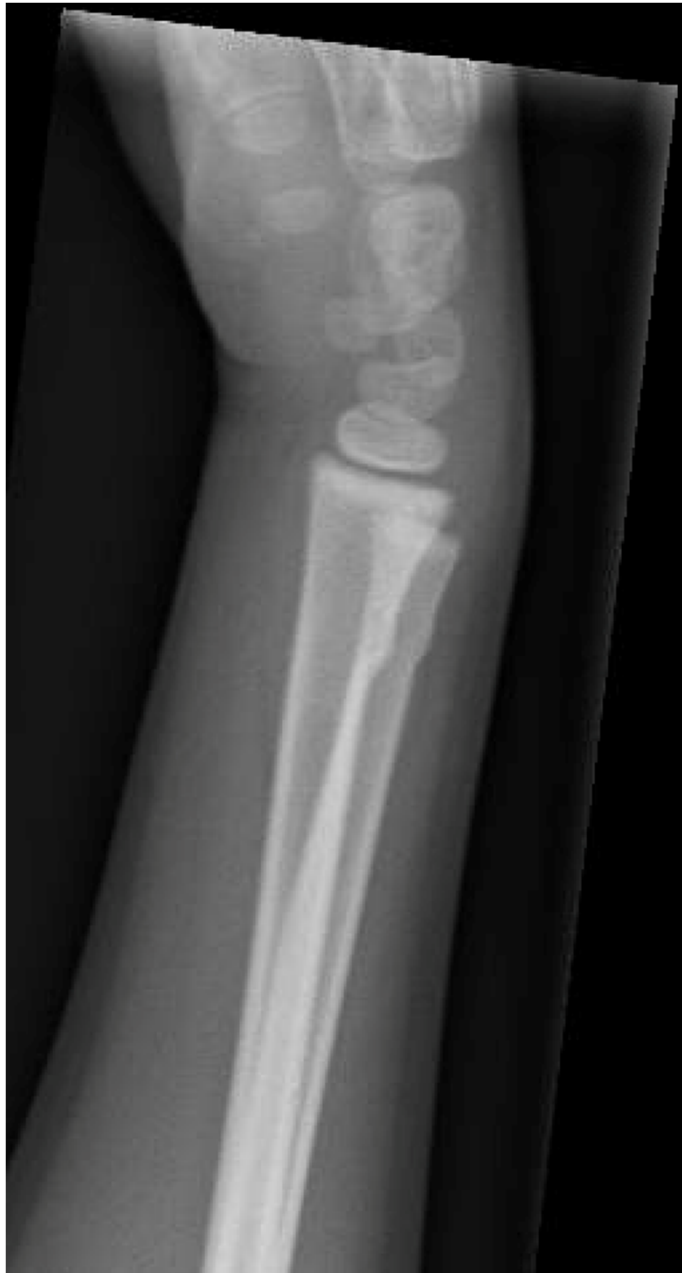Ligament triangulaire: « ménisque » interposé entre ulna et lunatum



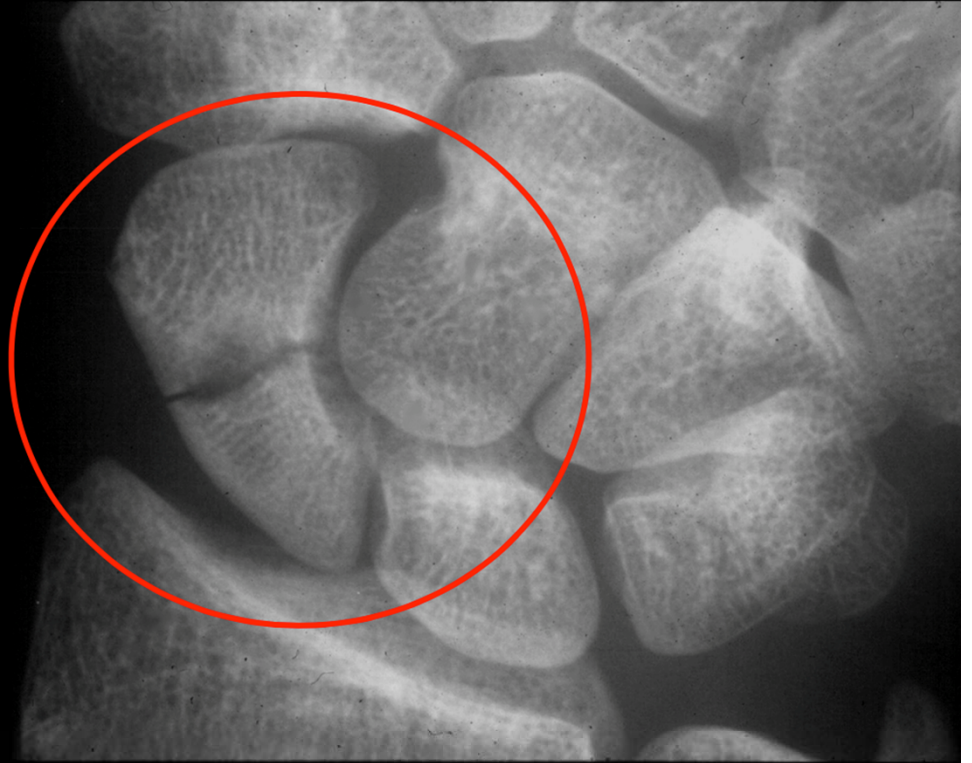
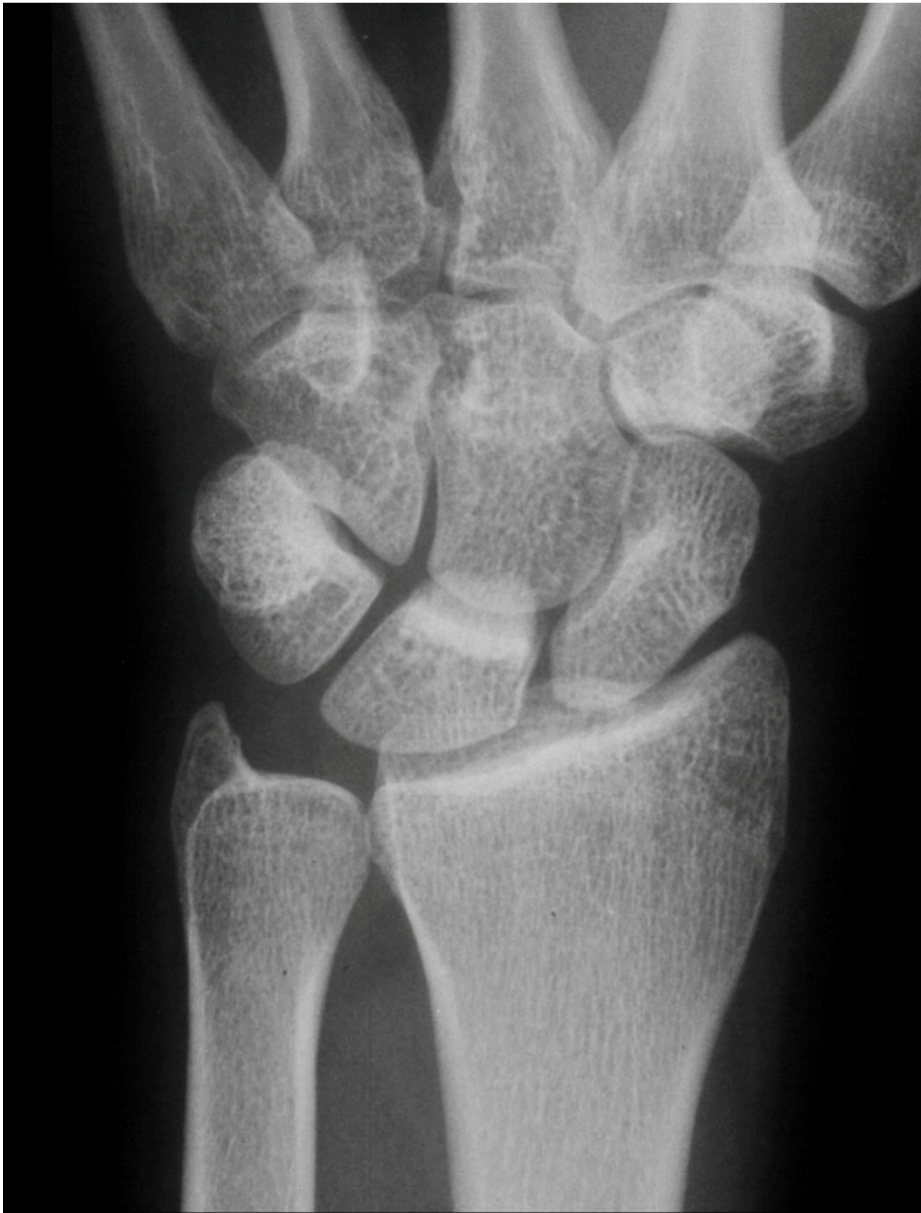


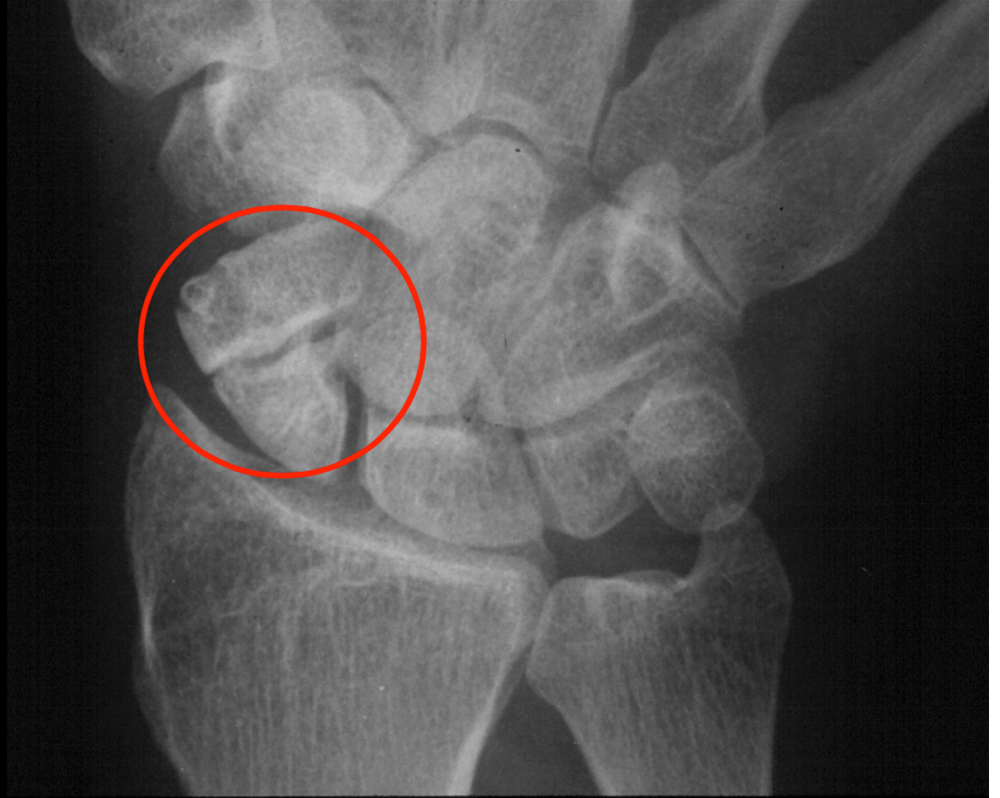


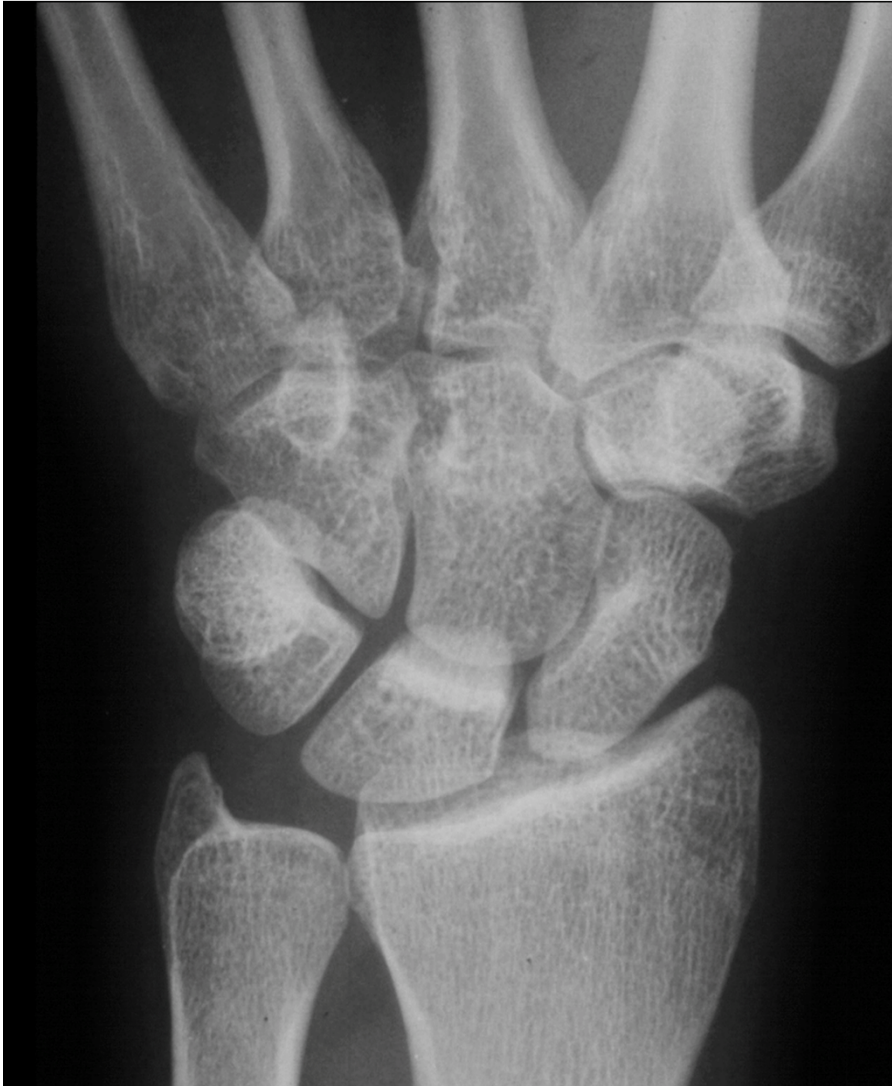



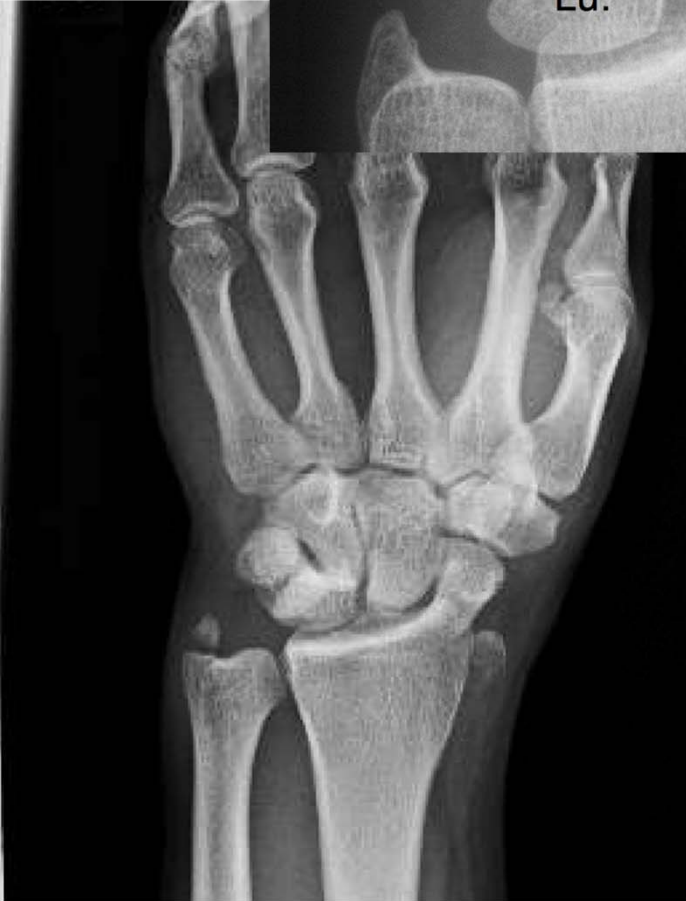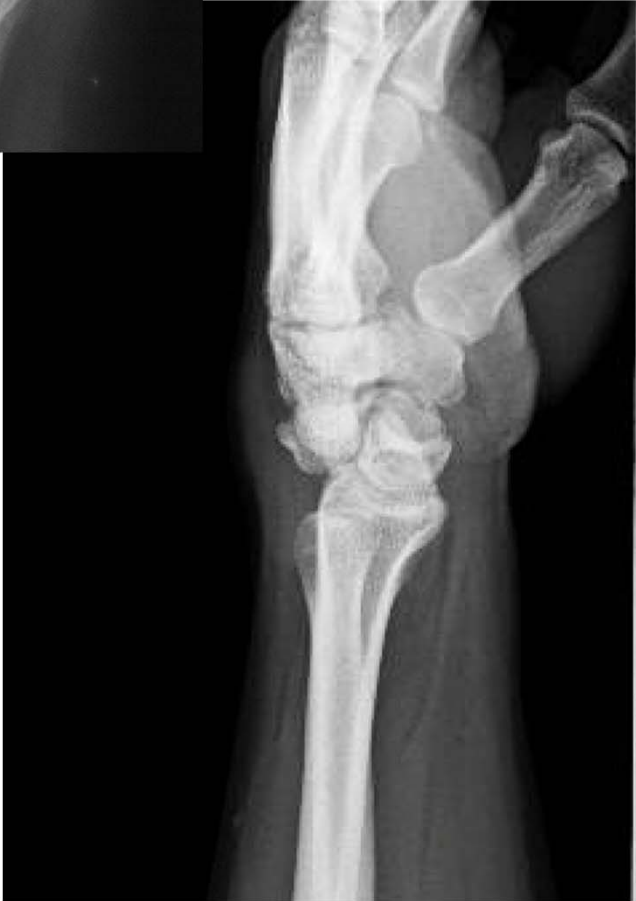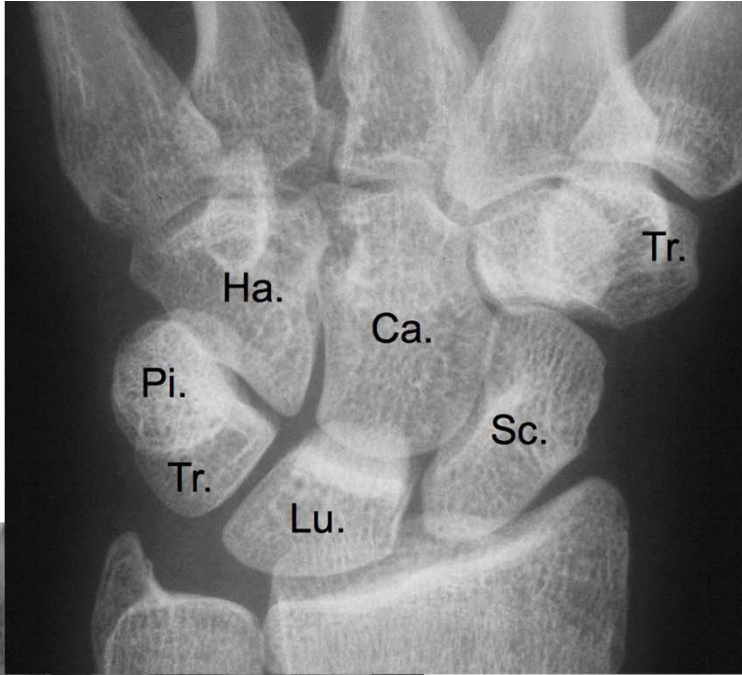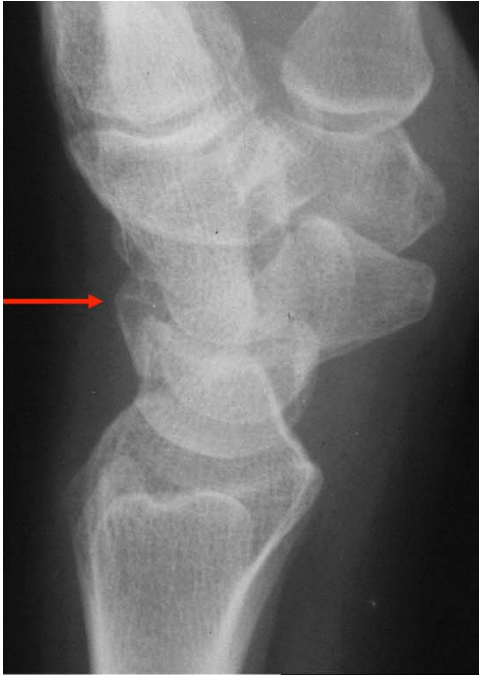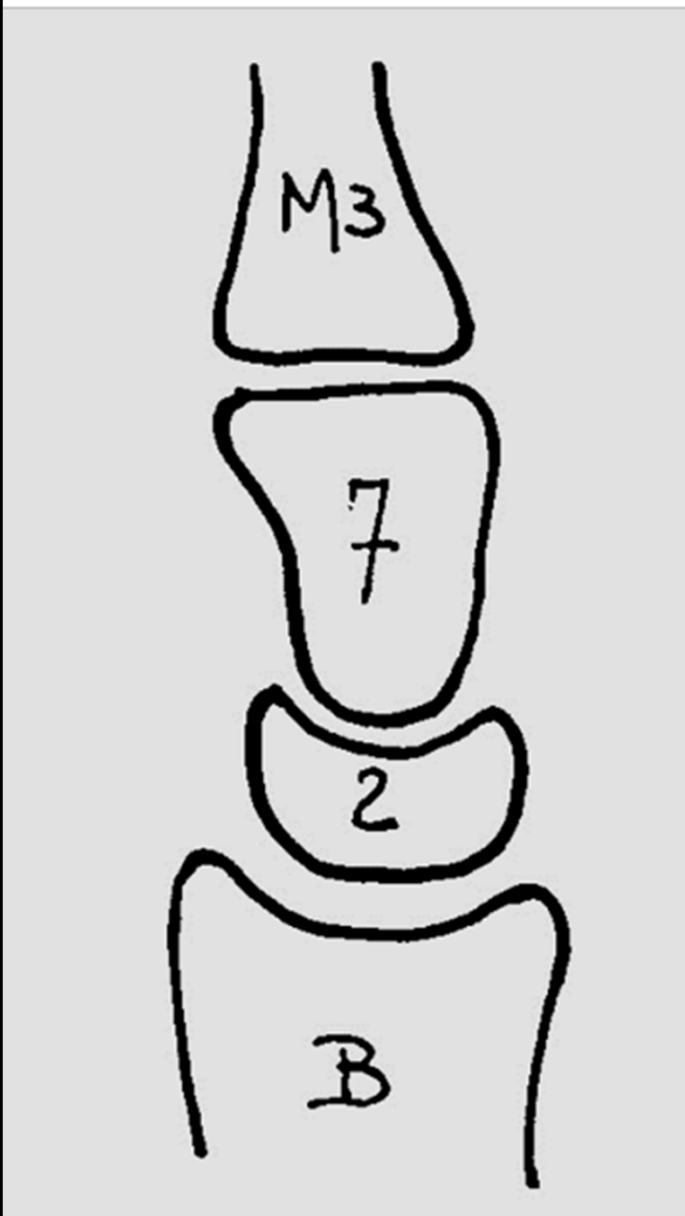


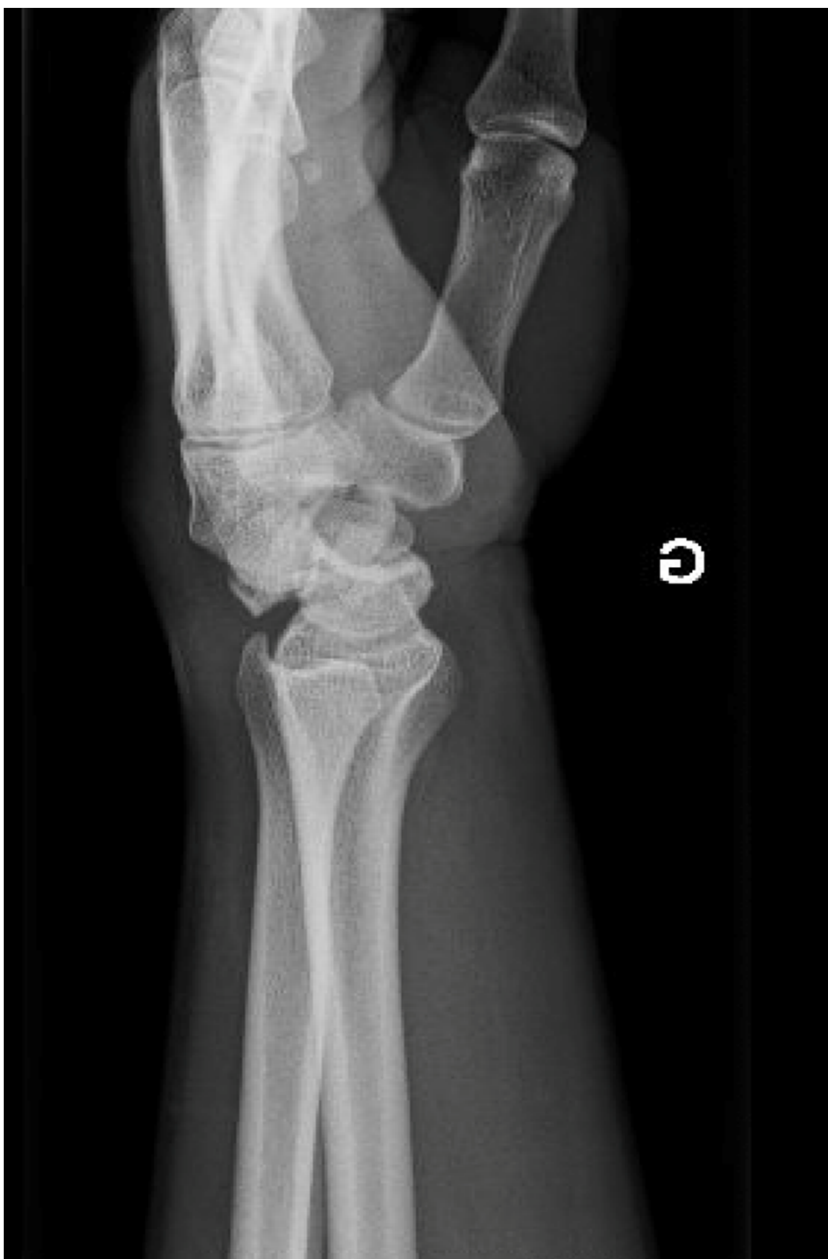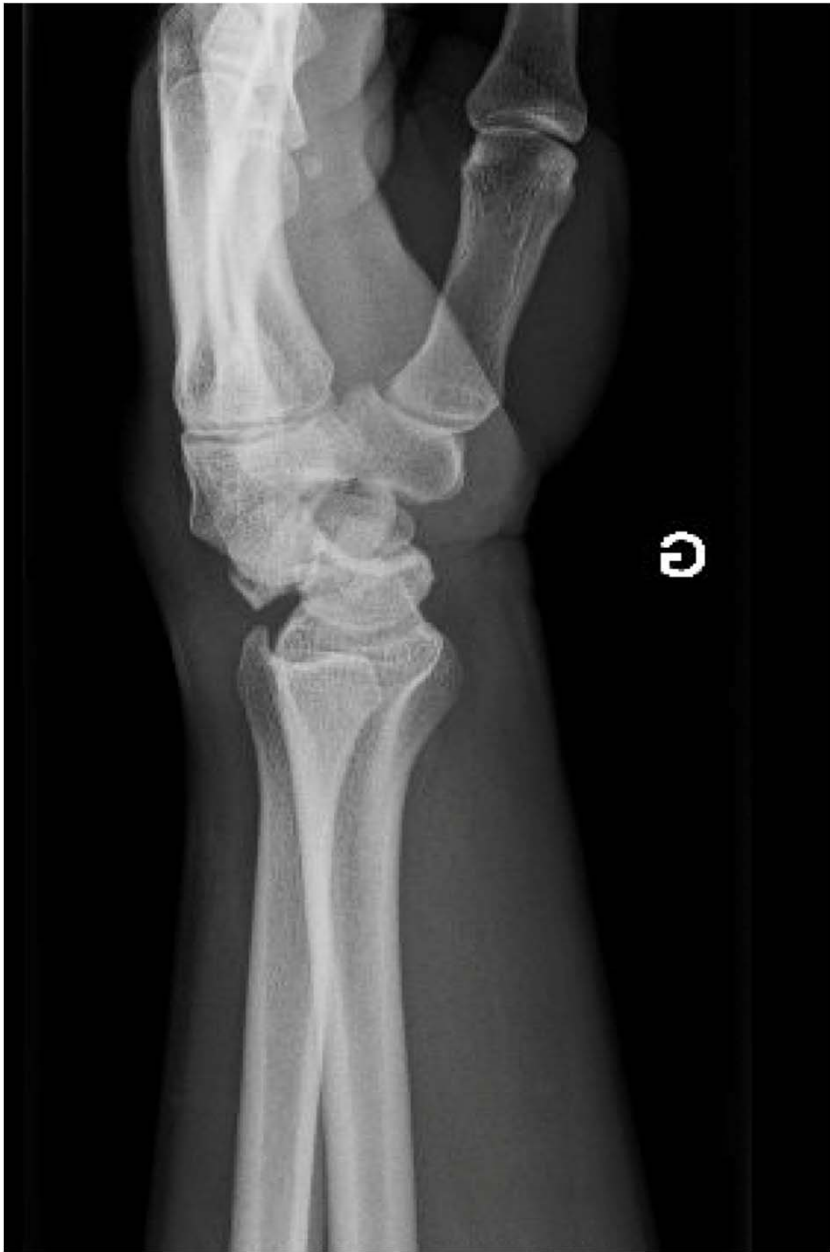Scaphoïde



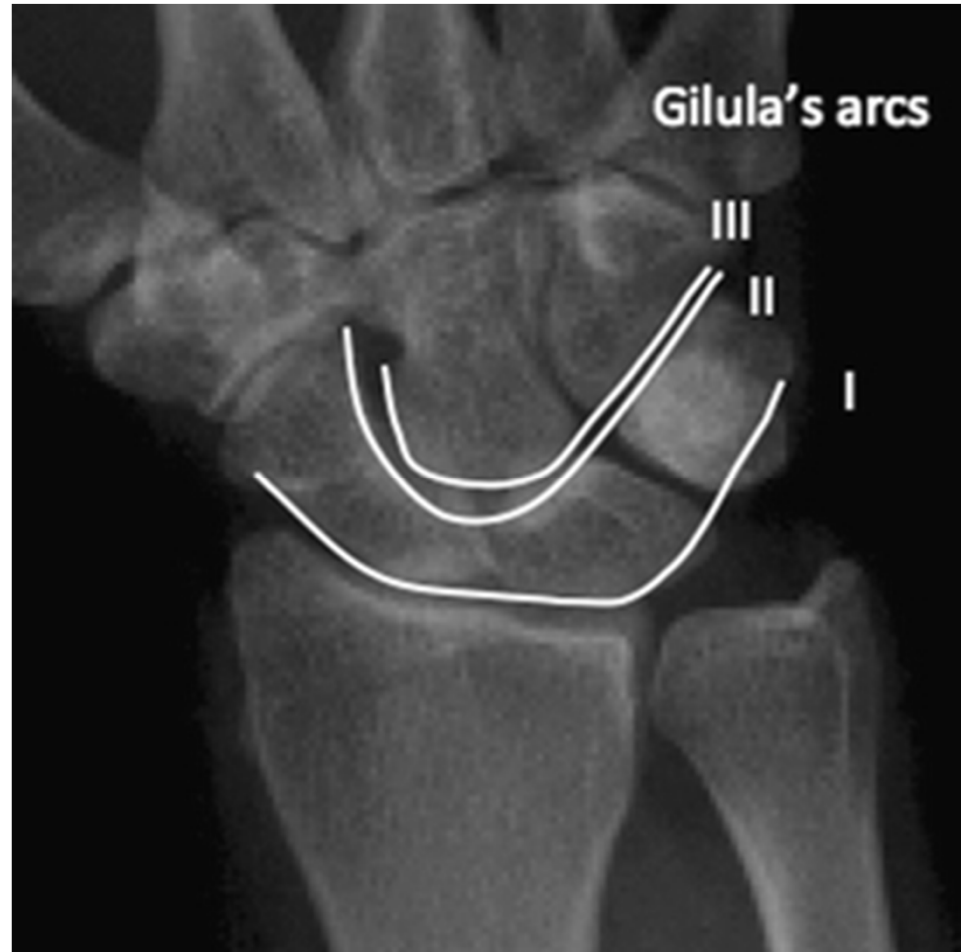
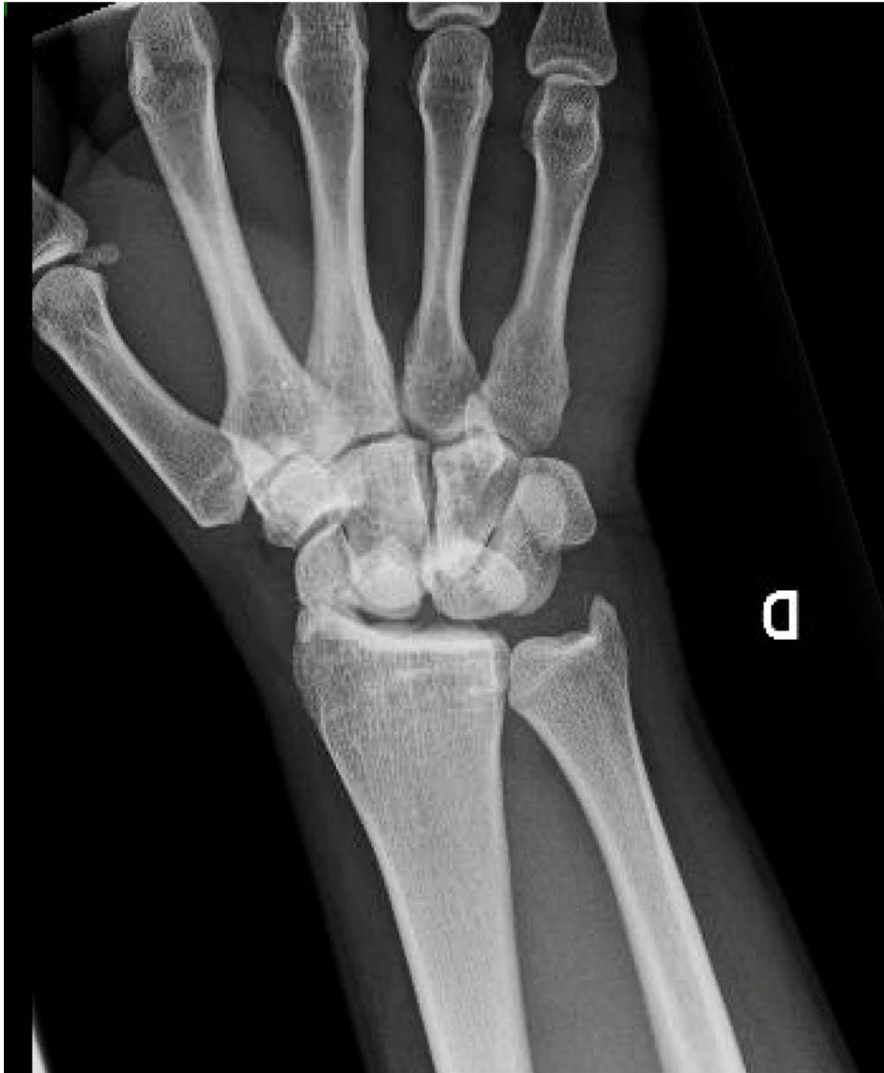










[https://www.researchgate.net/profile/Philip\\_Blazar/publication/26781722/figure/fig1/AS:202568669110280@1425307542693/Radiograph-showing-Gilula%27s-arcs-Three-smooth-arcs-normally-outline-proximal-arc-I-and.png](https://www.researchgate.net/profile/Philip_Blazar/publication/26781722/figure/fig1/AS:202568669110280@1425307542693/Radiograph-showing-Gilula%27s-arcs-Three-smooth-arcs-normally-outline-proximal-arc-I-and.png)