



Secteur des Sciences de la santé

Faculté de Médecine

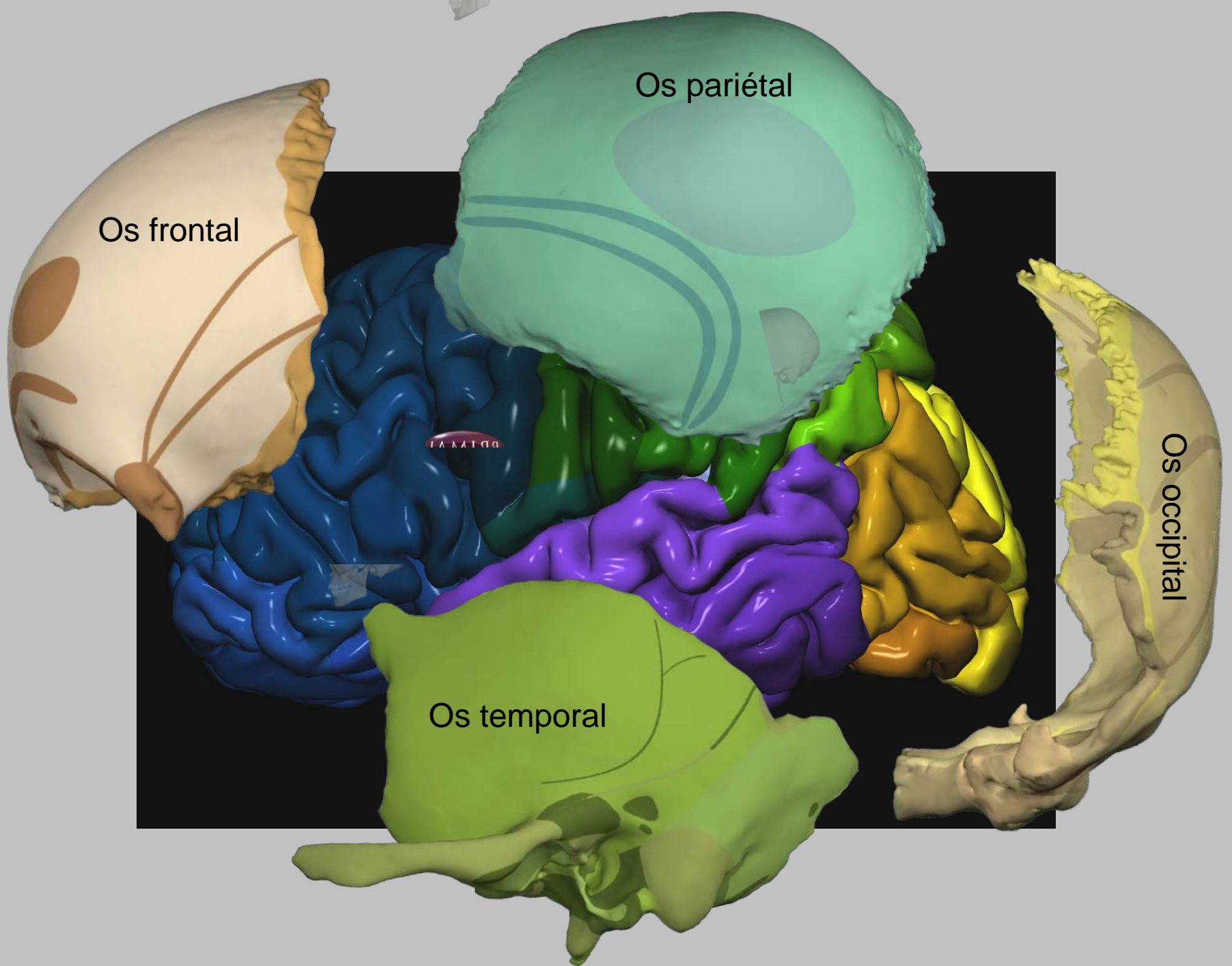
Cours WMDS ANAT 1311

Année académique 2019-2020

Neuroanatomie radiologique

Pr. Thierry DUPREZ

Module 3: anatomie de la corticalité




Lobe **FRONTAL**



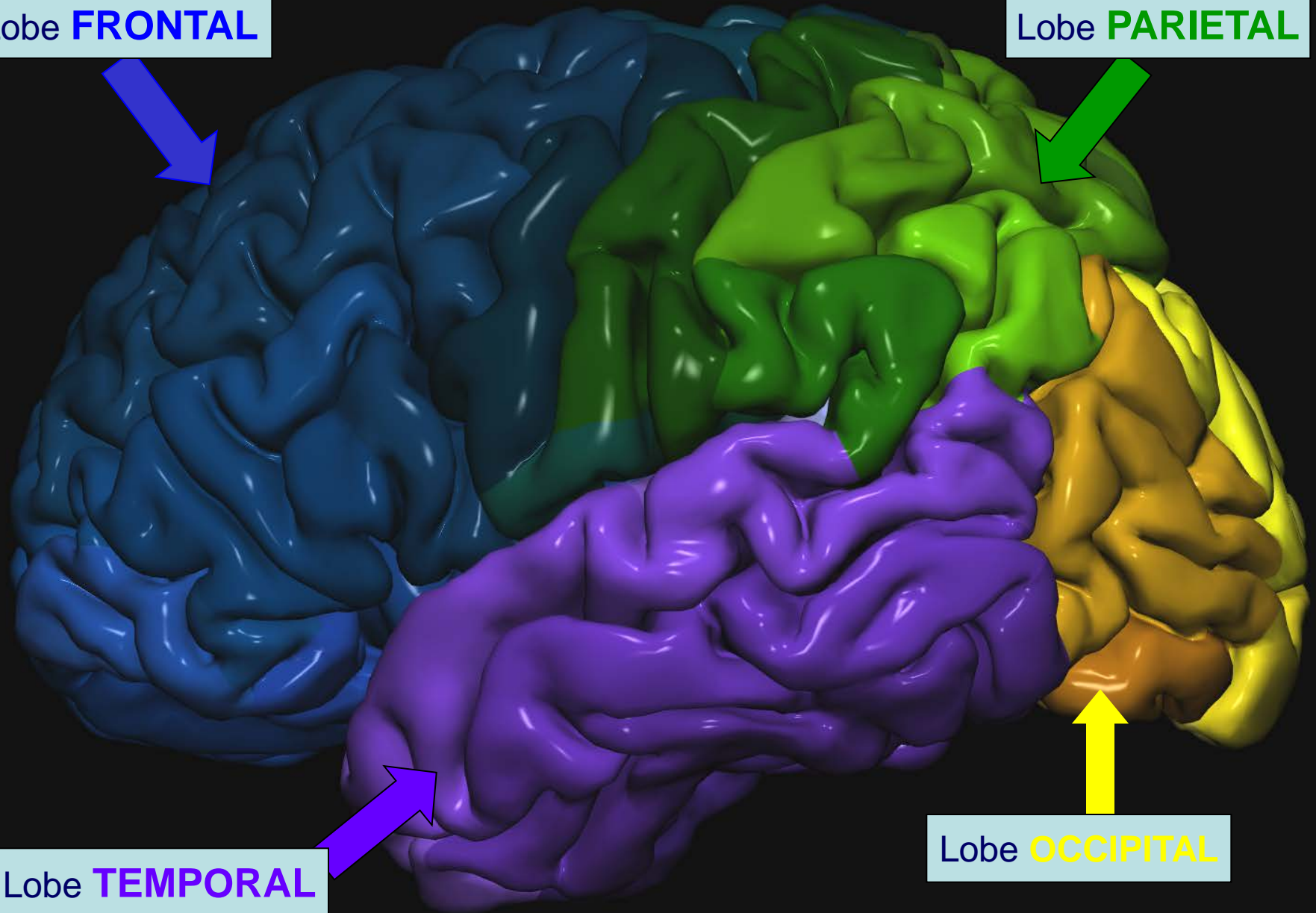
Lobe **PARIETAL**

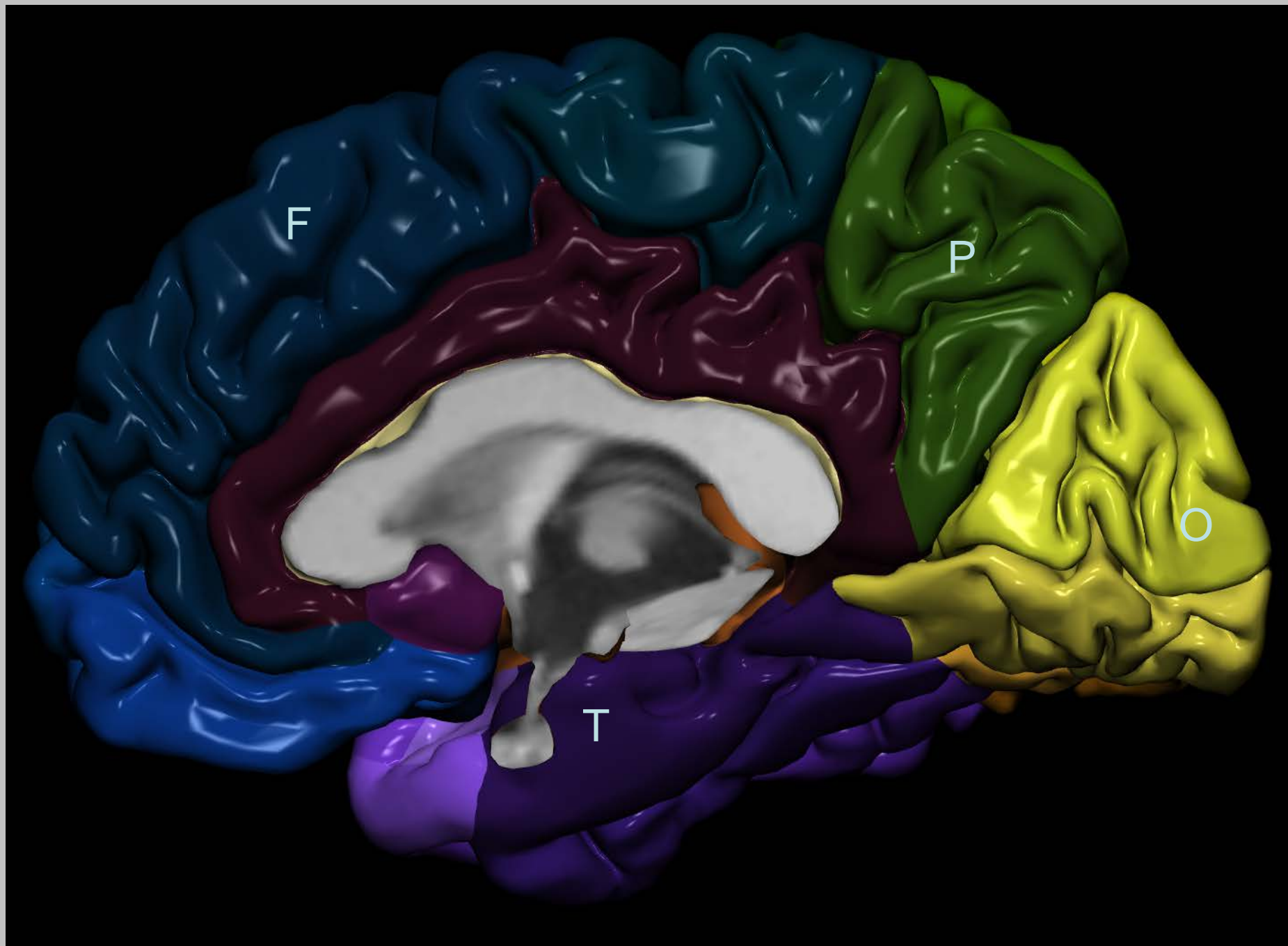


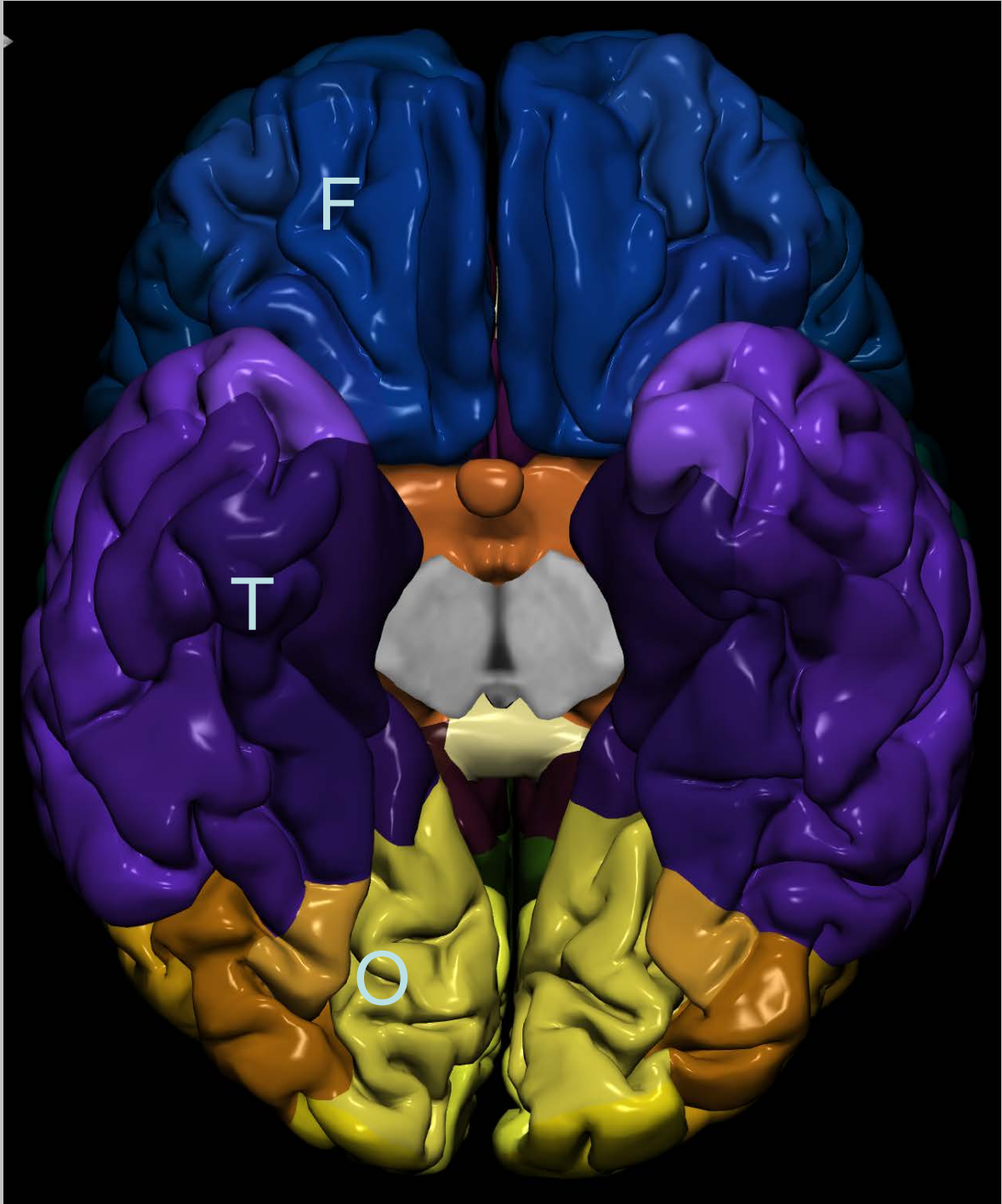
Lobe **TEMPORAL**



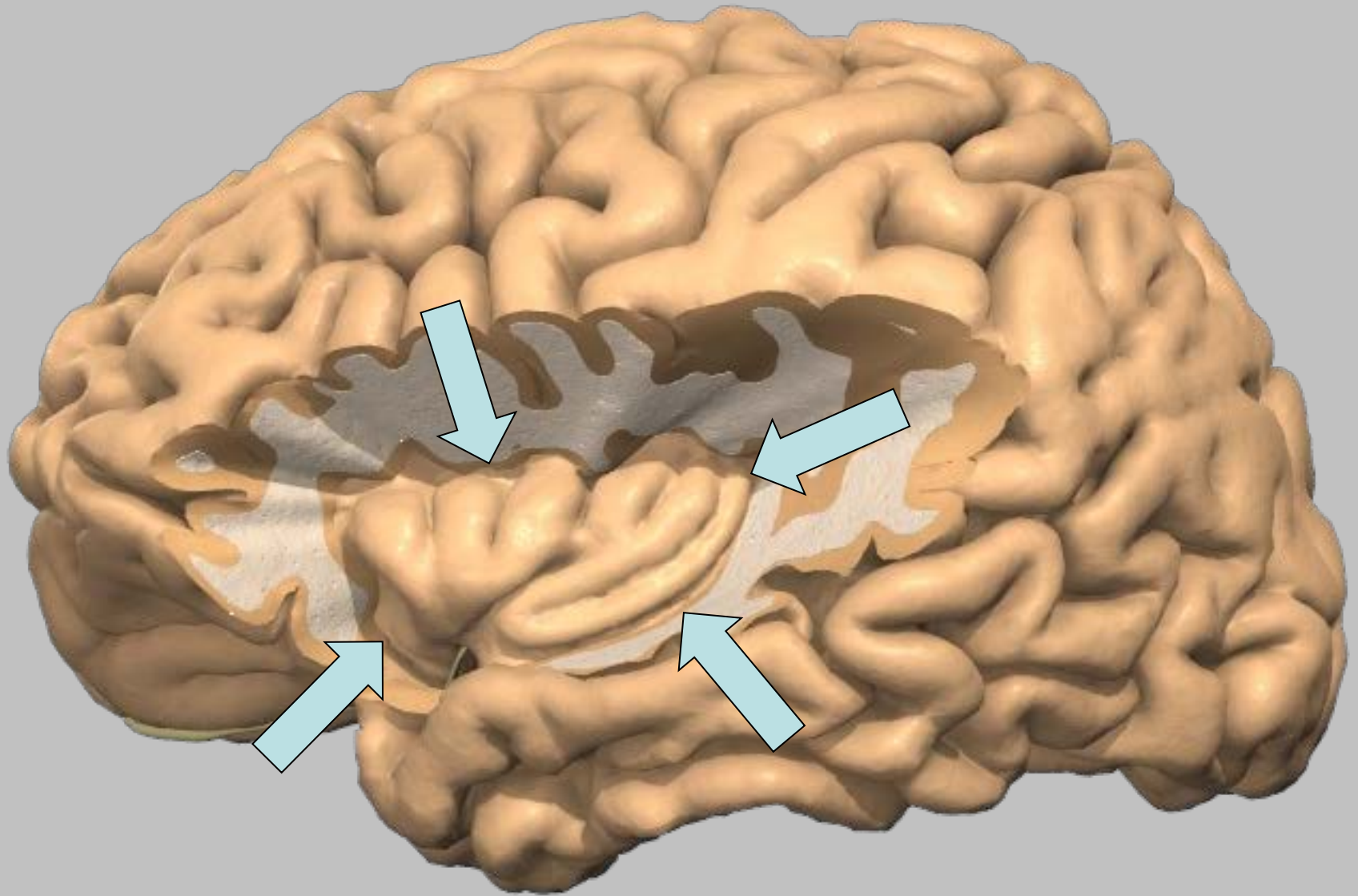
Lobe **OCCIPITAL**

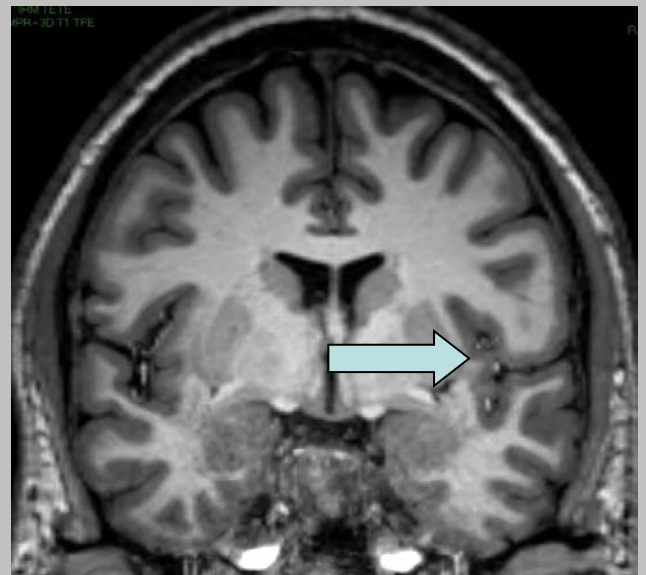
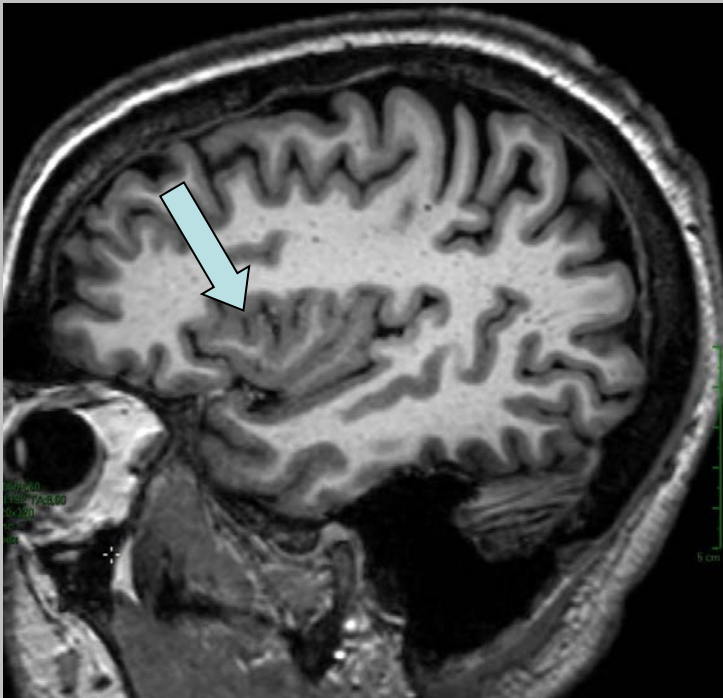
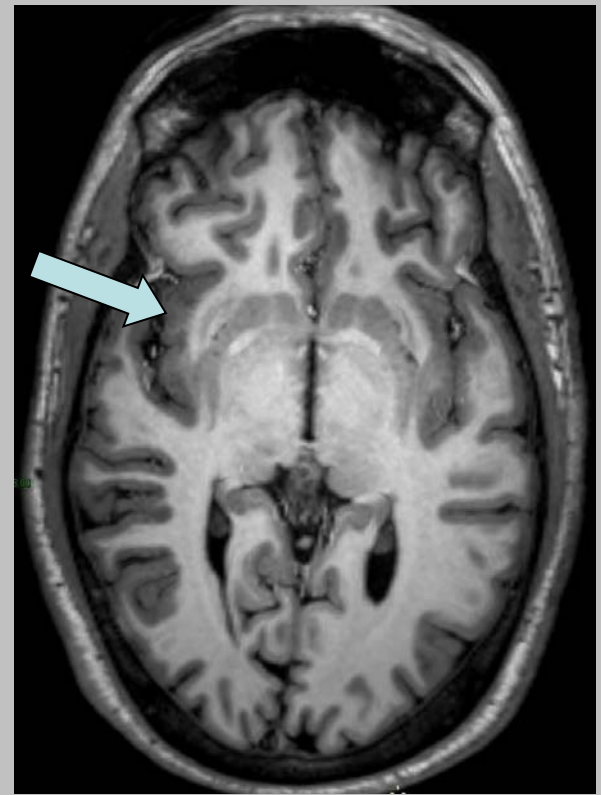
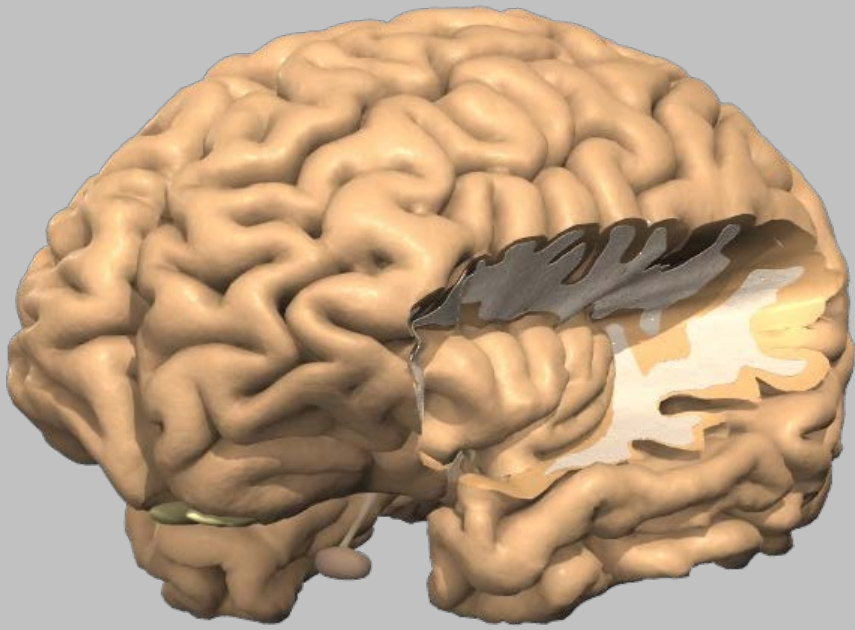




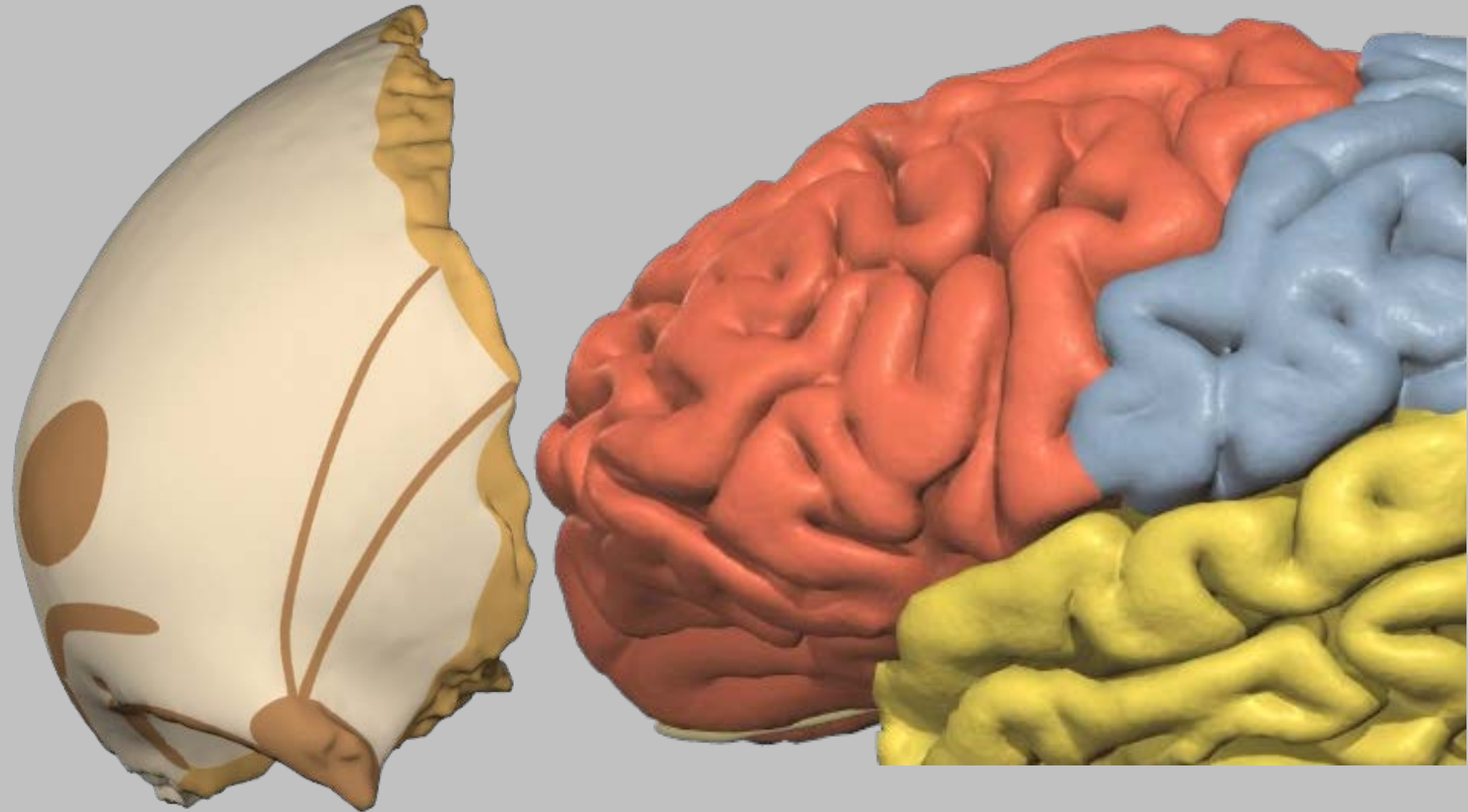


Lobe de l'insula





Lobe frontal



'Scissure de Rolando'

'Scissure de Sylvius'

Sillon central



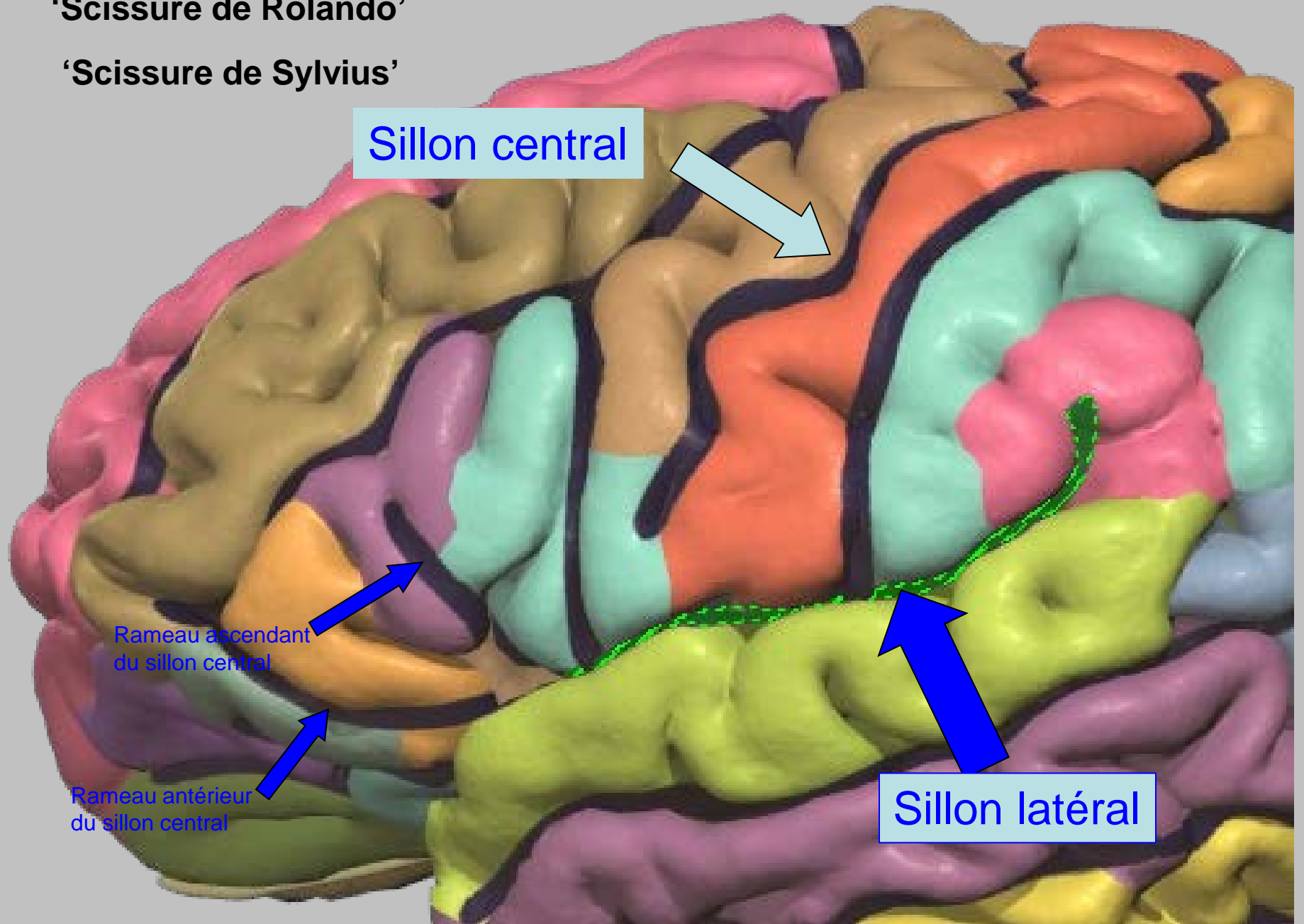
Rameau ascendant
du sillon central

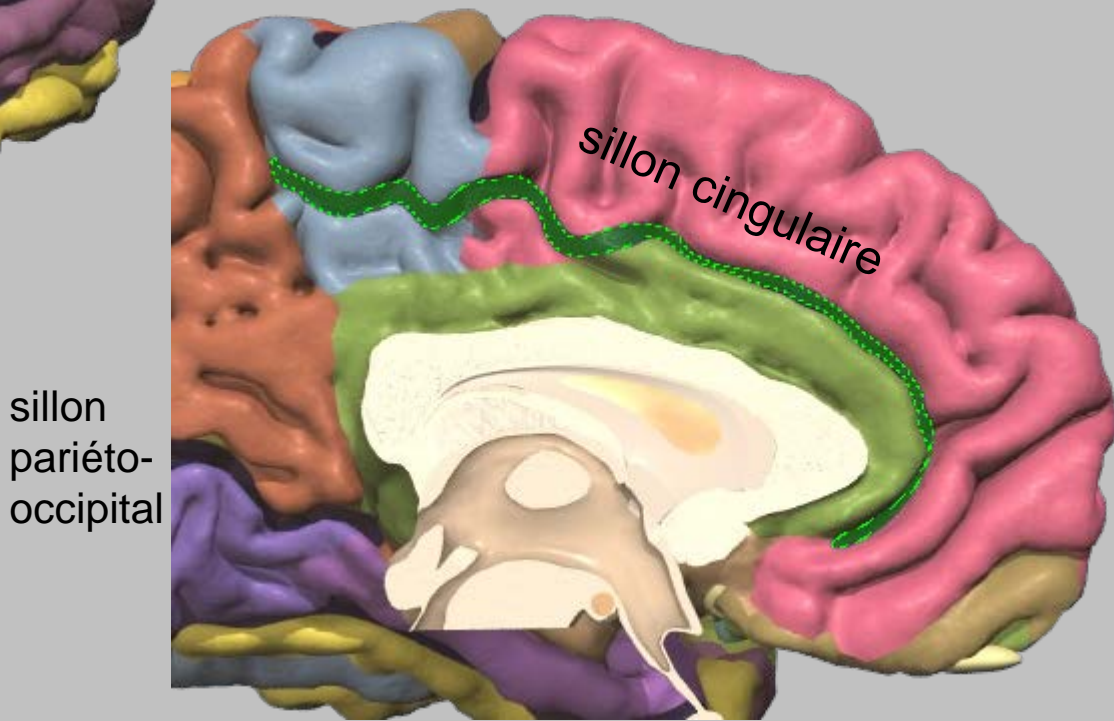
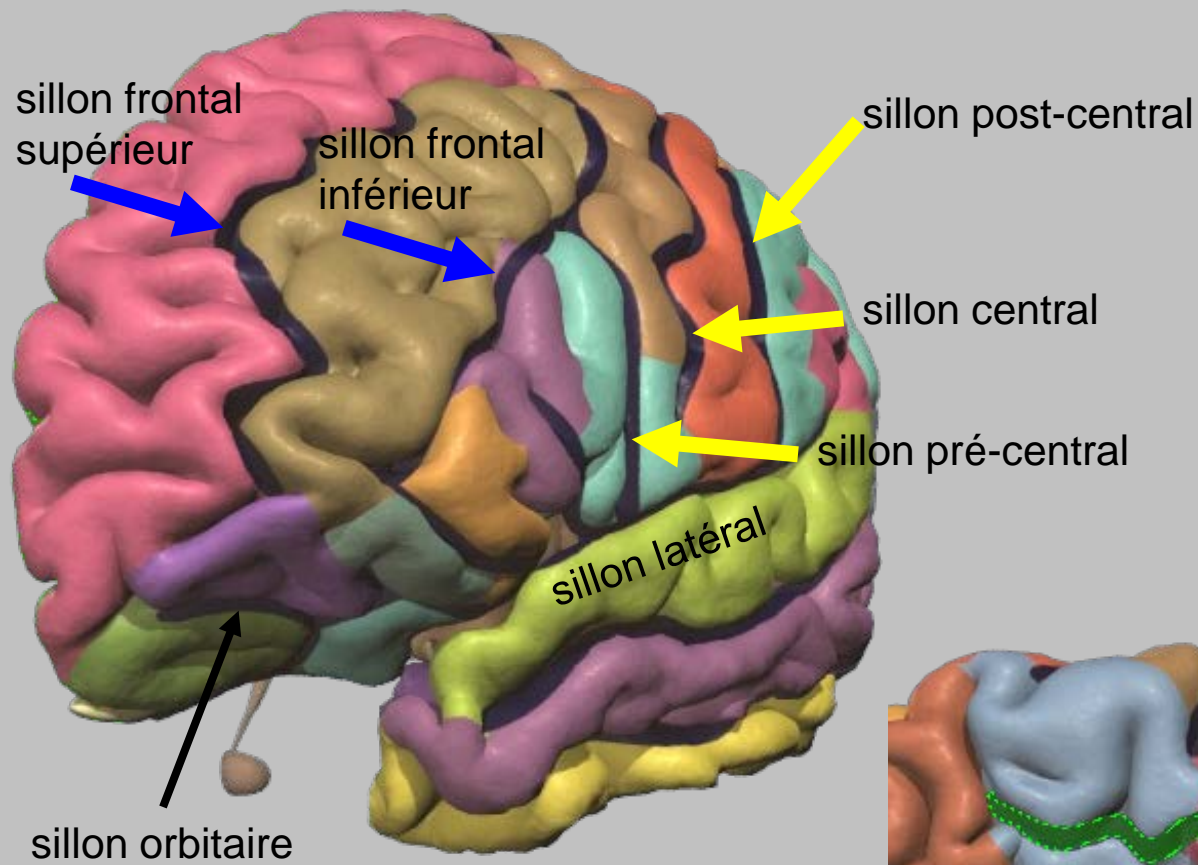


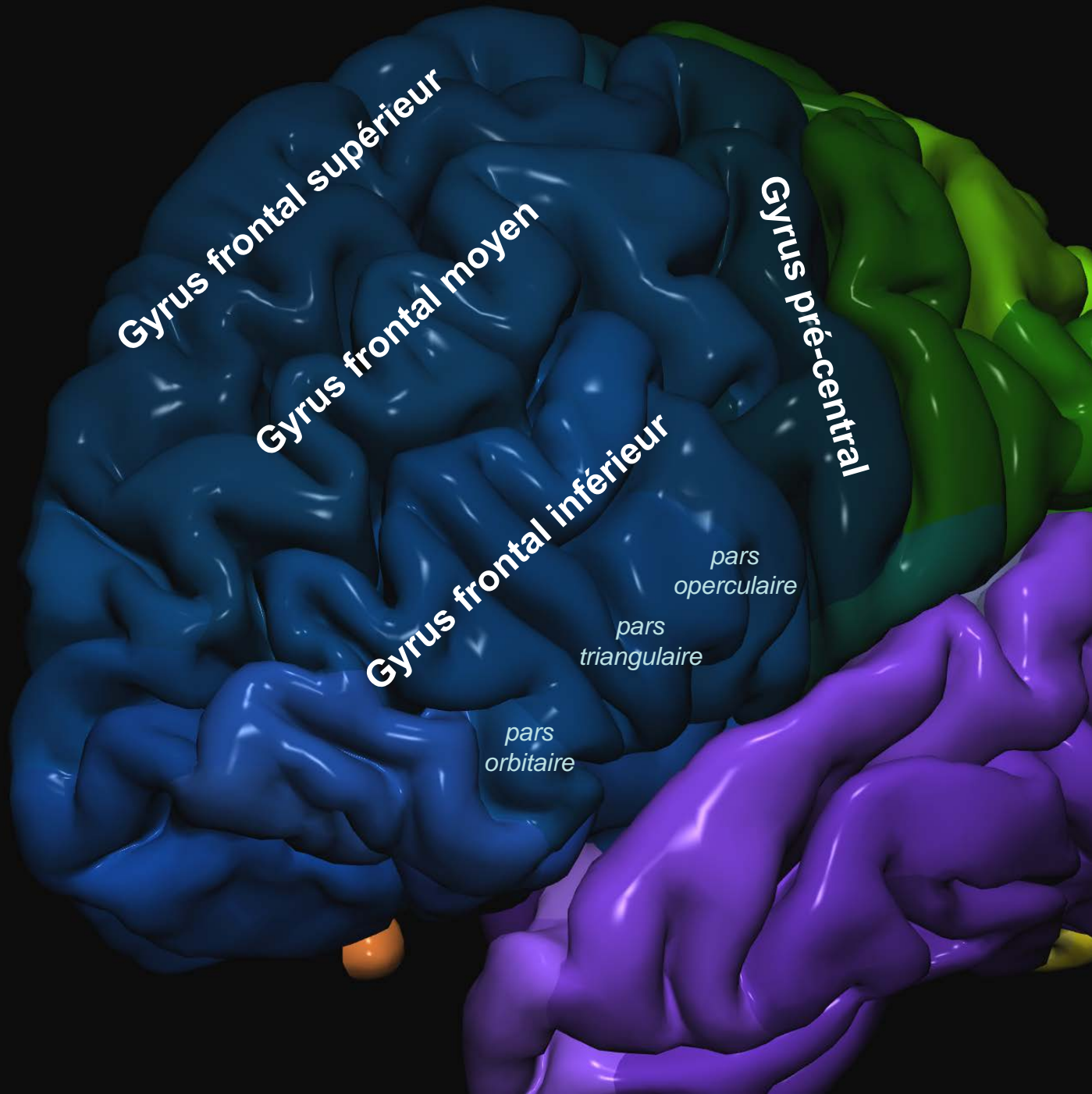
Rameau antérieur
du sillon central



Sillon latéral







Gyrus frontal supérieur

Gyrus frontal moyen

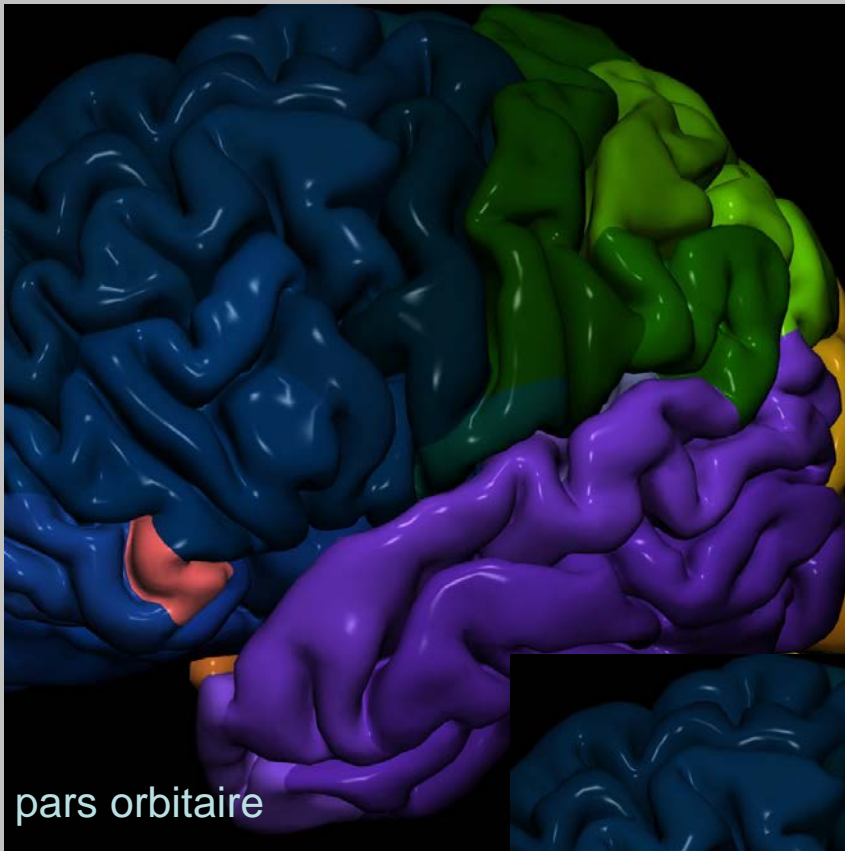
Gyrus frontal inférieur

Gyrus pré-central

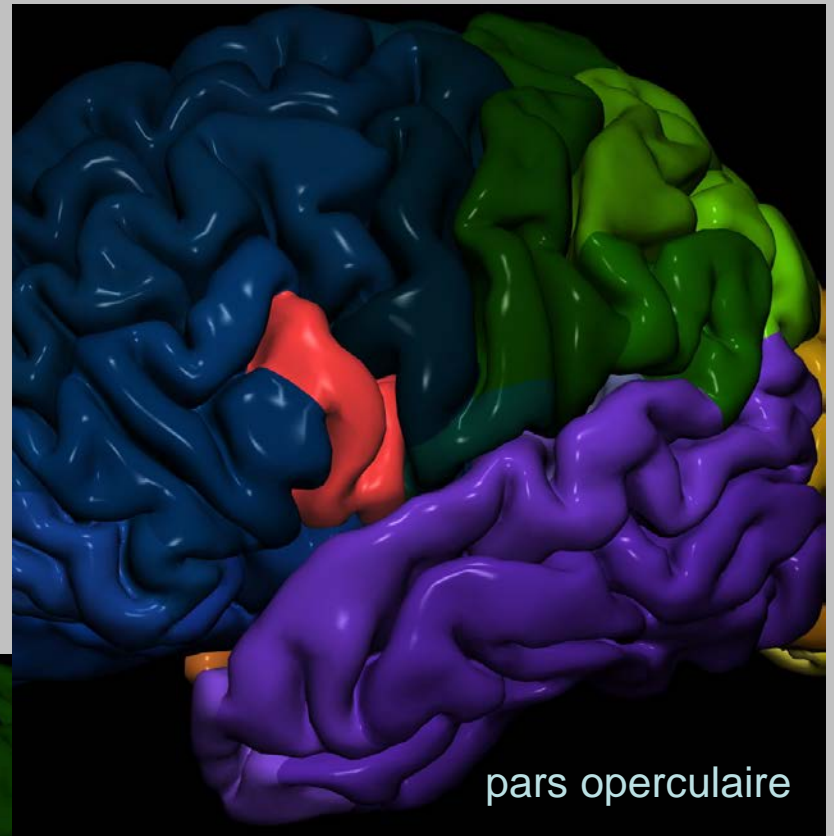
*pars
operculaire*

*pars
triangulaire*

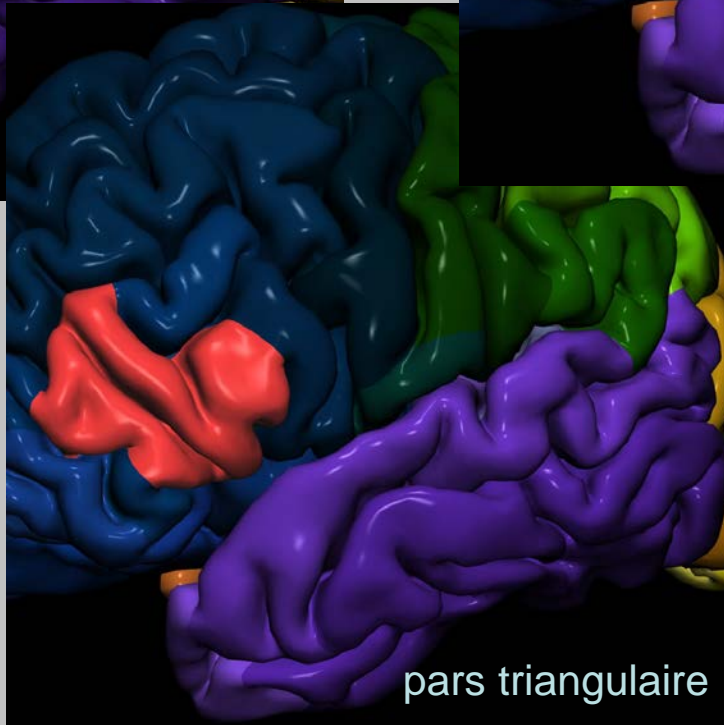
*pars
orbitaire*



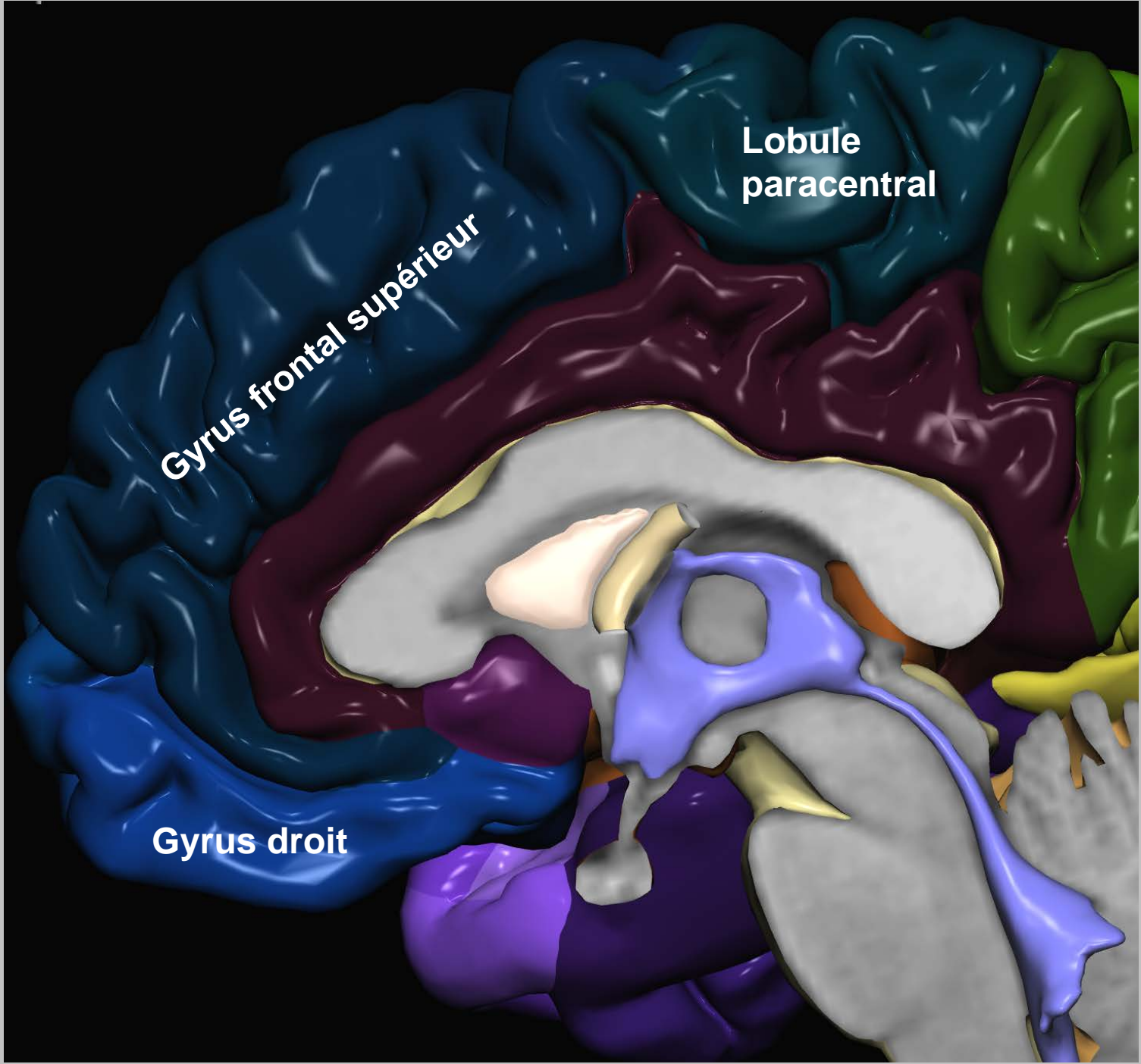
pars orbitaire



pars operculaire



pars triangulaire



Lobule
paracentral

Gyrus frontal supérieur

Gyrus droit

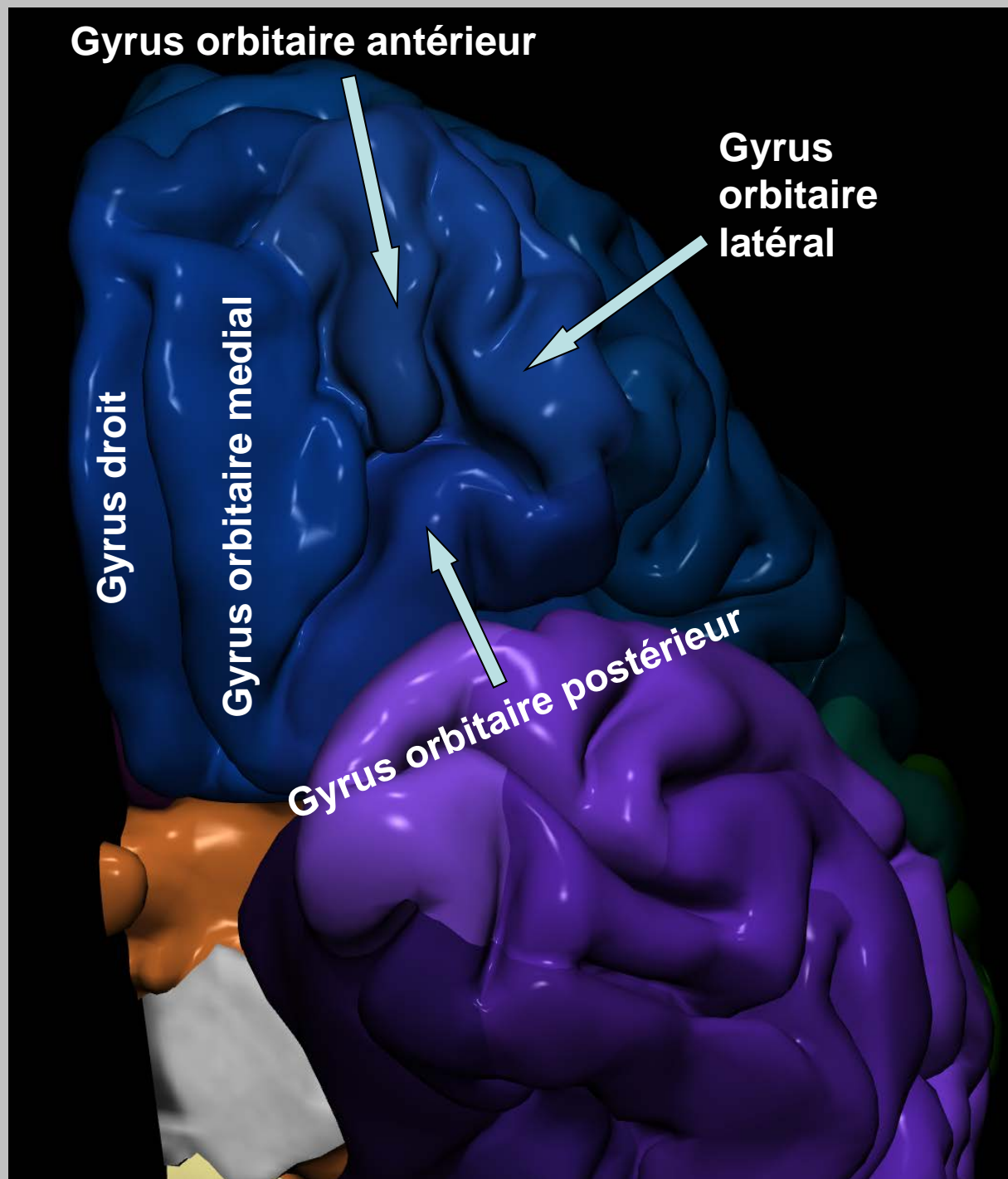
Gyrus orbitaire antérieur

**Gyrus
orbitaire
latéral**

Gyrus droit

Gyrus orbitaire medial

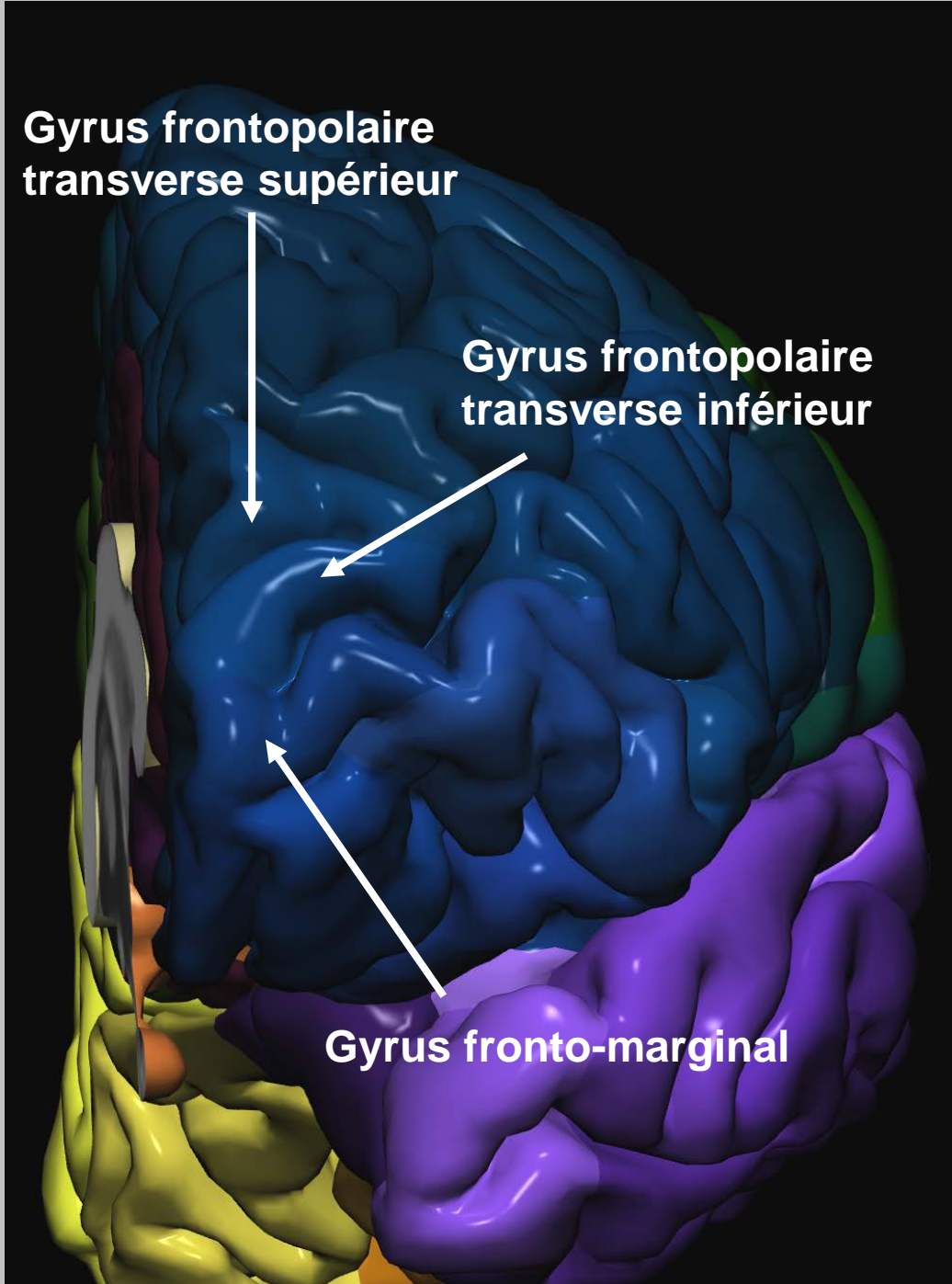
Gyrus orbitaire postérieur



**Gyrus frontopolaire
transverse supérieur**

**Gyrus frontopolaire
transverse inférieur**

Gyrus fronto-marginal

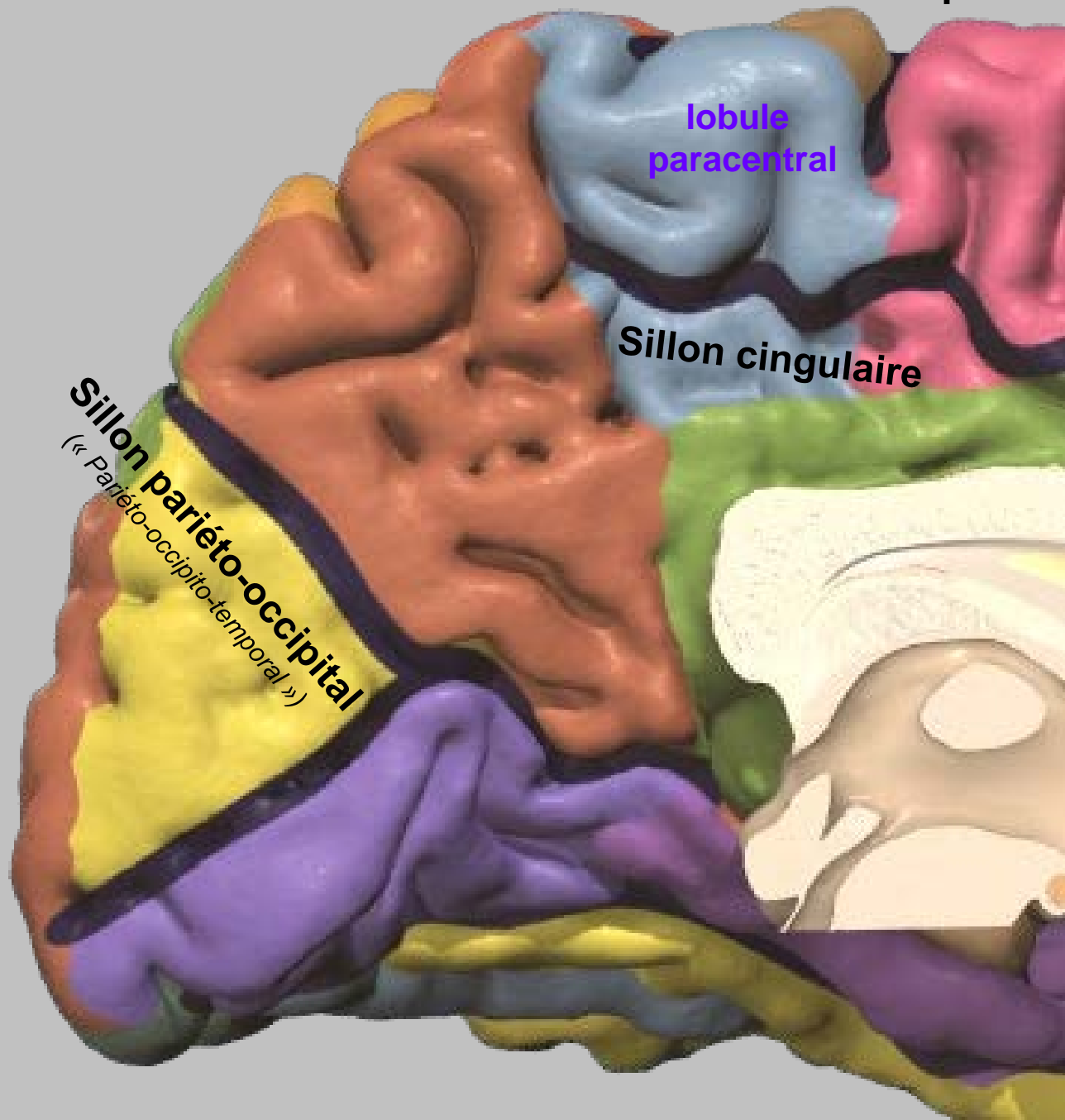


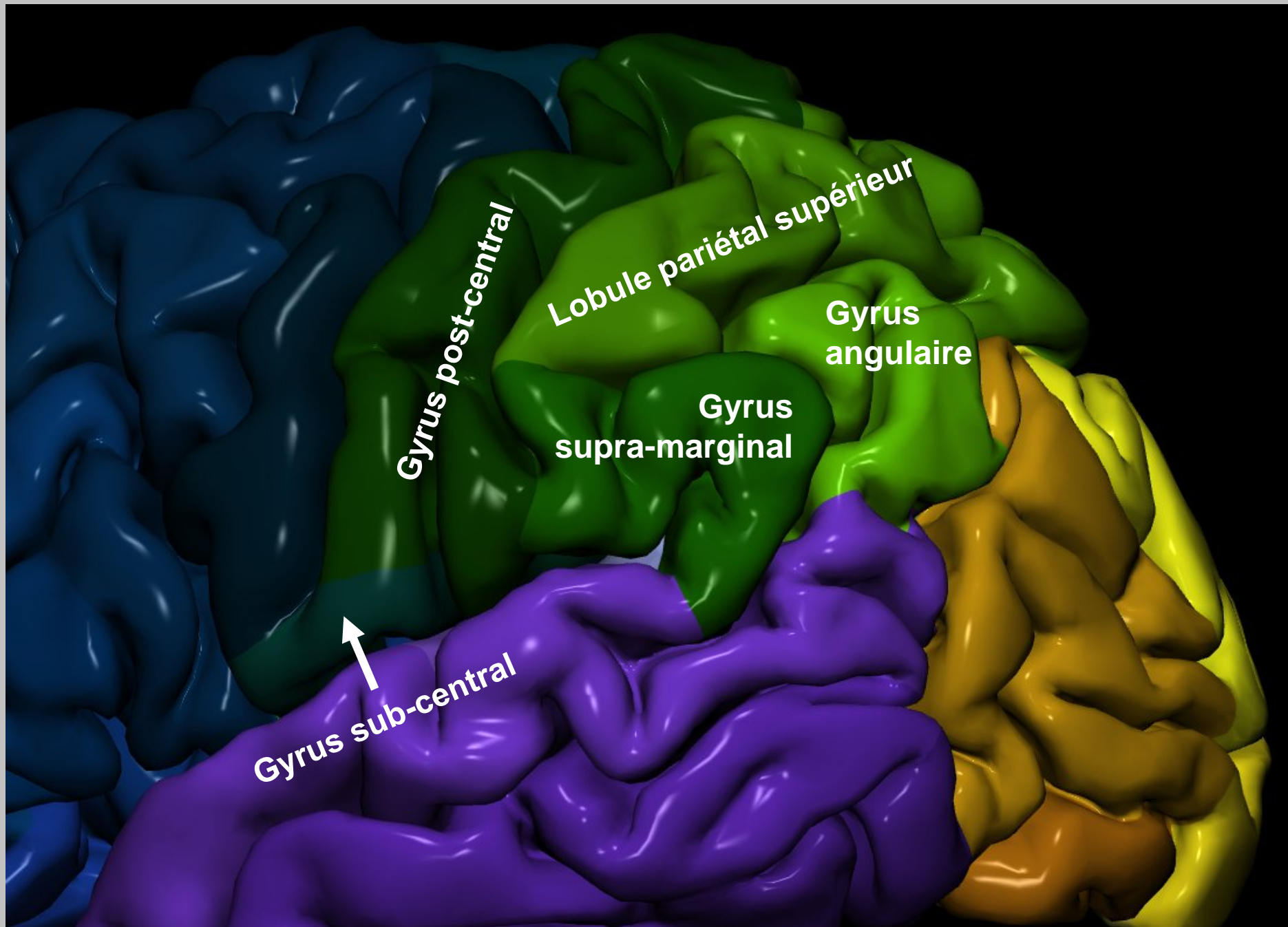
Sillon central Sillon pré-central

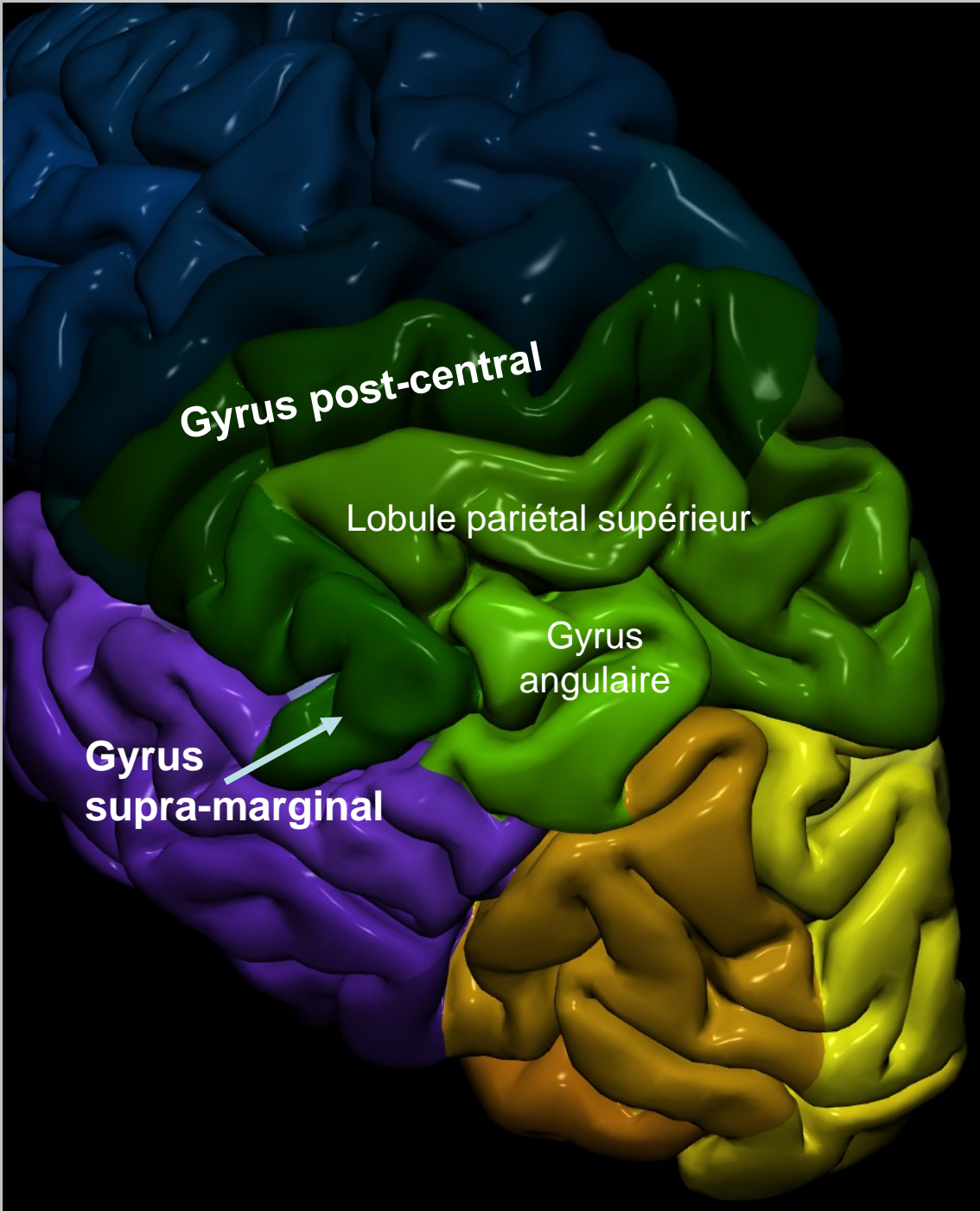
lobule
paracentral

Sillon cingulaire

Sillon pariéto-occipital
(« Pariéto-occipito-temporal »)





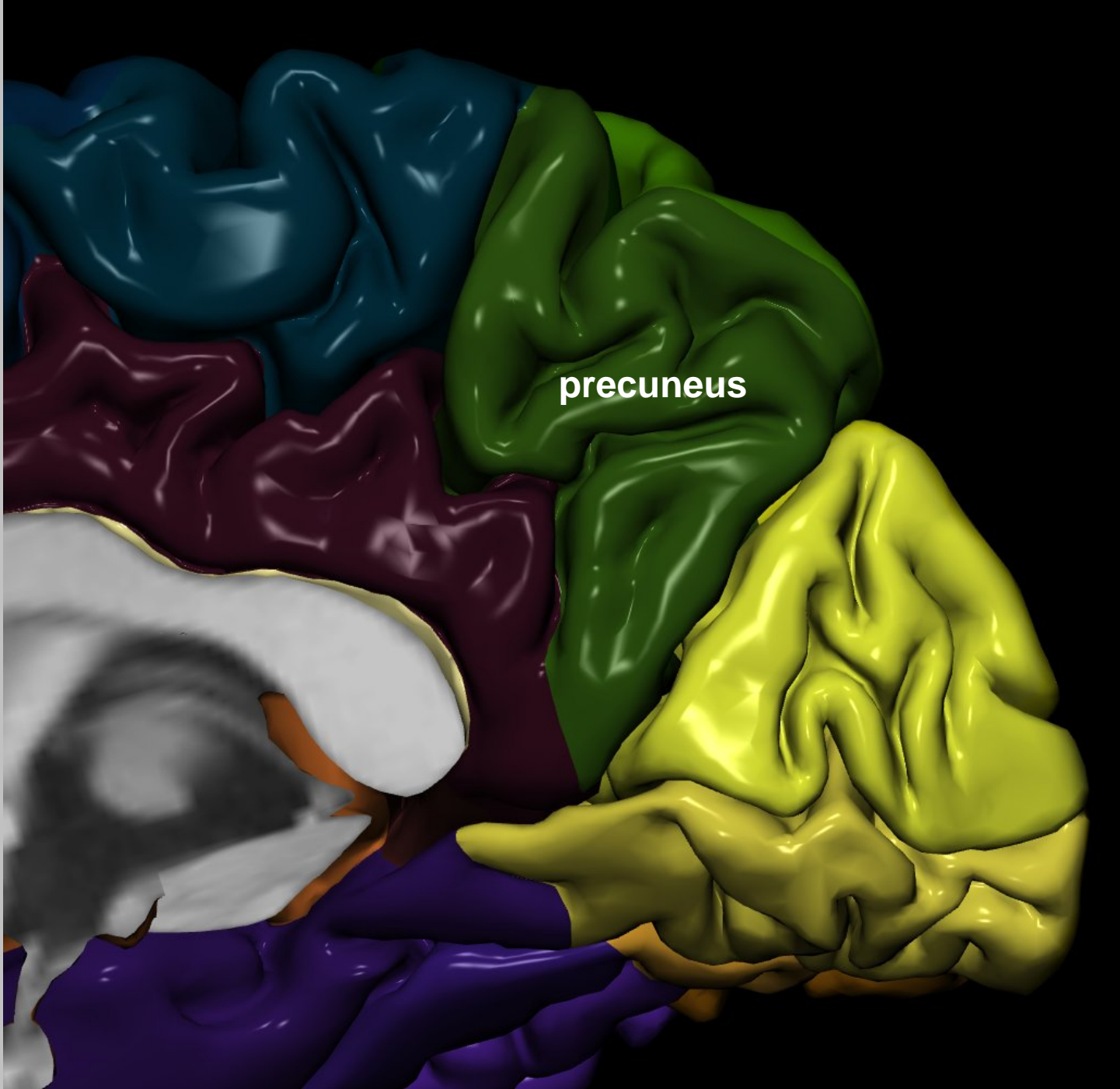


Gyrus post-central

Lobule pariétal supérieur

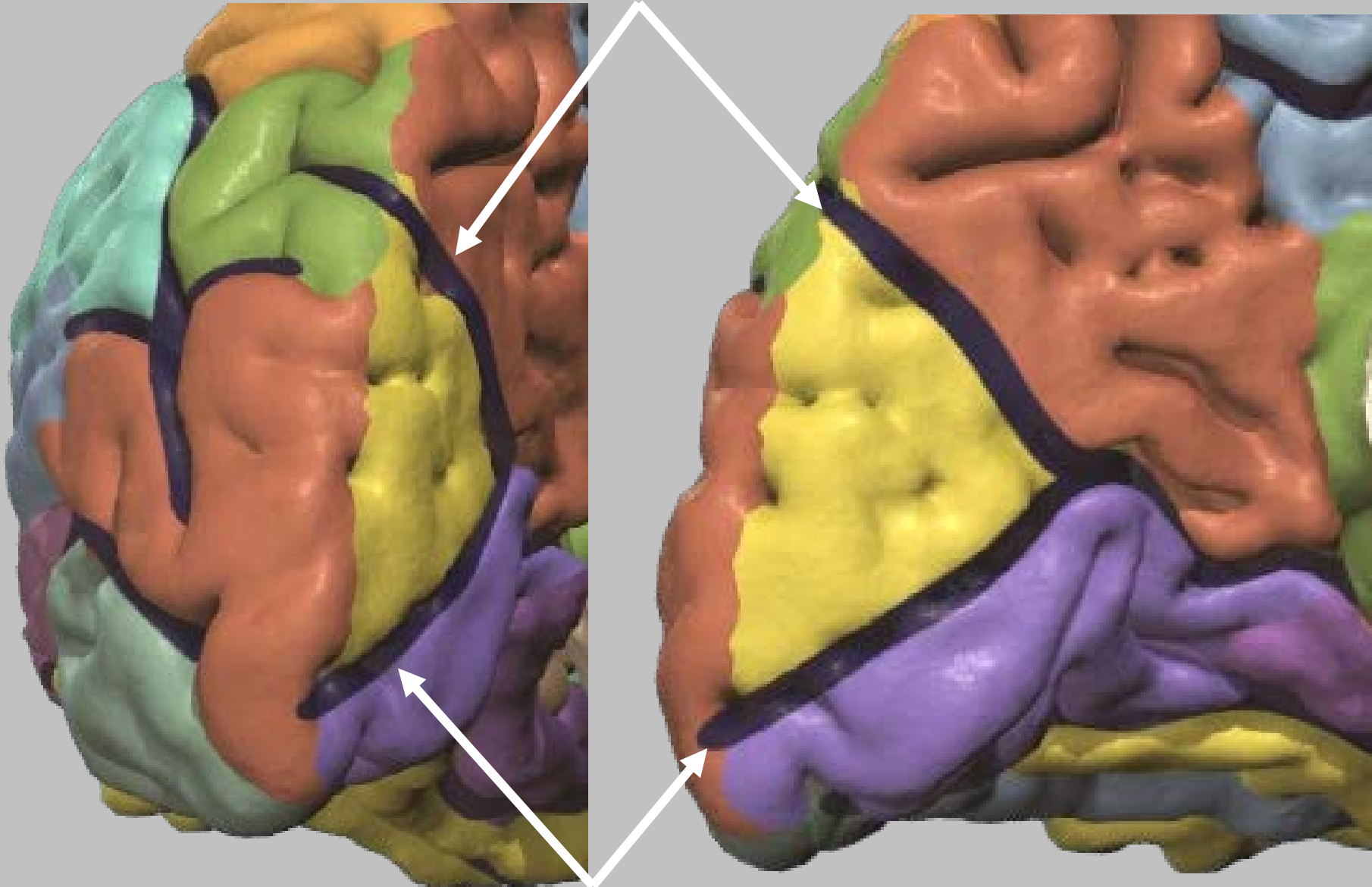
Gyrus angulaire

Gyrus supra-marginal

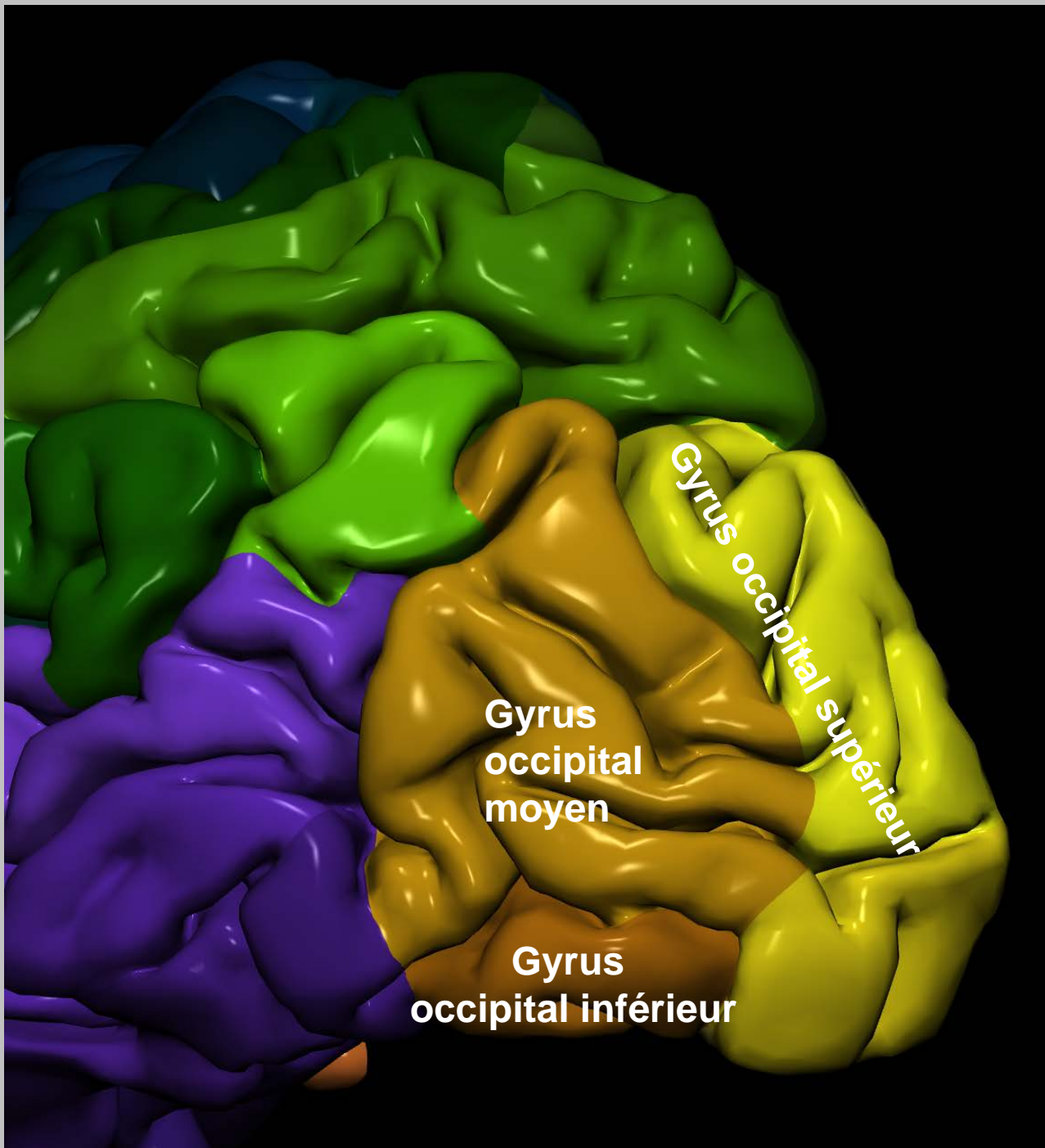


precuneus

Sillon pariéto-occipital



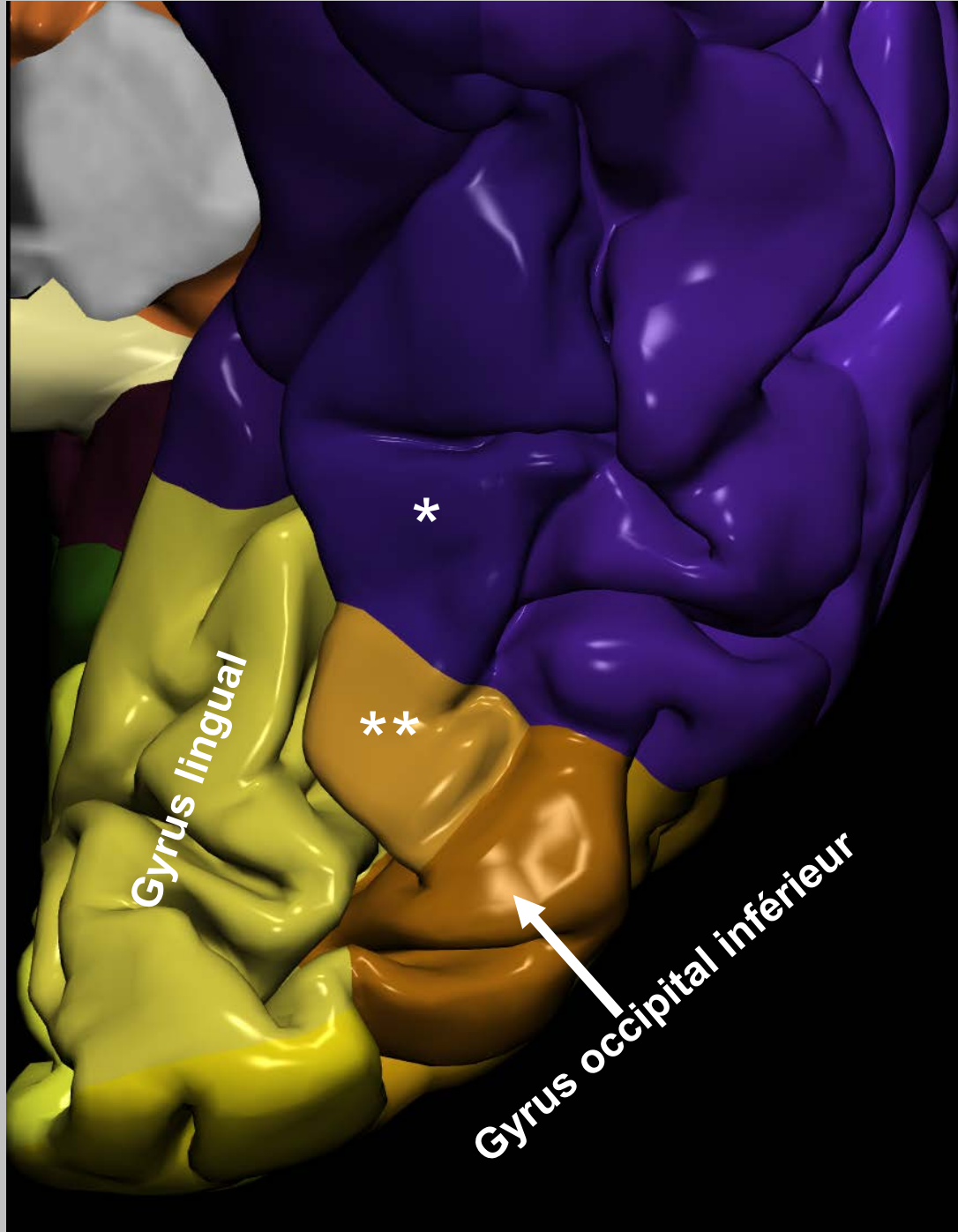
Sillon calcarin



Gyrus occipital supérieur

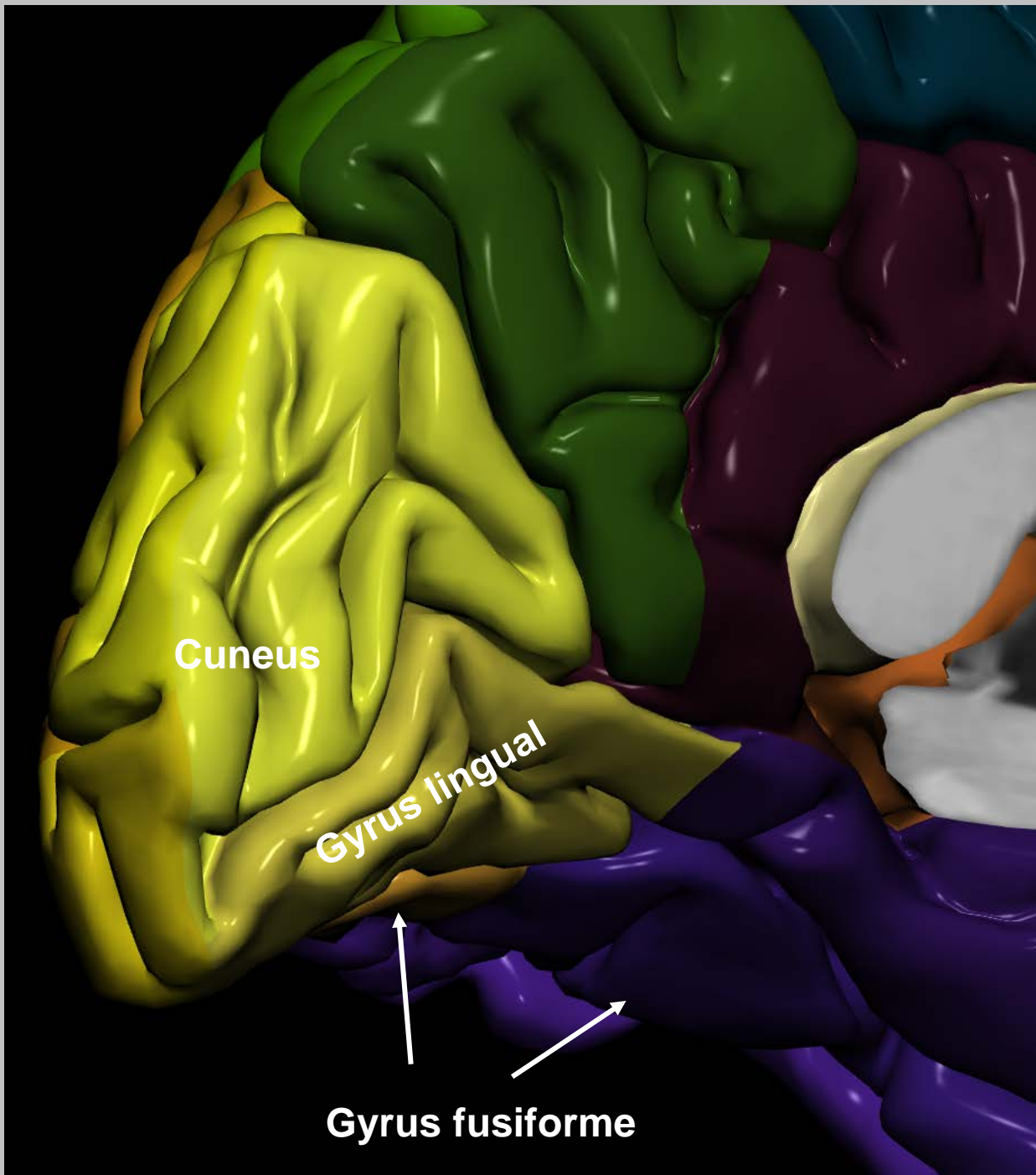
Gyrus occipital moyen

Gyrus occipital inférieur

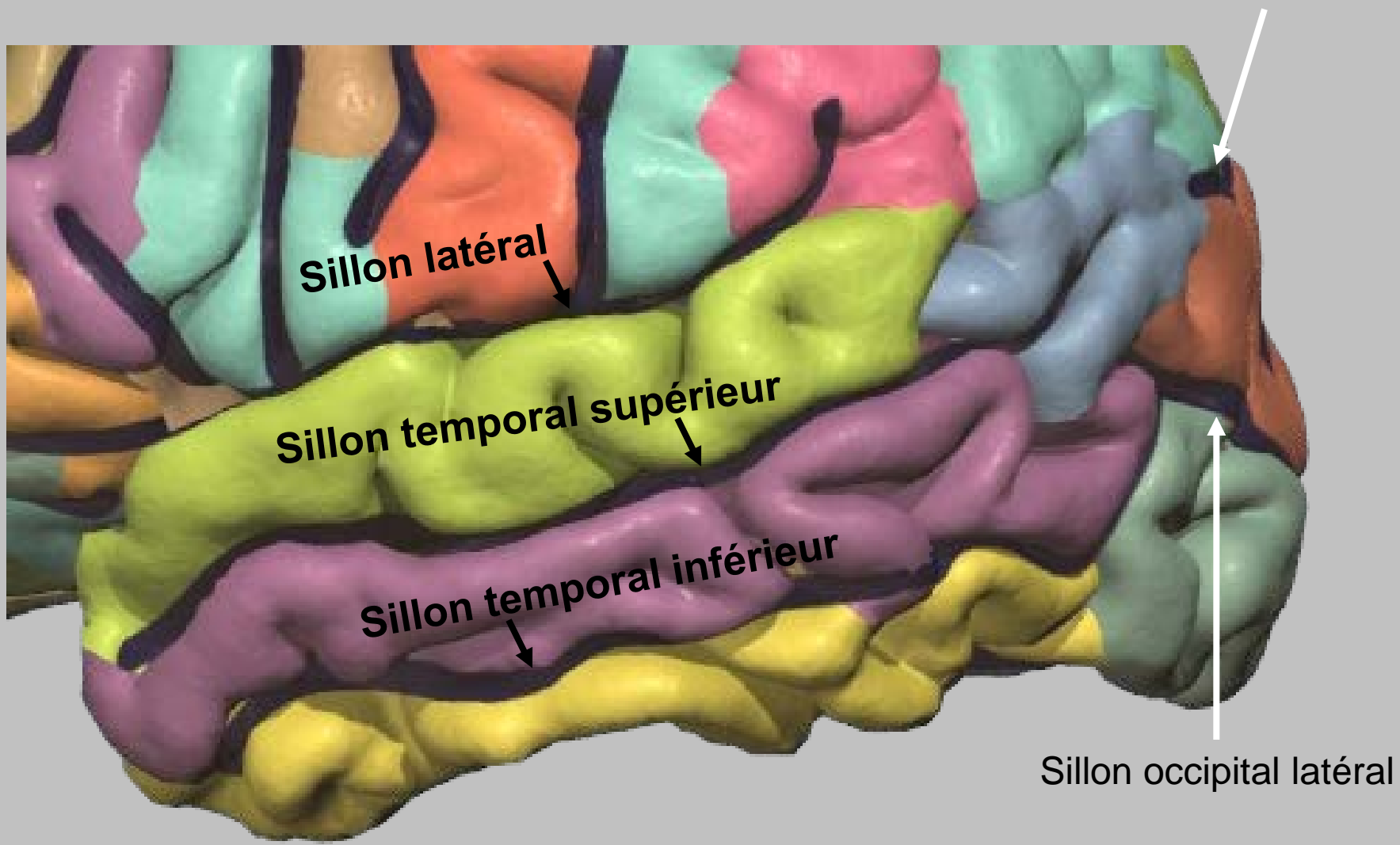


* Gyrus fusiforme (pars temporale)

** Gyrus fusiforme (pars occipitale)



Lobe temporal



Sillon trans-occipital

Sillon latéral

Sillon temporal supérieur

Sillon temporal inférieur

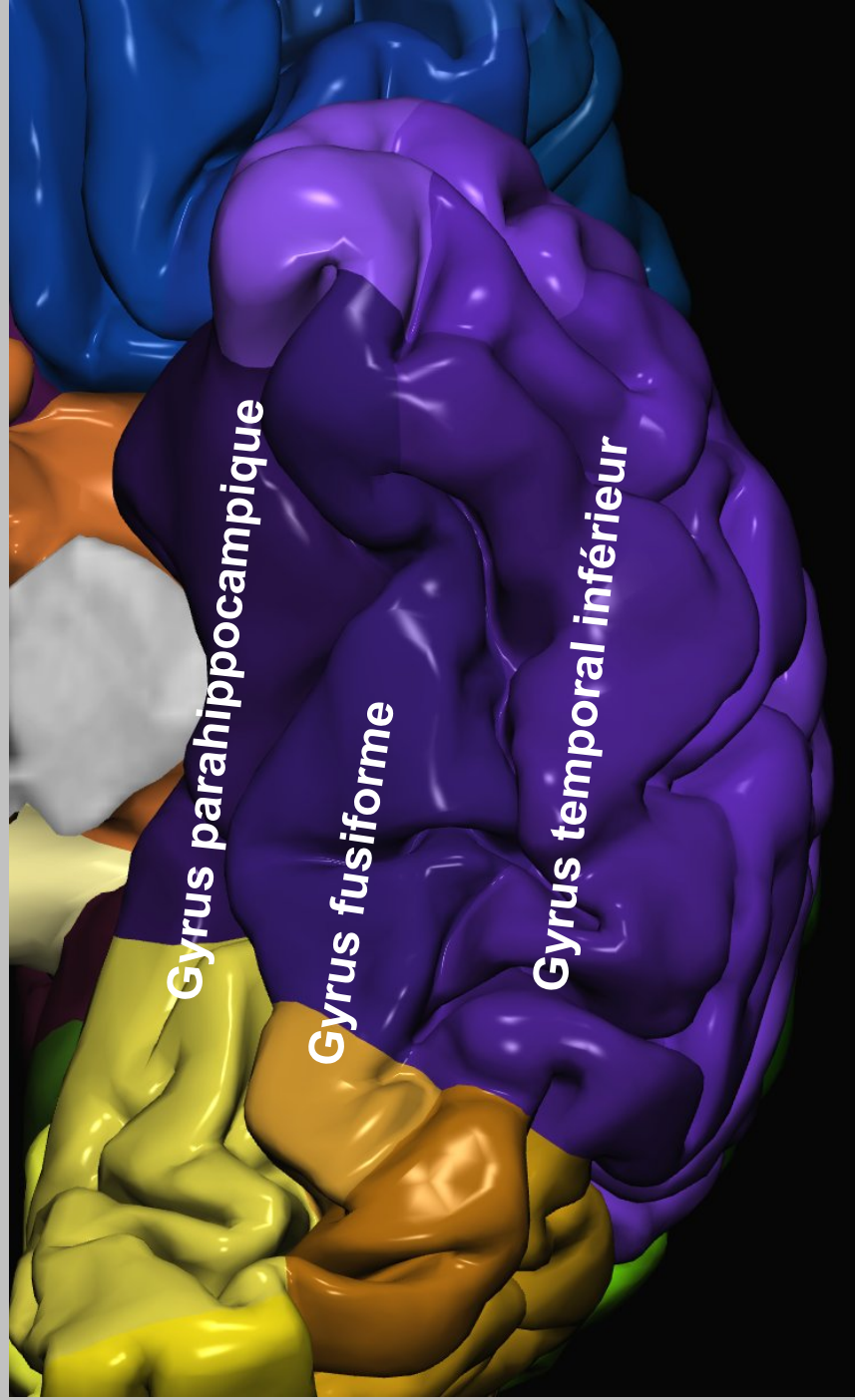
Sillon occipital latéral

A 3D anatomical model of the temporal lobe, showing its characteristic convoluted surface. The model is color-coded to distinguish different gyri: the superior gyrus is purple, the middle gyrus is blue, and the inferior gyrus is yellow. The labels are placed directly on the corresponding gyri.

Gyrus temporal supérieur

Gyrus temporal moyen

Gyrus temporal inférieur

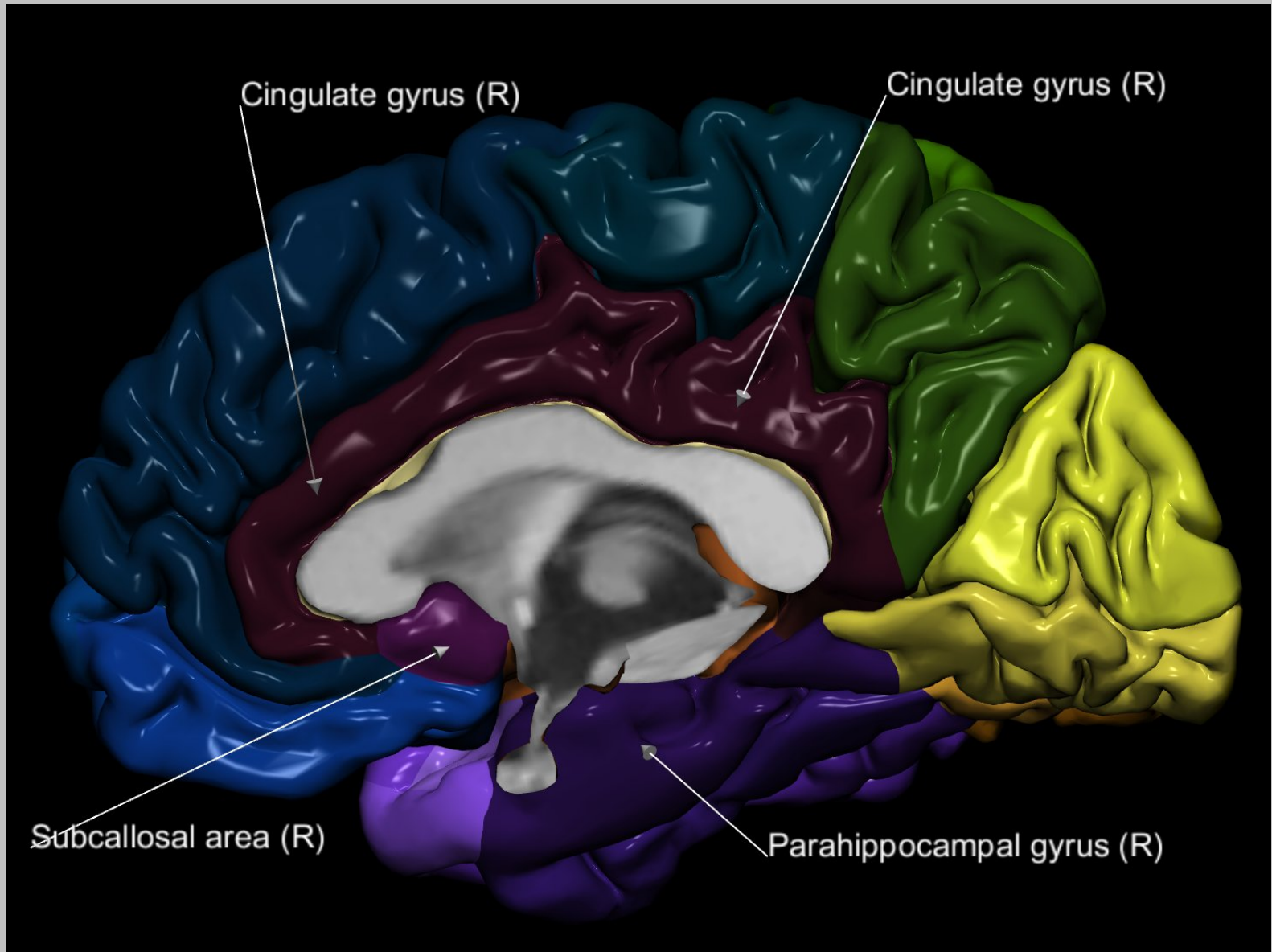


Gyrus parahippocampique

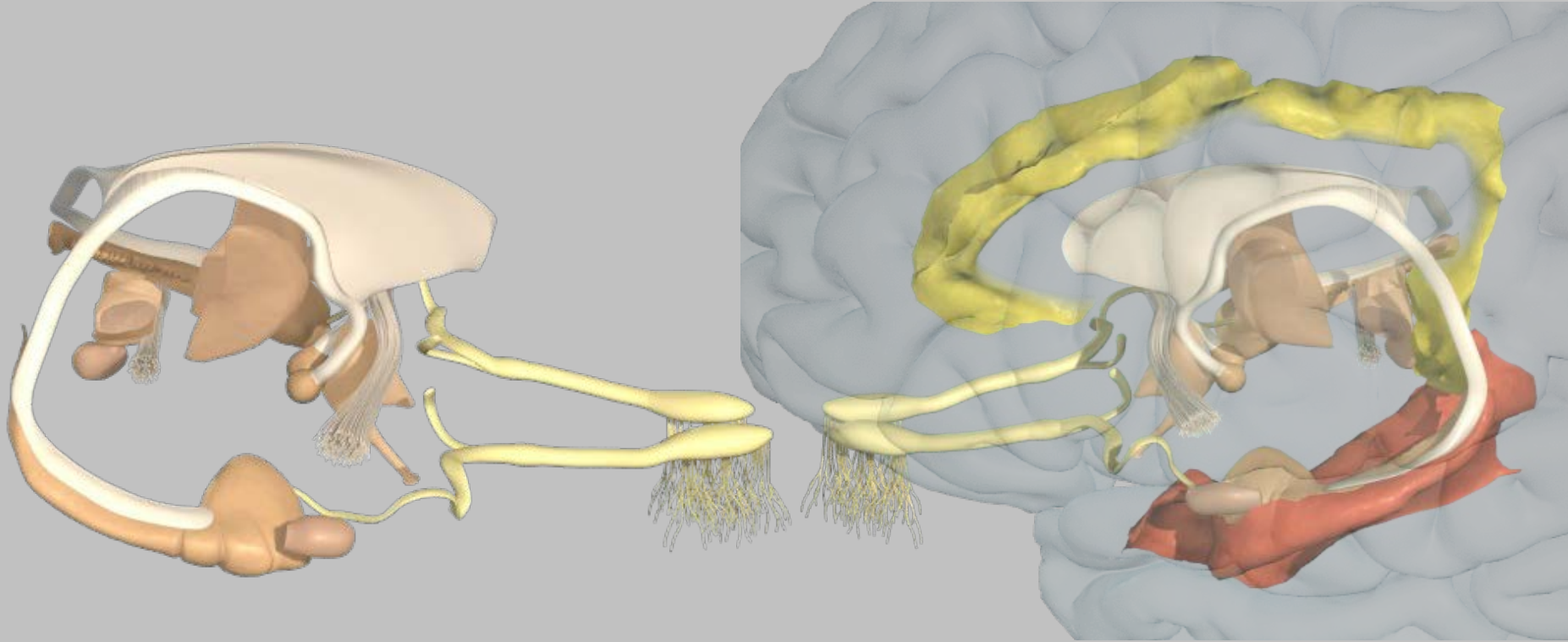
Gyrus fusiforme

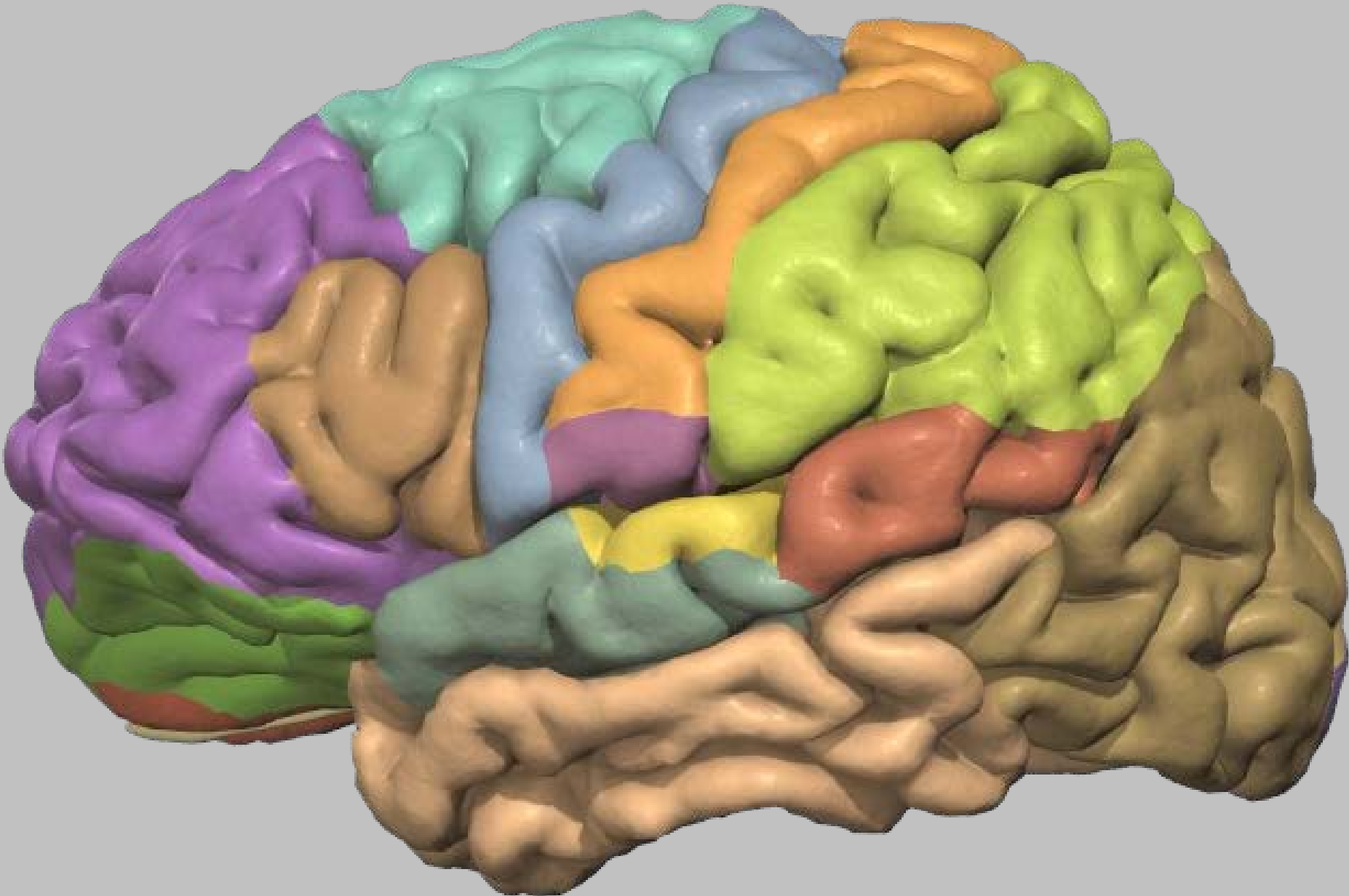
Gyrus temporal inférieur

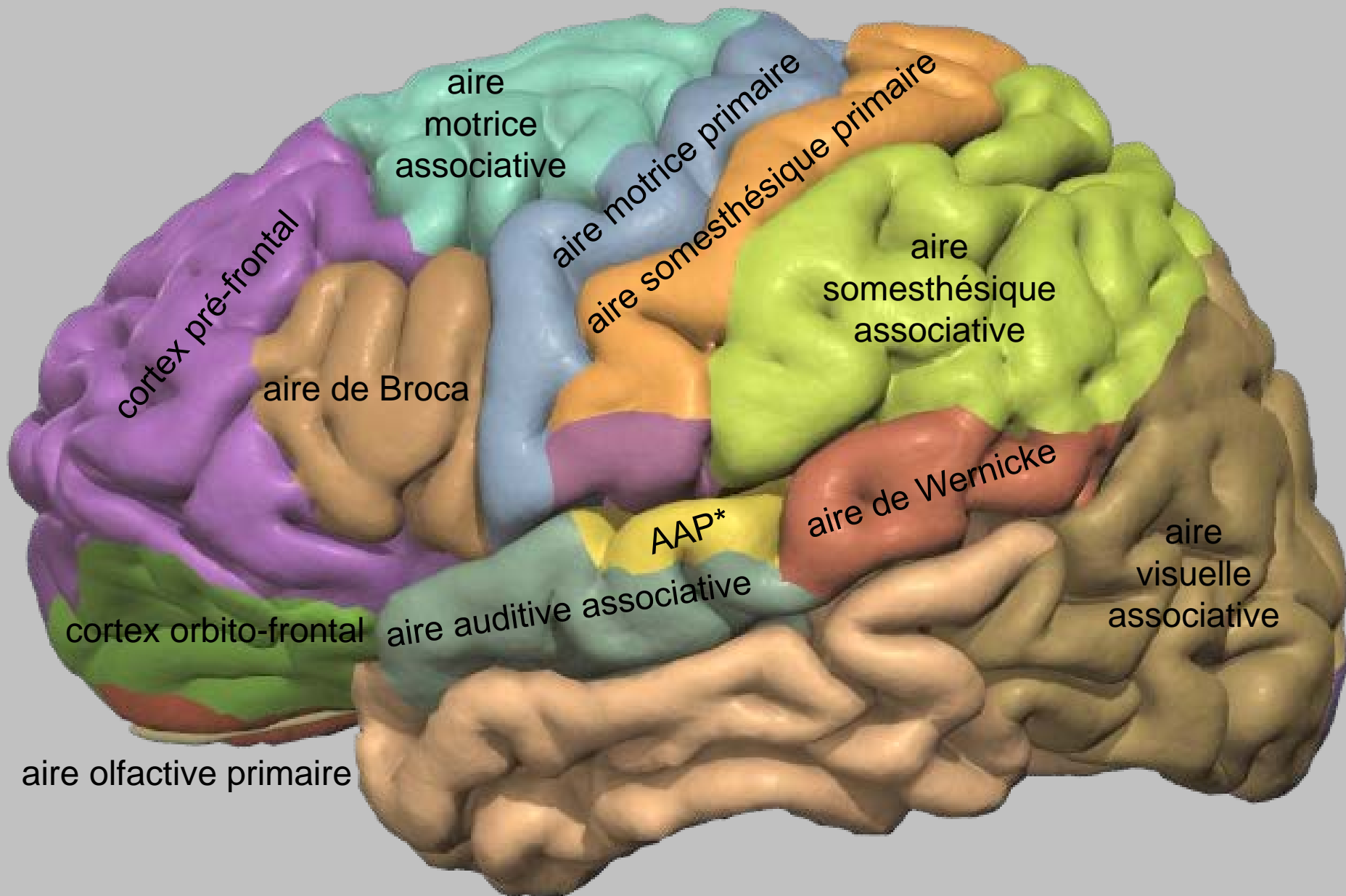
'Lobe' limbique et 'système limbique'



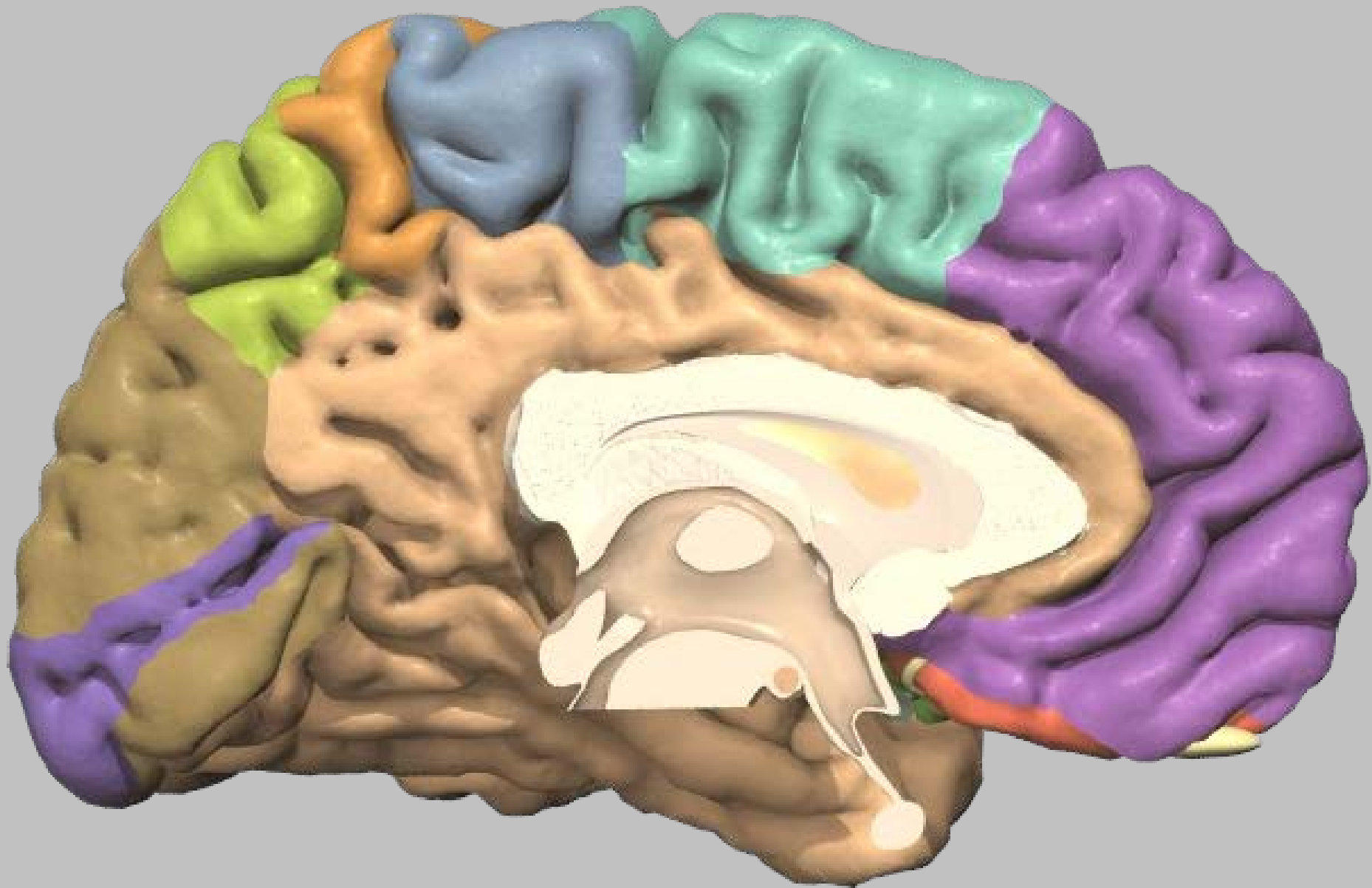
'Lobe' limbique et 'système limbique'

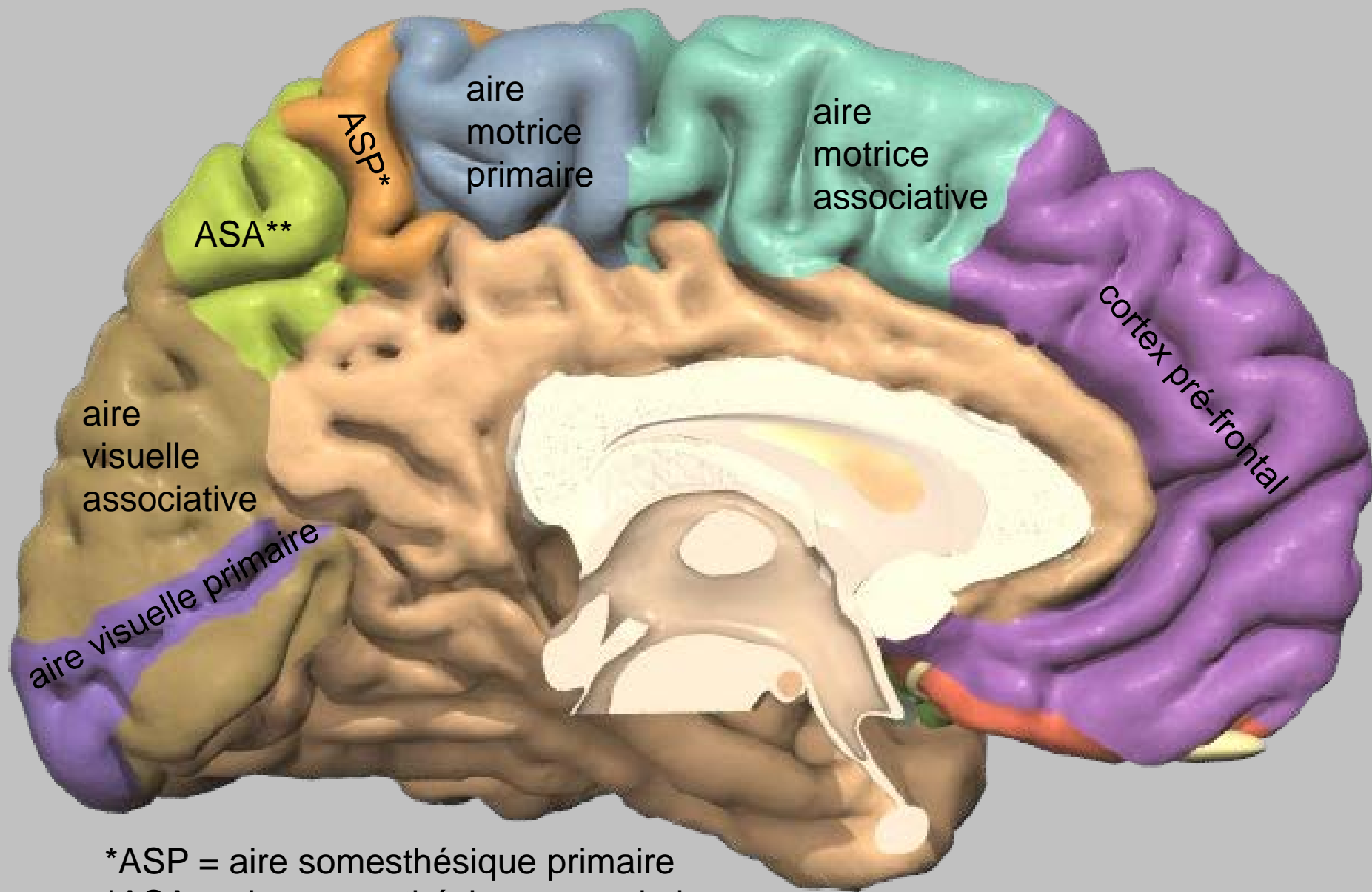






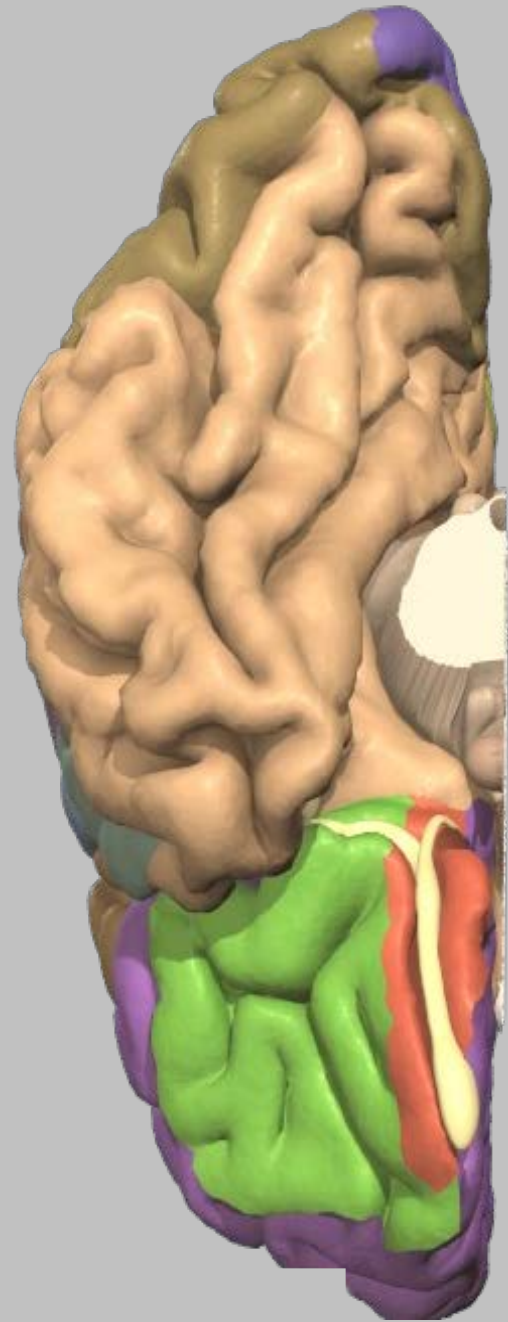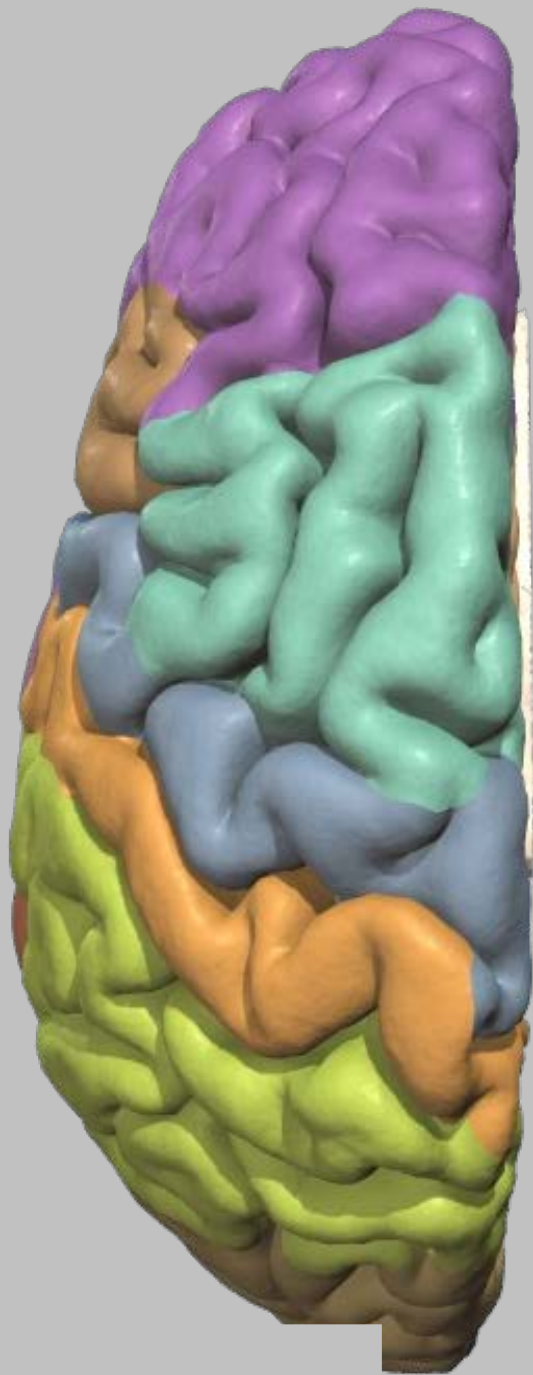
*AAP = aire auditive primaire

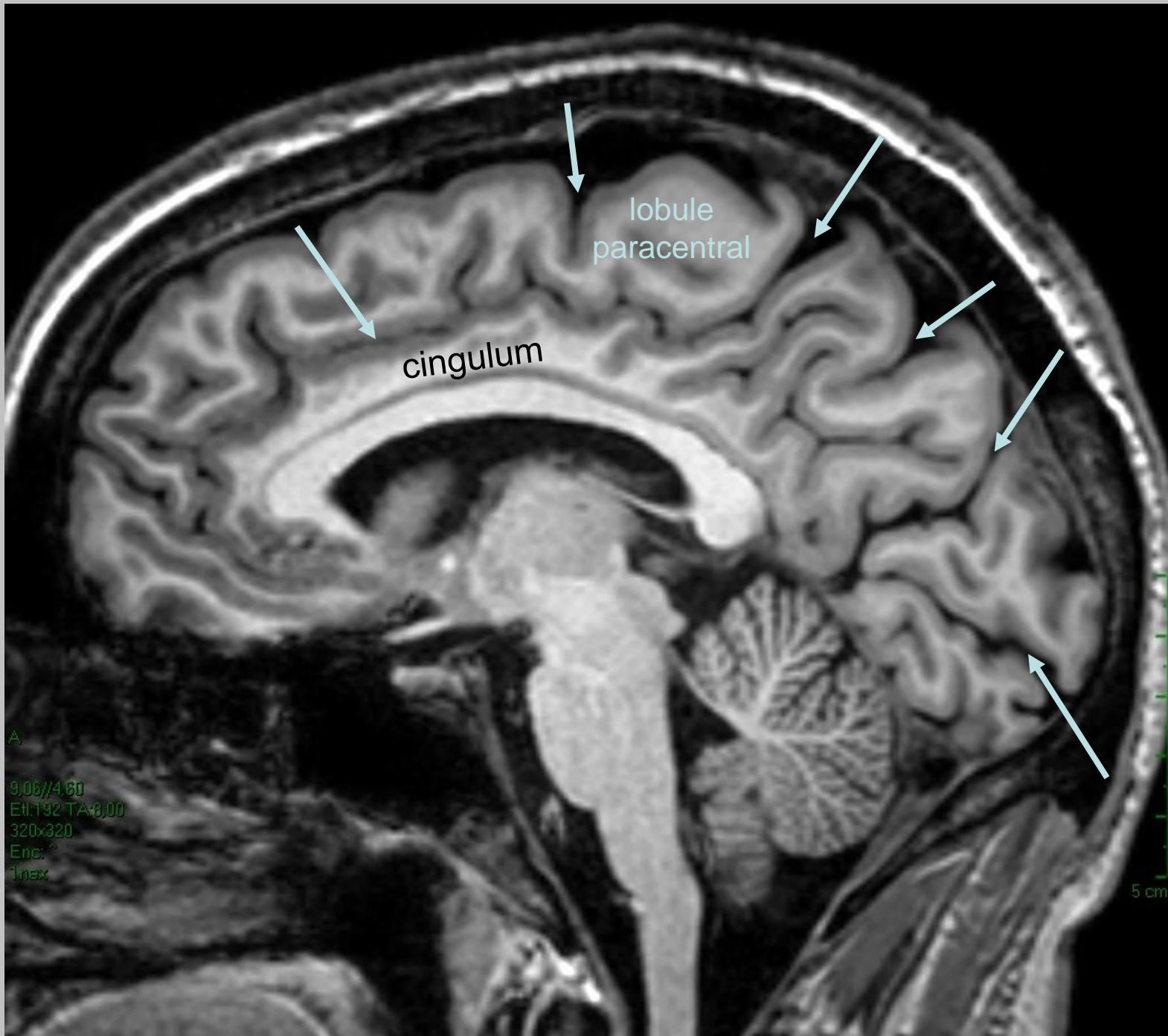




*ASP = aire somesthésique primaire

*ASA = aire somesthésique associative



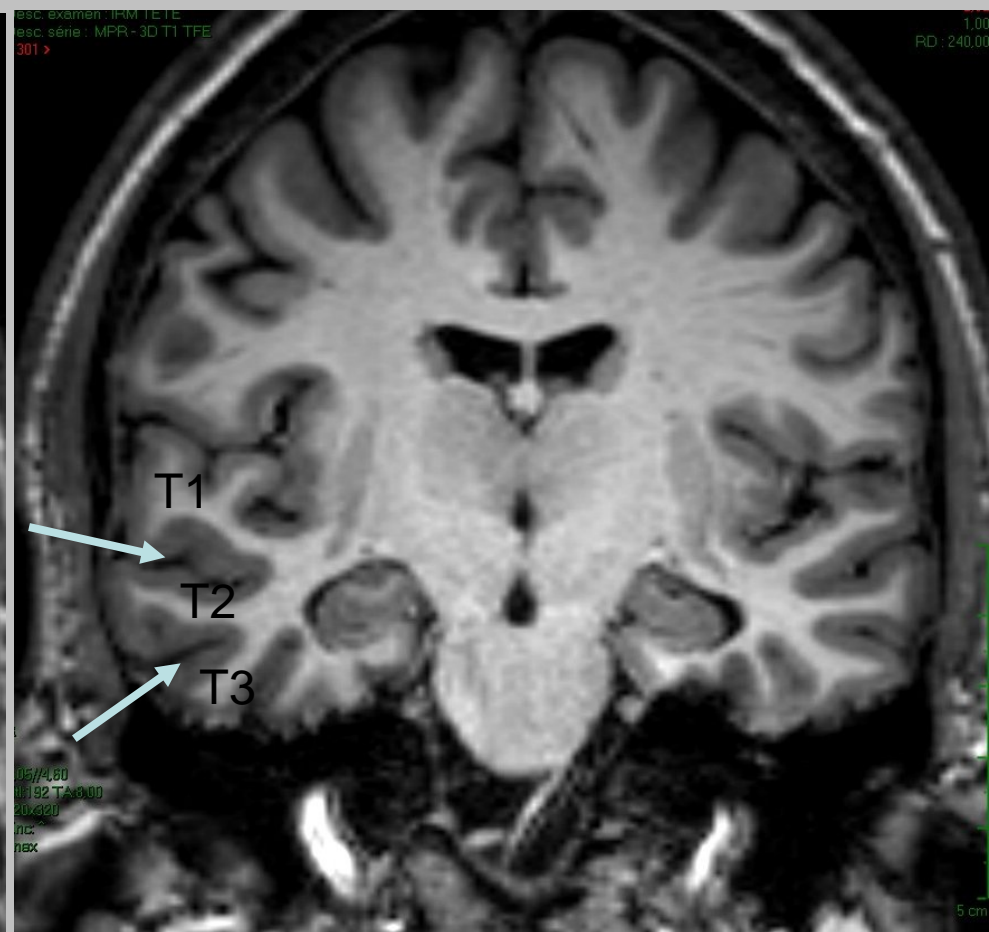
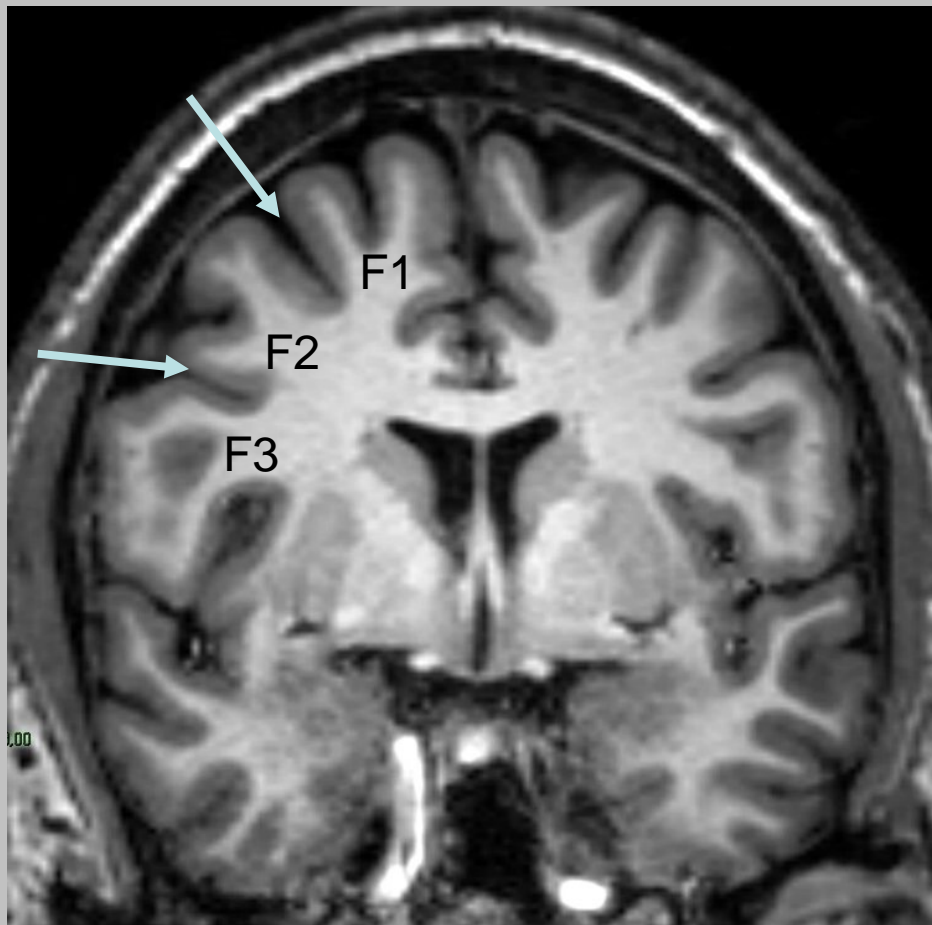


lobule
paracentral

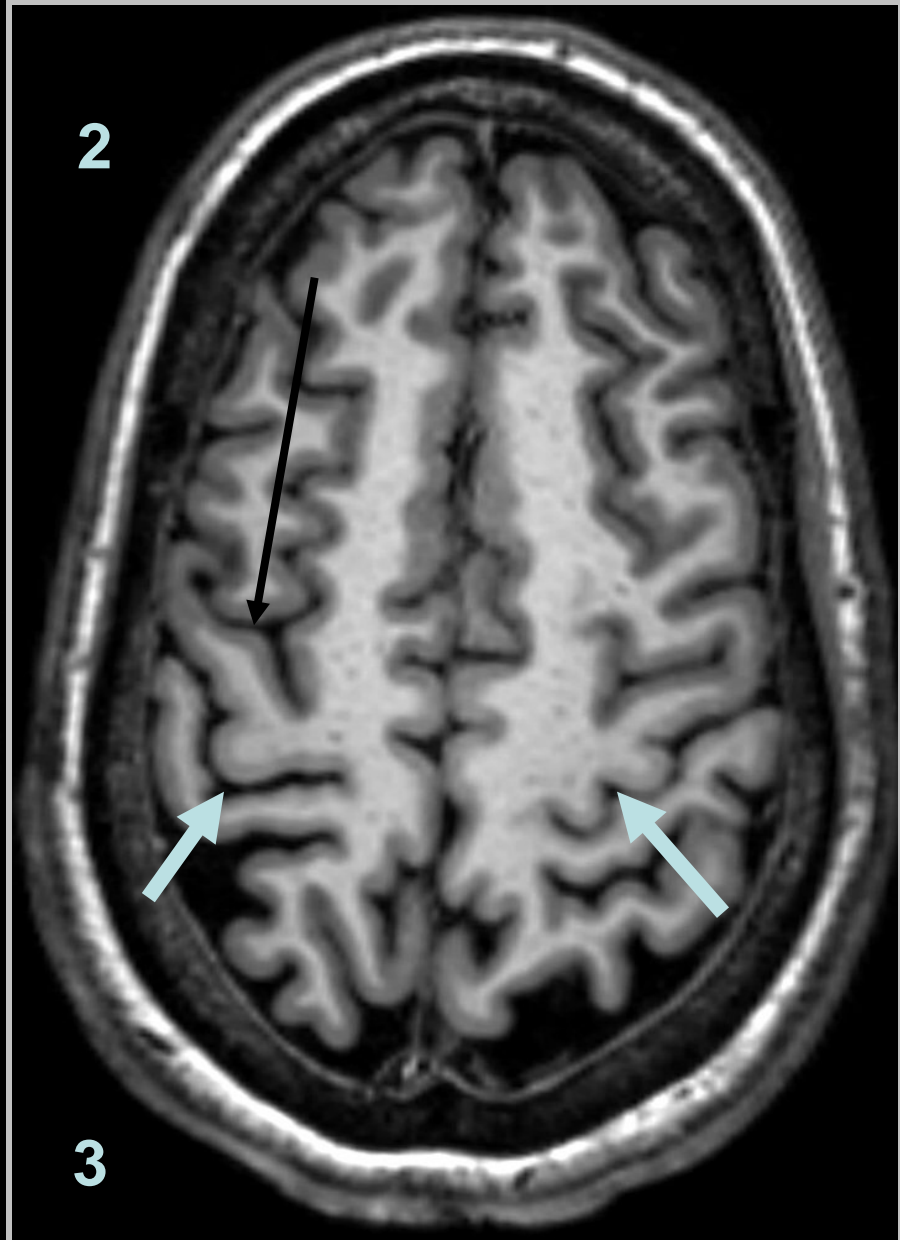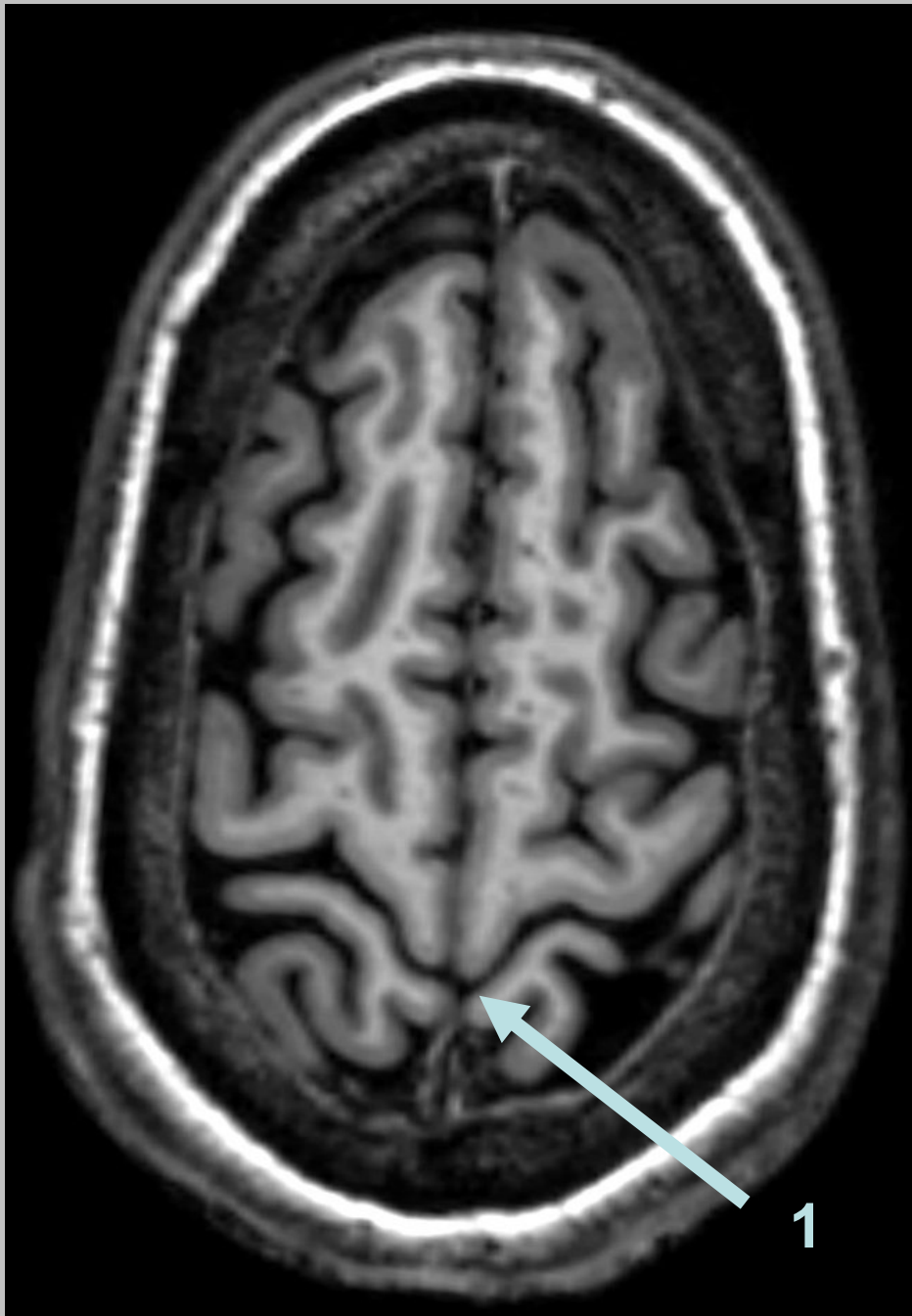
cingulum

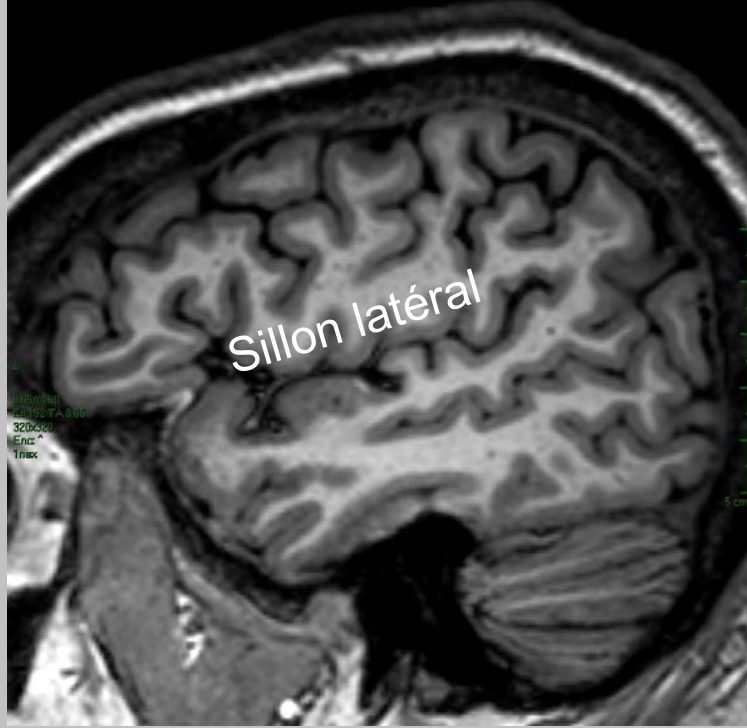A
9.08//4.60
Et: 192 TA: 8.00
320x320
Enc: ^
1max

5 cm

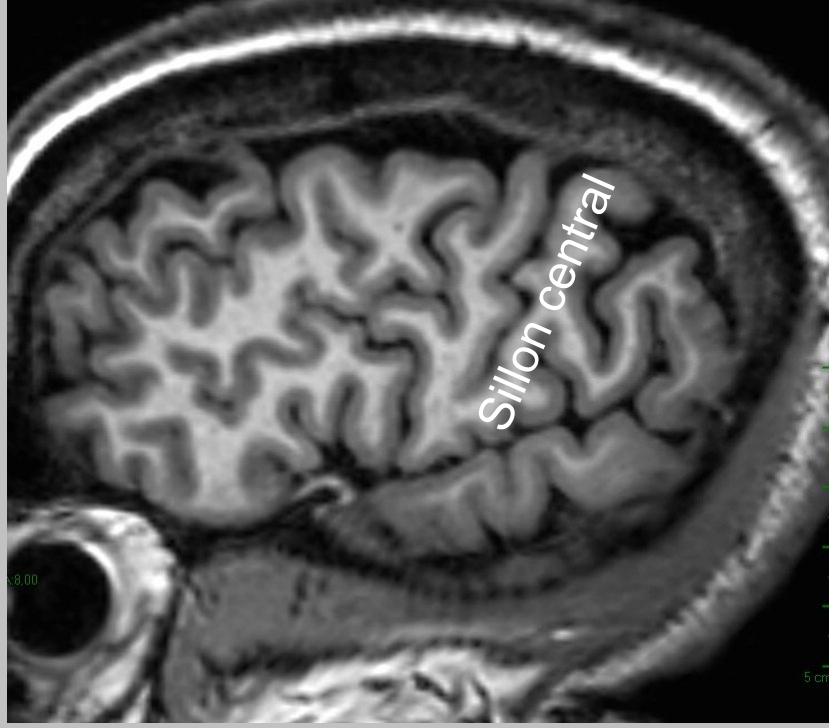


Recherche du sillon central

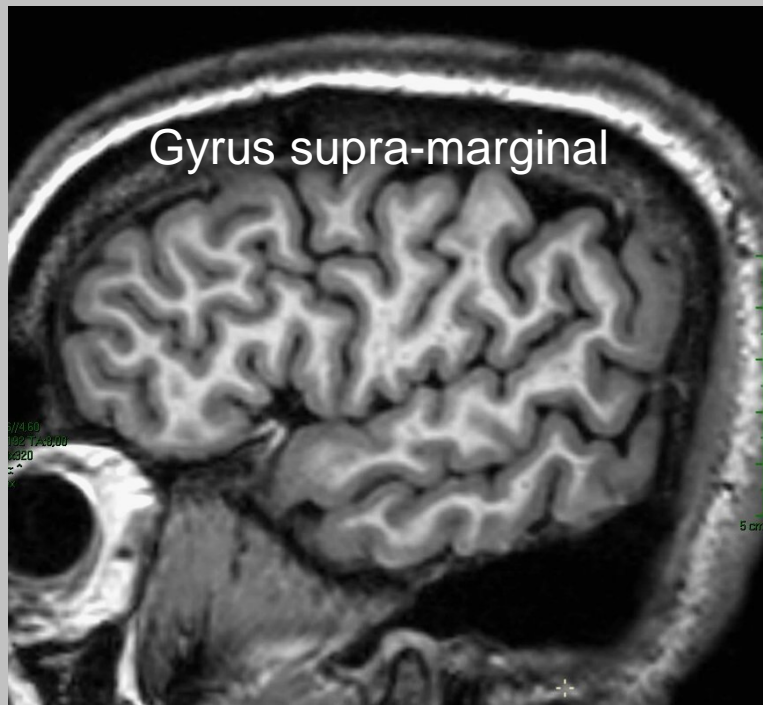




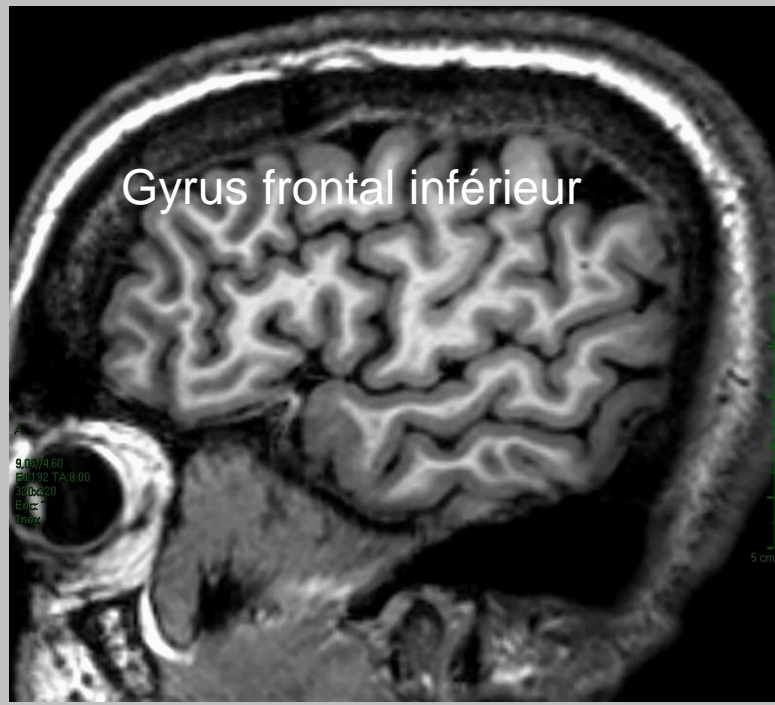
Sillon latéral



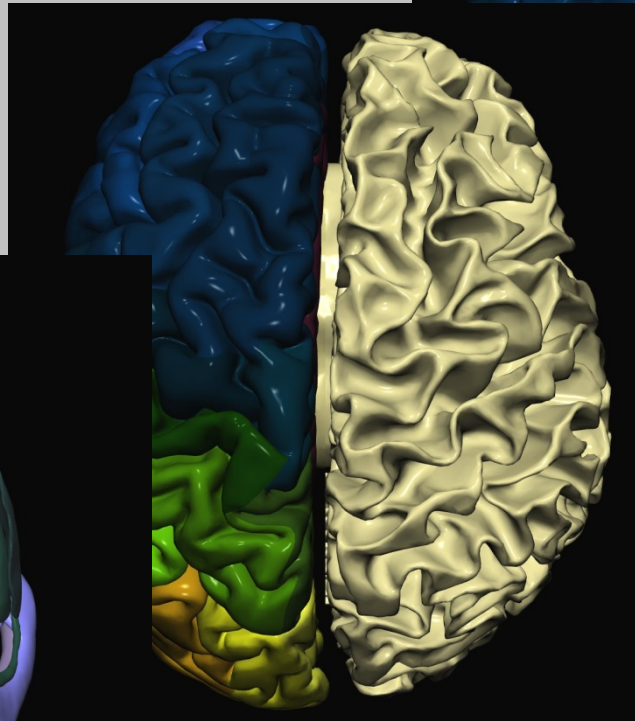
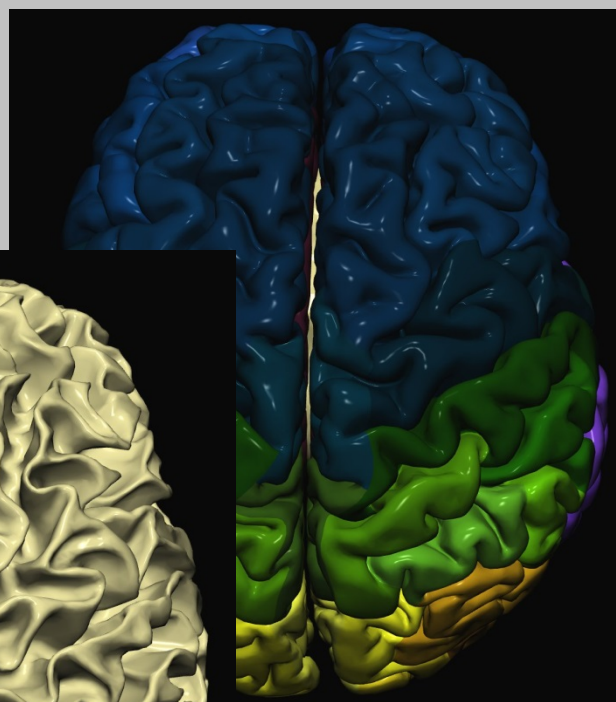
Sillon central



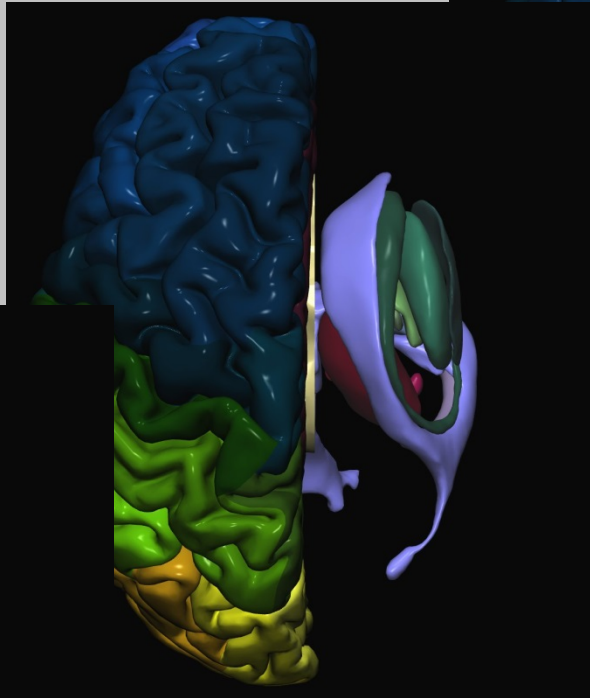
Gyrus supra-marginal



Gyrus frontal inférieur



décortication



**ablation de la
substance blanche**

