

Notions de radiologie abdominale

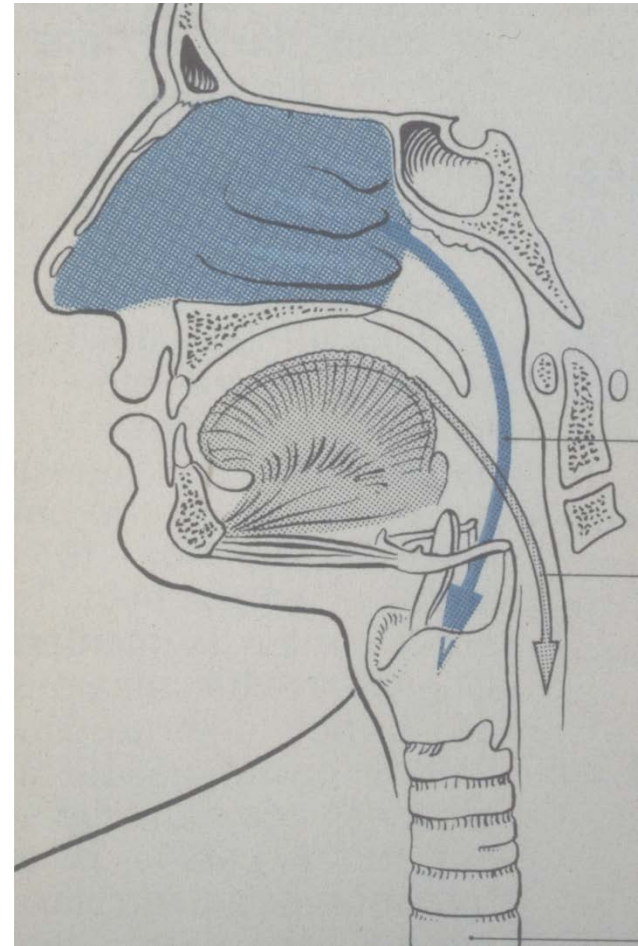
Bac 13

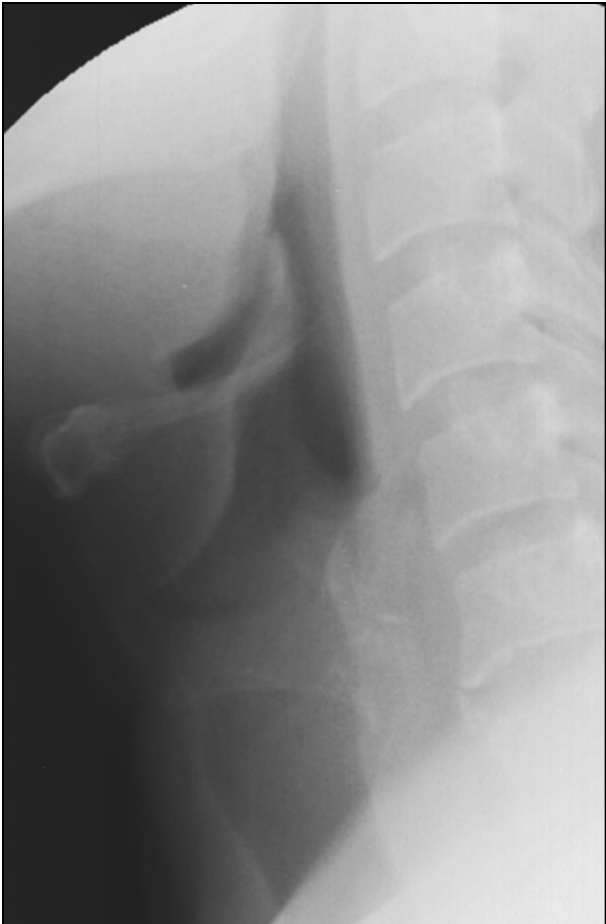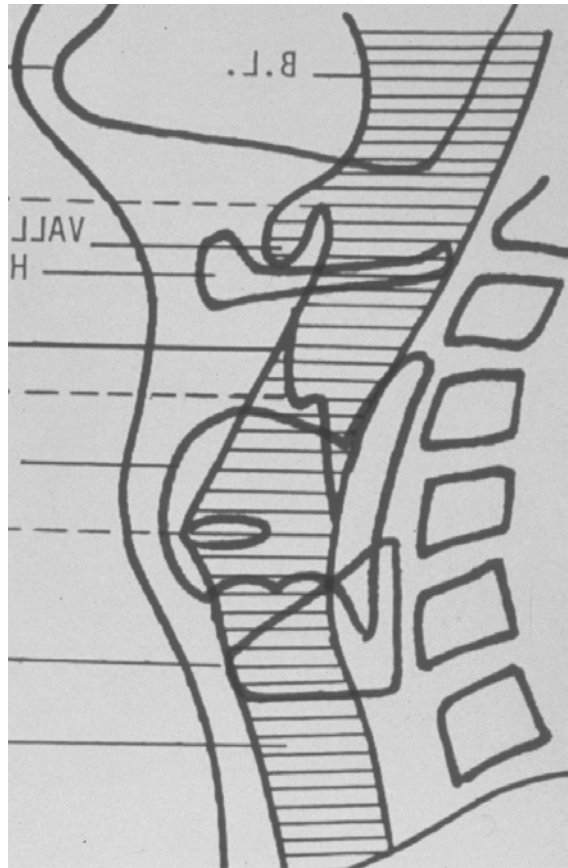
Notions d'anatomie radiologique

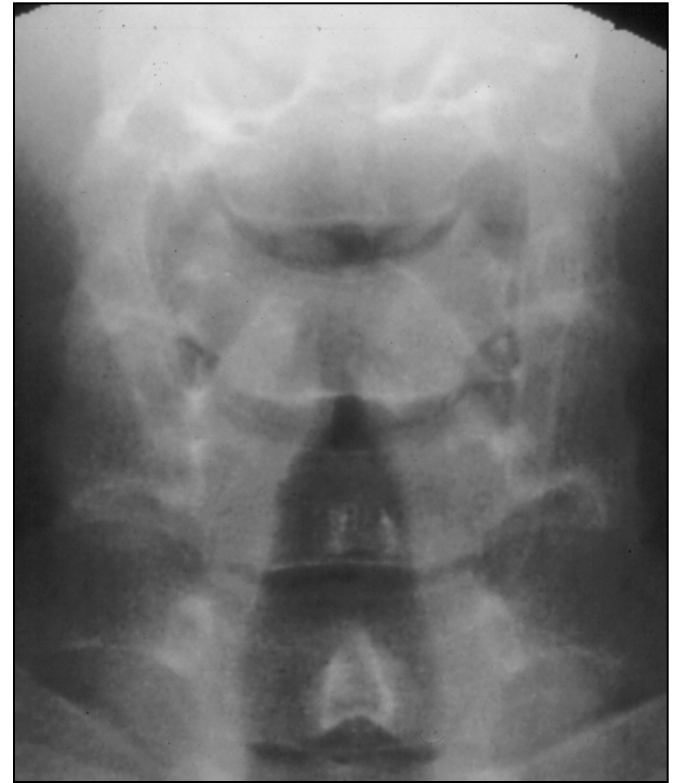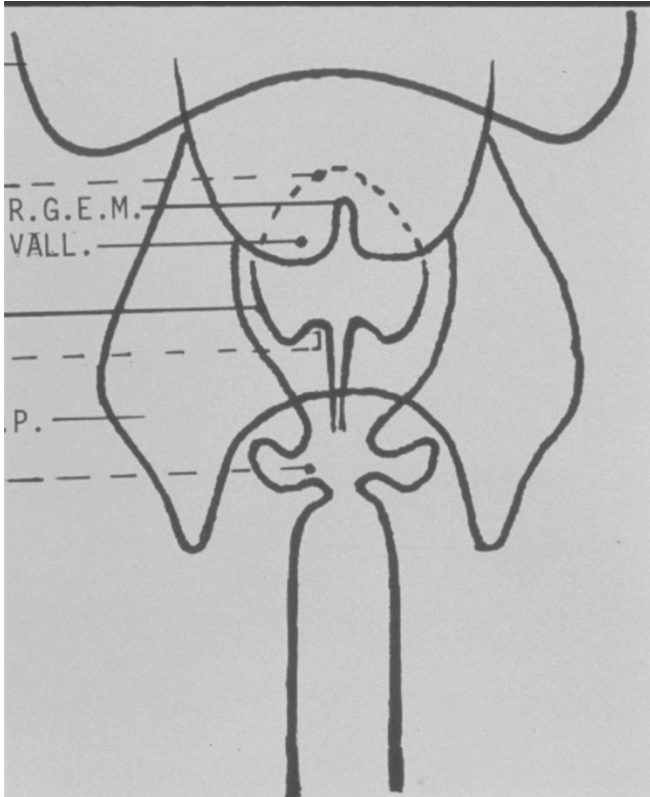
- Foie, voies biliaires, pancréas
- Tube digestif
 - Du pharynx à l'anus
- Voies urinaires
 - Des reins aux testicules
- Vascularisation abdominale et péritoine

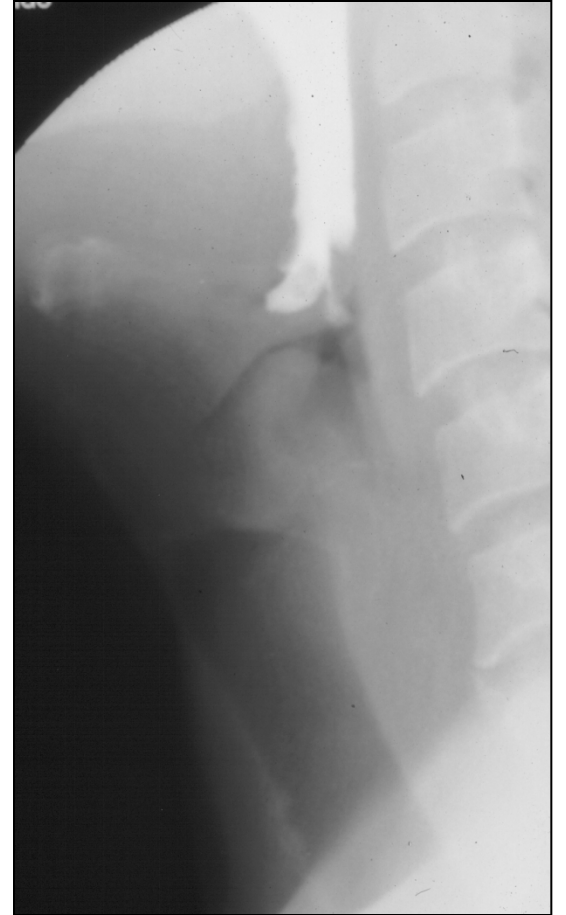
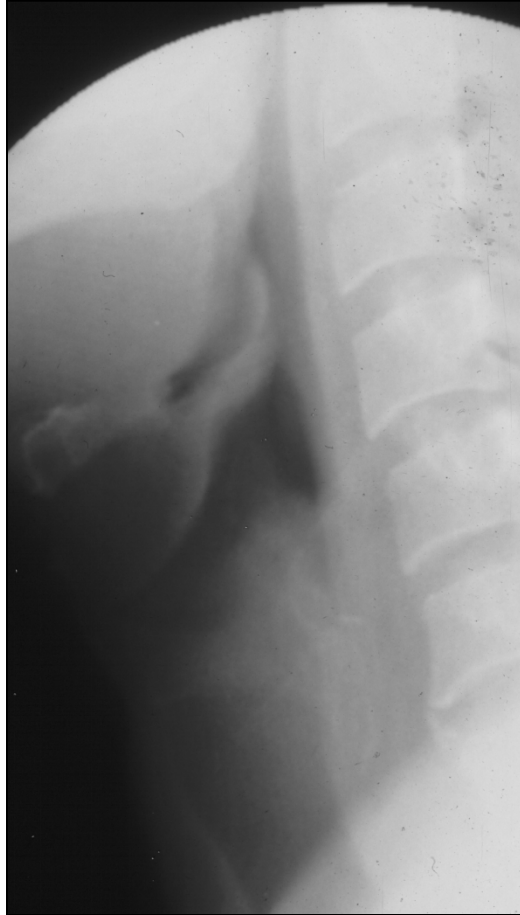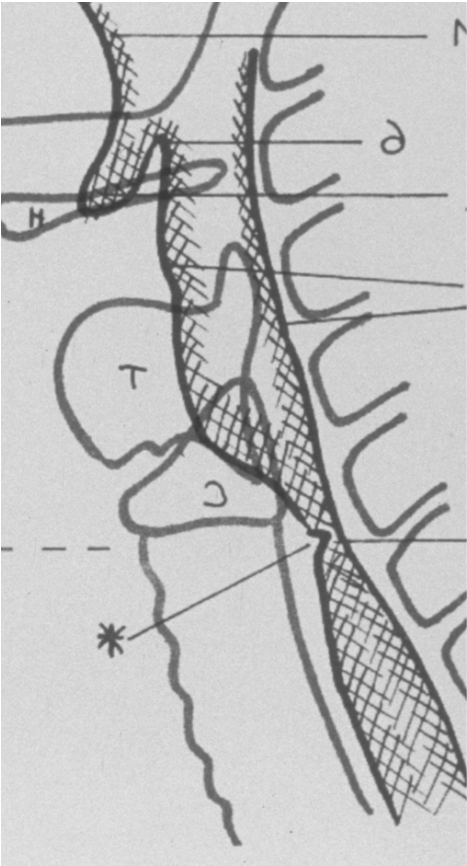
Pharynx

- Conduit mixte en arrière des cavités nasales et de la bouche et se continuant à son extrémité inférieure dans le larynx à l'avant et l'oesophage à l'arrière

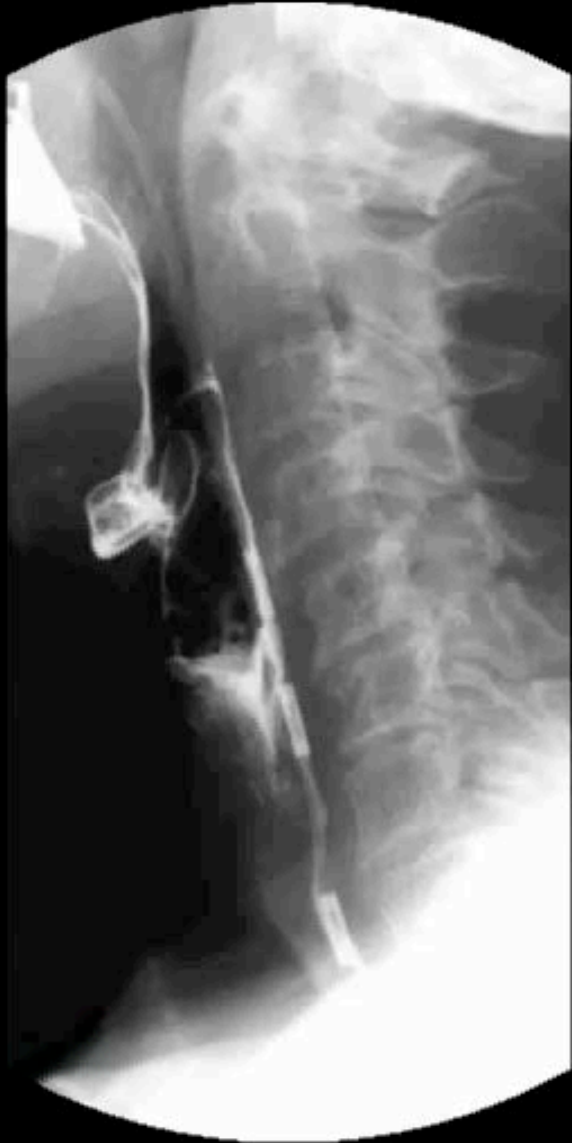







<2-1>



Déglutition

Bouche et pharynx

Accolement de la langue au voile du palais

Recul de la langue

Elévation du voile du palais

Contraction des muscles constricteurs

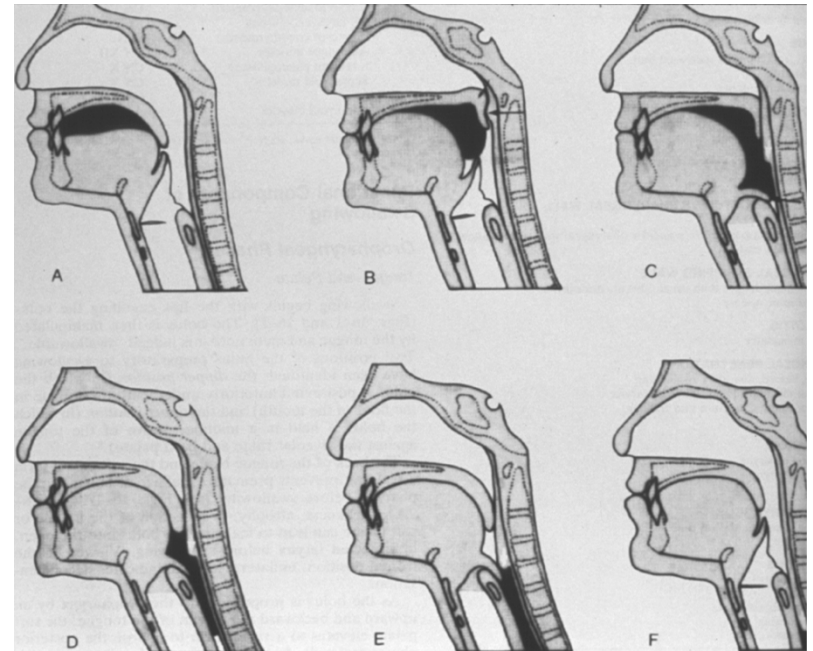
Larynx

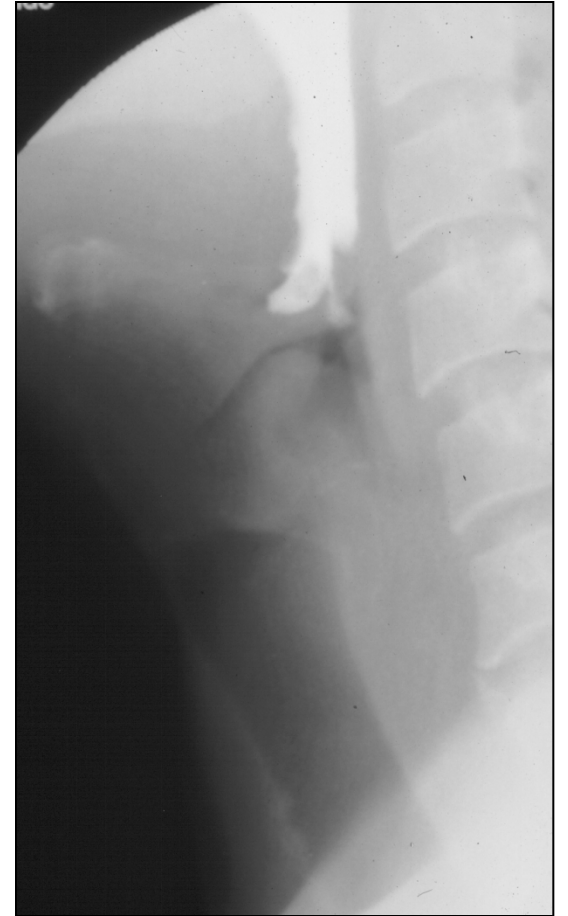
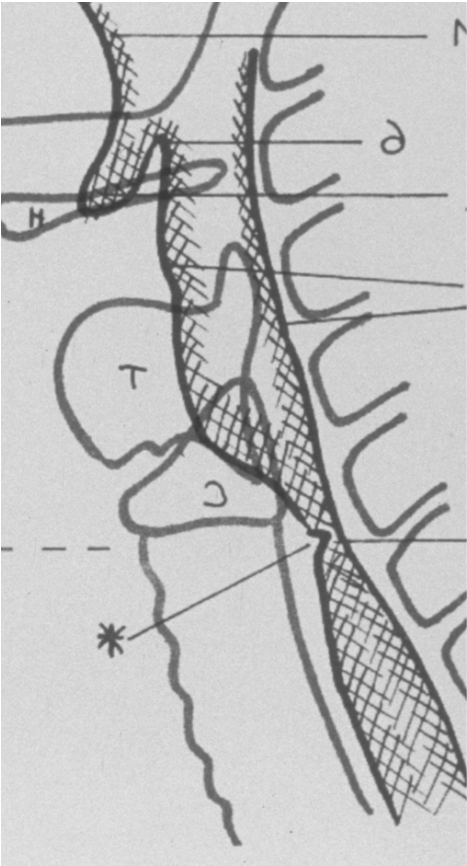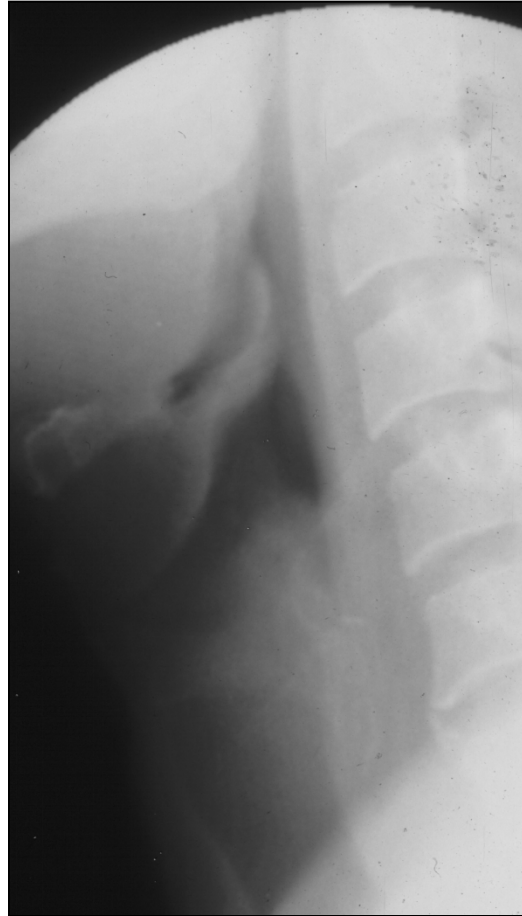
Fermeture du vestibule et des cordes

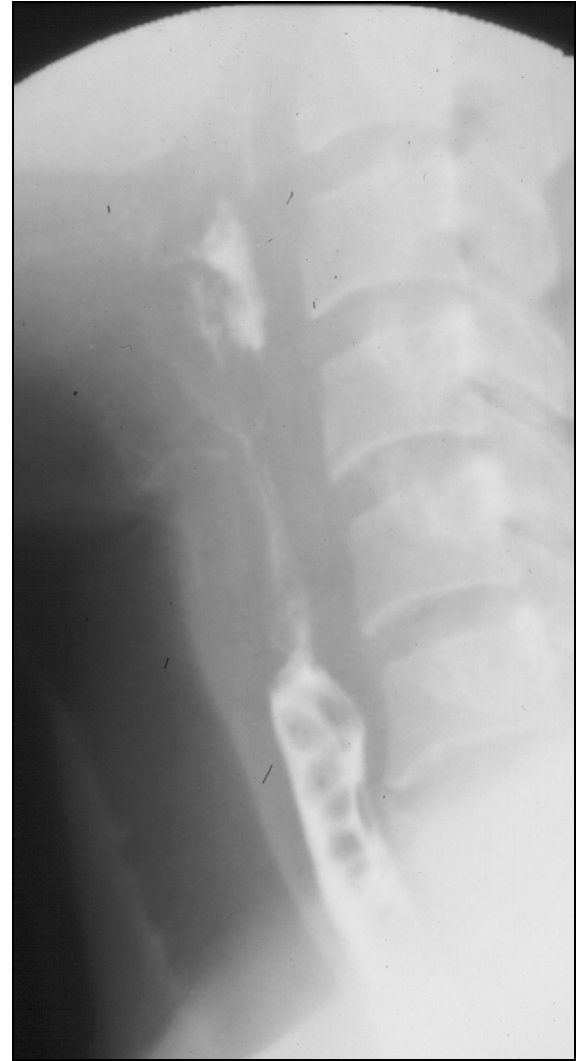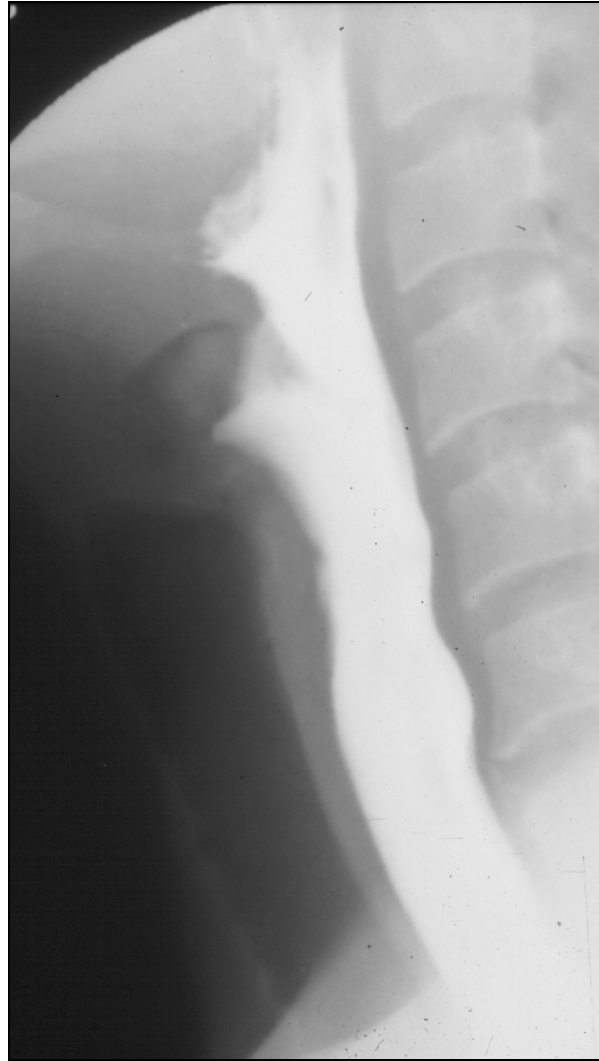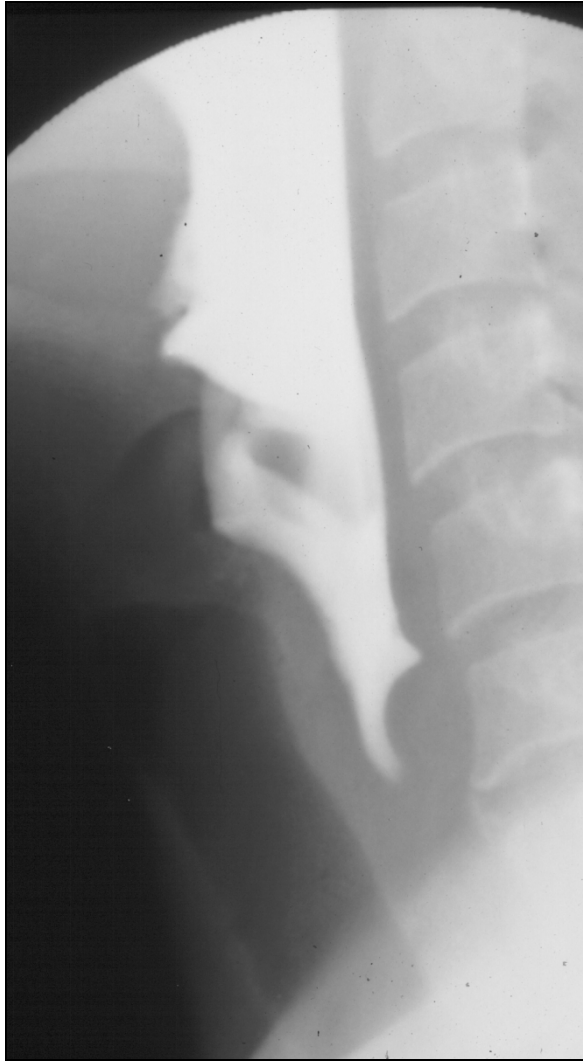Elévation du larynx et de l'os hyoïde

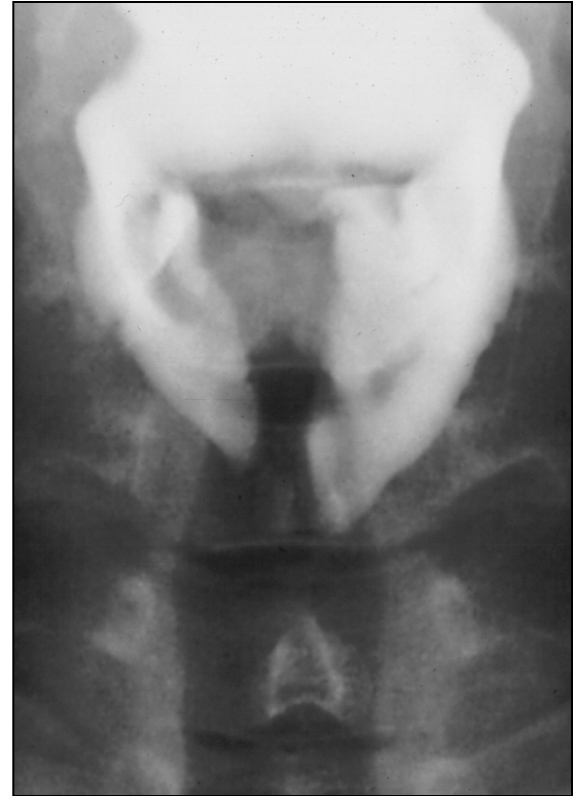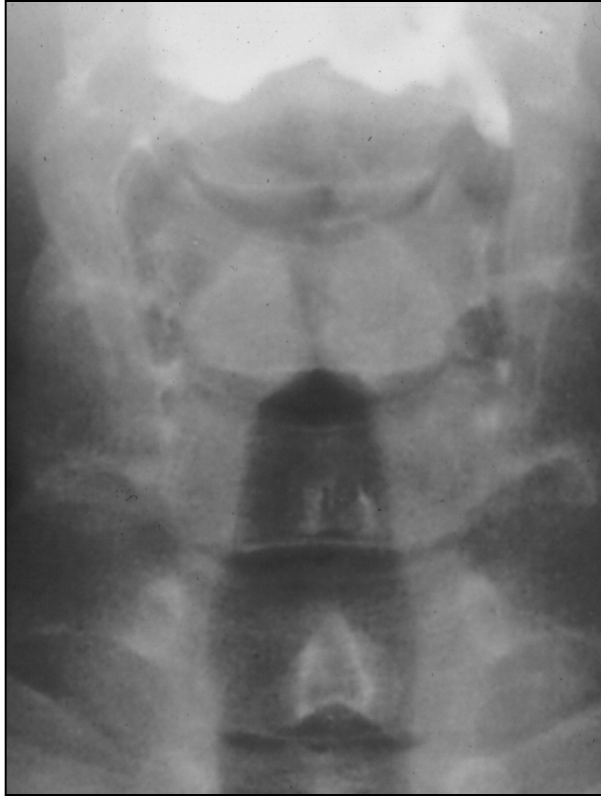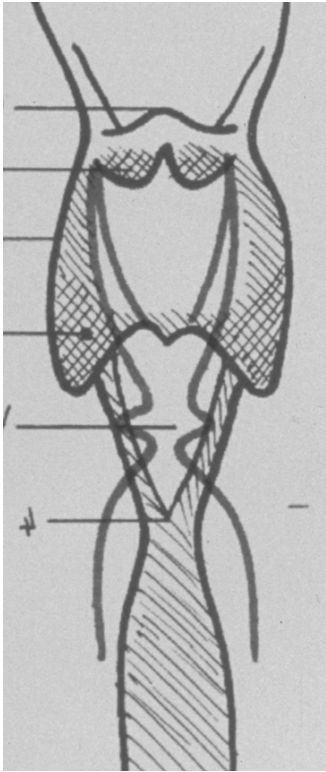
Epiglotte : bascule postérieure

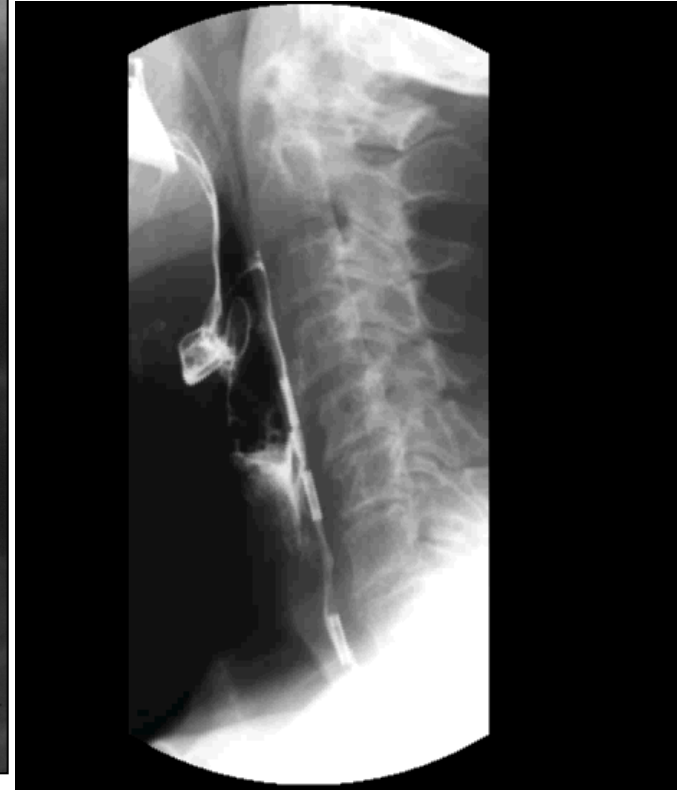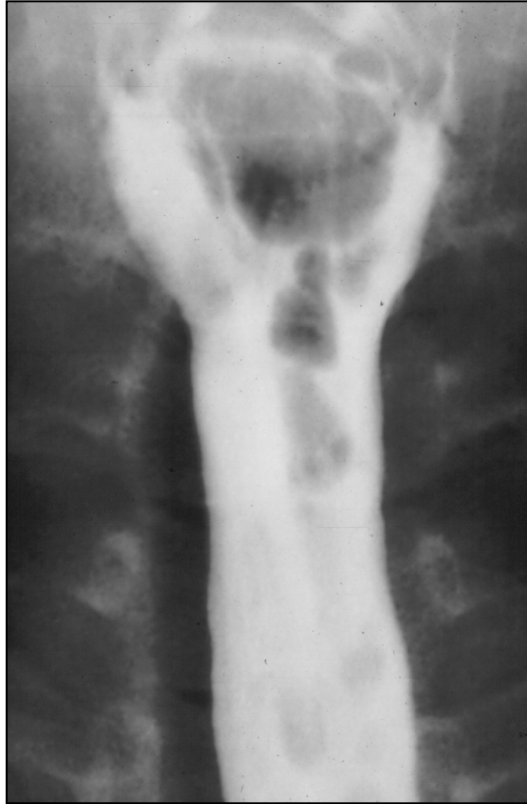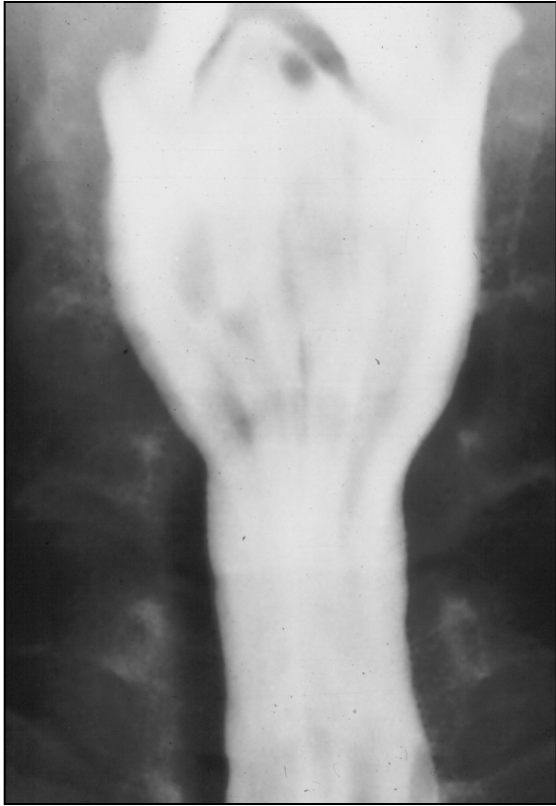Muscle crico-pharyngien : bouche
oesophagienne : relaxation

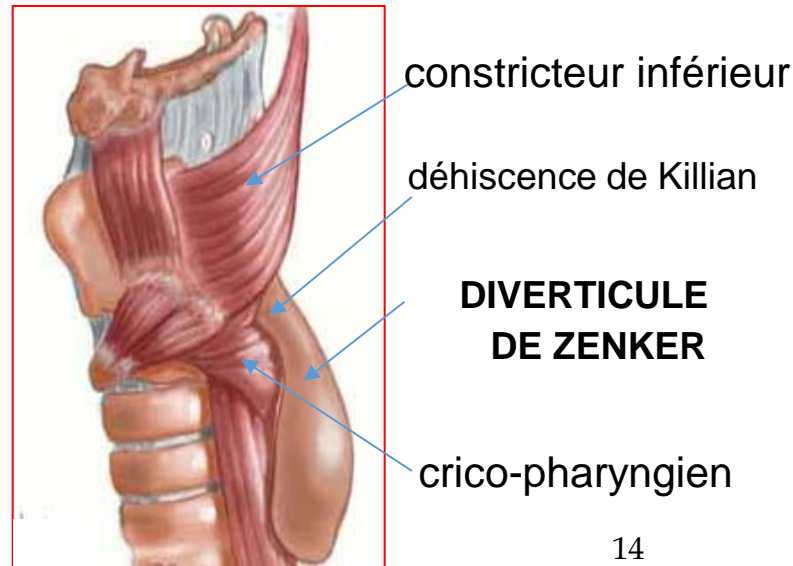
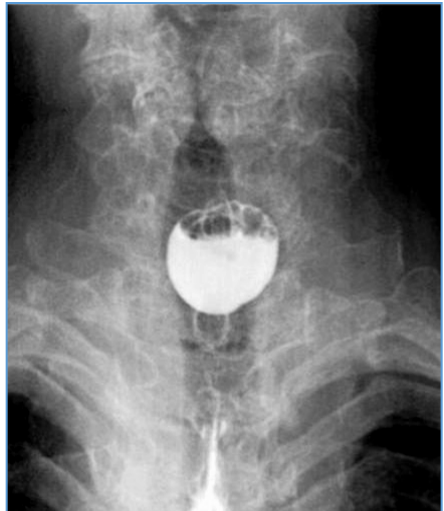
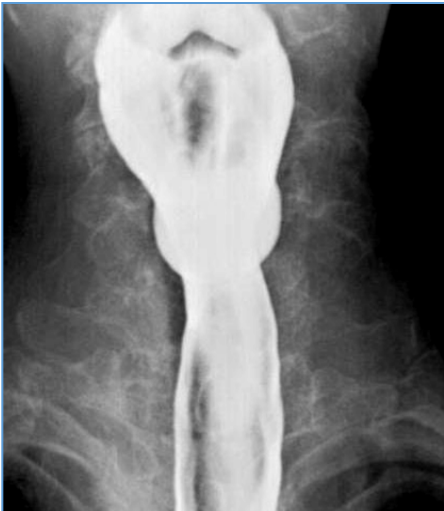
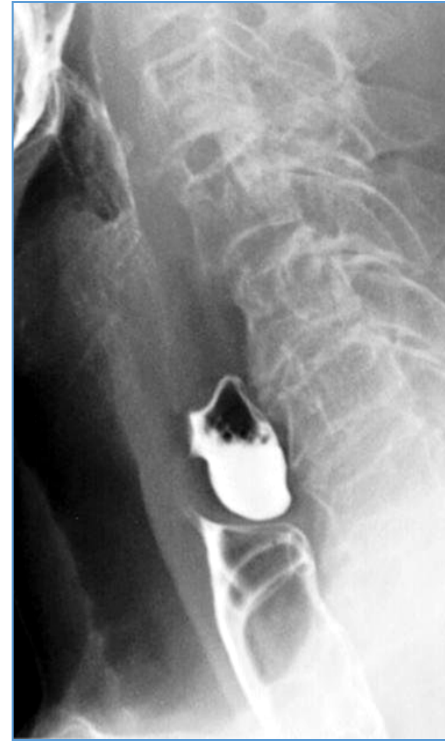
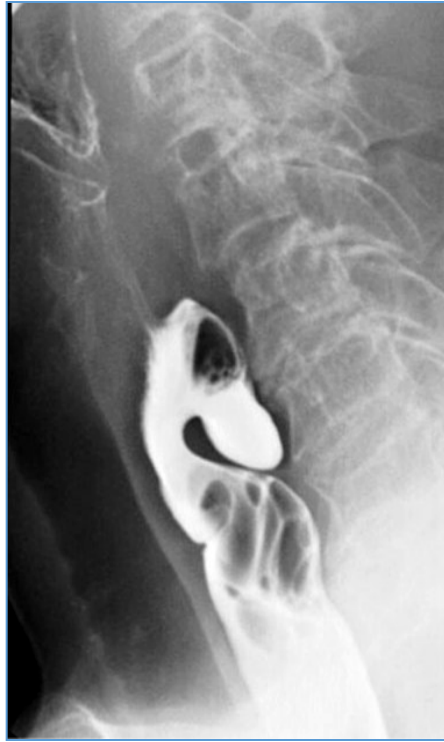
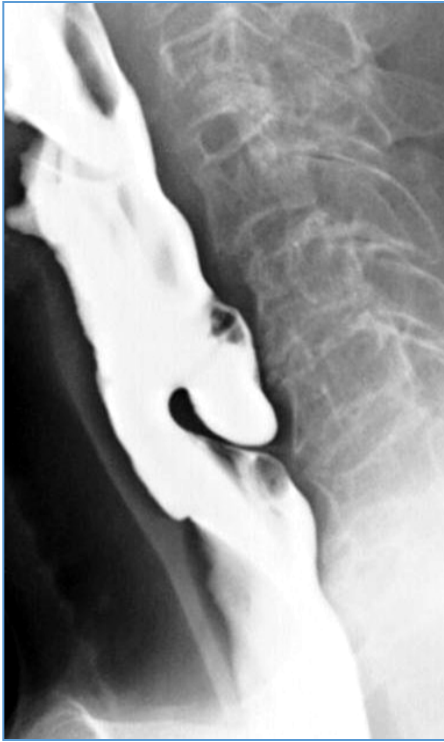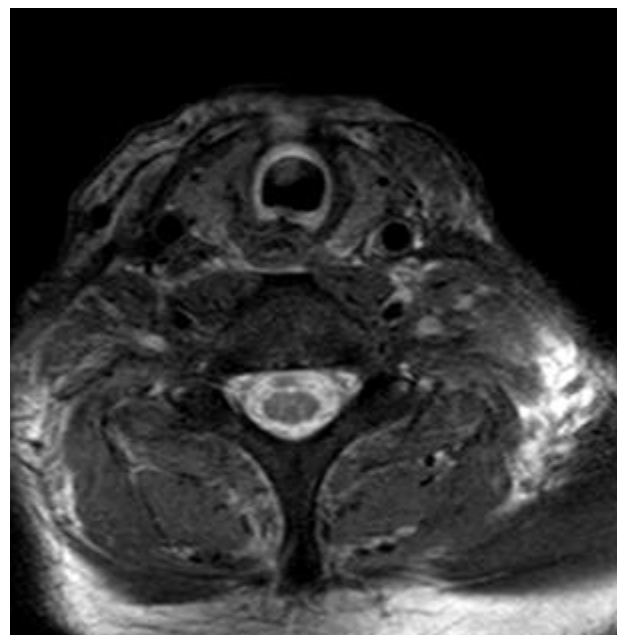





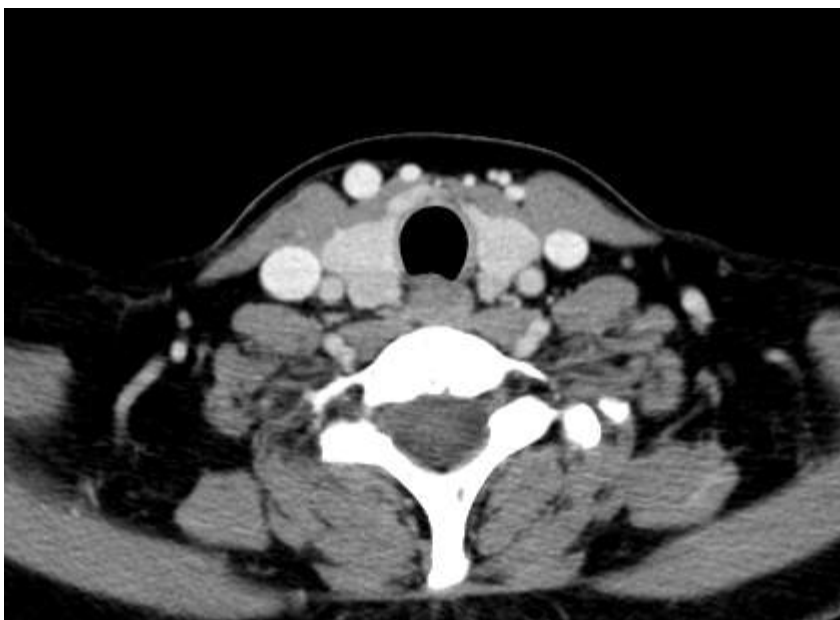


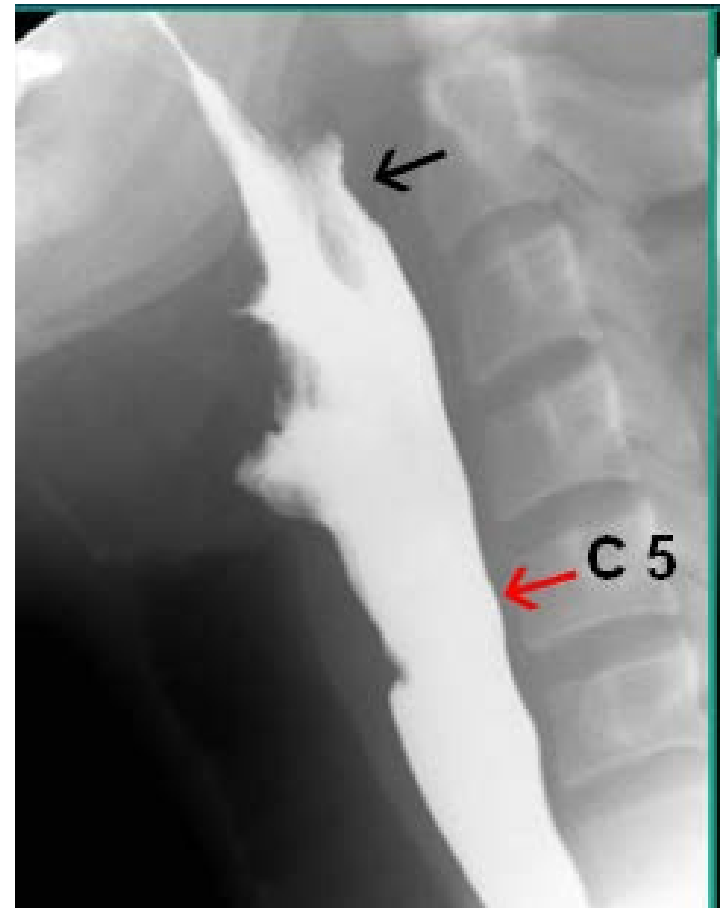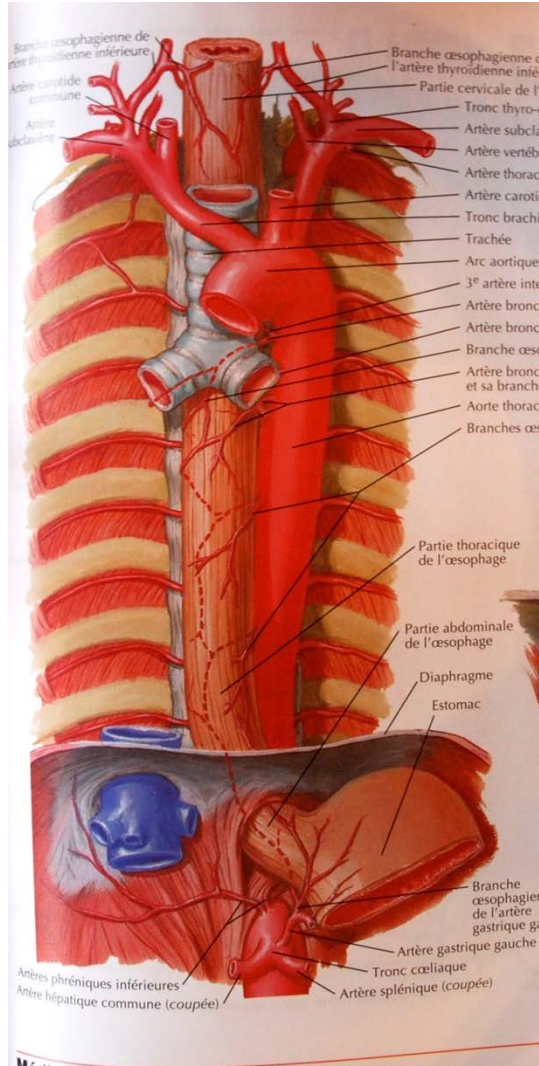
CT scanner – IRM du cou



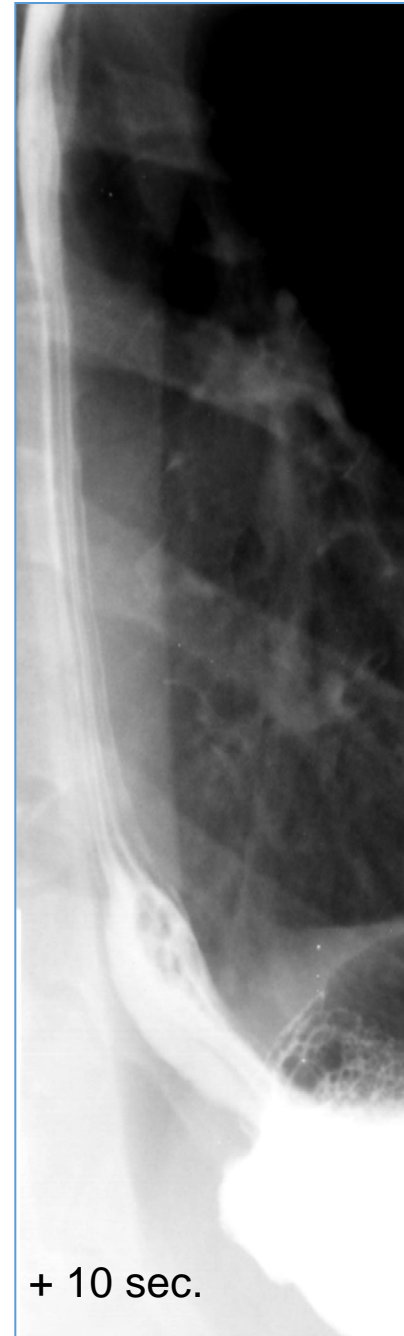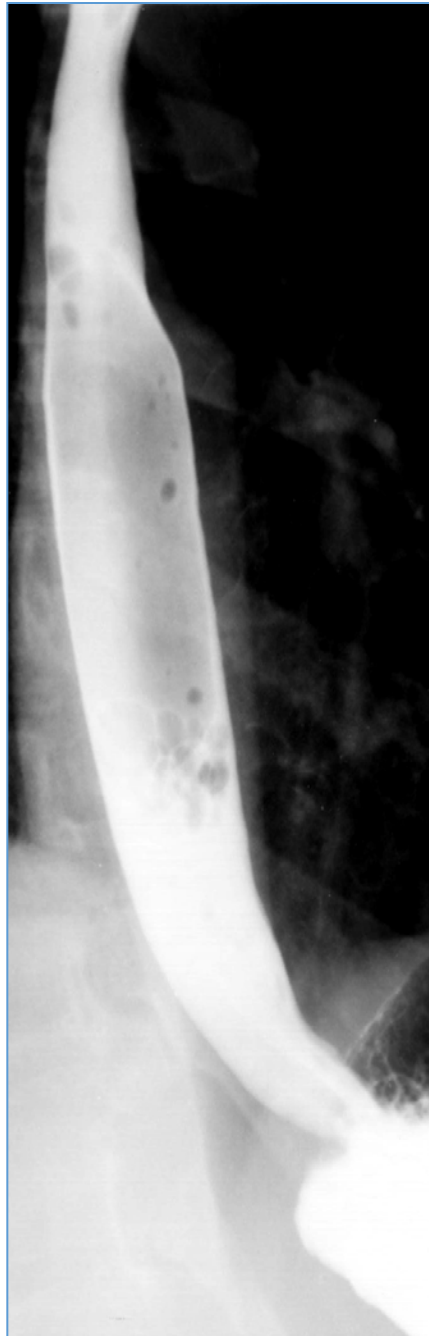Oesophagus

- Radiologie
- CT scanner





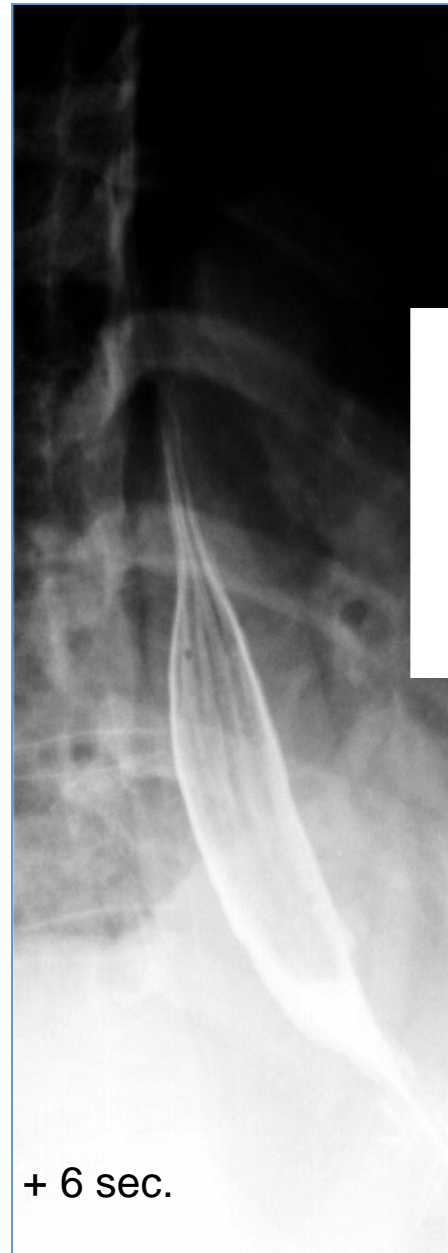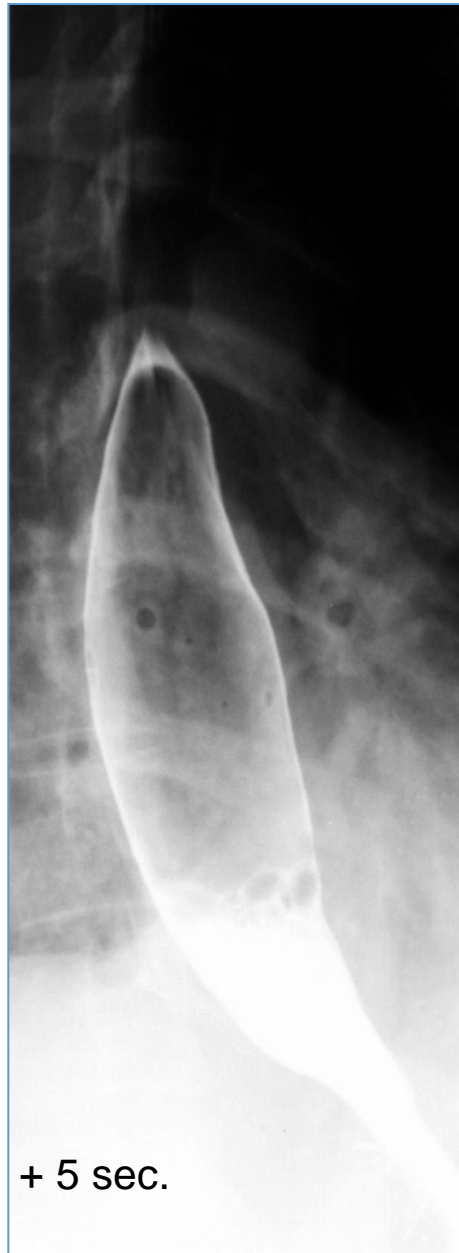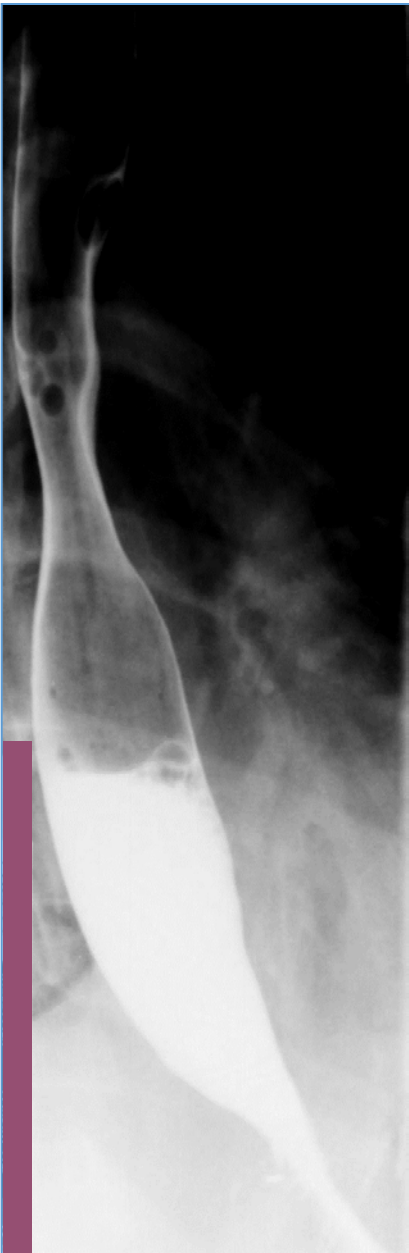
In Netter, Atlas d'anatomie humaine
Masson, 2007



PERISTALTIQUE
PRIMAIRE

(1- 4 cm / sec.)

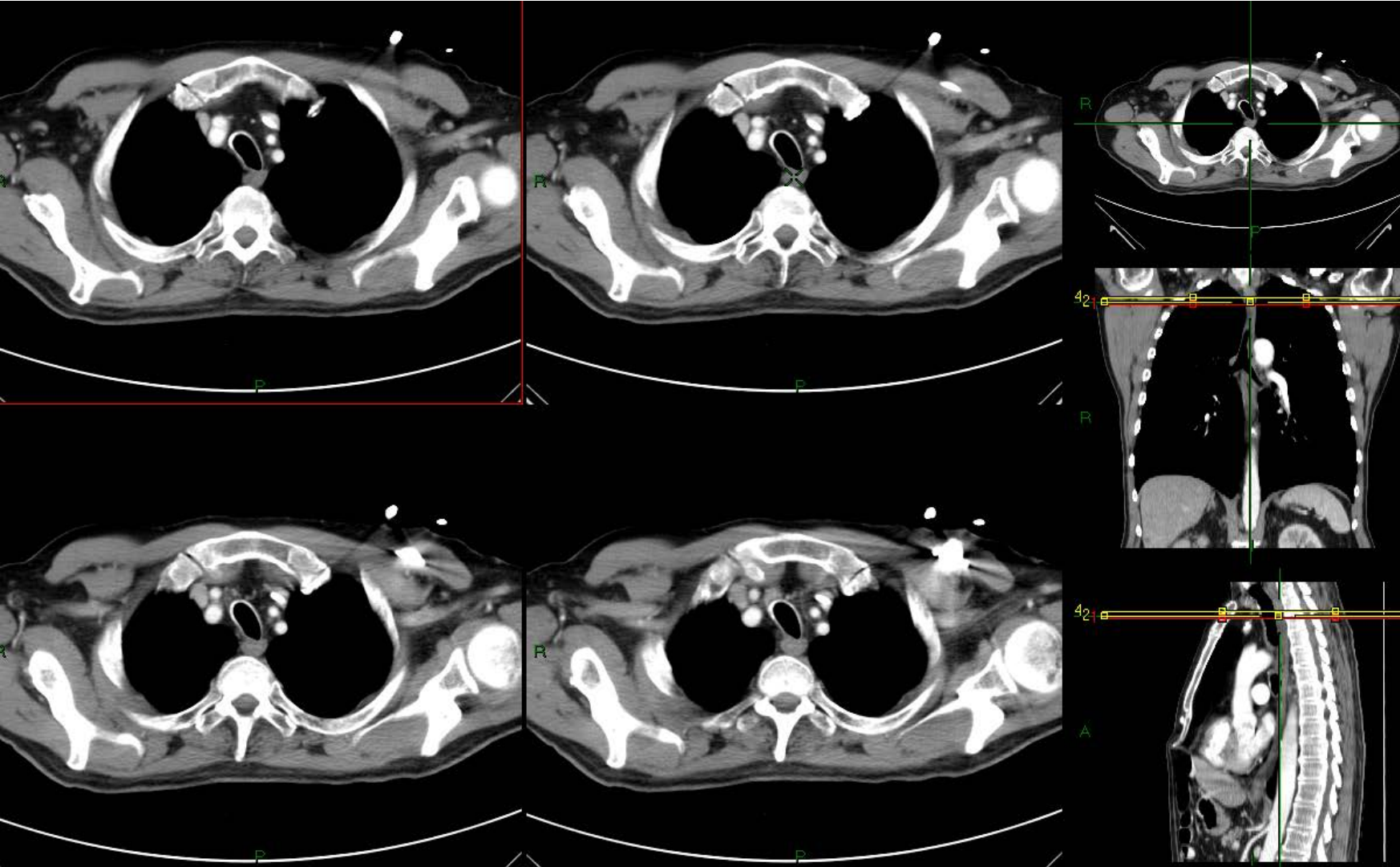
+ 10 sec.

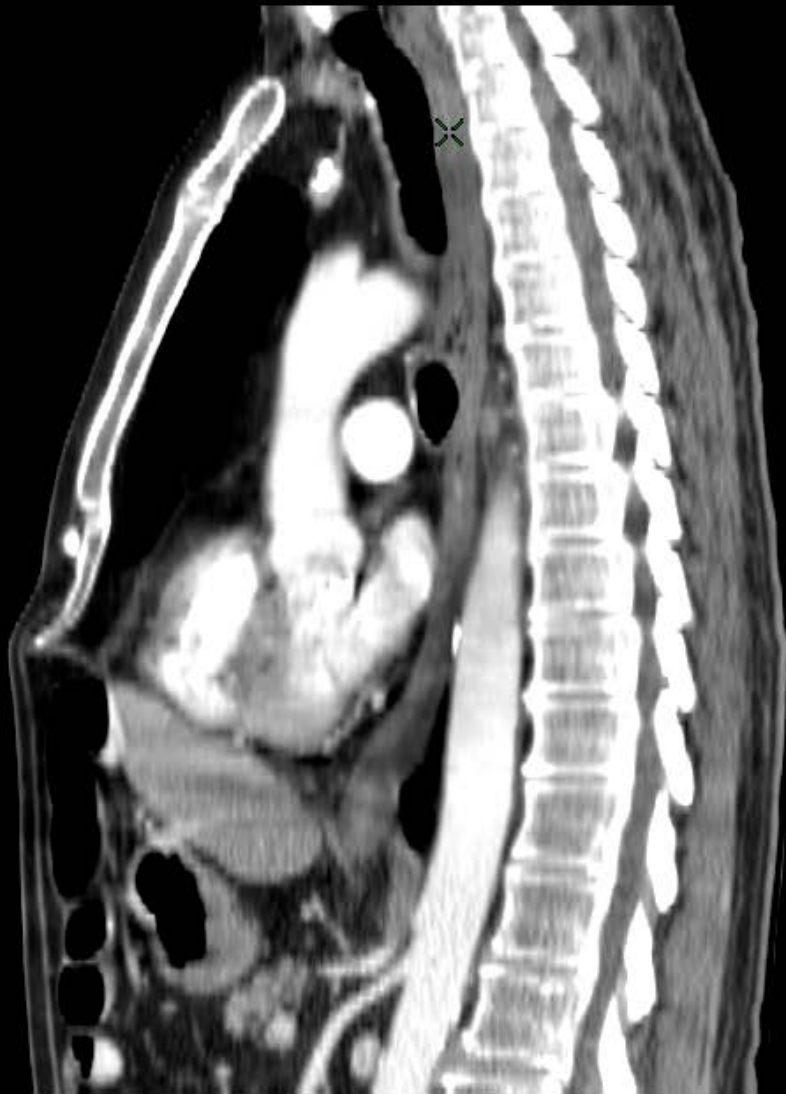

PERISTALTIQUE
PRIMAIRE
NORMALE
(en V inversé)

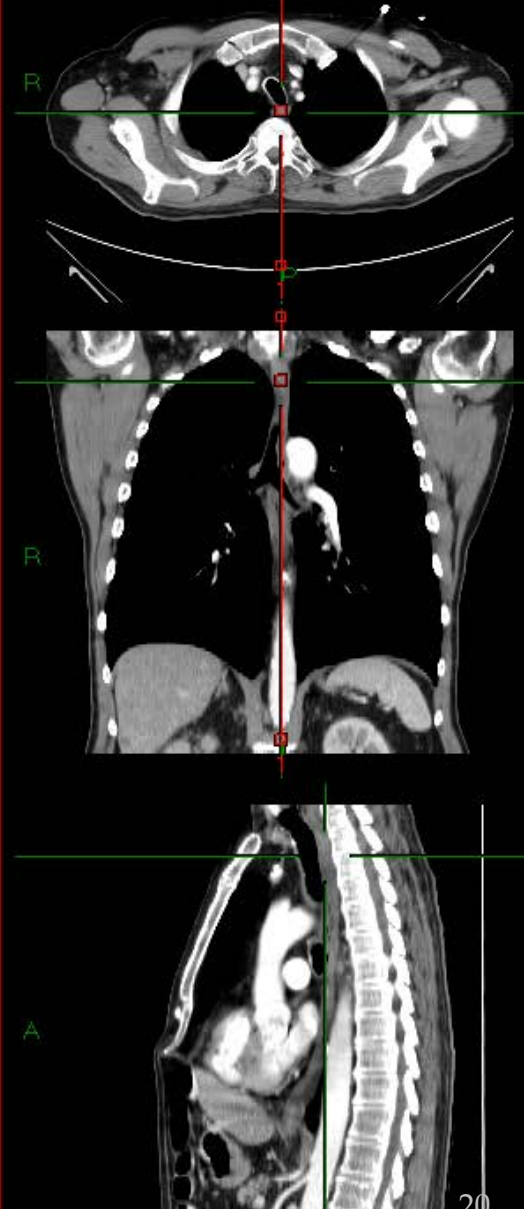
(1- 4 cm / sec.)

CT scanner



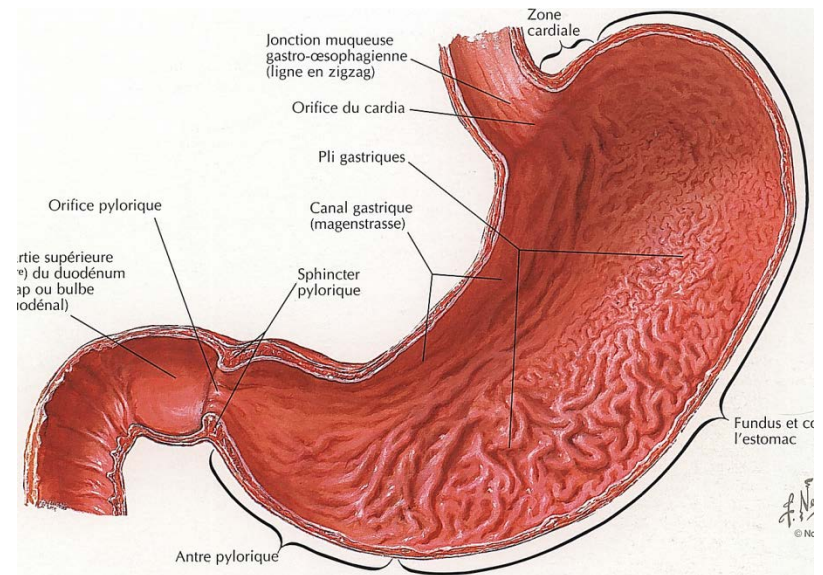


Épaisseur de la paroi de l'œsophage:
= 5 mm en contraction, 3 mm si distendu
= jamais > 5,5 mm
= 1 mm de plus chez l'homme



Estomac

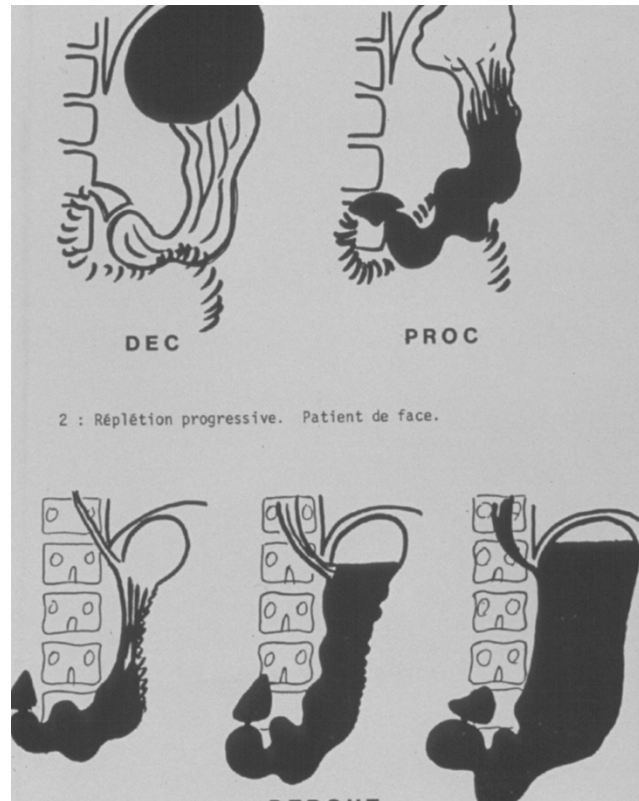
- Forme en J
- Deux faces : antérieure et postérieure
- Deux bords : petite et grande courbures
- Divisions
 - Cardia : extrémité supérieure
 - Fundus ou grosse tubérosité
 - Corps
 - Antre prépylorique
 - Pylore (sphincter) : extrémité inférieure
- Plis gastriques

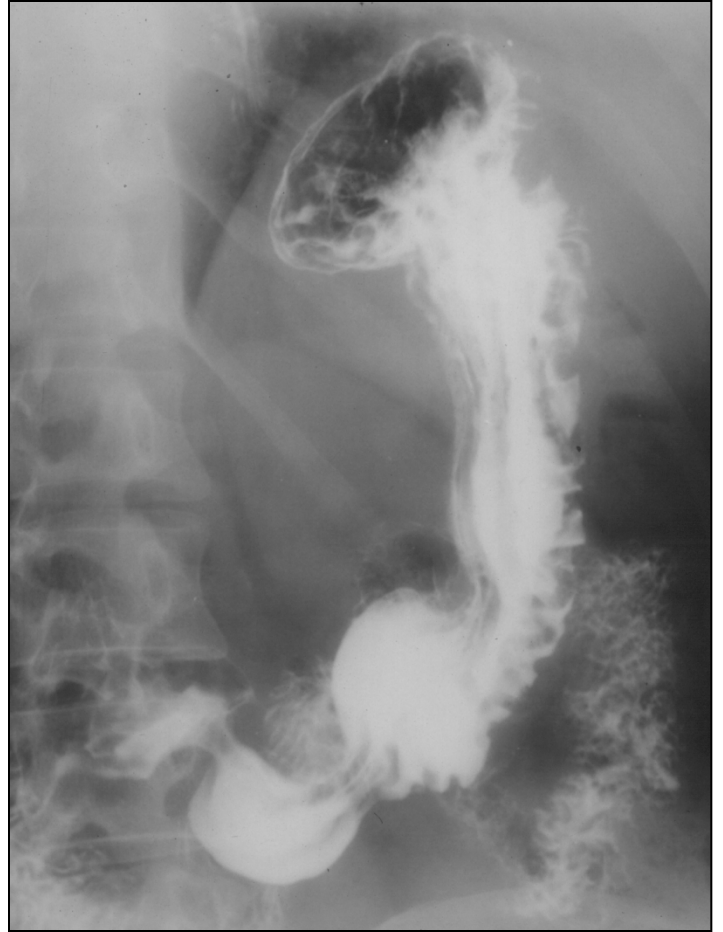
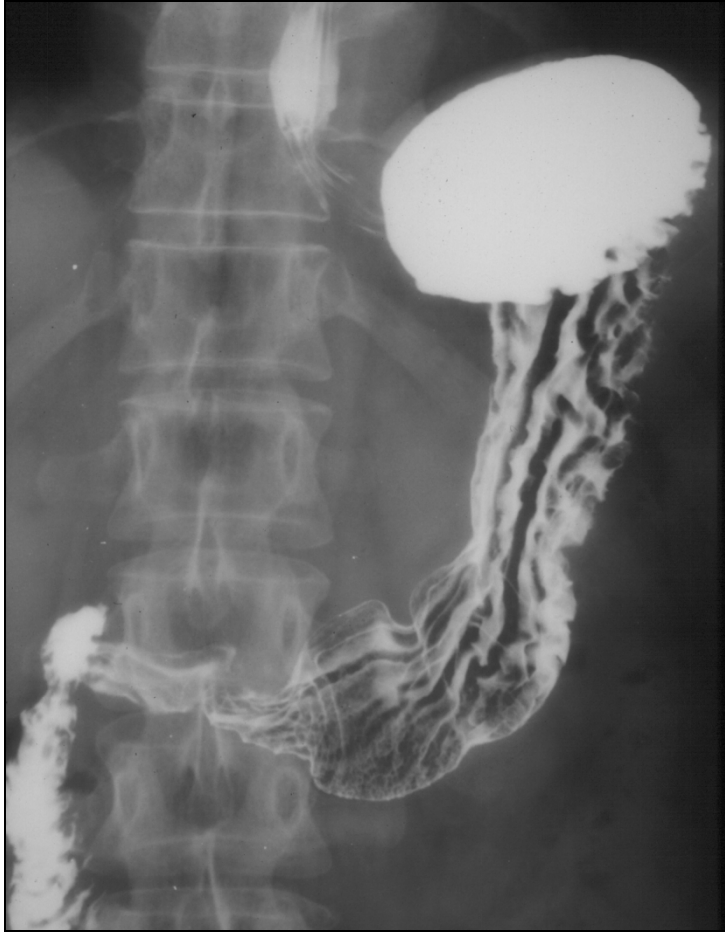
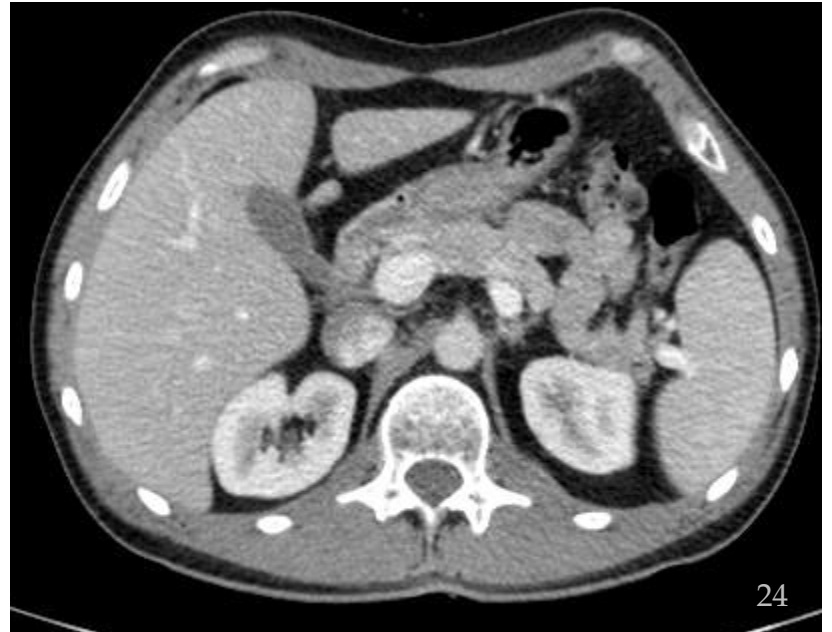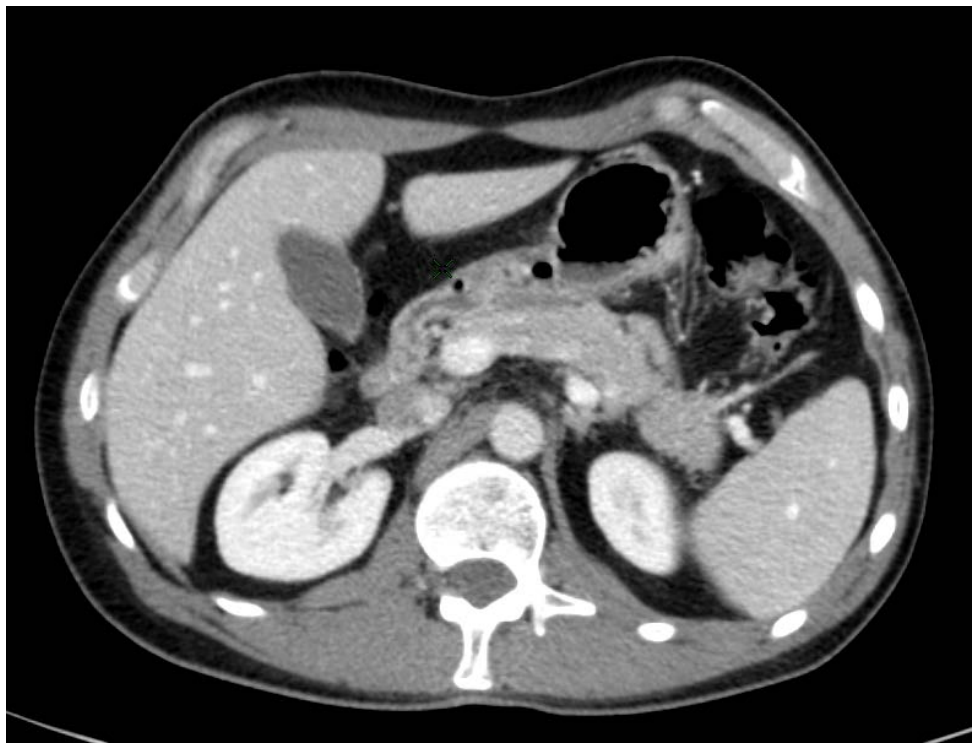
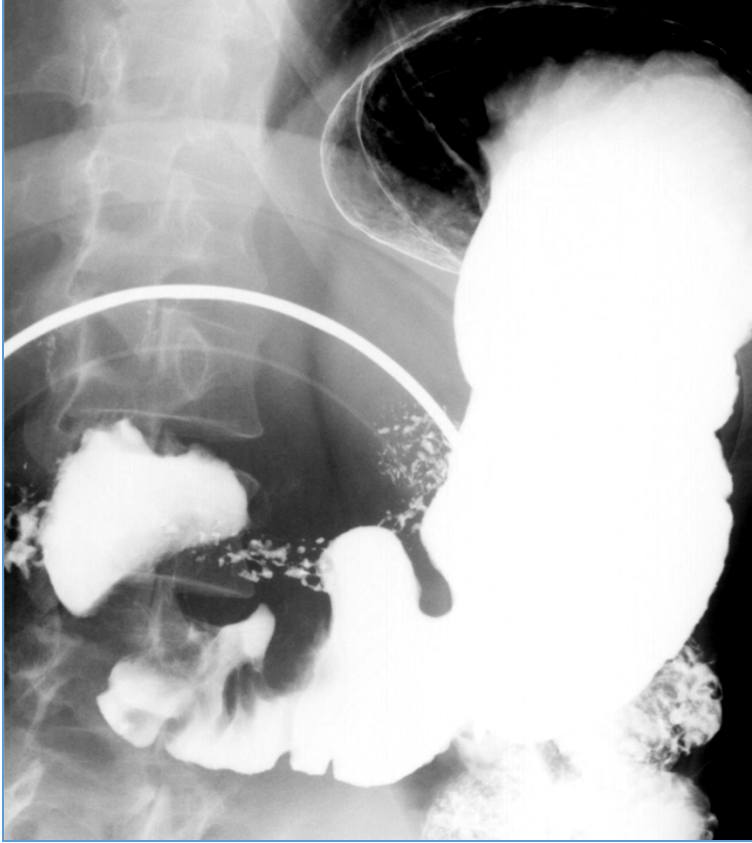In Netter, Atlas d'anatomie humaine, Masson, 2007

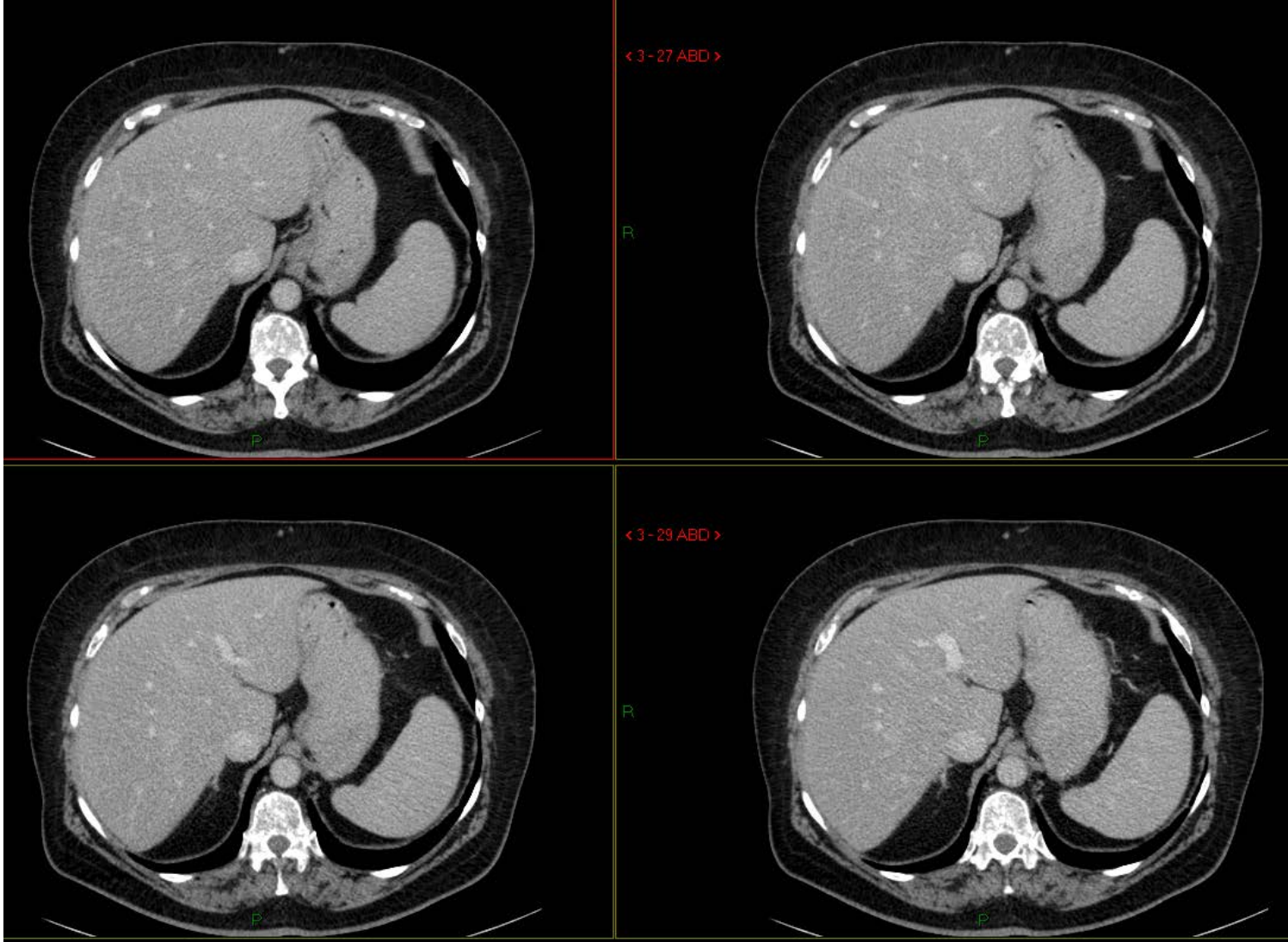
Incidences radiographiques de l'estomac

- Position debout : air dans le fundus et niveau hydro-aérique
- Procubitus : air dans le fundus
- Décubitus : air dans l'antre
- Morphologie variable en fonction de la corpulence



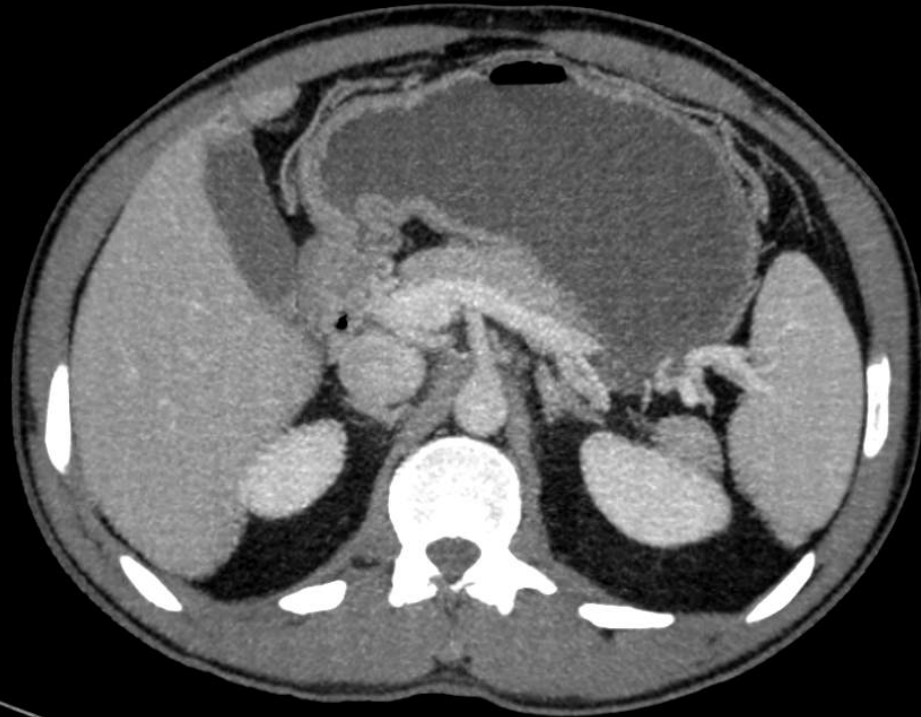
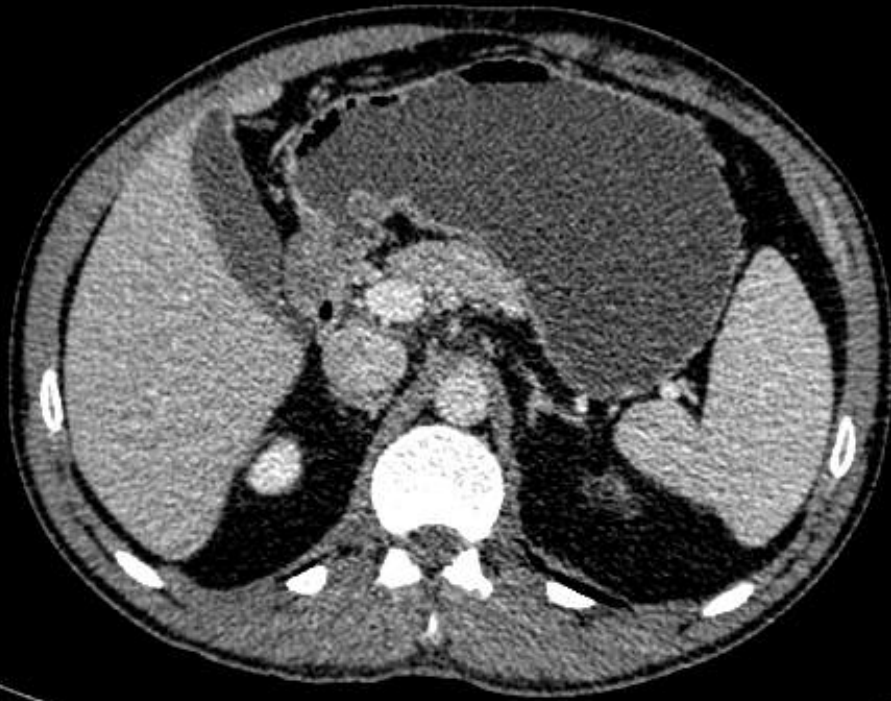





Grosse tubéros: épaisseur de sa paroi

- < 10 mm : sensibilité : 100 %, spécificité : 42 %
- < 20 mm: sensibilité : 50 %, spécificité : 88 %



corps gastrique < 5 mm

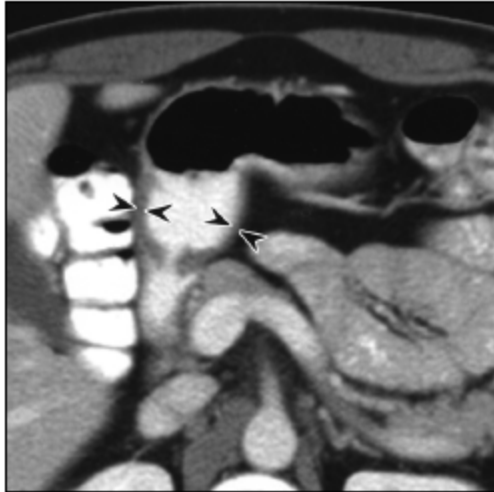


Fig. 1.—Contrast-enhanced axial multidetector CT (MDCT) image in 36-year-old man without gastric disease shows mild to moderate uniform concentric wall thickening involving well-distended gastric antrum (*arrowheads*). Pylorus and duodenal bulb are well depicted on this image. This appearance of gastric antrum was most common on MDCT.

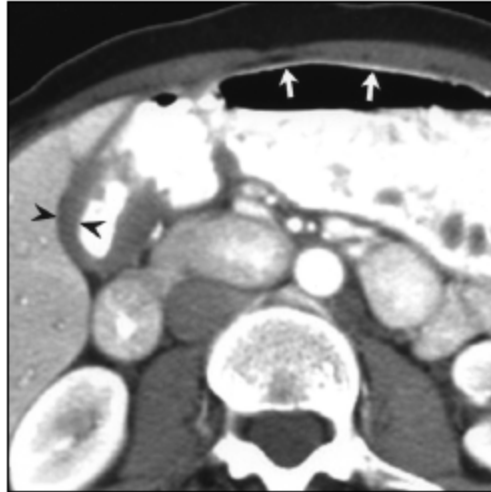

Fig. 2.—Contrast-enhanced axial multidetector CT image in 45-year-old woman without gastric disease shows prominent short-segment circumferential wall thickening (*arrowheads*) of distal gastric antrum. Note thin-walled gastric body (*arrows*).

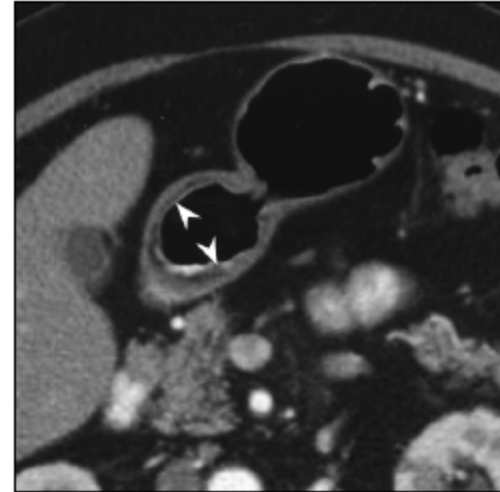


Fig. 3.—Contrast-enhanced axial multidetector CT image in 65-year-old man without gastric disease shows moderate antral wall thickening (*arrowheads*) relative to gastric body. Note linear submucosal fat attenuation in area of antral thickening.

antre < 12 mm

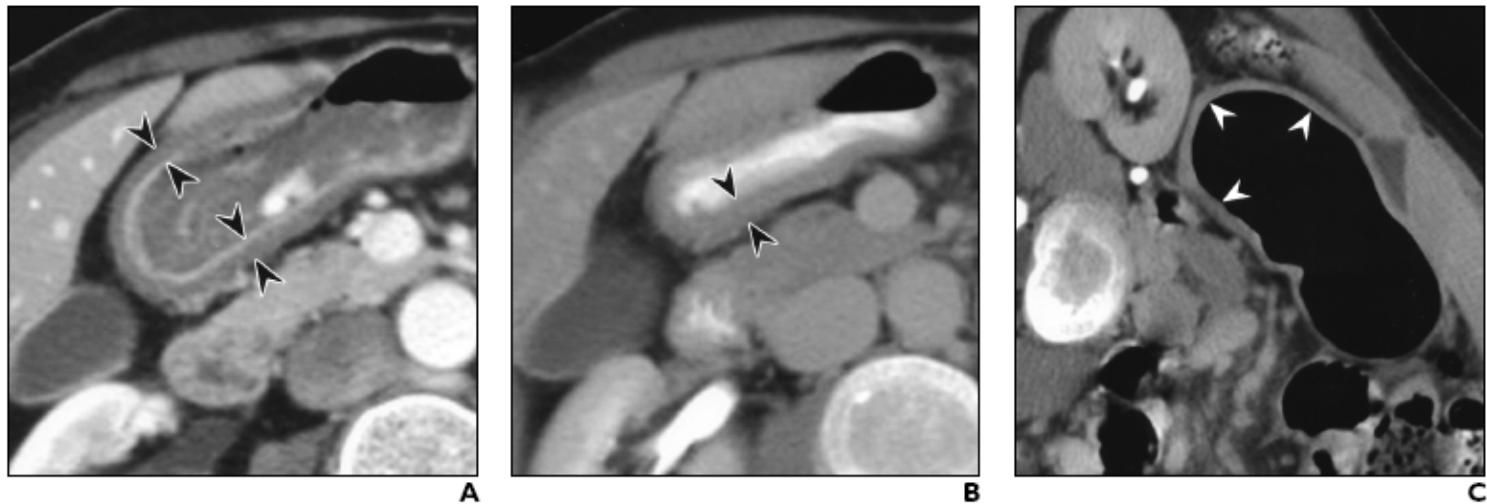
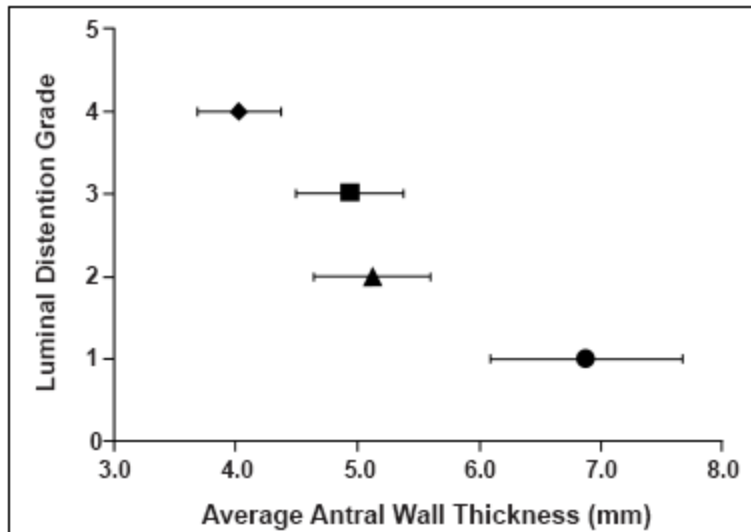


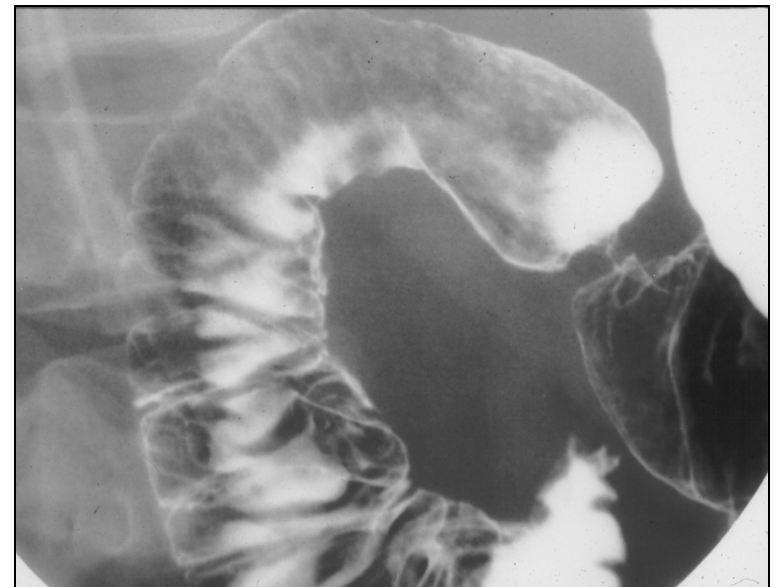
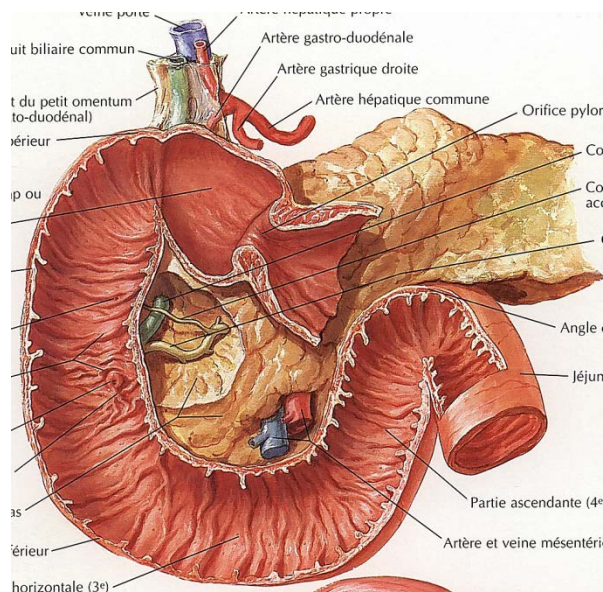
Fig. 6.—Images show effect of degree of luminal distention on appearance of concentric long-segment antral thickening in 62-year-old woman without gastric disease. **A**, Contrast-enhanced axial multidetector CT (MDCT) image during dynamic phase shows concentric antral thickening (*arrowheads*) with moderate luminal distention. Note conspicuity of bright mucosal enhancement using water as oral contrast material, which would be obscured by positive oral contrast material. **B**, Contrast-enhanced axial MDCT image during delayed phase shows decreased luminal distention and further increase in antral thickening (*arrowheads*). **C**, Delayed axial MDCT image with optimal distention and patient in decubitus position after ingesting effervescent crystals shows decreased but persistent antral wall thickening (*arrowheads*).

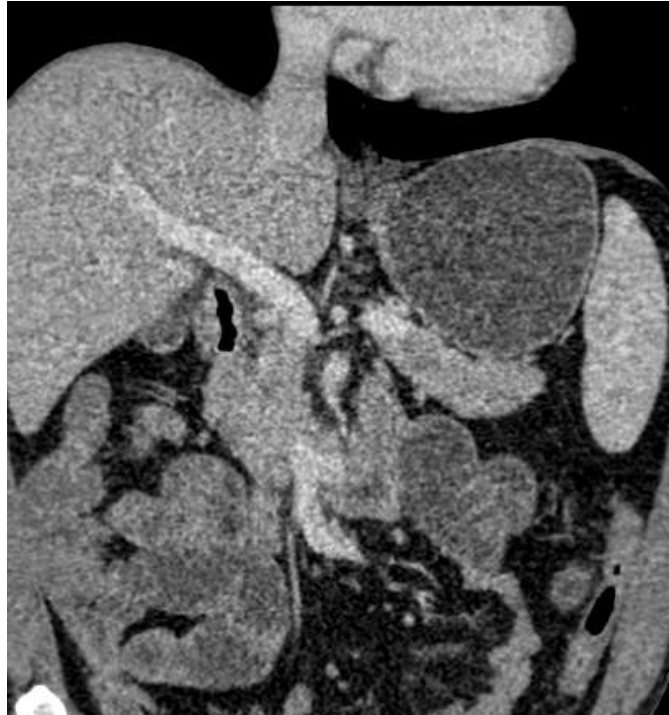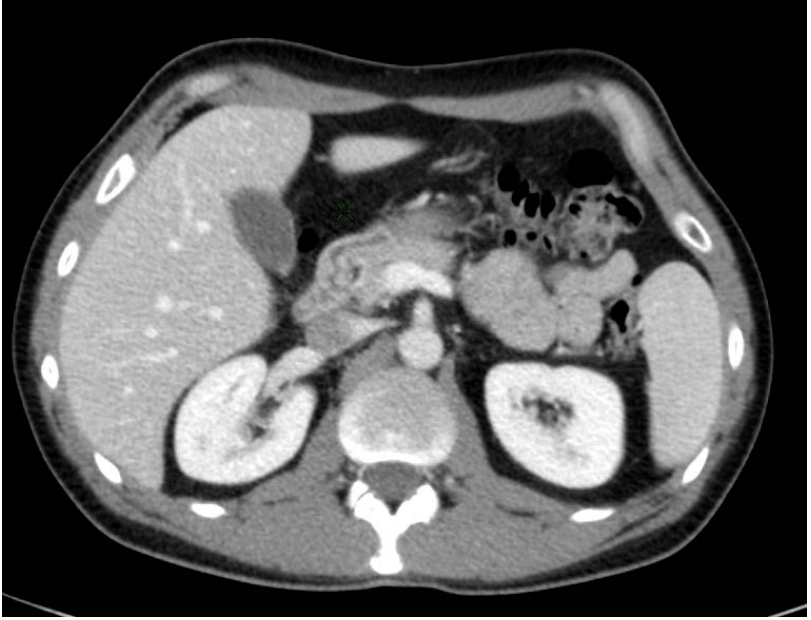

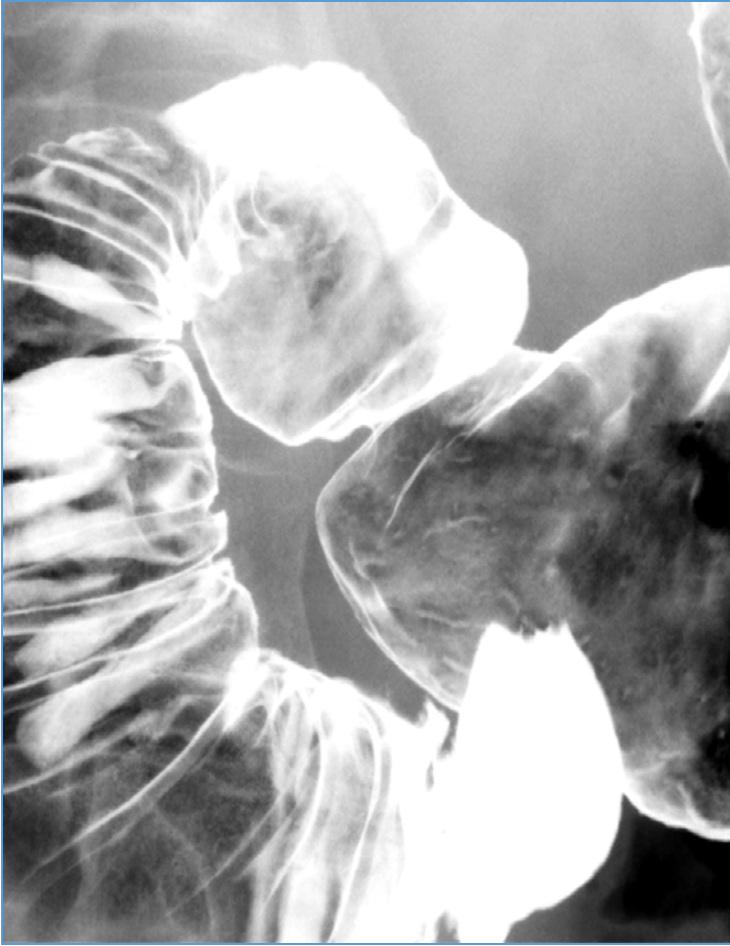
Pickhardt & Asher, *AJR*,
2003, 181, 973-979

Duodénum

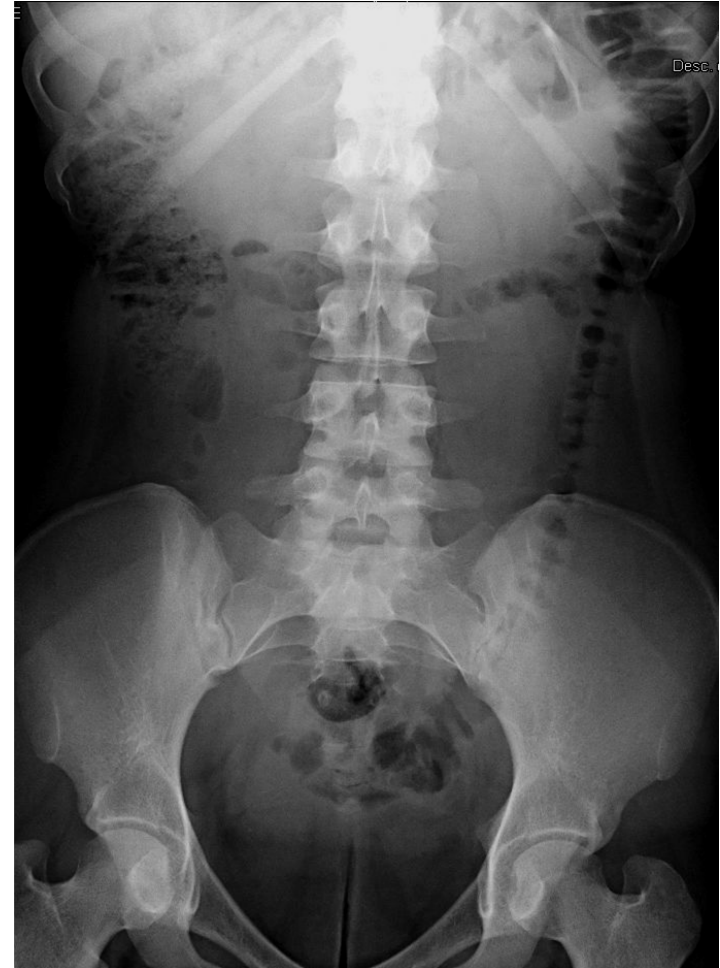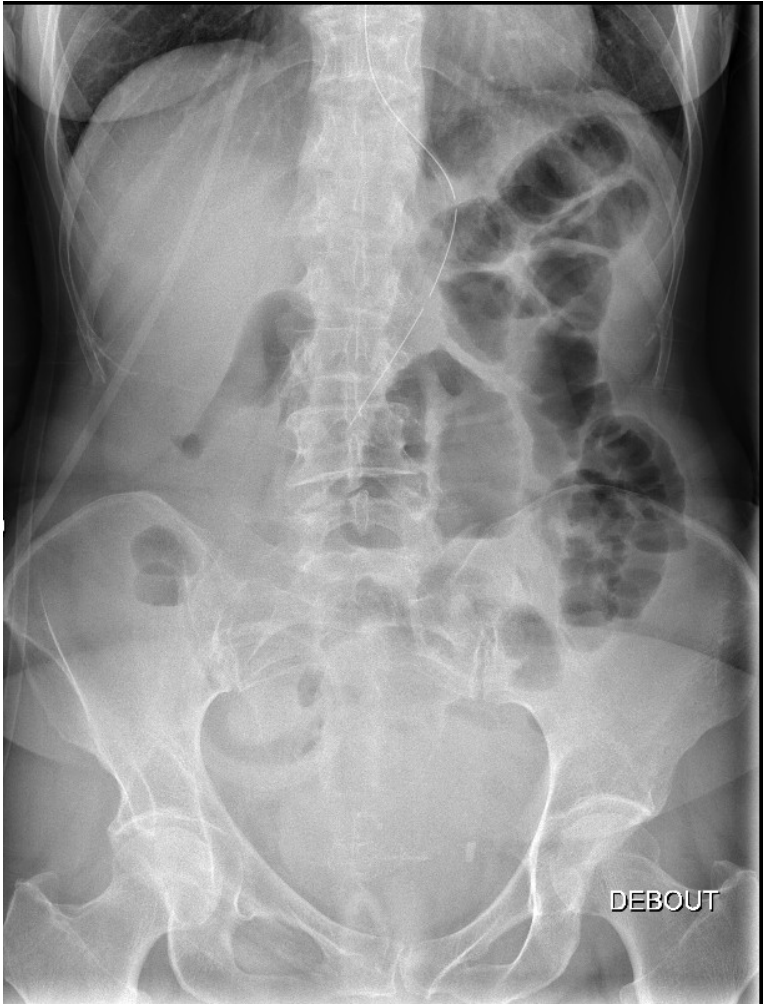
- Entoure la tête du pancréas
- Bord interne du tiers de moyen de D2
 - Papille majeure : cholédoque et conduit pancréatique principal
 - Papille mineure : conduit pancréatique accessoire

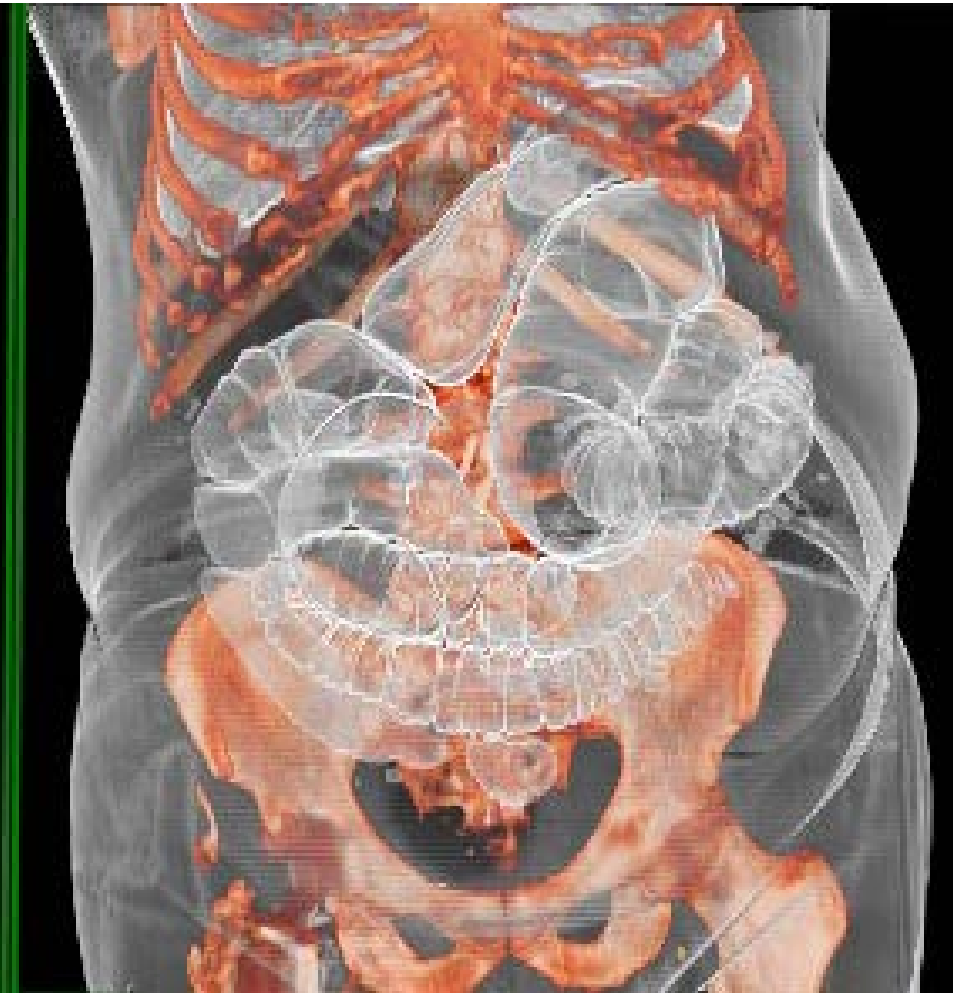
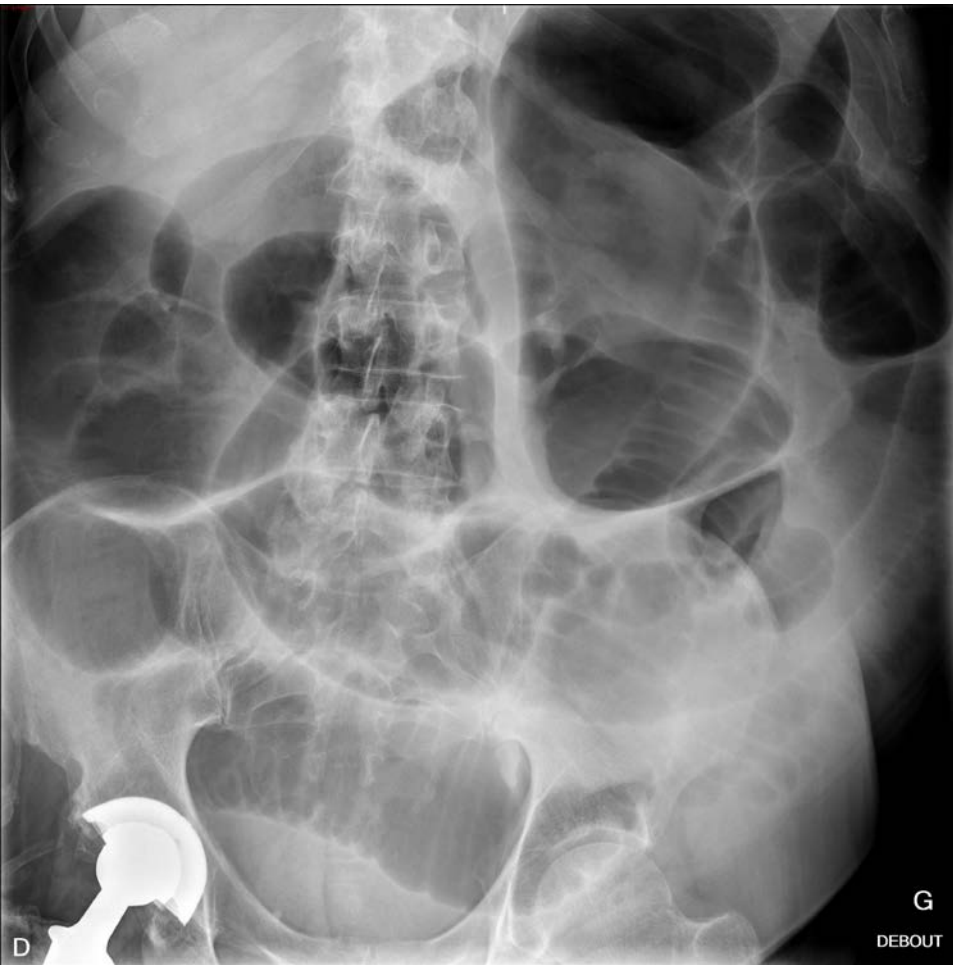


Intestin grêle et colon

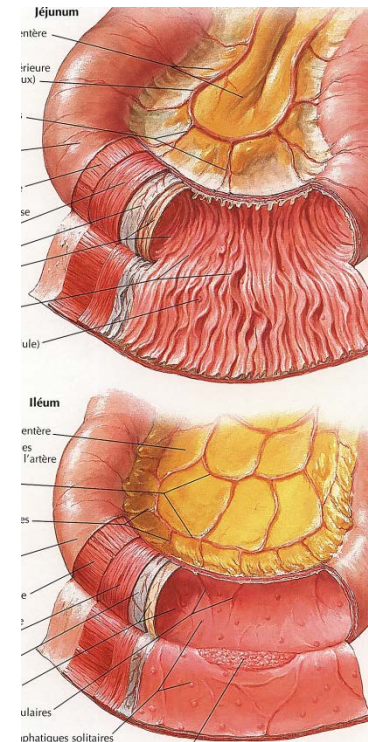
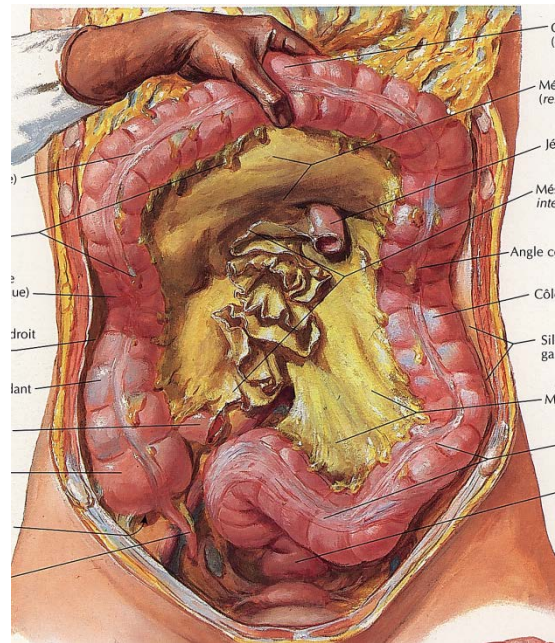
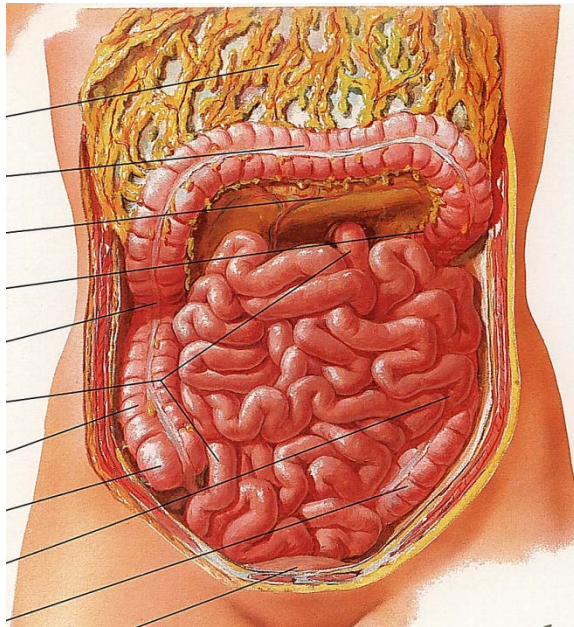
- RX, US, CT , IRM





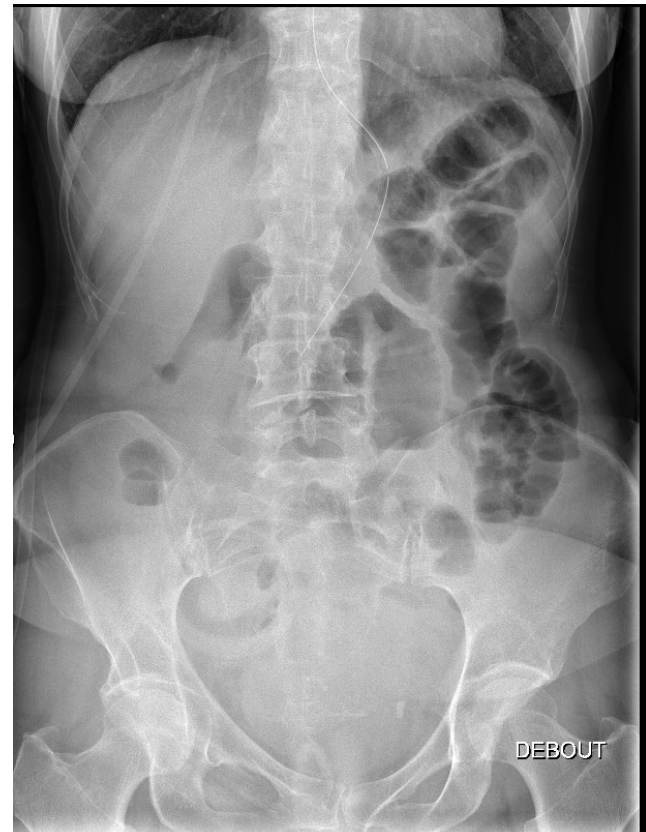
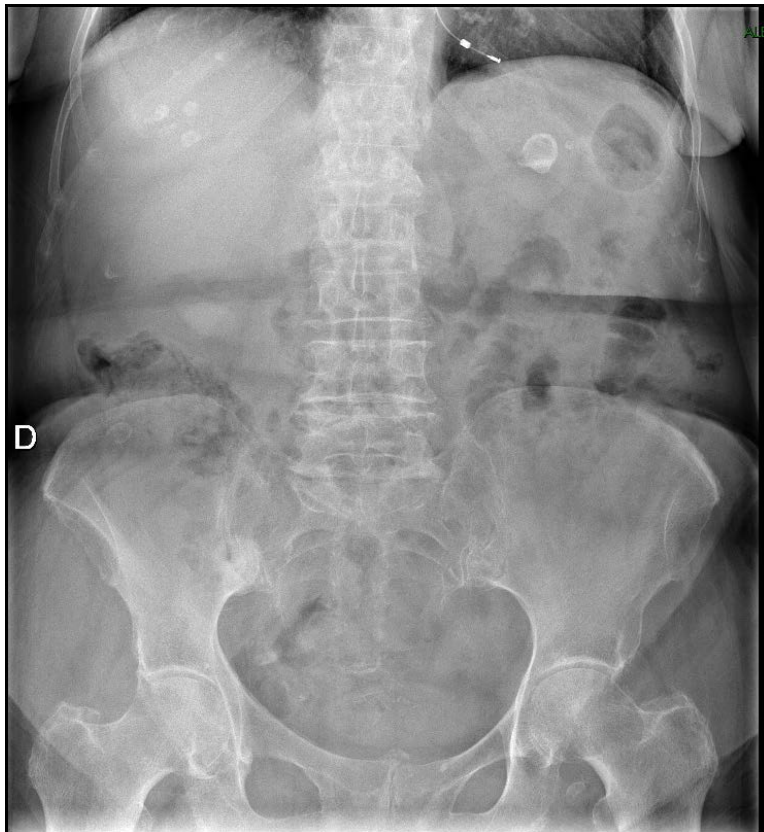
Jéjuno-iléon

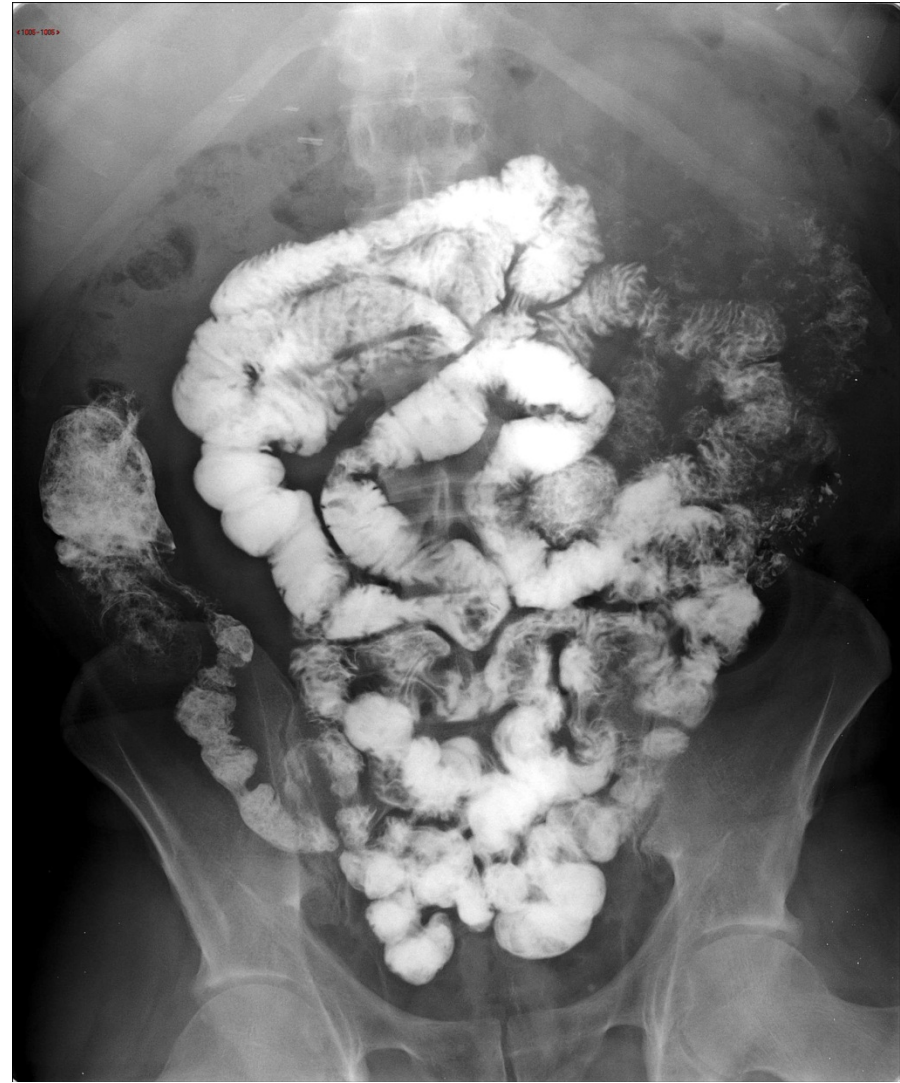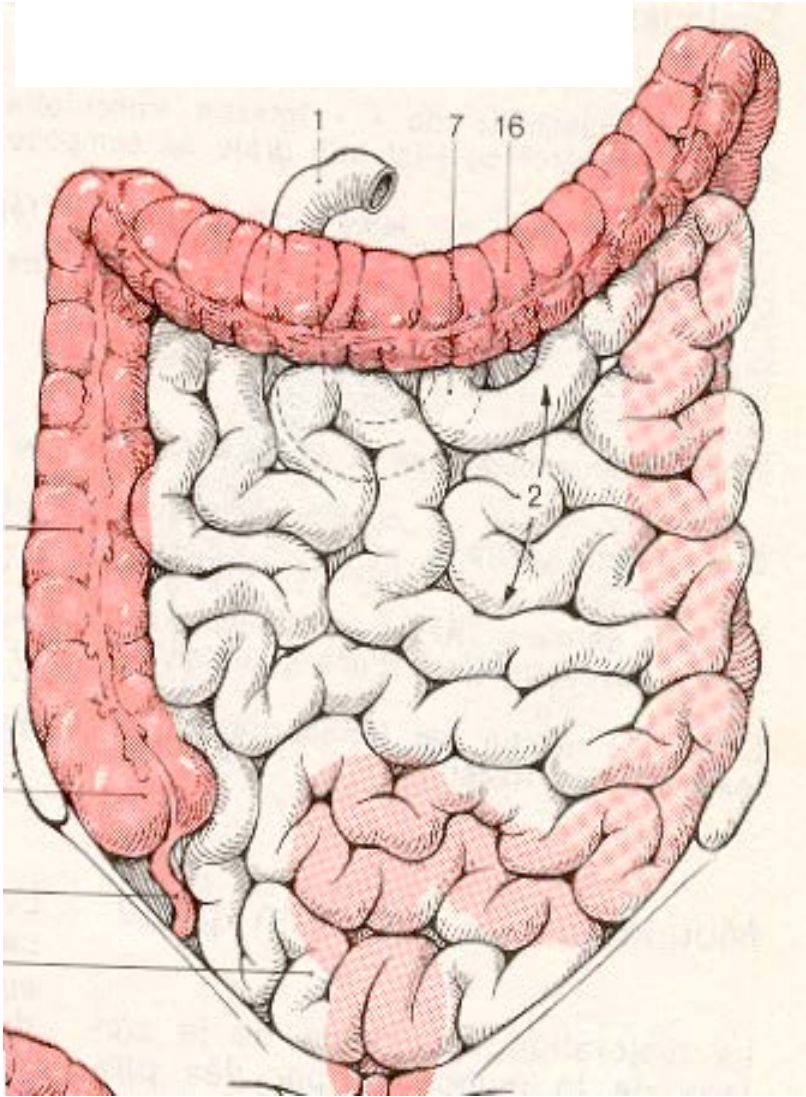
- Mésentère a un bord pariétal court suivant une ligne oblique en bas et à droite, allant de la face gauche de L2 à la fosse iliaque droite
- Jéjunum : essentiellement dans l'hypocondre et le flanc gauches
- Iléon : essentiellement dans le flanc droit
- Valvules conniventes : beaucoup plus nombreuses sur le jéjunum



Intestin grêle

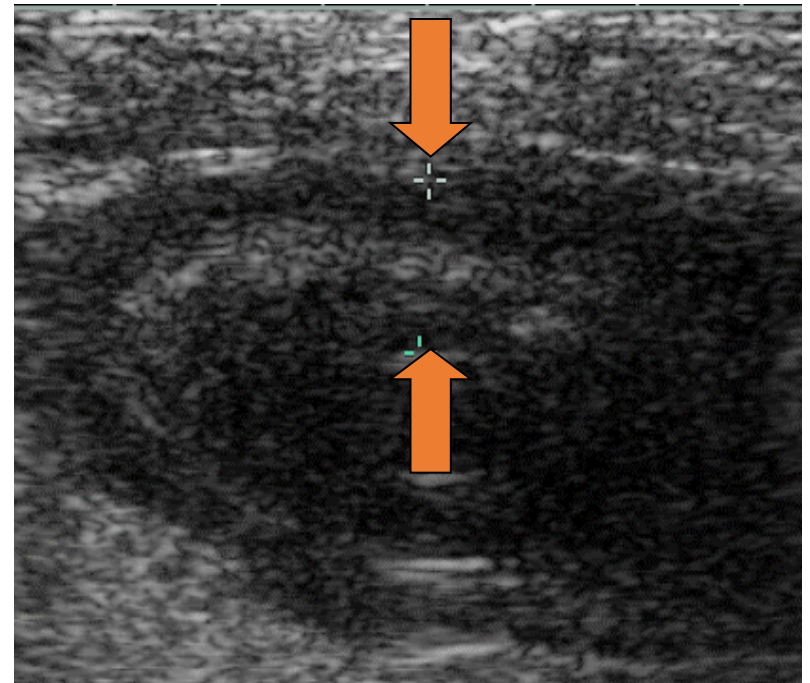
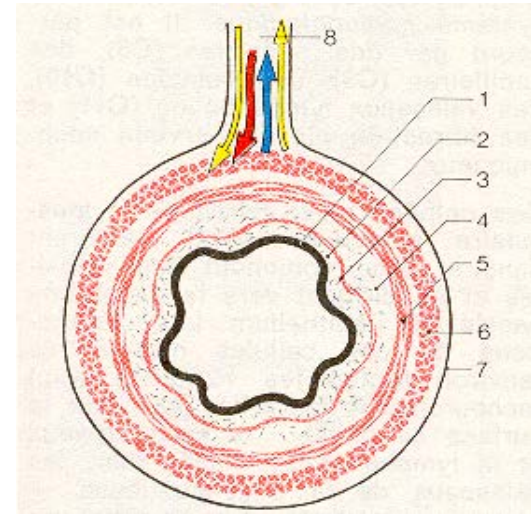
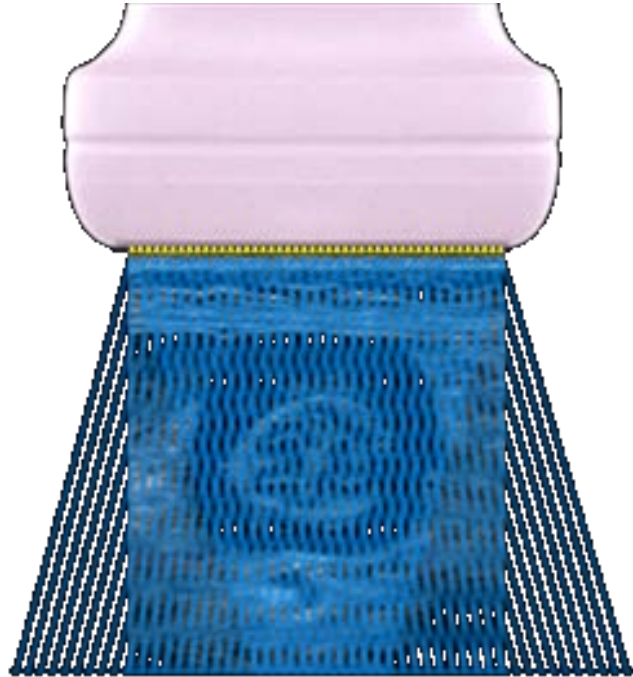
- RX, US, CT , IRM

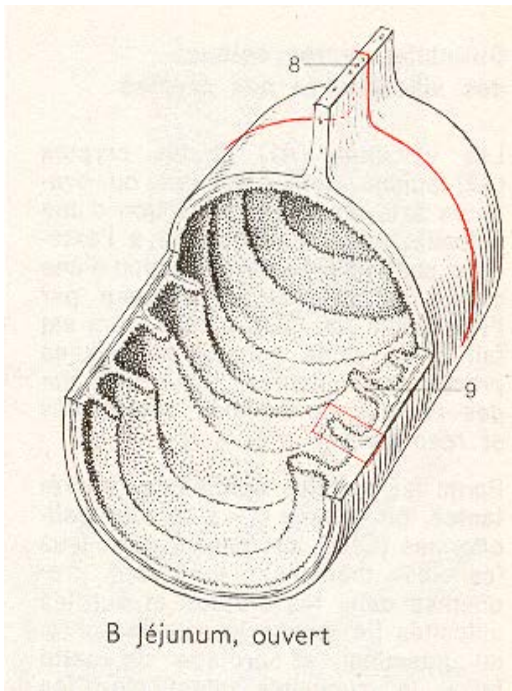




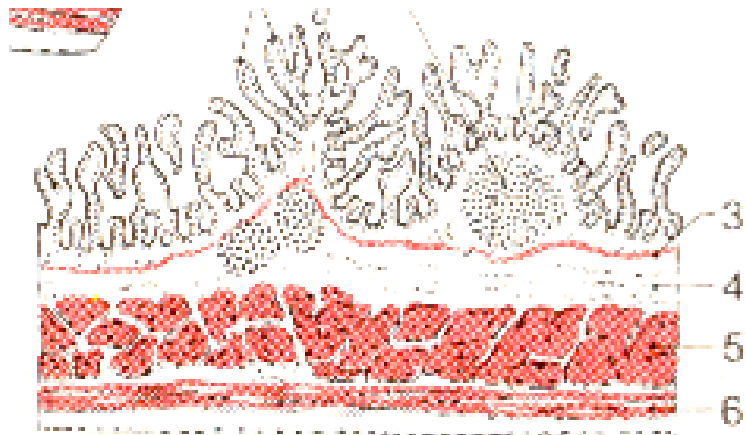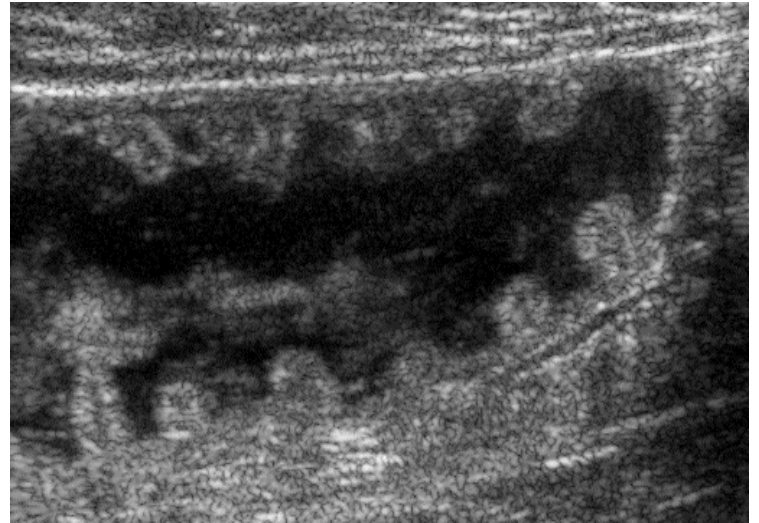
In Kahle W et al, Anatomie, tome 2,
Flammarion, Médecine-Sciences, 1979

In Kahle W et al, Anatomie, tome 2,
Flammarion, Médecine-Sciences, 1979

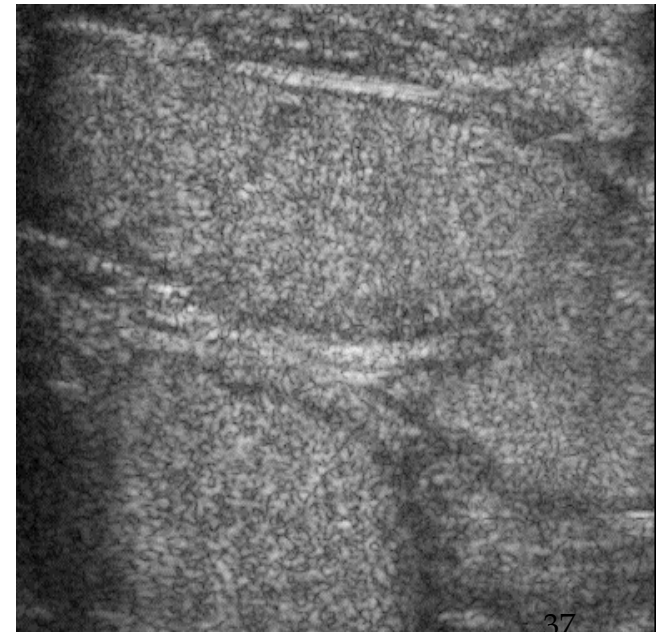

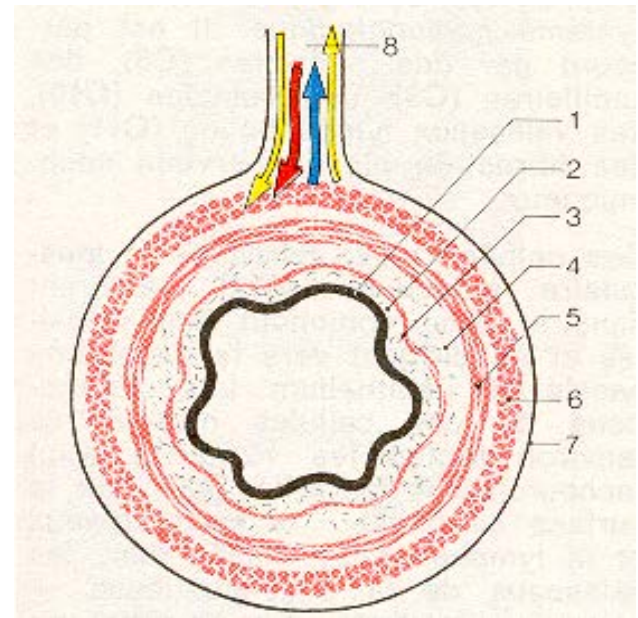

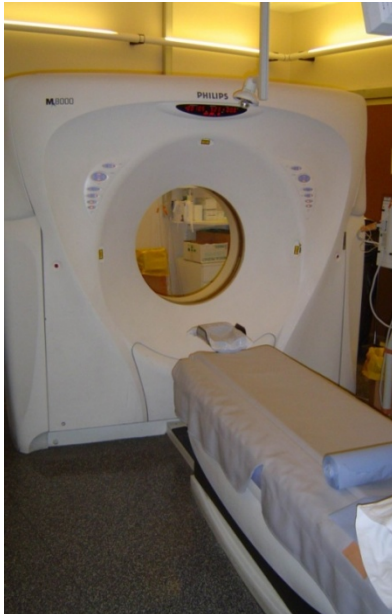
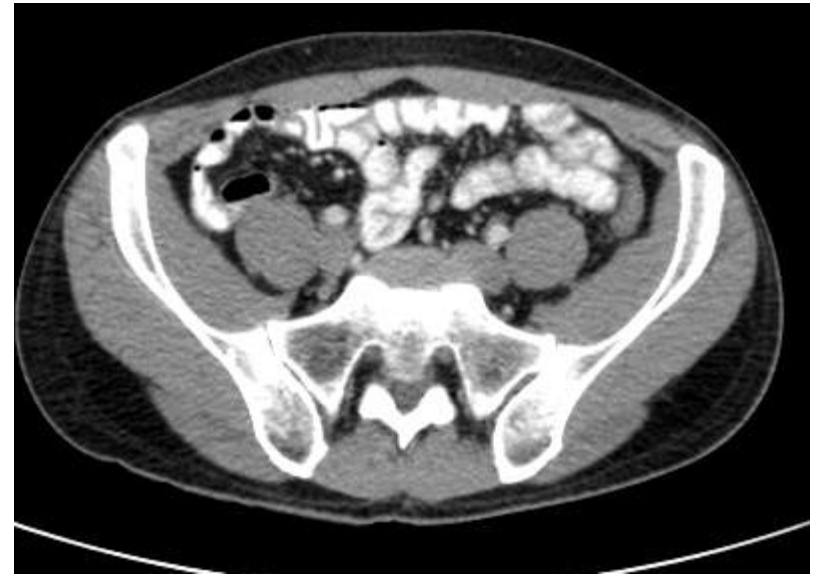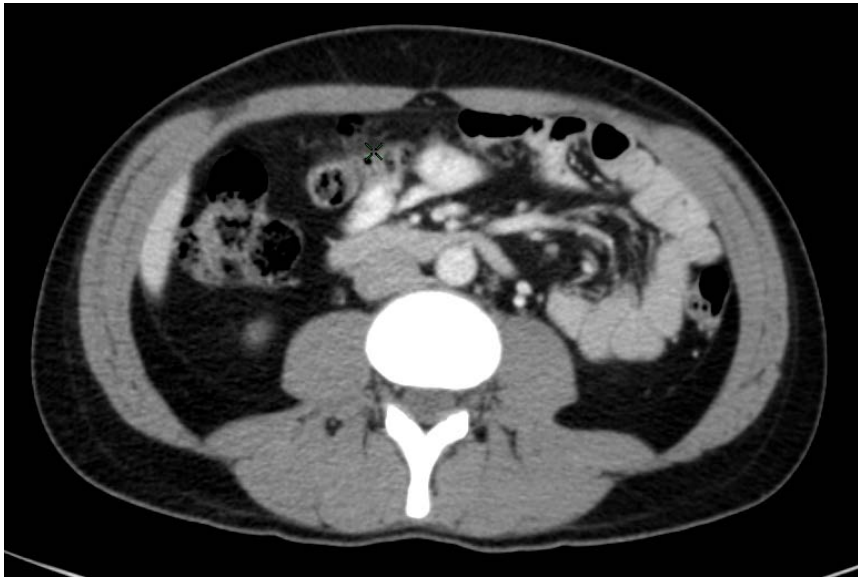Jejunum

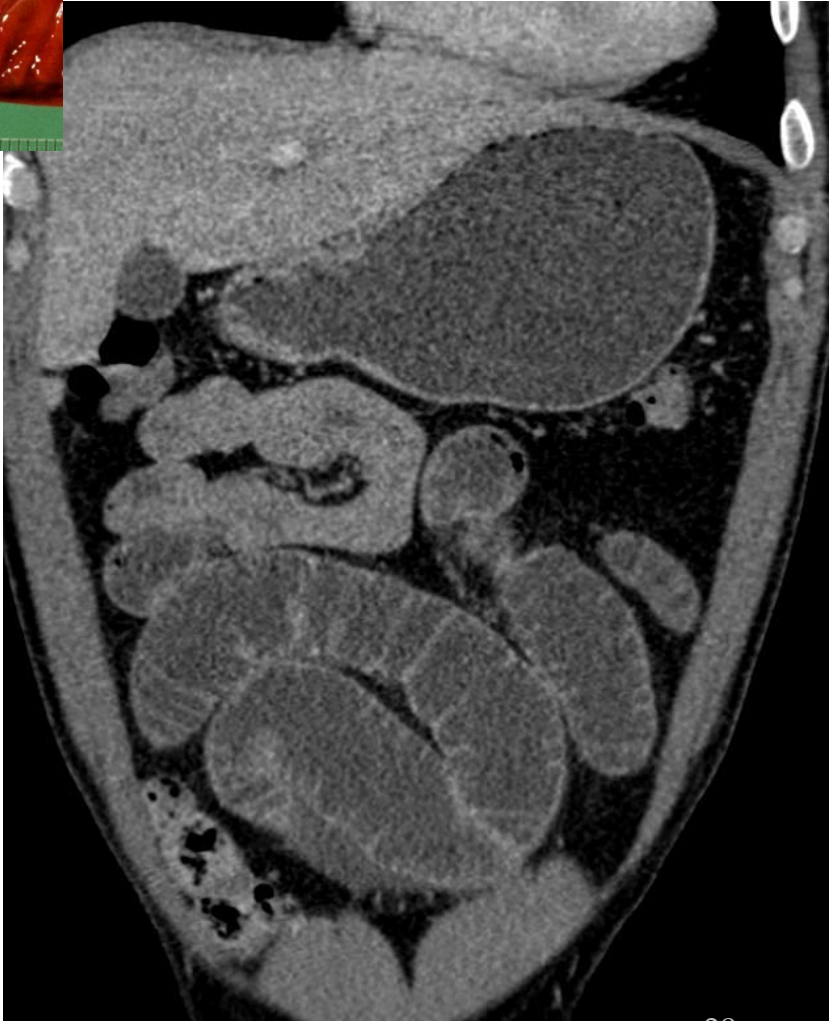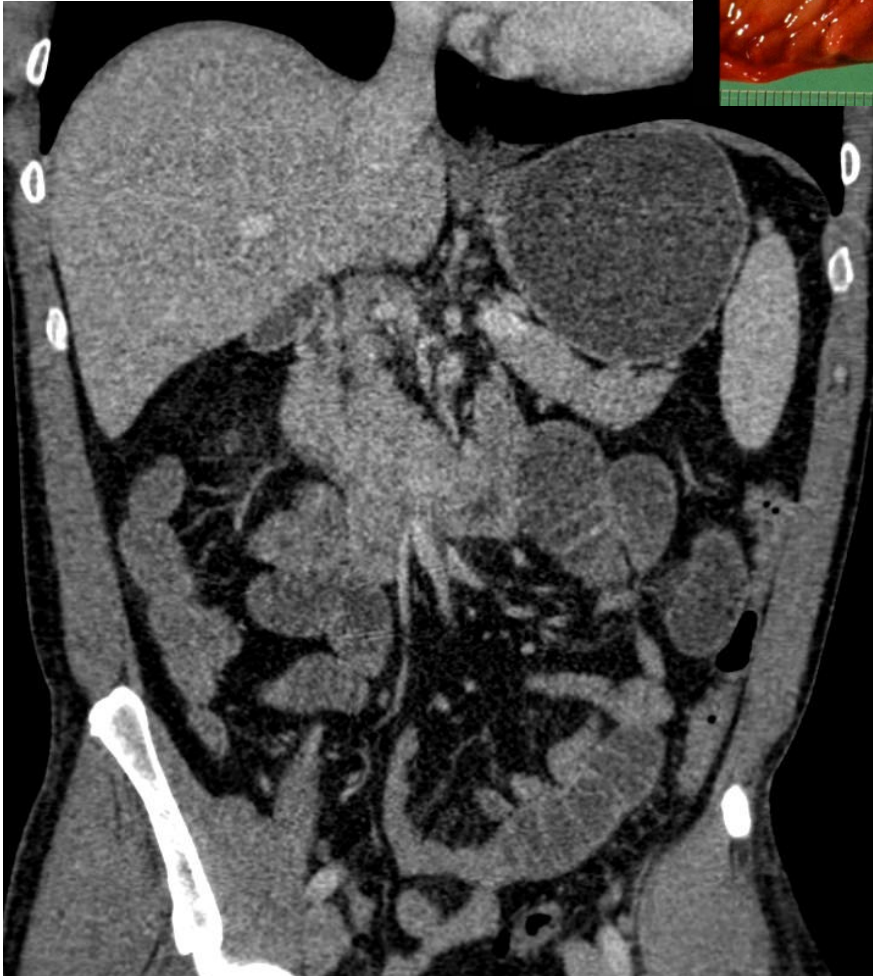

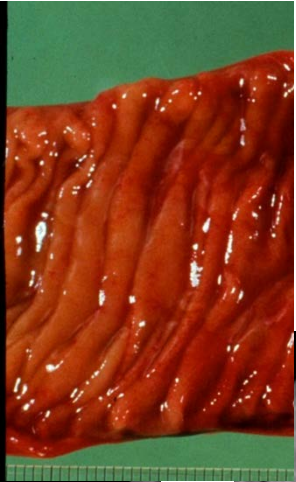
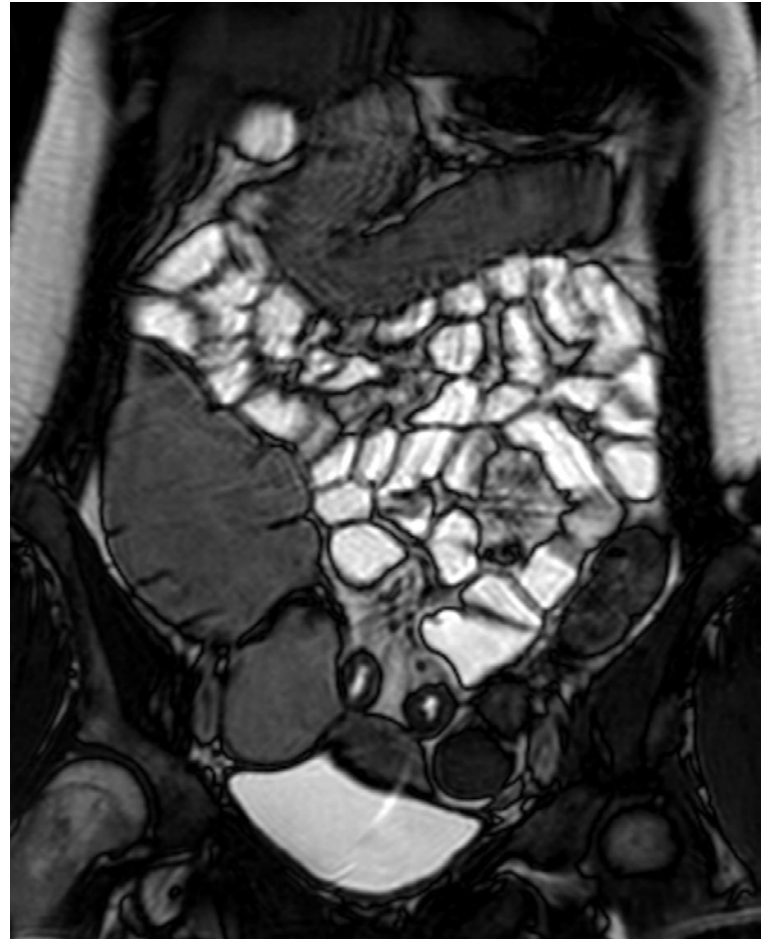
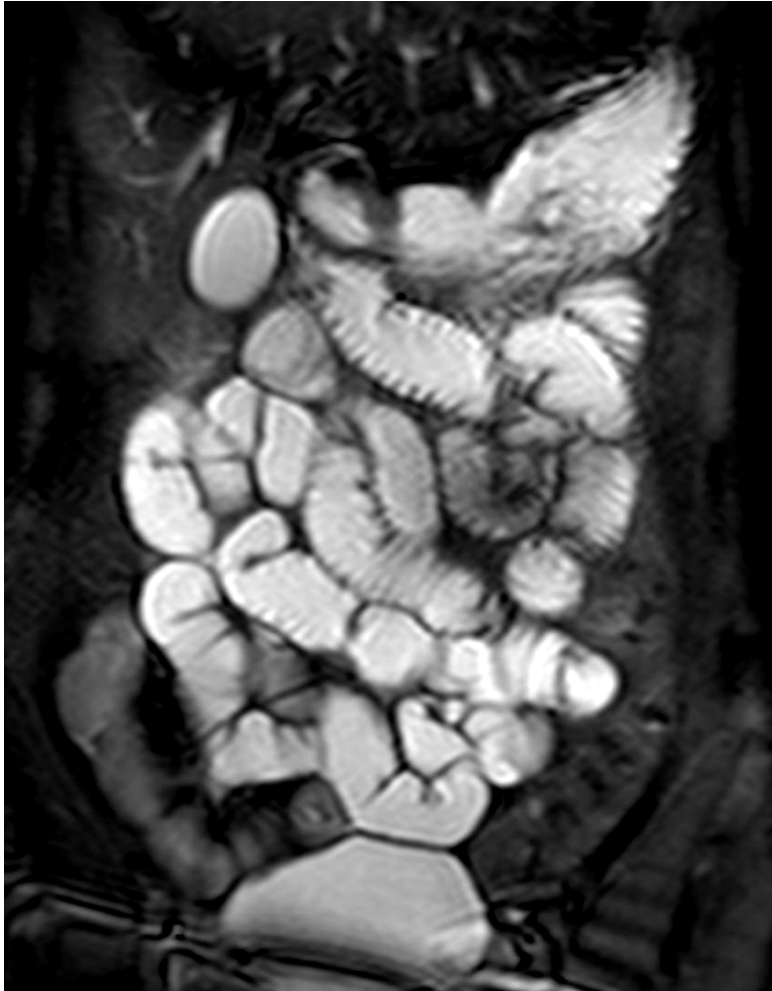Ileon

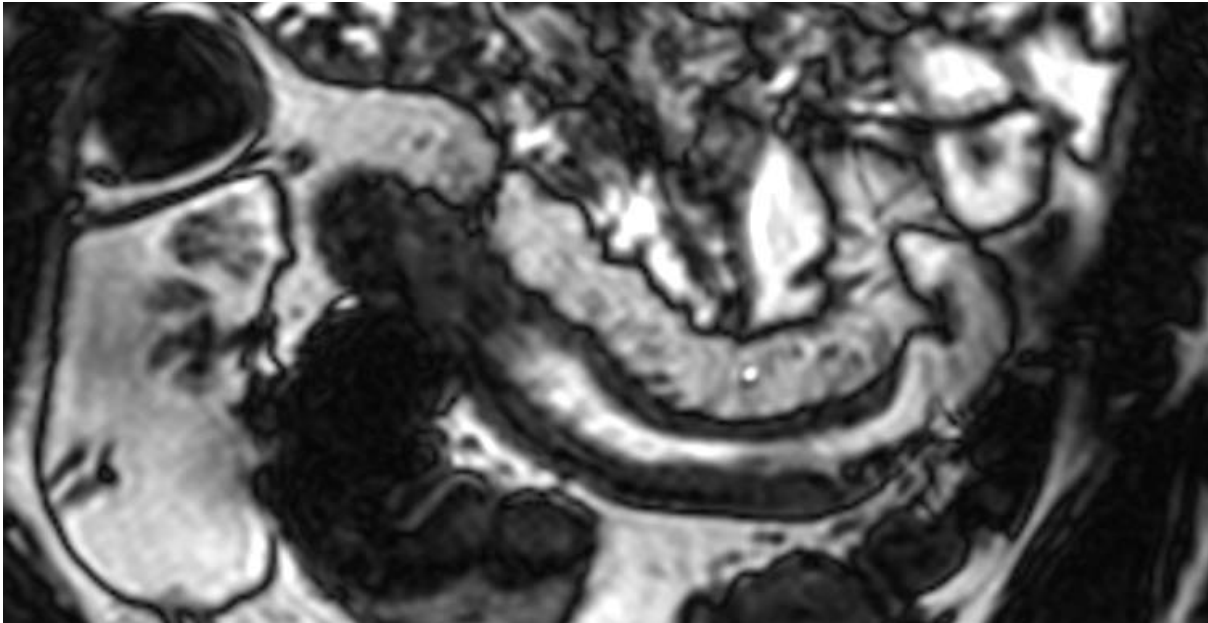




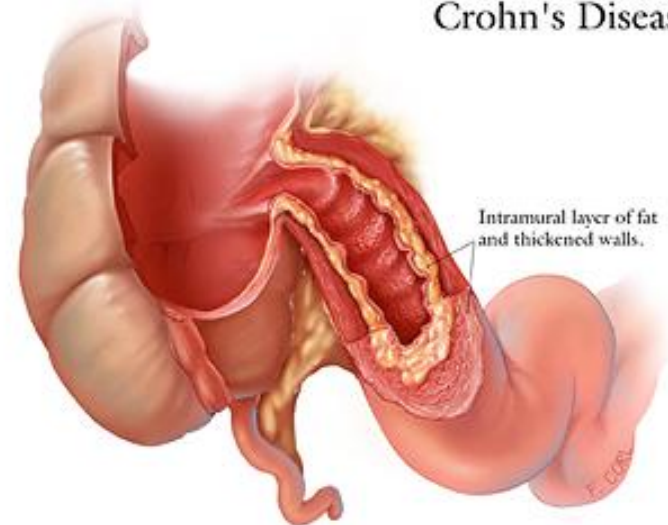
In Kahle W et al, Anatomie, tome 2, Flammarion, Médecine-Sciences, 1979







Crohn's Disease

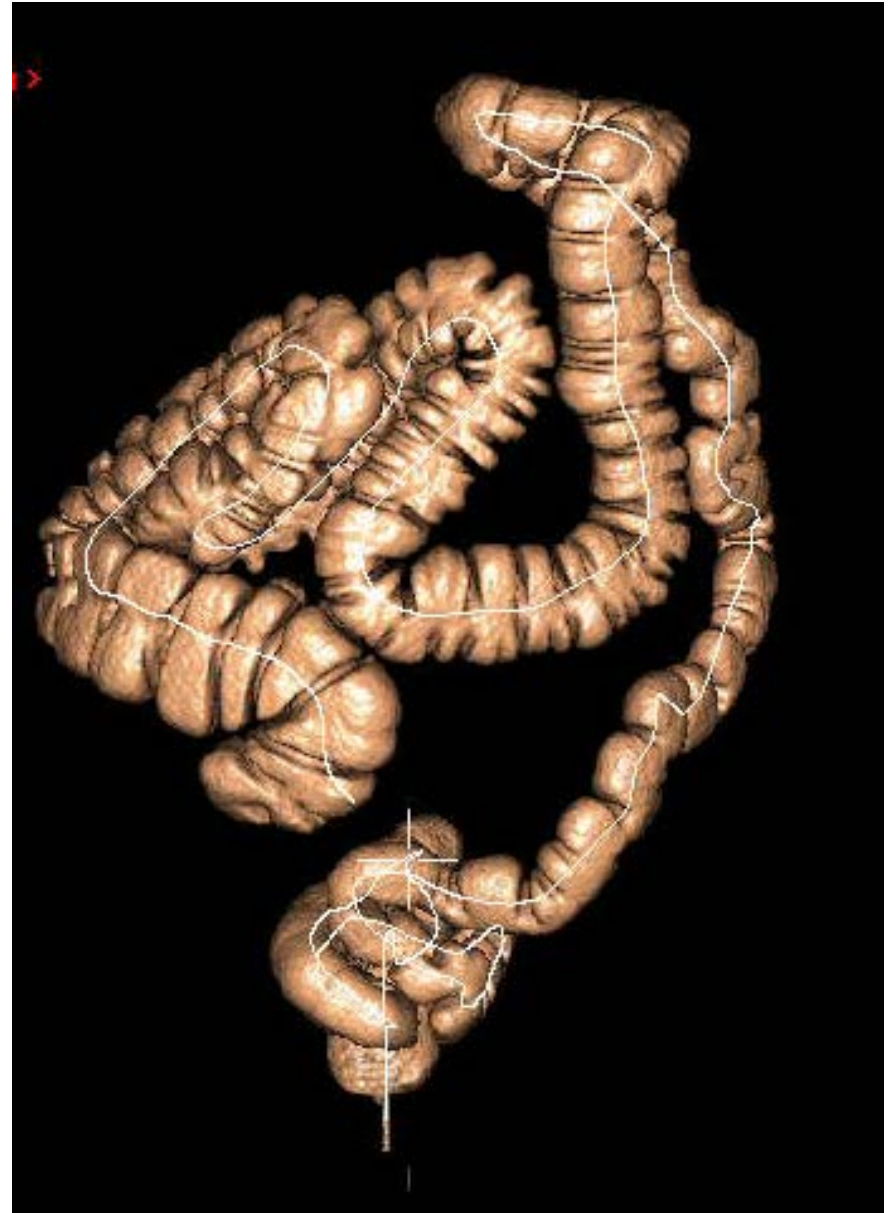


Colon (& rectum)

- Radiologie
 - Sans contraste
 - Par voie rétrograde
 - Par voie prograde
- Echographie
- Scanner
 - Colono CT
 - CT + Iode IV
- IRM

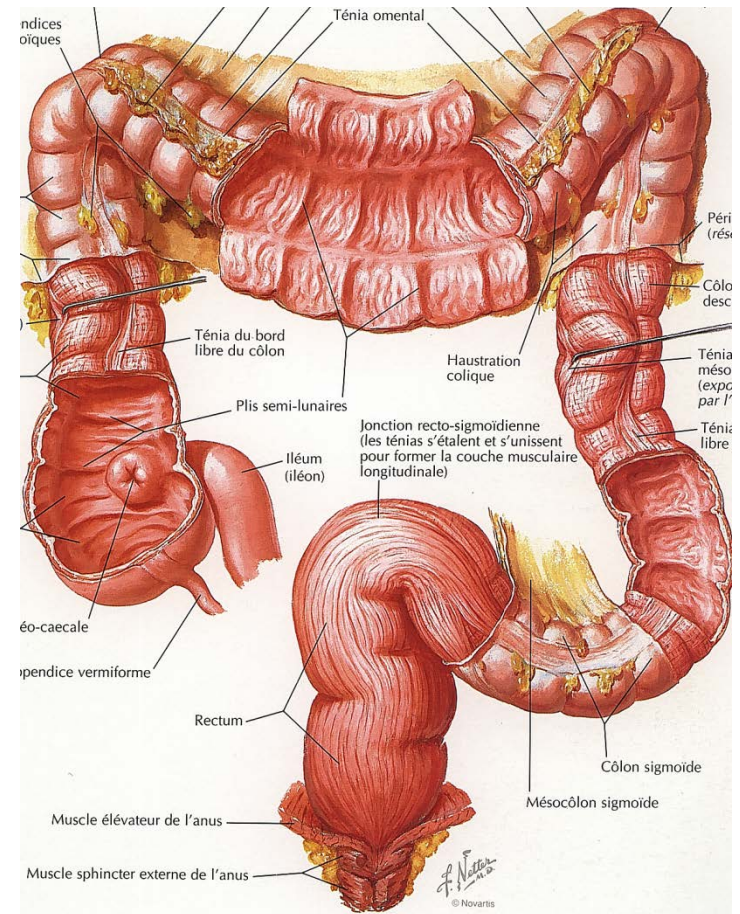
Gros intestin

- Caecum
- Appendice vermiforme
- Côlon ascendant
- Côlon transverse
- Côlon descendant
- Côlon sigmoïde
- Rectum

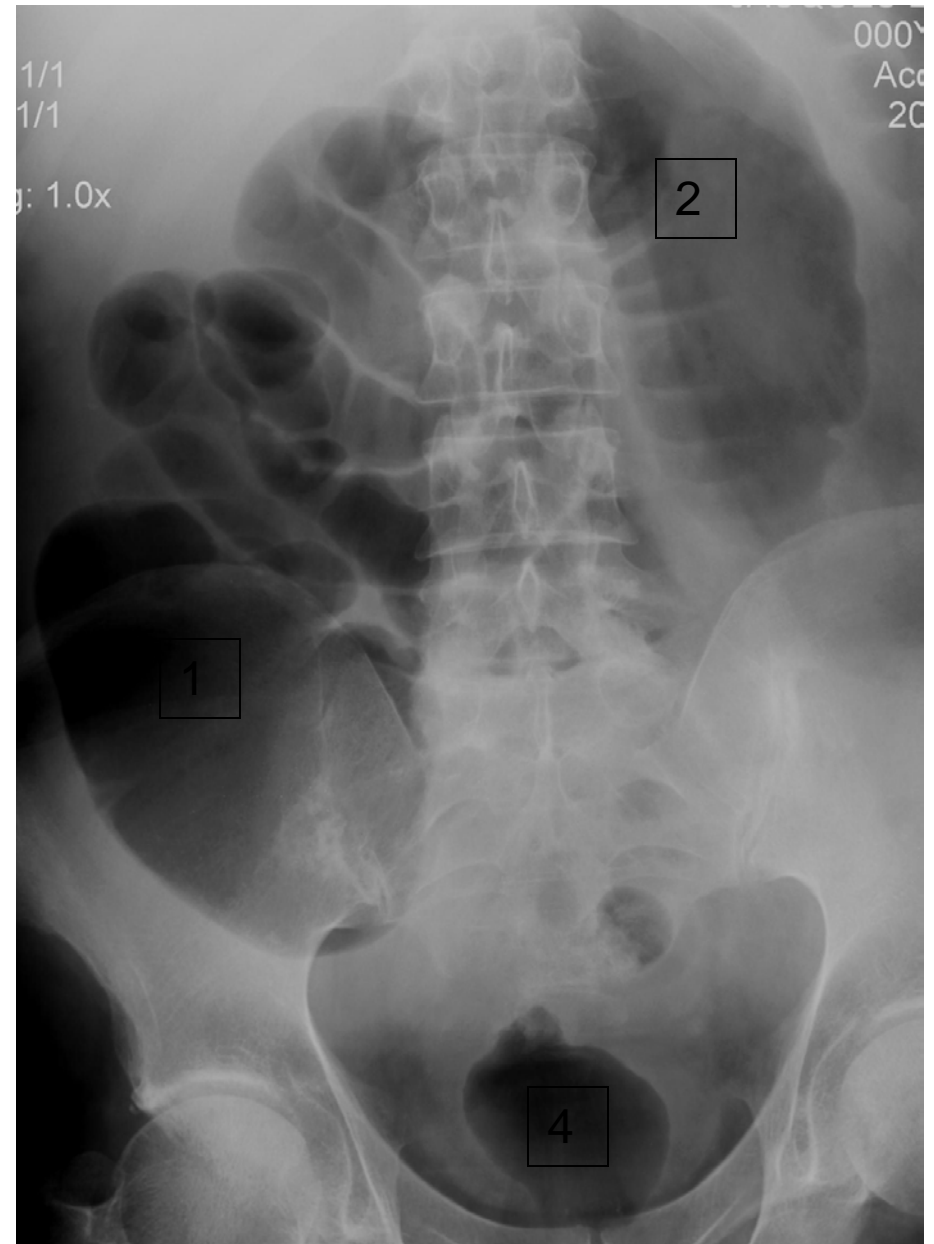
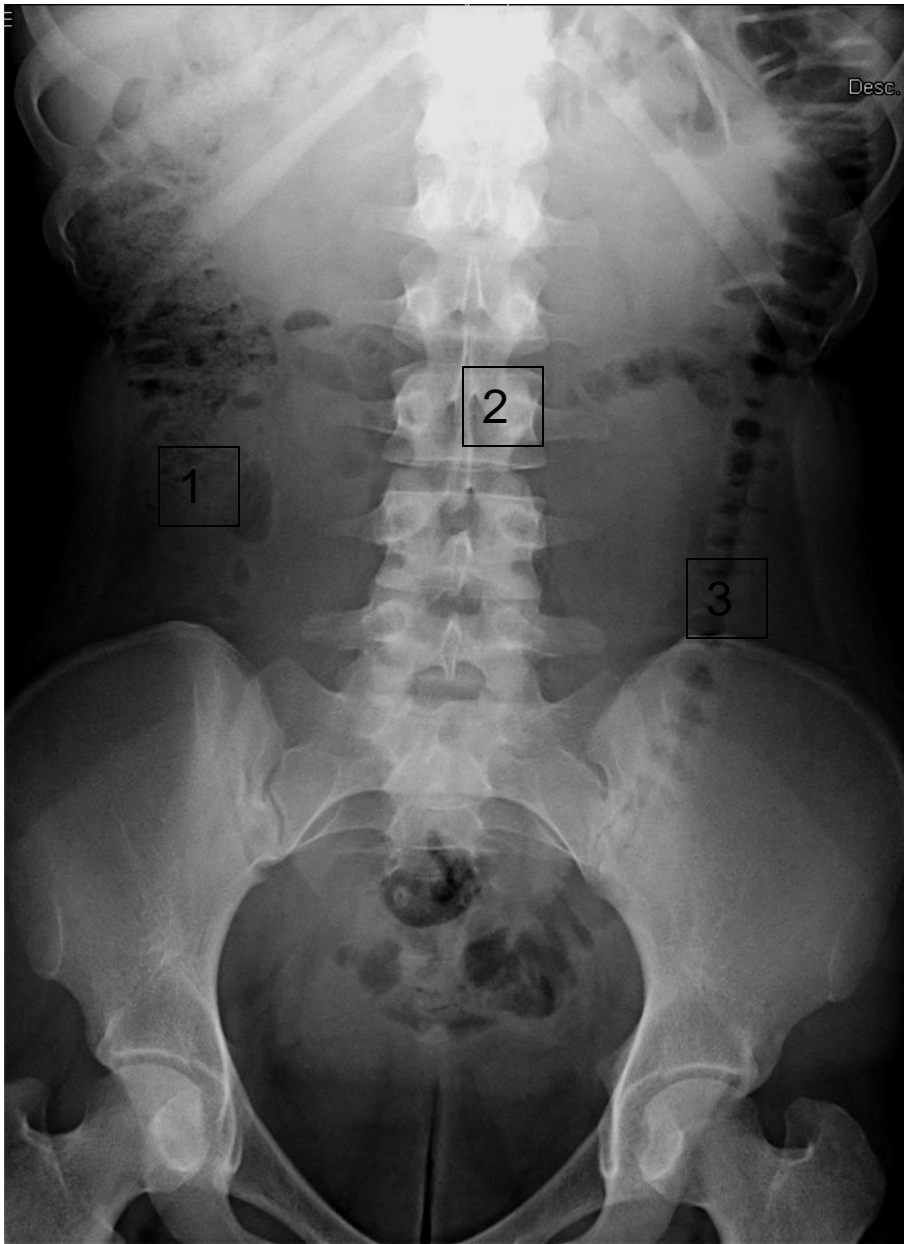


Muscle longitudinal du gros intestin

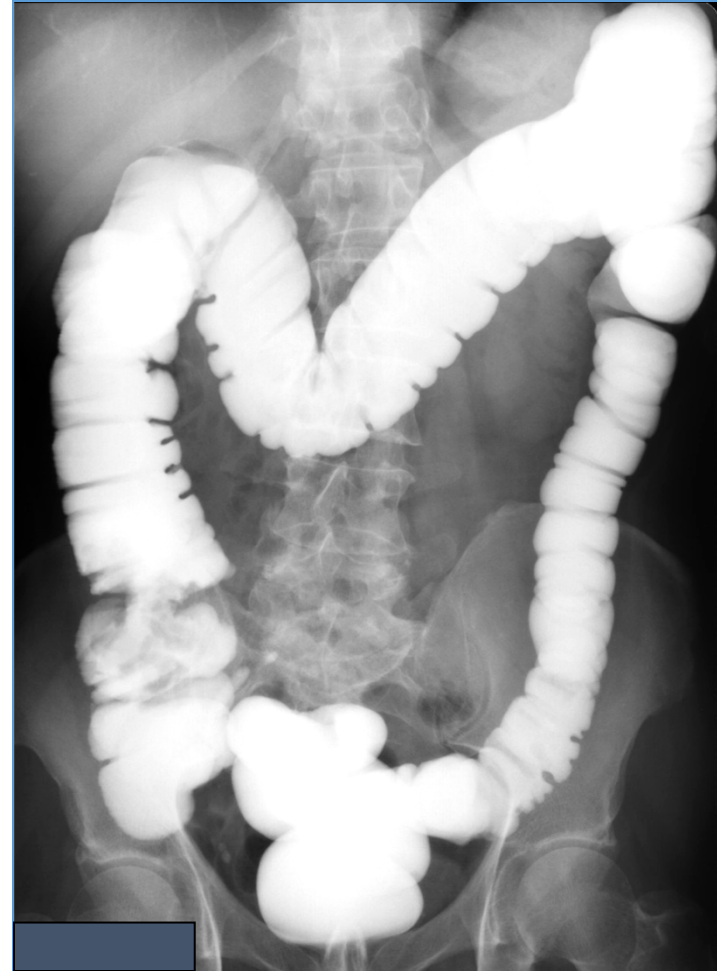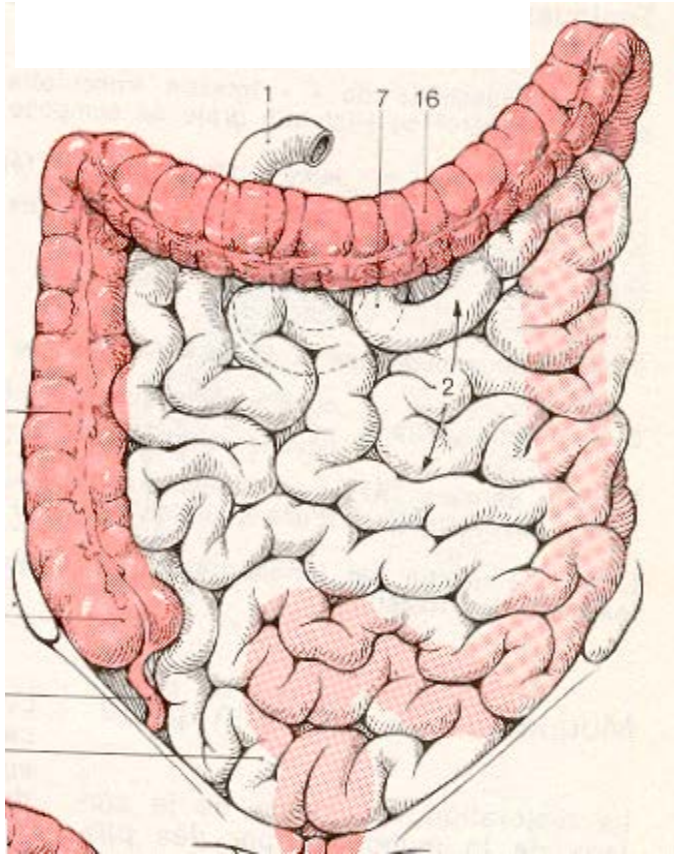
- Trois bandelettes longitudinales ou ténias
 - Ténia du bord libre
 - Ténia omental
 - Ténia mésocolique
- Deux bandelettes au niveau du côlon sigmoïde
- Muscle longitudinal continu au niveau du rectum



In Kahle W et al, Anatomie, tome 2,
Flammarion, Médecine-Sciences, 1979



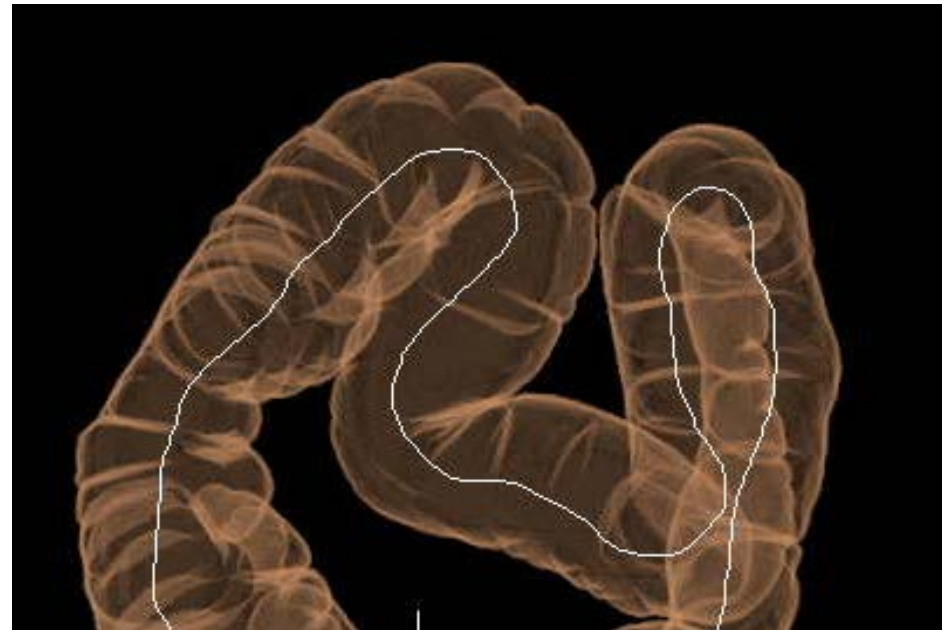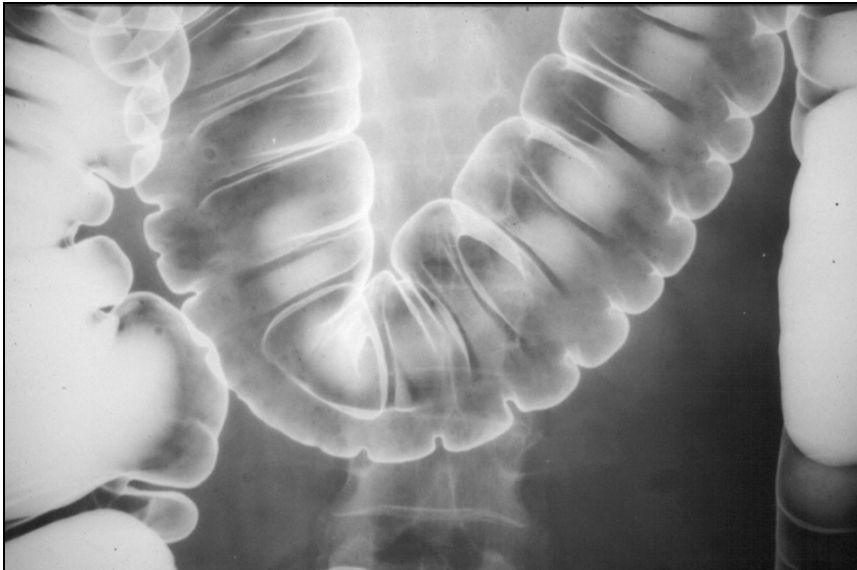1. Colon droit 2. Colon transverse 3. Colon gauche 4. Rectum



In Kahle W et al, Anatomie, tome 2,
Flammarion, Médecine-Sciences, 1979

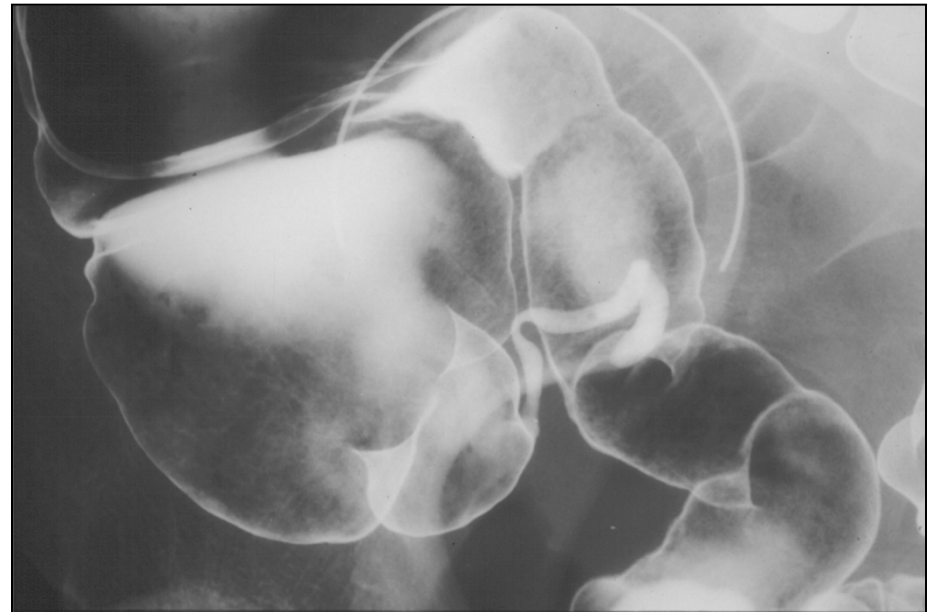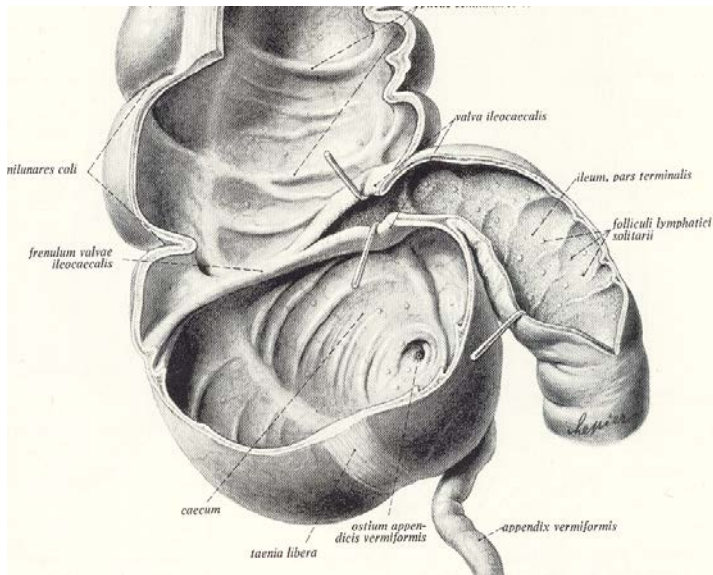
Gros intestin : aspect RX

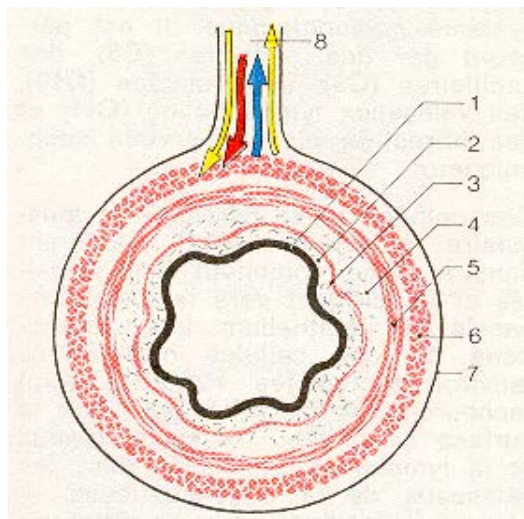
- Aspect bosselé
 - Sillons (plis) transversaux : sillons interhaustaux
 - Haustrations
- Franges graisseuses le long des ténias : appendices épiploïques



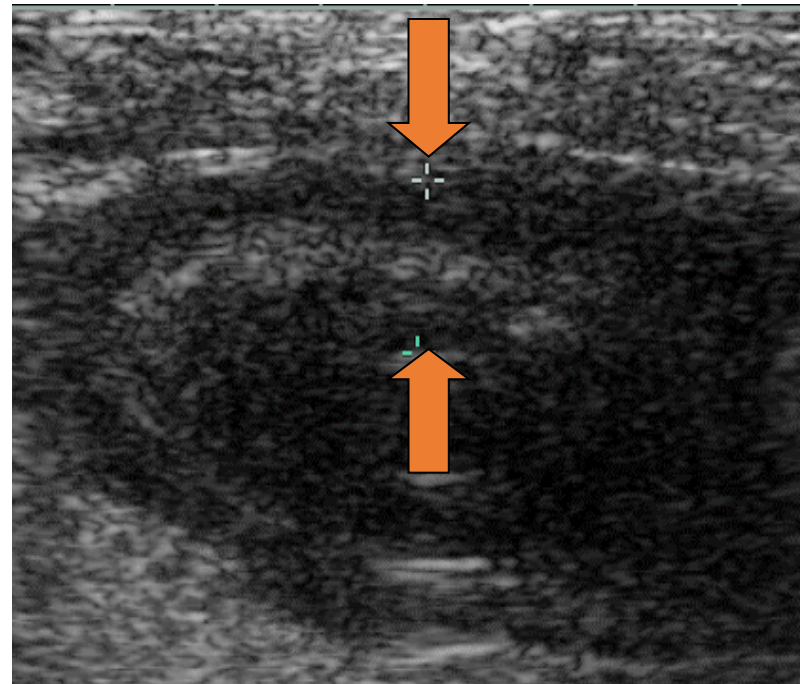
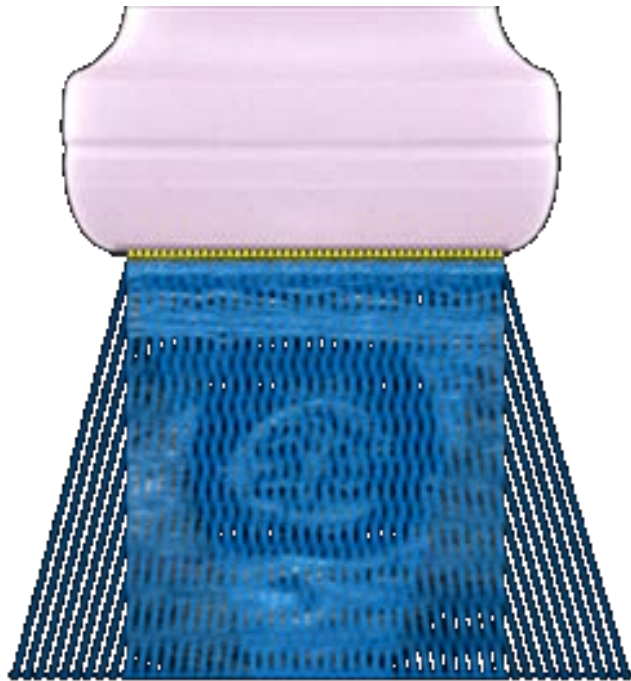
Caecum

- Entouré de péritoine sur toutes sa surface
- Limite supérieure : plan passant par la valvule iléocaecale ou valvule de Bauhin
- Valvule de Bauhin : fait protrusion dans la lumière du gros intestin



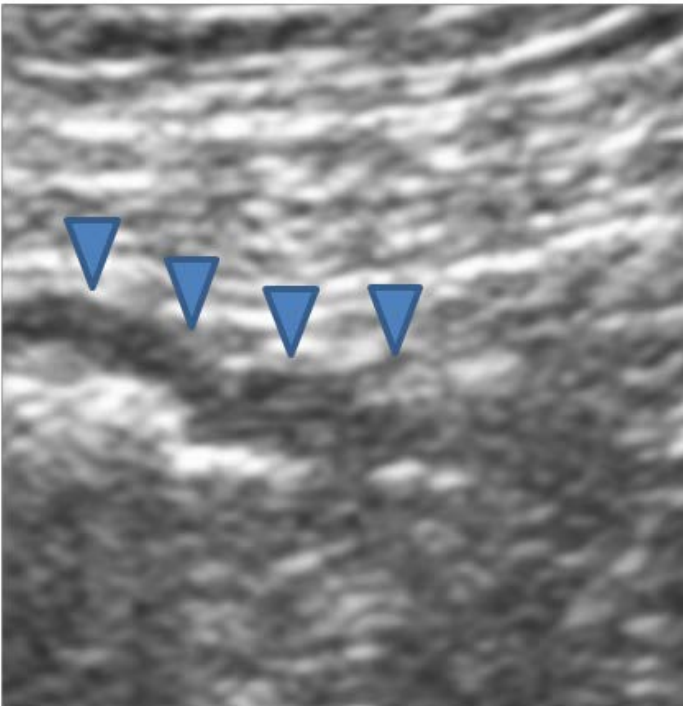


In Kahle W et al, Anatomie, tome 2, Flammarion, Médecine-Sciences, 1979

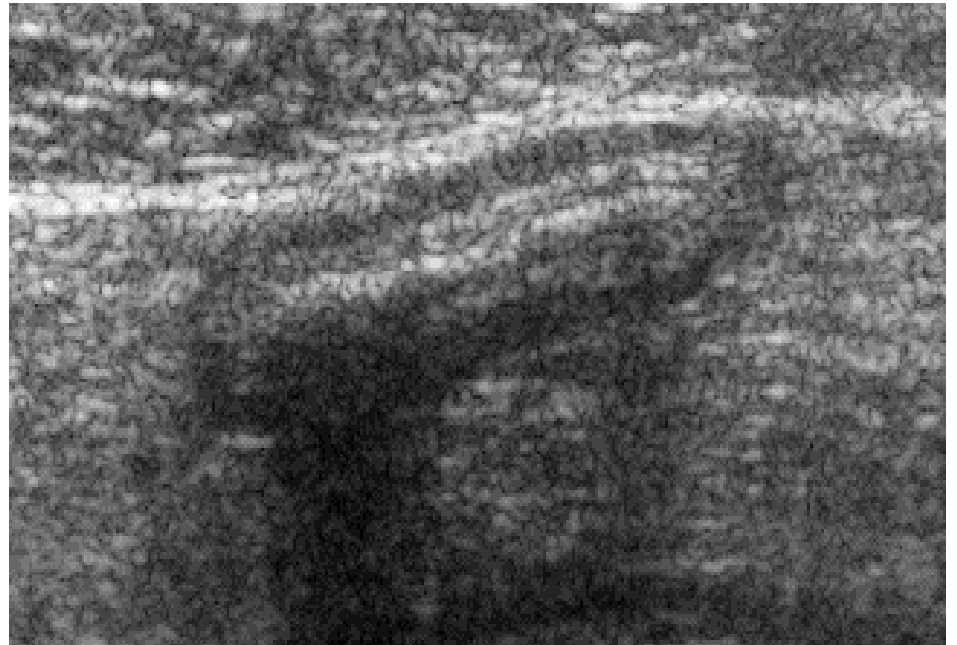


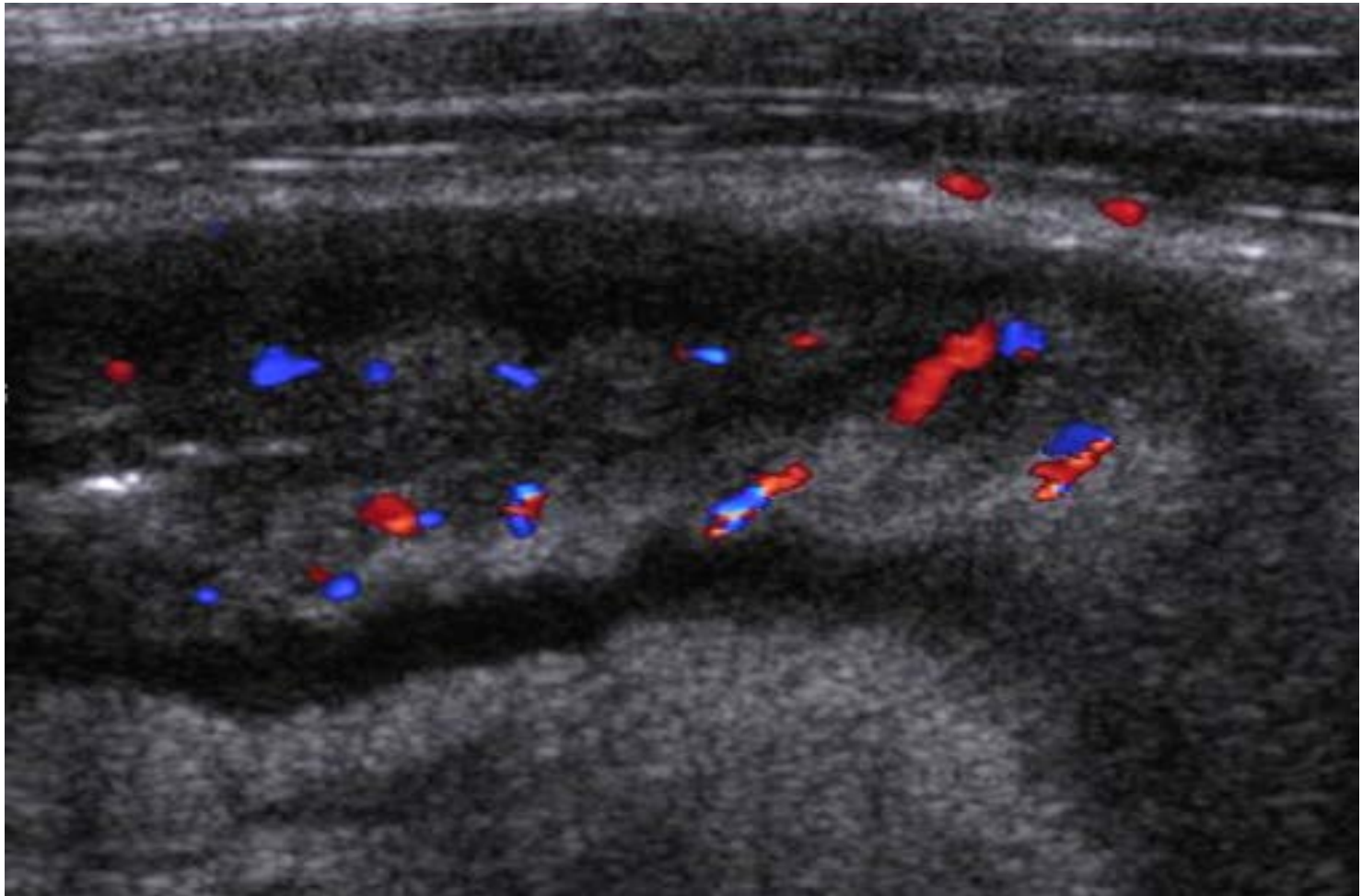
Le colon normal

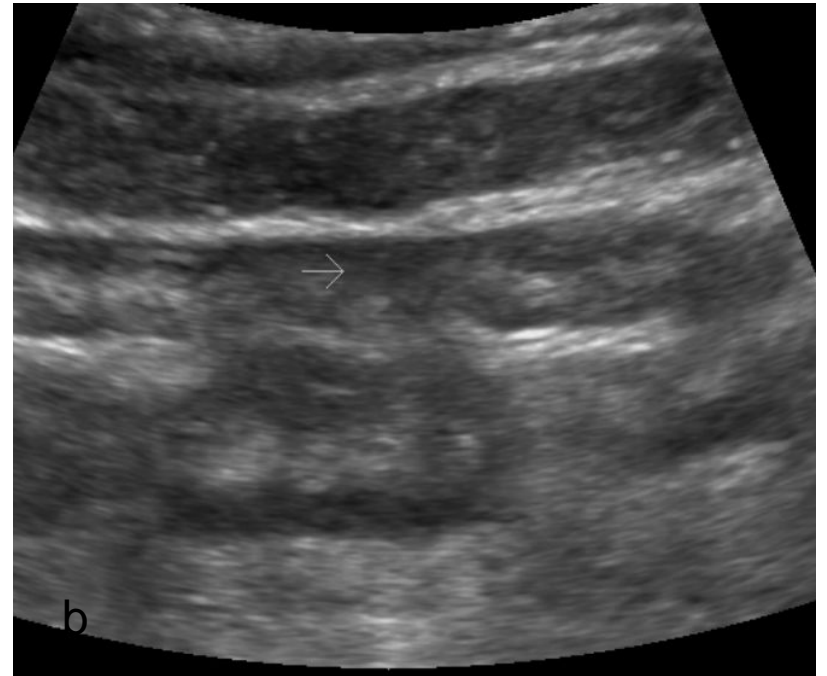
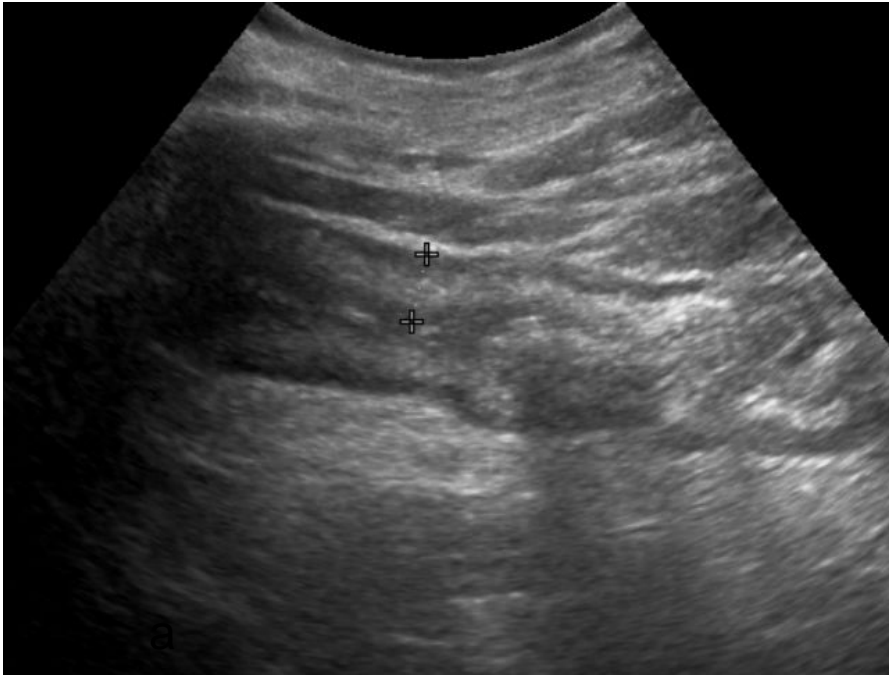
Epaisseur < 5 mm



Stratification

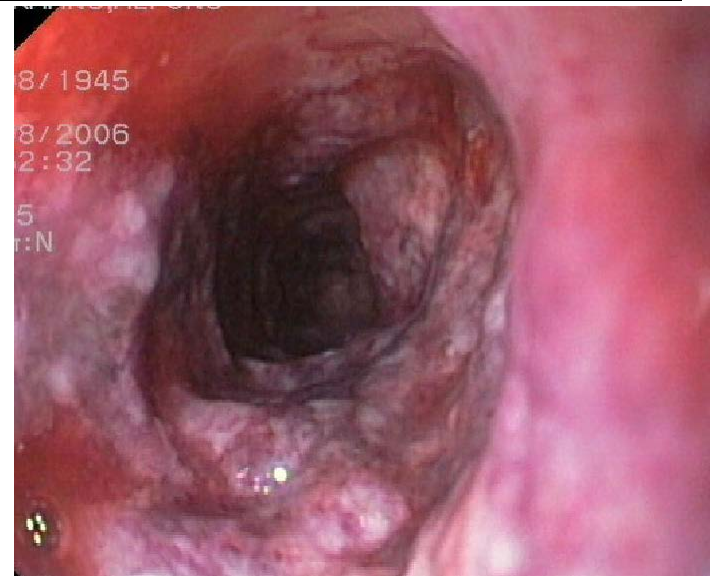


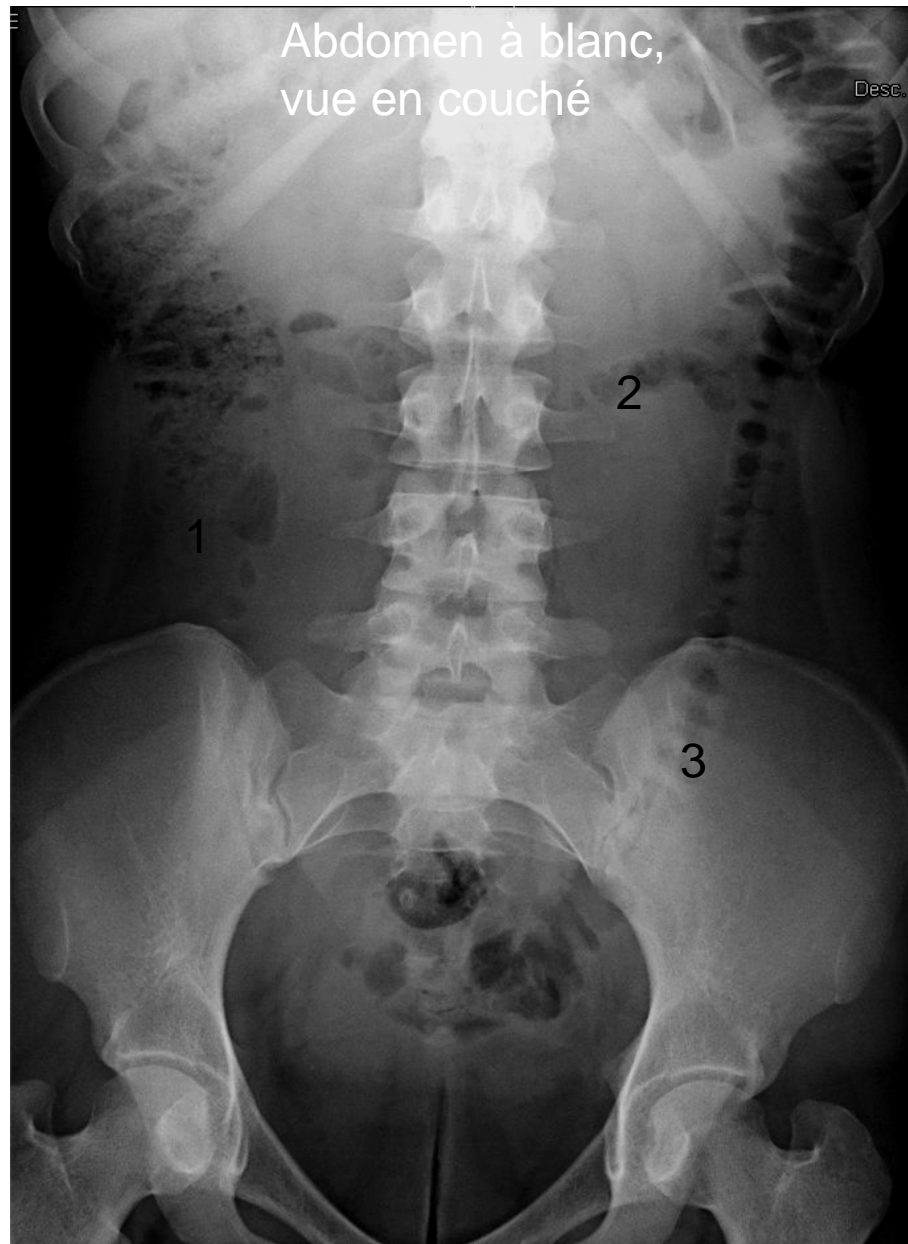



Colon normal : < 5 mm

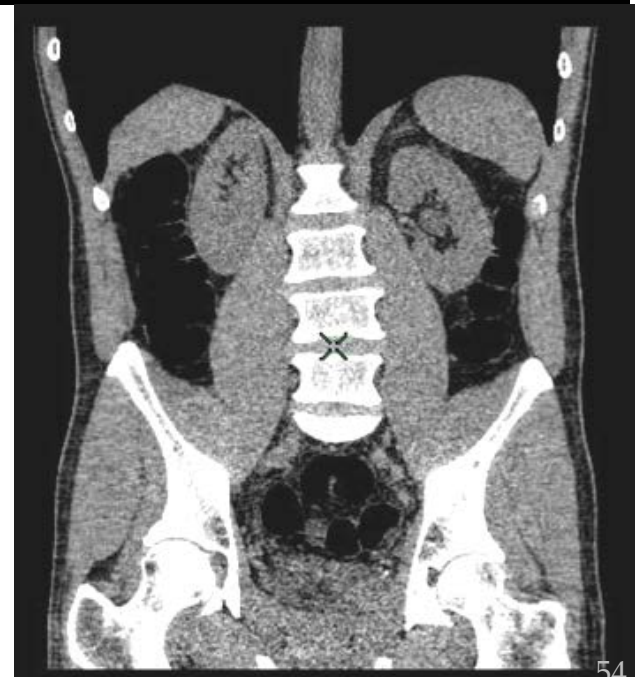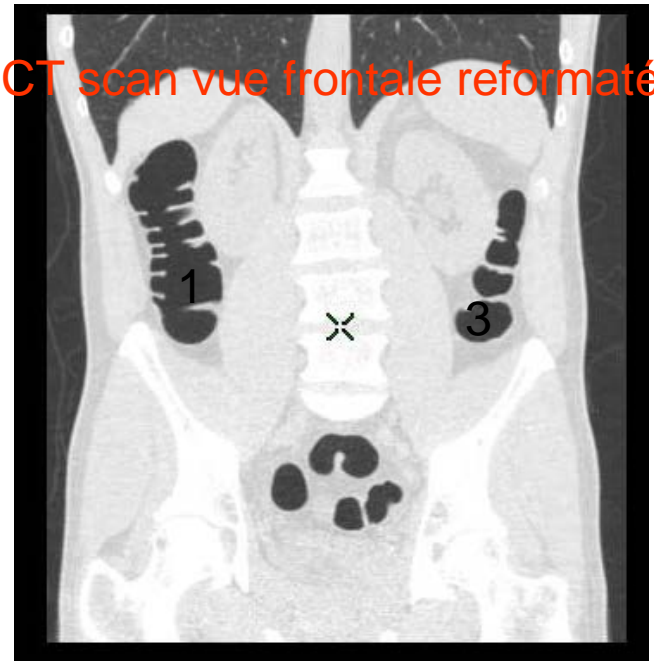
c





1. Colon droit 2. Colon transverse 3. Colon gauche

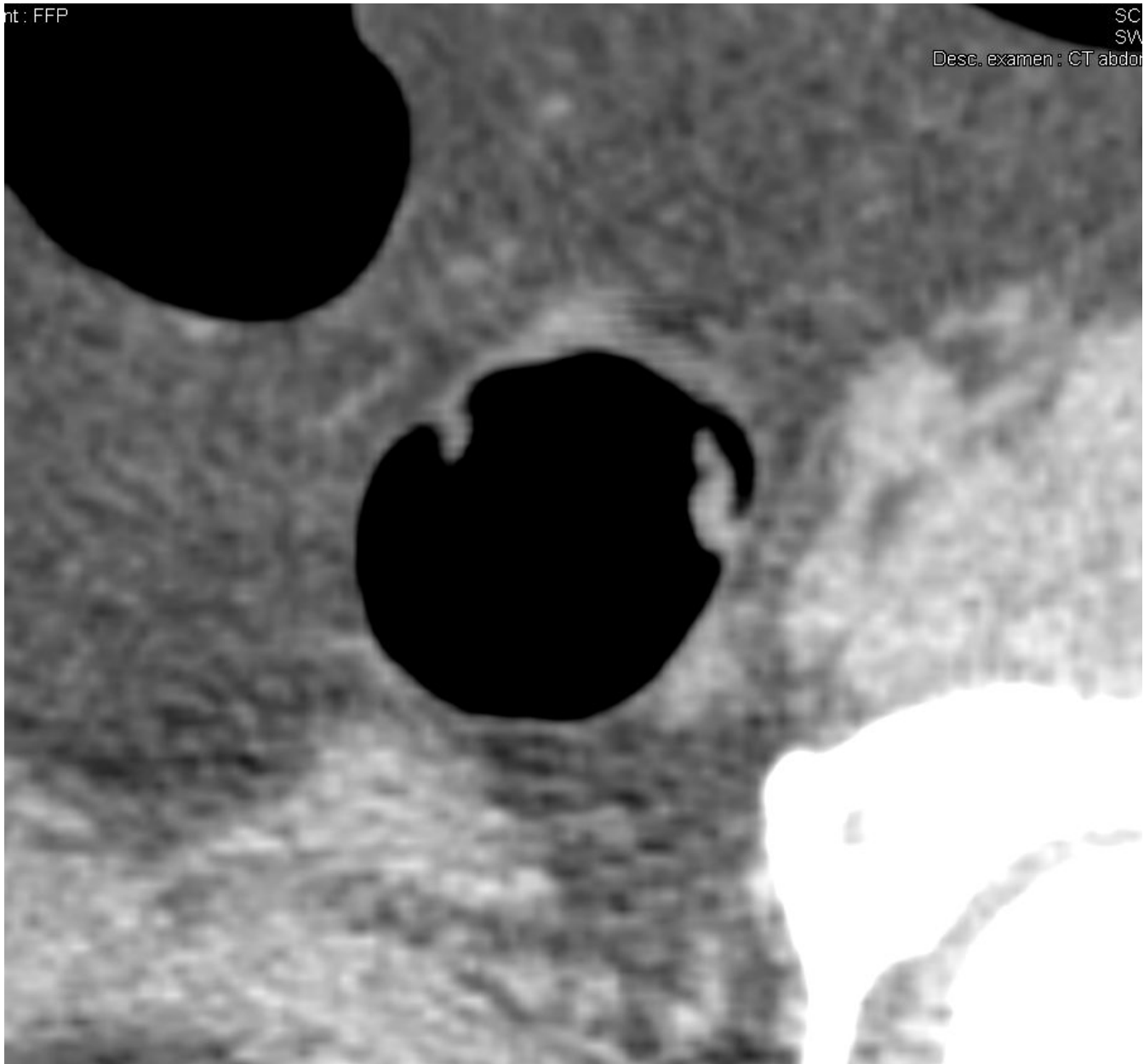
CT scan vue frontale reformatée



nt: FFP

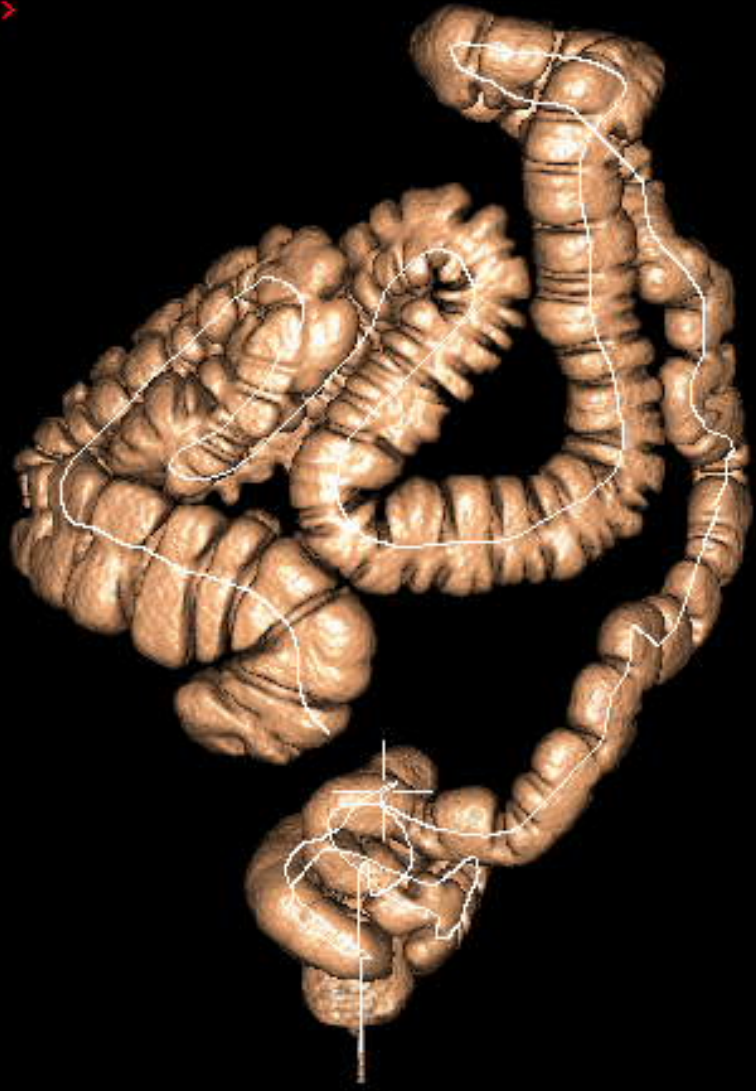
SC
SW

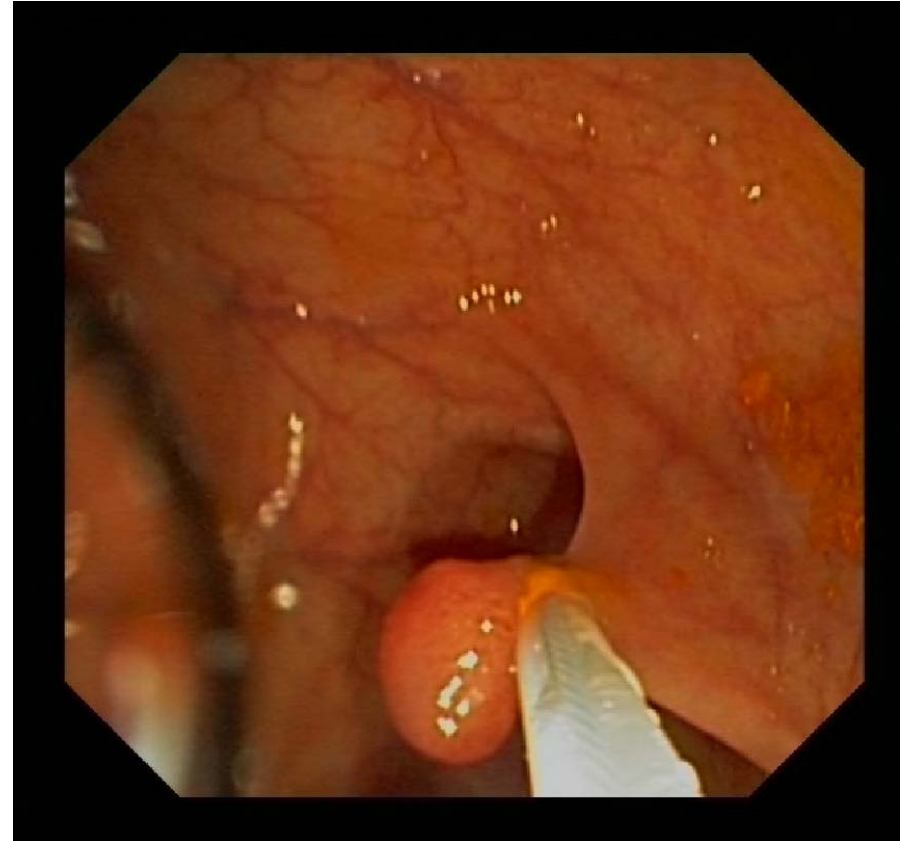
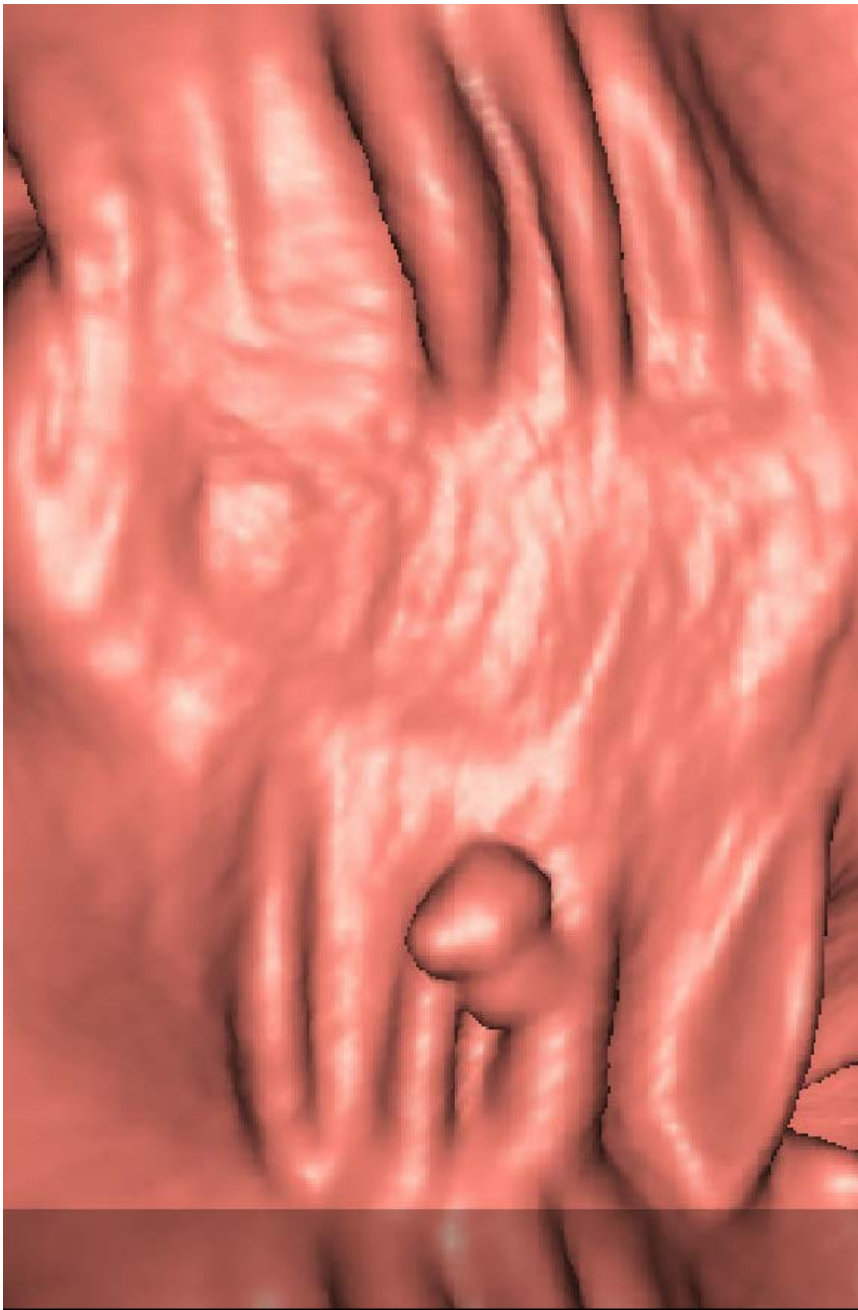Desc. examen : CT abdom

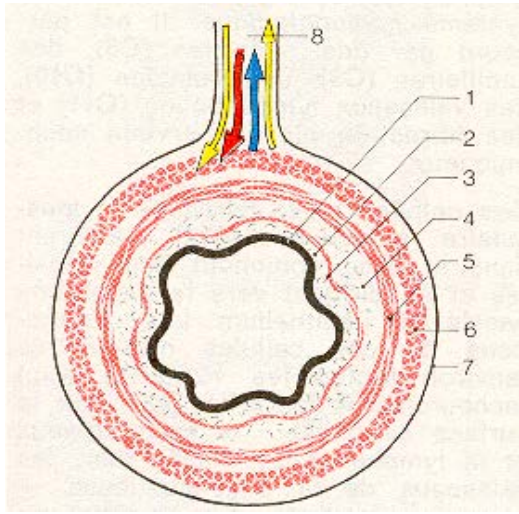


< 30220 (TOUT) >

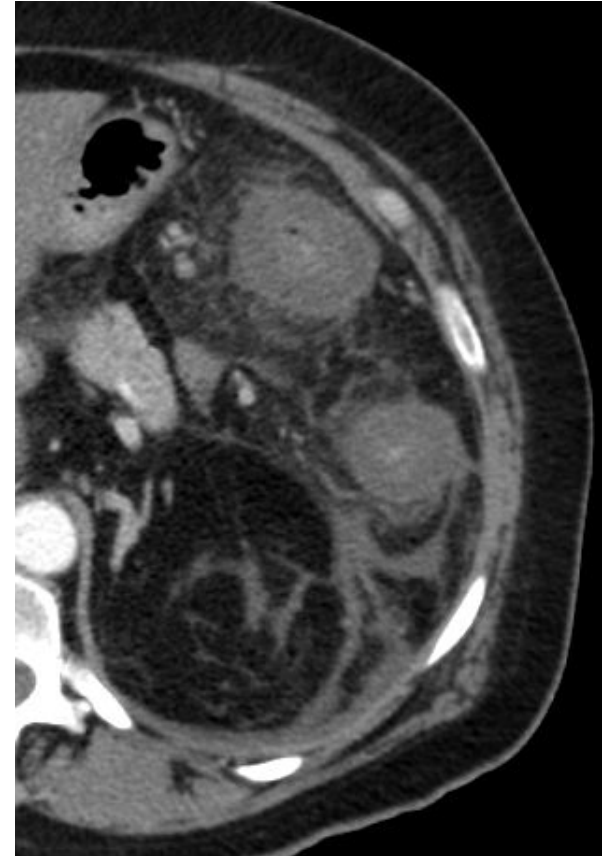
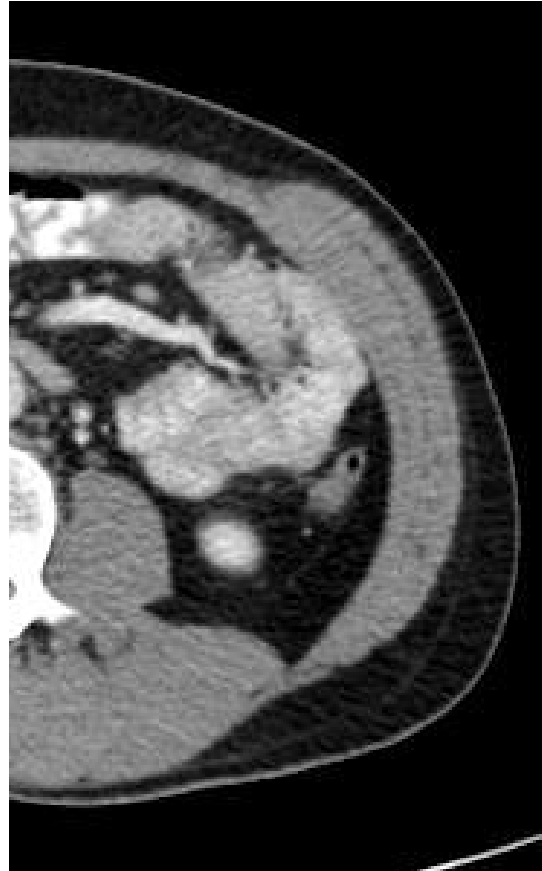R



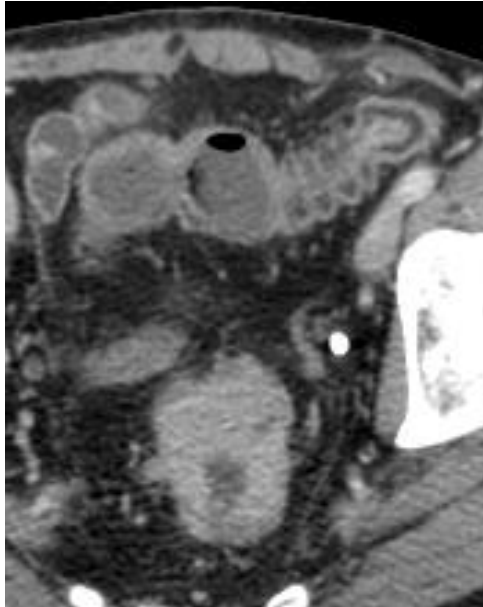




In Kahle W et al, Anatomie, tome 2, Flammarion,
Médecine-Sciences, 1979

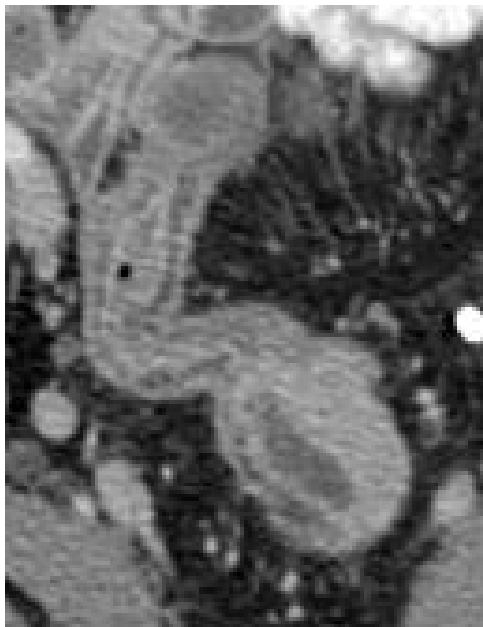

Colon normal : < 5 mm



Épaississement:

- < 5 mm,
- Homogène
- Sous-muqueuse grasseuse



Environnement:

- diverticules
- GGLS

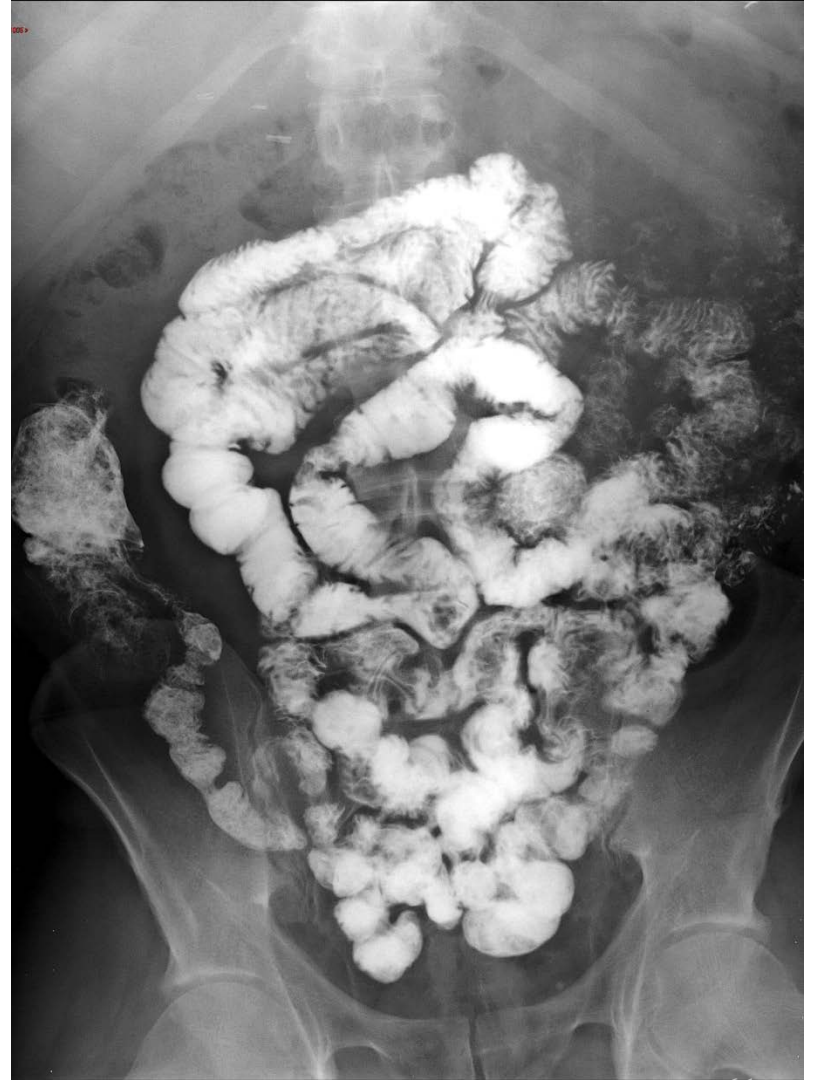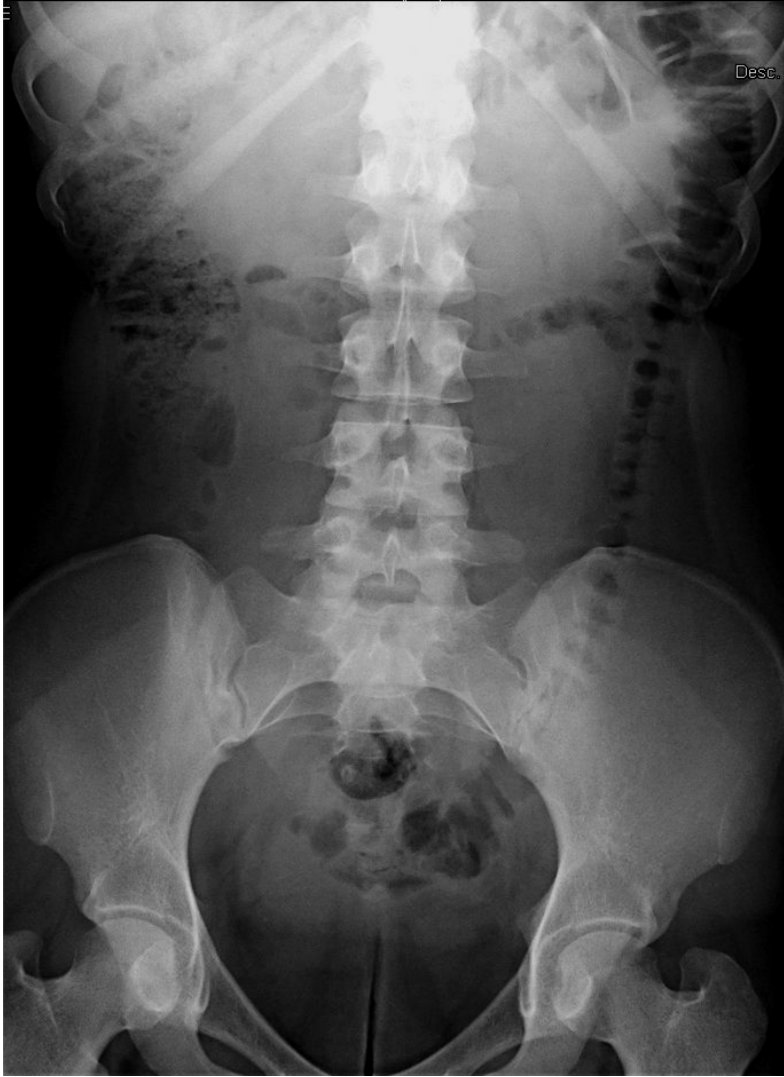INTESTIN NORMAL

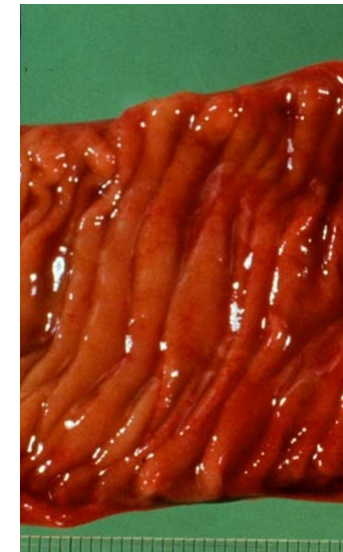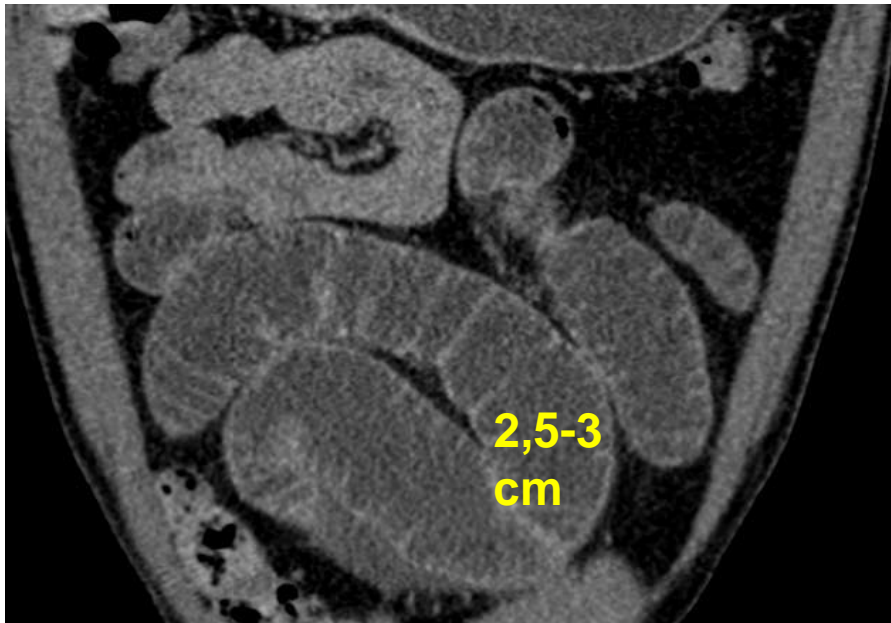
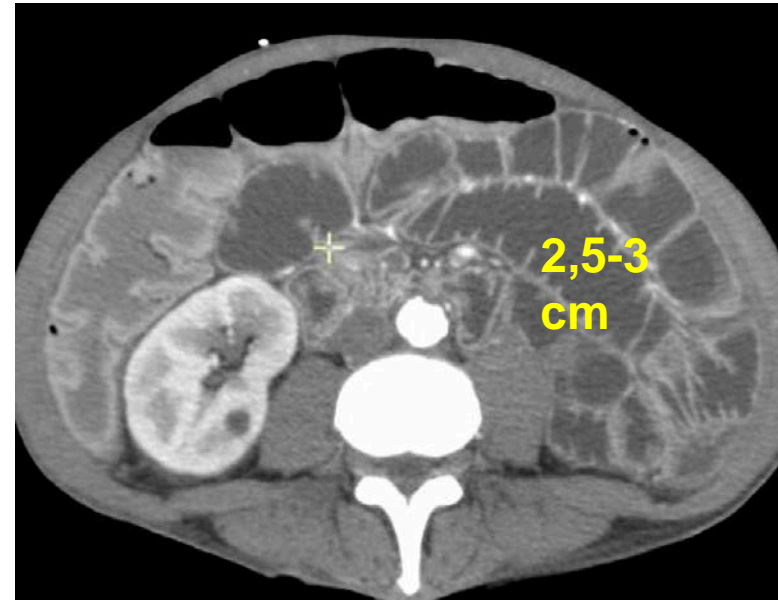

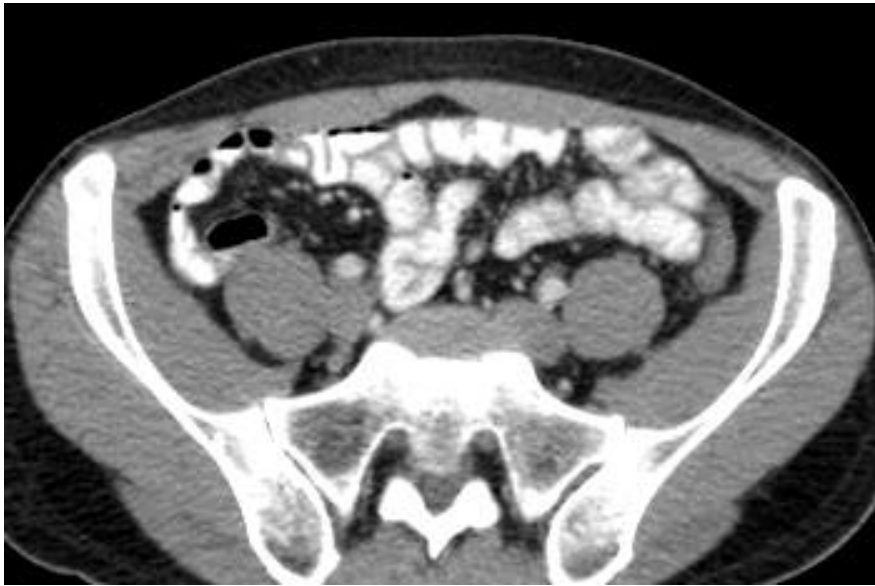
The diagram illustrates the normal intestine as a horizontal tube. The left end is rounded, representing the cecum. The tube is divided into three horizontal sections: a top blue section, a middle white section, and a bottom grey section. The middle white section is labeled 'GRELE' and the bottom grey section is labeled 'Colon'.

GRELE

Colon





Normal Small Bowel < 3 mm

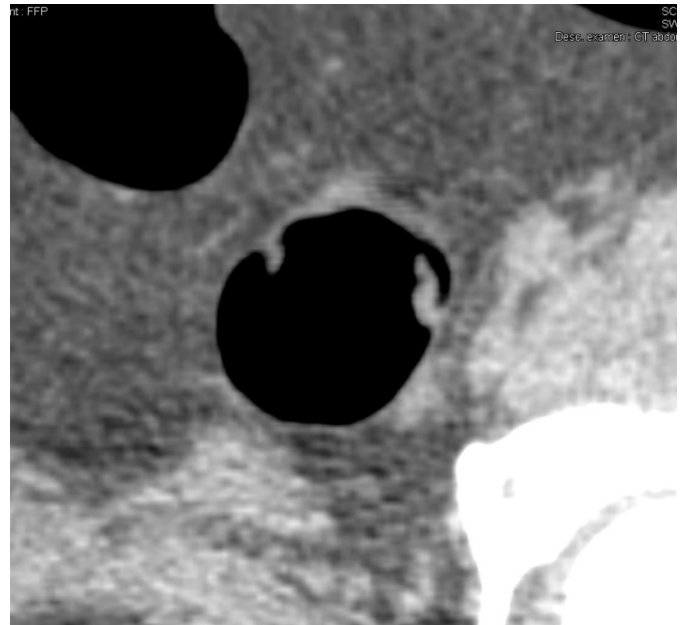
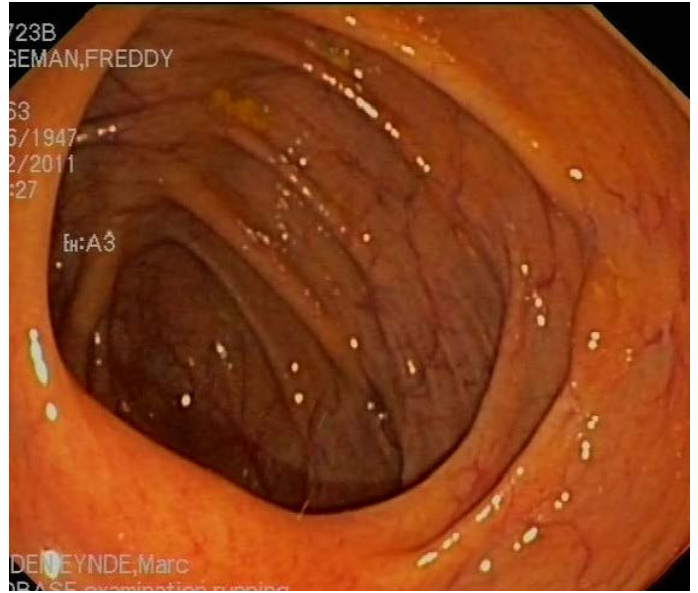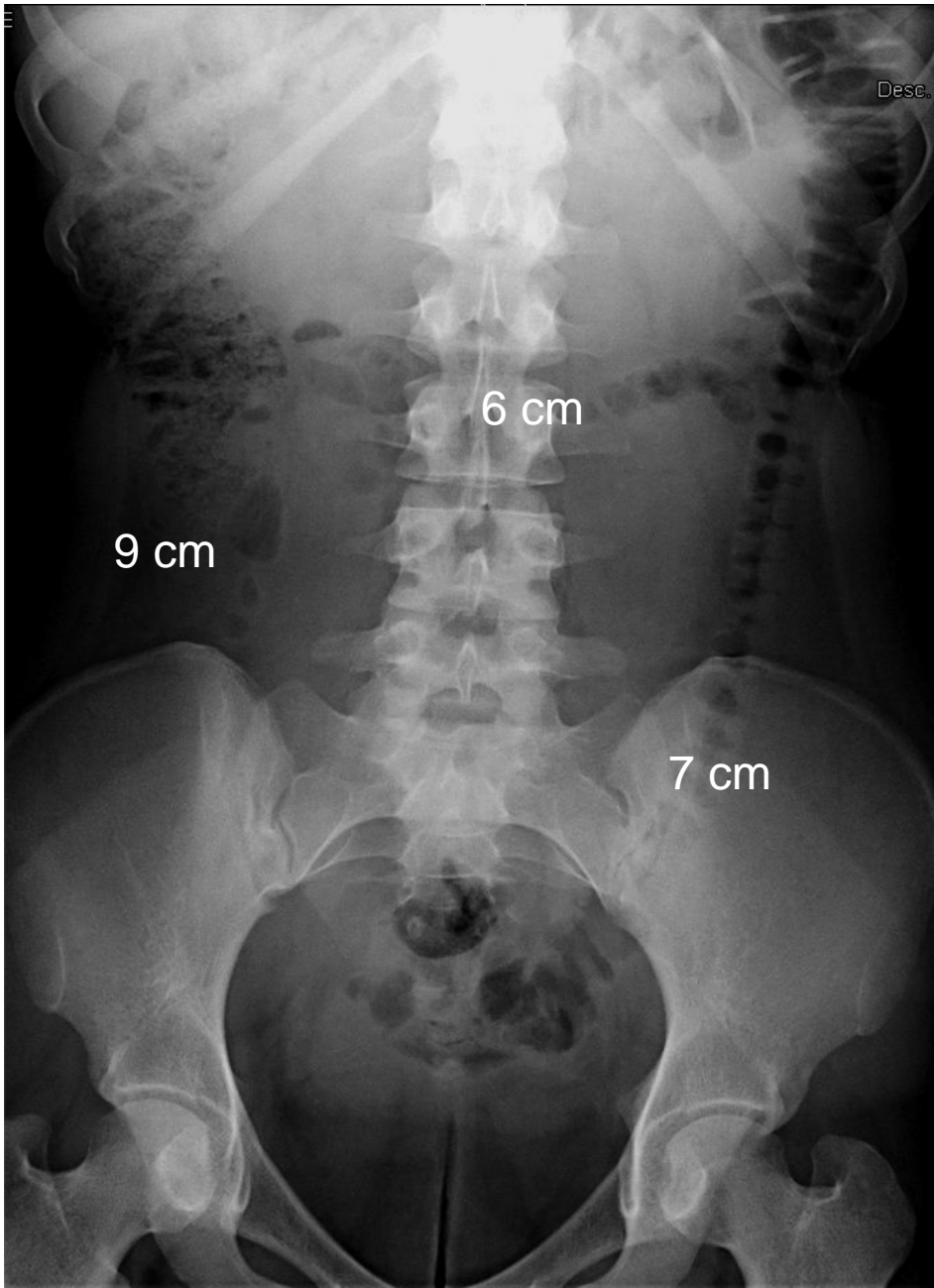
INTESTIN NORMAL

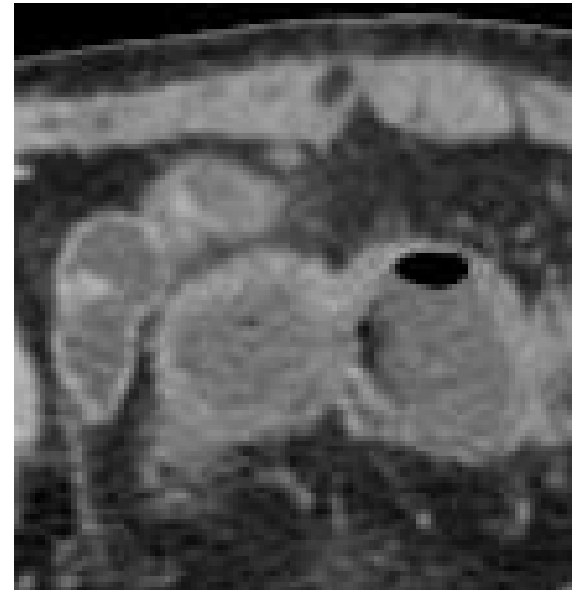
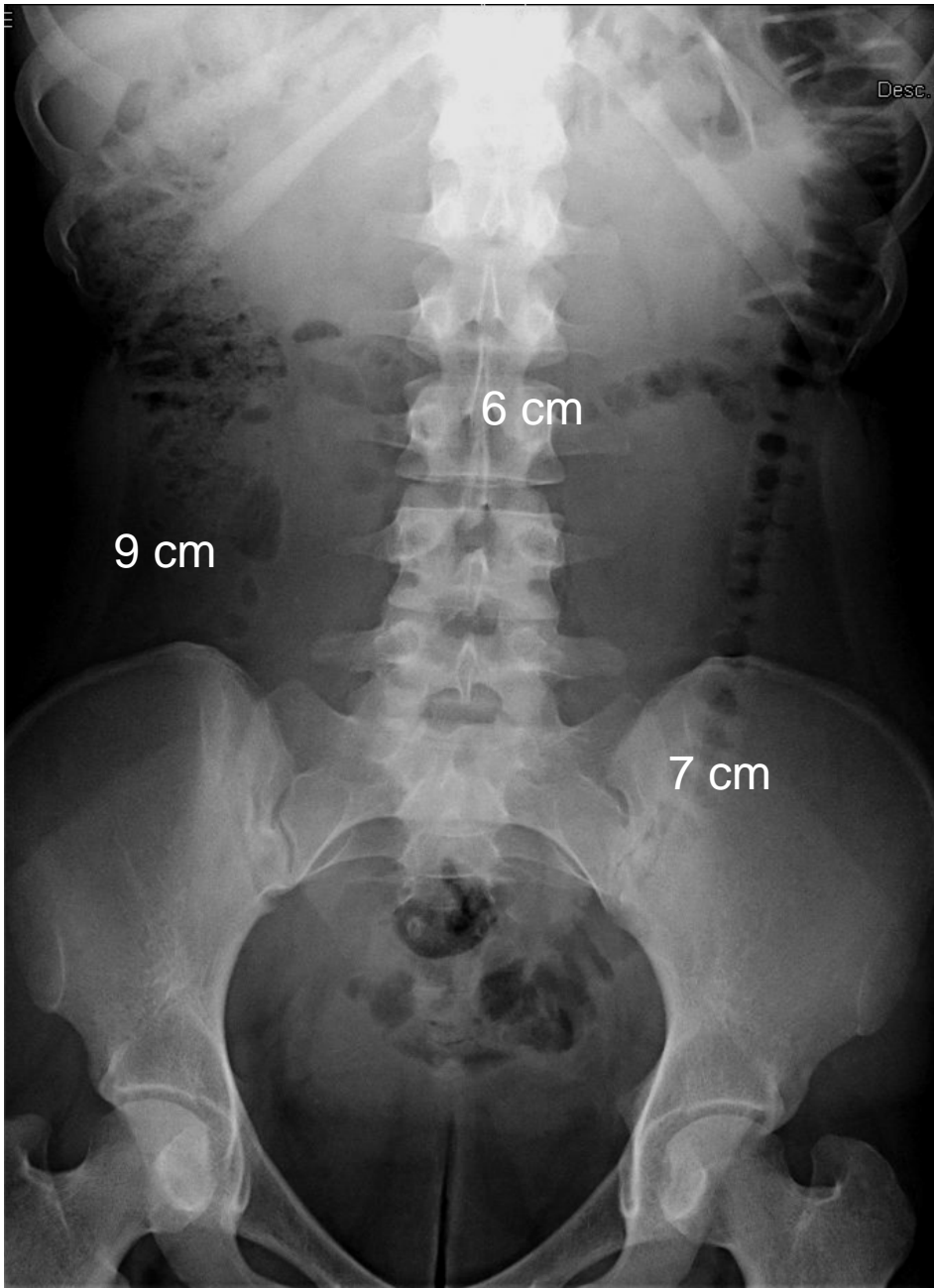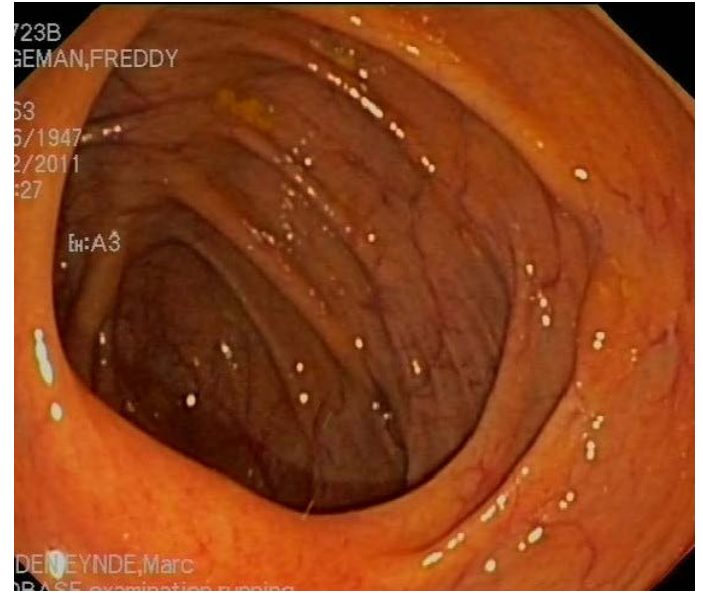


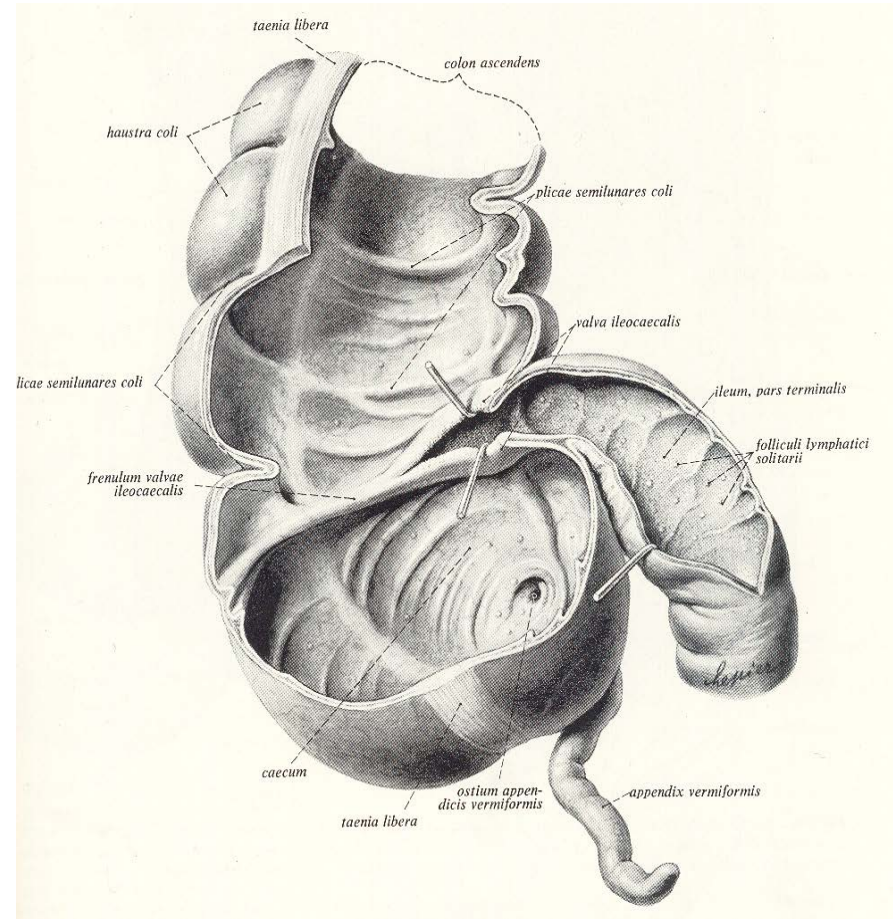
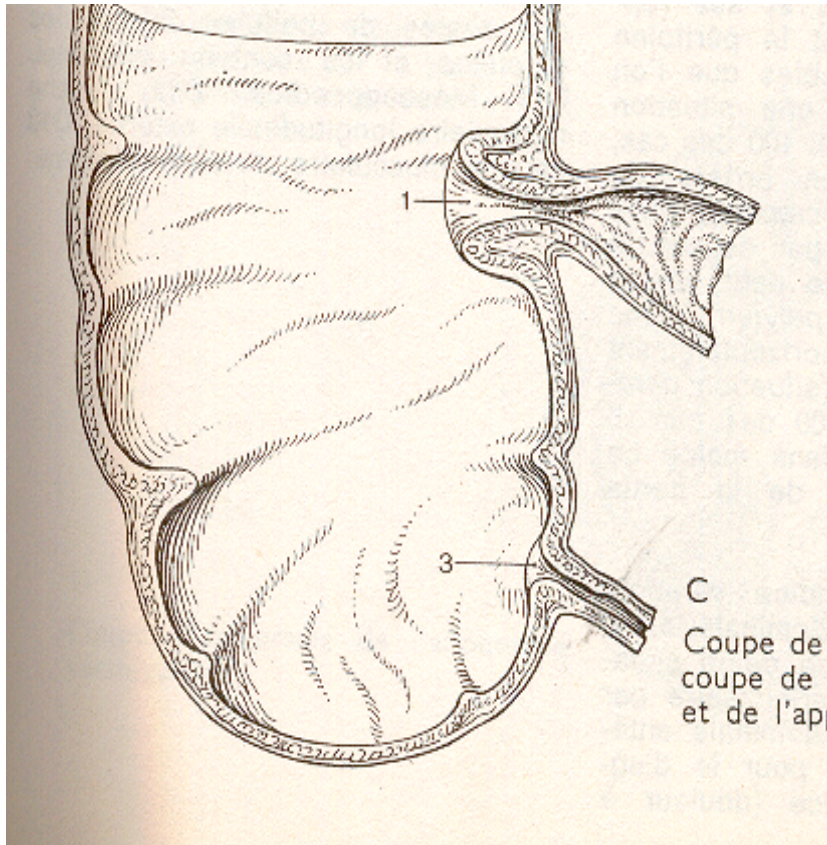
A diagram of the human intestine, represented as a horizontal tube. The left end is rounded. The tube is divided into three horizontal sections: a top blue section, a middle white section, and a bottom grey section. The white section is labeled 'GRELE' and the grey section is labeled 'Colon'.

GRELE

Colon



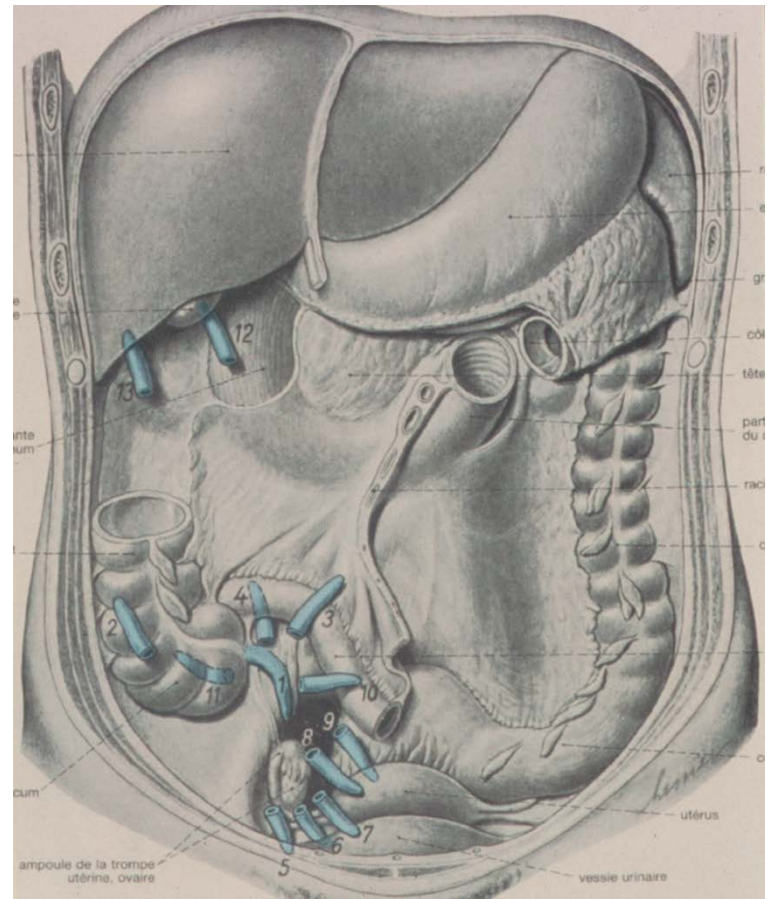




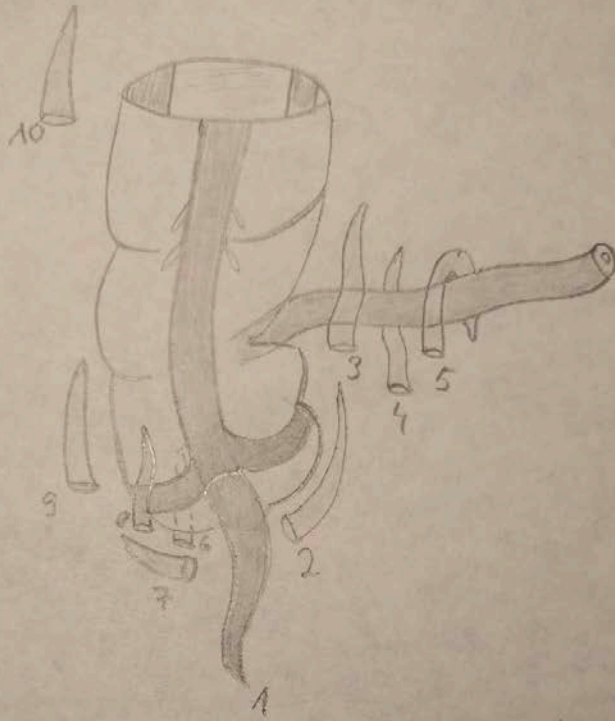
In Kahle et al, Anatomie, 2, Flammarion médecine Sciences, 1979

Appendice vermiforme

- Longueur : 6-12 cm
- Largeur : 6 mm
- Topographie variable
 - Descendant
 - Ascendant (rétrocaecal)
 - Latéral
 - Médial



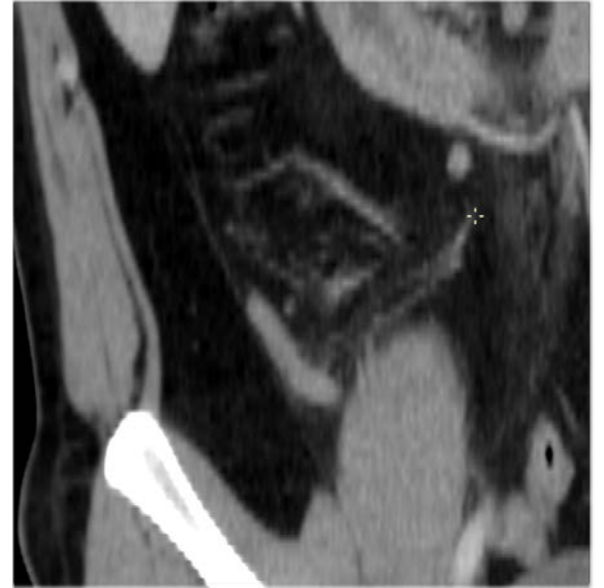In Netter, Atlas d'anatomie humaine, Masson, 2007



- 1: pelvienne
- 2: medio-caecale
- 3: pré-iléale
- 4: rétro-iléale
- 5: péri-iléale

- 6a rétro-caecale
- 7: infra-caecale
- 8: pré-caecale
- 9: latéro-caecale
- 10: infra-hépatique

6b: rétrocolique
(au dessus de la valve iléocaecale.)



Topographies appendiculaires, Dr Binsfeld, 2017

Appendice normal et US

- Topographie
- Taille et Diamètre
 - 2 à 25 cm de long
 - Paroi < 3 mm
 - Diamètre < 6 mm
- Contenu
 - Hyper ou hypoéchogène
- Doppler couleur

In Williams, 1994

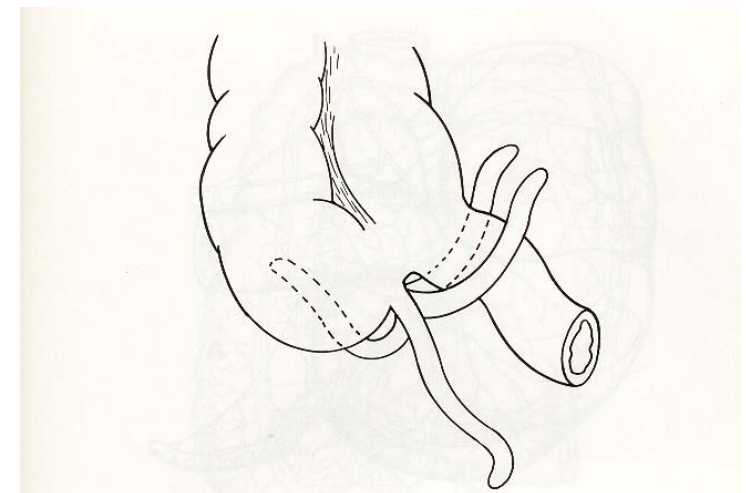
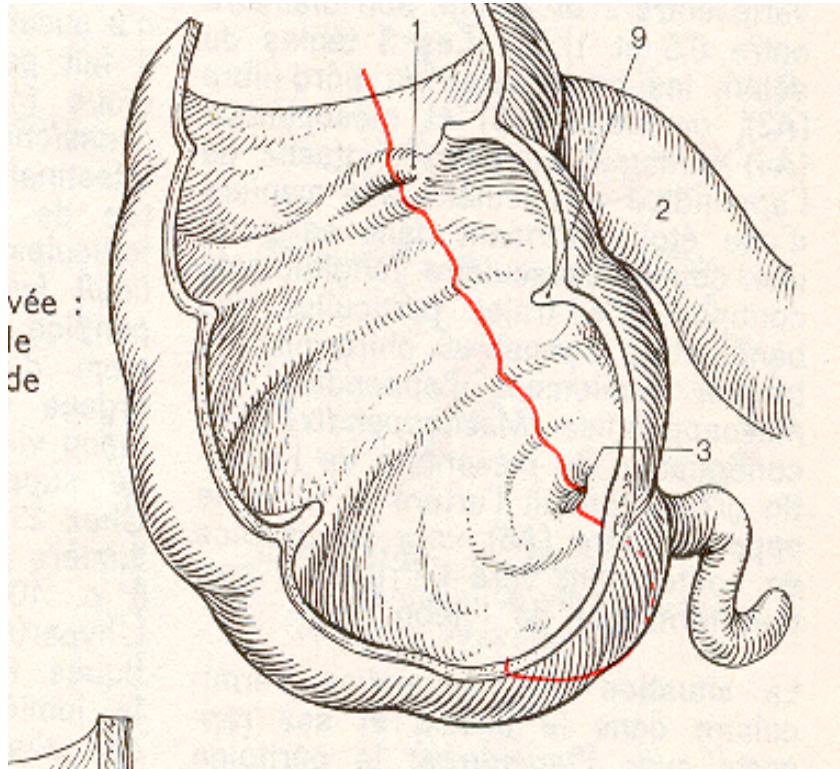


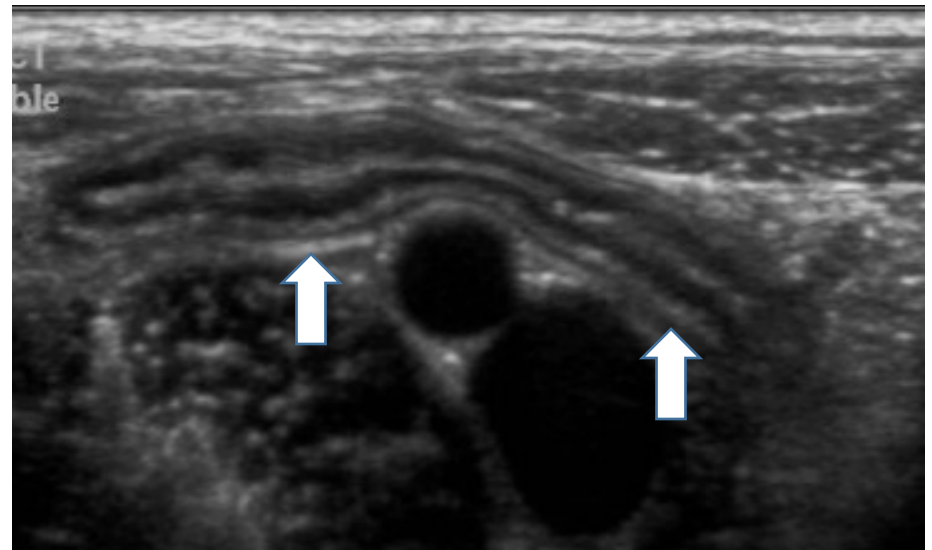
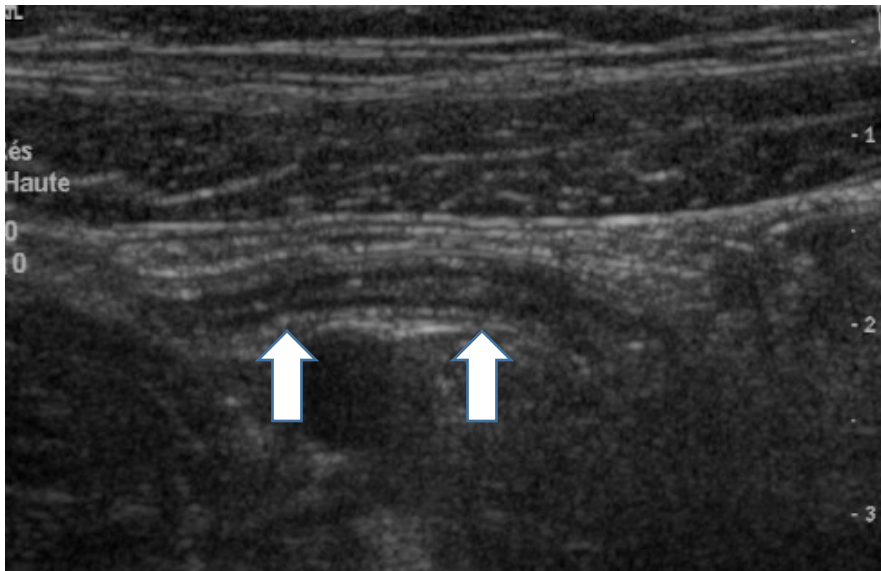
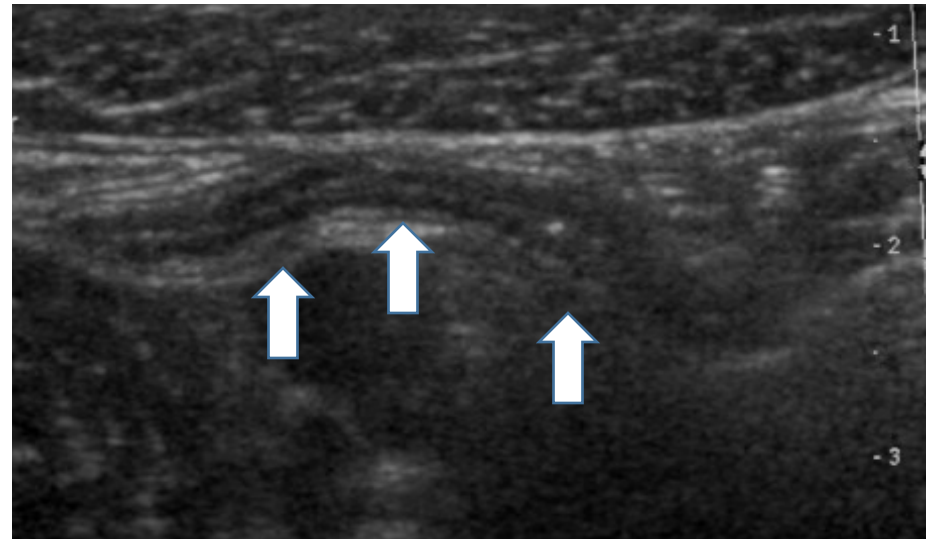
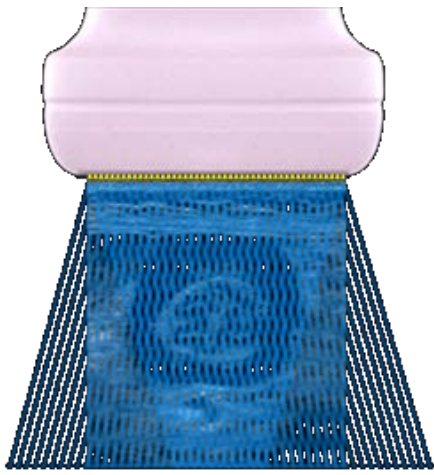
Figure 2.2 The diagram illustrates the four most common positions of the vermiform appendix.

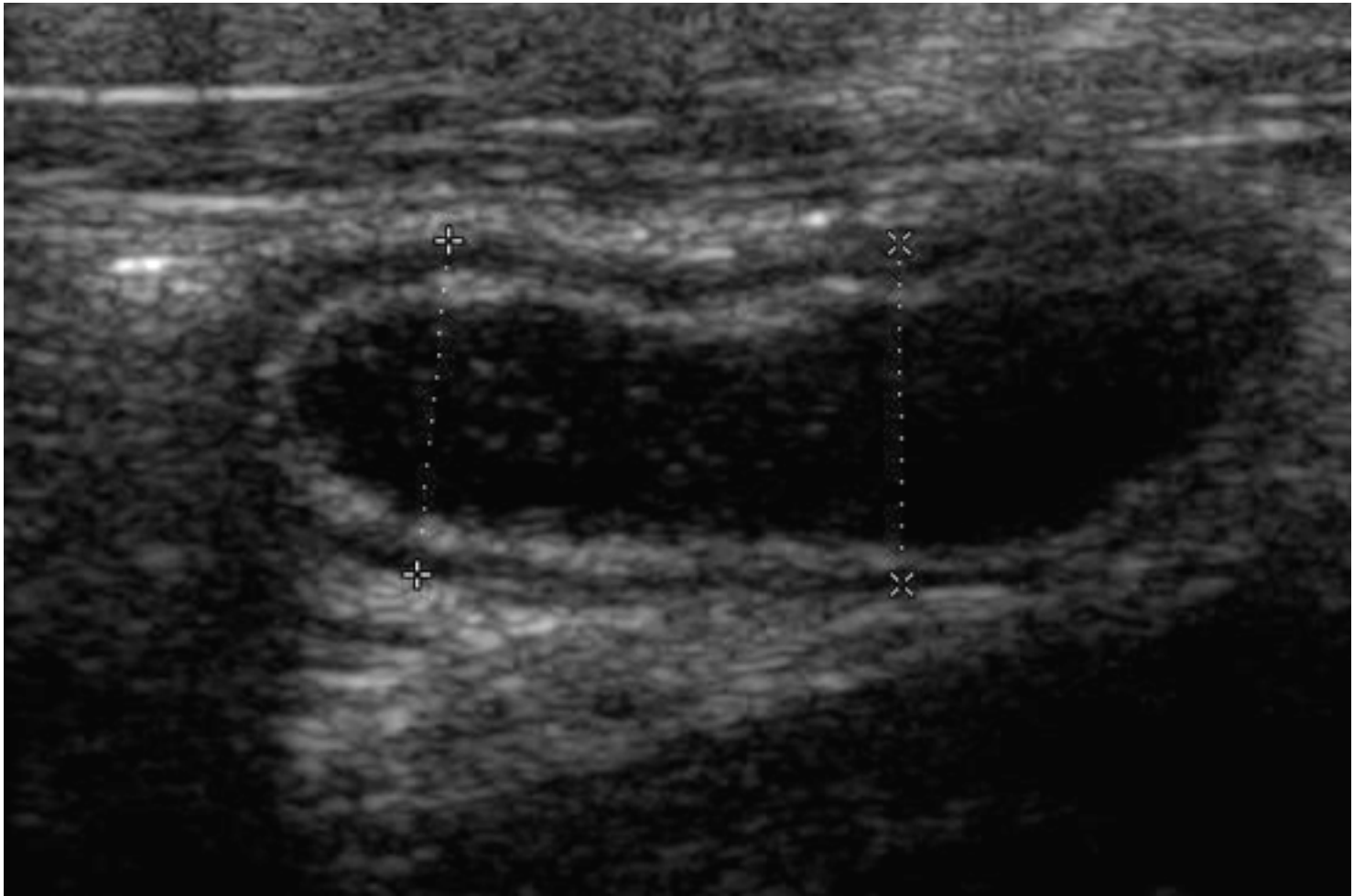
44.6 à 82 %



In Kahle et al, Anatomie, 2, Flammarion médecine Sciences, 1979

appendice





Appendice et TDM

- TDM :
 - Examen focalisé
 - Examen global
 - Opacifications
 - Orales
 - Rectales
 - Injection intraveineuse
 - 100 à 150 ml
 - » 70/270 sec; 2.5/2 ml/sec

Appendice normal et TDM

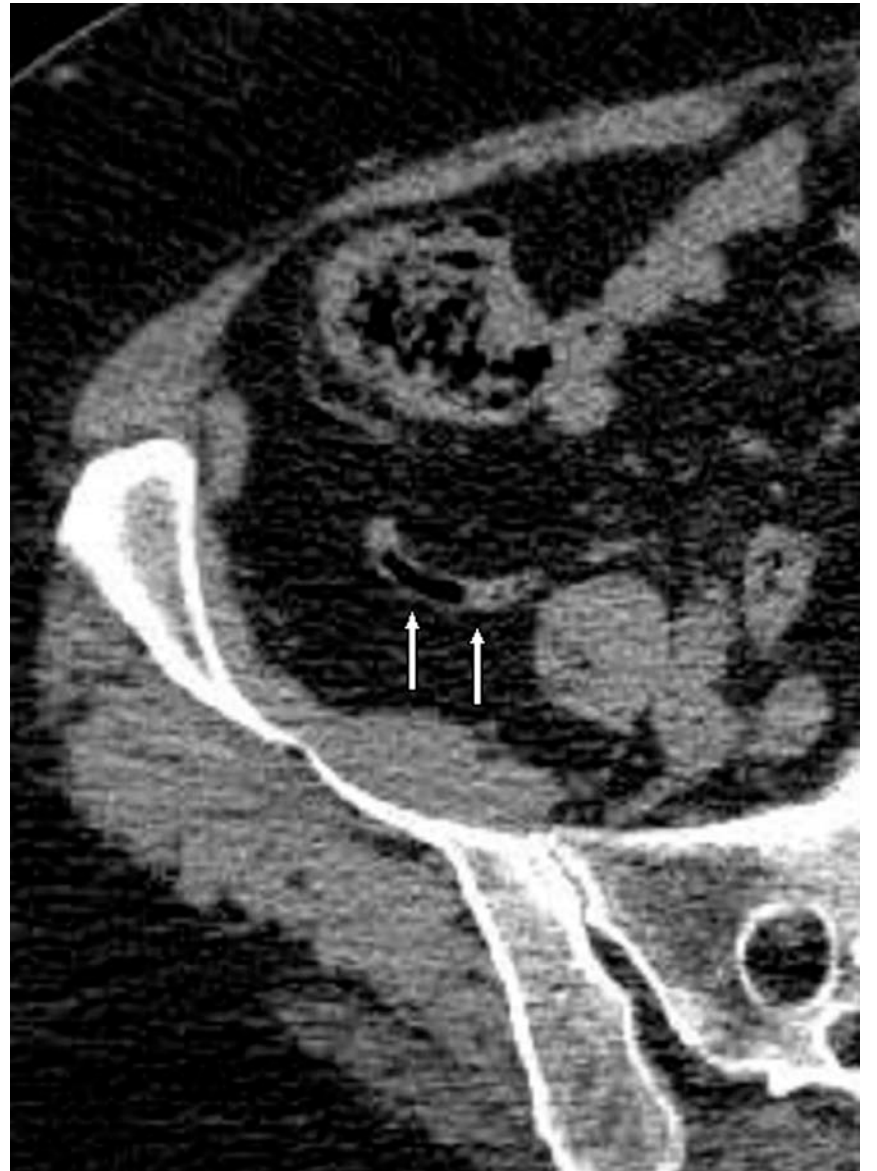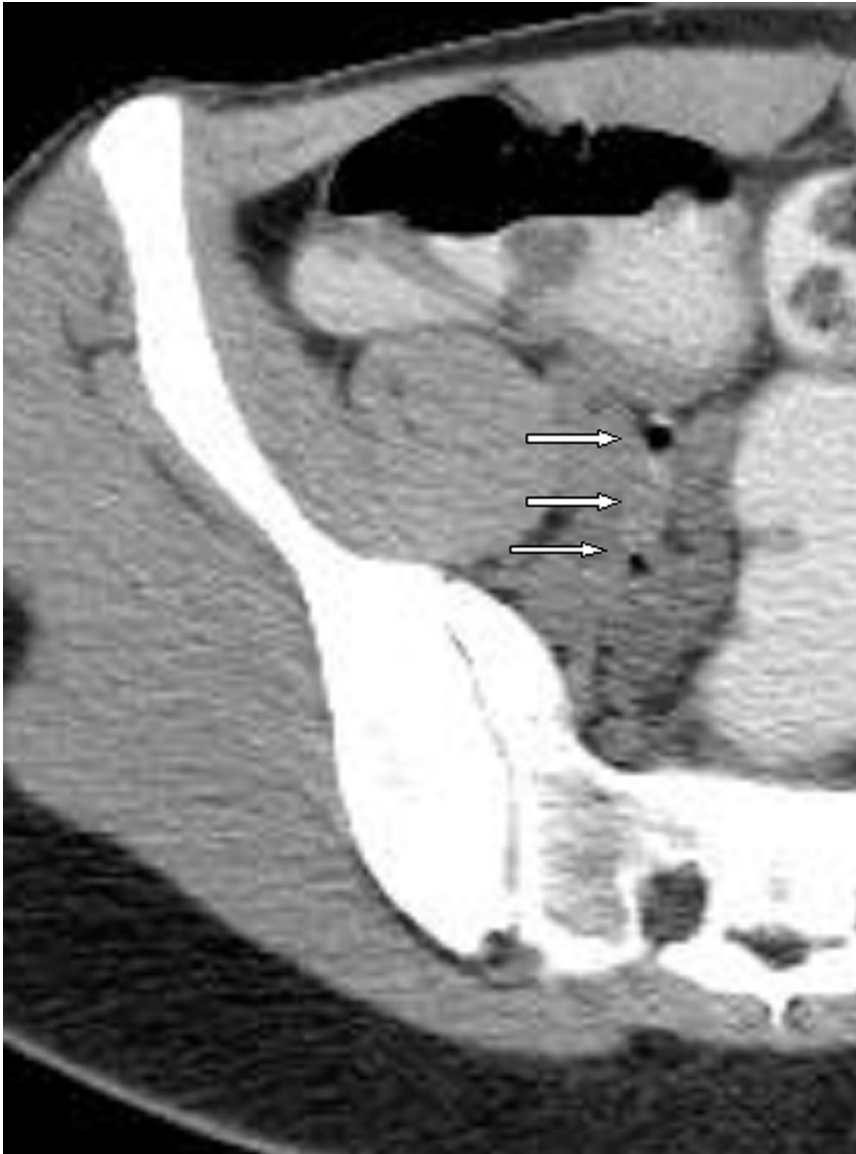- Appendice normal:
 - Rempli de matériel et/ou de gaz
 - Paroi < 2 mm
 - Graisse normale

- < 6 mm



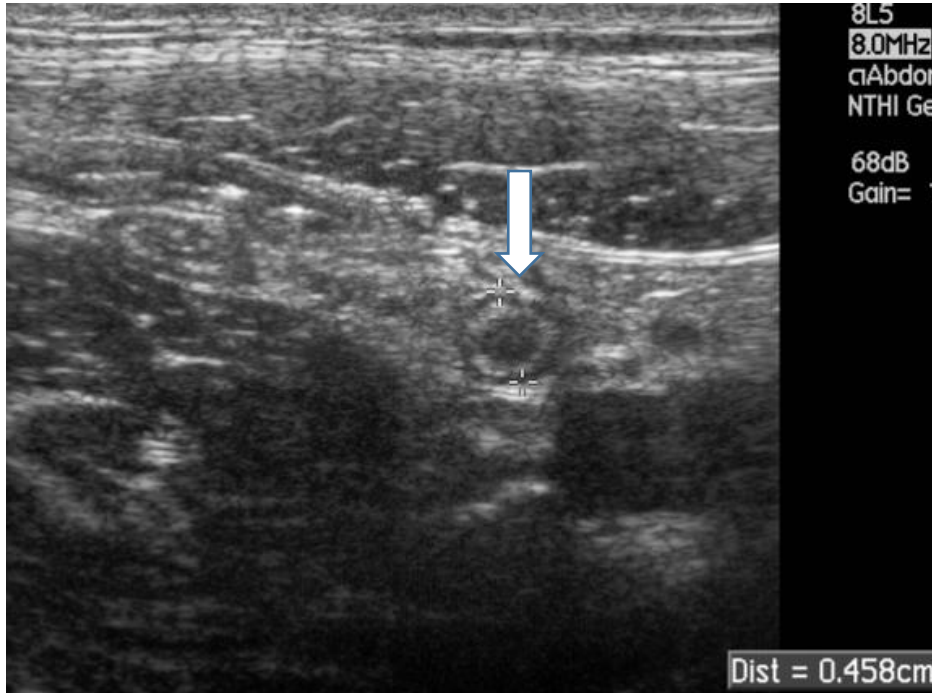
[6 - 8] mm

77 à 81 %



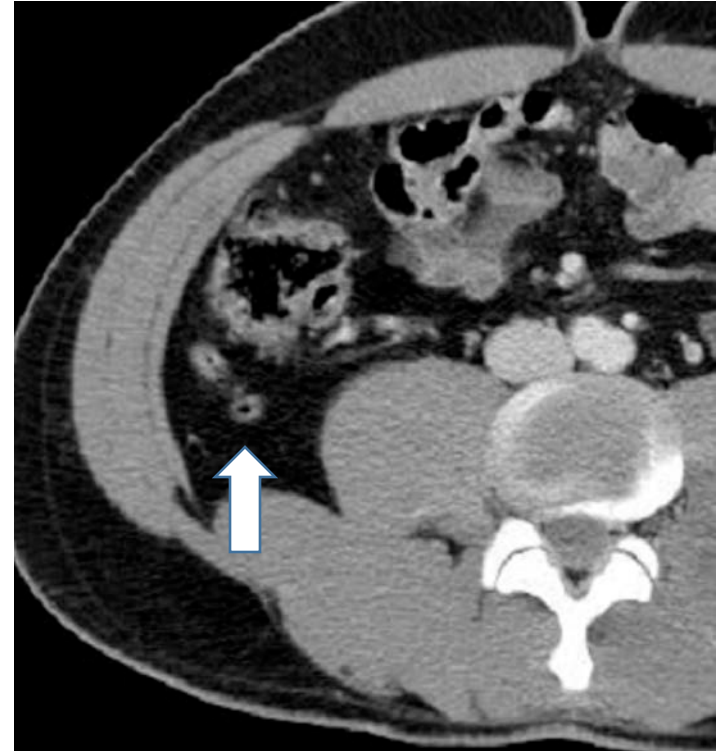
Appendice normal

En échographie



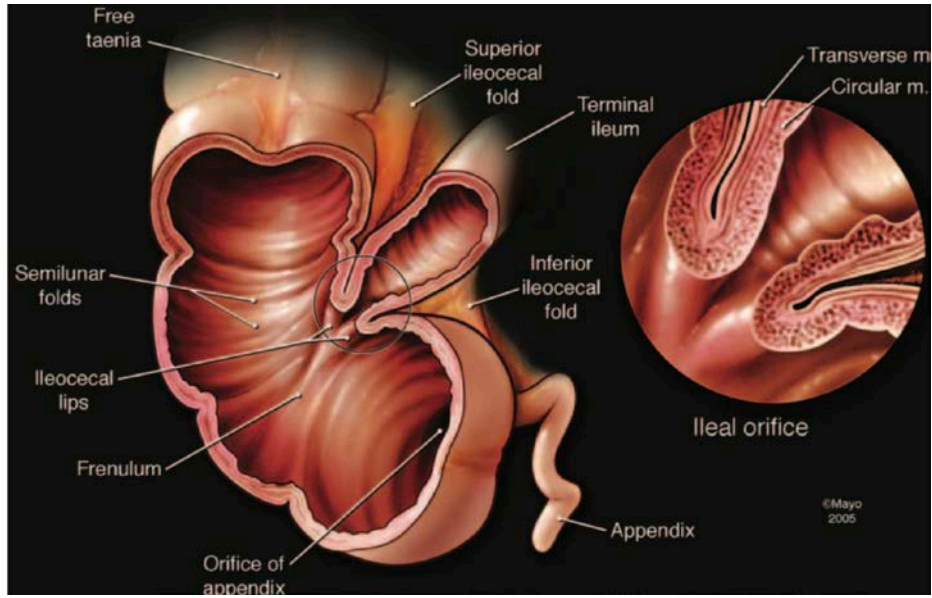
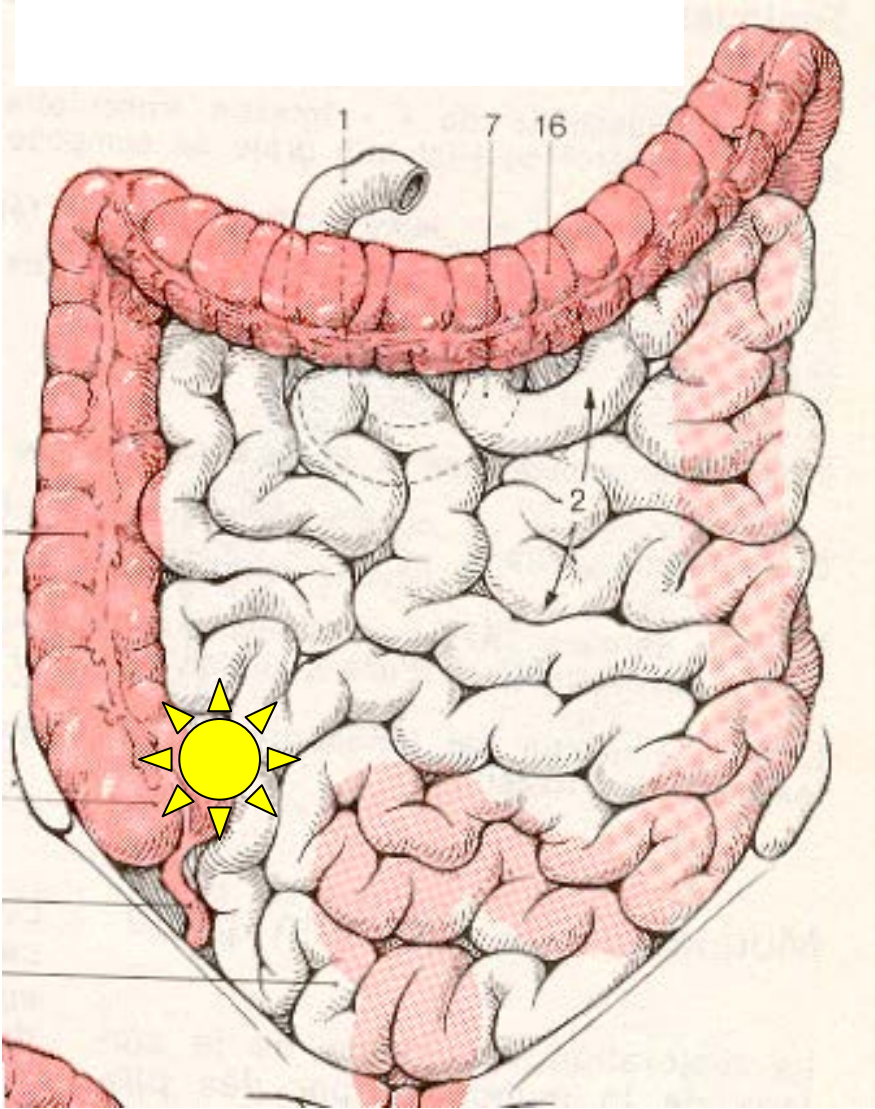
44.6 à 82 %

au scanner

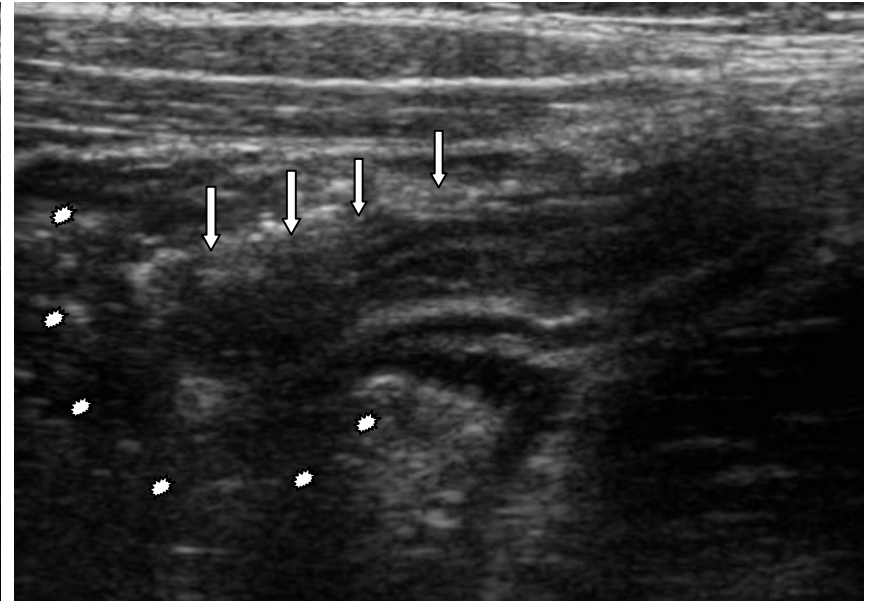
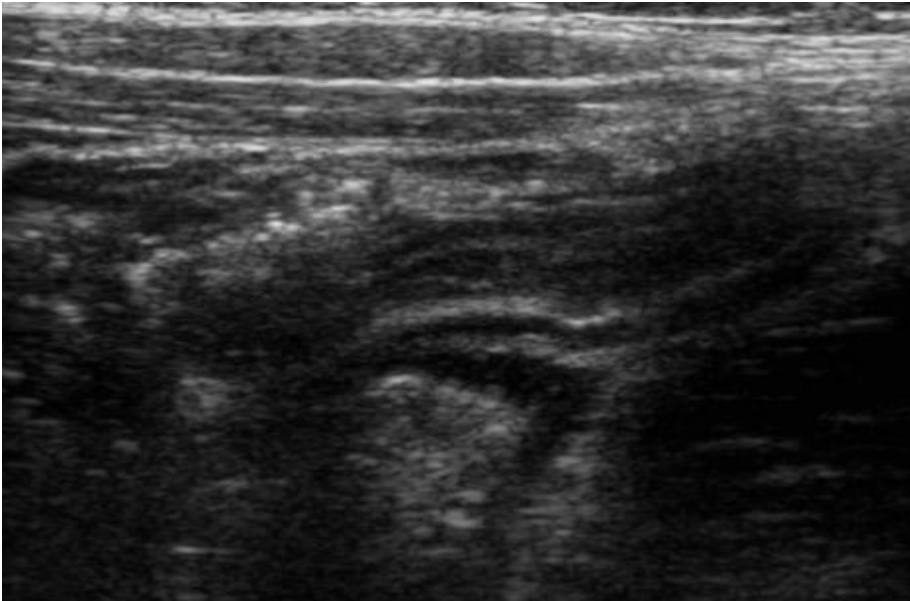
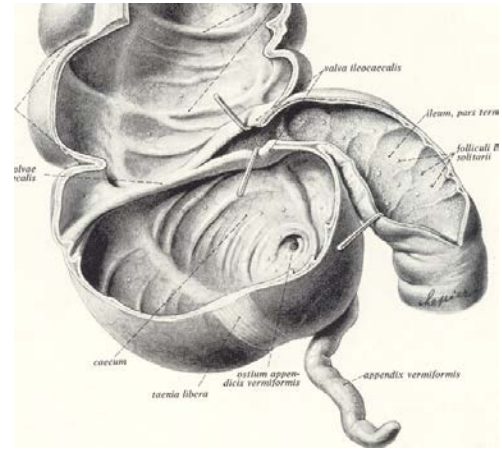
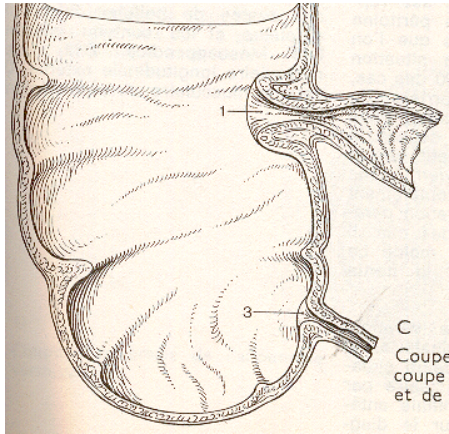


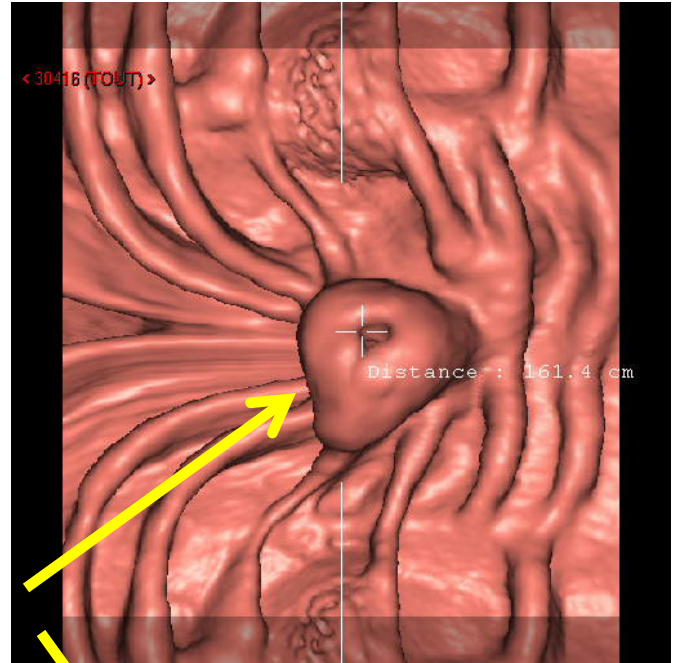
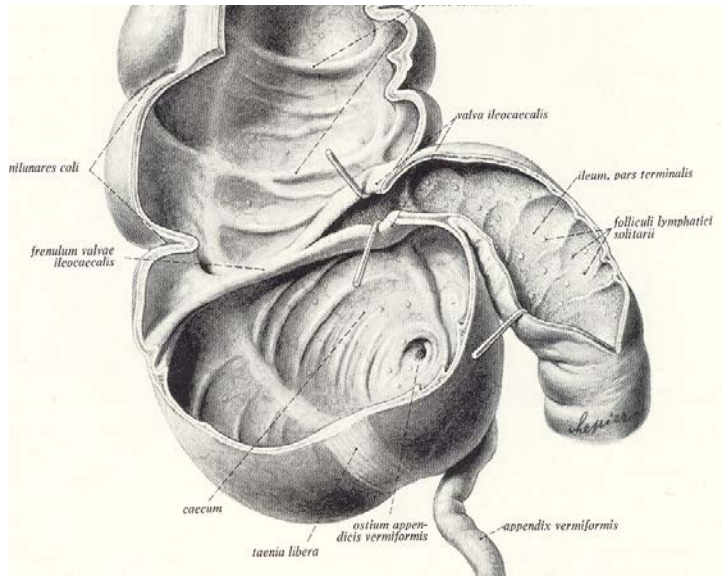
77 à 81 %

CARREFOUR ILEO COECAL

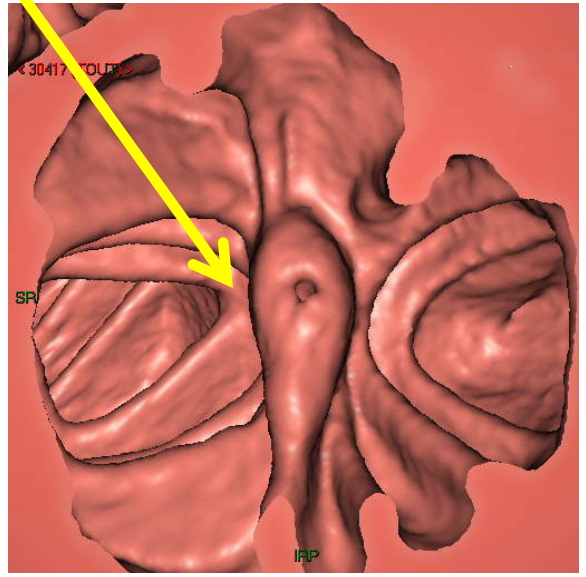
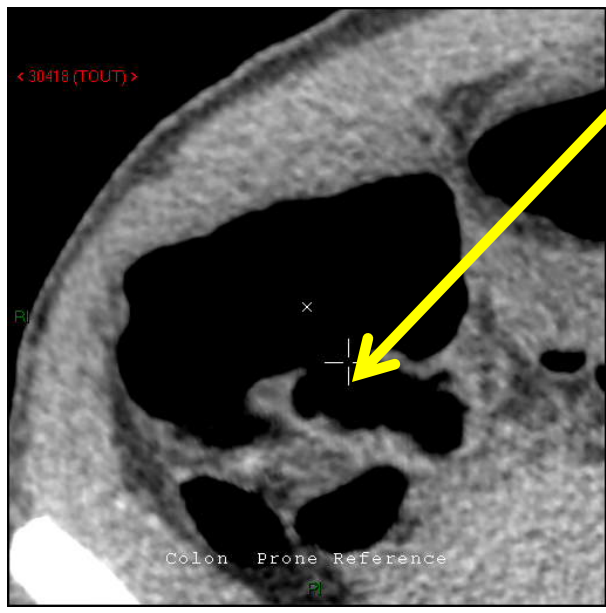


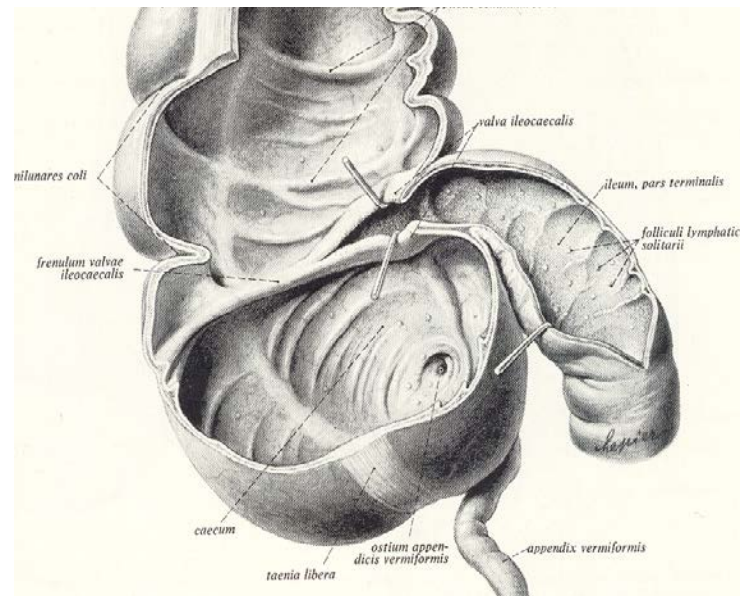
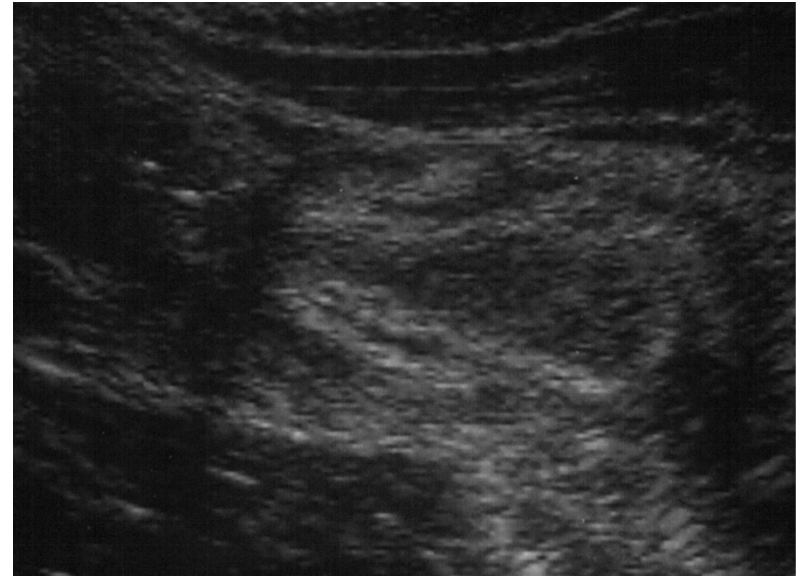
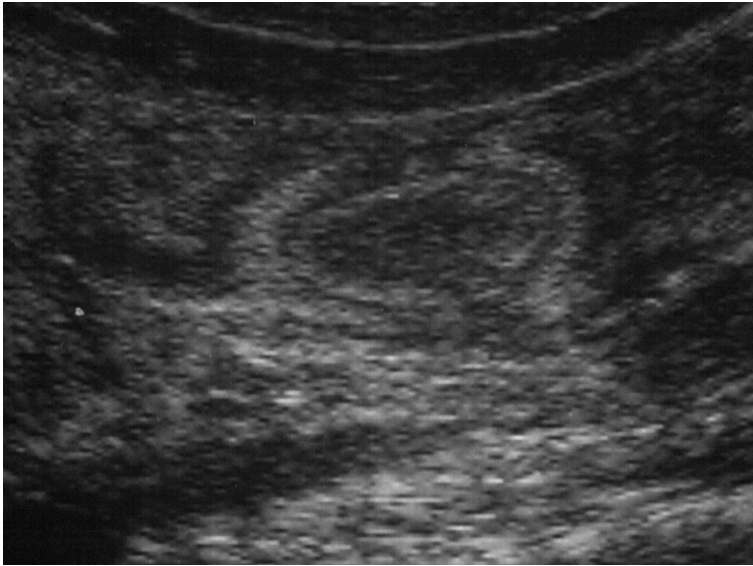
Alvin C. Silva, MD • Sean D. Beaty, MD • Amy K. Hara, MD • Joel G. Fletcher, MD • Jeff L. Fidler, MD • Christine O. Menias, MD • C. Daniel Johnson, MD

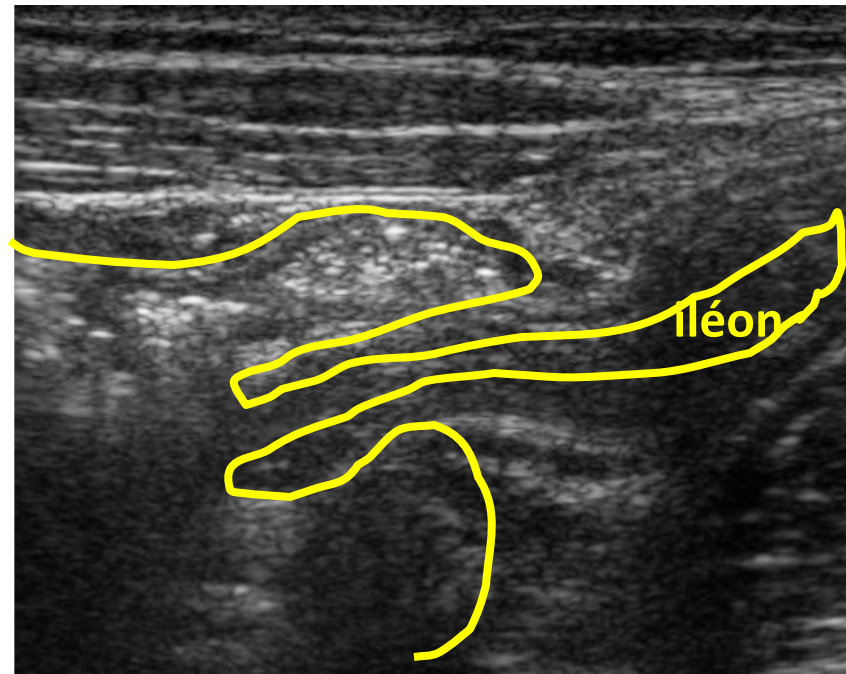
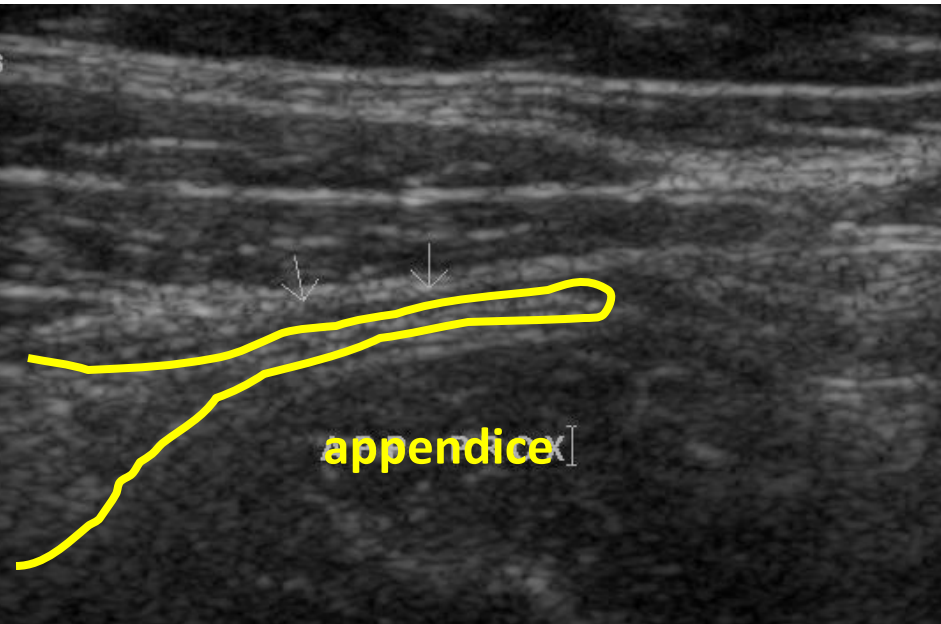



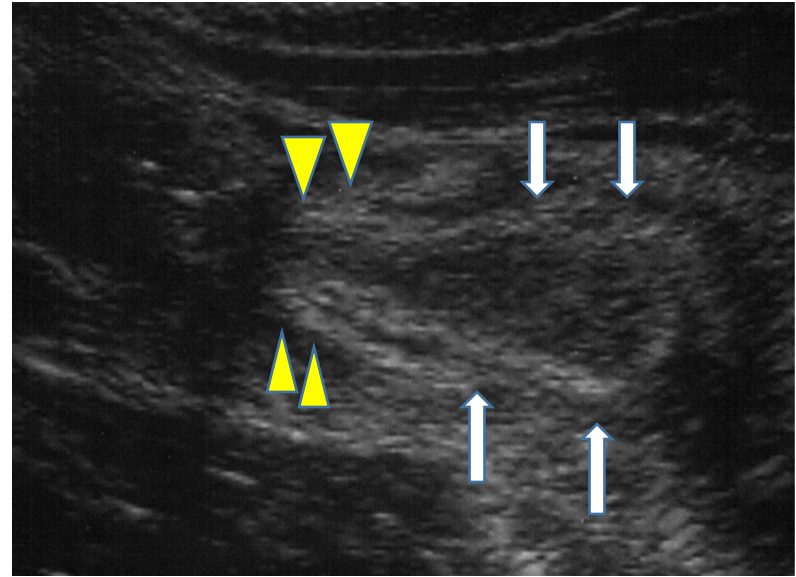
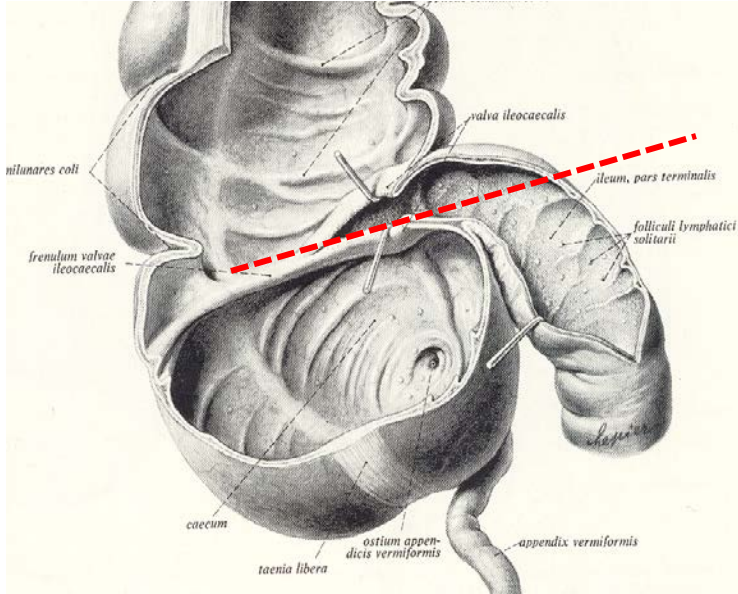


Valvule de Bauhin



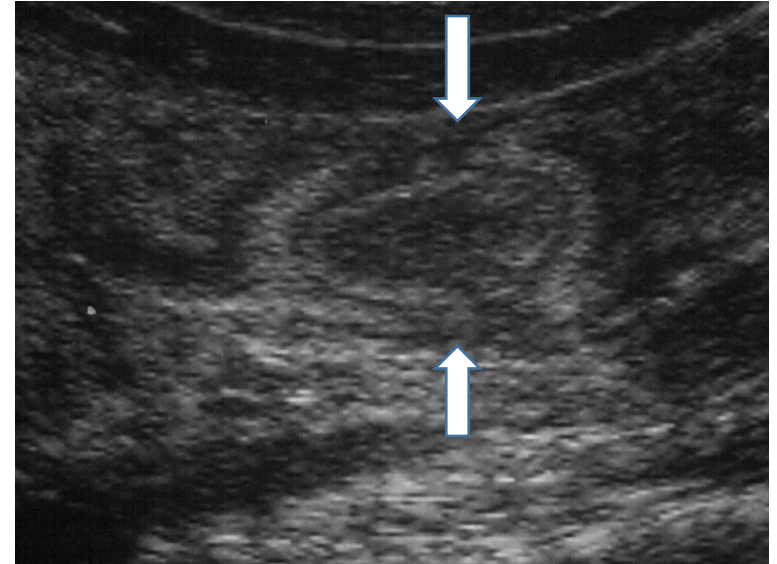
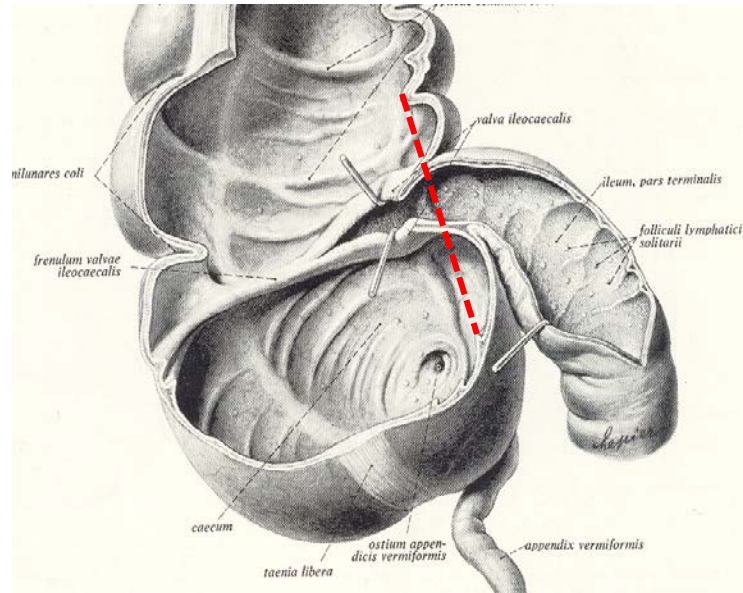




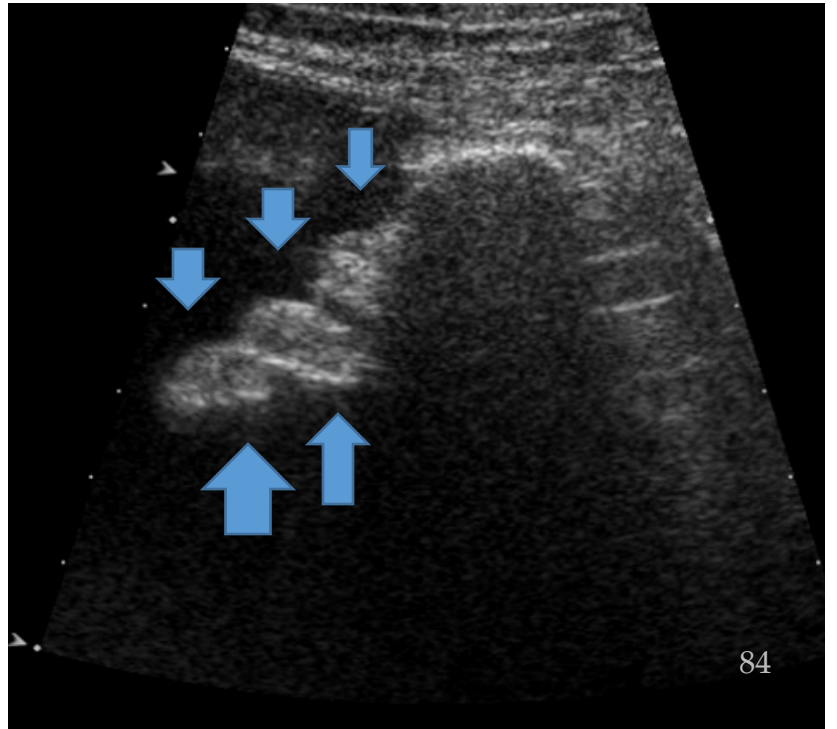
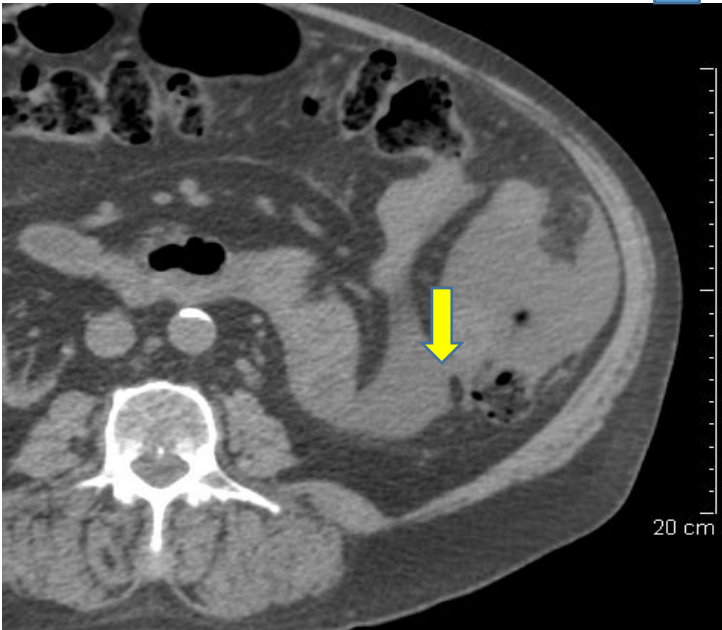
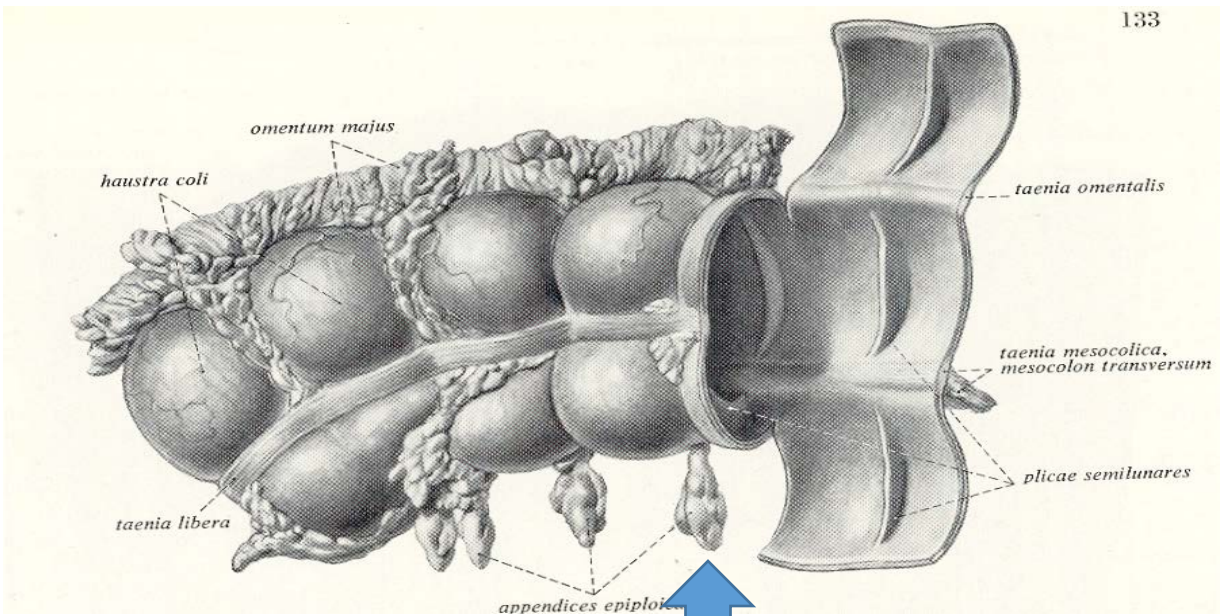


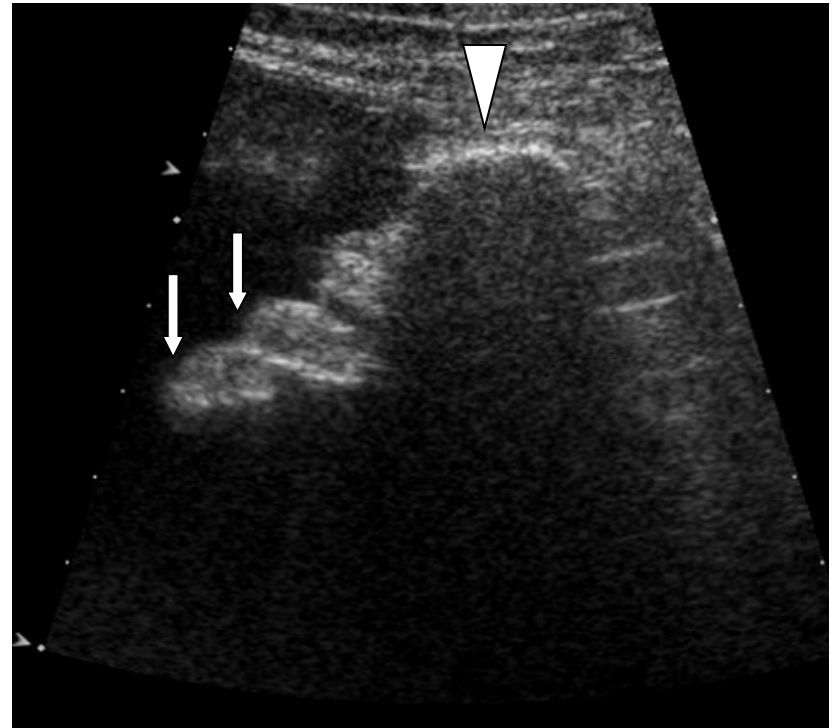
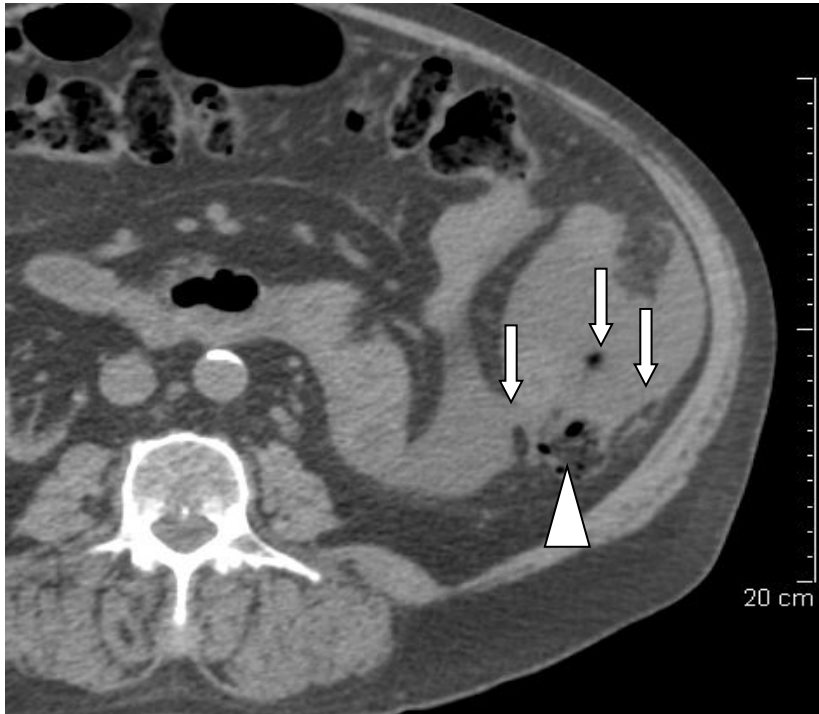
- La valvule de Bauhin, dans son grand axe
- Sur le dessin, le pointillé rouge montre le plan de l'image échographique
 - Sur l'image échographique,
 - les flèches délimitent l'iléon terminal
 - Les têtes de flèche se situent en regard de la valvule de Bauhin

In Kahle et al, Anatomie, 2, Flammarion médecine Sciences, 1979

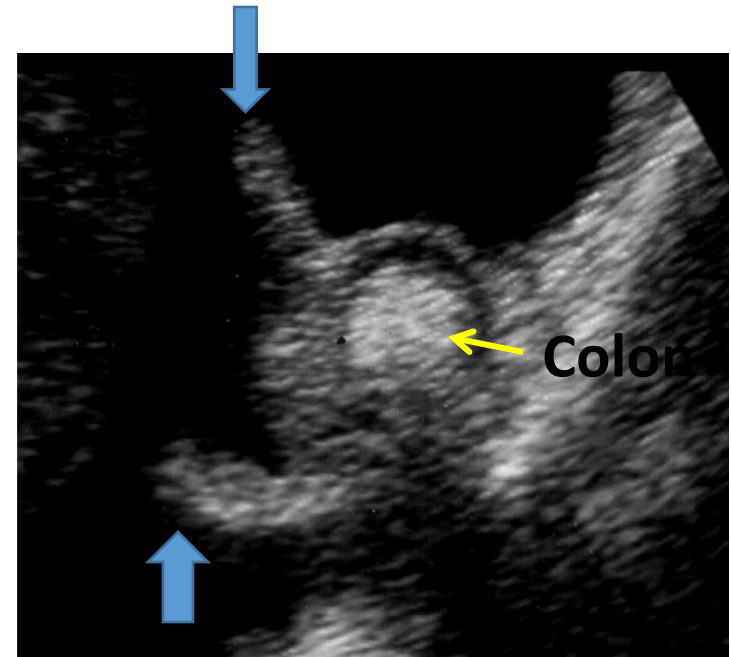
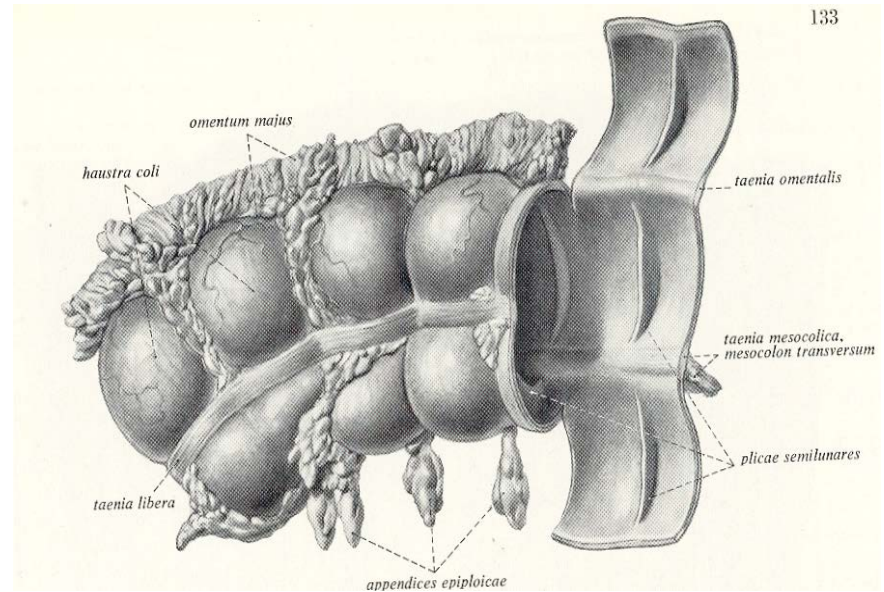
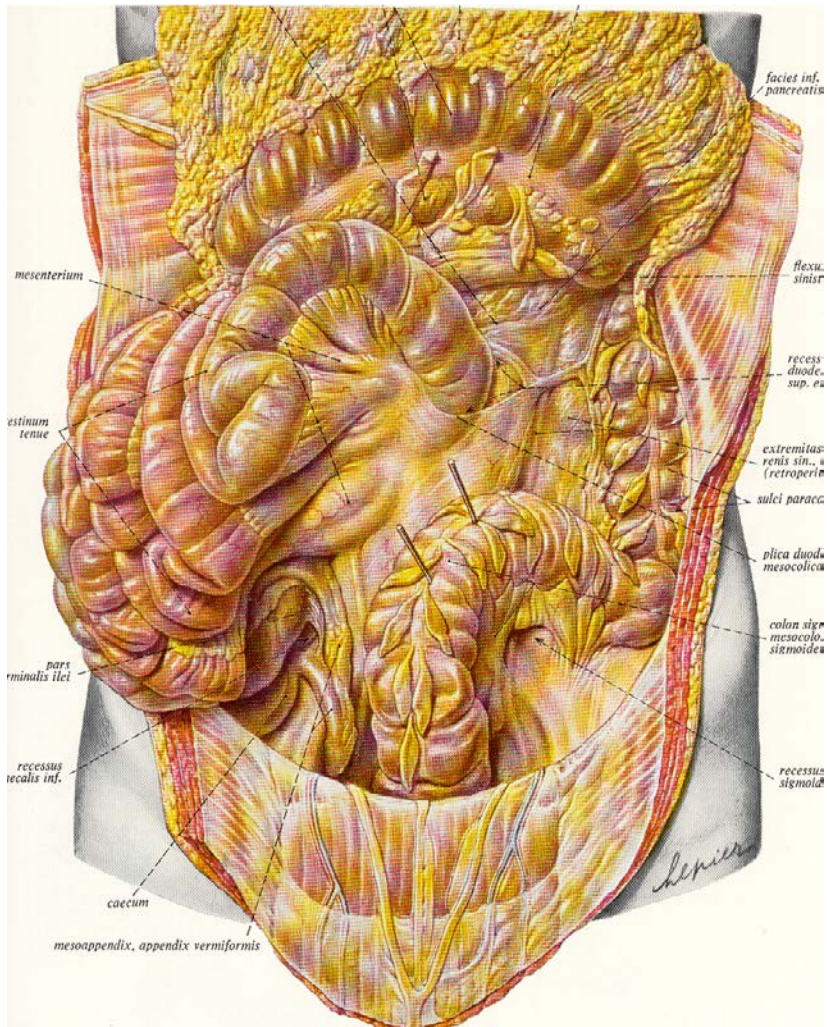


- La valvule de Bauhin, EN COUPE transverse
- Sur le dessin, le pointillé rouge montre le plan de l'image échographique
 - Sur l'image échographique,
 - les flèches délimitent l'iléon terminal





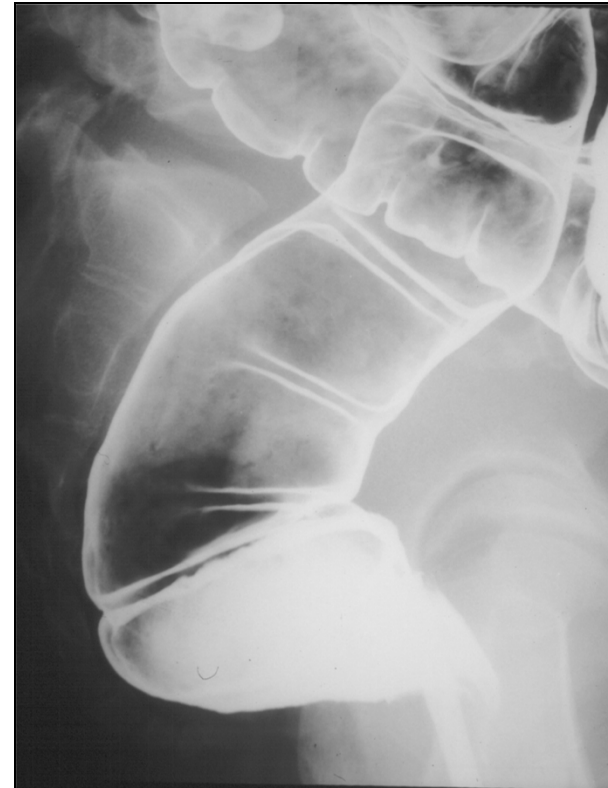
Colon : tête de flèche
Appendice épiploïque : flèches



In Netter, Atlas d'anatomie humaine, Masson, 2007

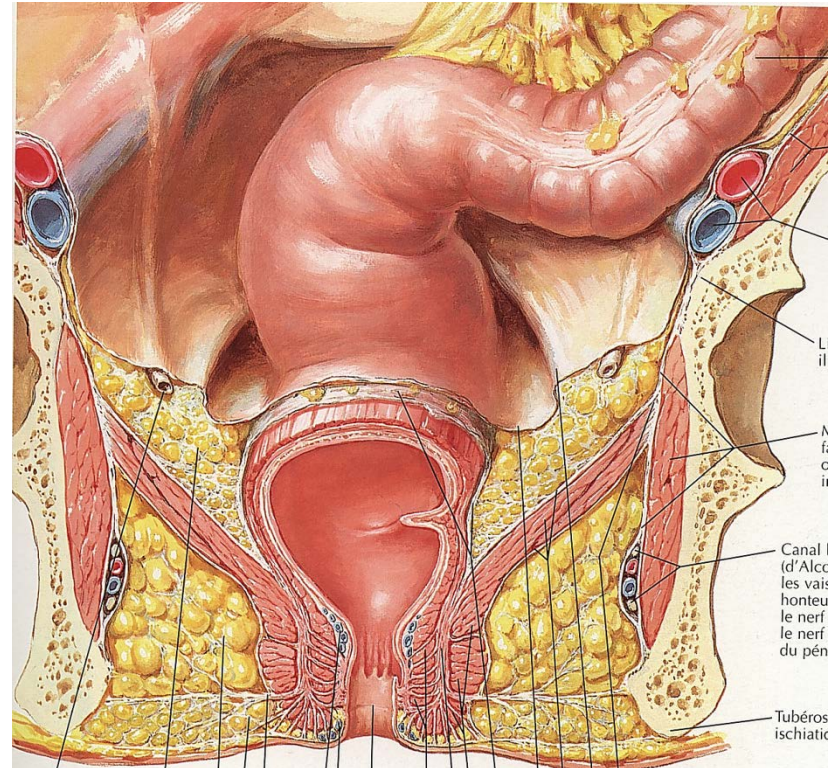
Rectum

- Muscle longitudinal continu
- Incisures : valves de Houston
- Suit la courbure du sacrum : convexité postérieure

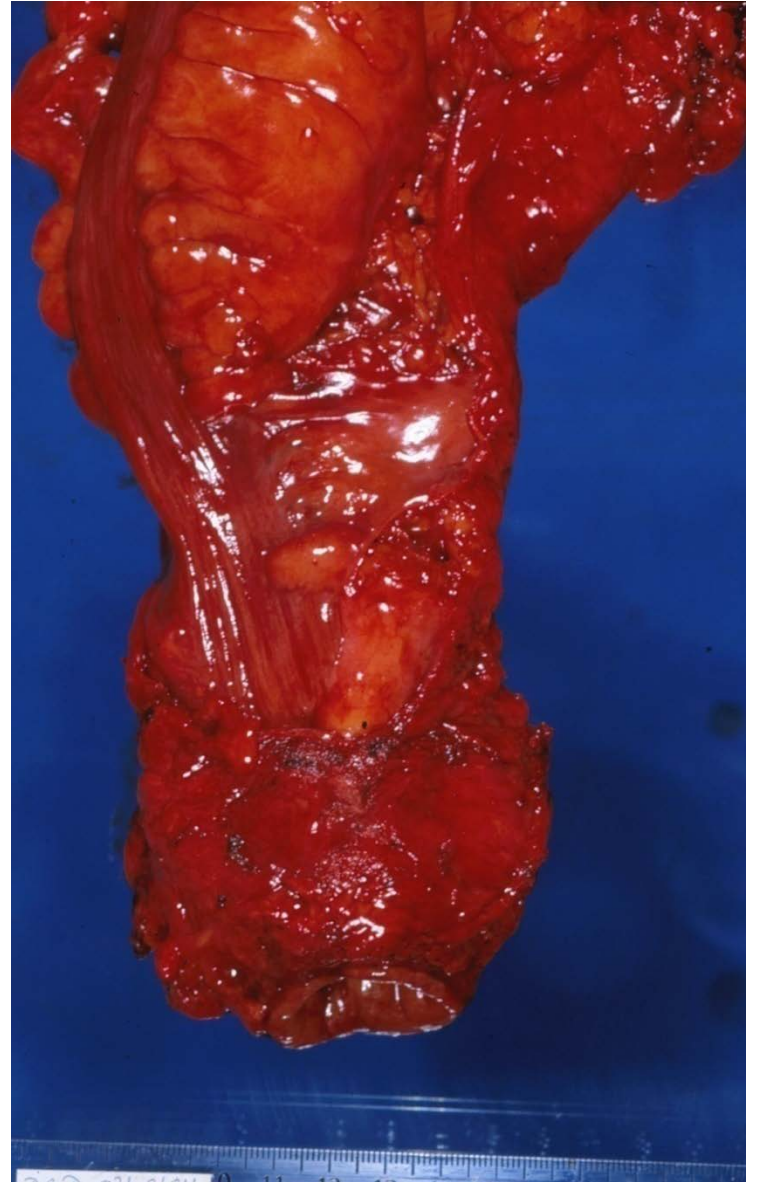
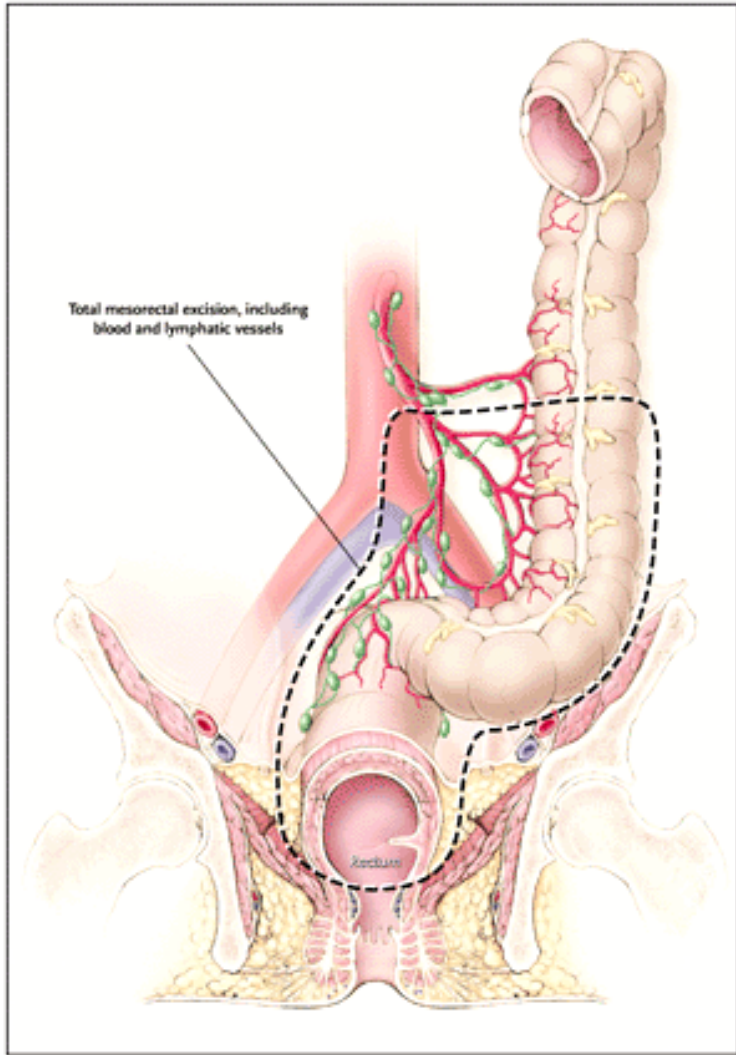


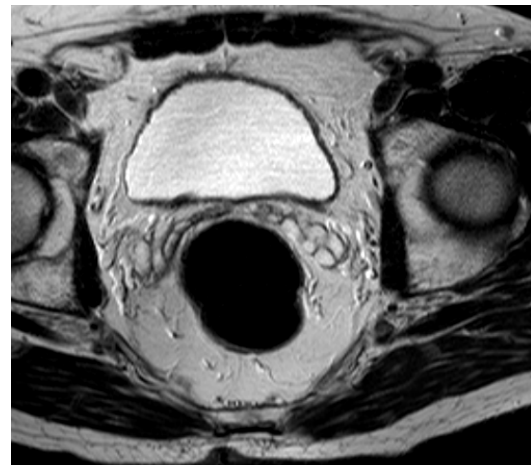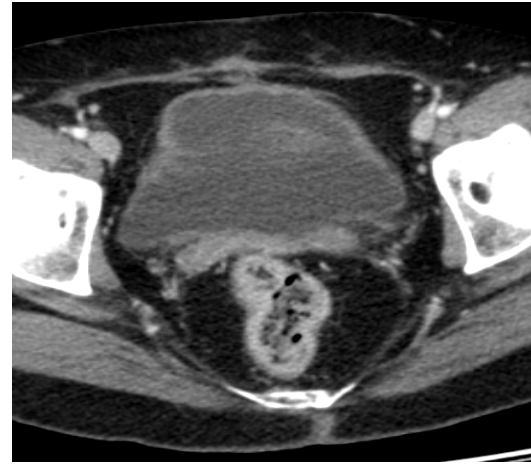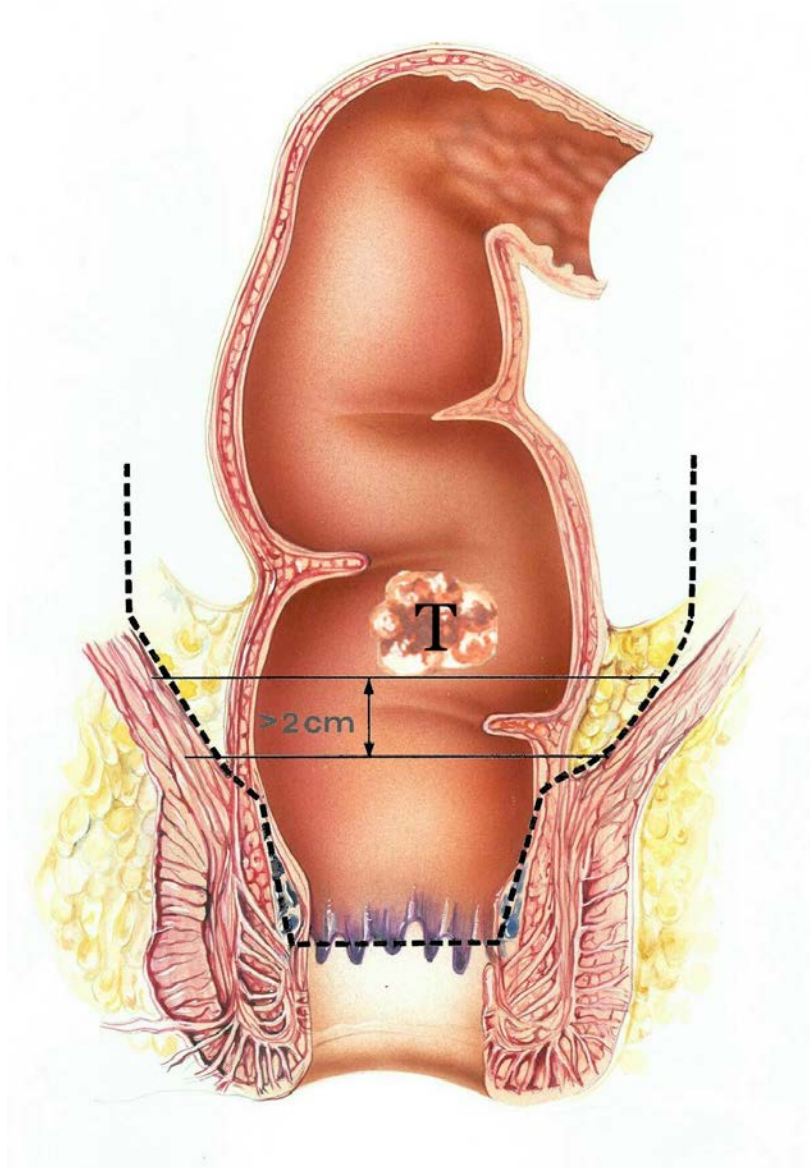
Rectum

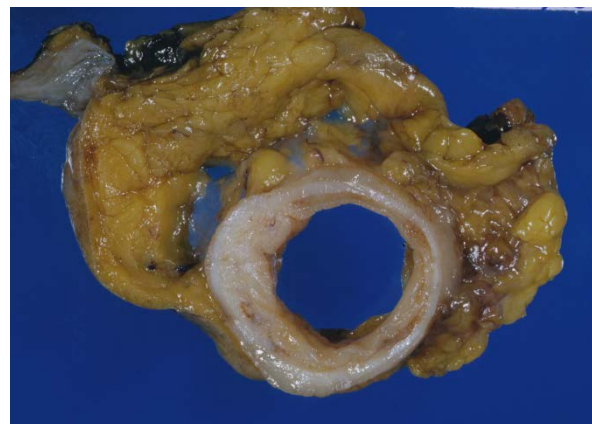
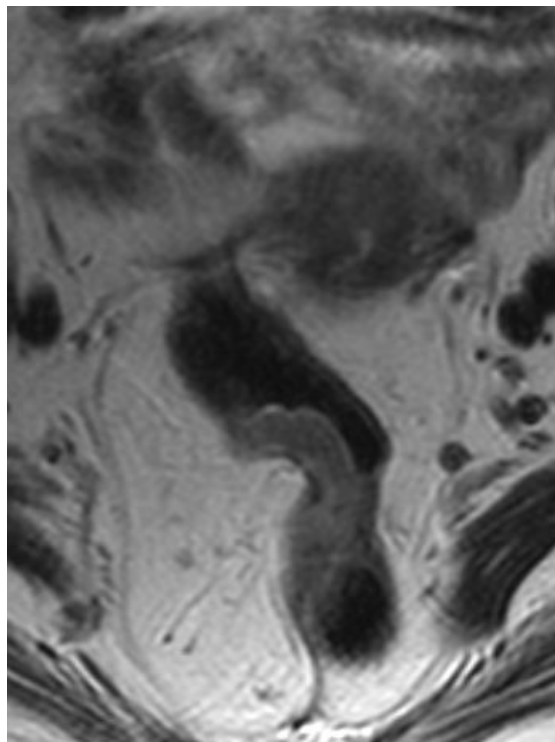
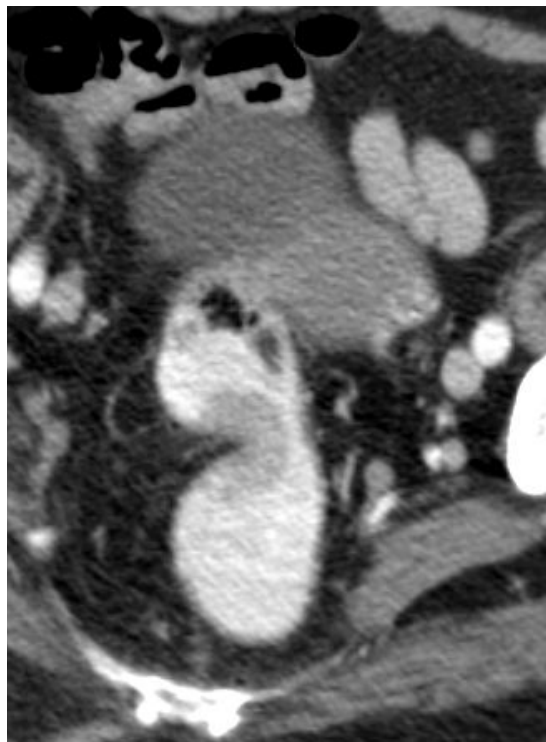
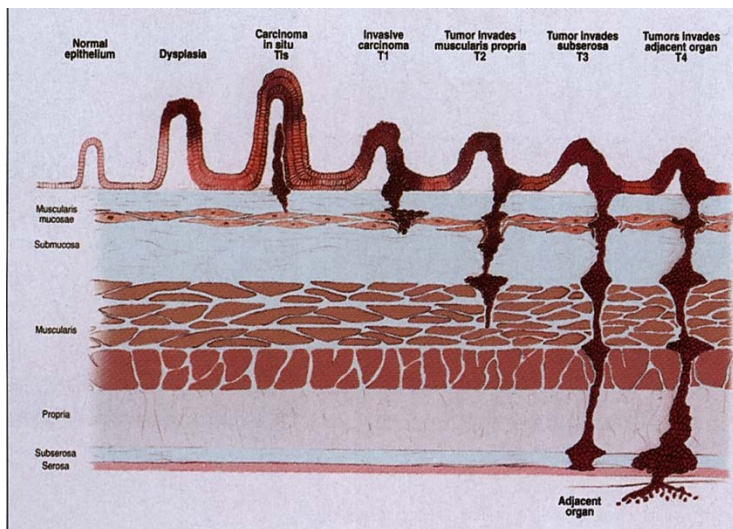
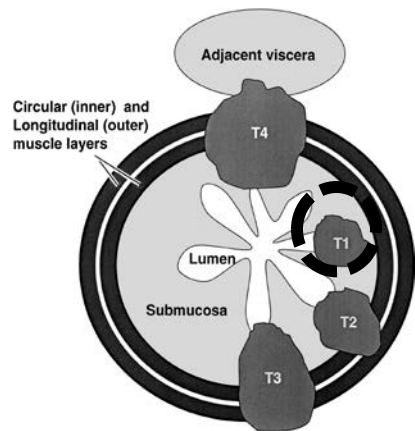
- Définition anatomique : s'étend jusqu'aux valvules anales de Morgagni
- Définition fonctionnelle : s'étend jusqu'au bord supérieur du sphincter externe

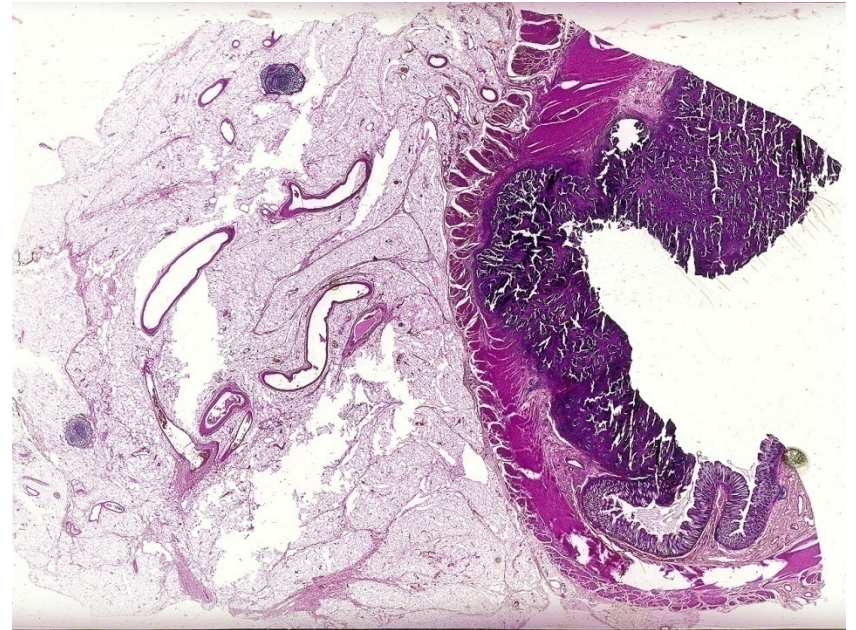
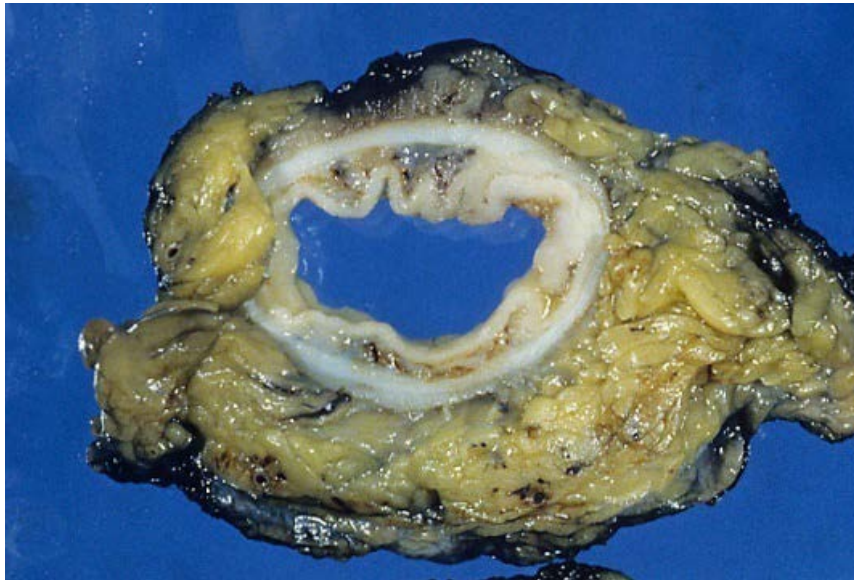
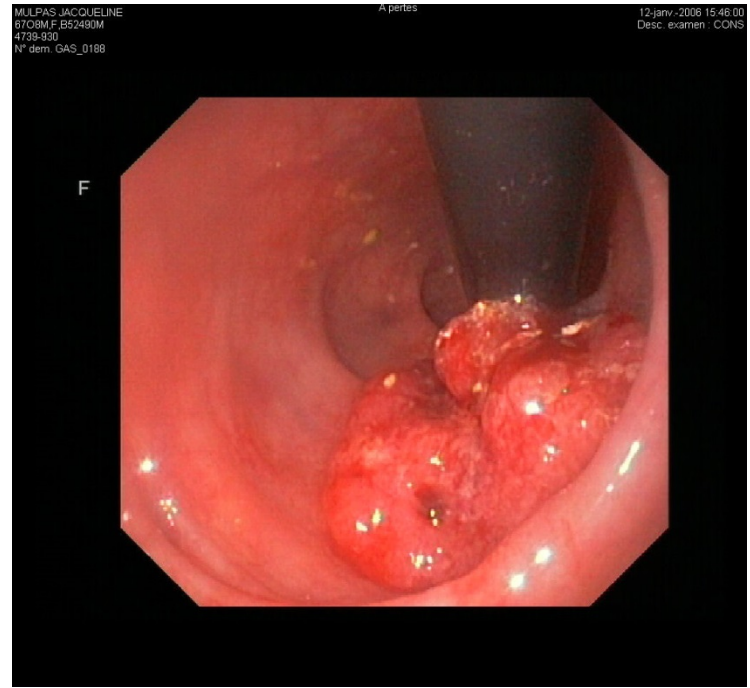
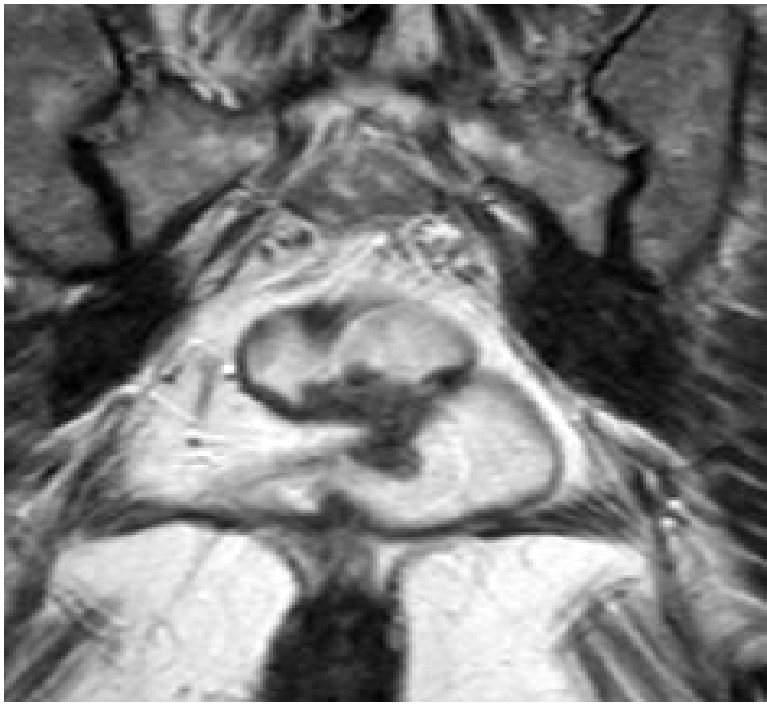

In Netter, Atlas d'anatomie humaine,
Masson, 2007



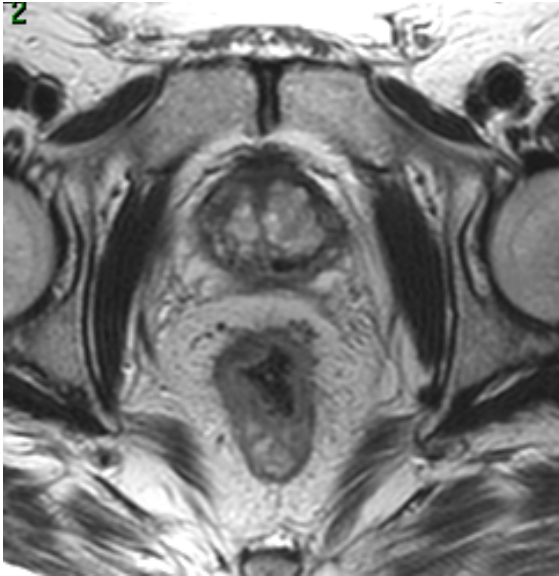



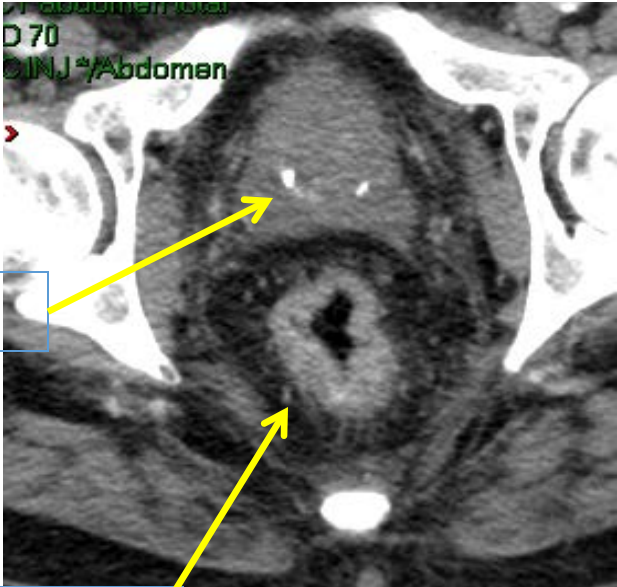


Vue du rectum en CT et en IRM

IRM

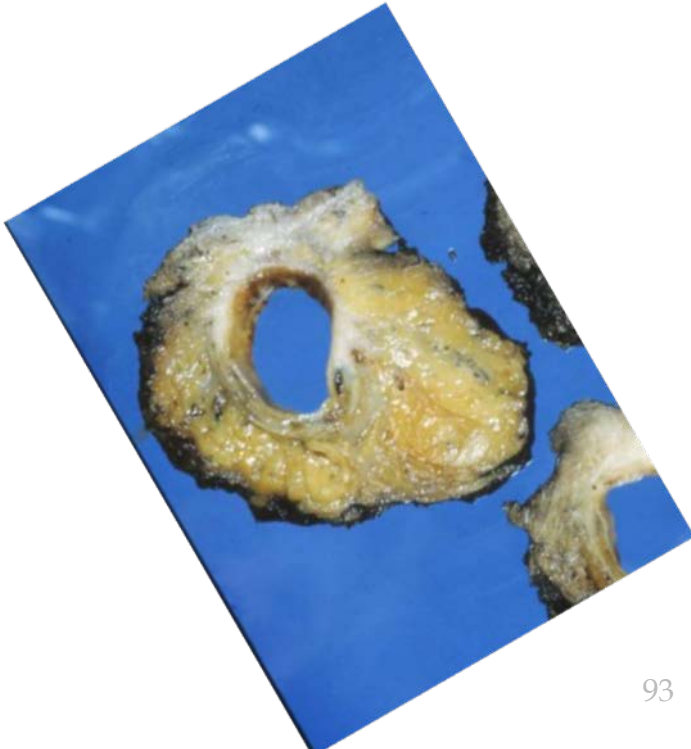


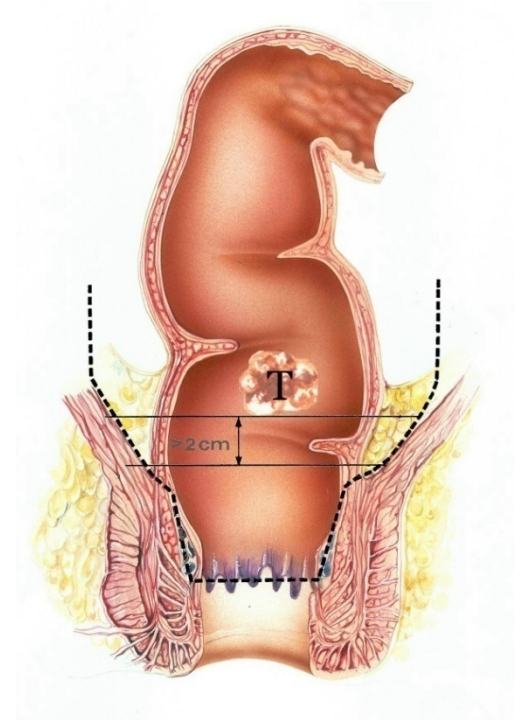
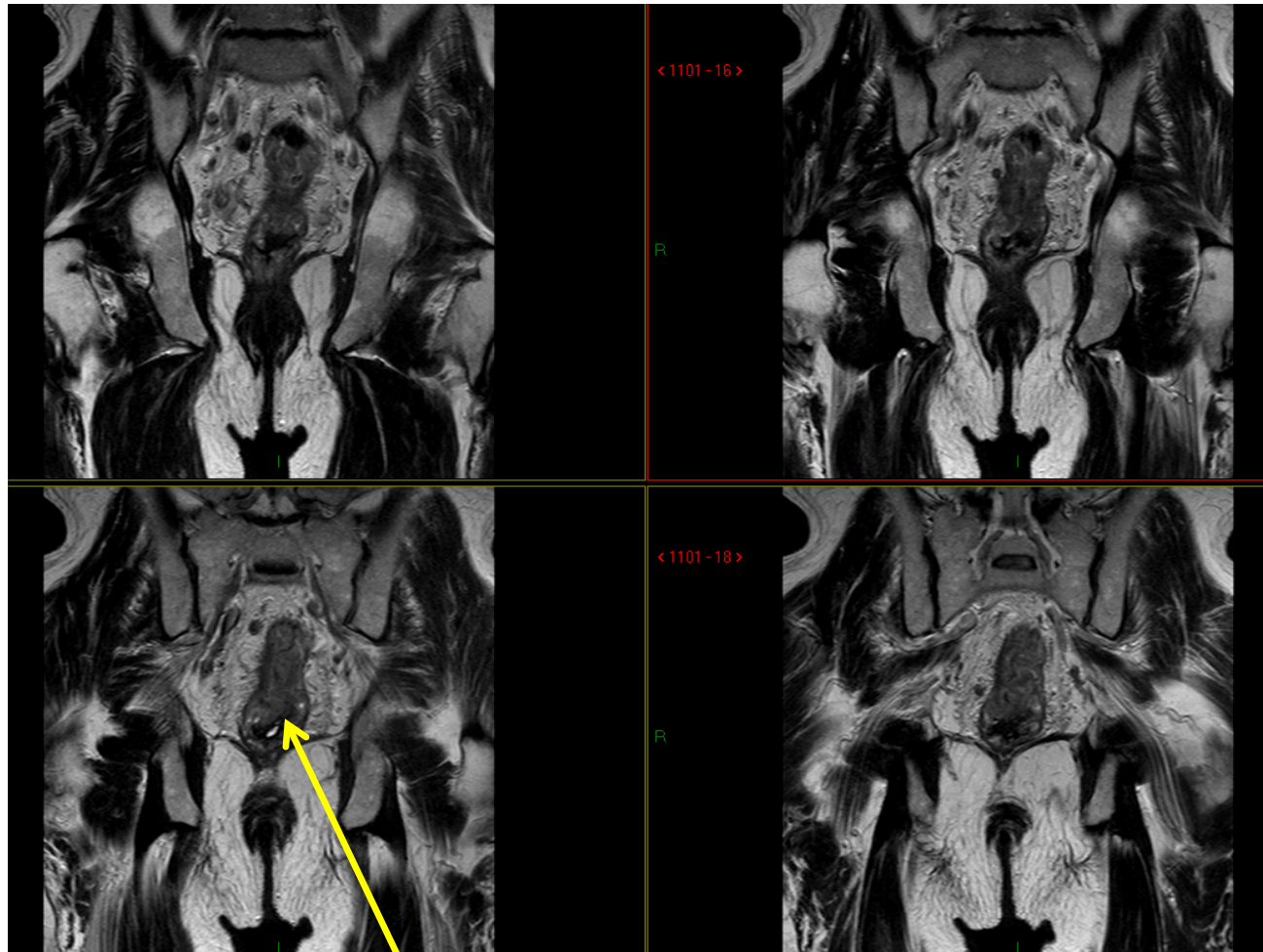
CT



Prostate

Rectum





Rectum en coupe frontale

Canal anal

- Sphincter interne : prolonge le muscle circulaire du rectum
- Sphincter externe : muscle strié
- Canal anal : concavité postérieure

