Cours **RDGN2120** *2021-2022*

Compléments de Neuroradiologie

6ième cours du jeudi 28 octobre 2021 (1)

Imagerie des démences

Dr Thierry Duprez
Professeur Clinique
Chef de Clinique
Université catholique de Louvain
Cliniques universitaires Saint-Luc
thierry.duprez@uclouvain.be
http://www.saintluc.be

Démences dégénératives organiques 'primaires'/'moléculaires'

5.5 millions d'AD aux USA

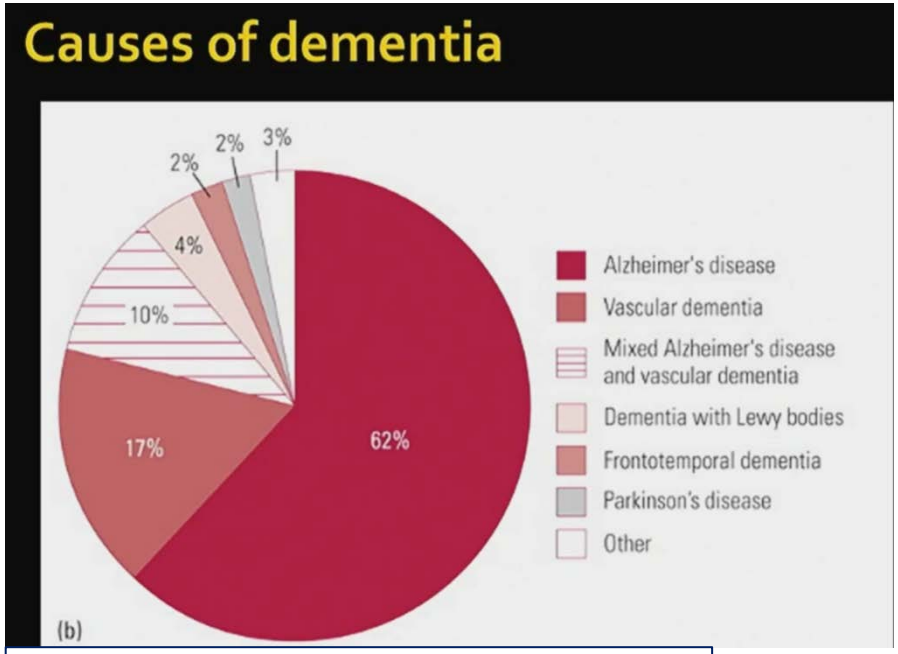

Prépondérance de AD dans les démences dégénératives

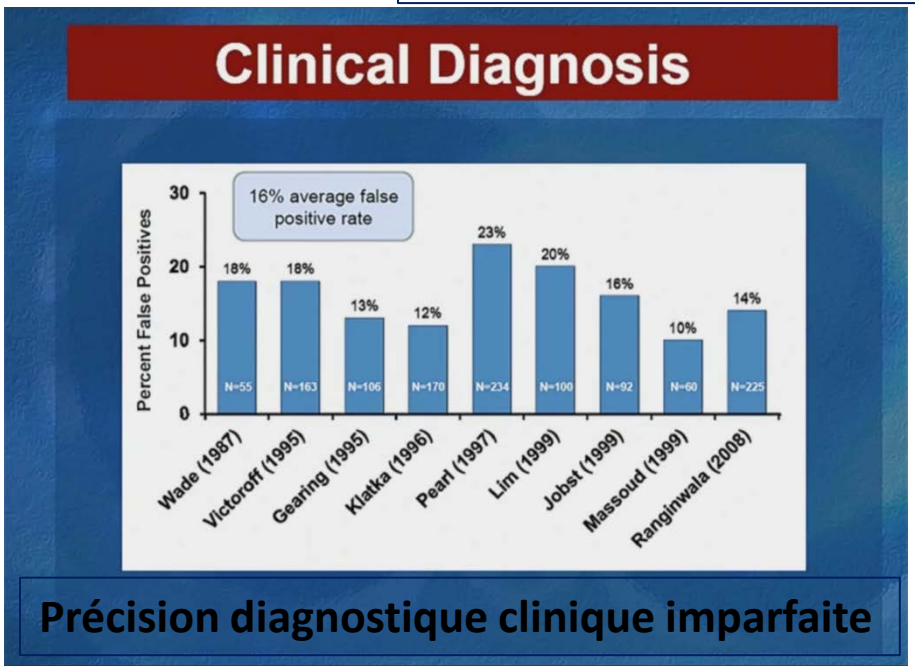

Précision diagnostique clinique imparfaite

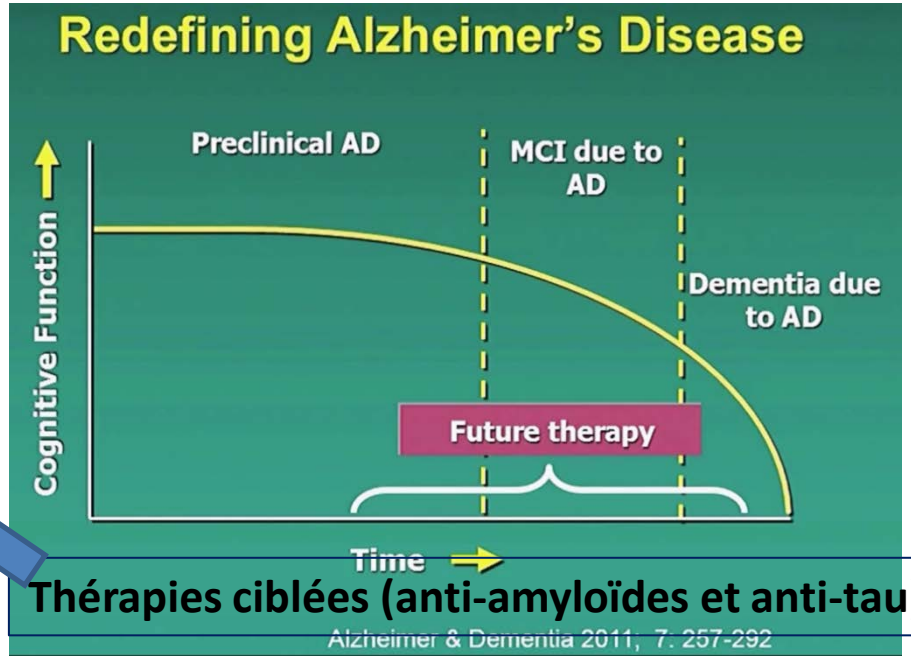

Thérapies ciblées (anti-amyloïdes et anti-tau)

Place pour l'imagerie
- diagnostique
- monitoring de réponse thérapeutique

FDA-approved techniques for imaging dementia

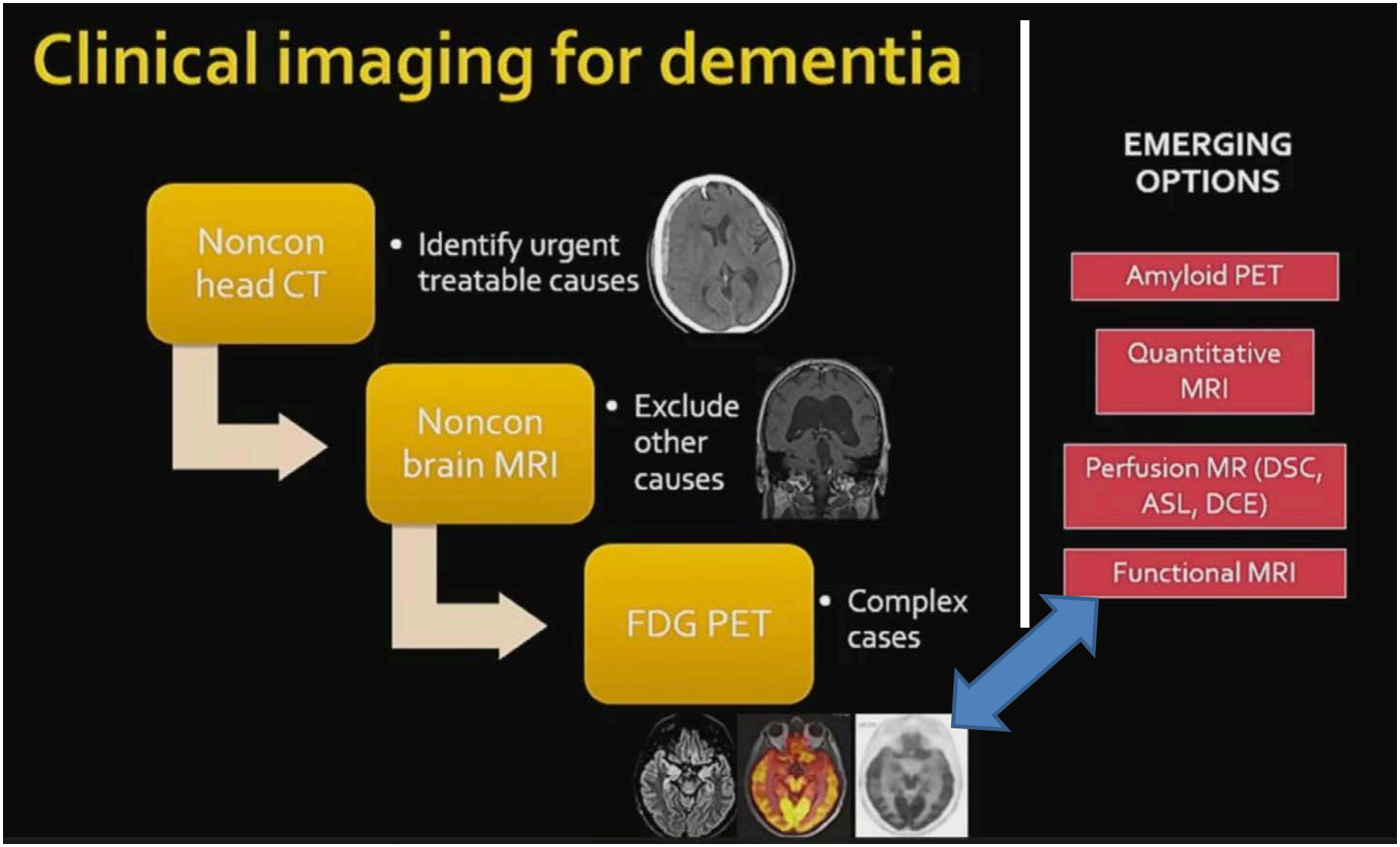

Imagerie morphologique CT/IRM → démences ‘secondaires’

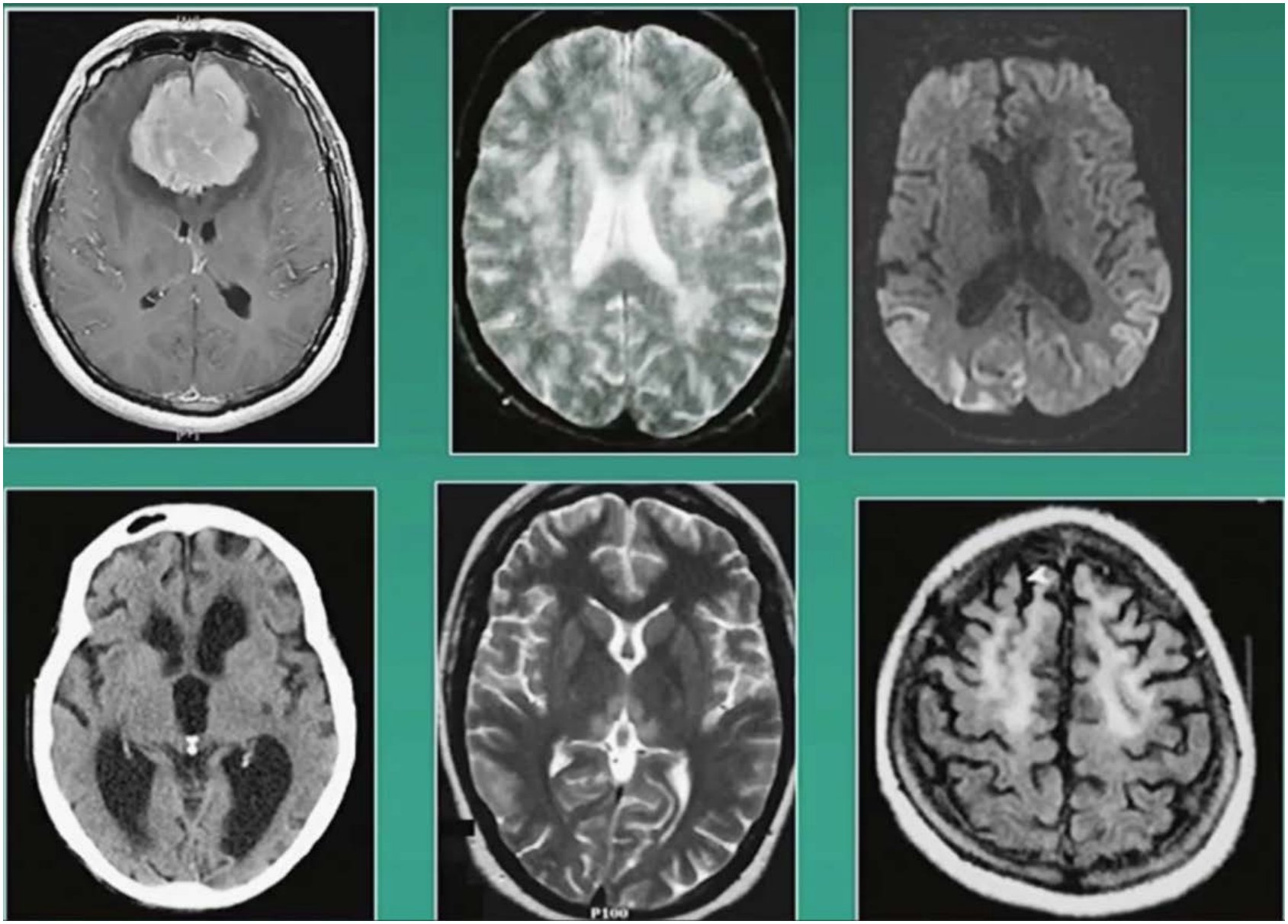

Veillissement cérébral ‘normal’

Petites lésions *aspécifiques* de la SB

- Espaces péri-vasculaires de Virchow-Robin larges
  → LCR

- Leucoaraiose
  → démyélinisation/gliose cicatricielle

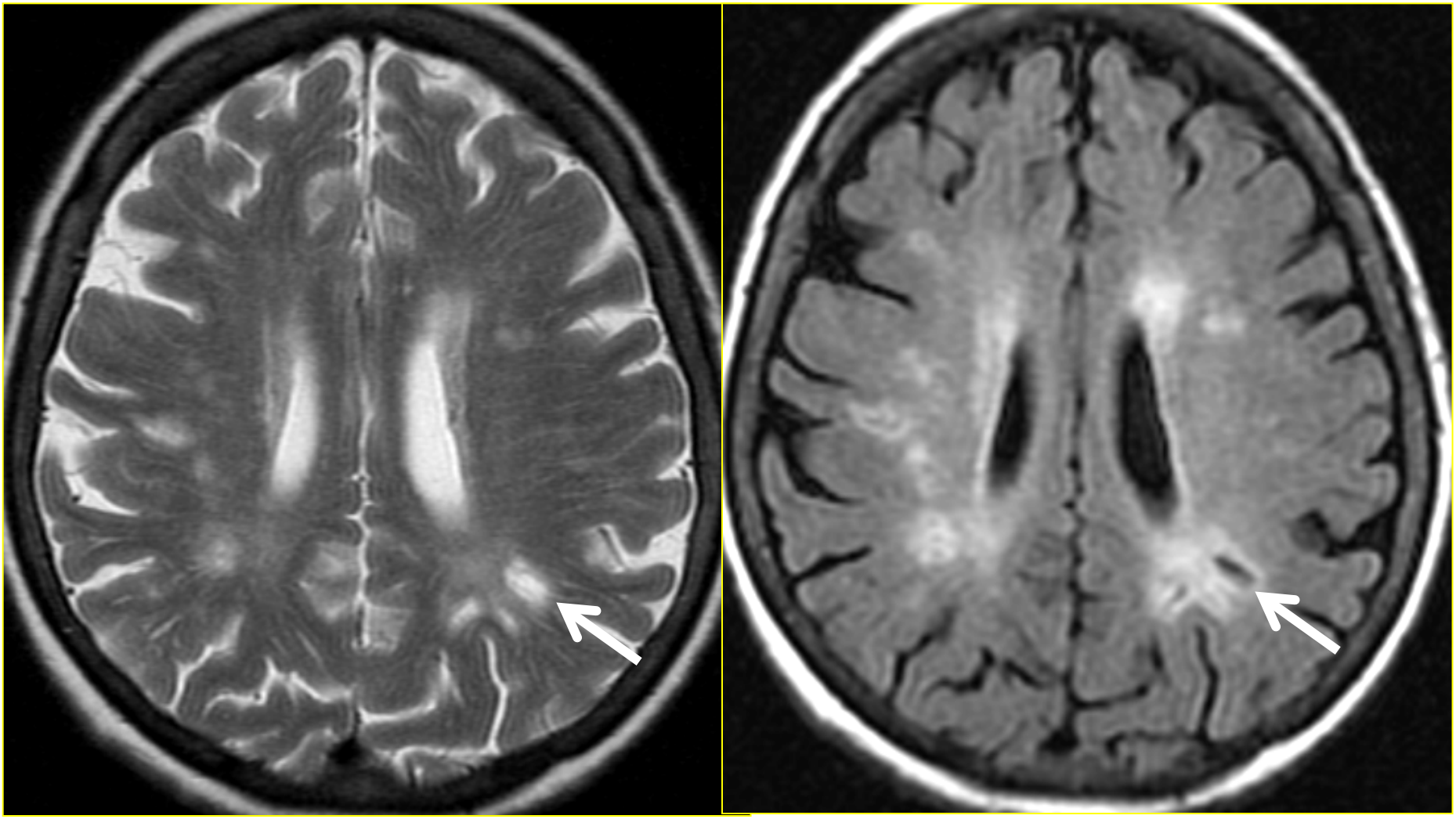

’leucoaraiose’ + 1 EPV de VR

Petites lésions aspécifiques de la SB

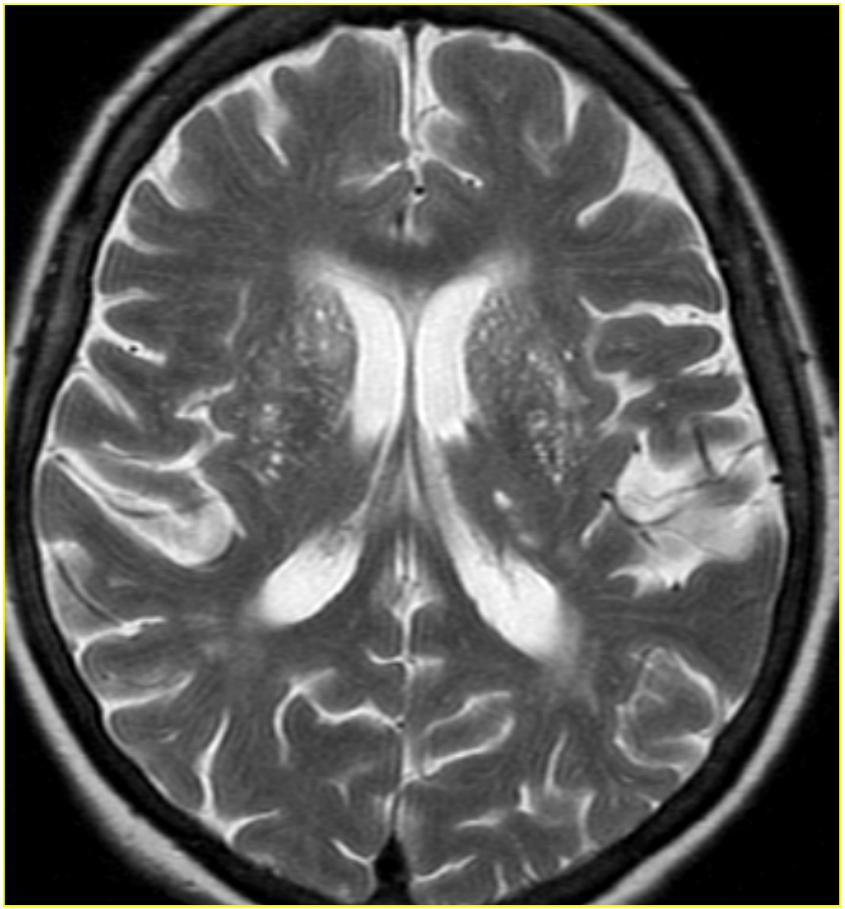

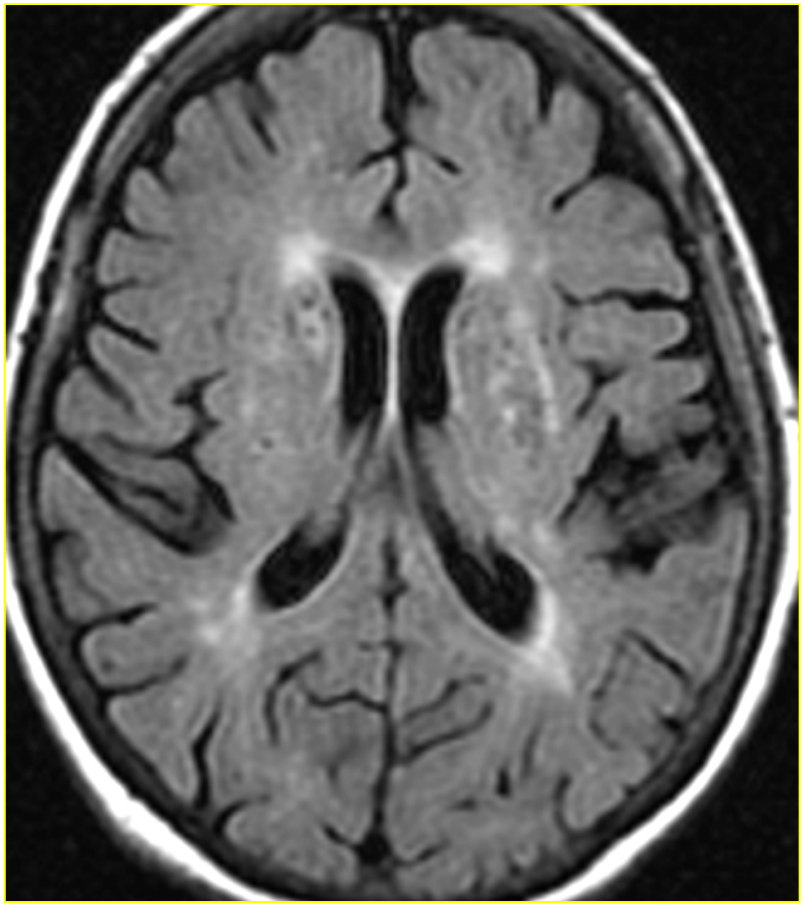

2 types

Blanc-Blanc = gliose

Blanc –Noir = LCR = EPV

Veillissement cérébral

Petites lésions aspécifiques de la SB: *EPV de VR*

Localisations typiques

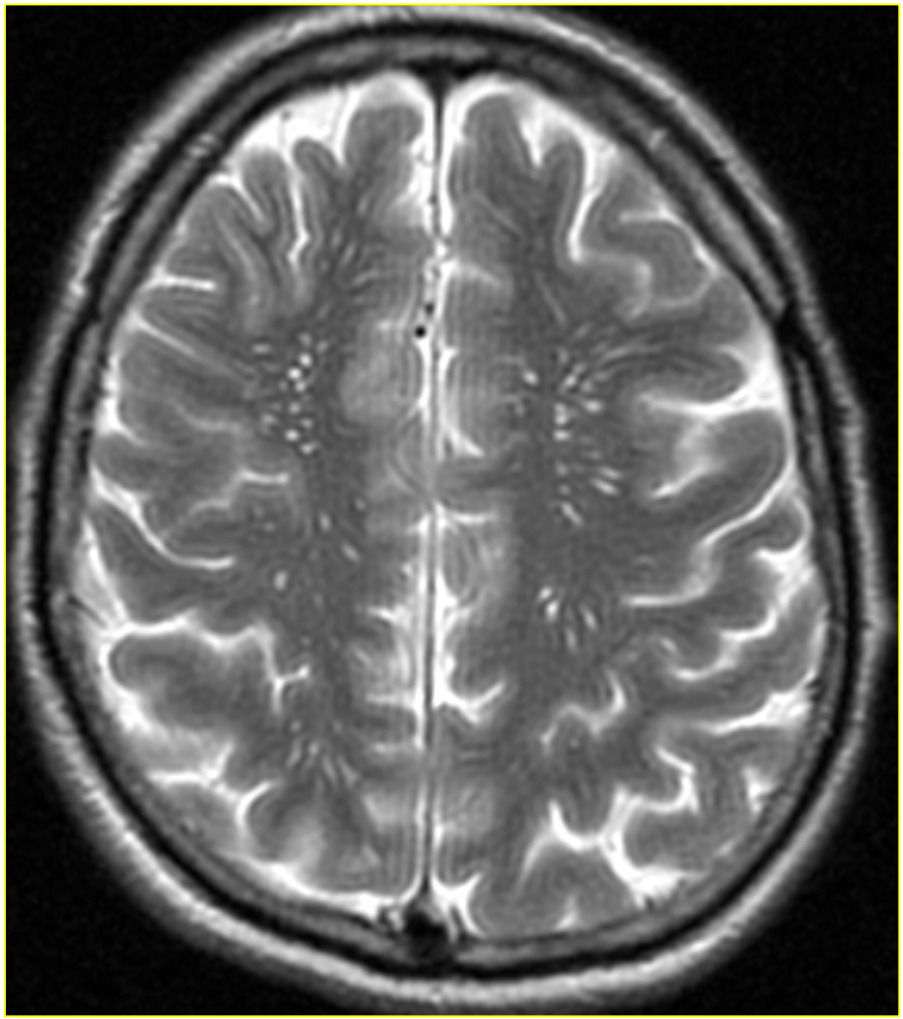

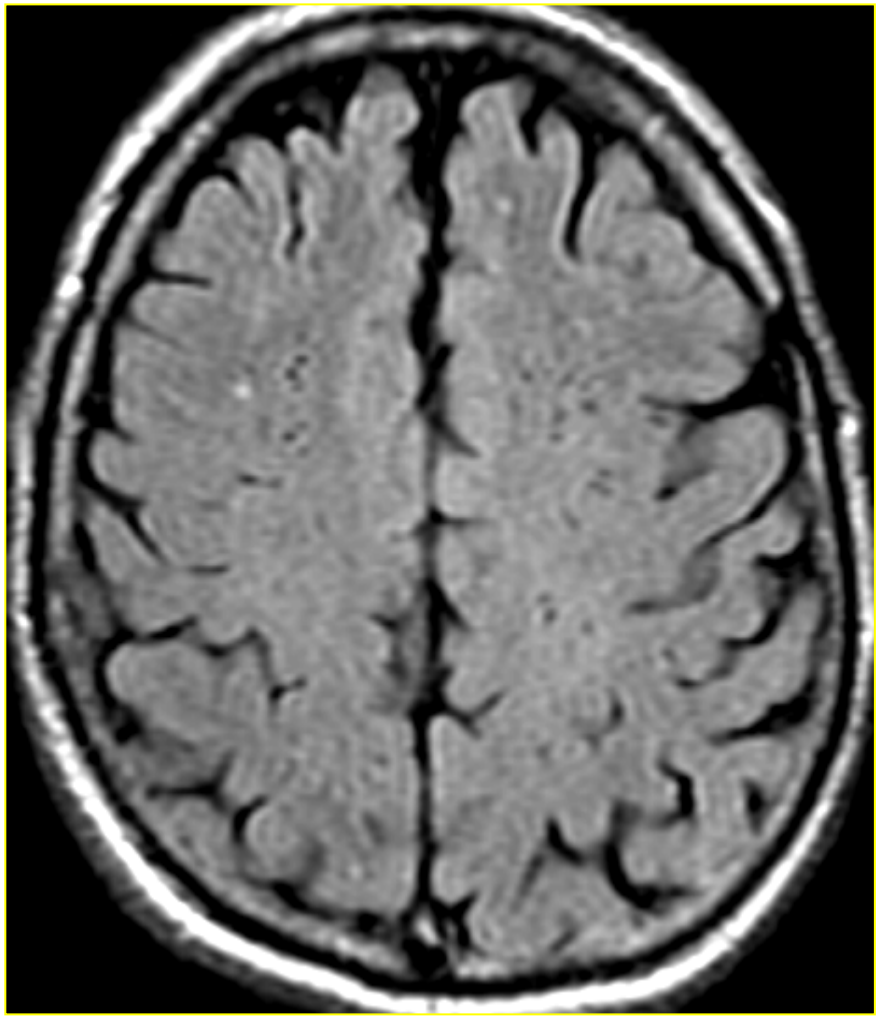

Petites lésions aspécifiques de la SB: *EPV de VR*

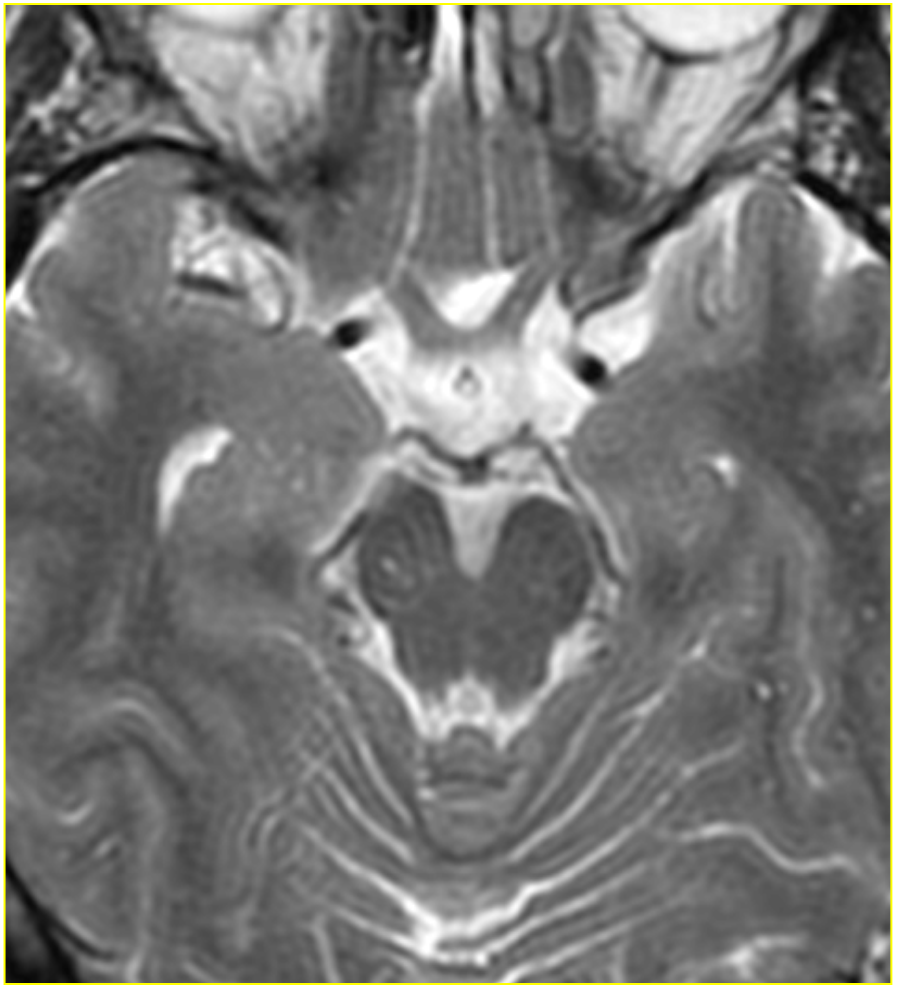

Démence vasculaire leucoaraiosique

La « bande des quatre »

* WMHs

* CAPs

* PV Rim

* EVR larges

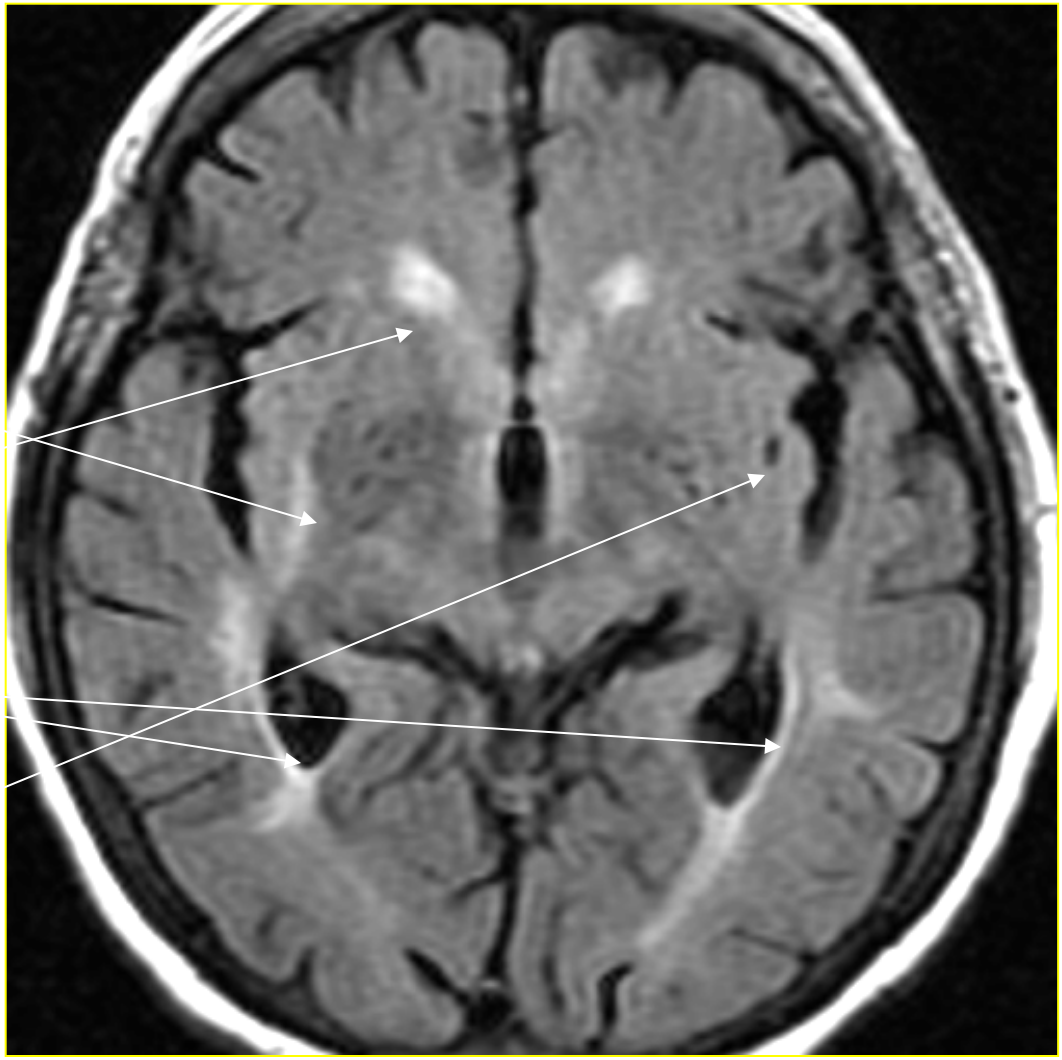

Petites lésions aspécifiques de la SB

* nombre/fréquence étroitement corrélés à l'âge et …

* … aux facteurs de risques vasculaires
  - diabète
  - HTA
  - dyslipidémie
  - maladie cardio-vasculaire

* signification clinique hasardeuse s'agissant des fonctions cognitives

Leucoaraiose….

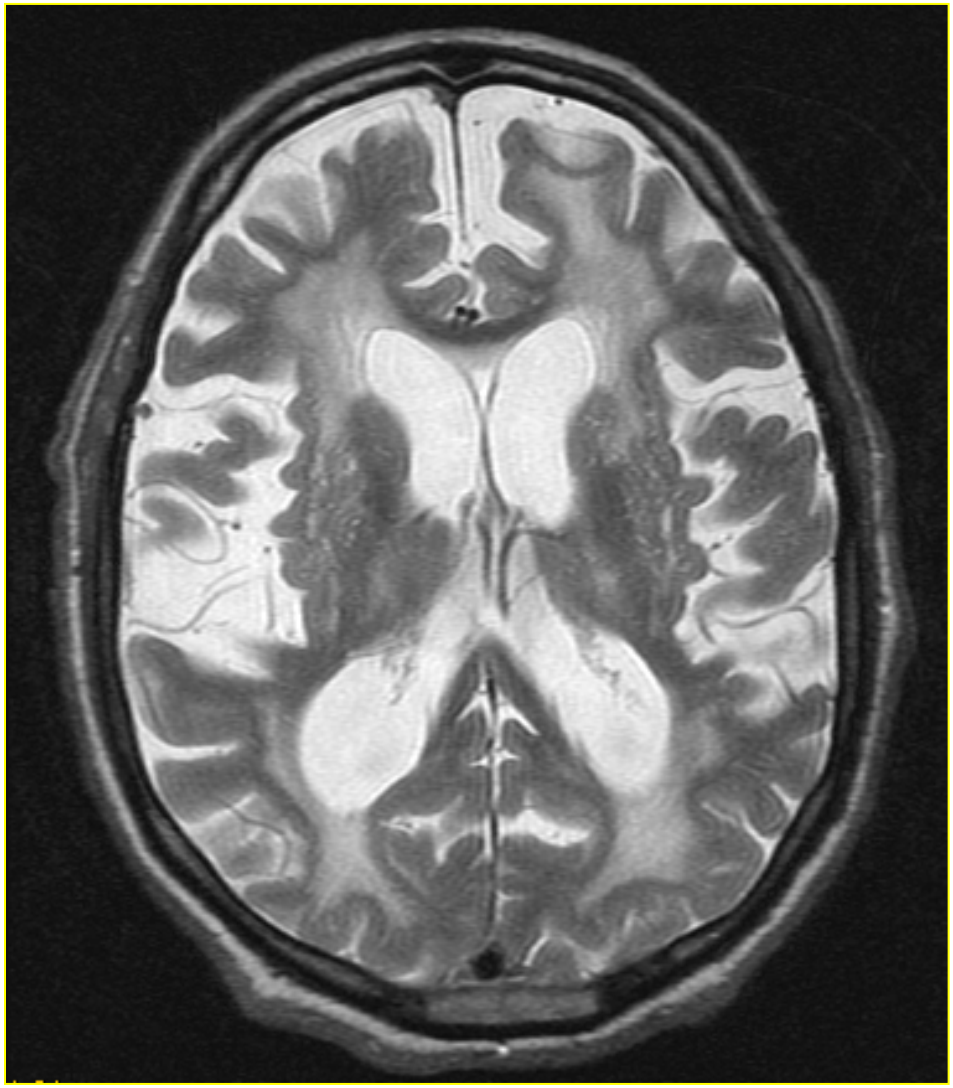

… et atrophie cérébrale

Atrophie cérébrale globale ‘aspécifique’

1. Élargissement des cavités ventriculaires

« hydrocéphalie a vacuo »

2. Approfondissement des sillons de la convexité et des citernes

3. Elargissement des espaces de Virchow-Robin

Atrophie cérébrale globale aspécifique

Notion connexe: vieilles notions sémiologiques
atrophie ***corticale***, ***sous-corticale*****,** et ***cortico-sous-corticale***

1. Elargissement comparable des sillons de la convexité et des ventricules
   = atrophie « globale » ou « **cortico-sous-corticale** »

2. Elargissement excessif des sillons par rapport aux ventricules
   = atrophie « **corticale** »

3. Elargissement minime des sillons par rapport aux ventricules
   = atrophie « **sous-corticale** »

Hydrocéphalie normo-tensive vs ***'atrophie sous-corticale'***

1. Cavités ventriculaires (très) larges
2. Sillons de la convexité normaux ou légèrement aplatis
3. Modifications sous-épendymaires accentuée, non transsudatives
4. Troubles de pulsation du LCR (turbulences)

= diagnostic radiologique probabiliste, de <u>compatibilité</u> avec le diagnostic

PIC 24(48) heures / triple PL

hydrocéphalie normo-tensive

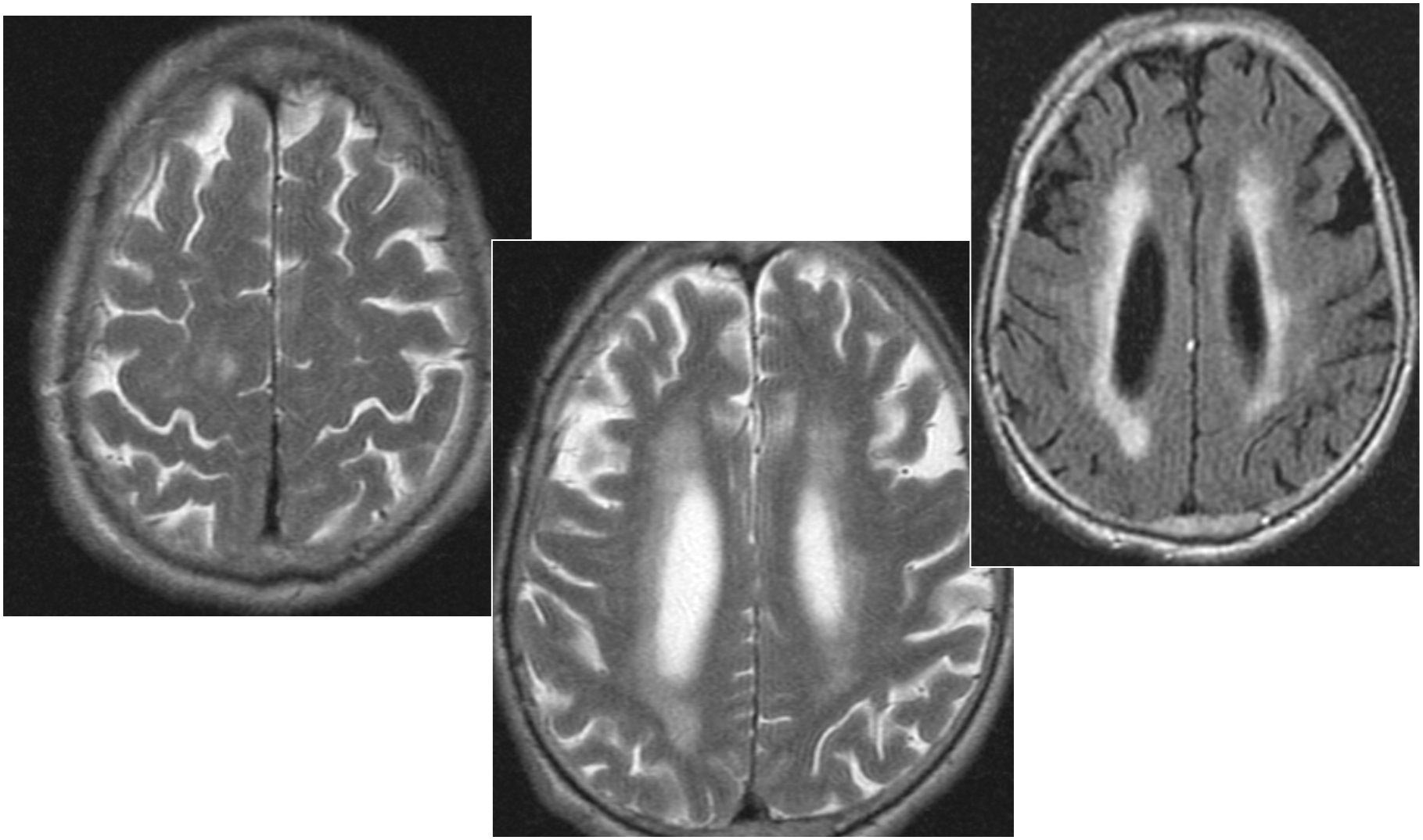

hydrocéphalie normo-tensive

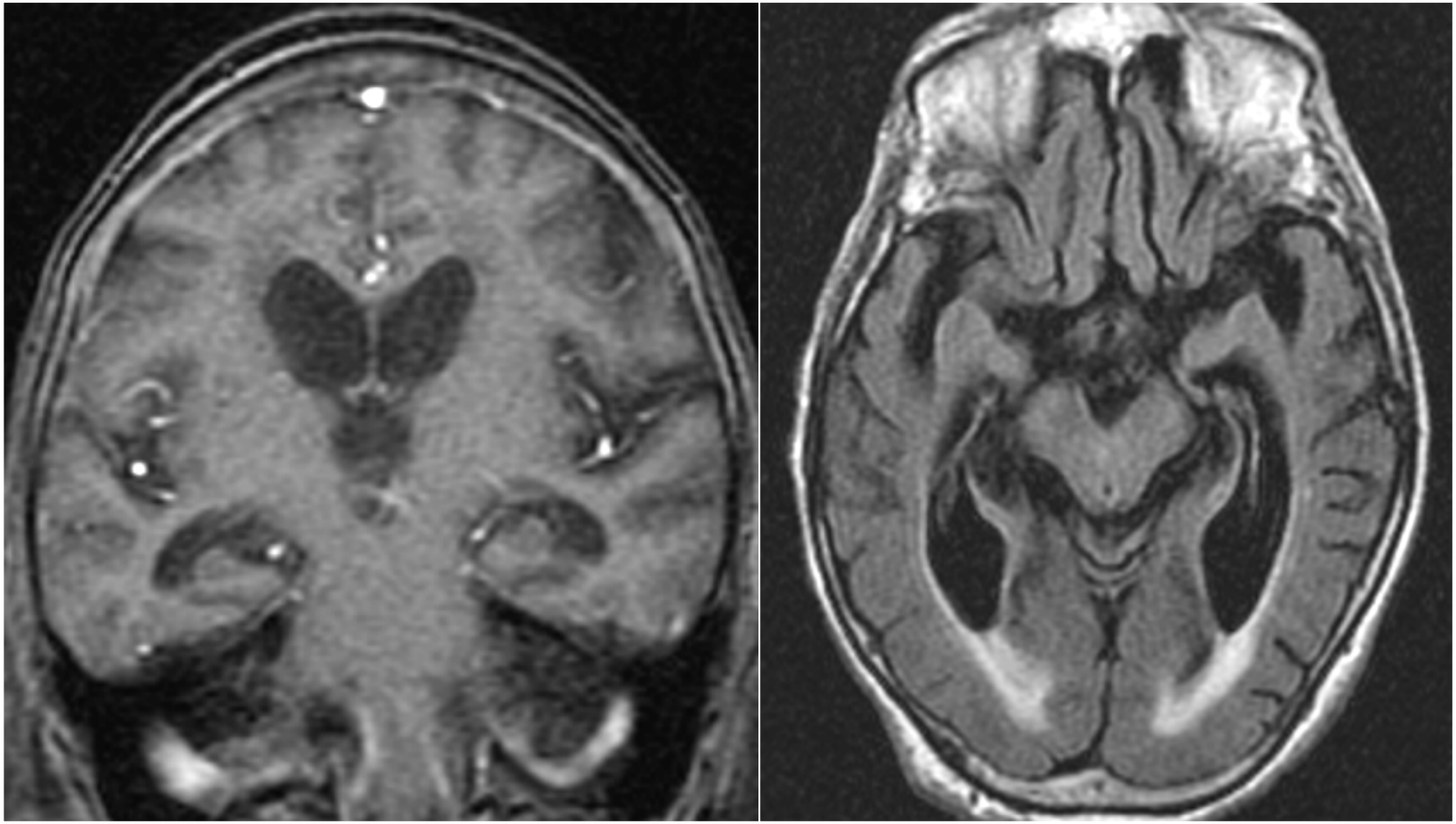

Triade de HAKIM (1965)

-trouble de la marche astasie-abasie
-incontinence urinaire
-démence progressive

« Démence curable »

Tests diagnostiques:
-PL: pression normale
-Tap test: amélioration à la soustraction de 30-50 ml de LCR
-PIC de 24 heures

Bénéfice sur la démence: 25-80%

Désordres neuro-dégénératifs acquis de la substance grise

1. Maladie d ’Alzheimer

* souvent une *atrophie cérébrale globale*, aspécifique

* parfois une *atrophie lobaire préférentielle* au niveau des lobes *temporaux*, surtout les régions hippocampiques

* dans les examens sériels, une vitesse d’atrophie plus rapide

1. Atrophie temporale bilatérale

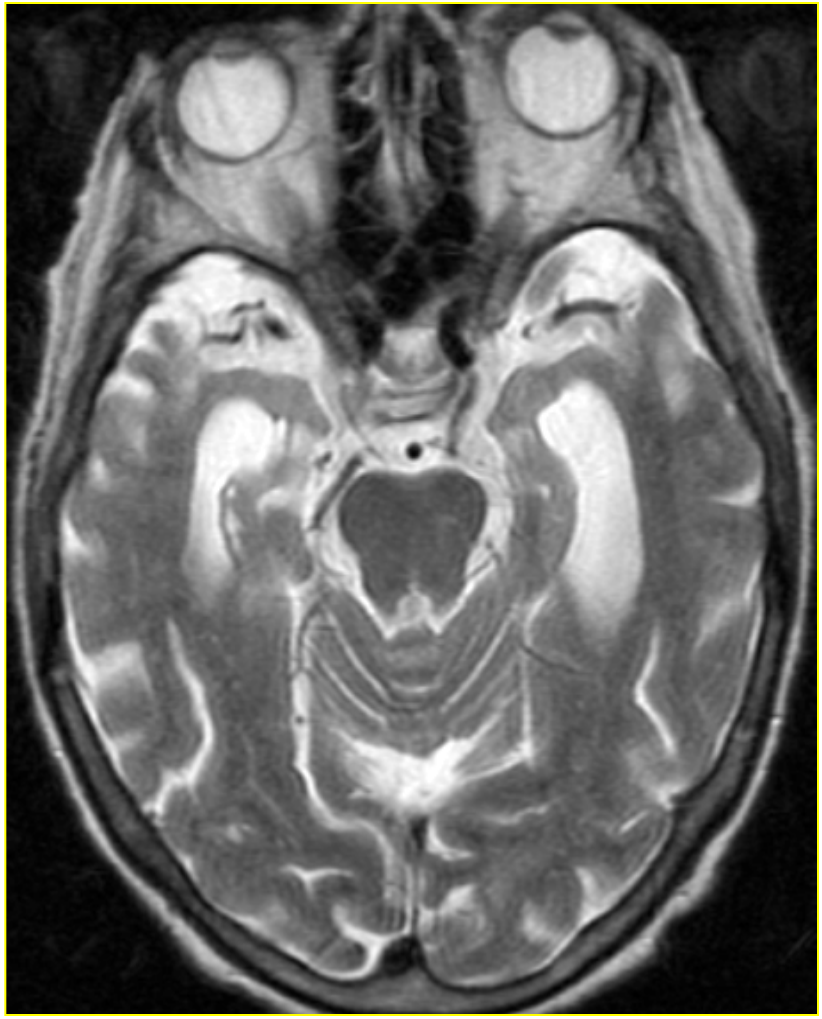

1. Atrophie temporale bilatérale

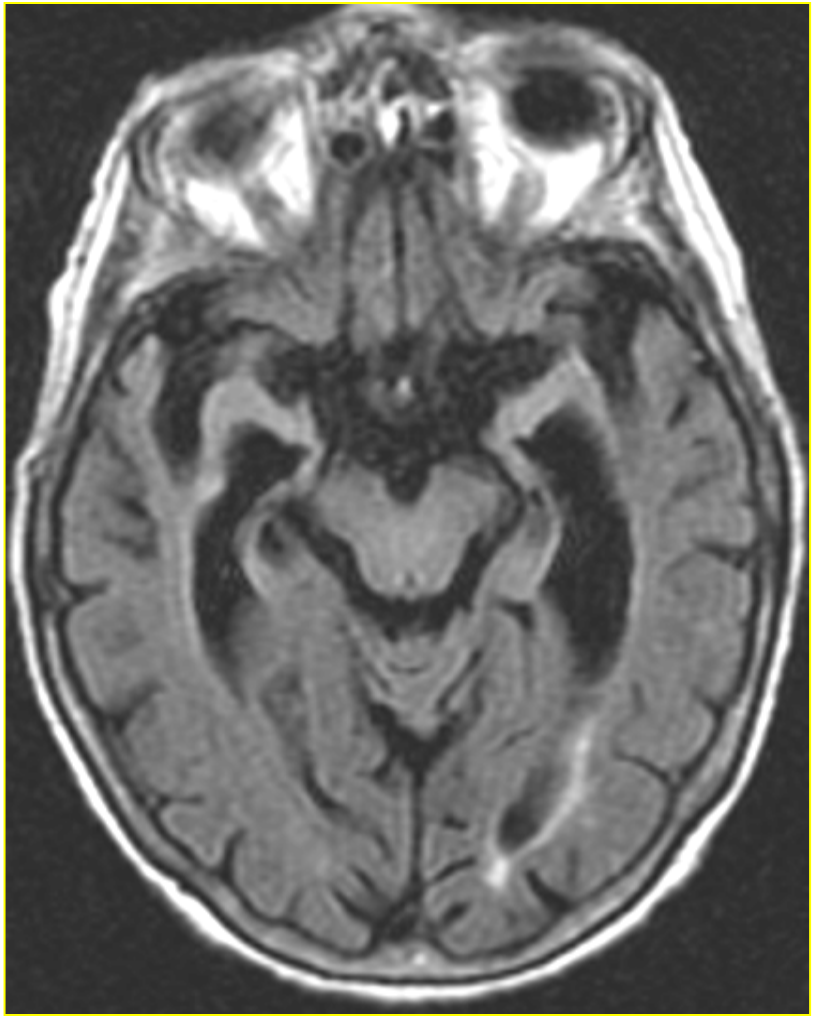

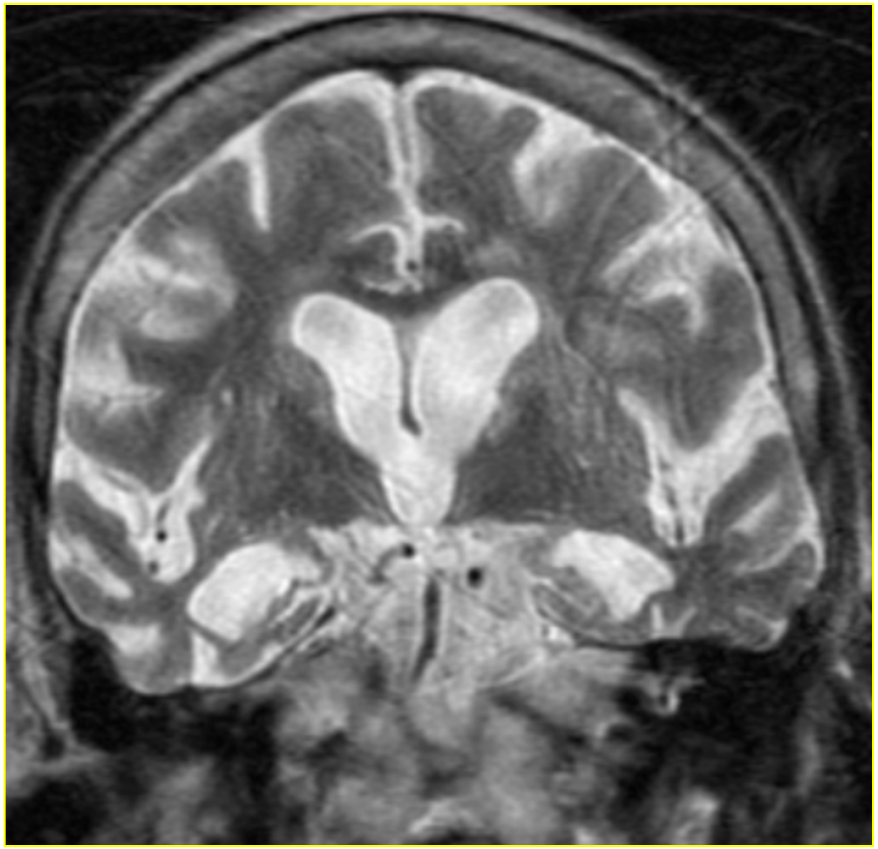

2. Atrophie temporale unilatérale

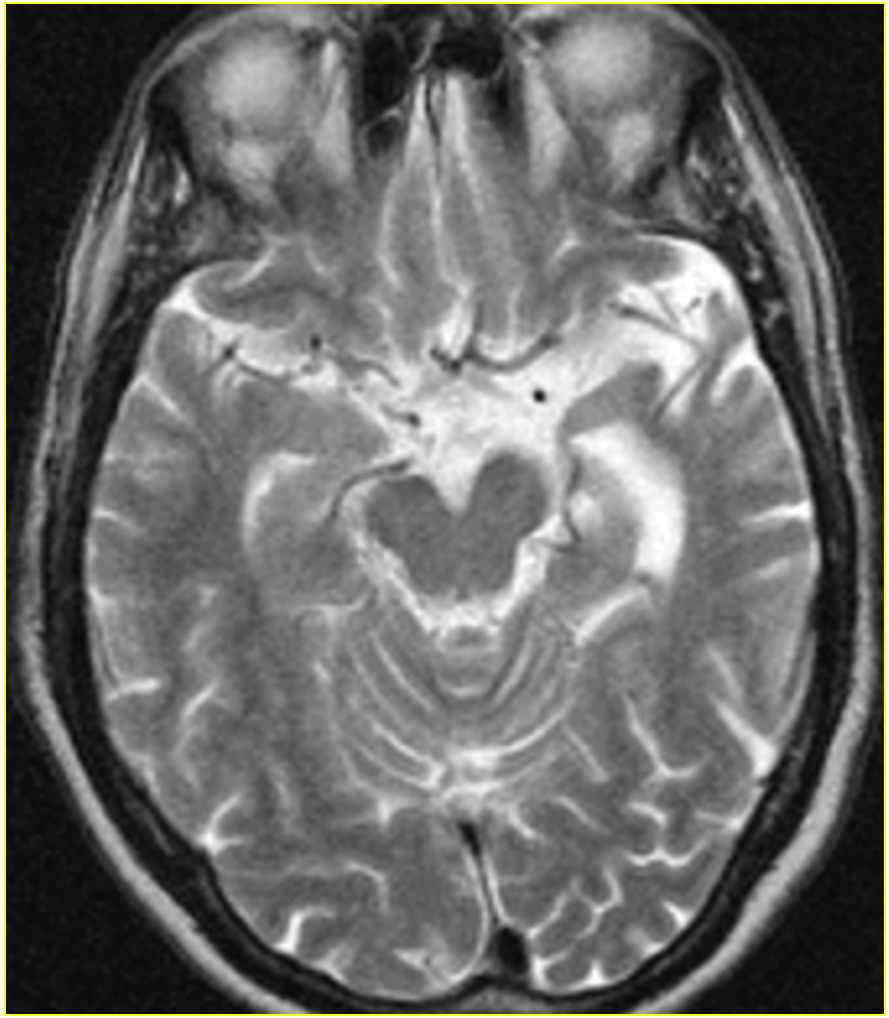

2. Maladie de Pick

Atrophie lobaire préférentielle

corticale

frontale interne

2. Maladie de Pick

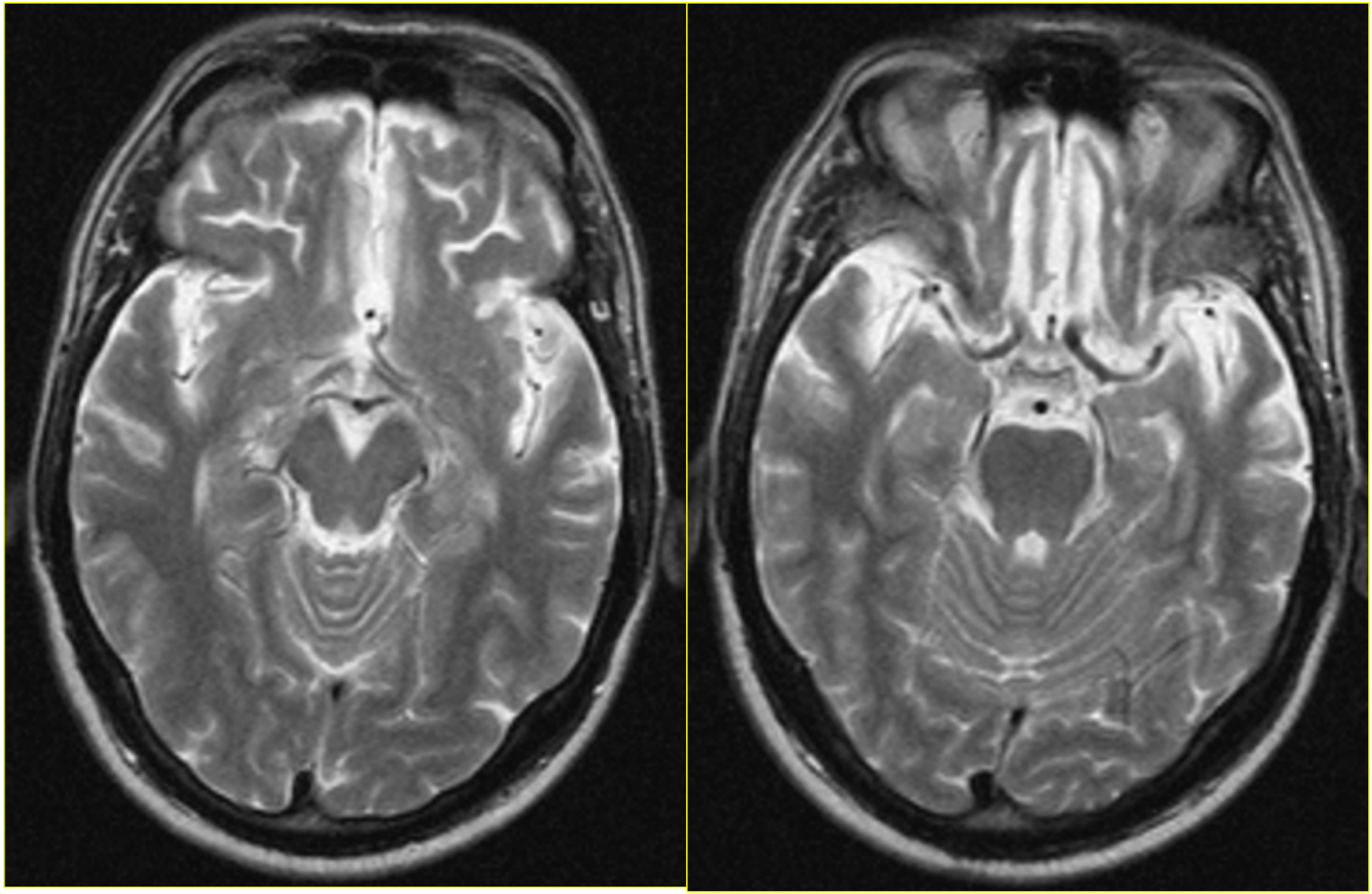

2. Maladie de Pick

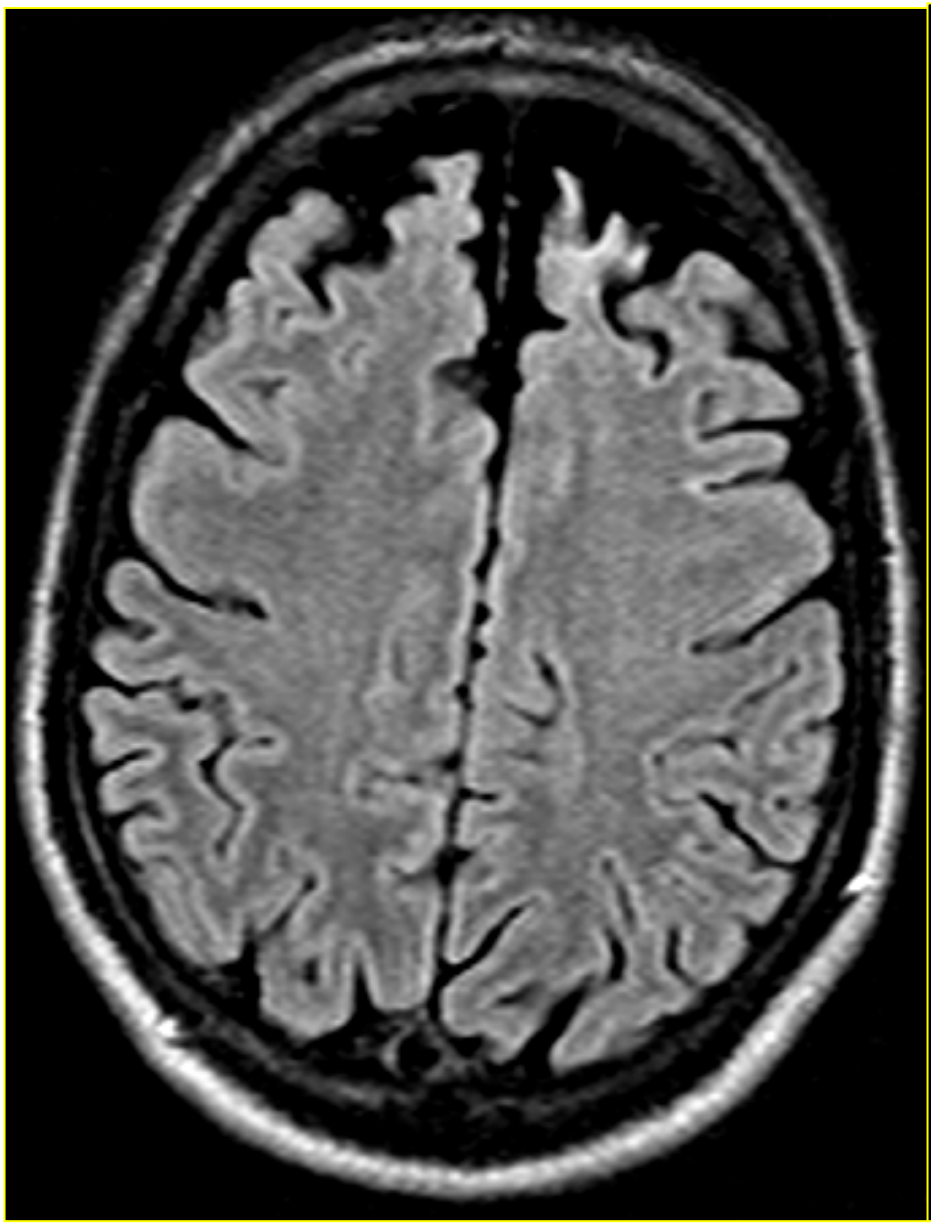

2. Maladie de Pick

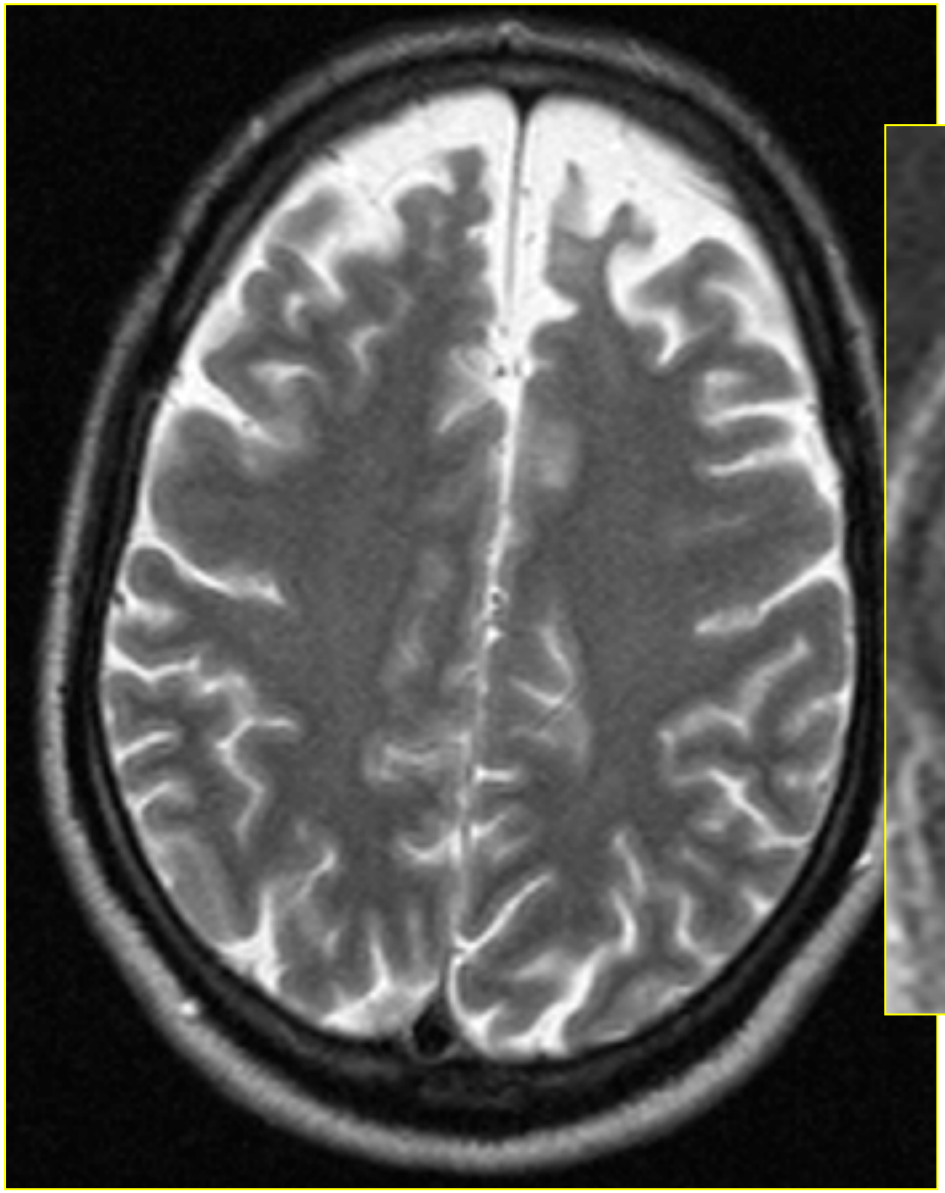

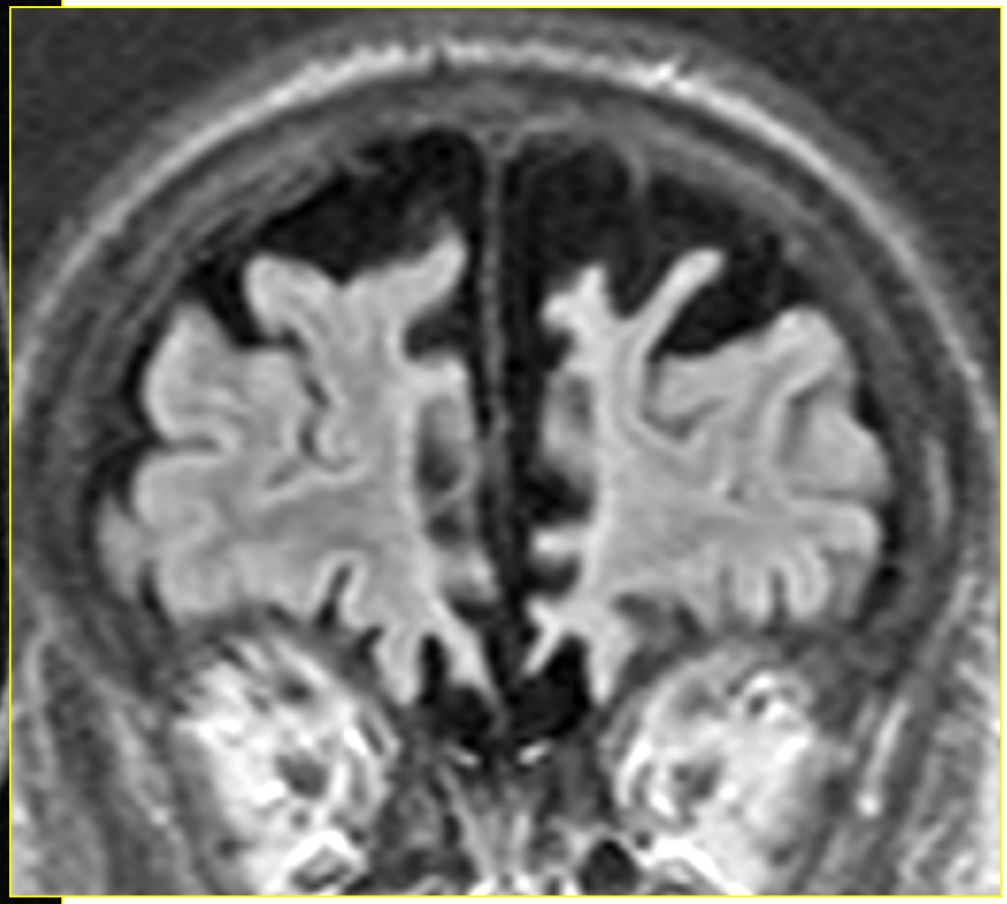

2. Maladie de Pick

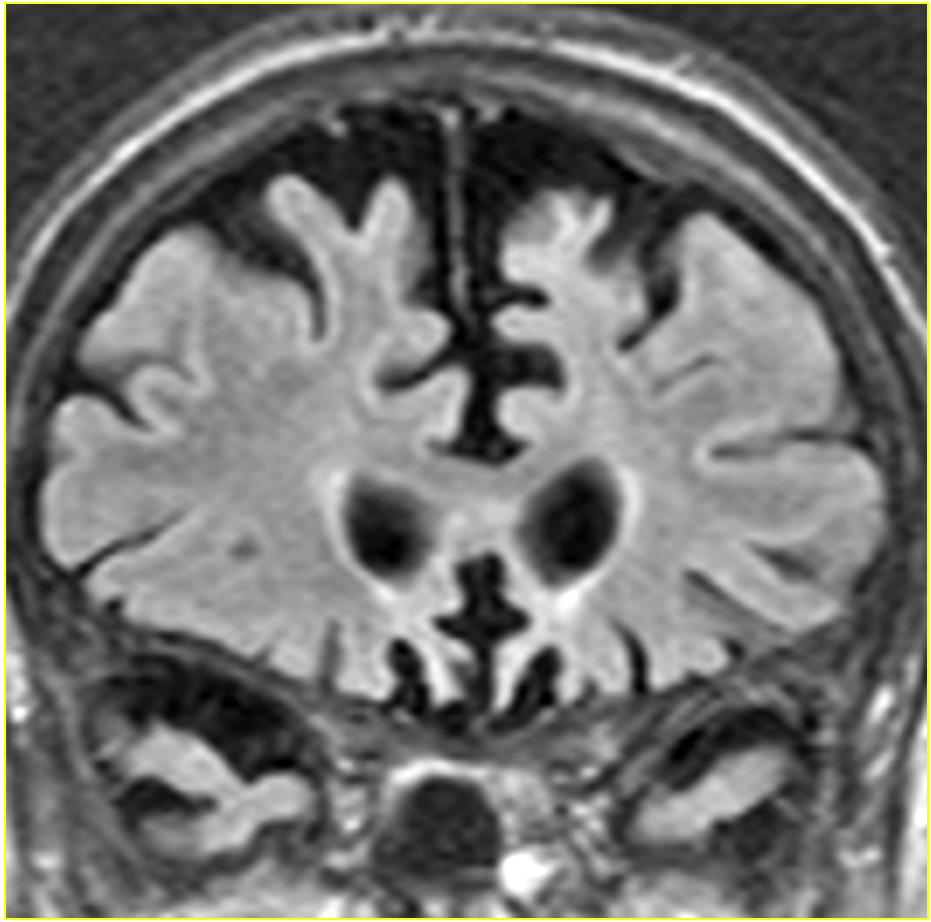

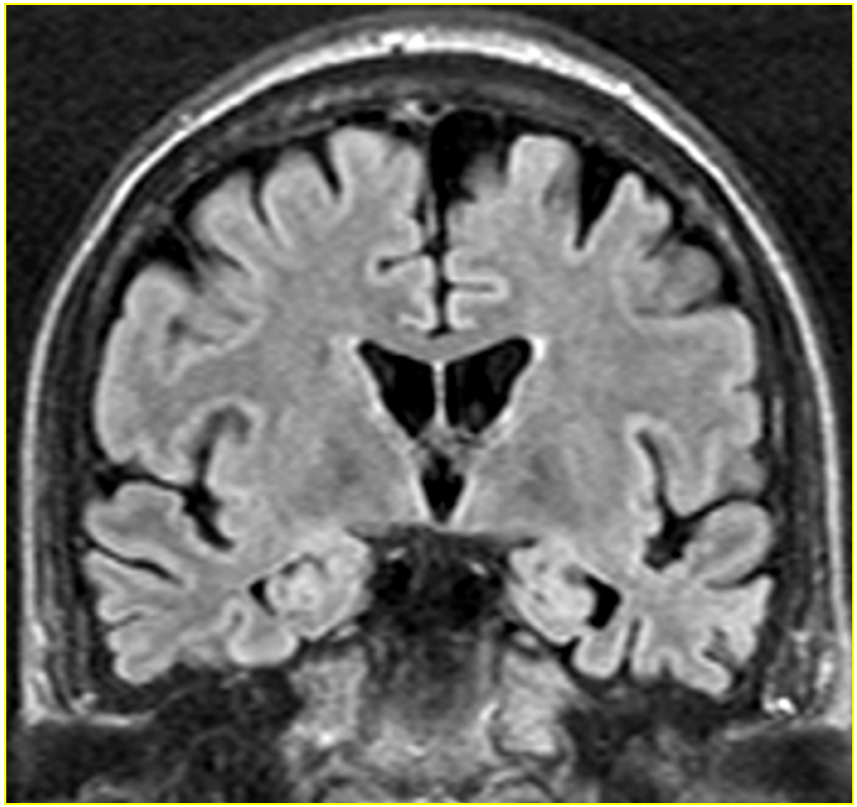

3. Démence vasculaire

Présence d ’une quantité anormalement élevée
de lésions ischémiques cérébrales,
soit

- **micro-vasculaire** (leucoariose excessive)
  « Subcortical Arteriosclerotic Encephalopathy »
  SAE - Binswanger Disease

- **macro-vasculaire**: Multi-Infarct Dementia - MID

3. Démence vasculaire

1. Multi-Infarct-Dementia MID

macro-vasculaire

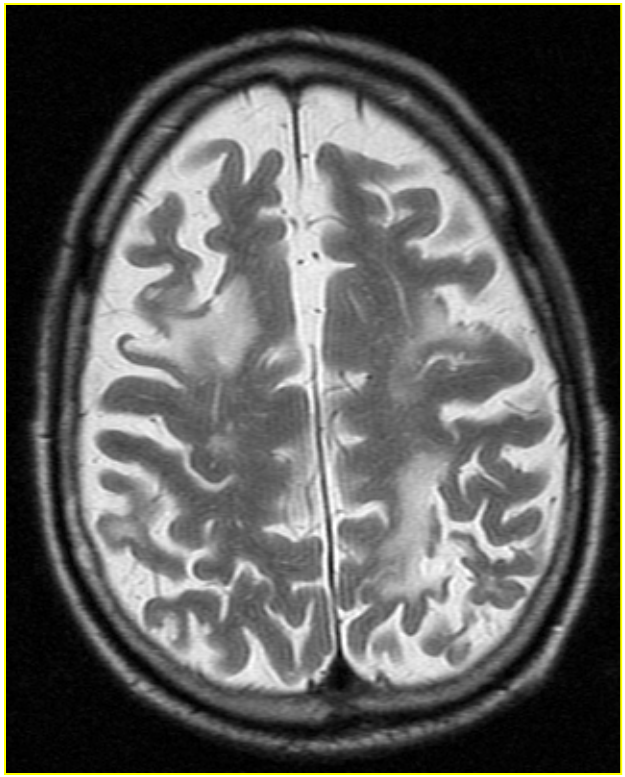

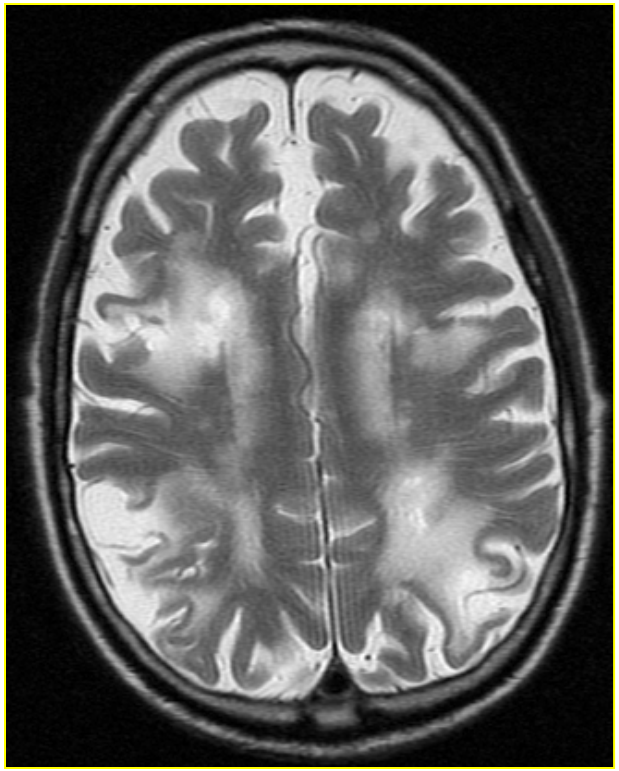

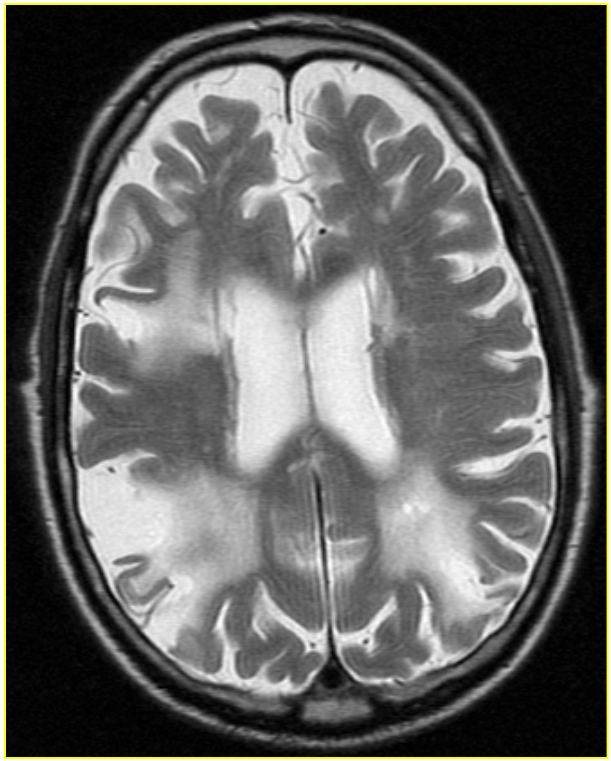

3. Démence vasculaire

Subcortical Arteriosclerotic Encephalopathie (SAE)

micro-vasculaire

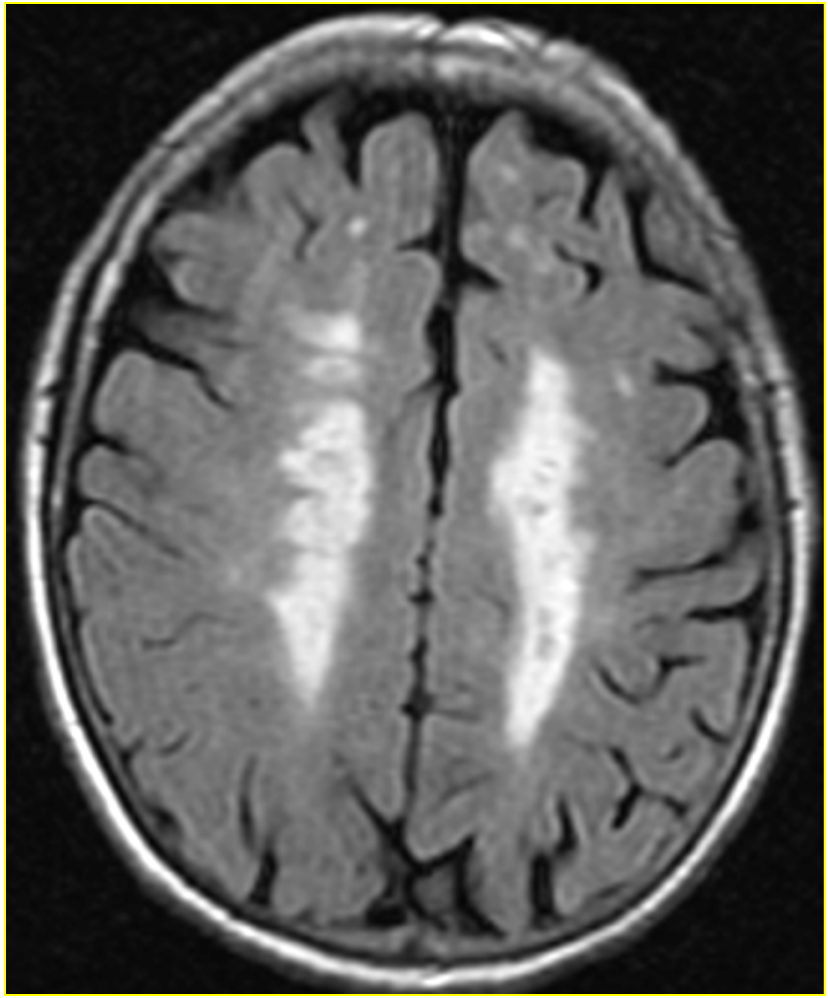

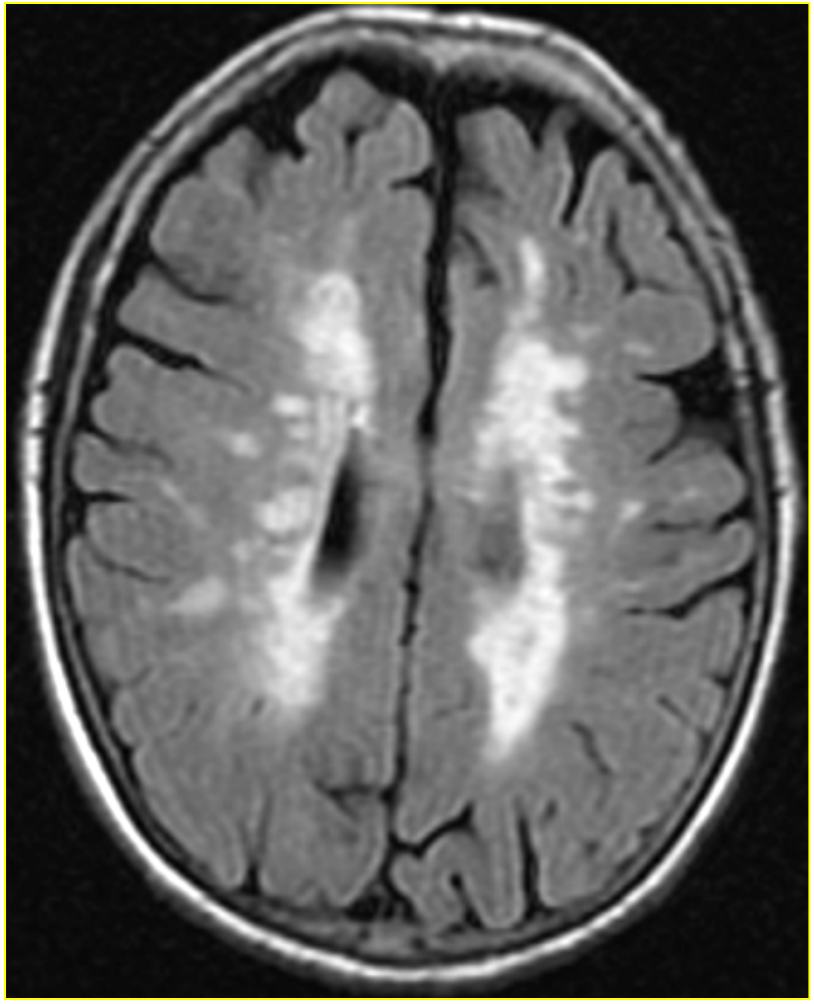

Démence d’Alzheimer
IMAGERIE
QUANTITATIVE

L'atrophie mésio-temporale précède l'expression symptomatique démentielle catégorisée

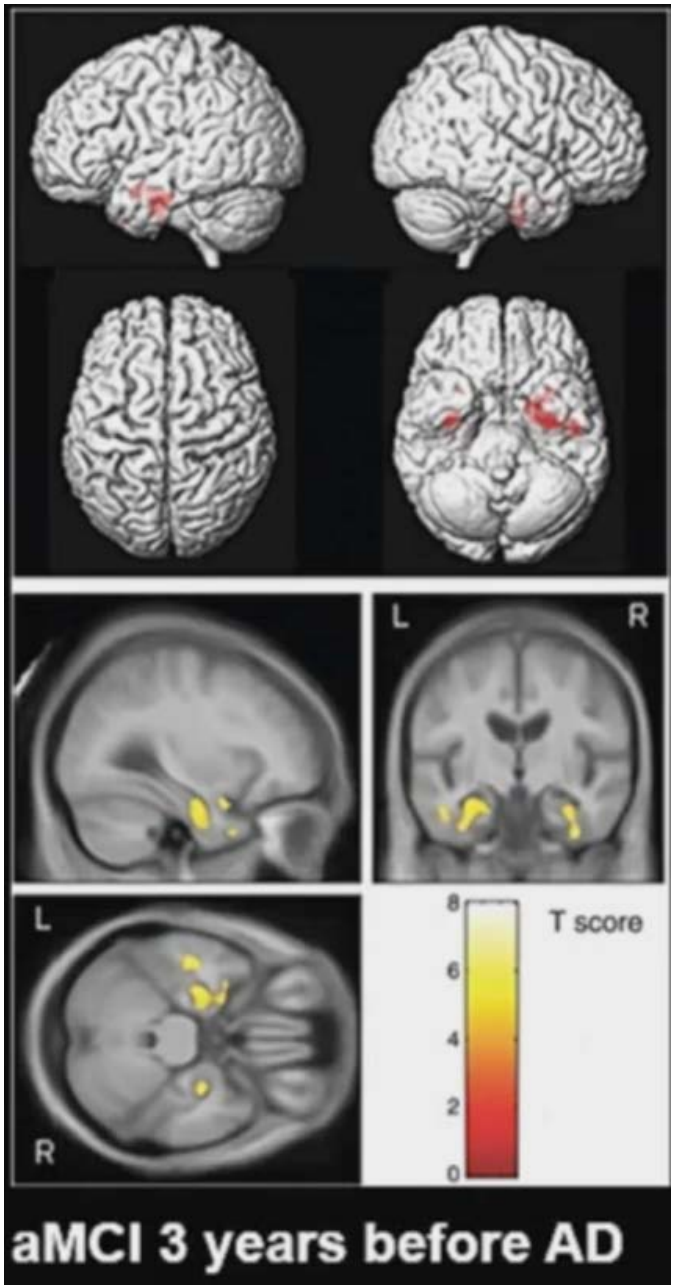

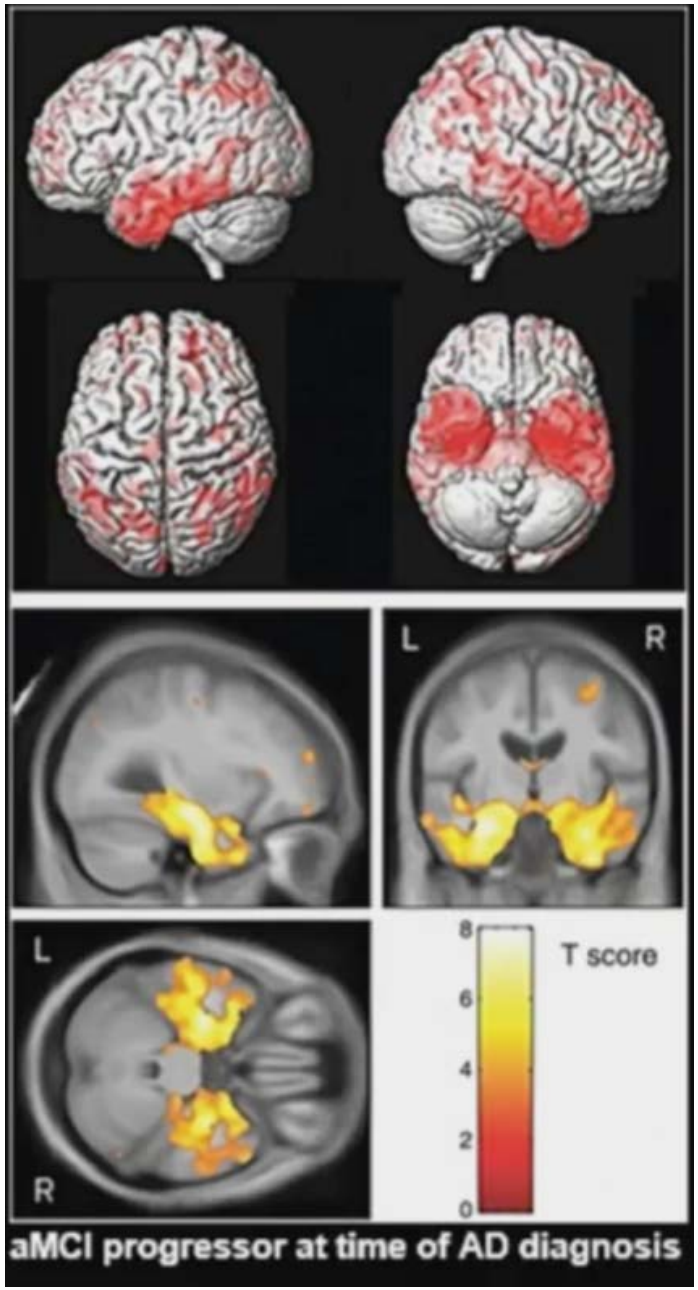

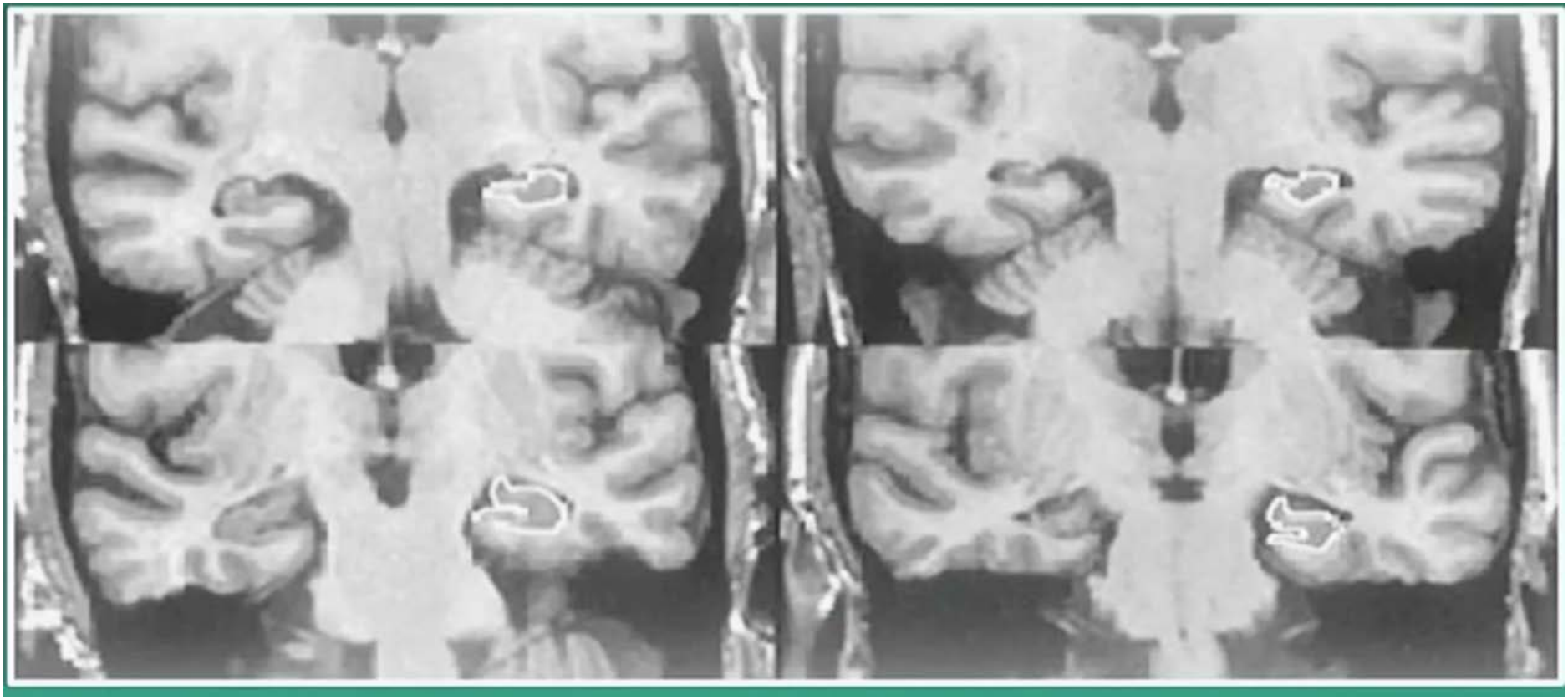

Jack CR, Neurology. 1999 April 22; 52(7): 1397–1403

Volumétrie manuelle

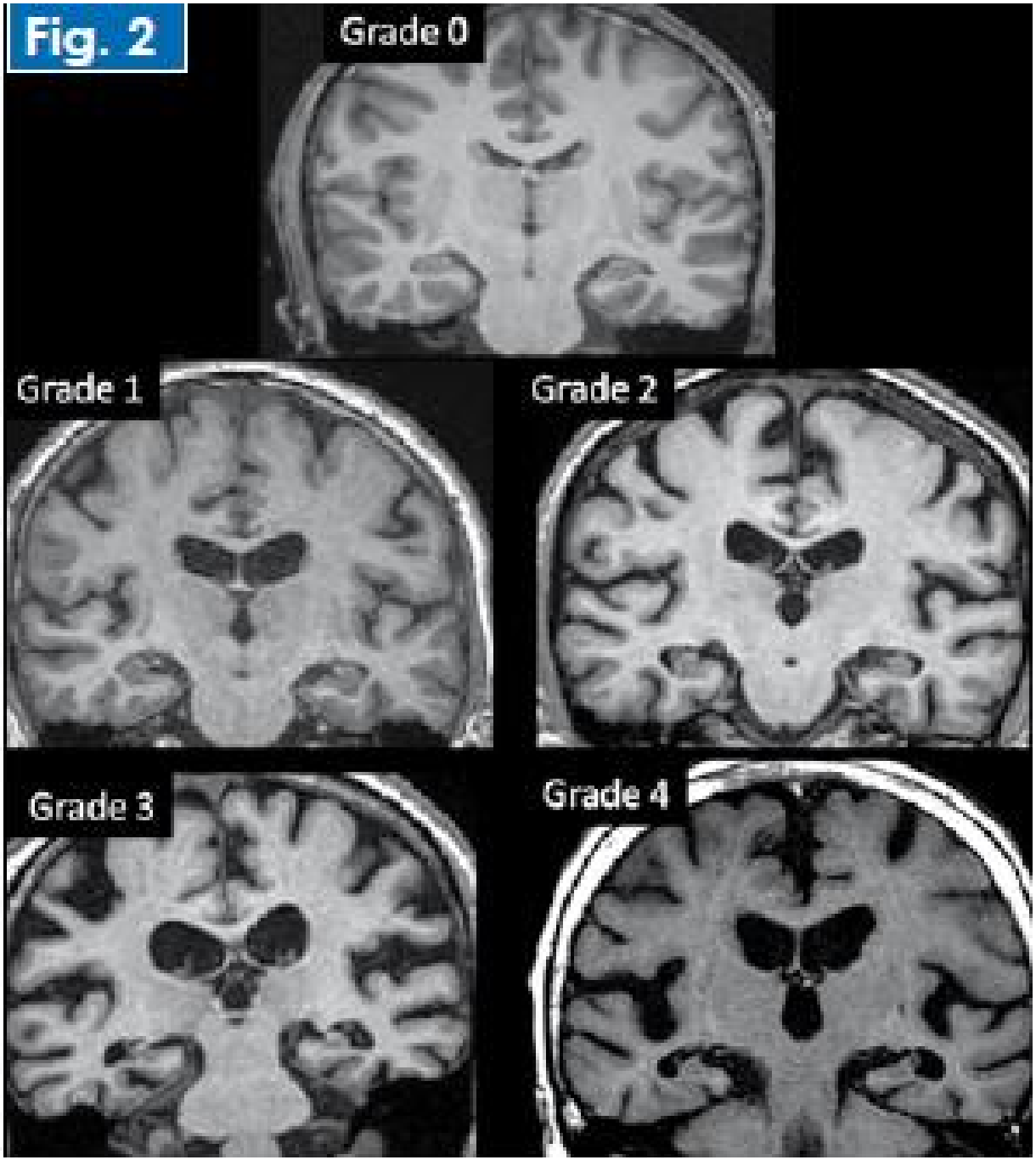

Echelle de Scheltens

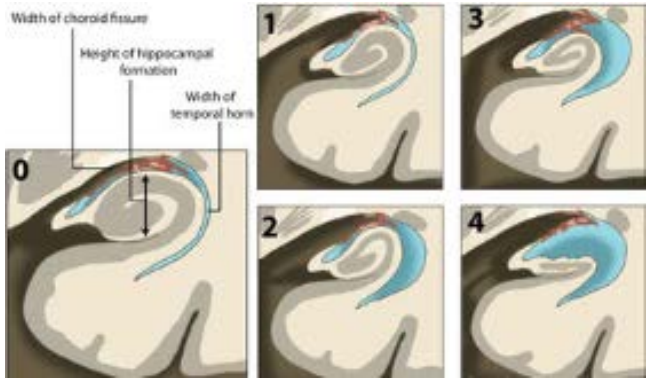

Clinical volumetric MRI

Case 1

Classic AD pattern

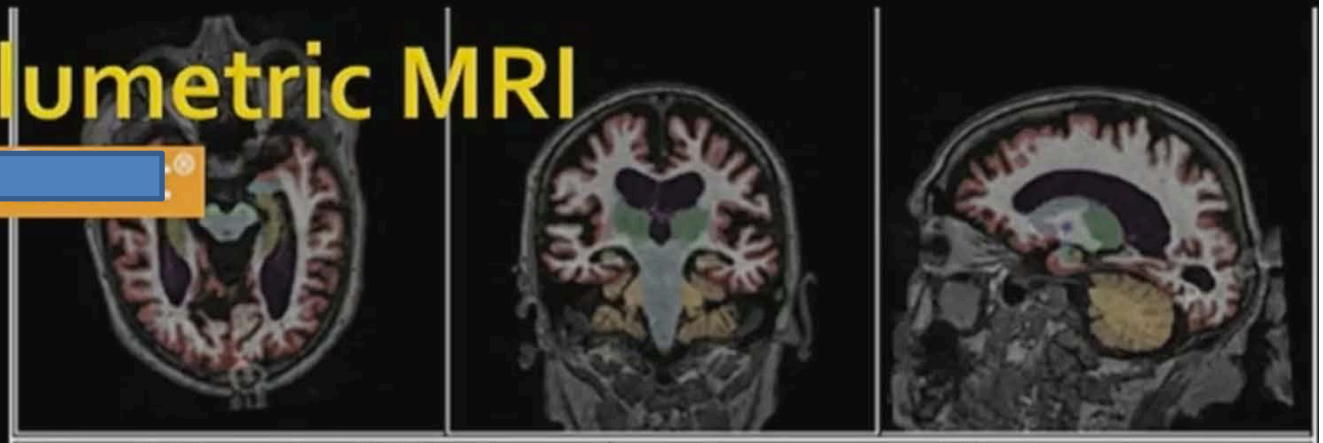

Hippocampal Occupancy Score (HOC)		0.41	
Brain Structure	Volume (cm³)	% of ICV (5%-95% Normative Percentile*)	Normative Percentile*
Hippocampi	4.46	0.23 (0.32-0.46)	< 1
Lateral Ventricles	125.25	6.55 (1.85-4.98)	> 99
Inferior Lateral Ventricles	6.54	0.34 (0.13-0.29)	99

AGE-MATCHED REFERENCE CHARTS

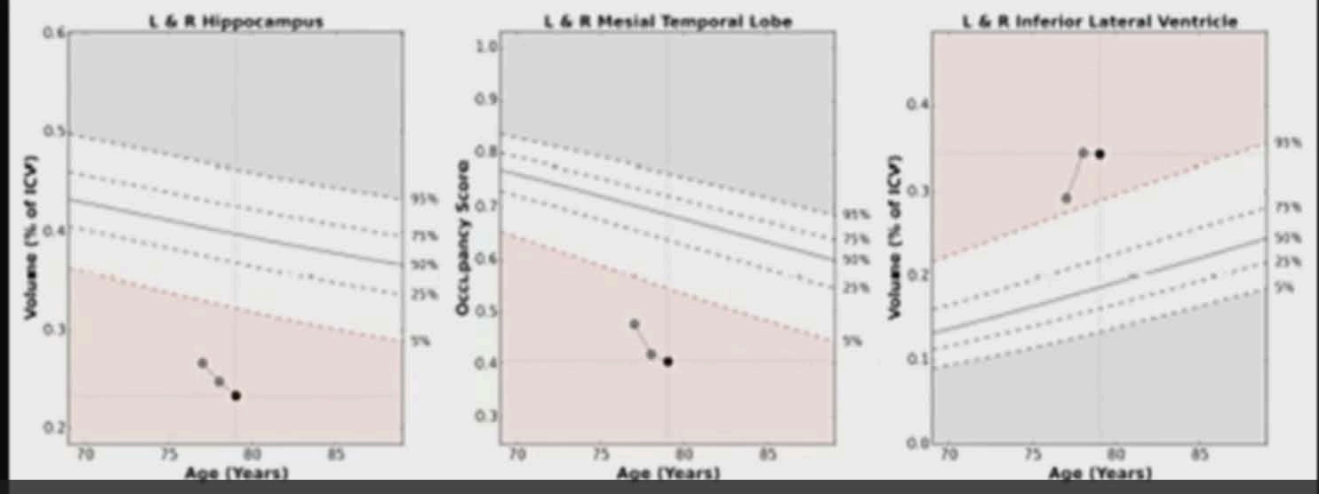

Volumétrie numérisée

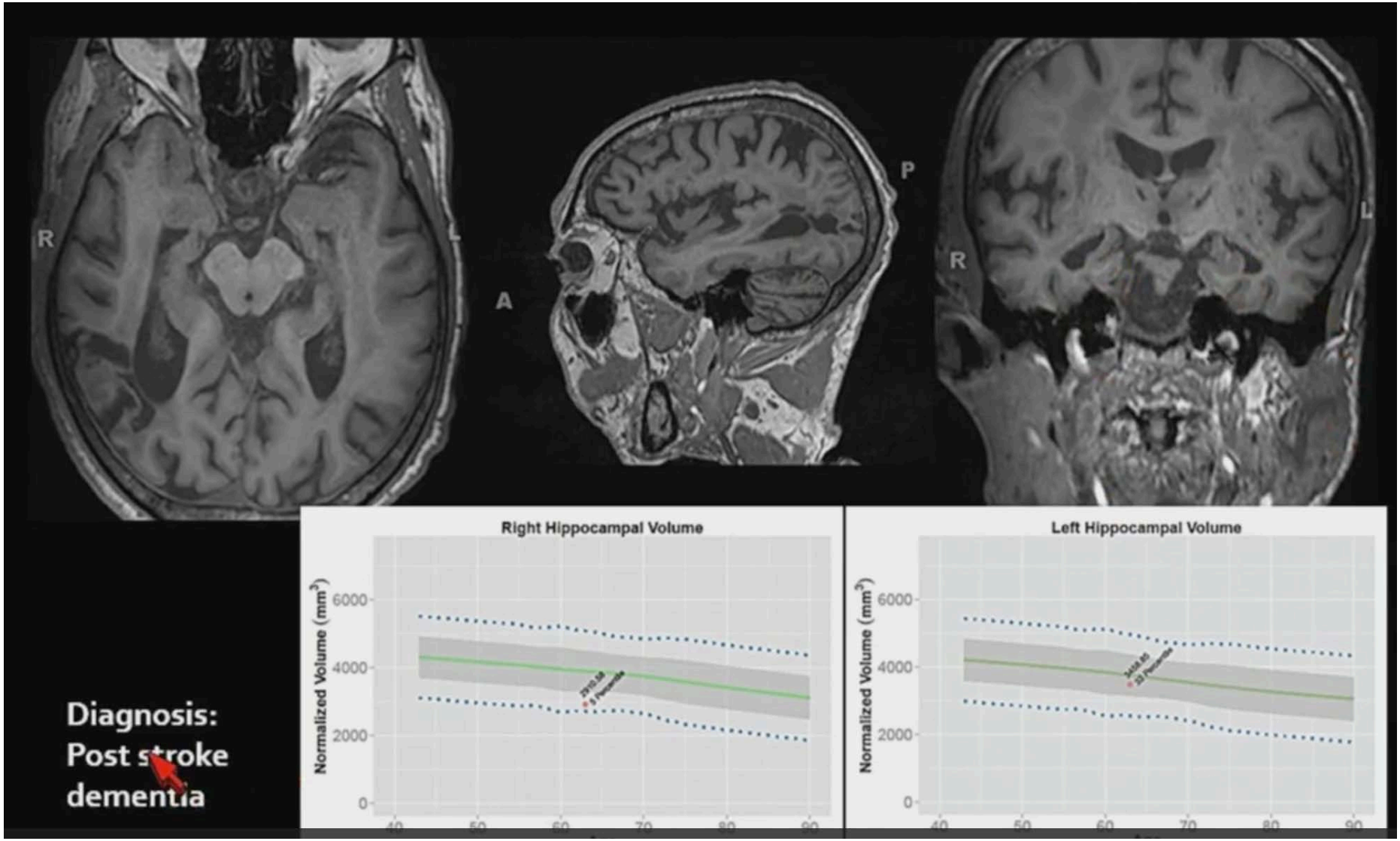

… parfois décompensation sur 1 stroke fatal

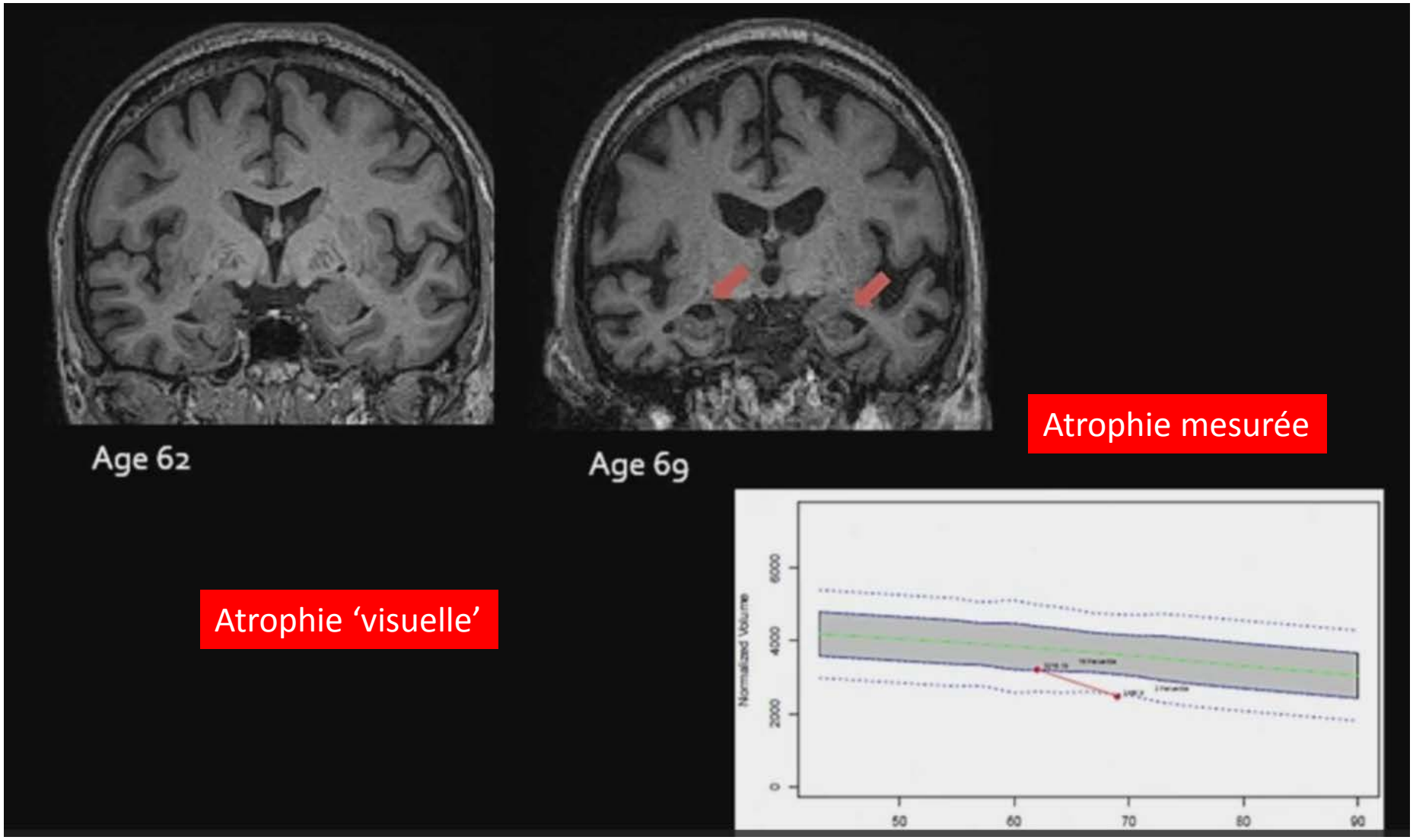

Pattern typique d'AD: atrophie hippocampique élective

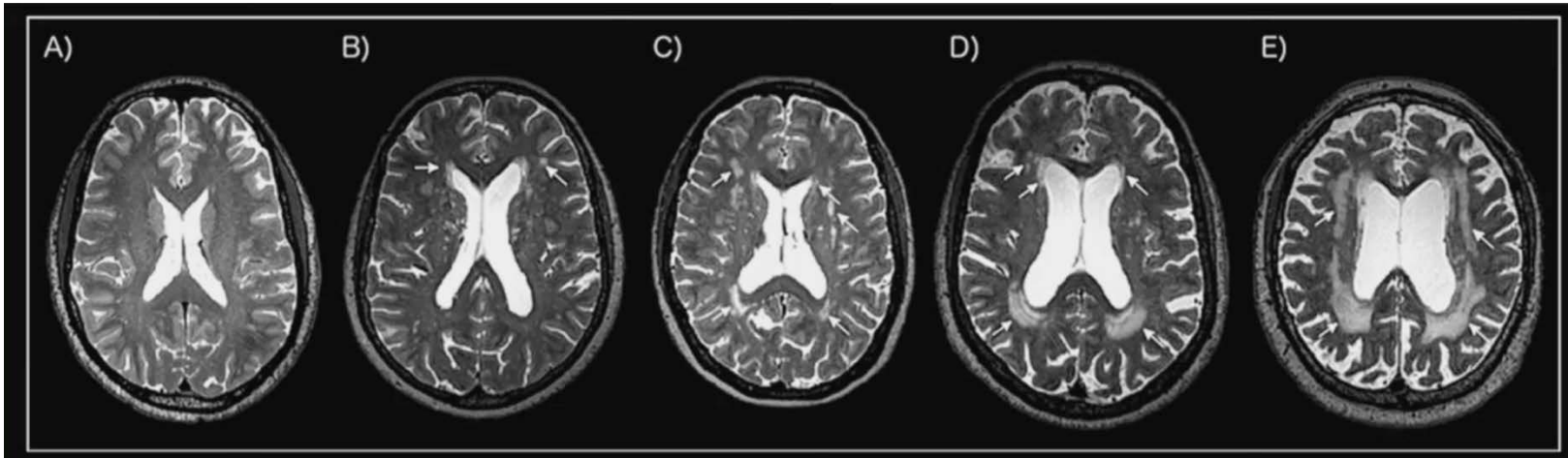

Levels of amyloid deposition (ps < 0.01), as well as ratings of periventricular white matter hyperintensitites (WMH) (p < 0.01) and deep WMH (p < 0.05) discriminate between cognitively normal and demented individuals.

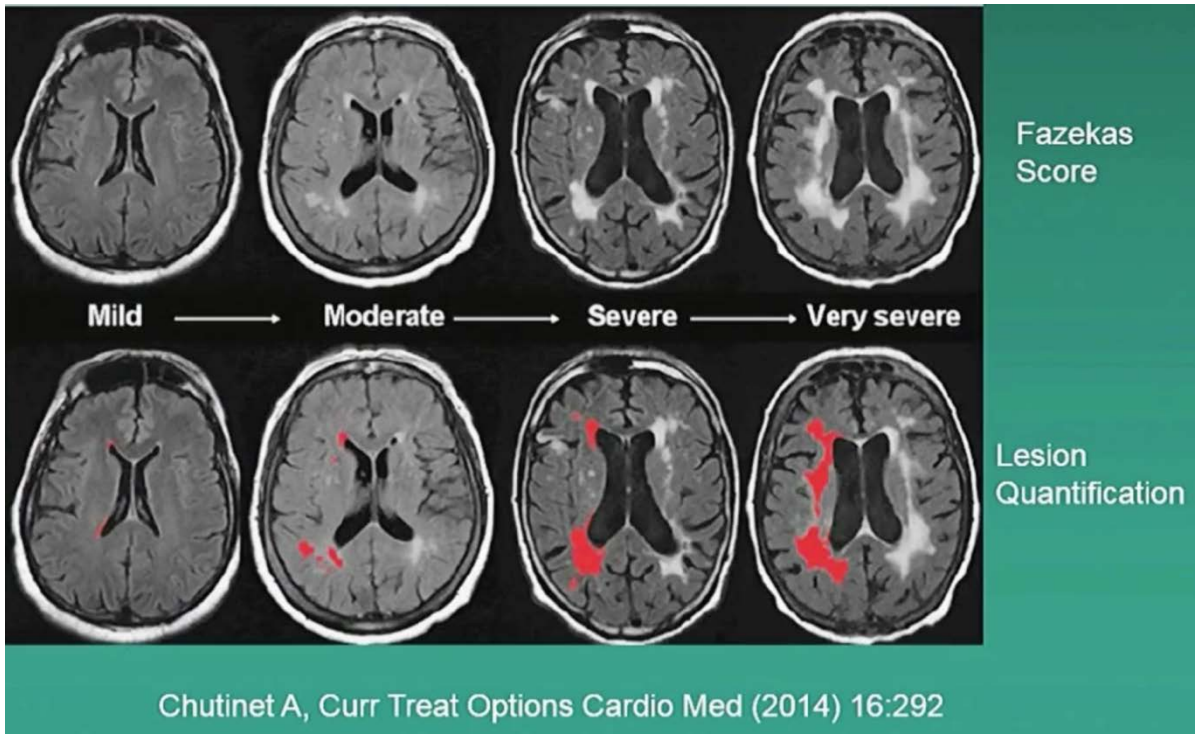

Chutinet A, Curr Treat Options Cardio Med (2014) 16:292

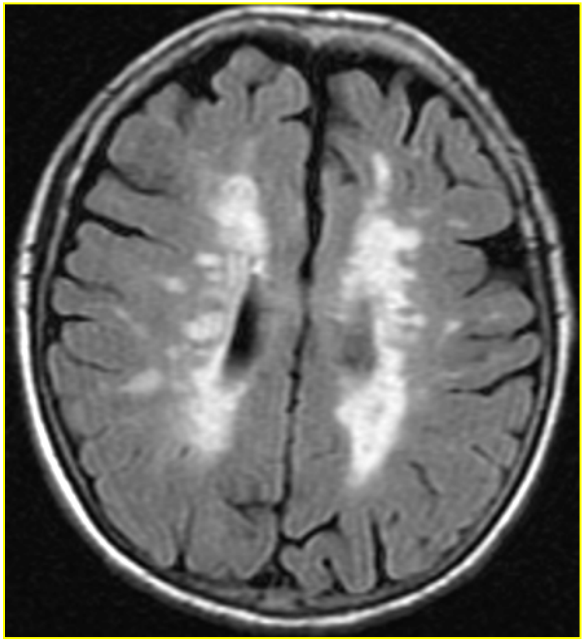

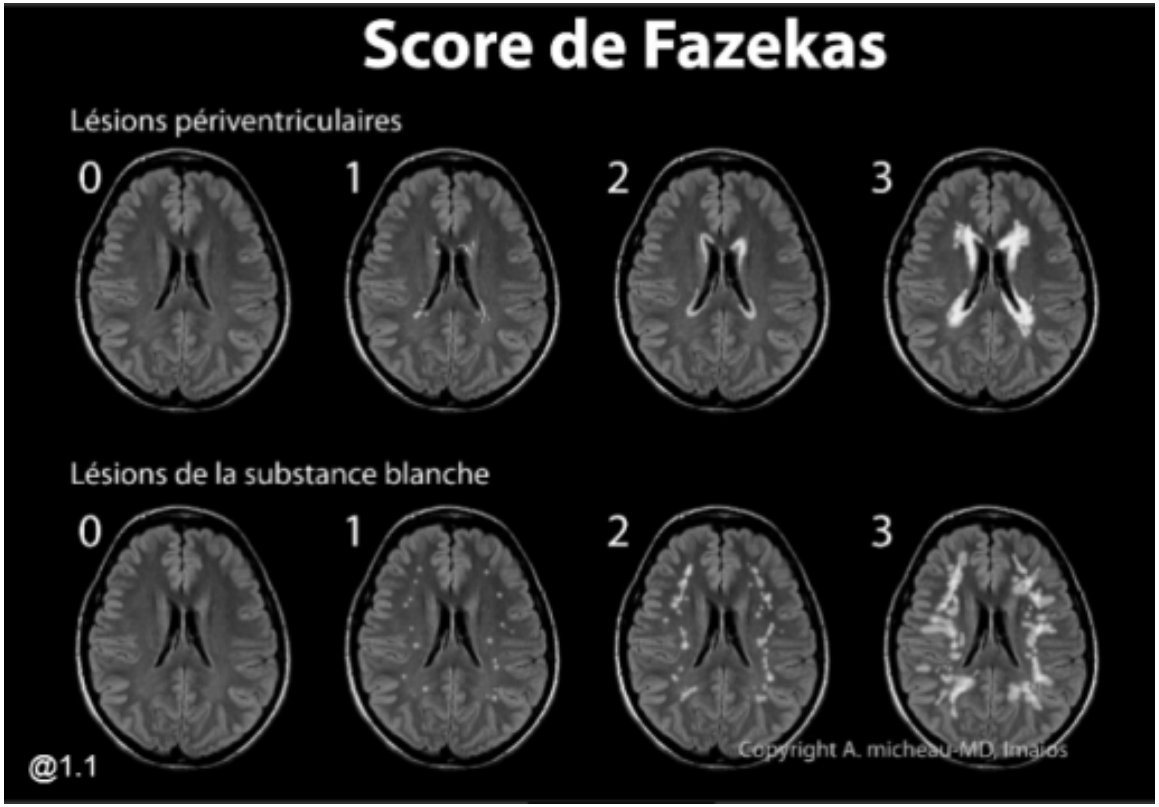

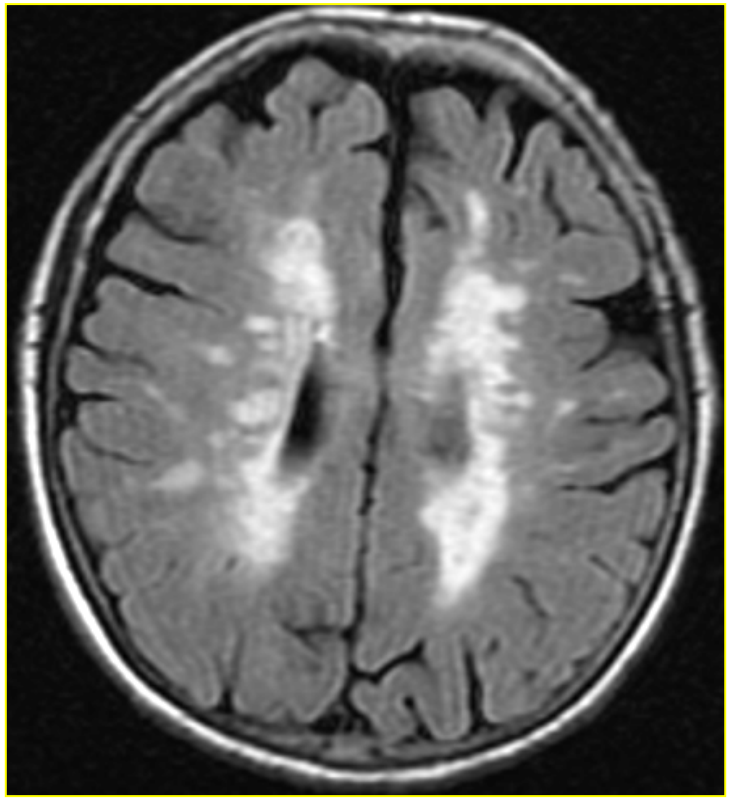

Démence micro-vasculaire sous-corticale
‘Leucoariose pathologique’
« Subcortical Arteriosclerotic encephalopathy » SAE
Binswanger’s Disease

Comparison of Two Commercial Volumetric Software Products

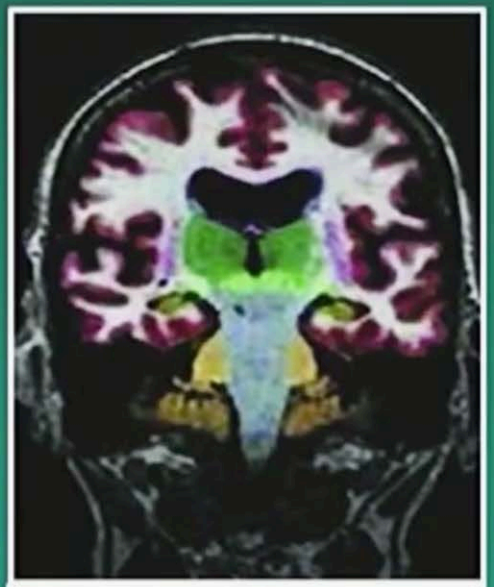

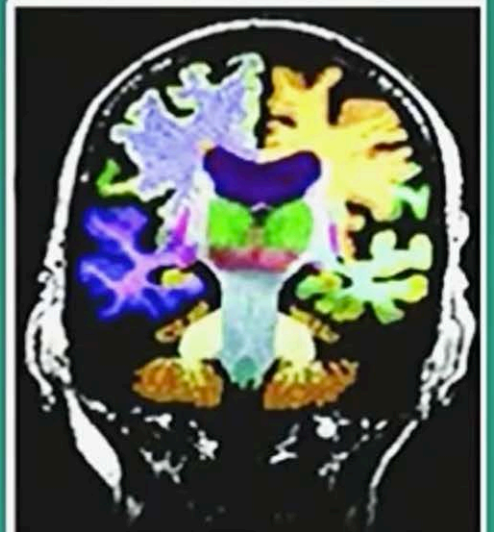

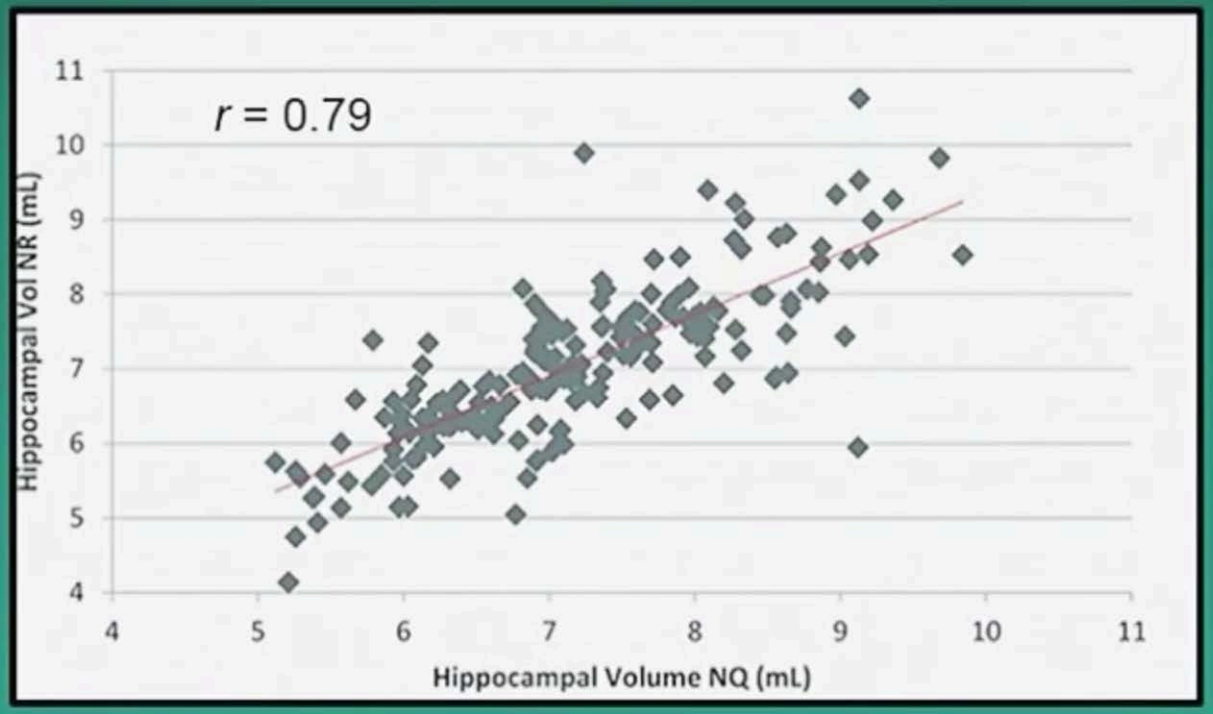

Tanpitukpongse TP, Mazurowski MA, Ikhena J, Petrella JR
AJNR 2017

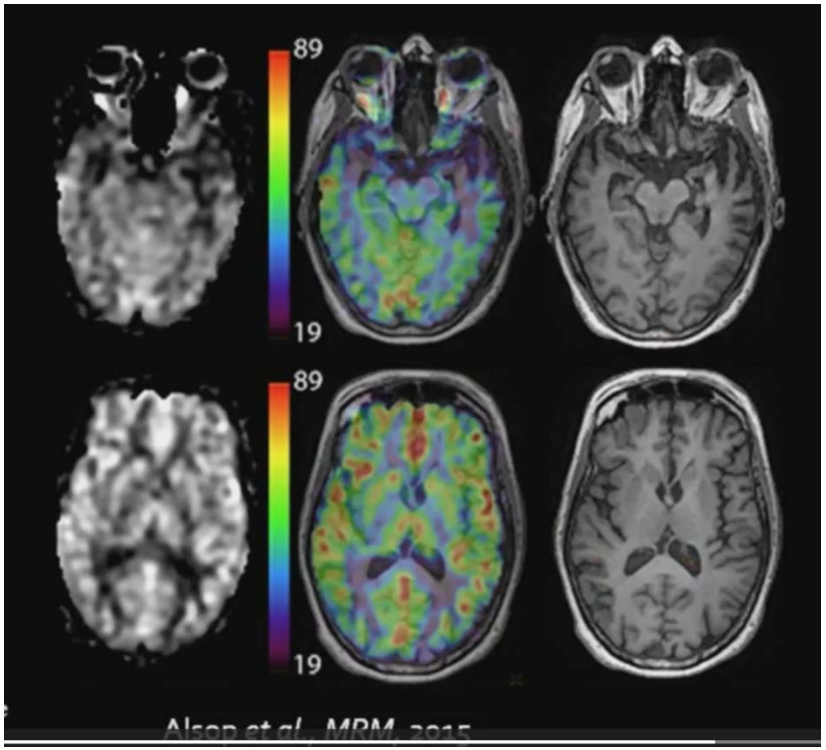

Aphasie dégénérative primaire

Co-registration de la perfusion ASL
avec l'image morphologique T1

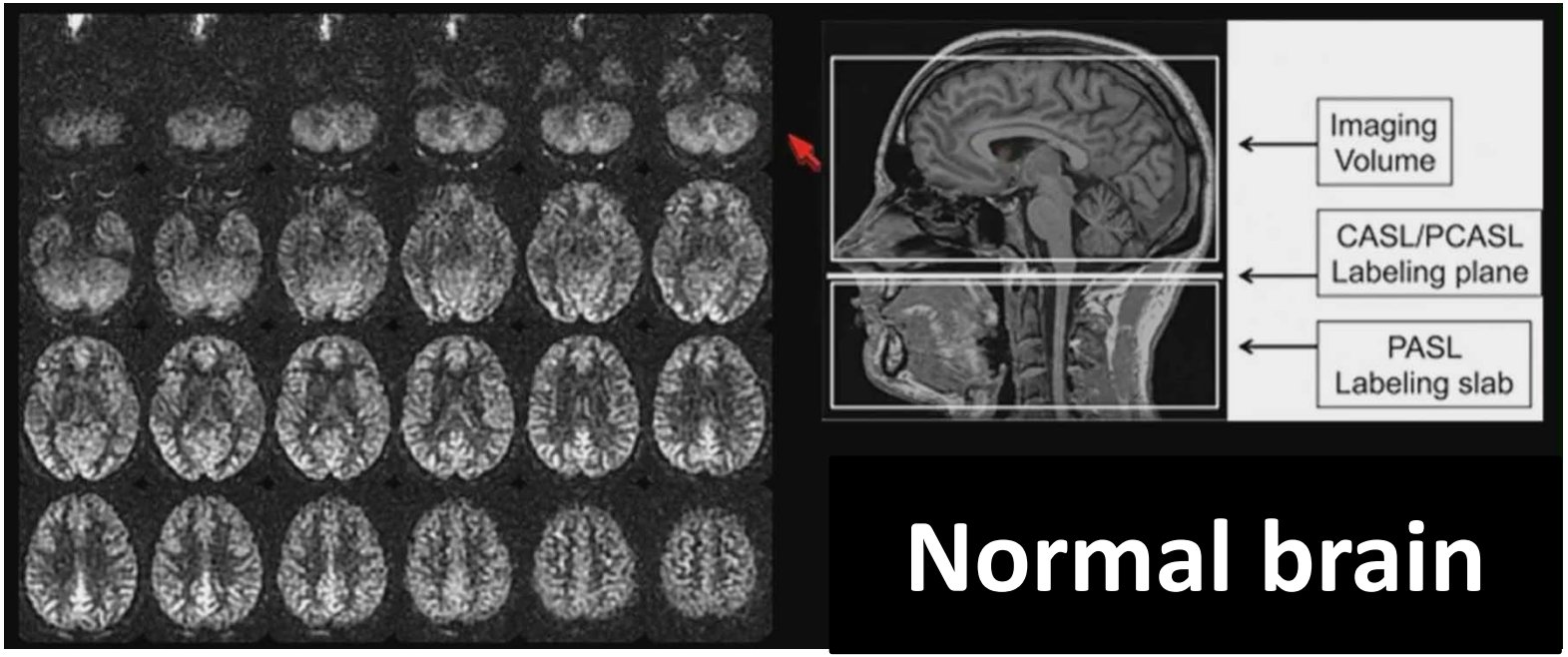

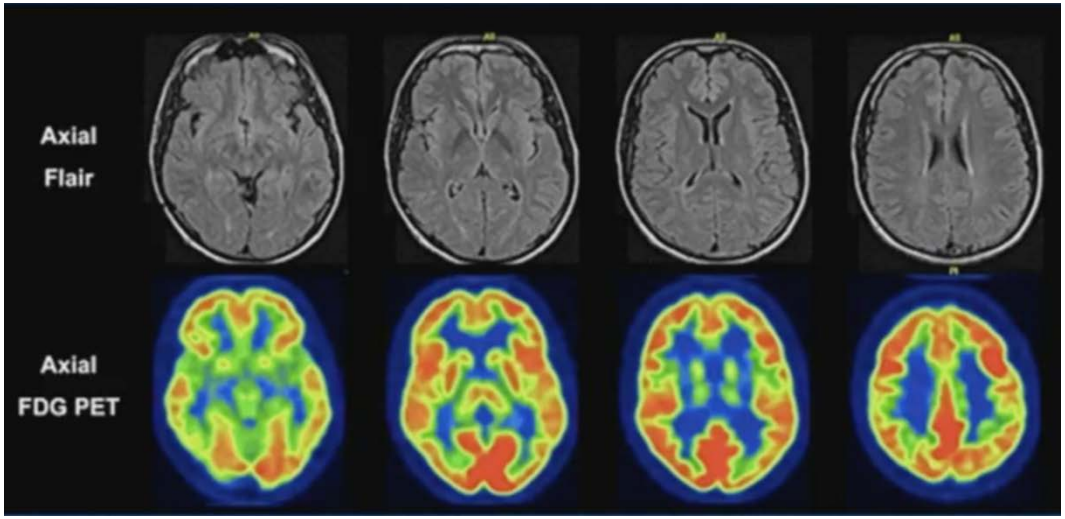
Axial
Flair
Axial
FDG PET

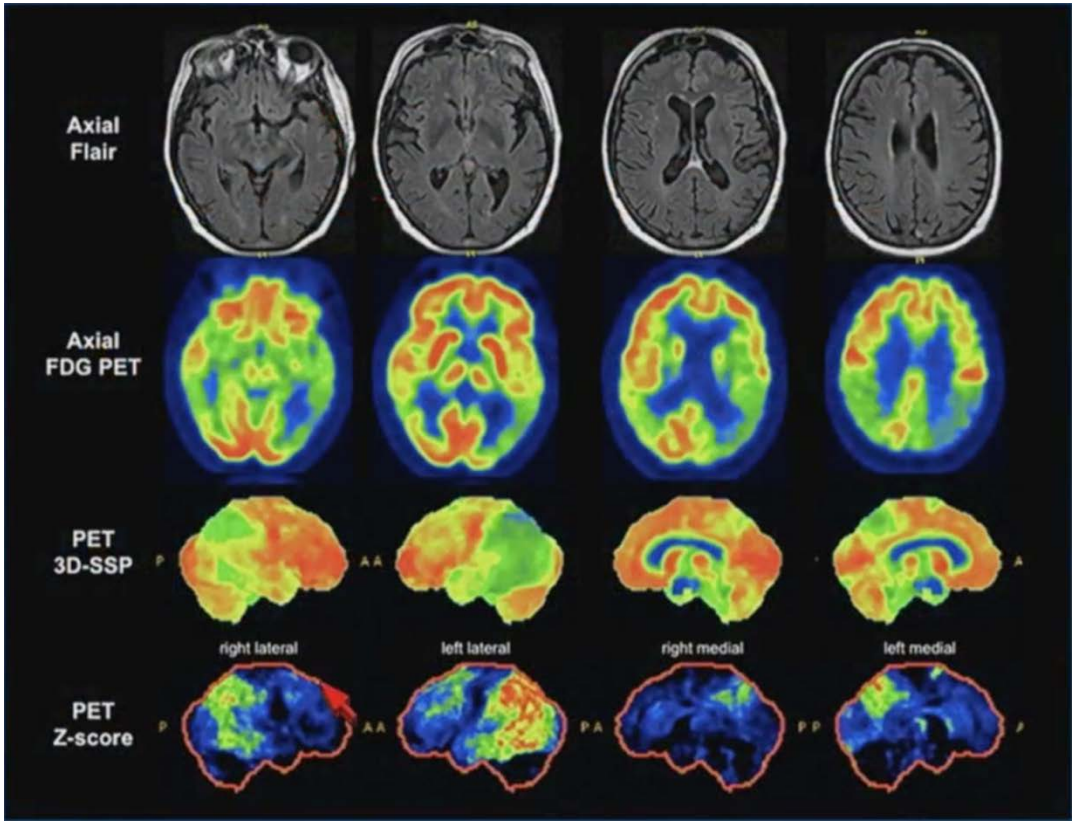
Axial
Flair
Axial
FDG PET
PET
3D-SSP
right lateral
left lateral
right medial
left medial
PET
Z-score

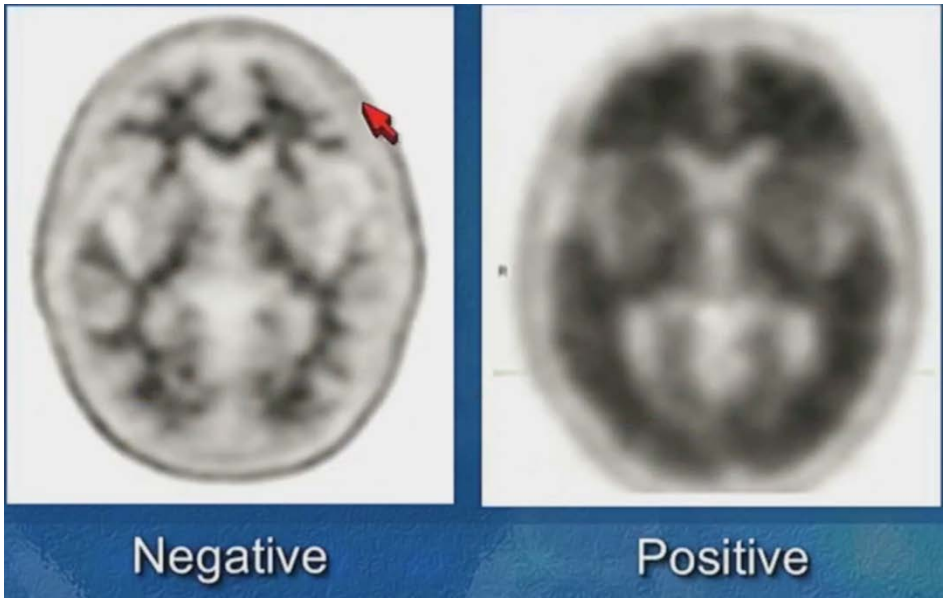

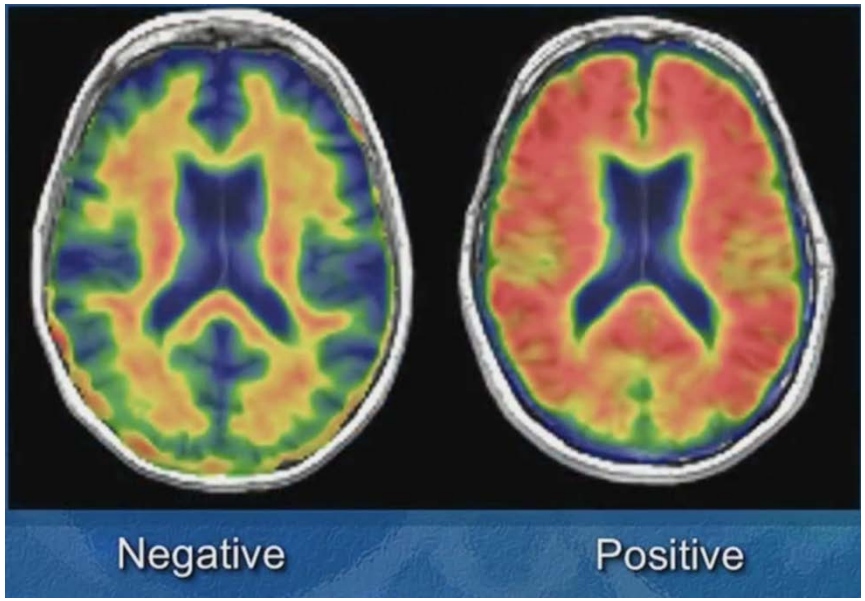

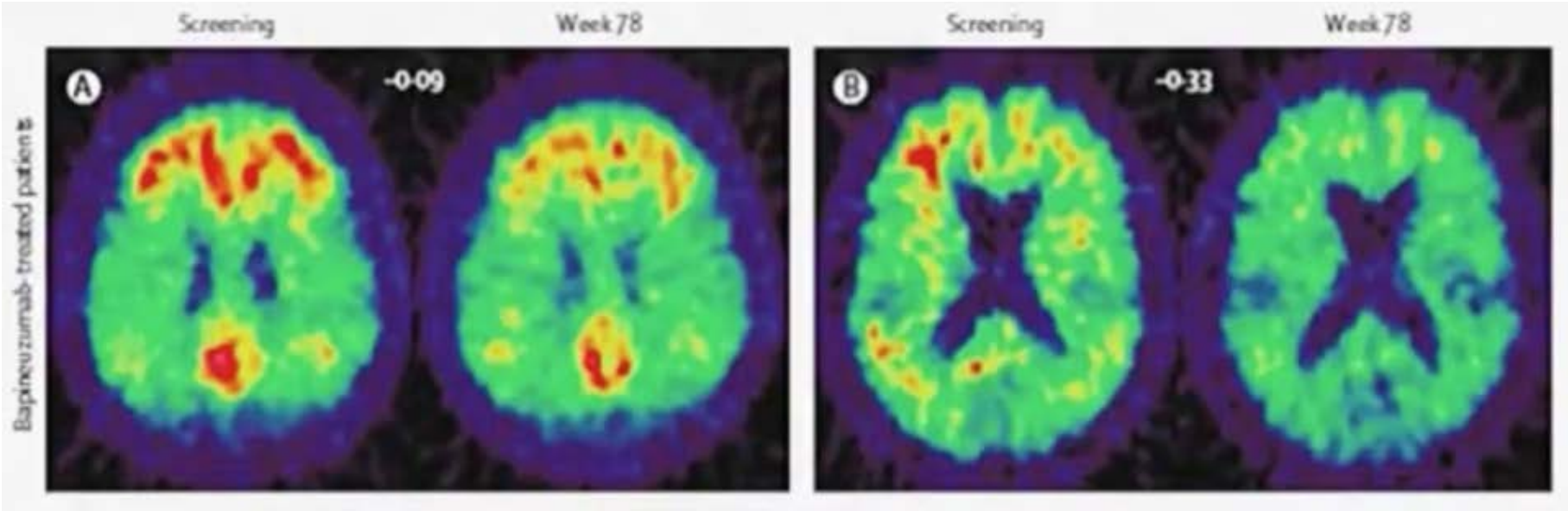

^{11}C-PiB PET assessment of change in fibrillar amyloid-β load in patients with Alzheimer's disease treated with bapineuzumab: a phase 2, double-blind, placebo-controlled, ascending-dose study

Rinne et al. Lancet Neurology 2010;9:363-372

Guidelines
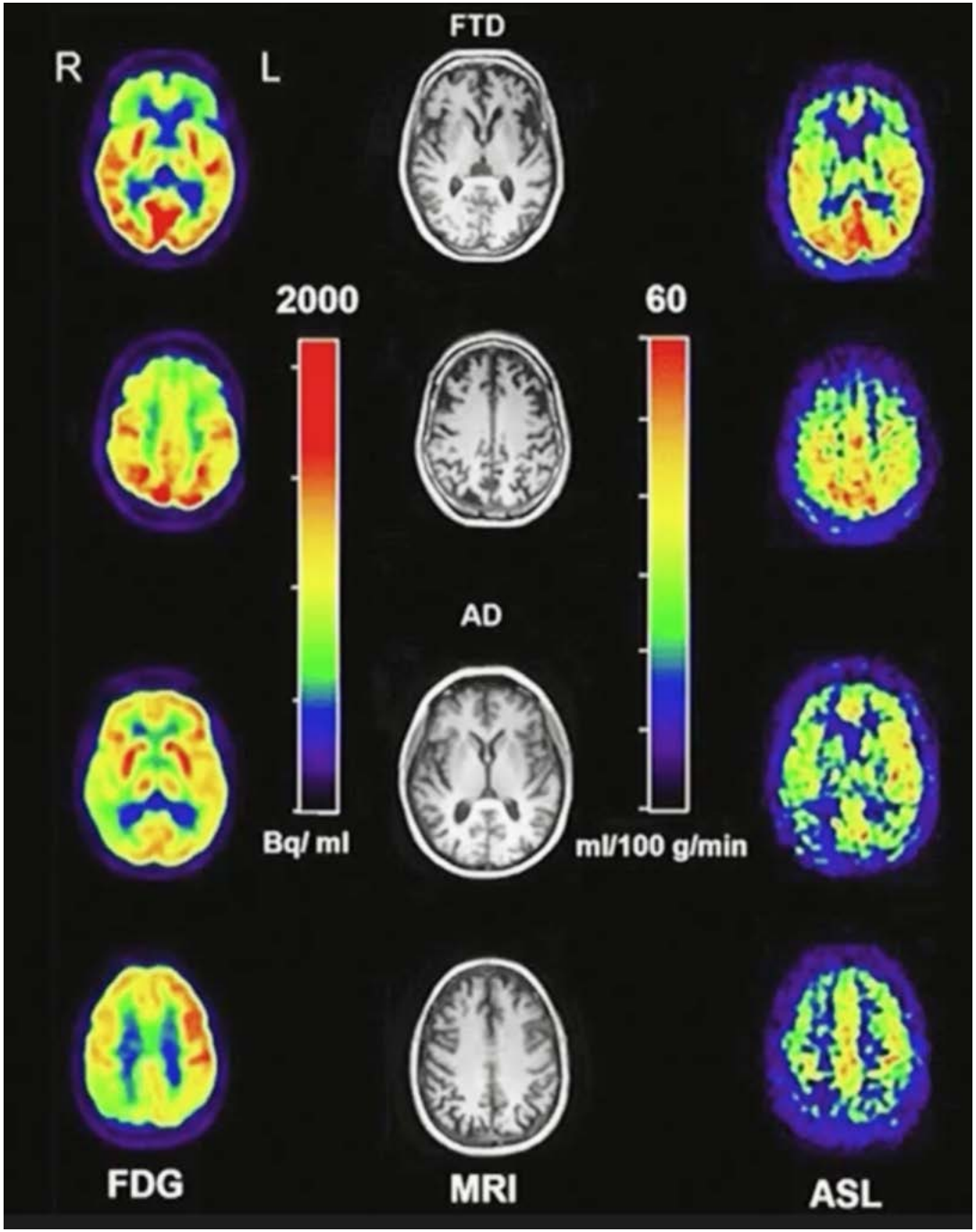
1. Analyse morphologique ‘éclairée’
   (connaissance des entités morphologiques)
2. Analyse quantitative
   1. Scheltens
   2. Volumétrie → sérielle
3. Intégration ASL