

RDGN 2120 – NEURORADIOLOGIE

Année académique 2019-2020

Pathologie vasculaire cérébrale aiguë (I)



Dr Thierry Duprez

Professeur Clinique

Chef de Clinique

Université catholique de Louvain
Cliniques universitaires Saint-Luc

duprez@rdgn.ucl.ac.be

<http://www.saintluc.be>

3^{ème} cours du 10 octobre 2020

ISCHEMIE (→infarctus)

HEMORRAGIE

Intra-
parenchymateuse

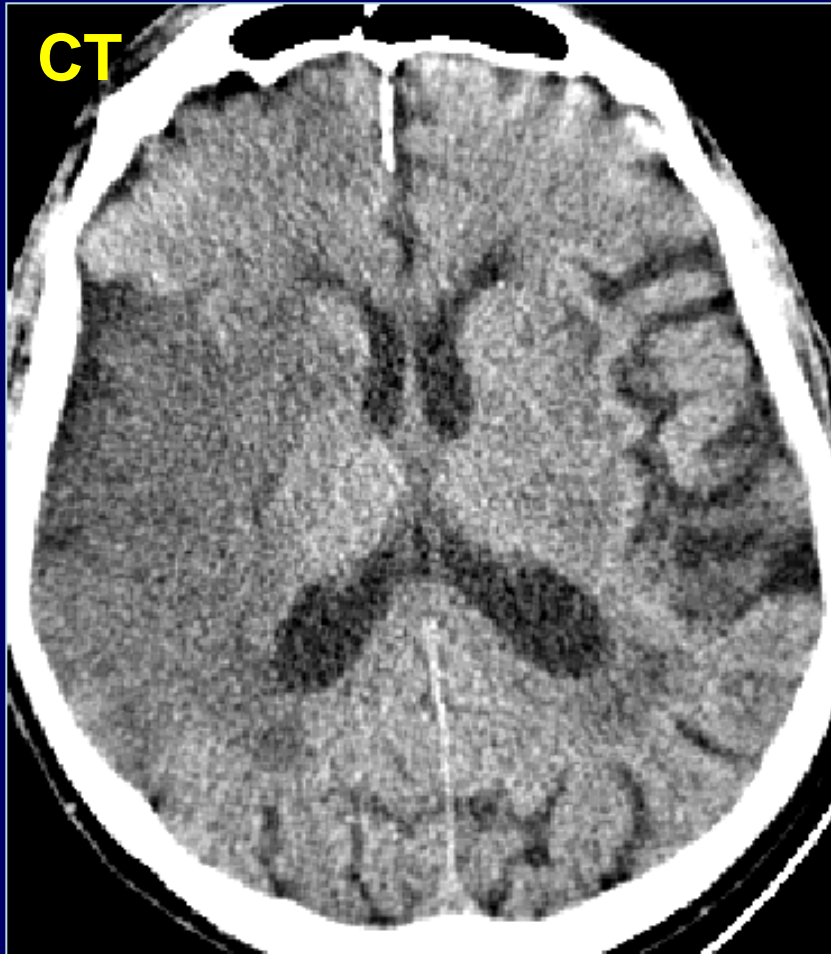
Extra-
parenchymateuse

**THROMBOSE
VEINEUSE**

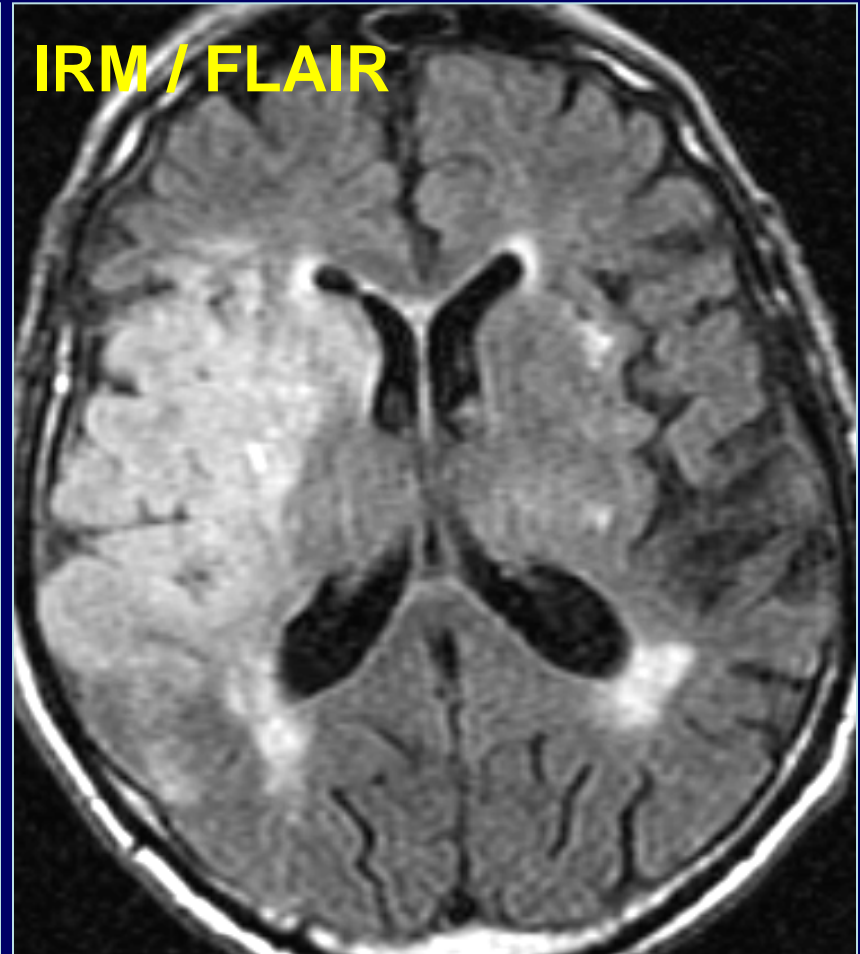
'corticale'
'superficielle'

'profonde'
'centrale'

Ischémie cérébrale aiguë



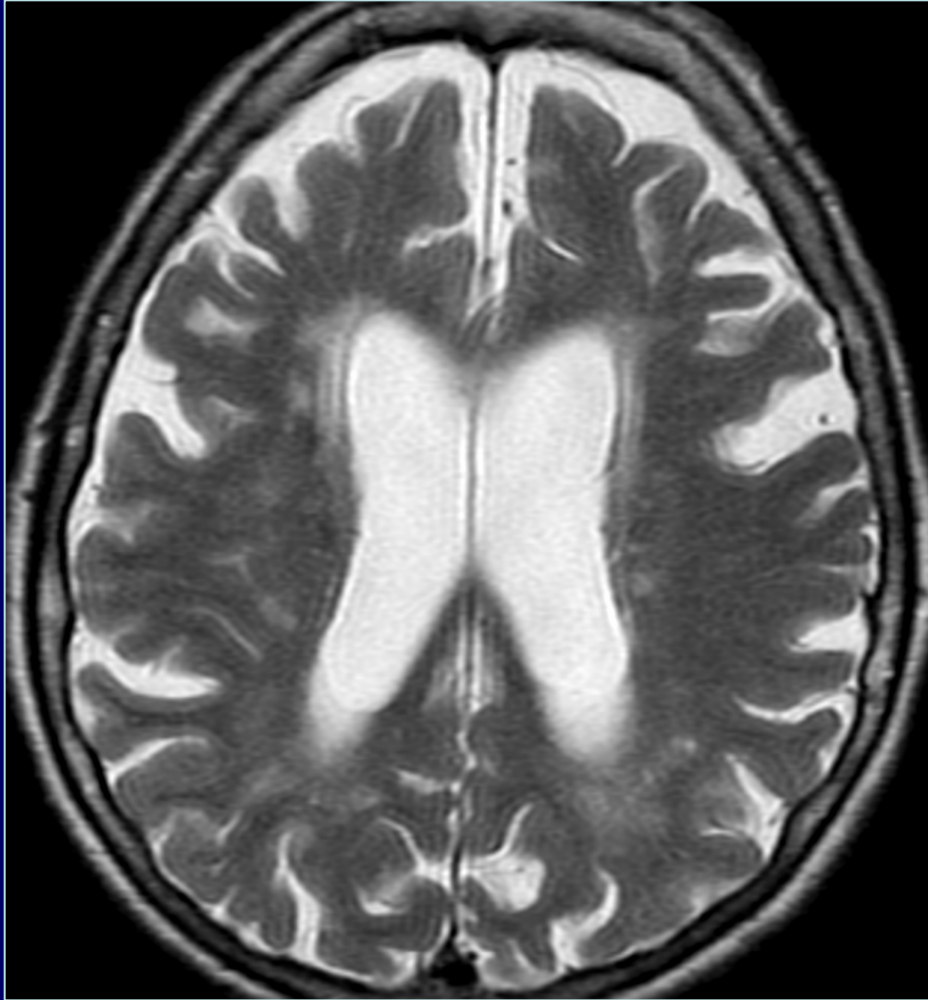
hypodensité



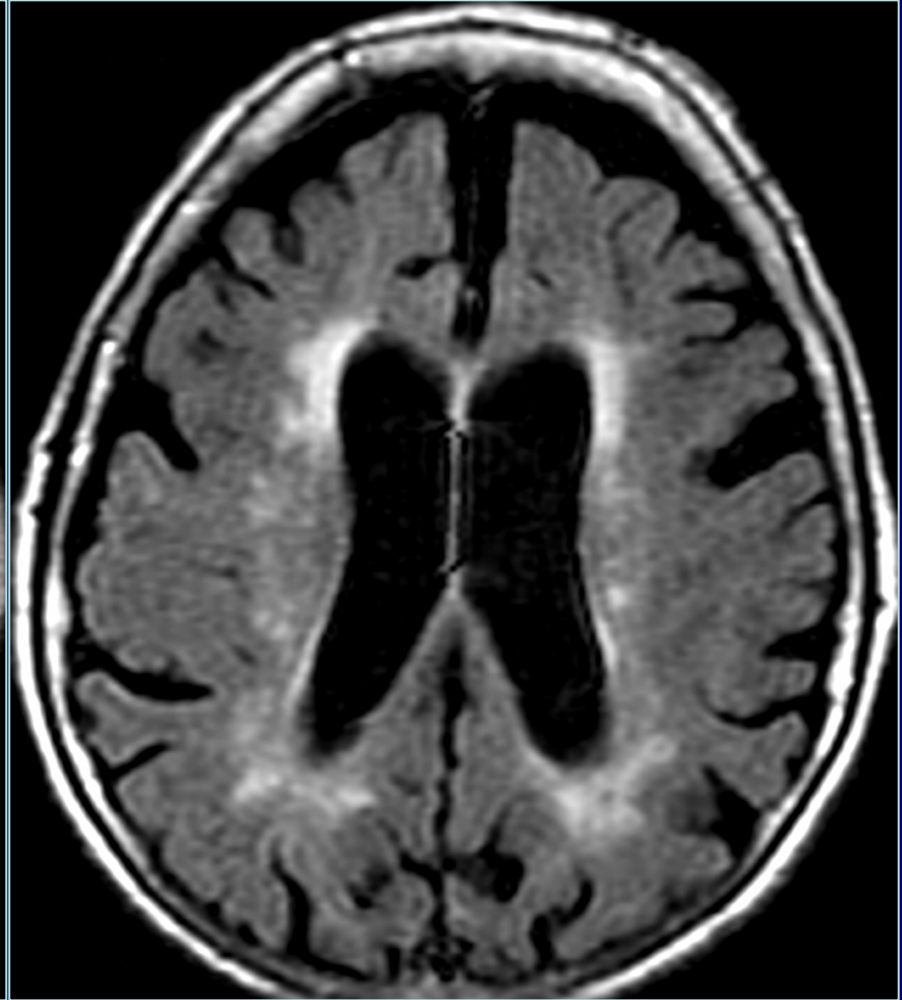
hypersignal FLAIR/T2

> 6 heures (« fenêtre thérapeutique » pour traitement thrombolytique)

<6 heures: imagerie de diffusion (Diffusion-Weighted Imaging)

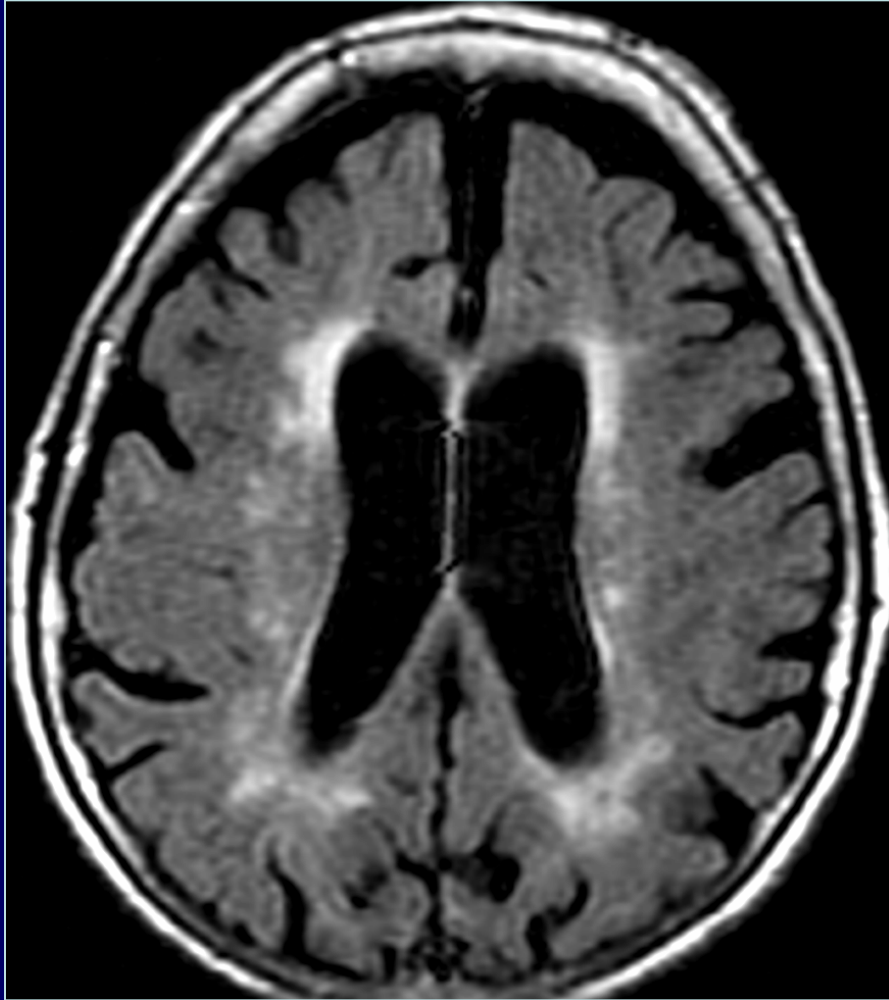


T2-FSE

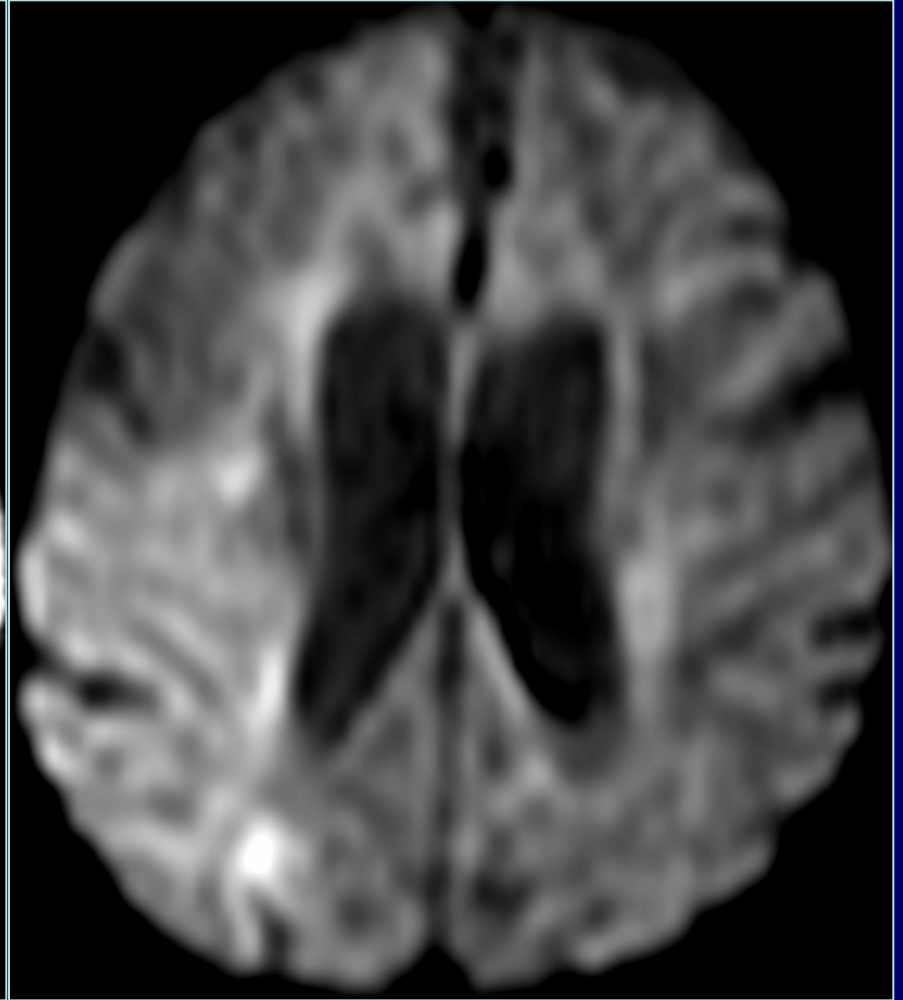


FLAIR

<6 heures: imagerie de diffusion

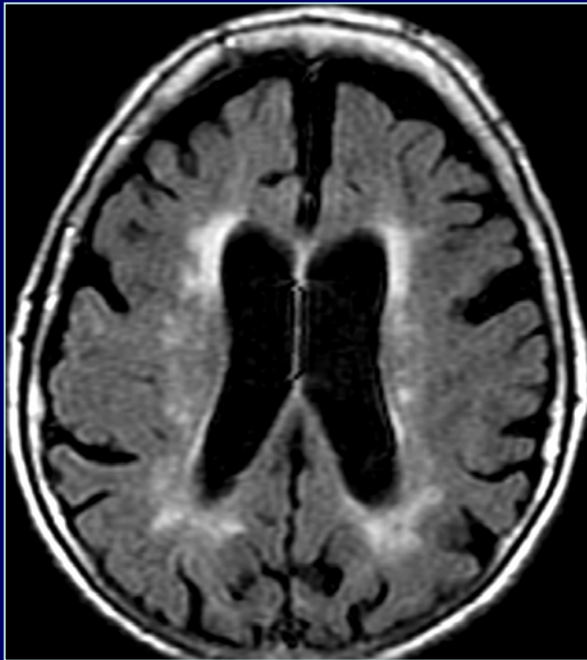


FLAIR

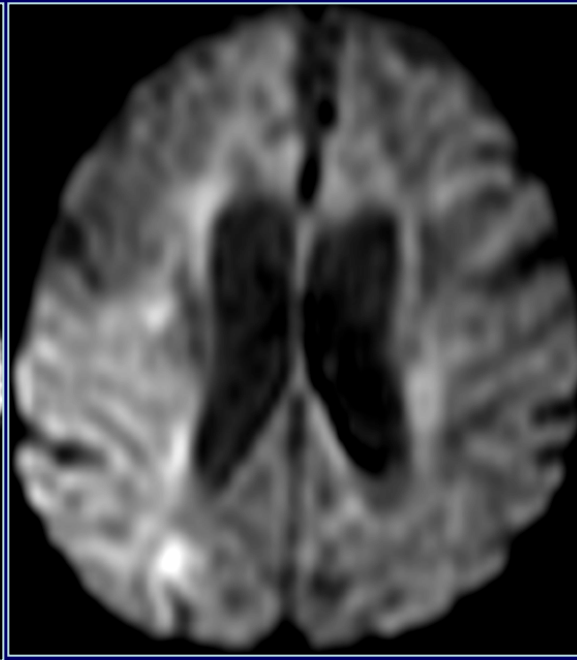


Imagerie de diffusion

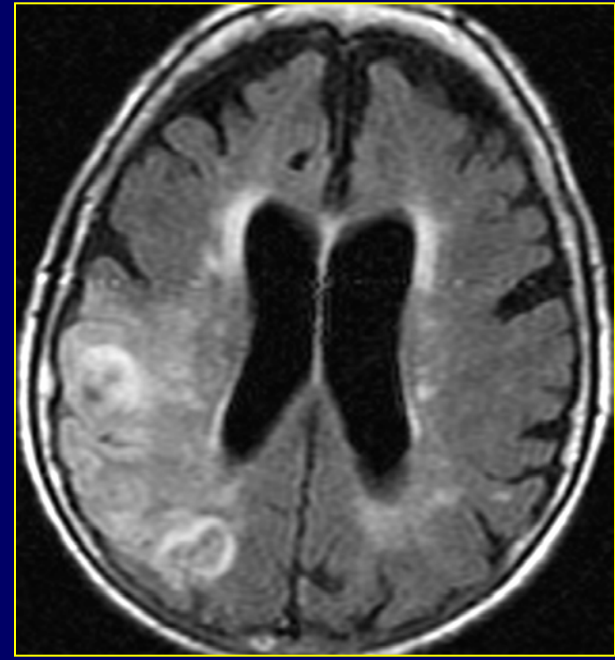
<6 heures: imagerie de diffusion



FLAIR 3 heures

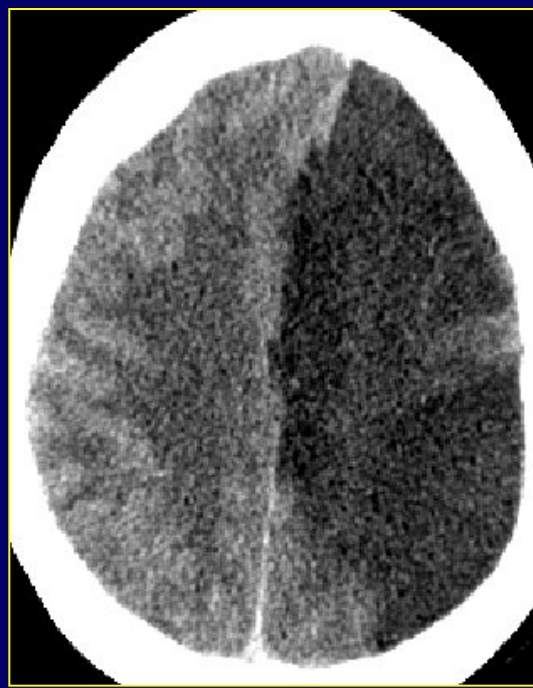
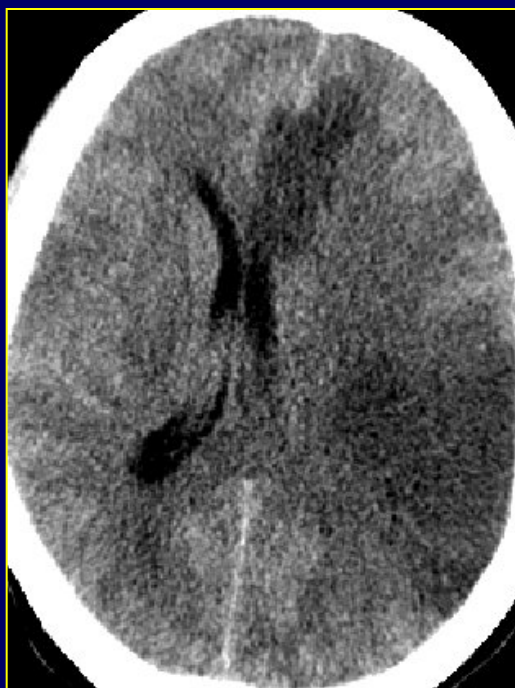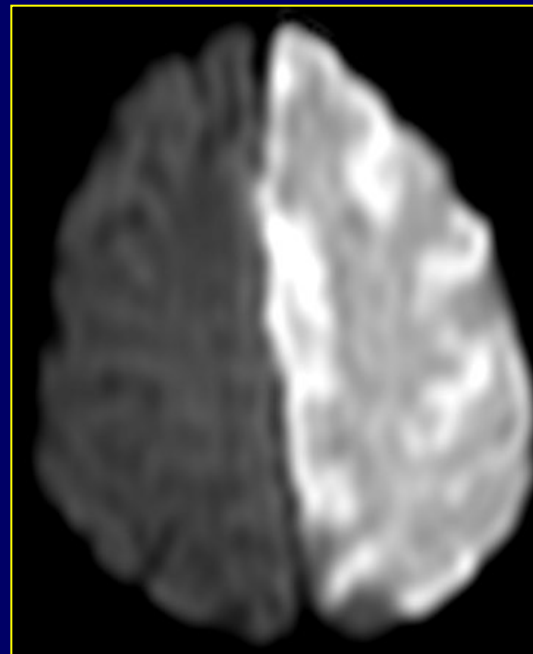
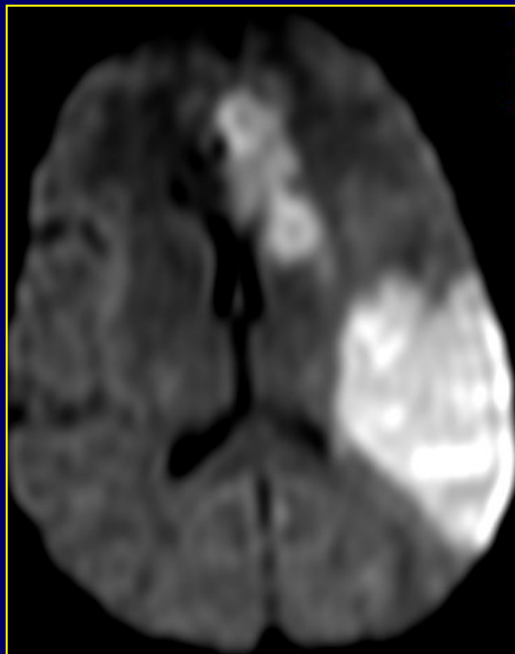


Diffusion 3 heures



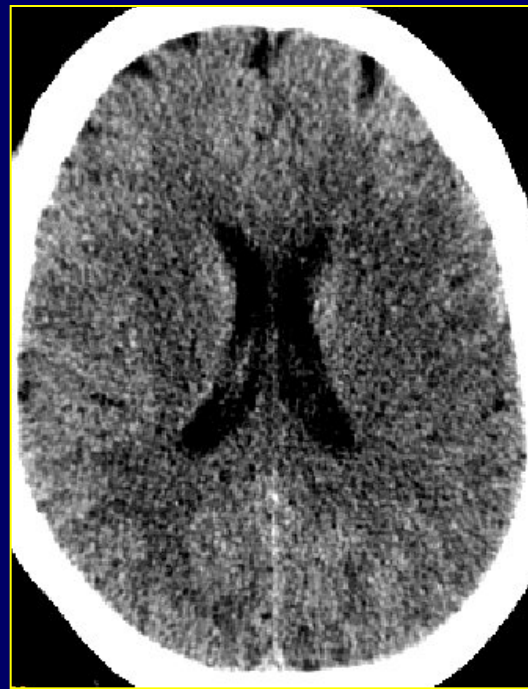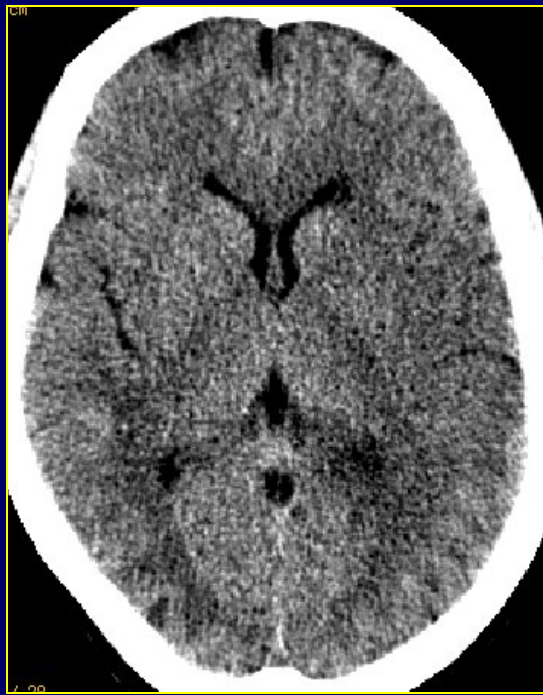
FLAIR 24 heures

72 heures

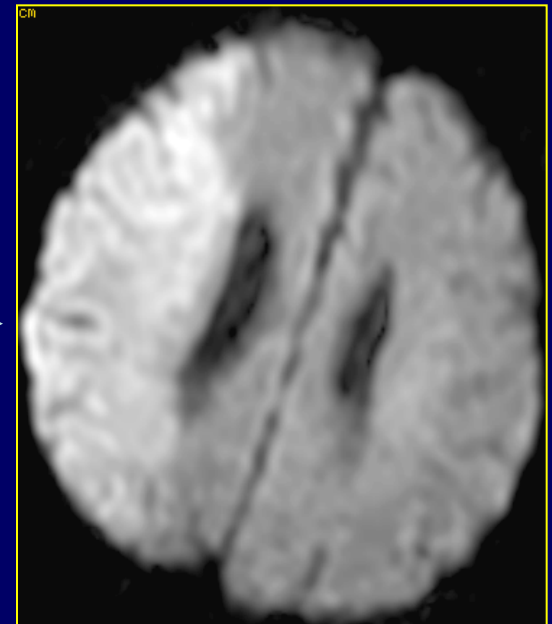
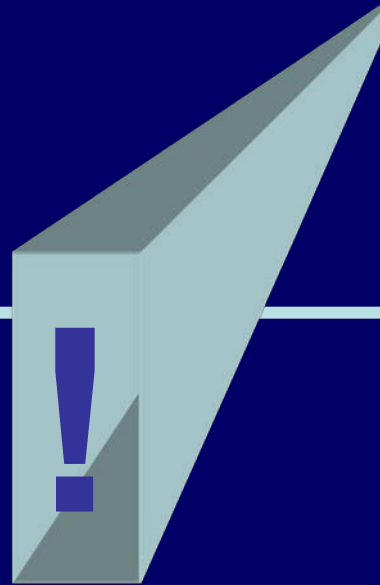
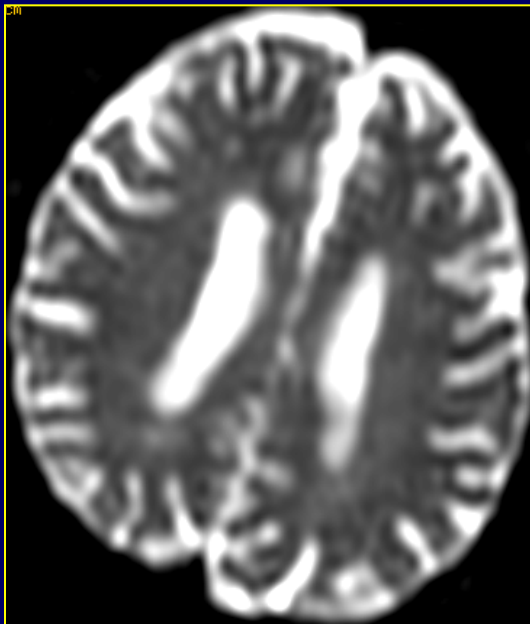


MR
=
CT

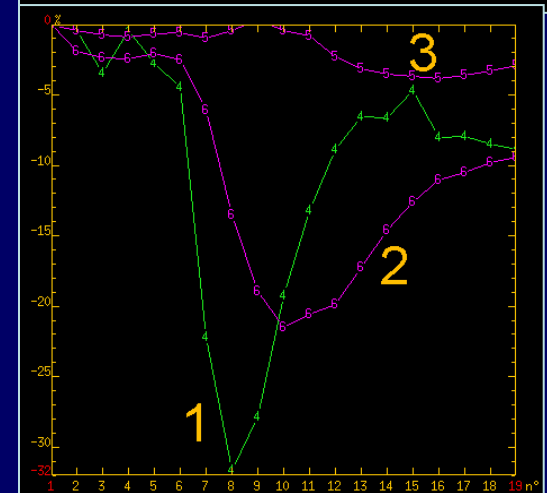
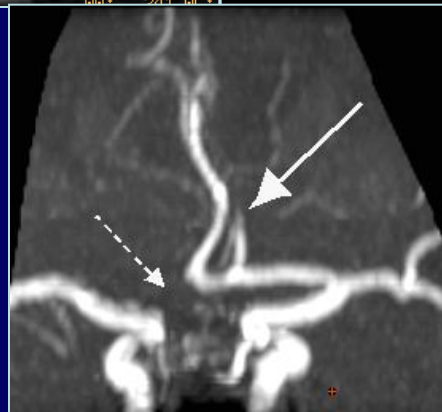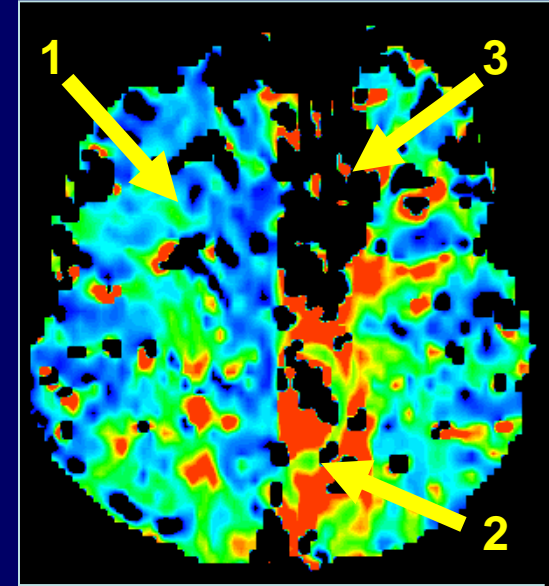
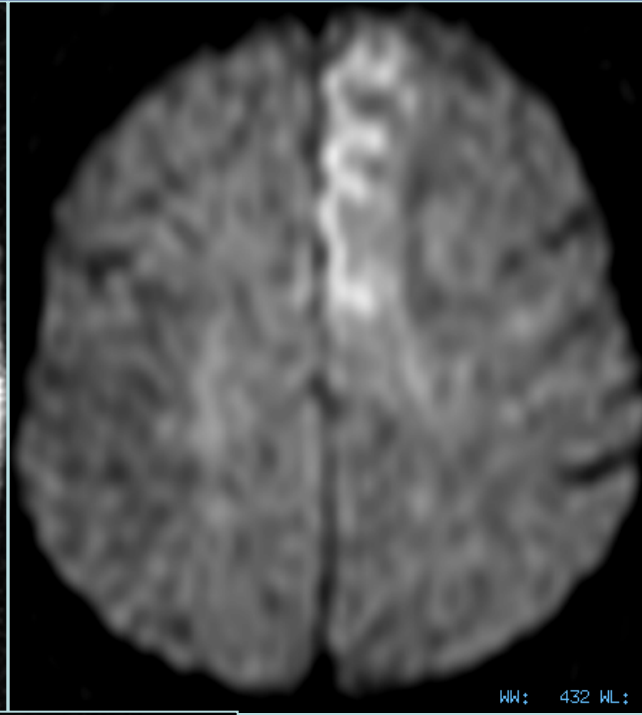
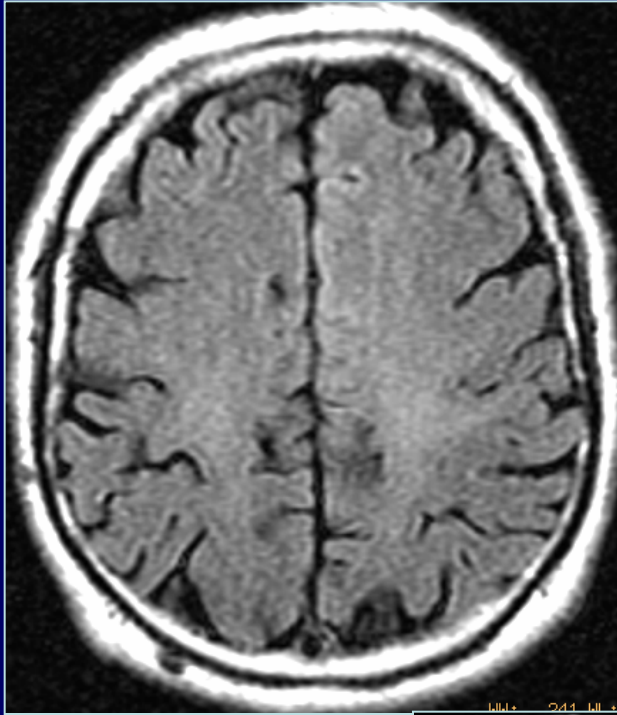
<6 heures



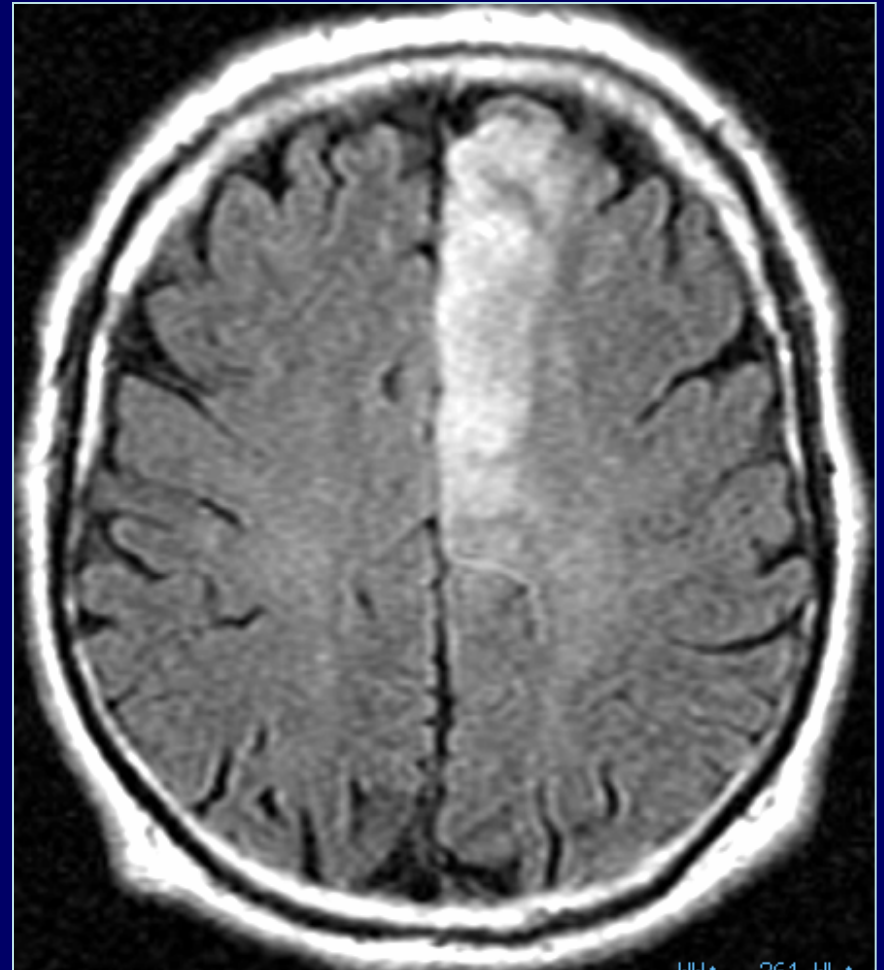
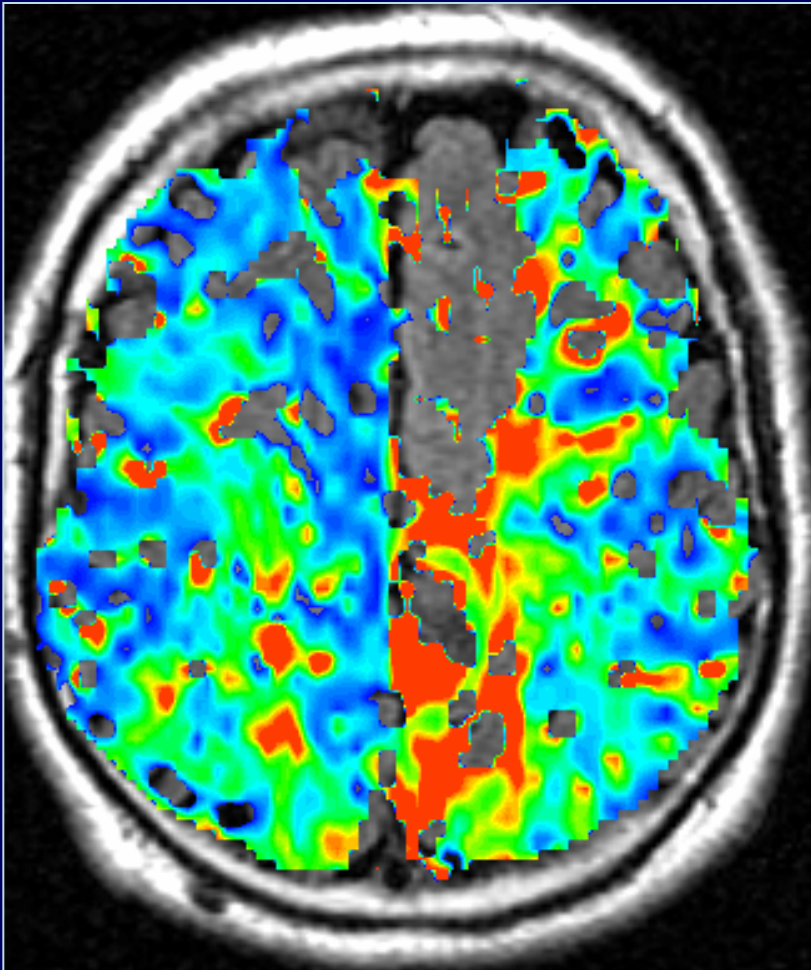
???



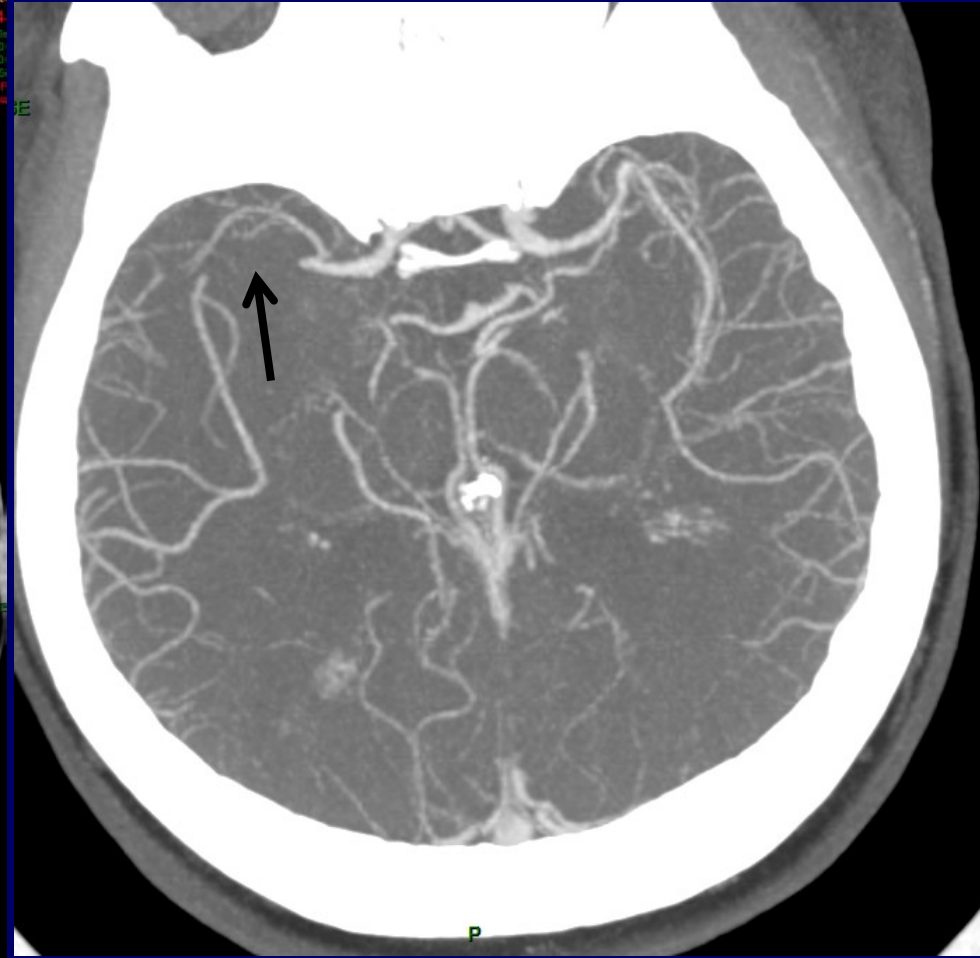
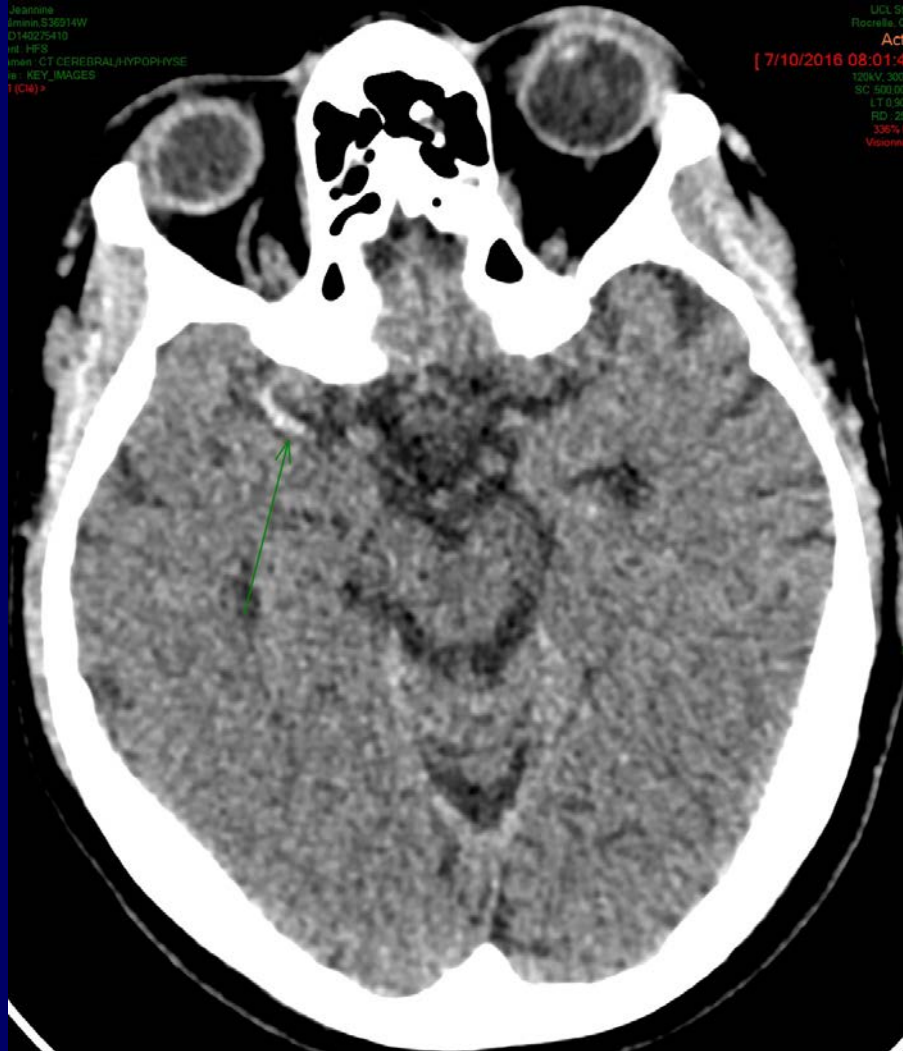
<6 heures: imagerie de perfusion (Perfusion-Weighted Imaging) (I)



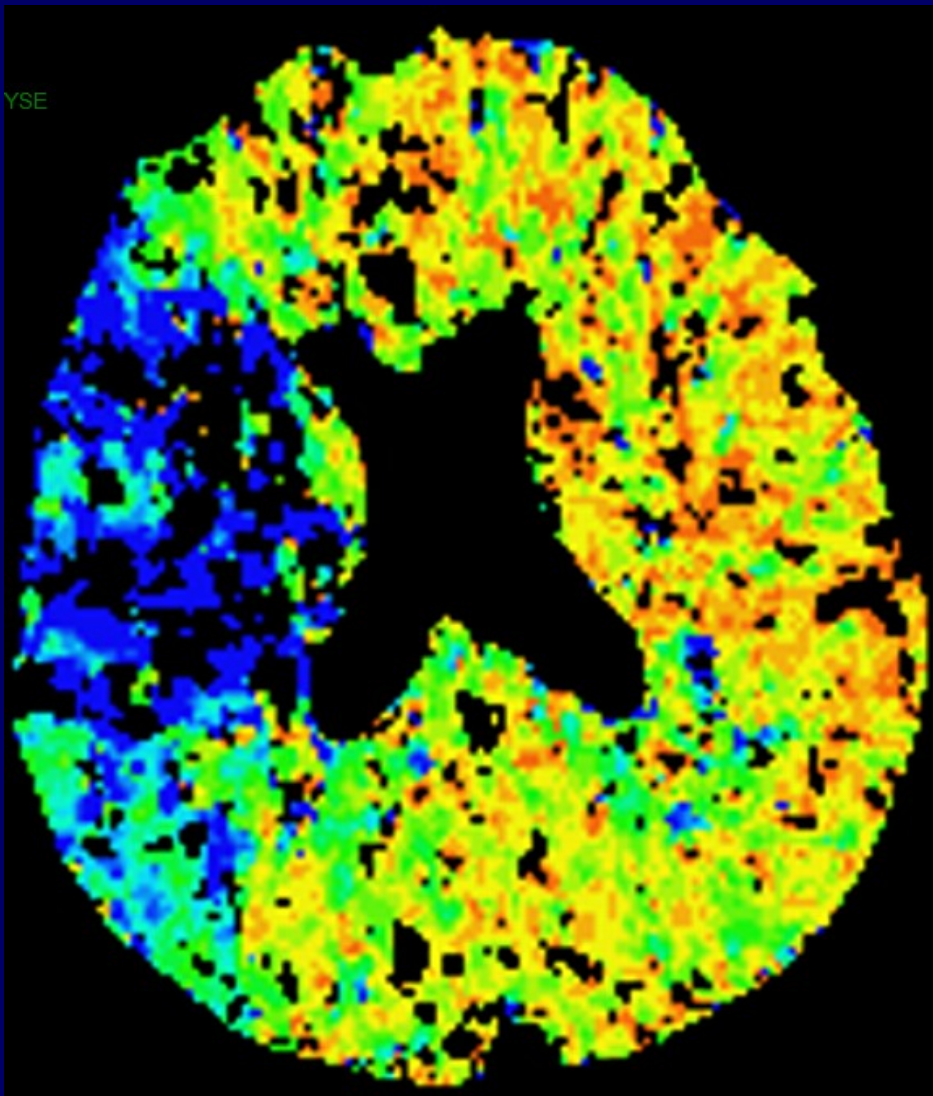
<6 heures: imagerie de perfusion (Ib)



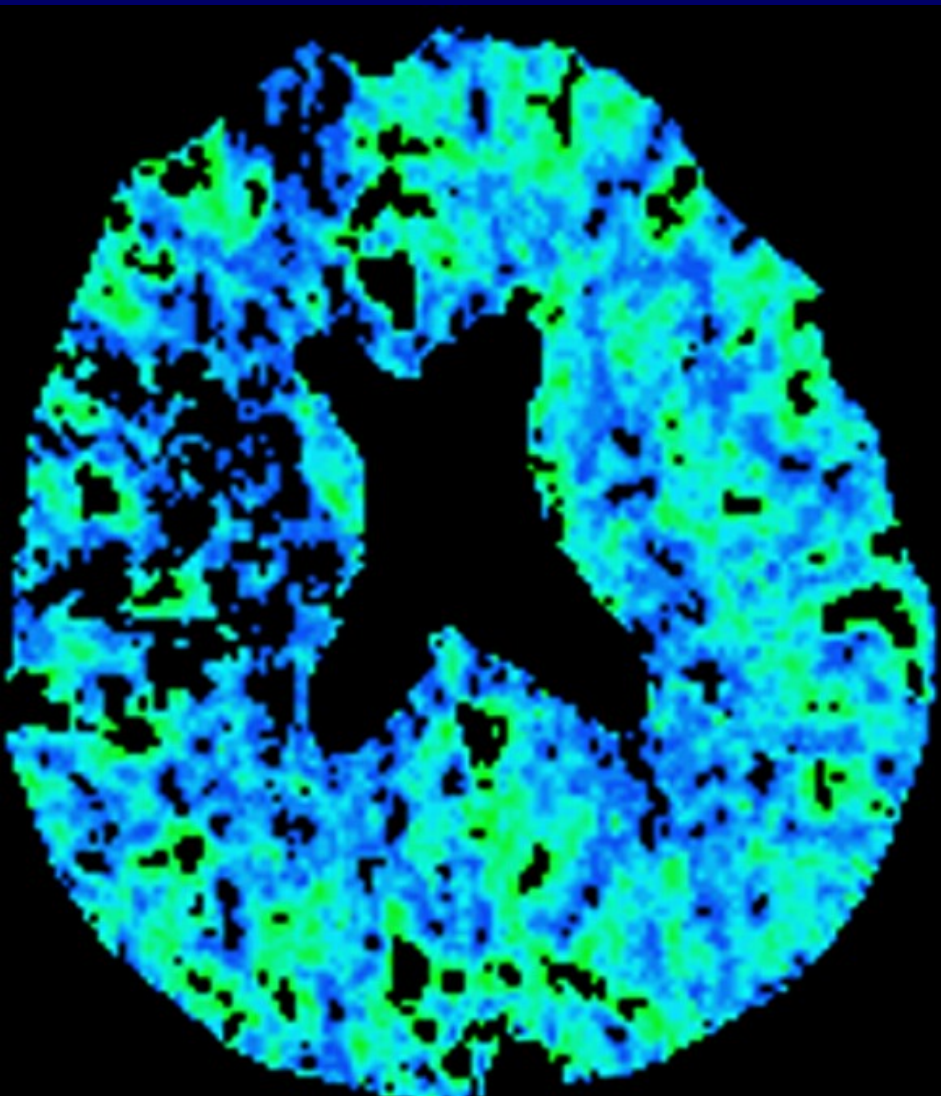
PERFUSION CT (CTP)



YSE



MTT



CBV

Pos. coupe : 187.1 mm

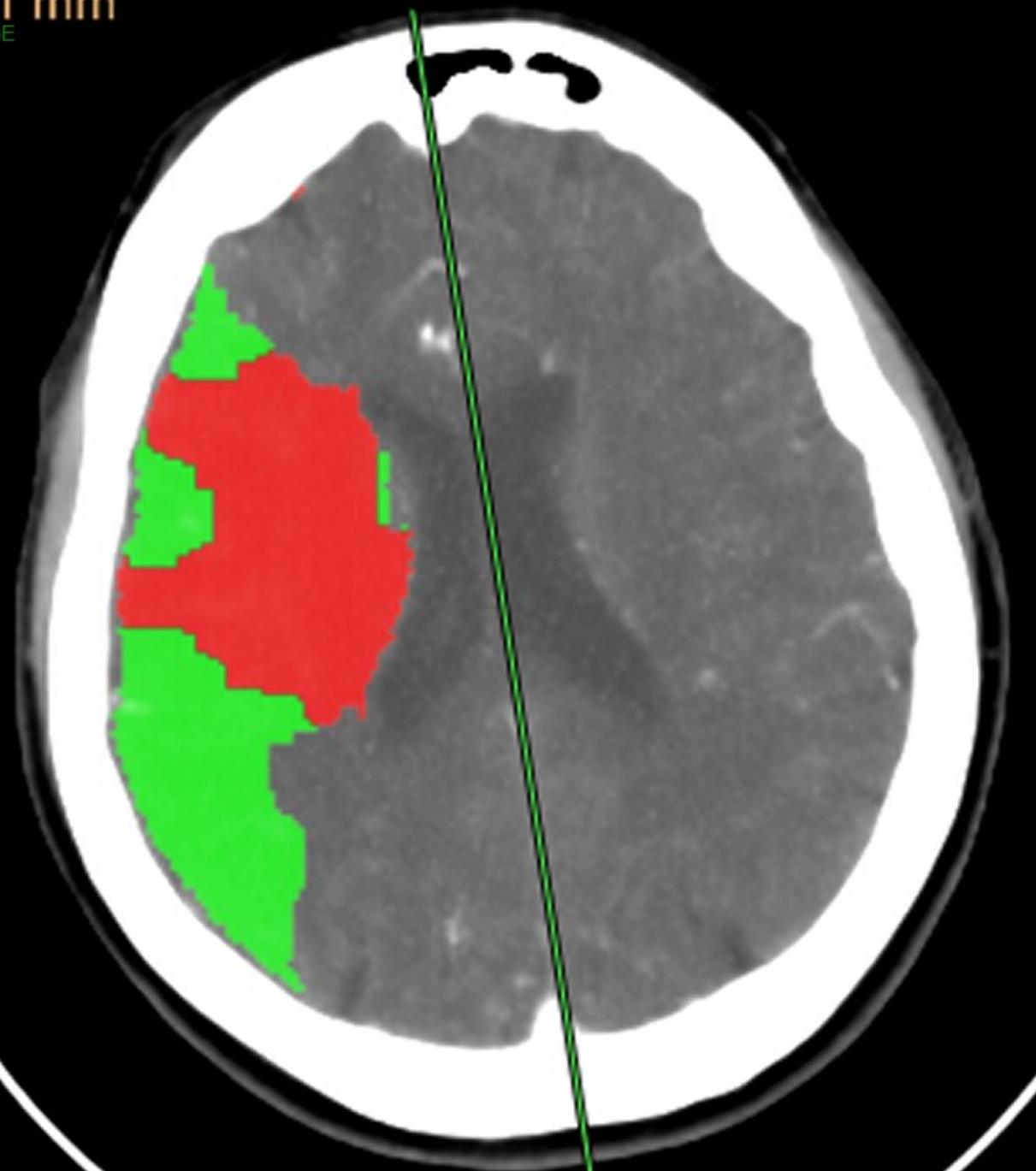Desc. examen : CT CEREBRAL/HYPOPHYSE

Desc. série : resultats perfusion

<2184 - 8 >

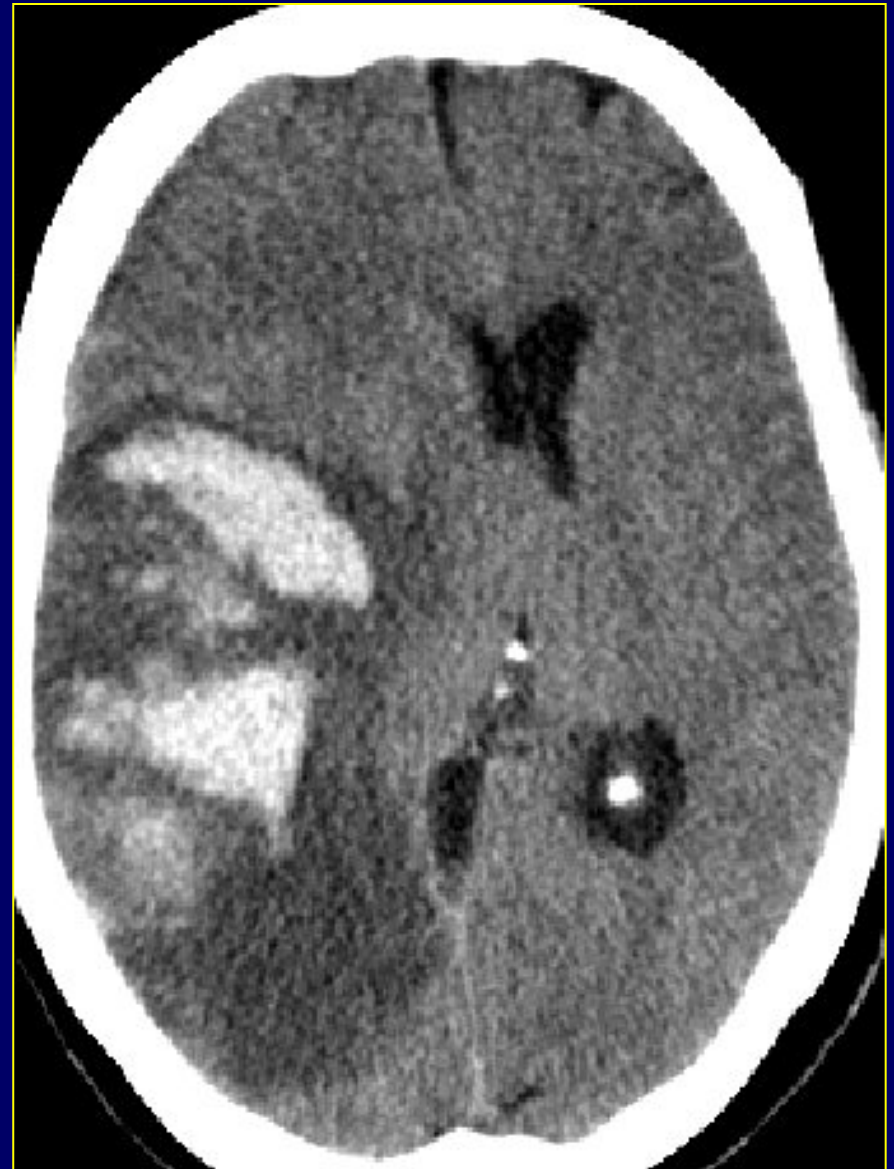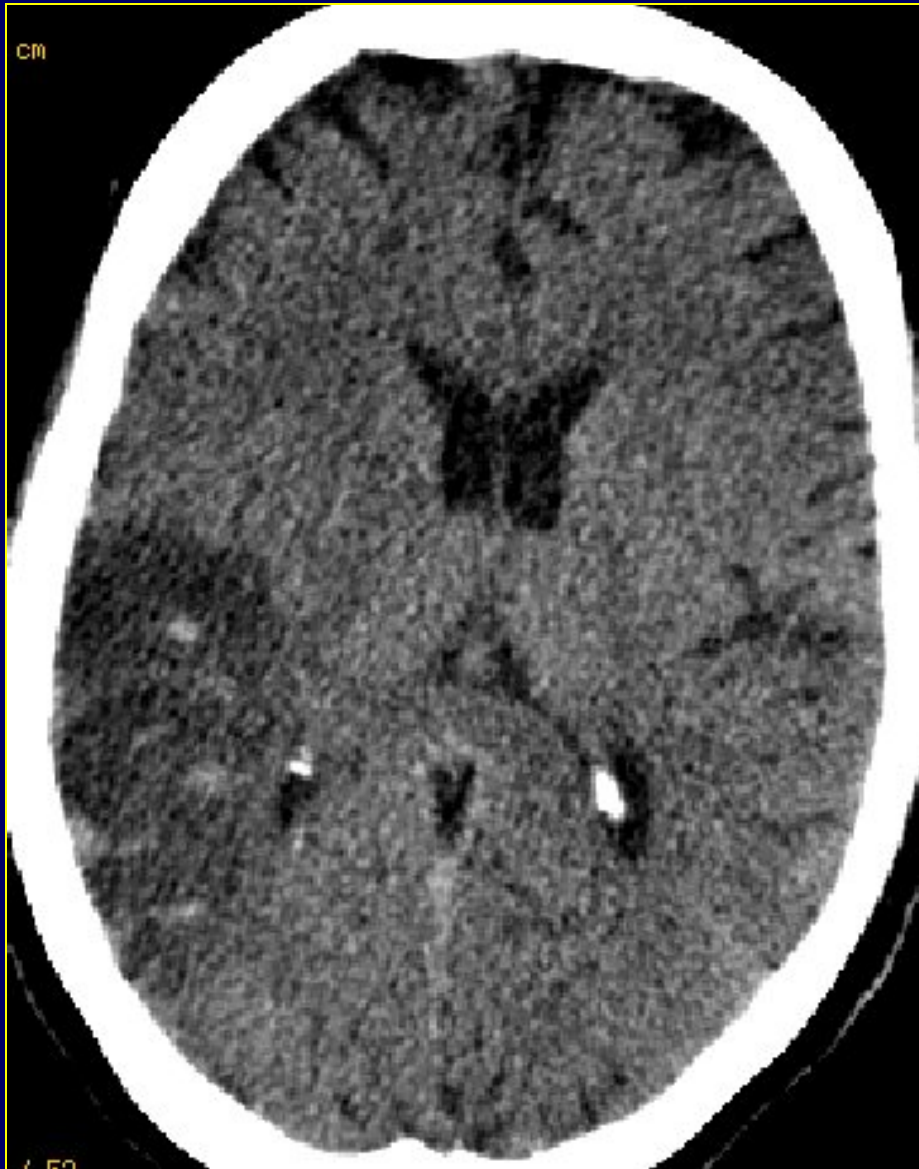
MTT aug. et
CBV norm.

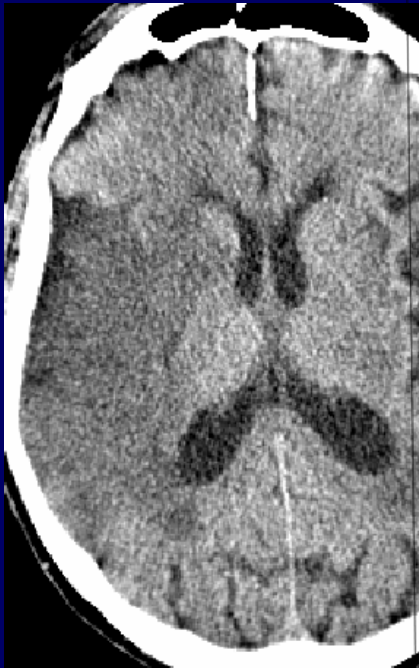
MTT aug. et
CBV rouge.



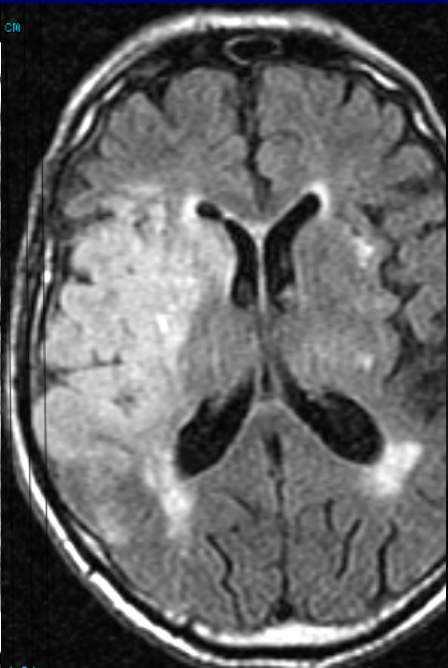
4110

Transformation hémorragique: infarctus 'blanc' devenant 'rouge'

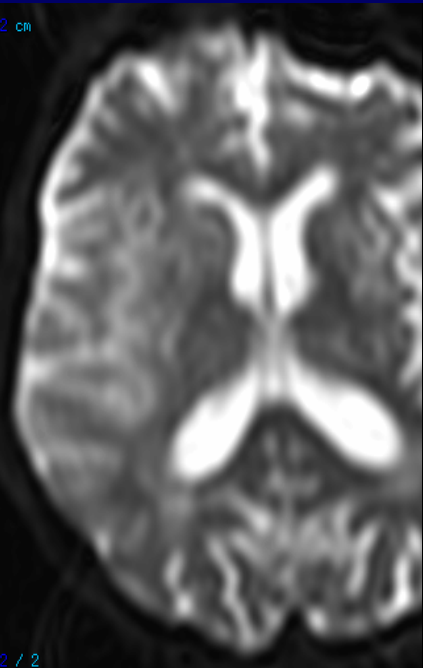




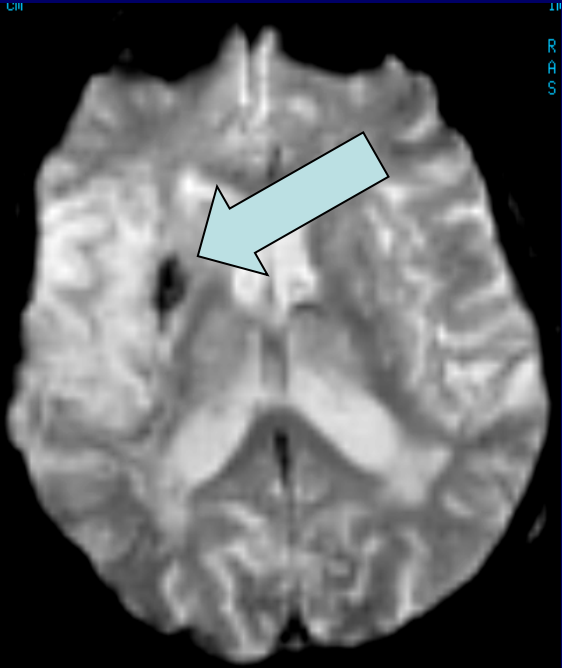
CT



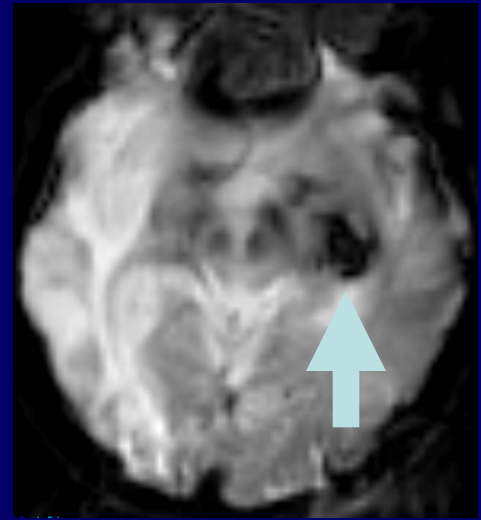
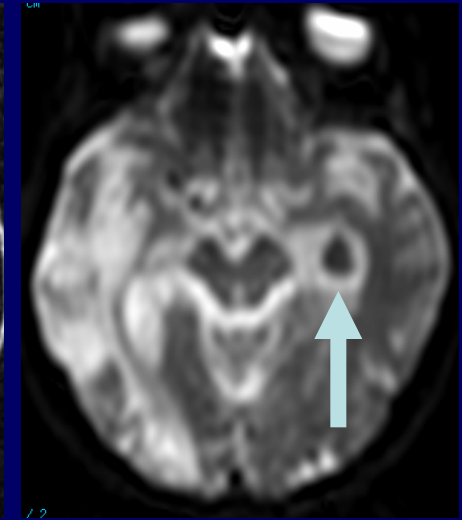
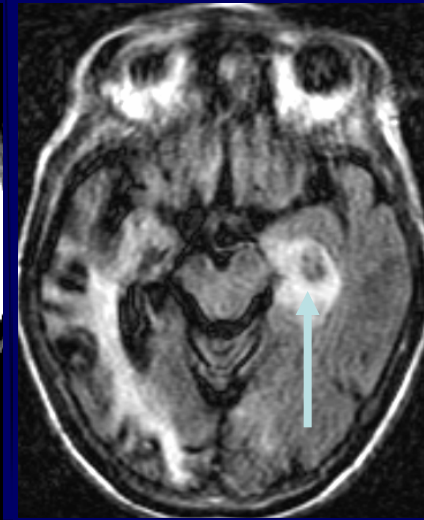
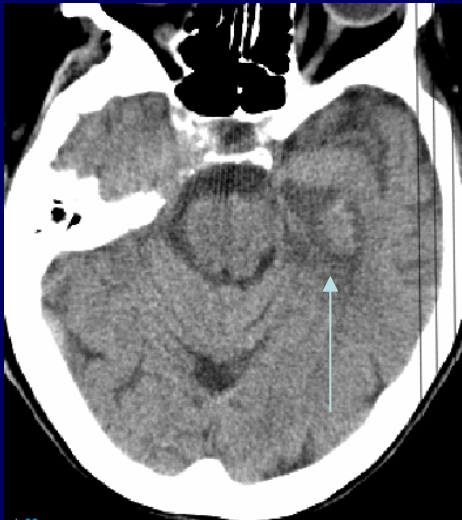FLAIR



EPI-SE-T2



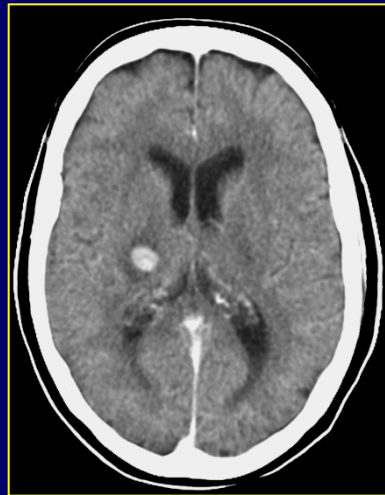EPI-GRE-T2*



Hémorragie cérébrale

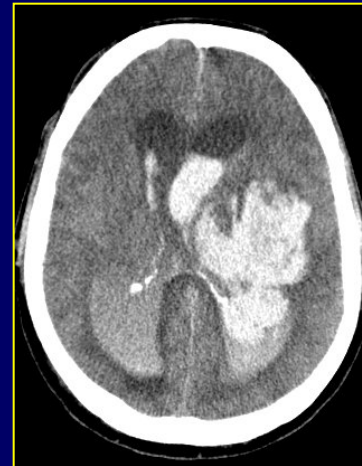Parenchymateuse
(cloisonnée)

Hématome
parenchymateux

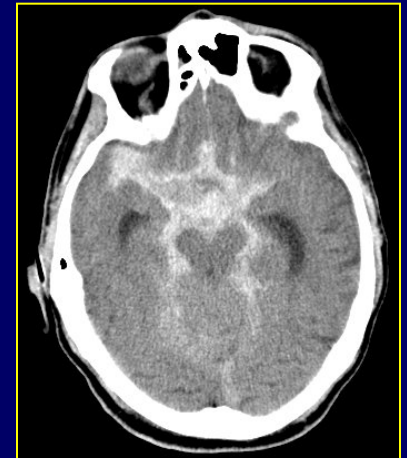

Extra-parenchymateuse
(non cloisonnée)

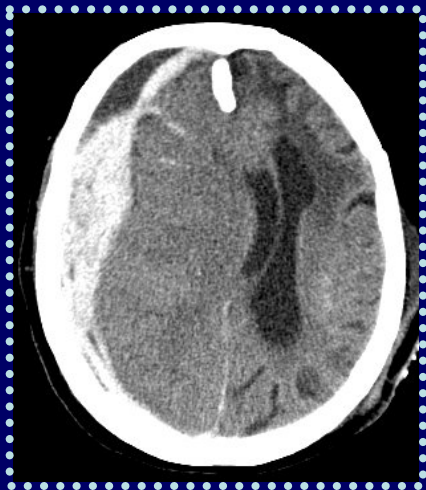Hémorragie
ventriculaire



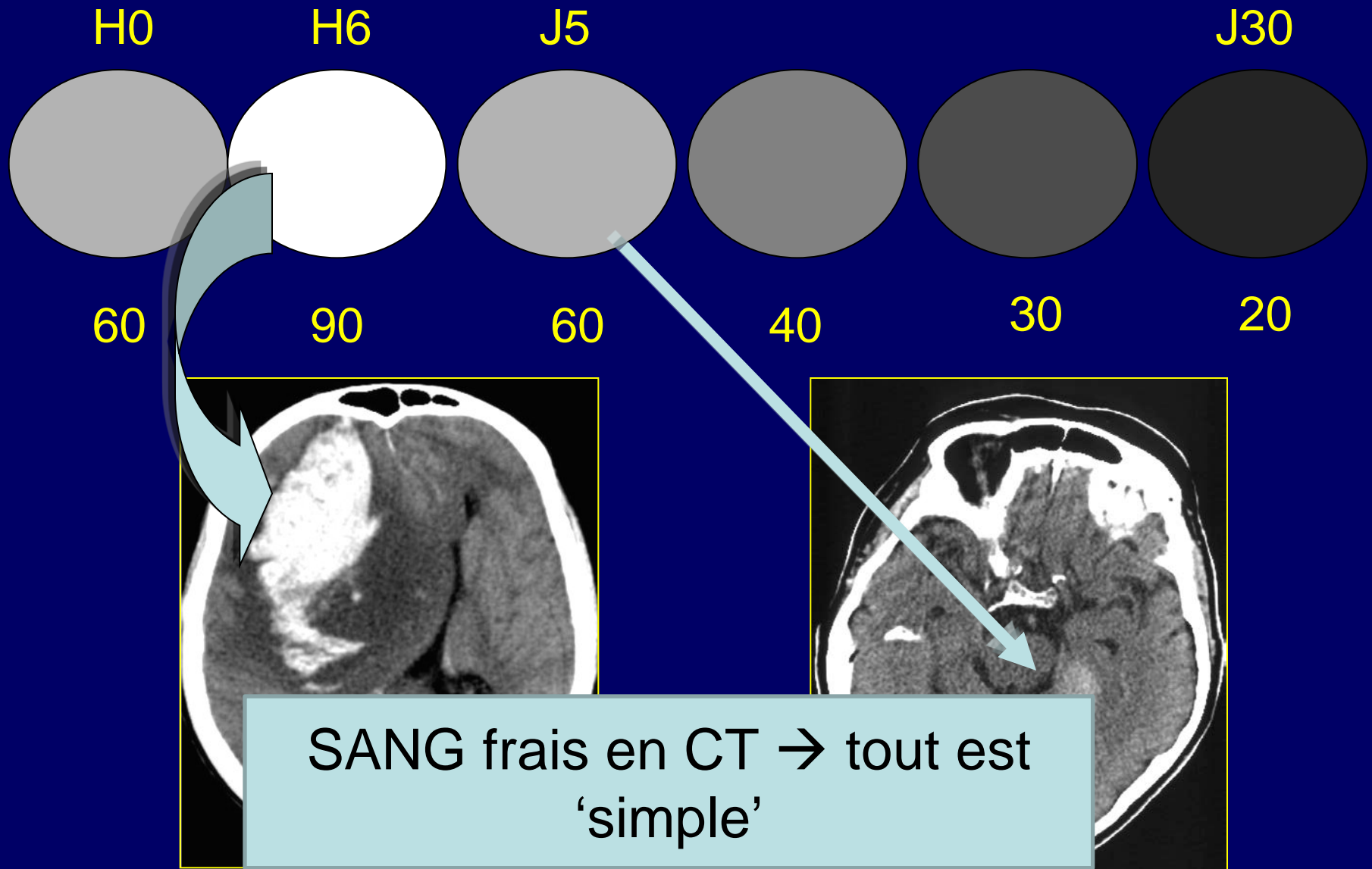
Hémorragie
méningée



Collection
Péri-cérébrale

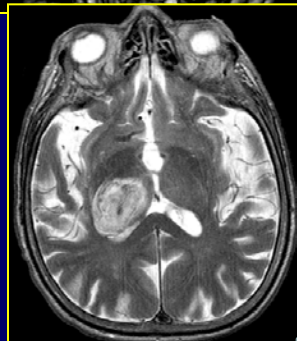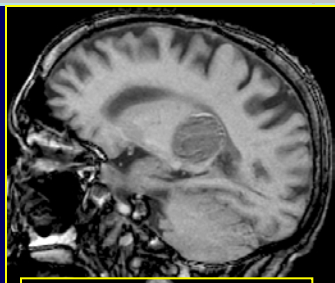


Hématome parenchymateux en TDM

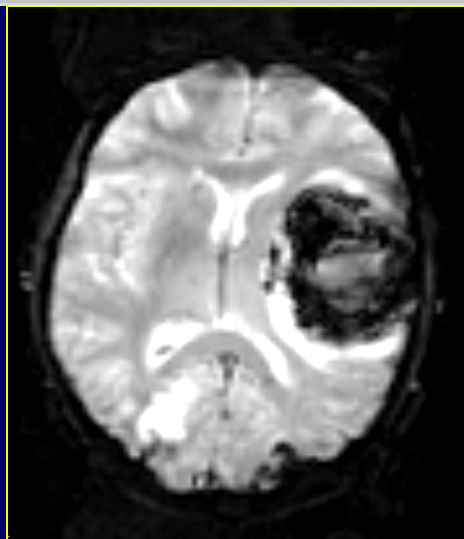


Hématome parenchymateux IRM

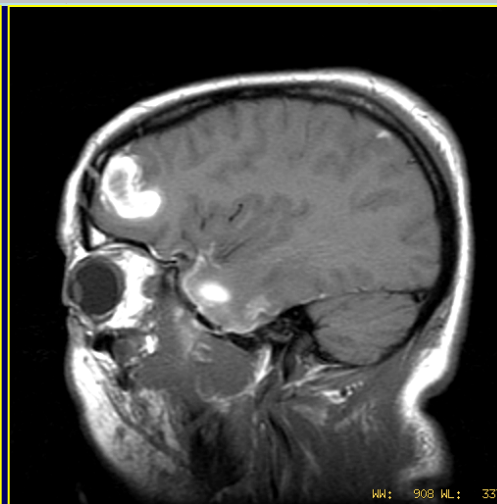
Délai	< 3 heures	4-24 heures	> 48 heures	1 semaine	1 mois
Pondération T1	hypo/iso	iso	hyper	hyper	hypo
substrat du signal	<i>oxyHb</i>	<i>oxyHb</i>	<i>metHb IC</i>	<i>metHb EC</i>	<i>liquide EC</i>
Pondération T2	hyper	hypo++*	hypo	hyper	hyper
substrat du signal	<i>serum</i>	<i>déoxyHb</i>	<i>déoxyHb</i>	<i>metHb EC</i>	<i>liquide EC</i>
					couronne hypo++*
* mieux mis en évidence par susceptibilité magnétique (séquence en écho de gradient)					<i>hémossidérine</i>
EC=extracellulaire / IC=intracellulaire					



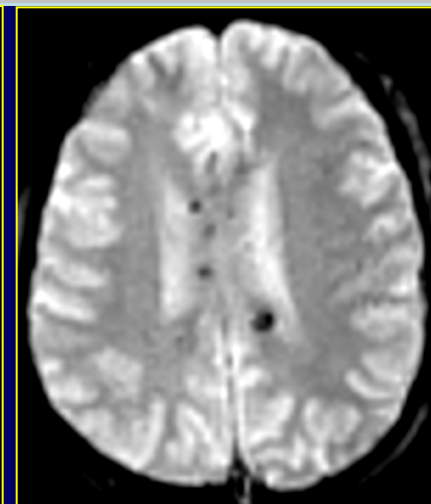
eau



déoxyHb → hypoT2



metHb → hyperT1



hémossidérine → hypoT2

SANG frais en IRM → tout est compliqué

Sang frais endocrânien

→ Rechercher une cause sous-jacente

→ Malformative vasculaire MAV/fistule >> cavernome

→ Tumeur

→ Séquence de susceptibilité SWI, GRE-T2*, EPI-GRE-T2*

→ non pas pour le foyer hémorragique

→ pour trouver ailleurs un effet de susceptibilité
d'origine sanguine pour cerner un contexte spécifique:

→ Cavernomatose

→ Hémosidérose méningée

→ Angiopathie amyloïde

→ Injecter le PdC en CT scanner (en garde !)

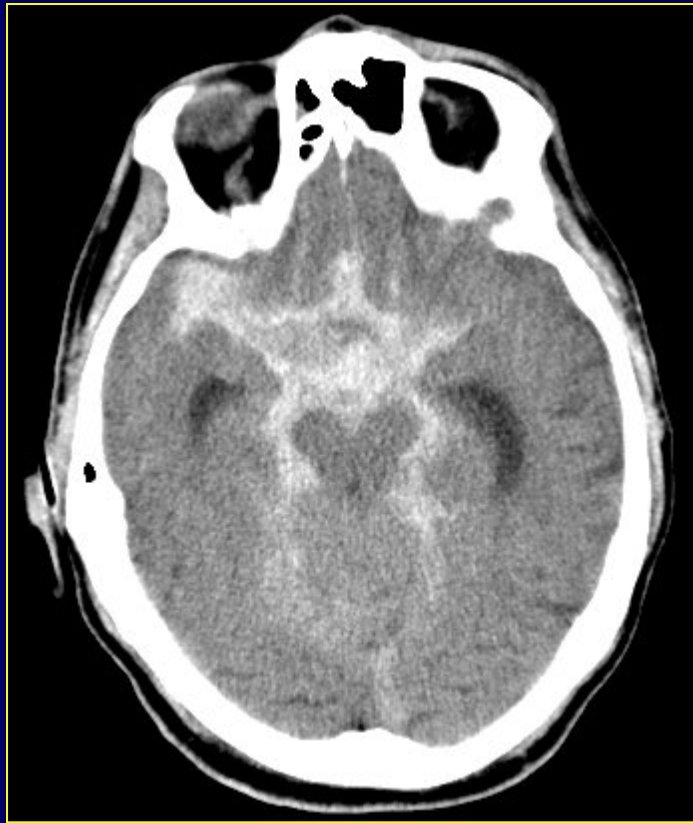Hémorragie sous-arachnoïdienne

**Diagnostic
radiologique
positif
d'HSA**

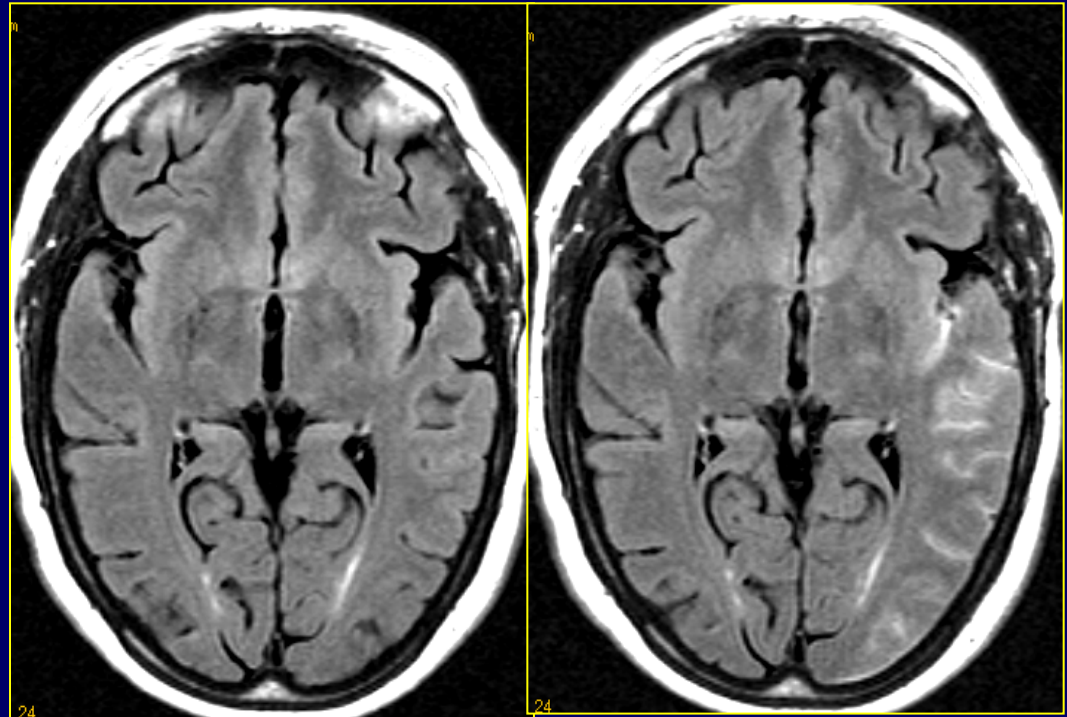


**Rupture
d'anévrisme
sacculaire
intra-cranien
85%**

1.  Diagnostic (+) d'HSA



CT scan

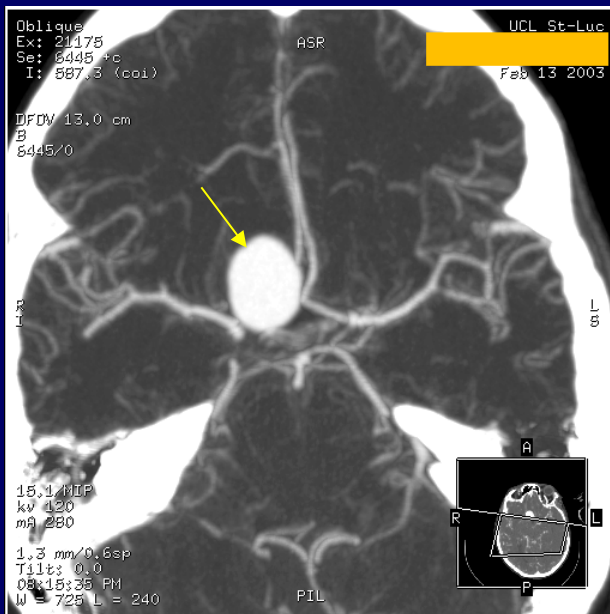
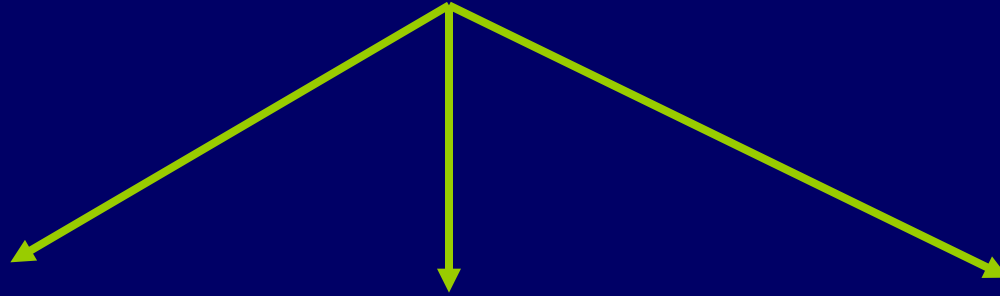


(-)

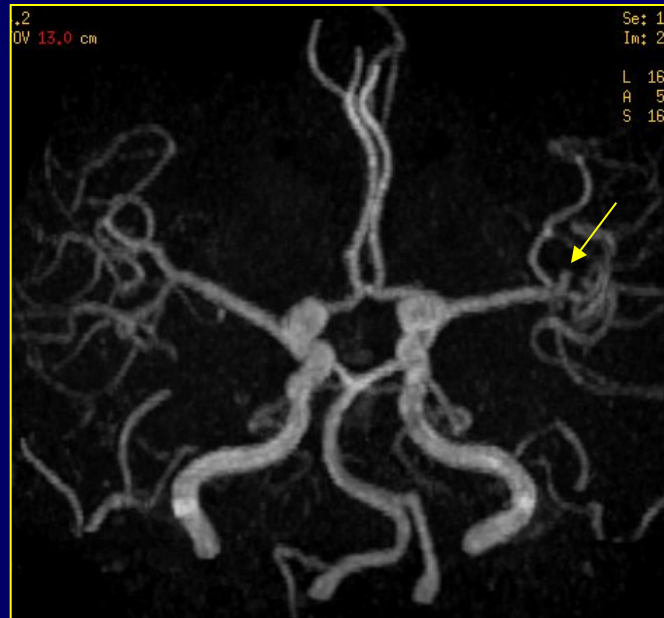IRM

(+)

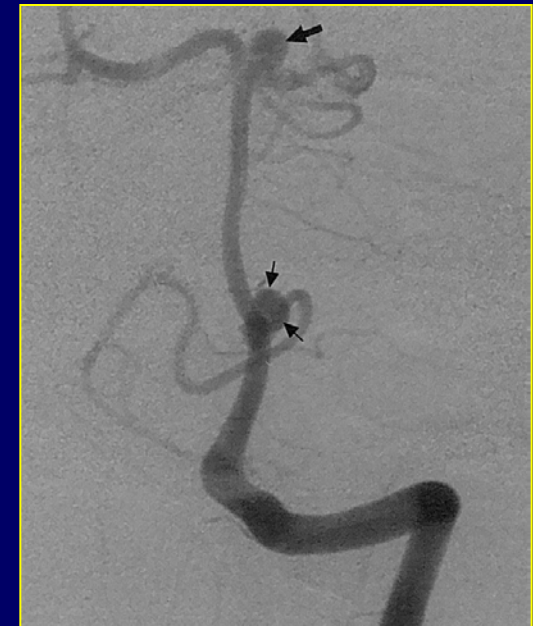2. Localisation de l'anévrisme causal



Angio-CT

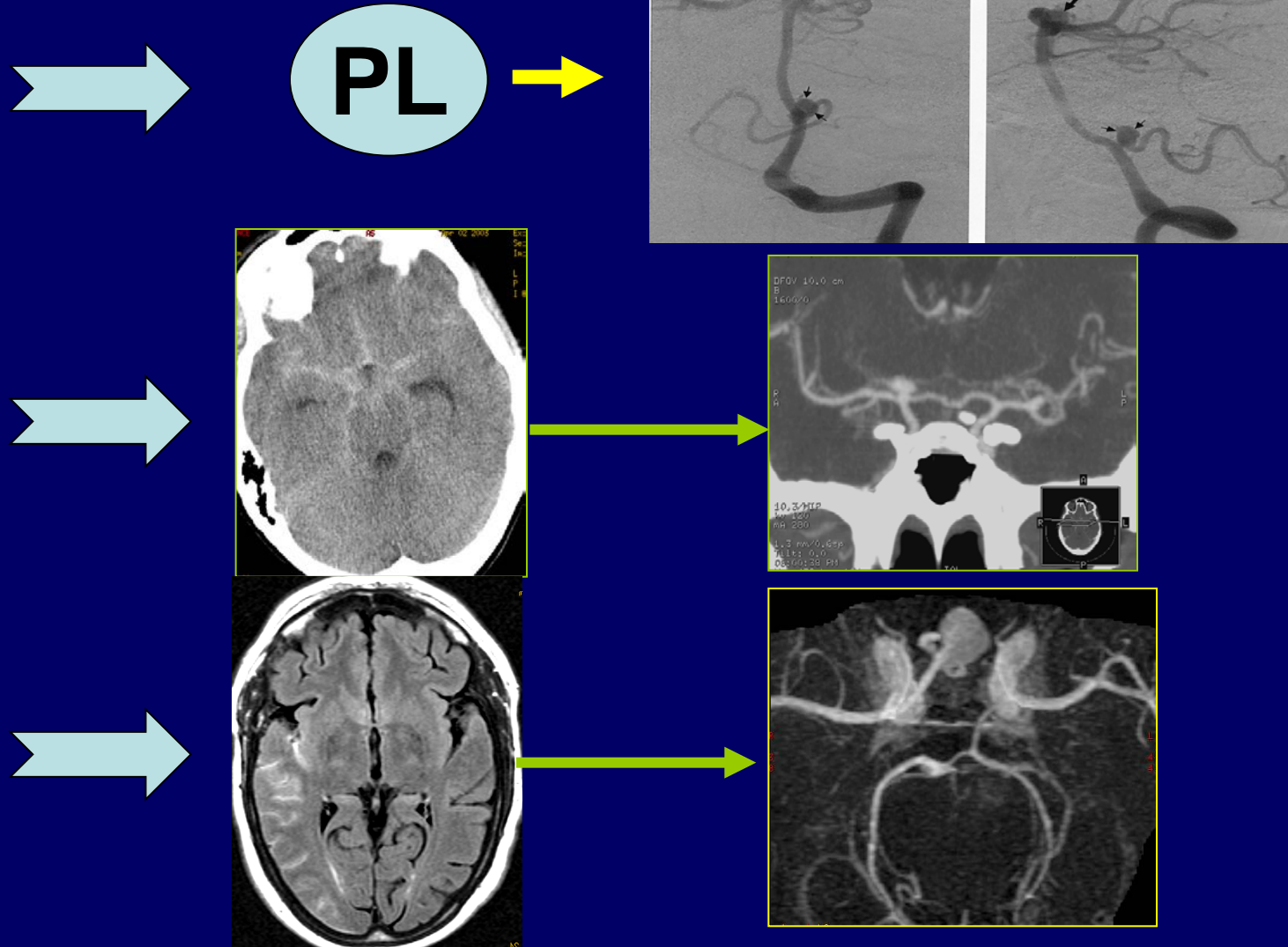


Angio-IRM

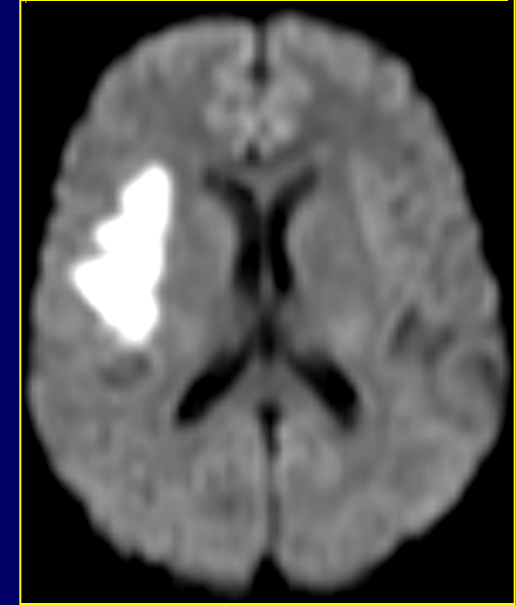
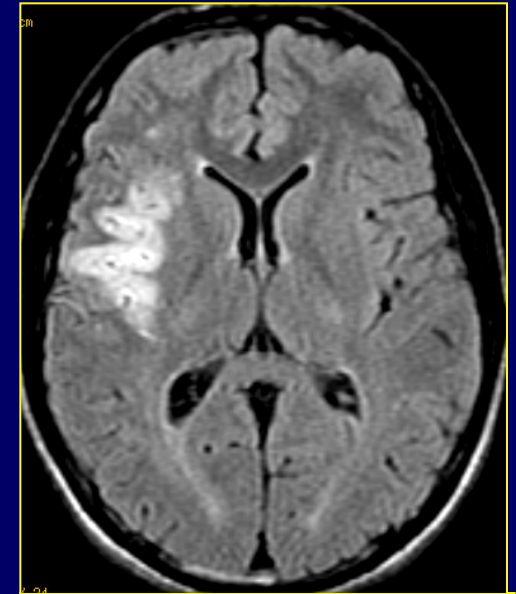
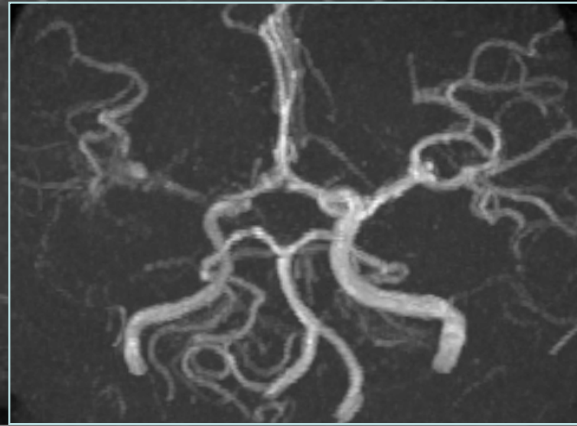
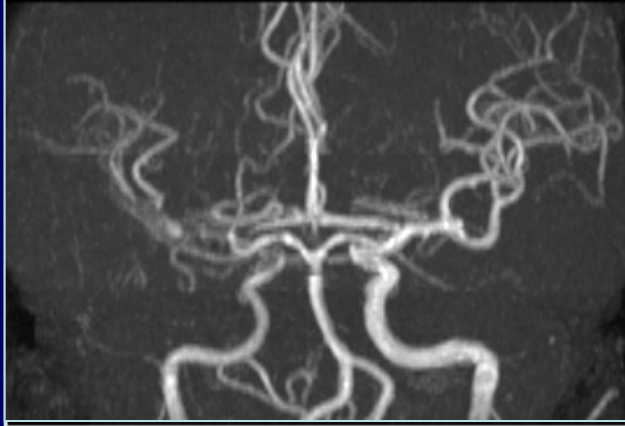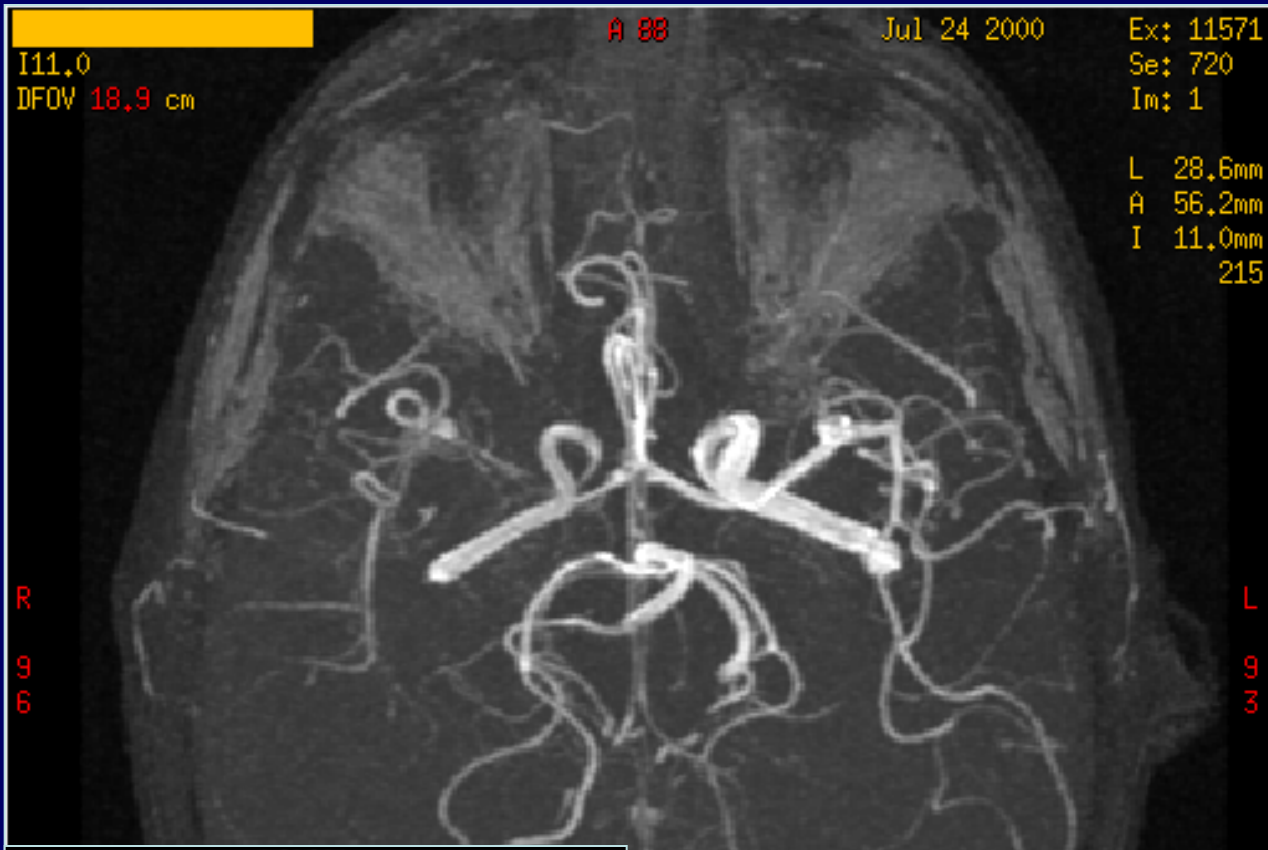


Angiographie

Diagnostic positif et étiologique d'HSA



Spasme artériel



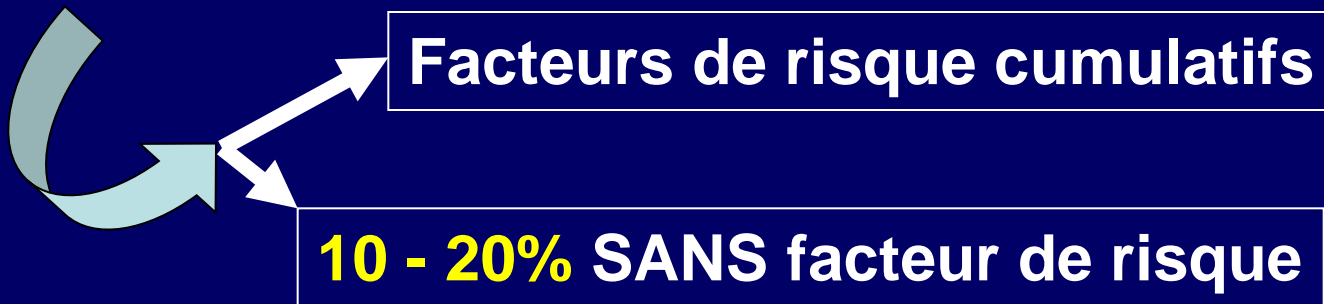
➔ Rare: < 1 case / 10.000/an

➔ Facteurs de risque


hypercoagulabilité systémique

±

infections ou dommage tissulaire local



➔ Diagnostic clinique non *univoque*



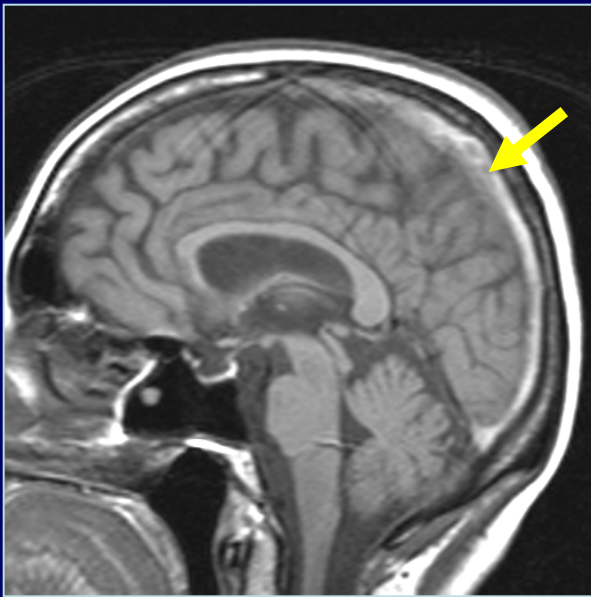Place majeure de l'imagerie

➔ Forme maligne: évolution fatale en dépit d'un R/ adhoc

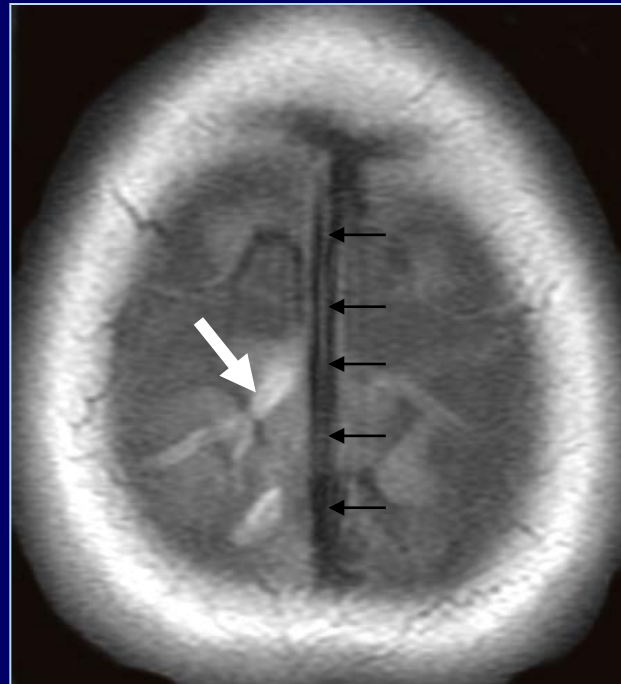
intrathrombus rtPA

rheolytic
thrombectomy

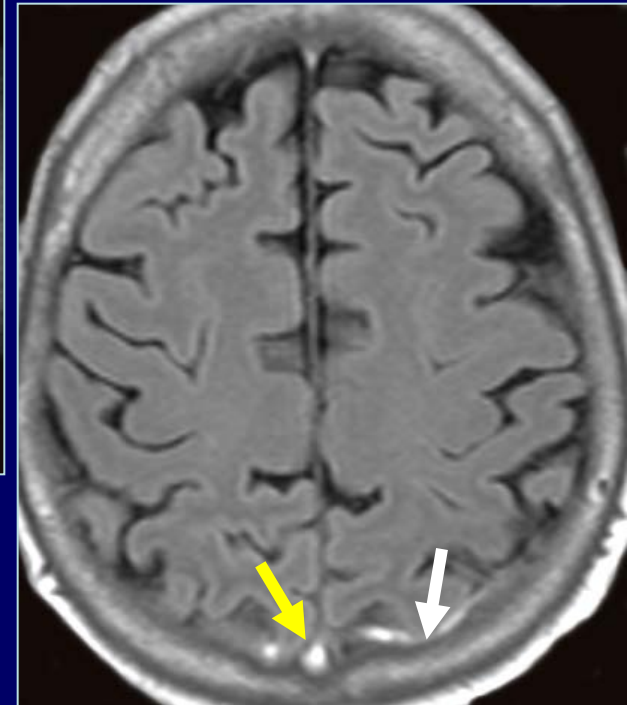
Localisations de la thrombose veineuse



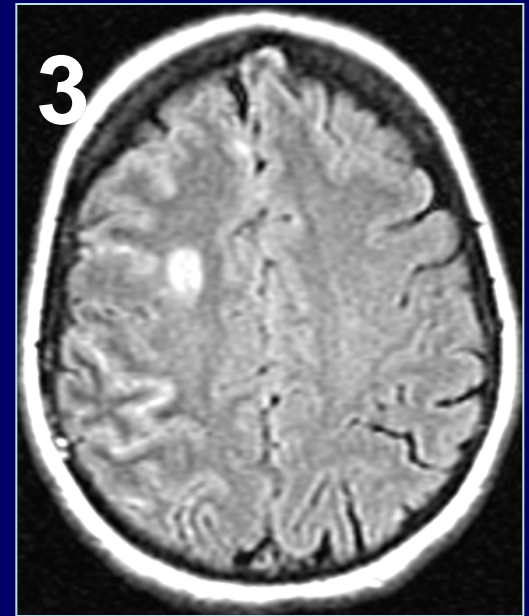
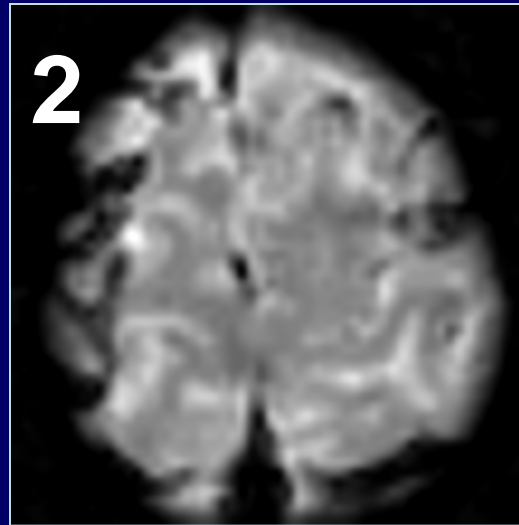
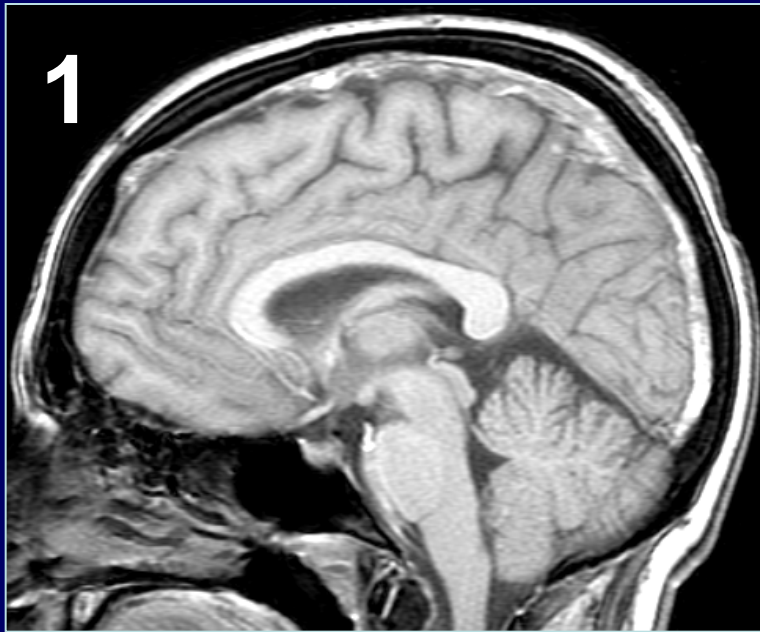
**Dural sinus thrombosis
(‘deep’ CVT)**



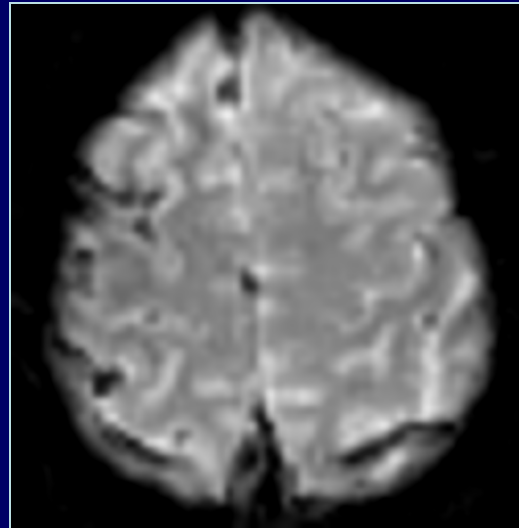

**Cortical vein thrombosis
(‘superficial’ CVT)**



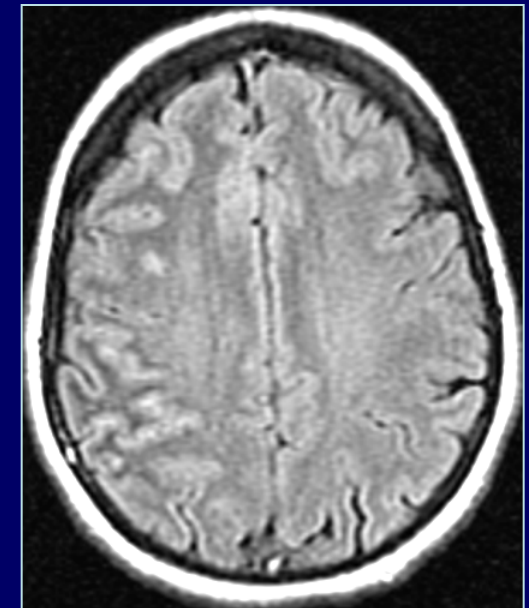
**Deep & superficial
Dural & cortical**



**venous
occlusion**



**draining veins
stasis**

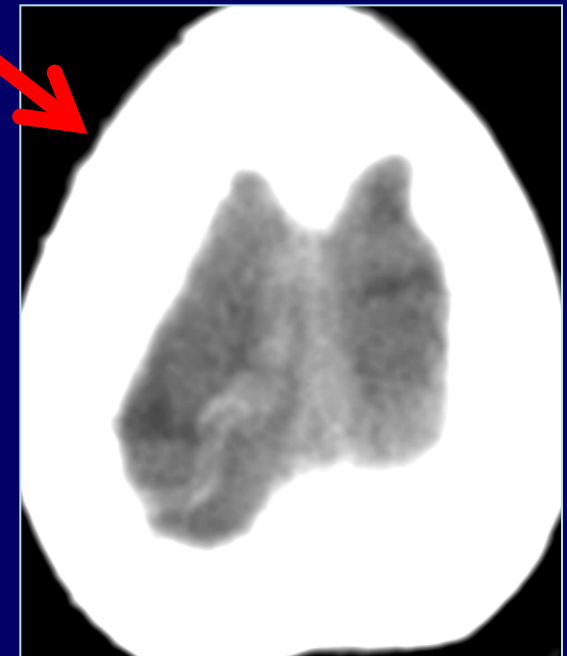
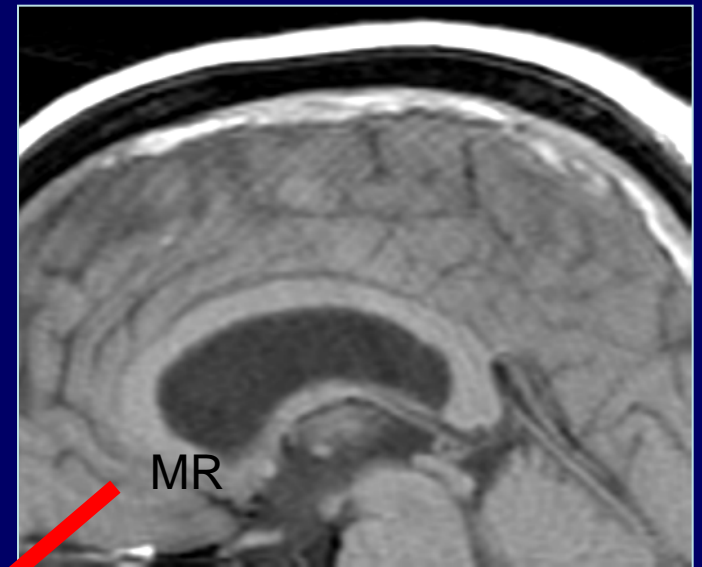
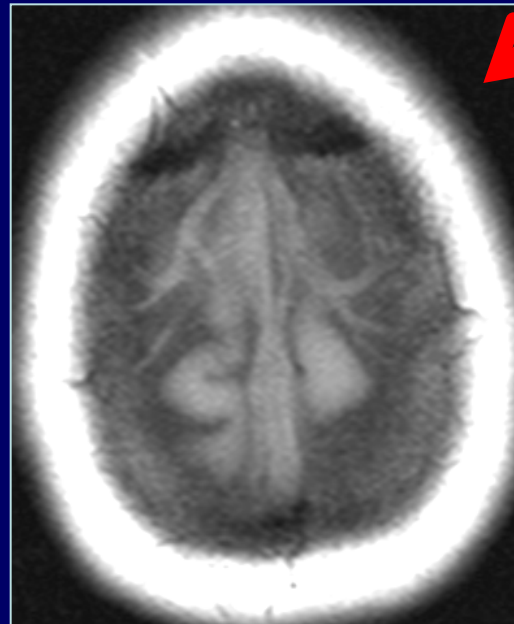
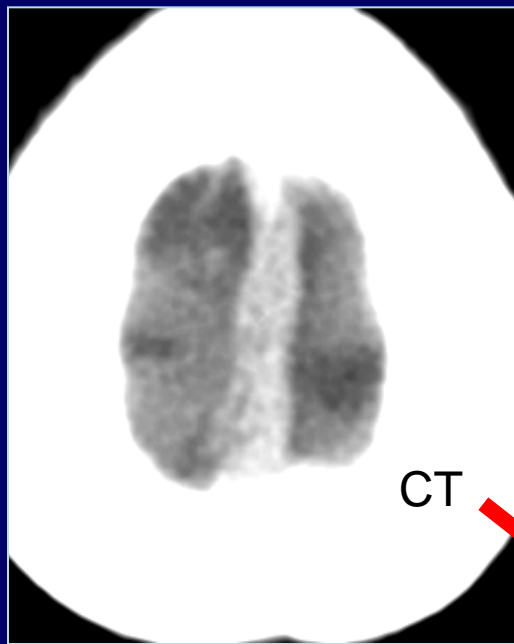


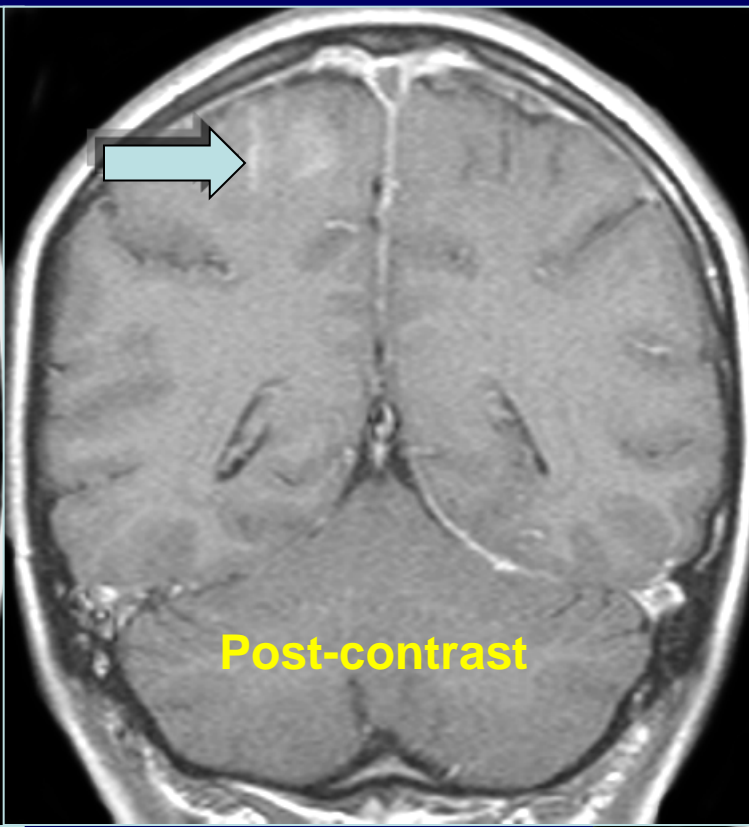
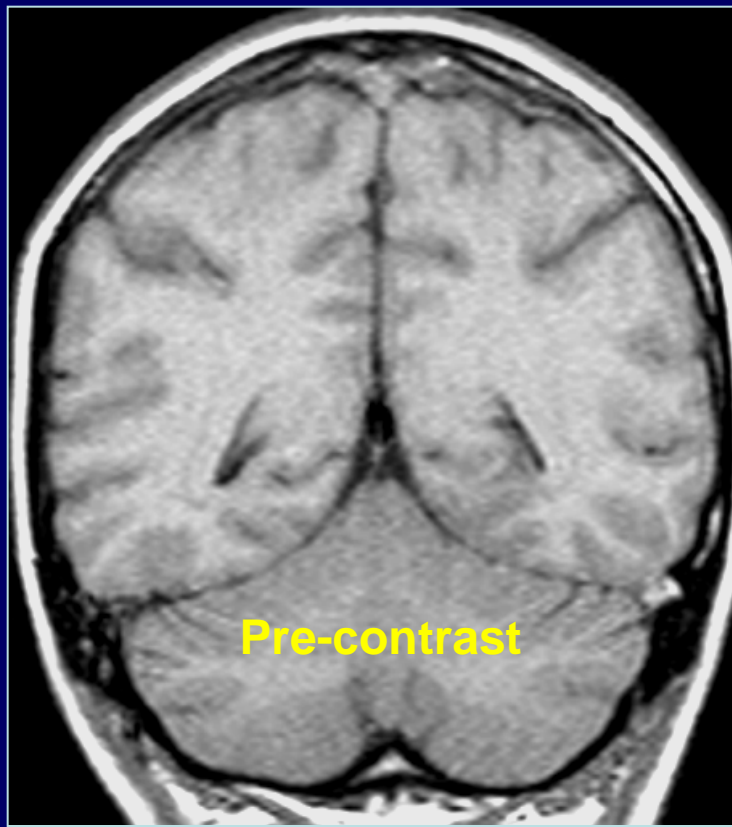
parenchymal damage

‘**Signe
du
cordon**’

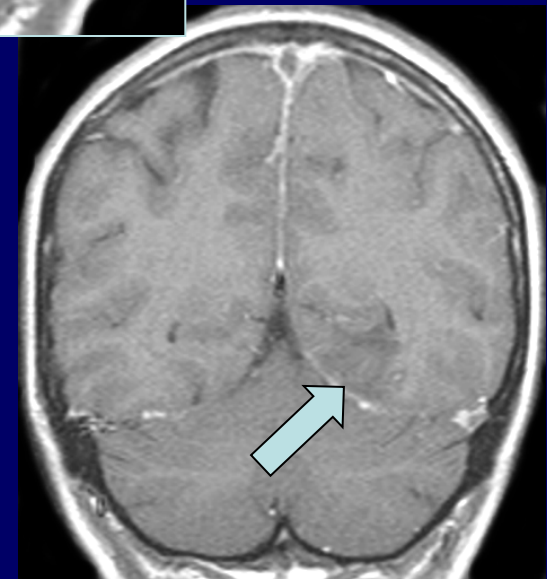

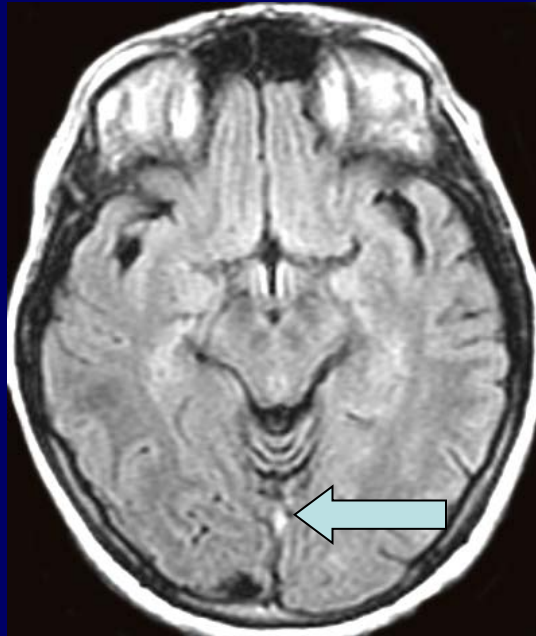
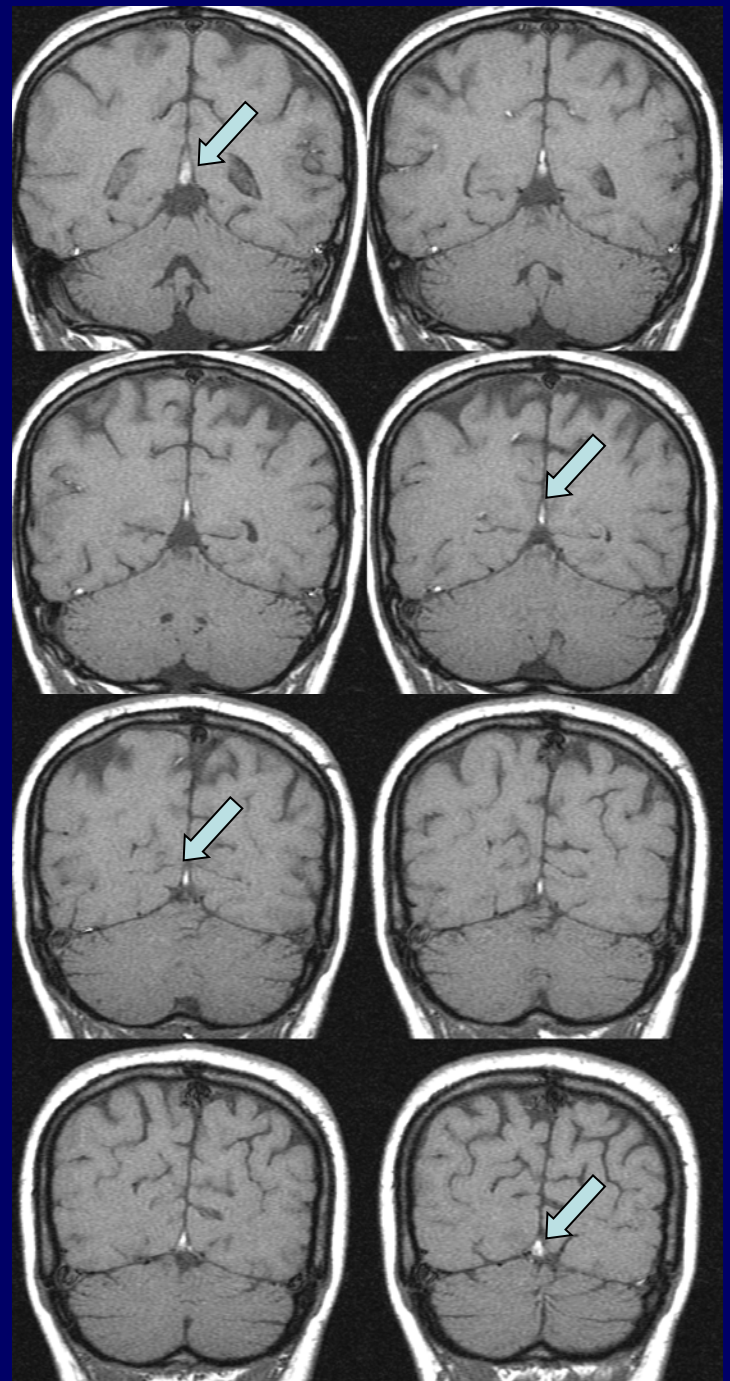
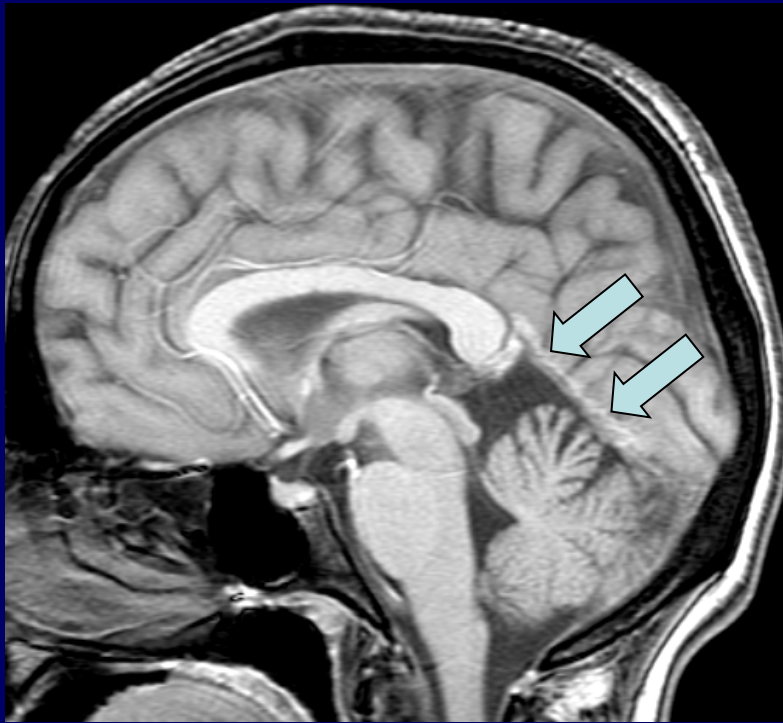Dépendant du temps

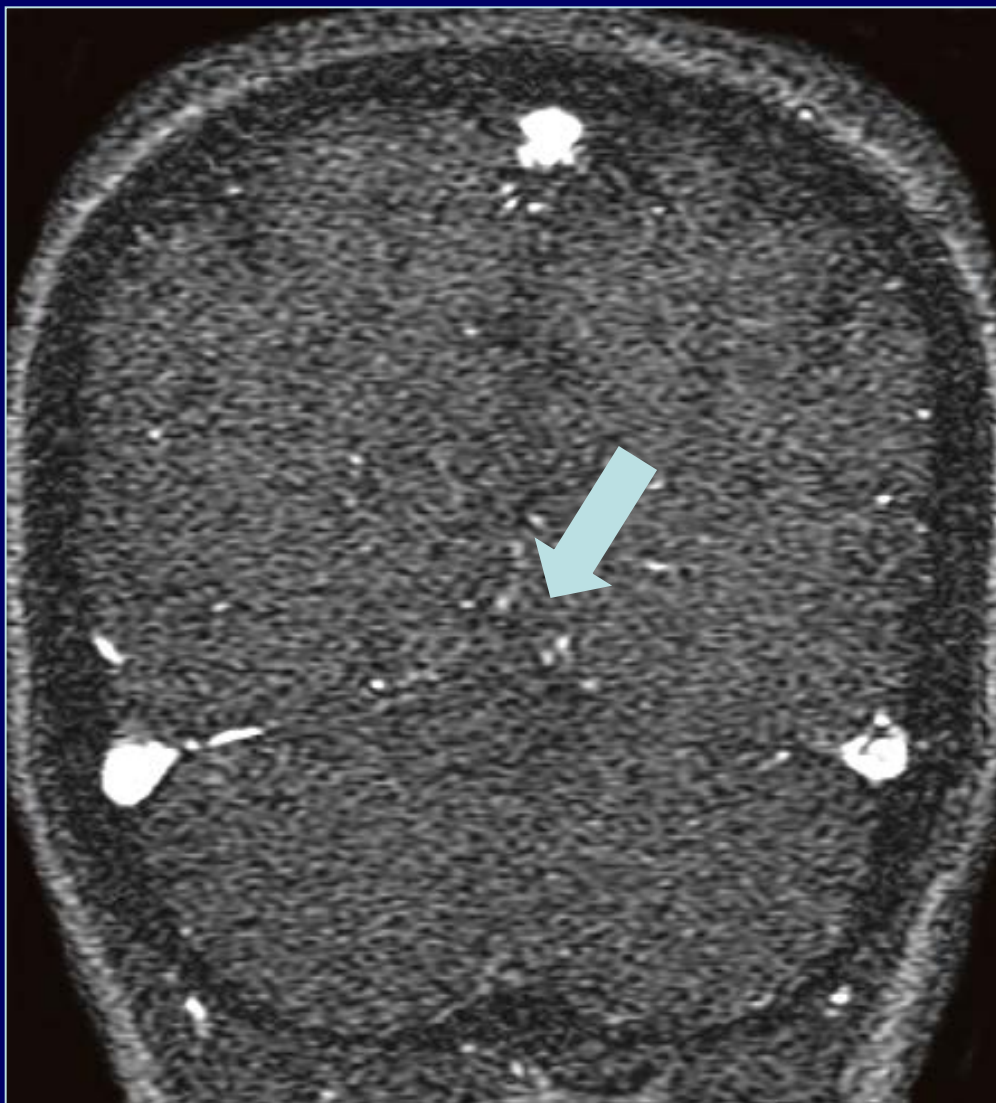




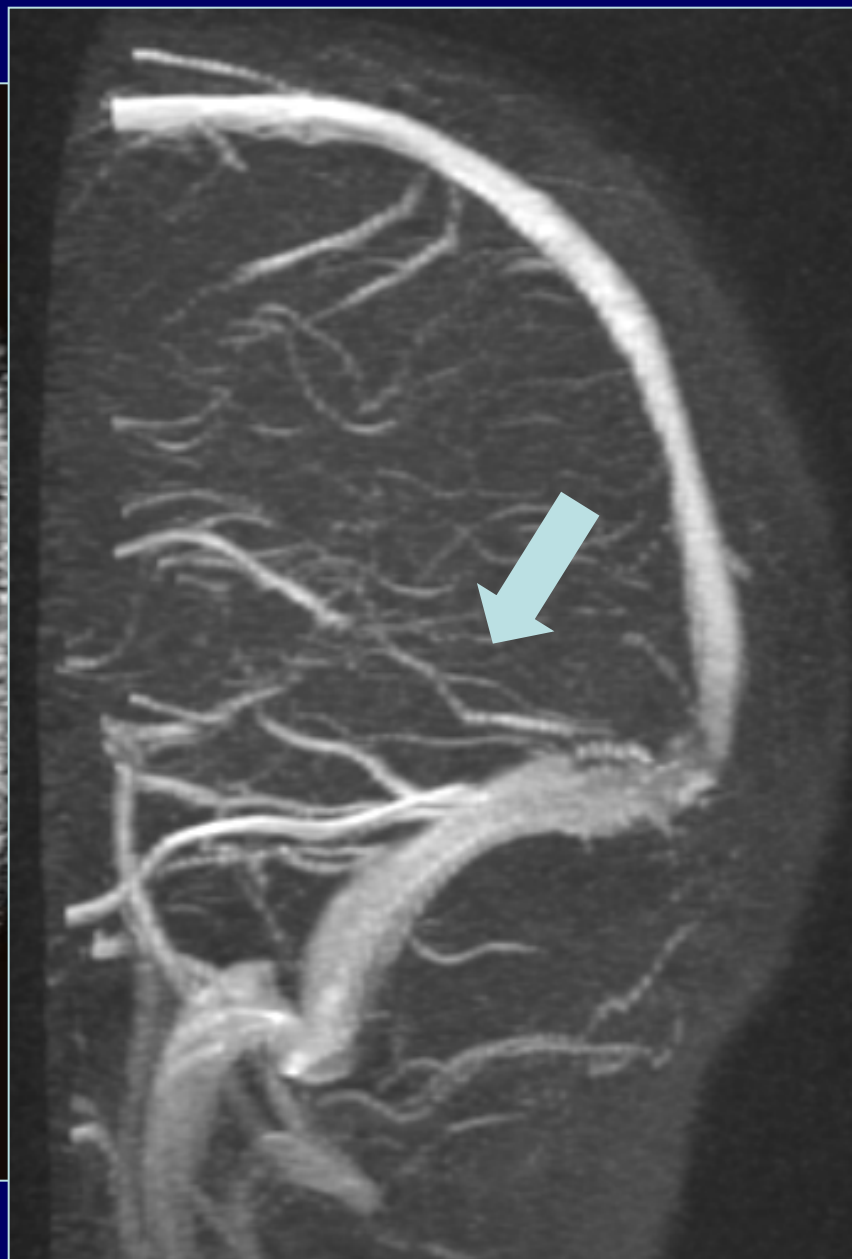'Signe du delta'



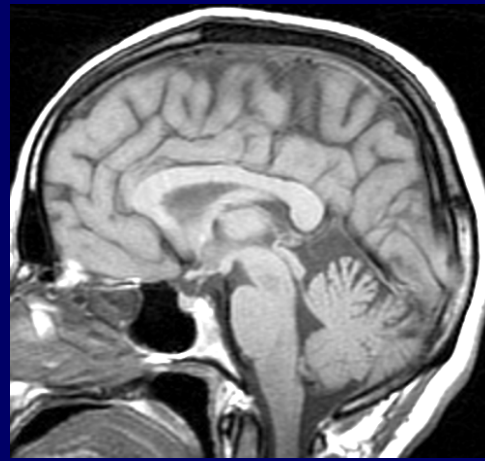
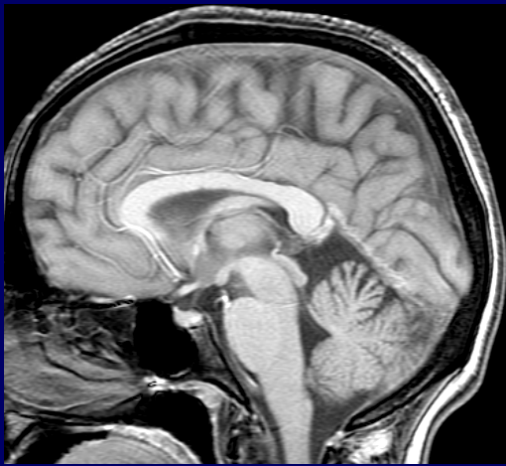




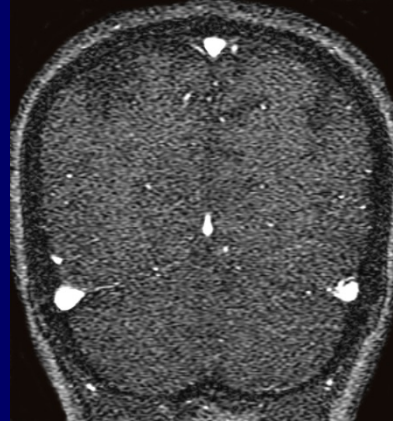
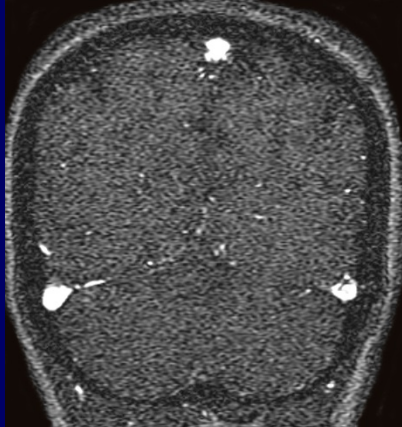
source image



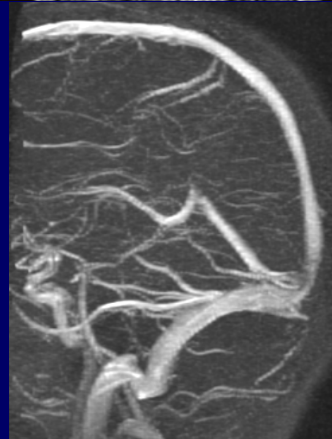
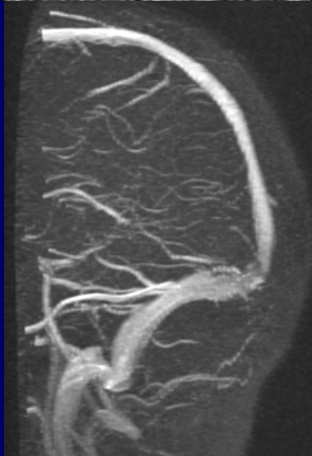
reconstruction



May 8th



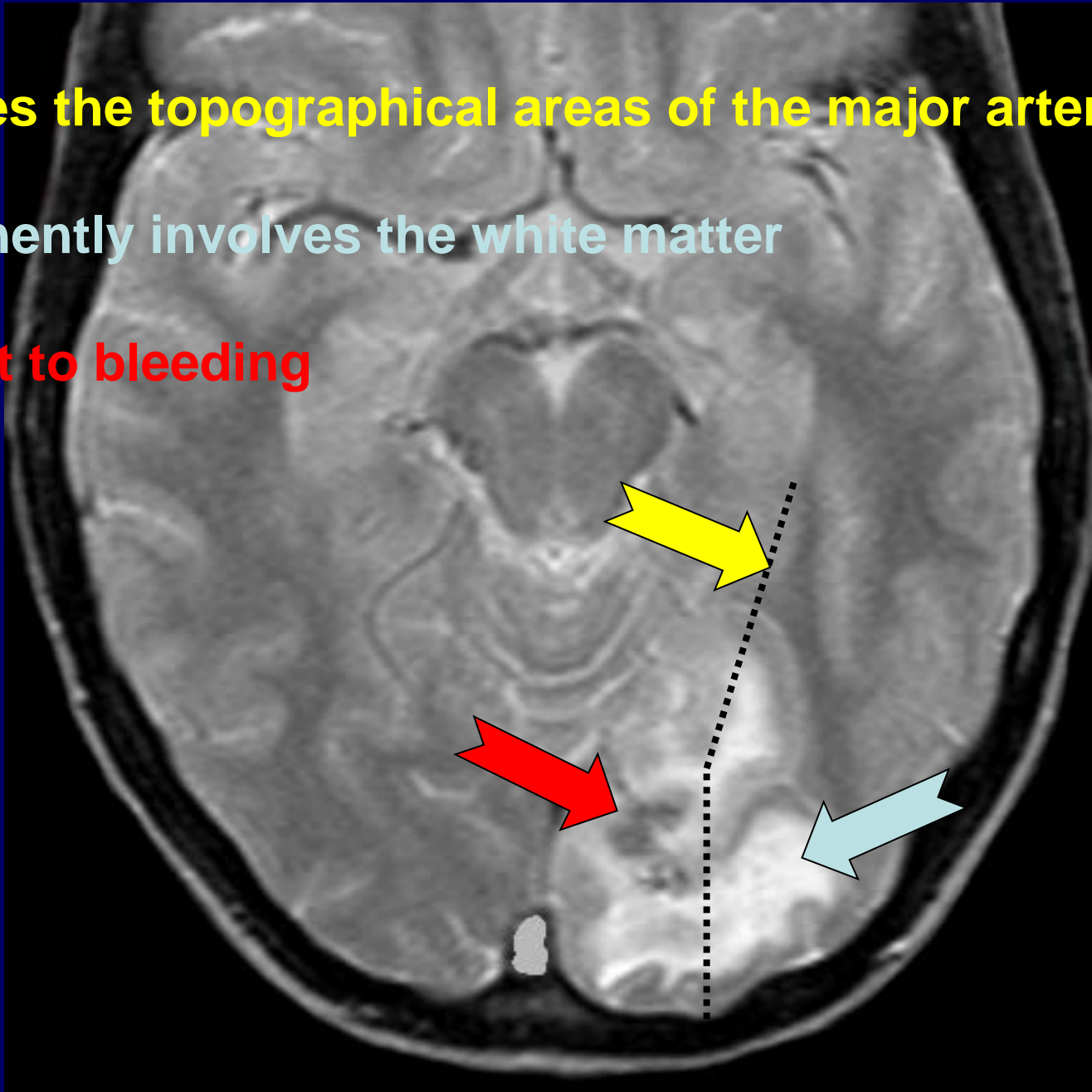
June 21th

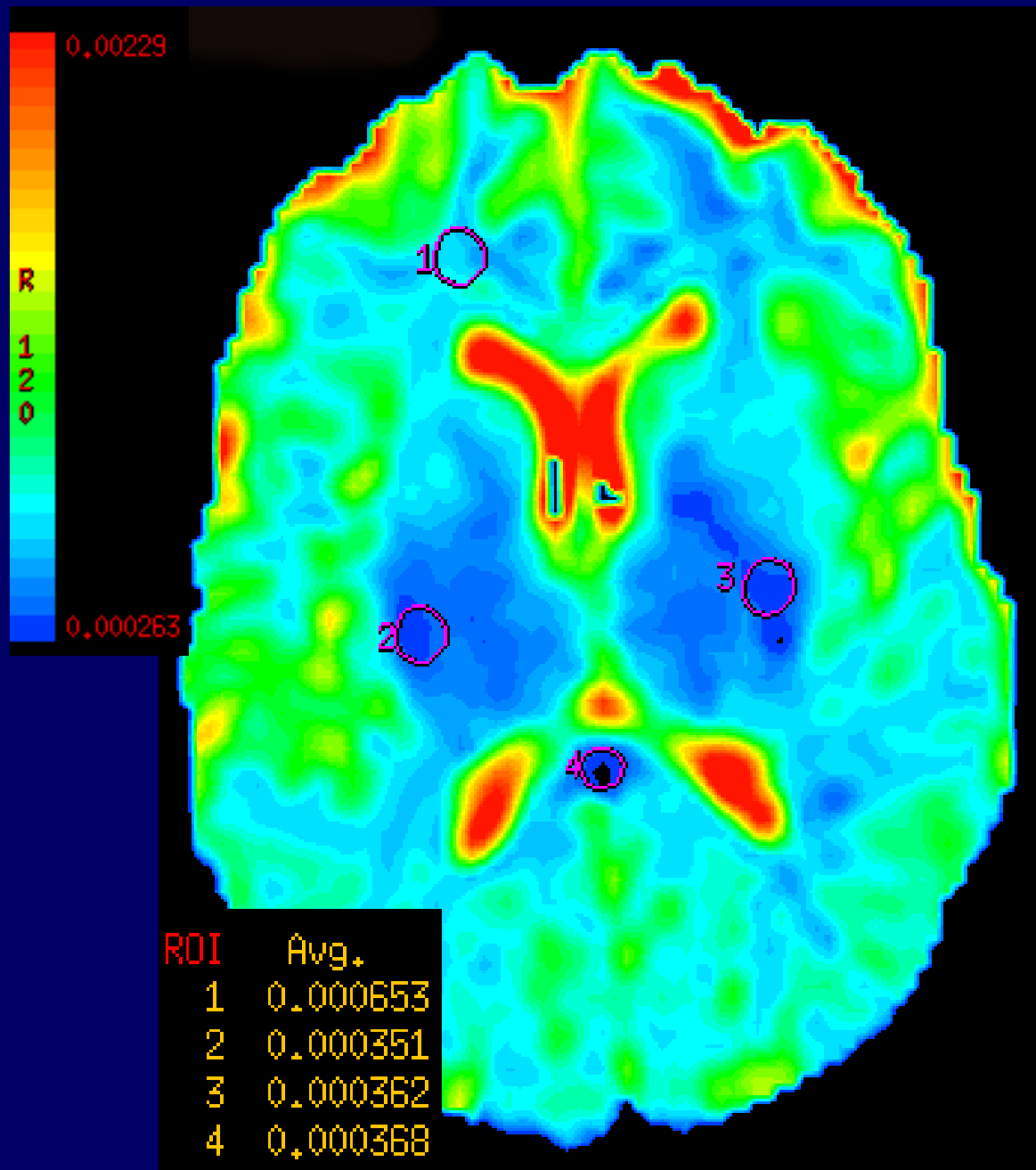
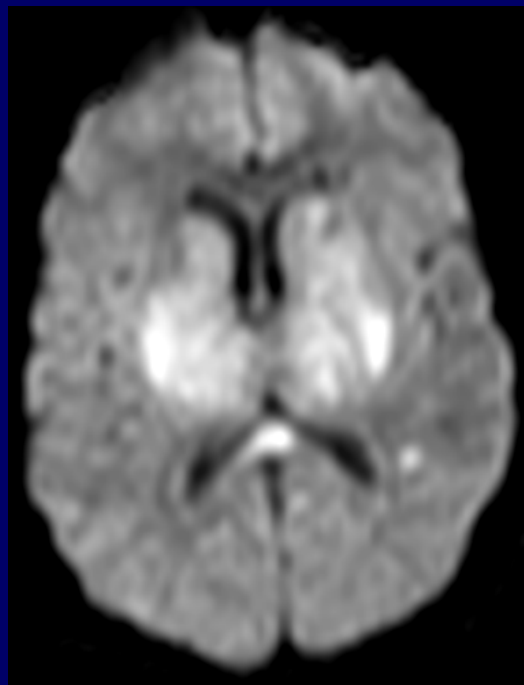
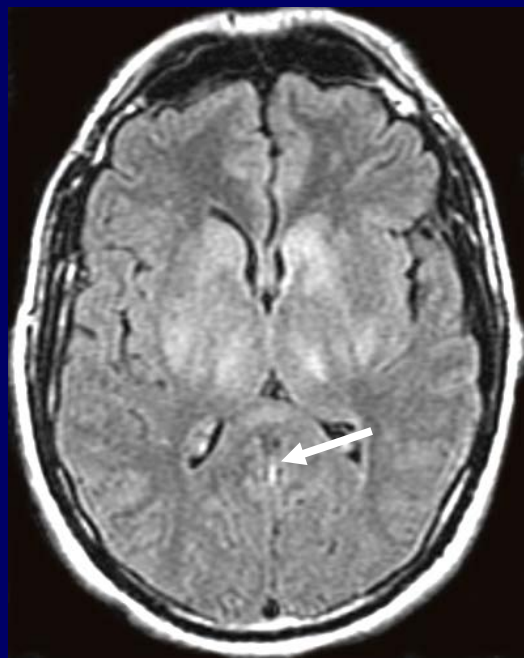


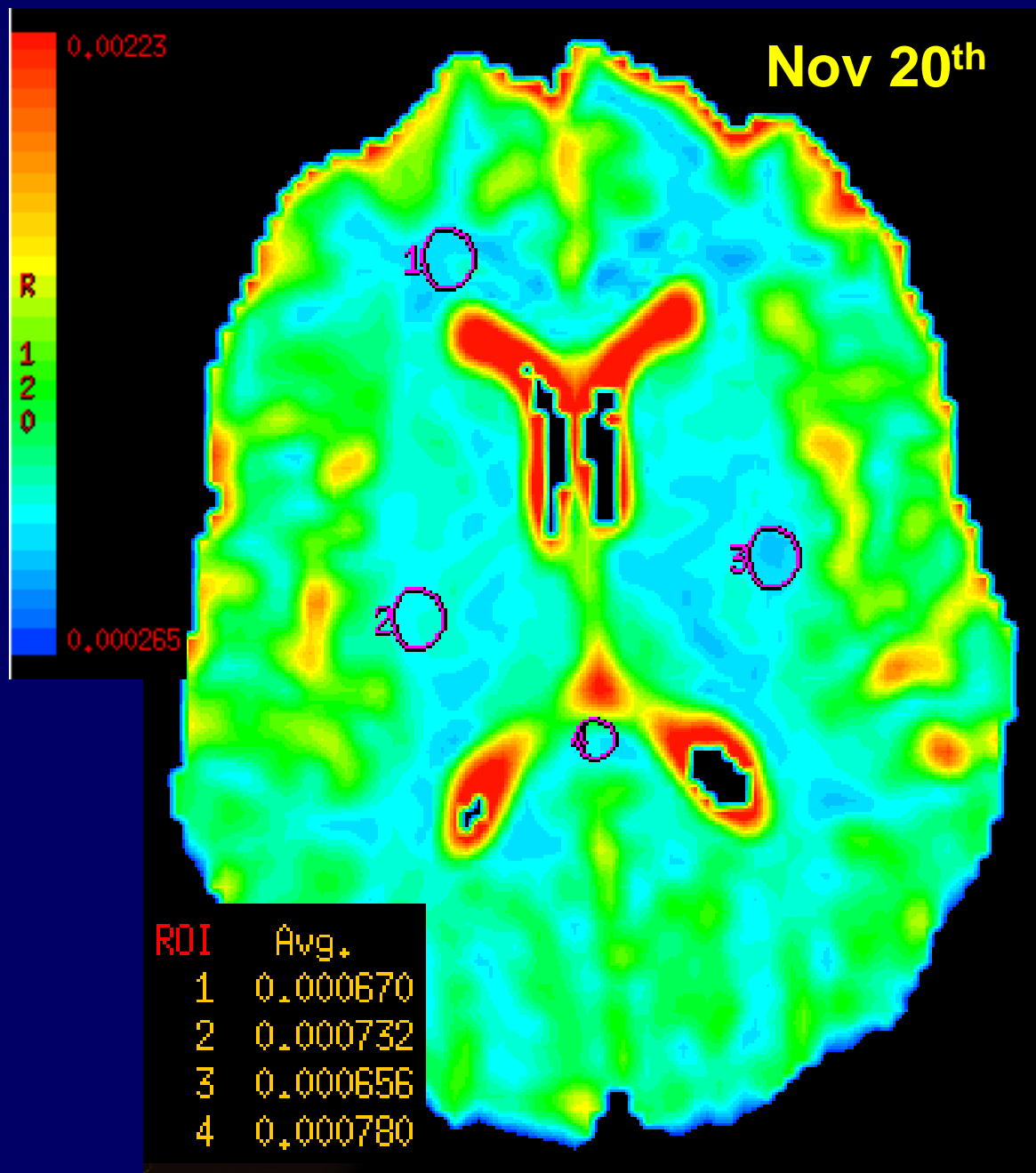
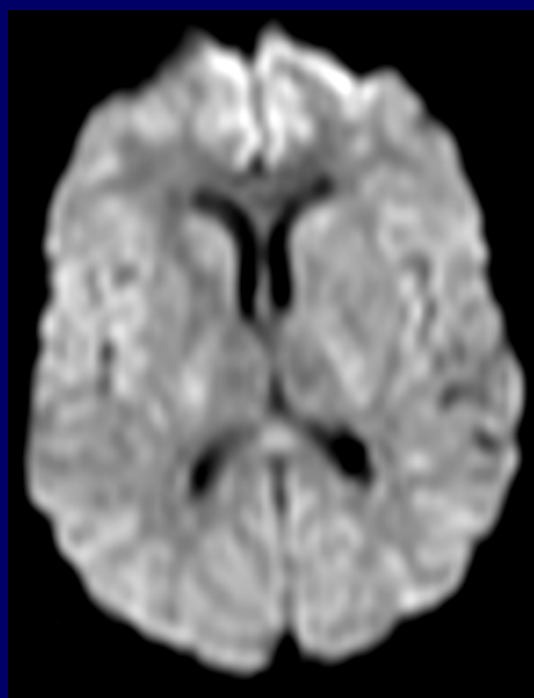
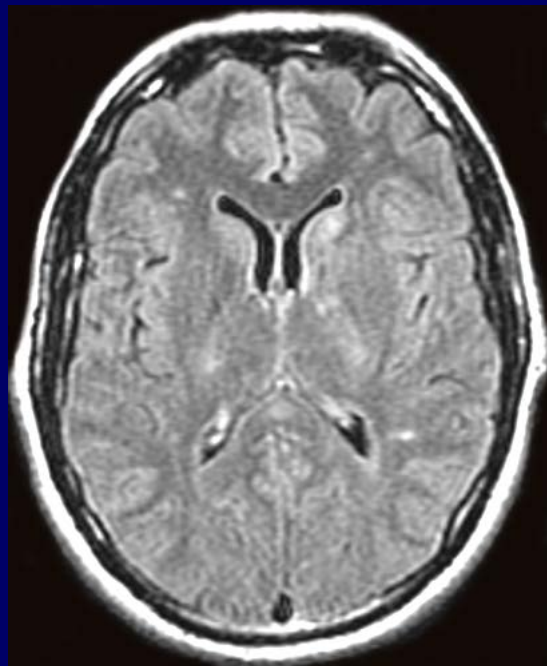
1. Crosses the topographical areas of the major arteries

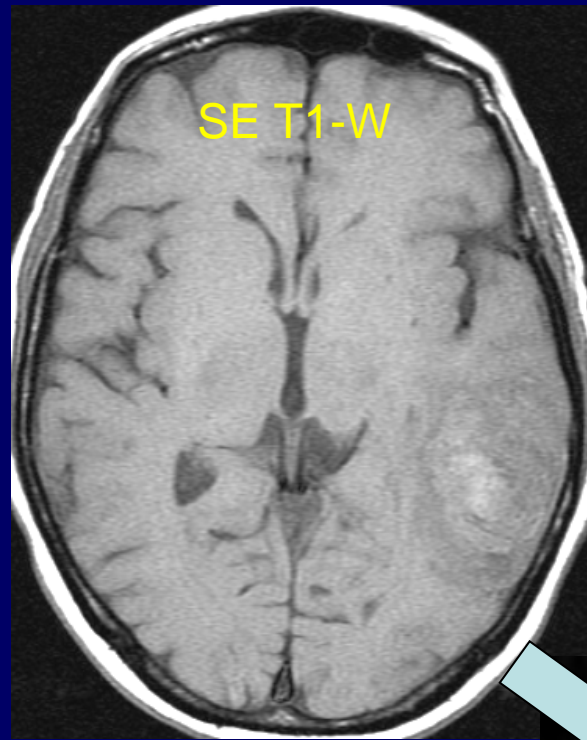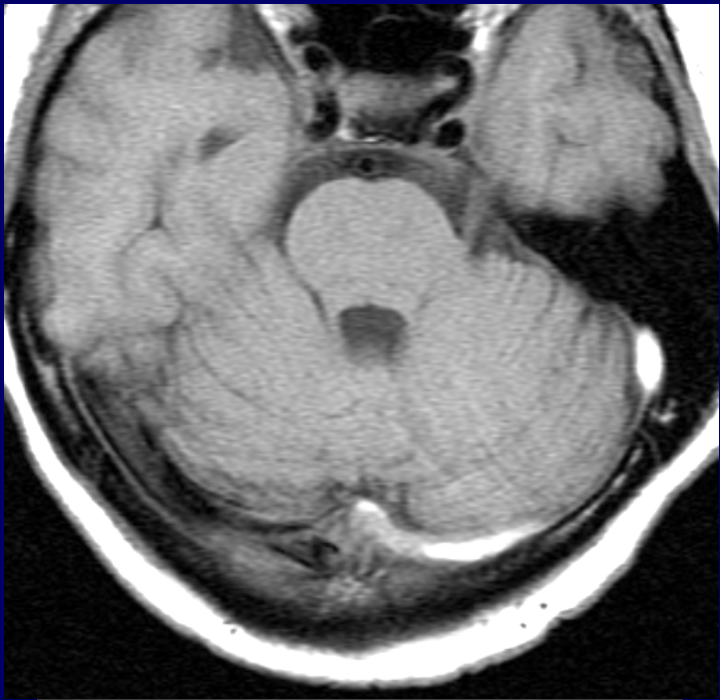
2. Prominently involves the white matter

3. Prompt to bleeding

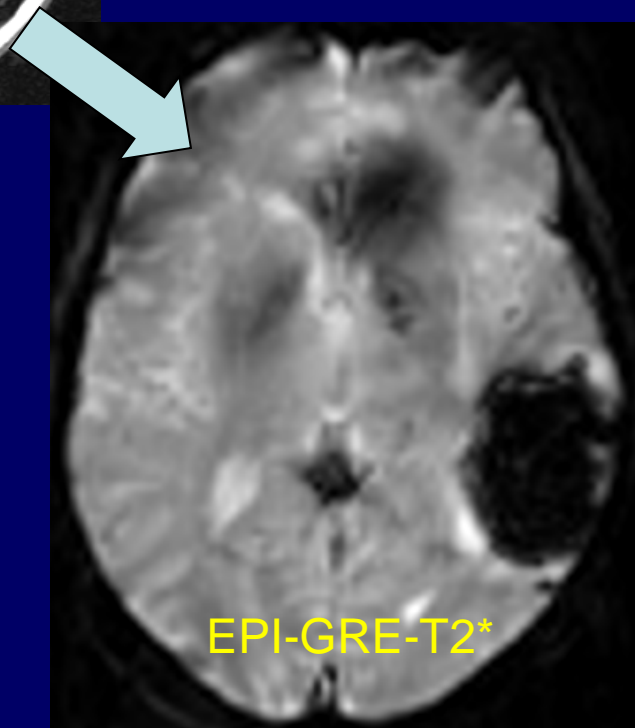
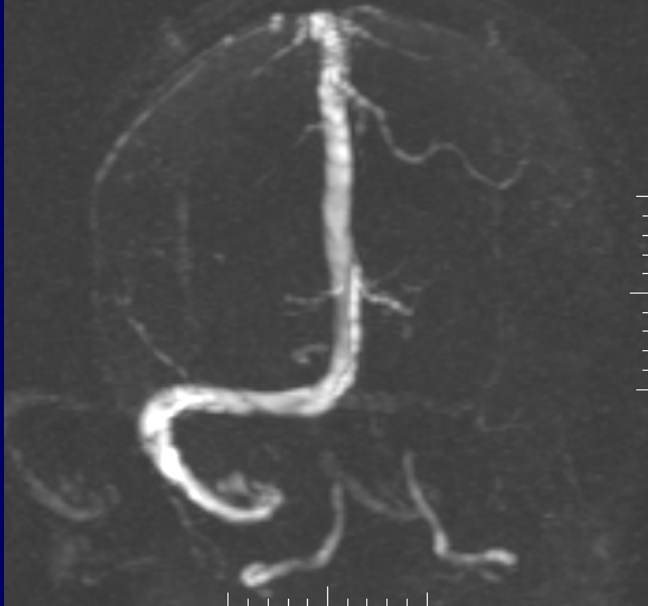



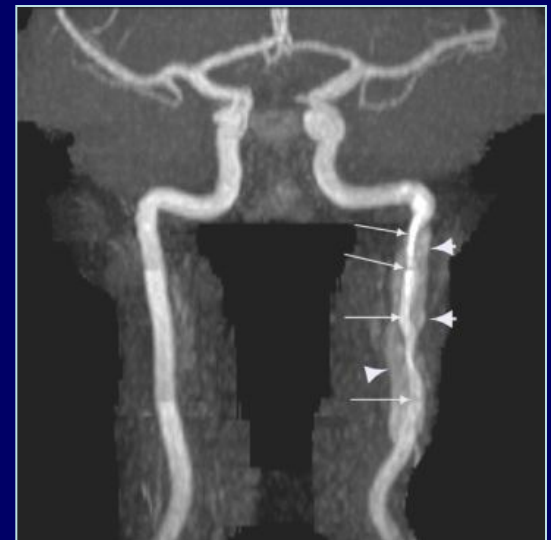
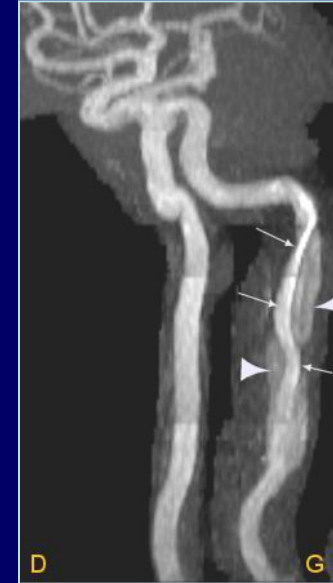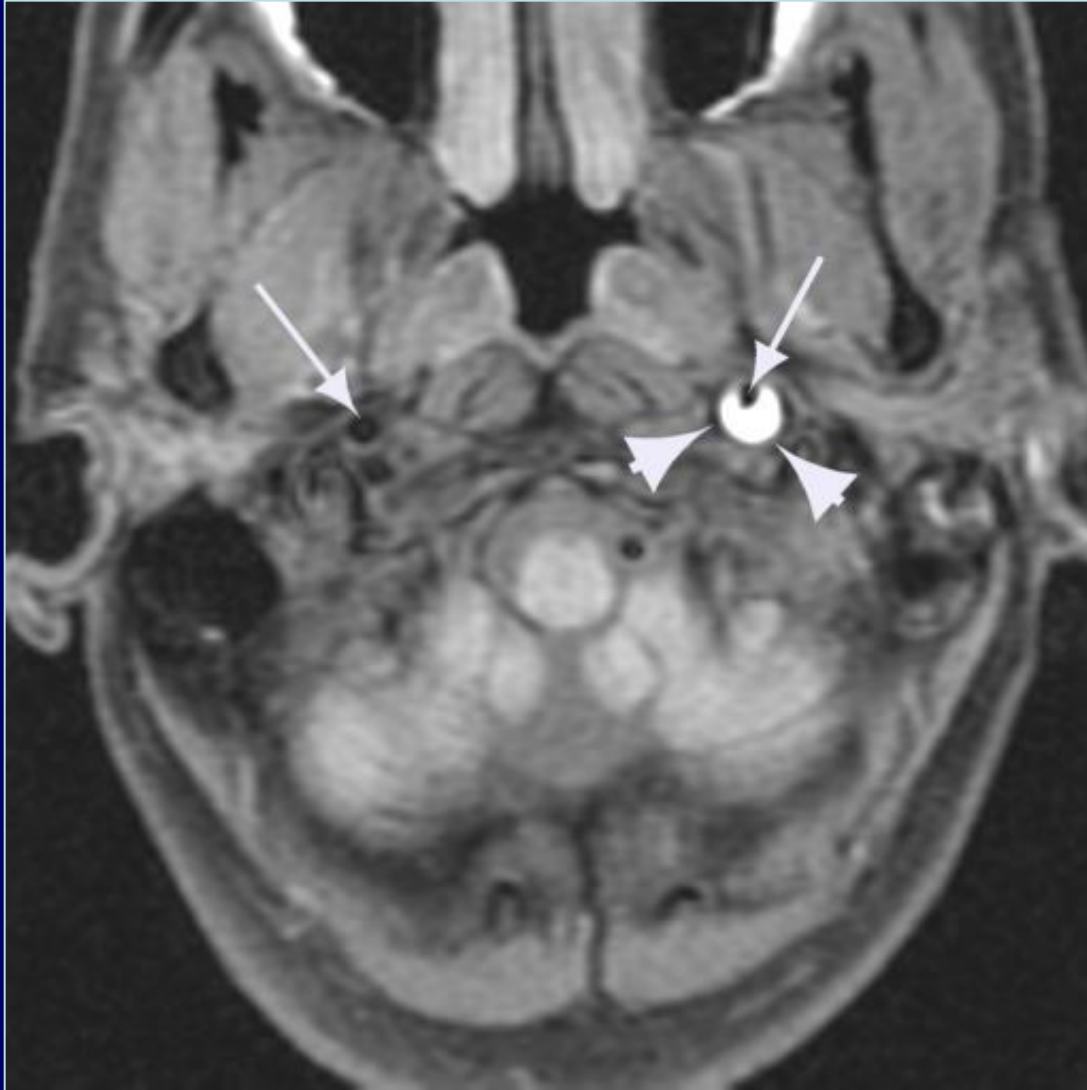




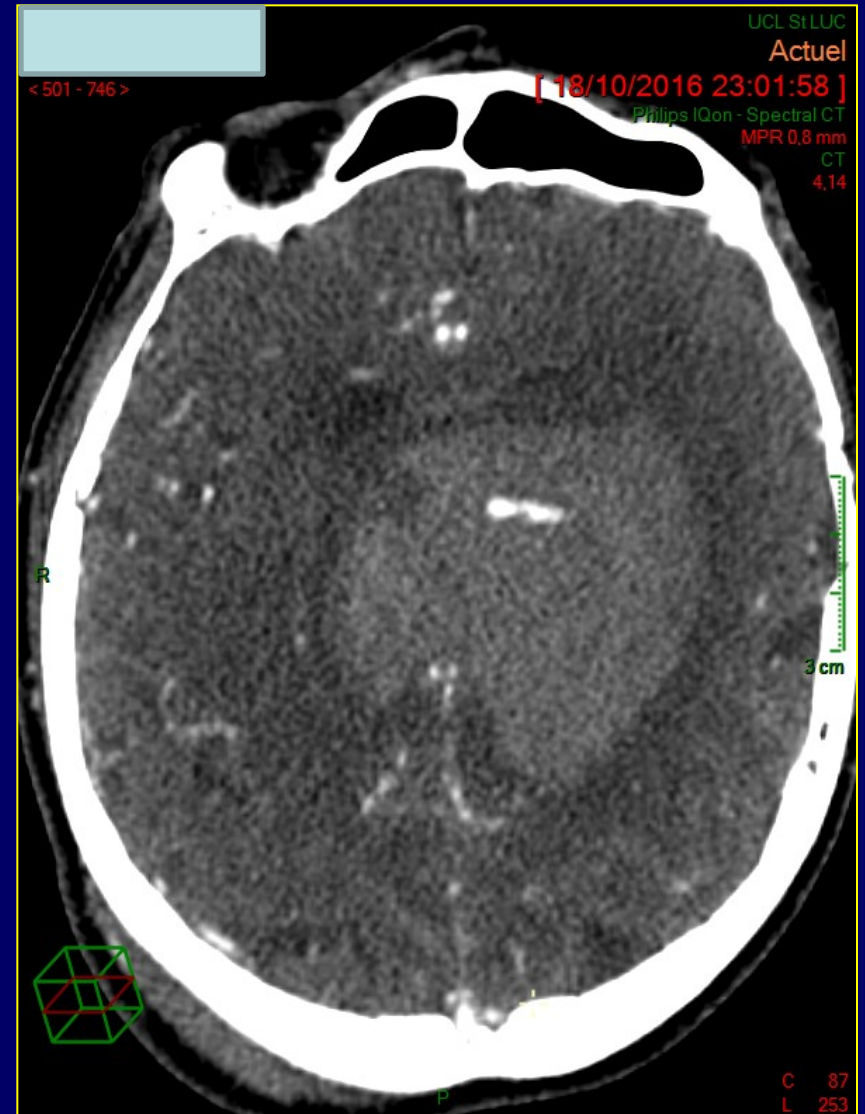
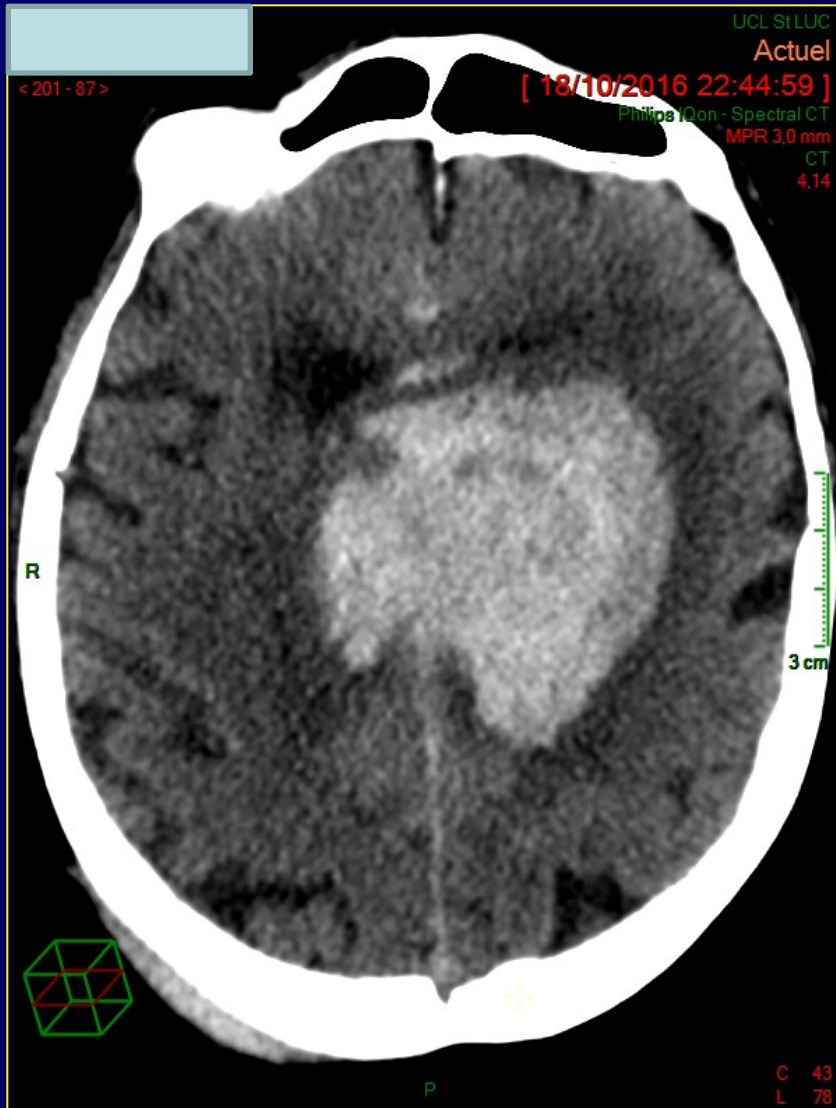bleeding



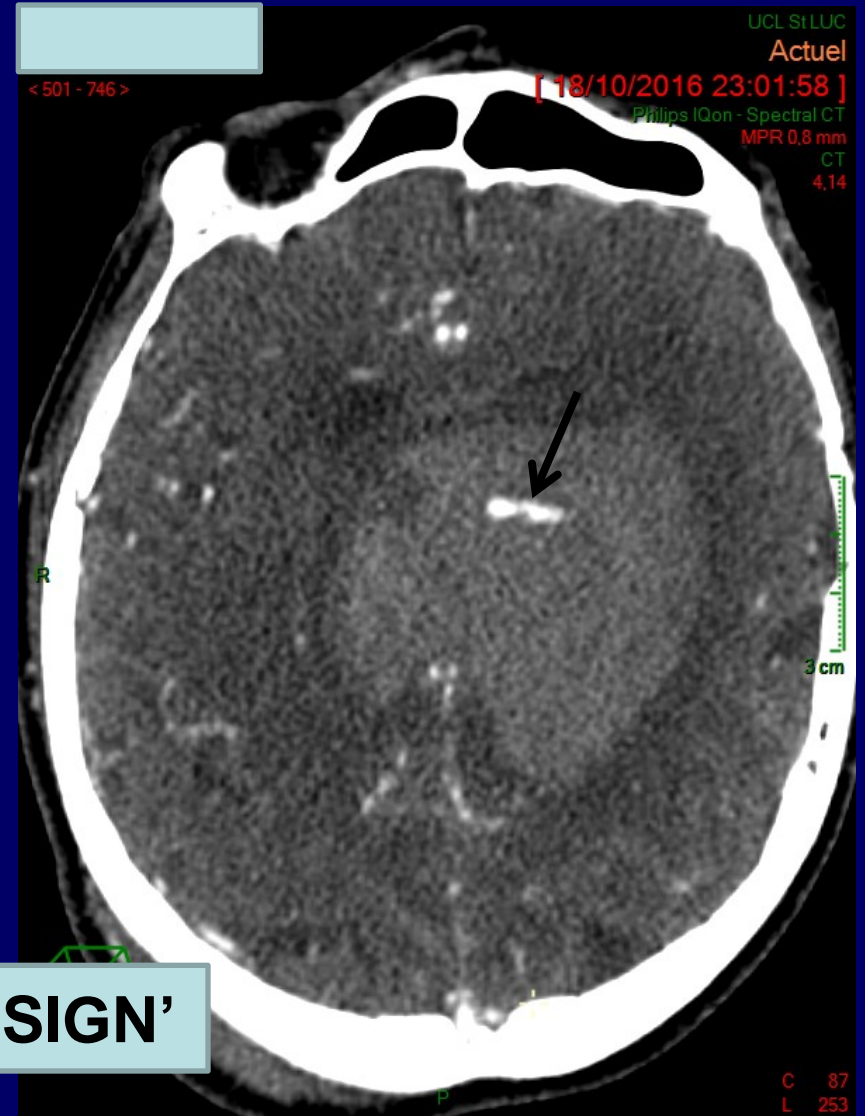
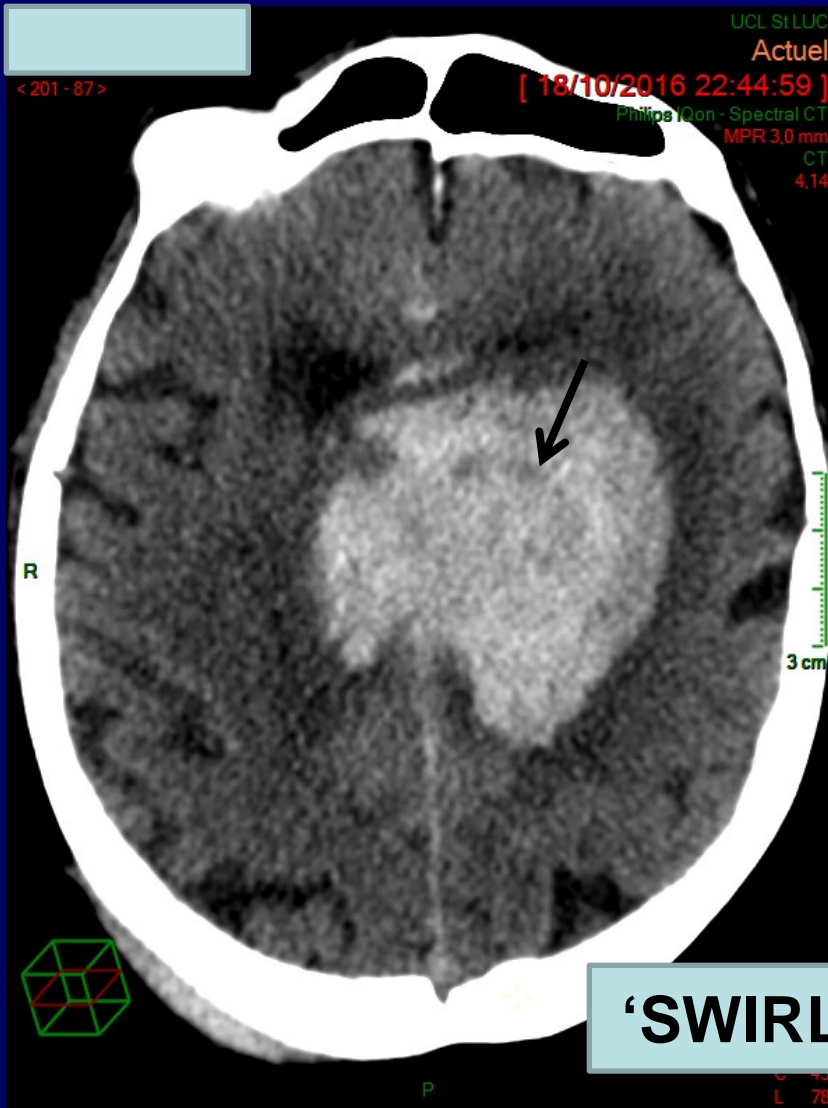Dissection artérielle



Case approach 1

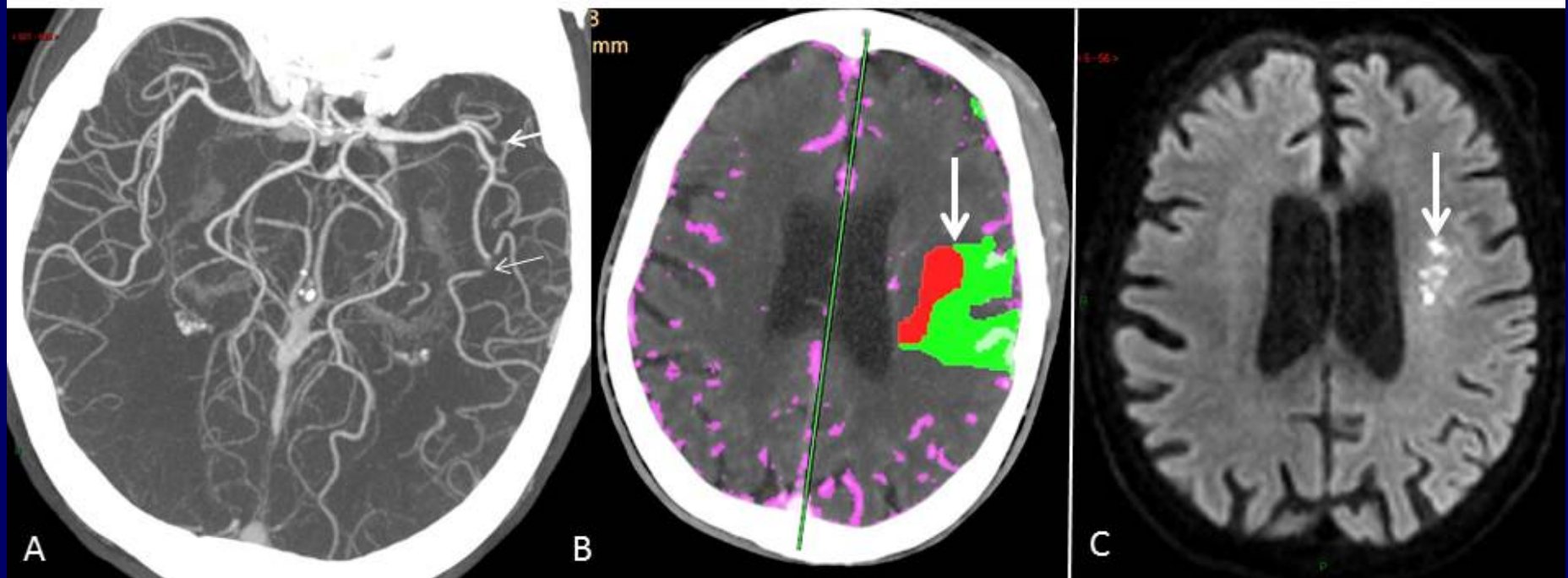


Case approach 1



'SWIRL-SIGN'

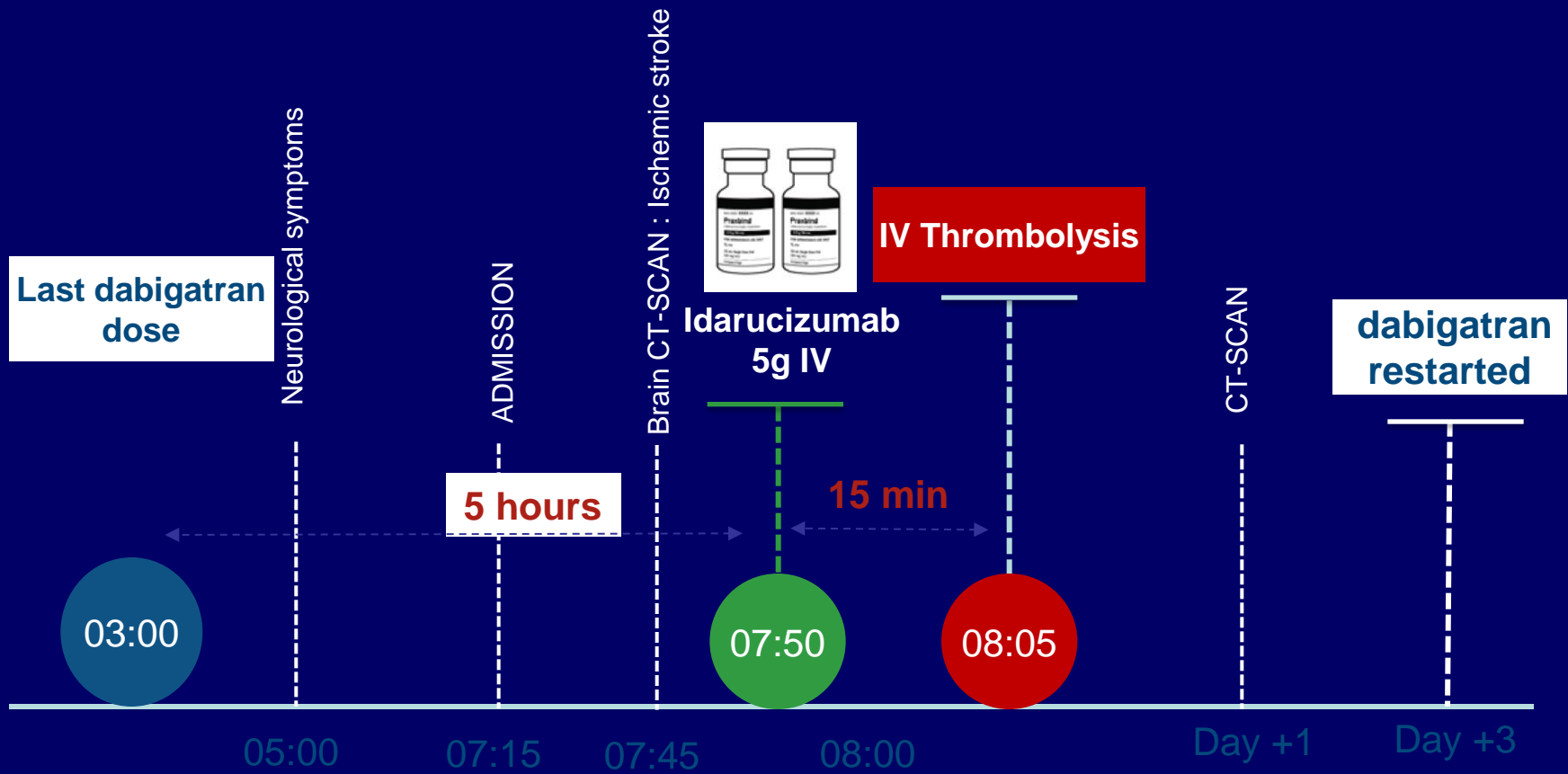
Case approach 2



85 ans – FA – HTA dyslipidémie

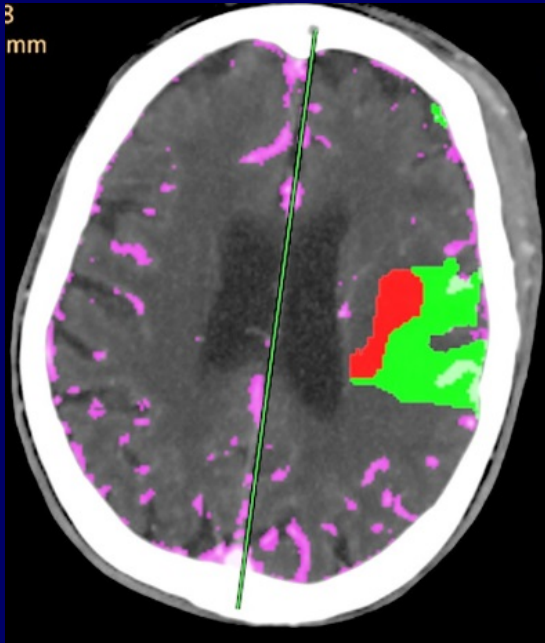
Aphasie et 1/2plégie droit → NHISS 17

Sous PRADAXA® → CI à la thrombolyse

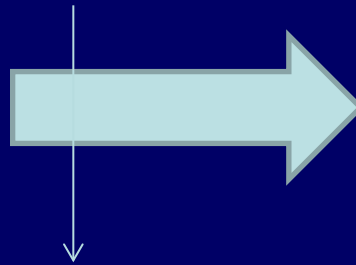


Case approach 2

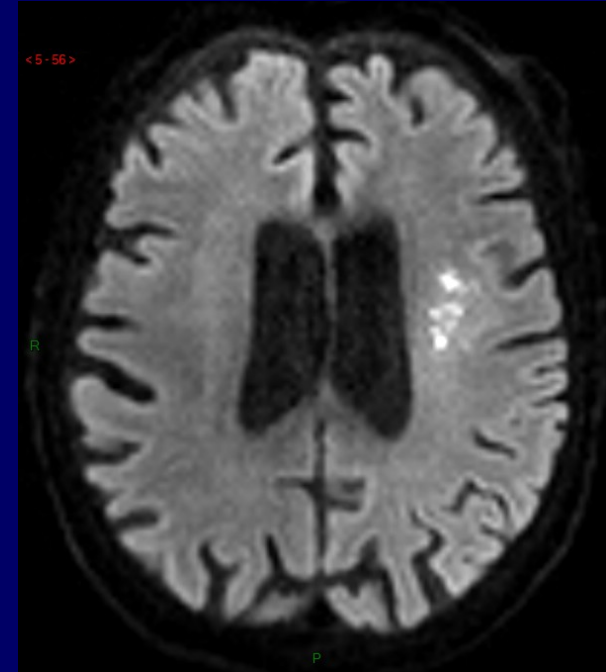
Case approach 2



Neutralisation du PRADAXA®
par PRAXBIND®



Thrombolyse !



R/ AC → CI à la thrombolyse IV (risque hémorragique)

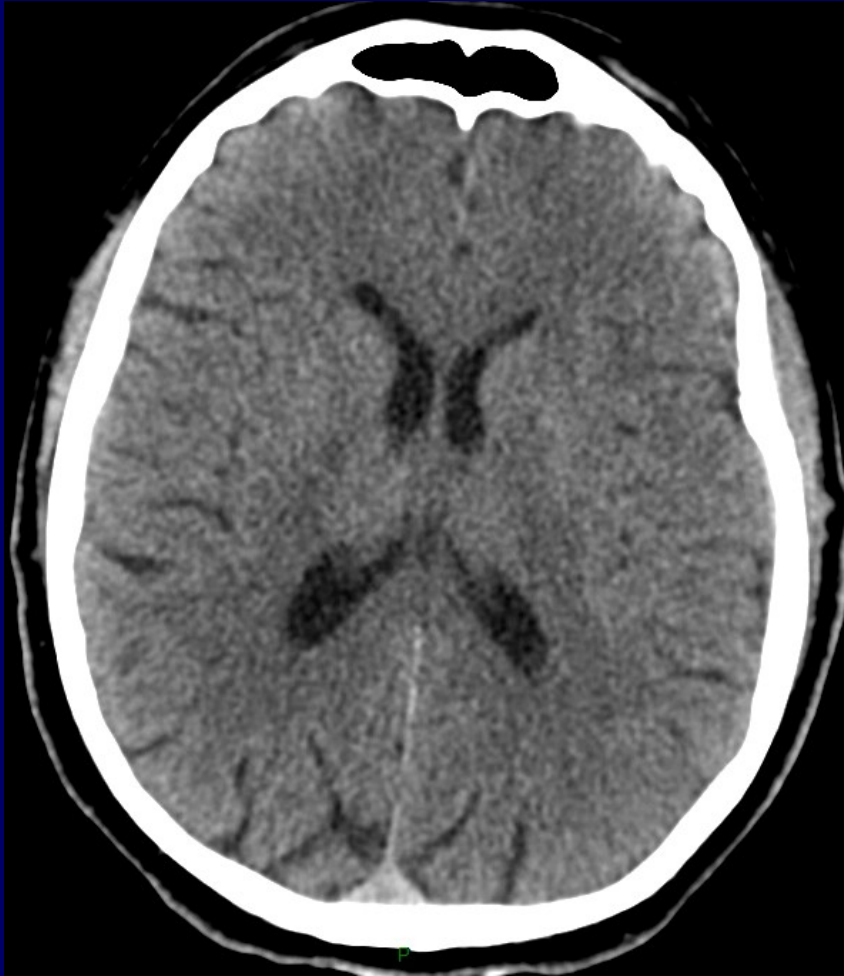
Antivit K → INR >1.7 → exclu

Anti thrombine (Pradaxa®) → agent neutralisant disponible (Praxbind®)

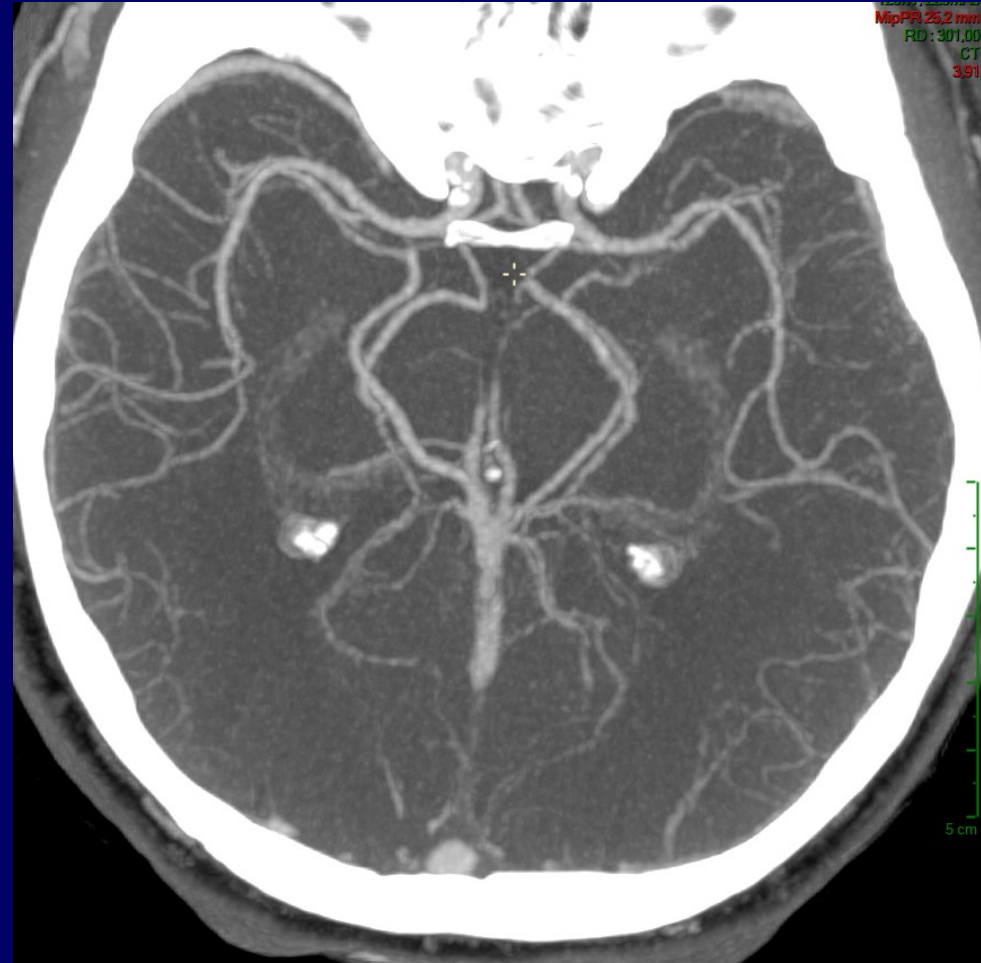
Anti facteur X (Xarelto®) → agent neutralisant dans le pipe-line

Case approach 3

Hémiplégie droite + aphasie



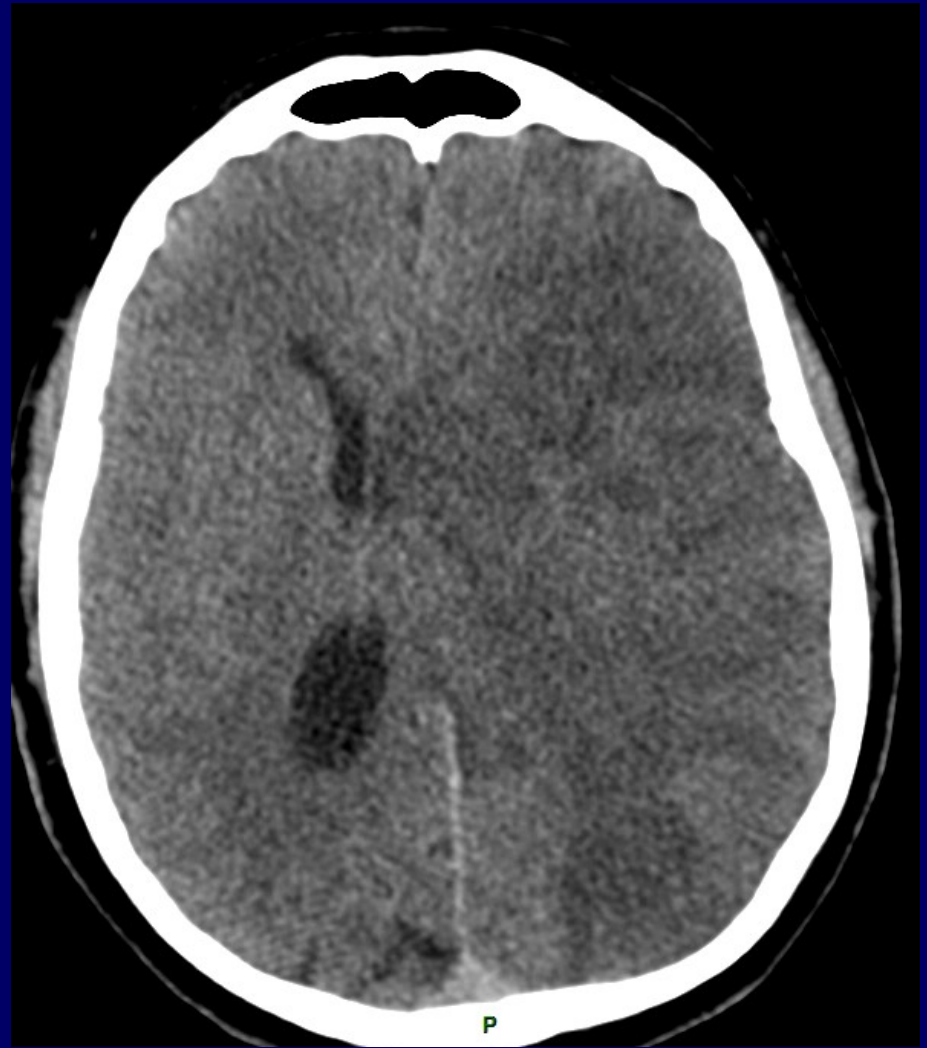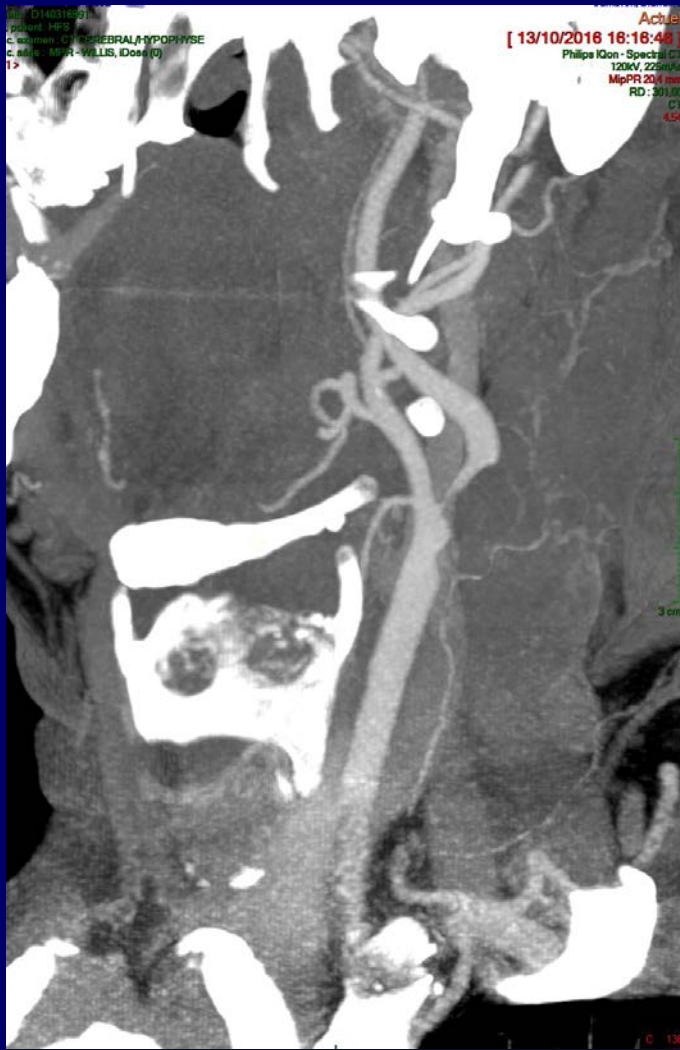NCCT: normal



CTA: normal

Que faire ?

Case approach 3

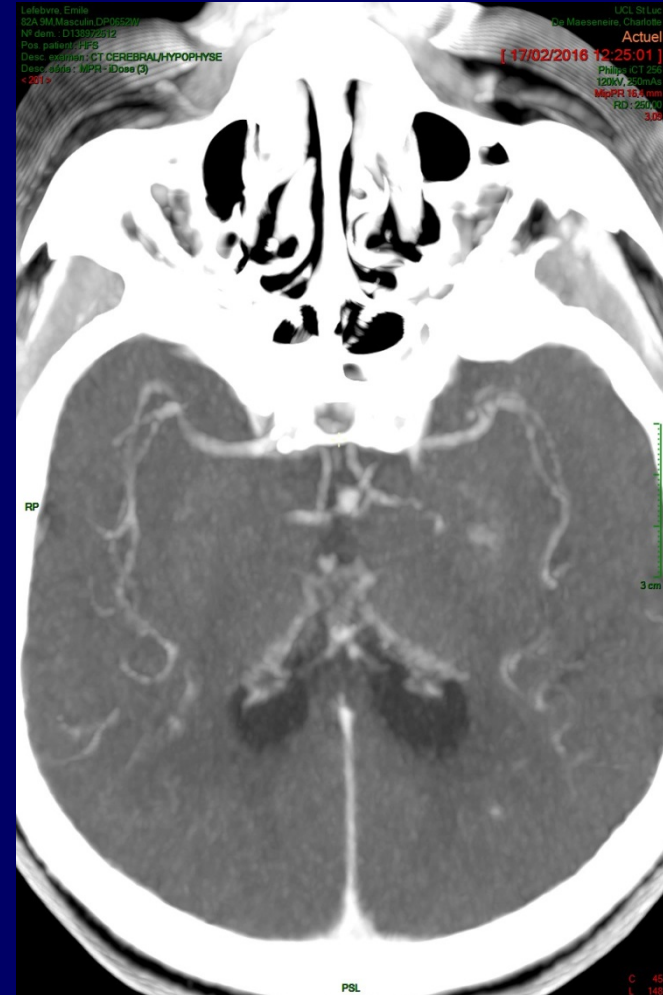
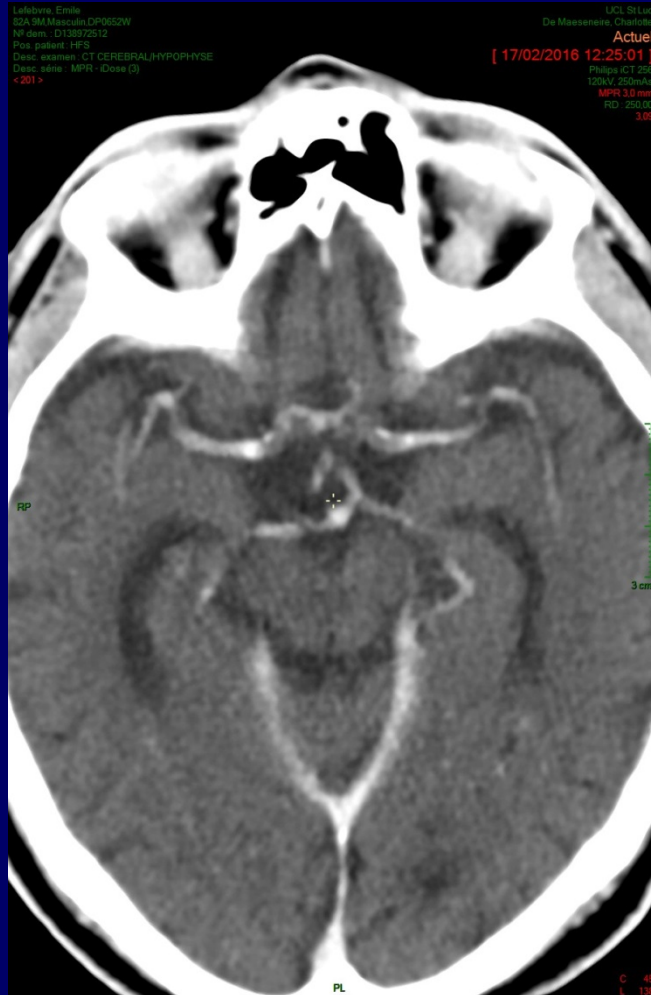

Regarder plus bas !

... trouver un chirurgien vasculaire et une SO libres

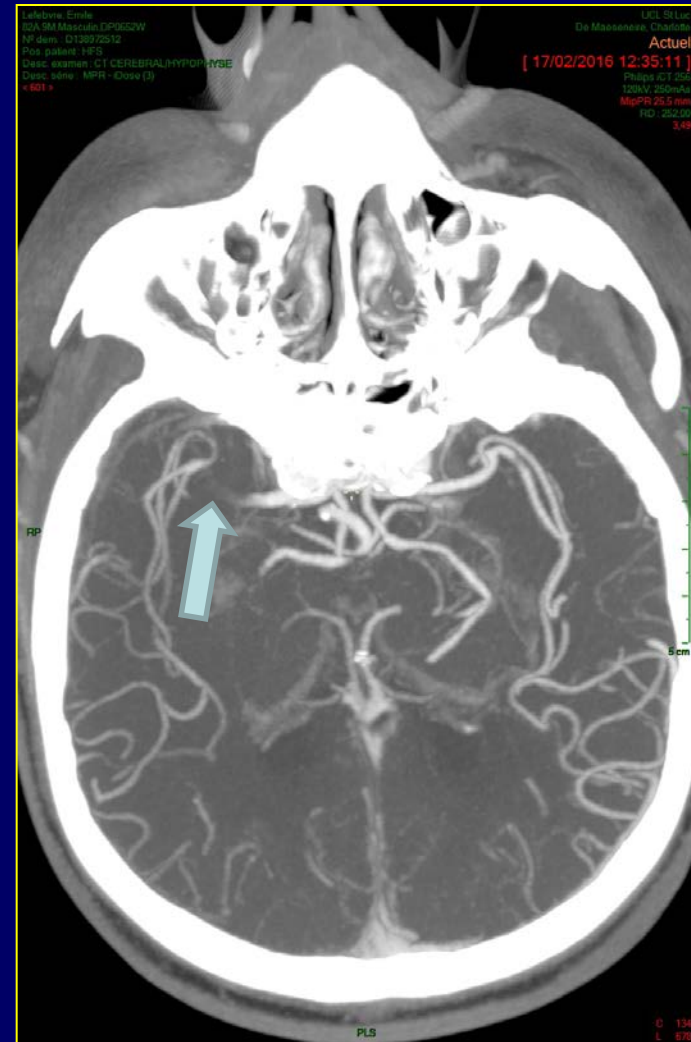
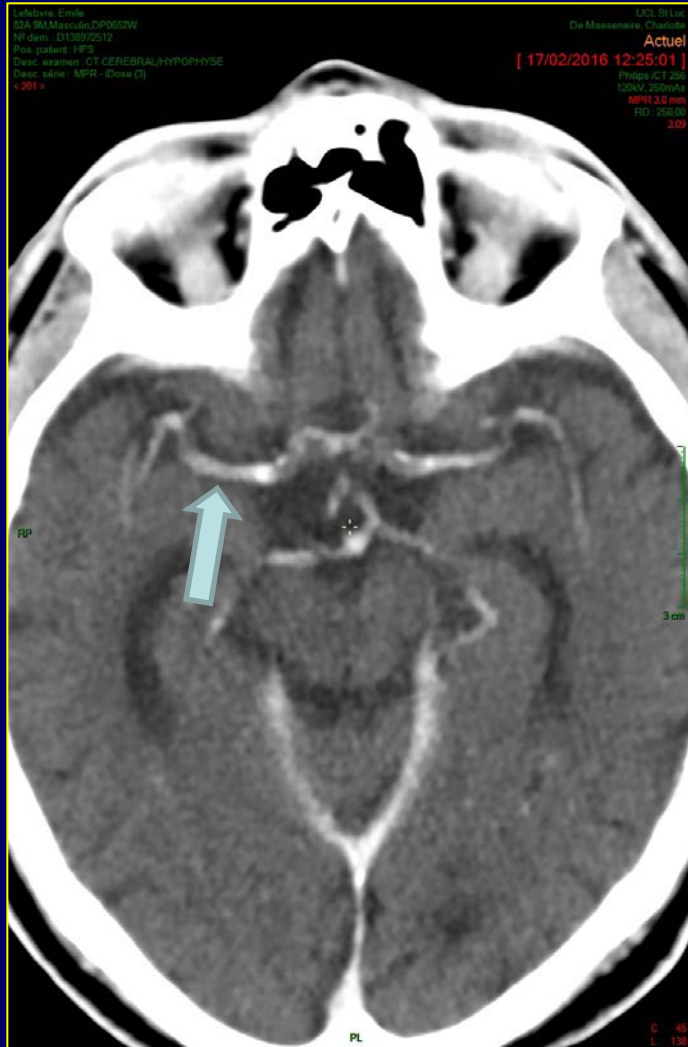Case approach 4

Procédure interventionnelle: TAVI - ½ parésie gauche



Examen 'à blanc'

Case approach 4



Angiogramme → thrombectomie