

Cours à Option de Neuroradiologie

RDGN 2120

Année académique 2019-20

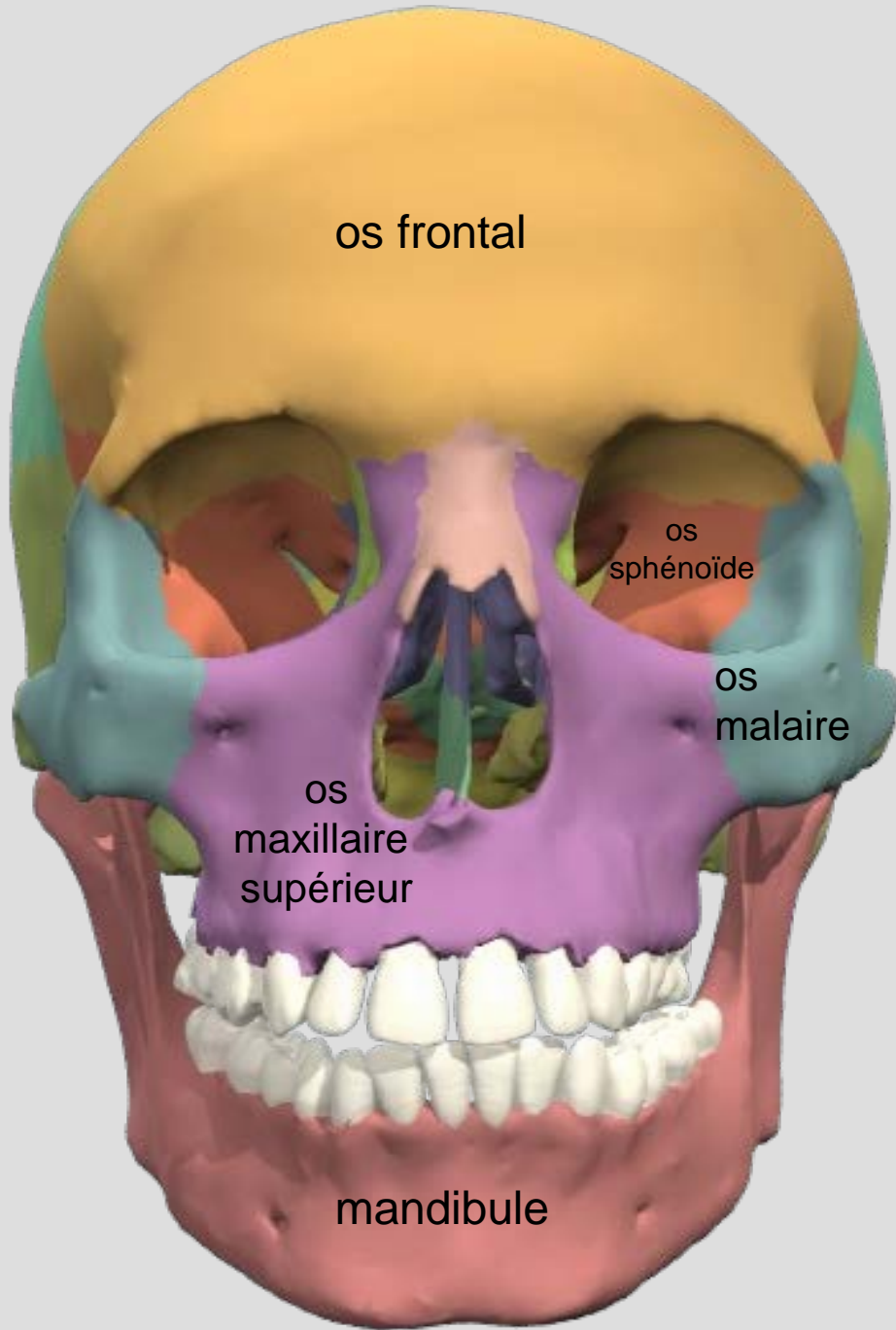
Traumatisme facial



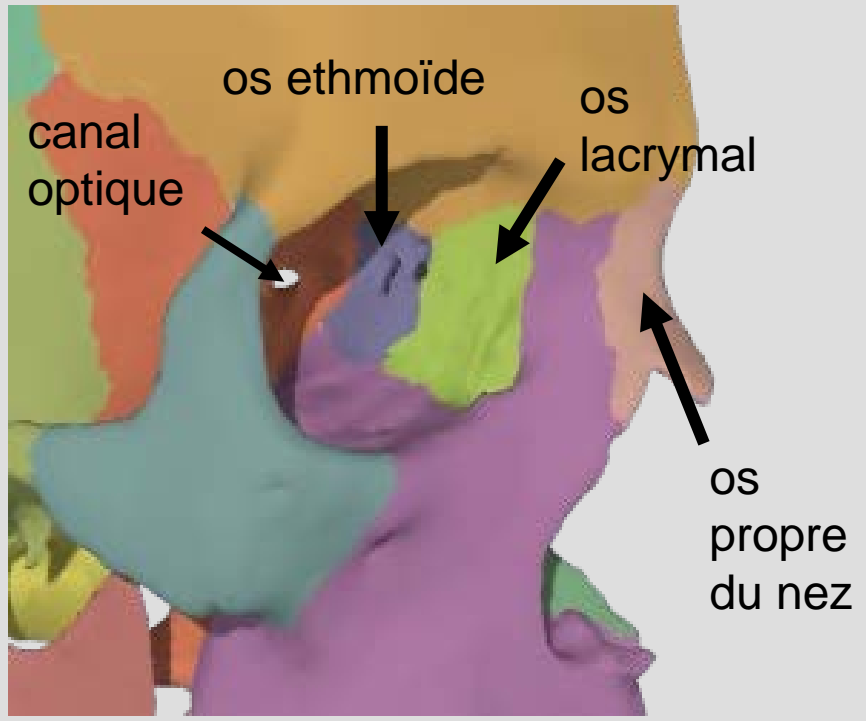
Dr Thierry Duprez
Professeur clinique (UCL)
Chef de Clinique (UCL-St-Luc)
<http://www.uclimaging.be>
<http://www.saintluc.be>
<http://www.centreducancer.be>

8^{ième} cours du mardi 10.12.2019

- **Anatomie osseuse**
 - Pièces du **puzzle**
 - Concept des **piliers et contreforts**
- **Fractures isolées**
 - Fracture **Os Propres du Nez** (OPNs)
 - Fracture du **cadre orbitaire**
 - Fractures de la **mandibule**
 - Fractures de l'**arcade zygomatique**
 - Fractures de **base du crâne et du palais**
- **Entités fracturaires systématisées**
 - # naso-orbito-ethmoïdale (NOE)
 - # du trépied malaire)
 - # transfaciale de Lefort
(bouillie faciale)
- **Restitution des # du massif facial**

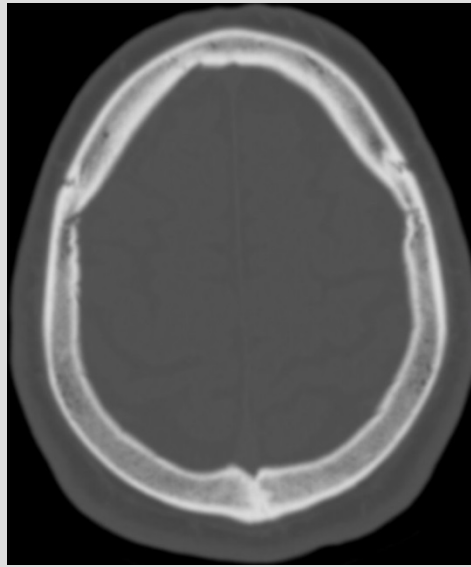


Puzzle

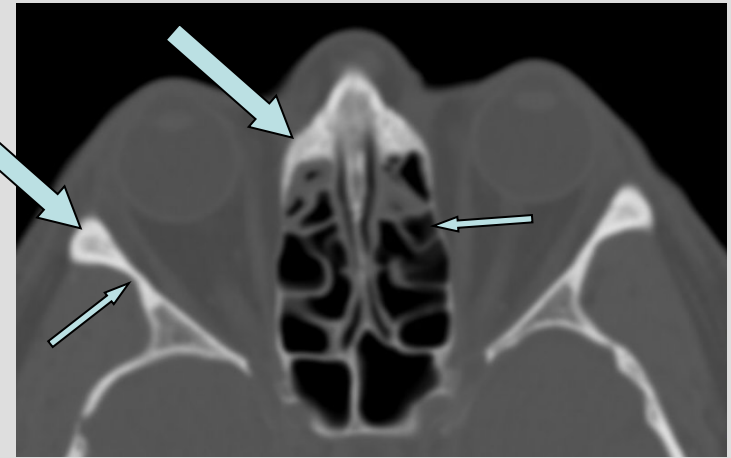




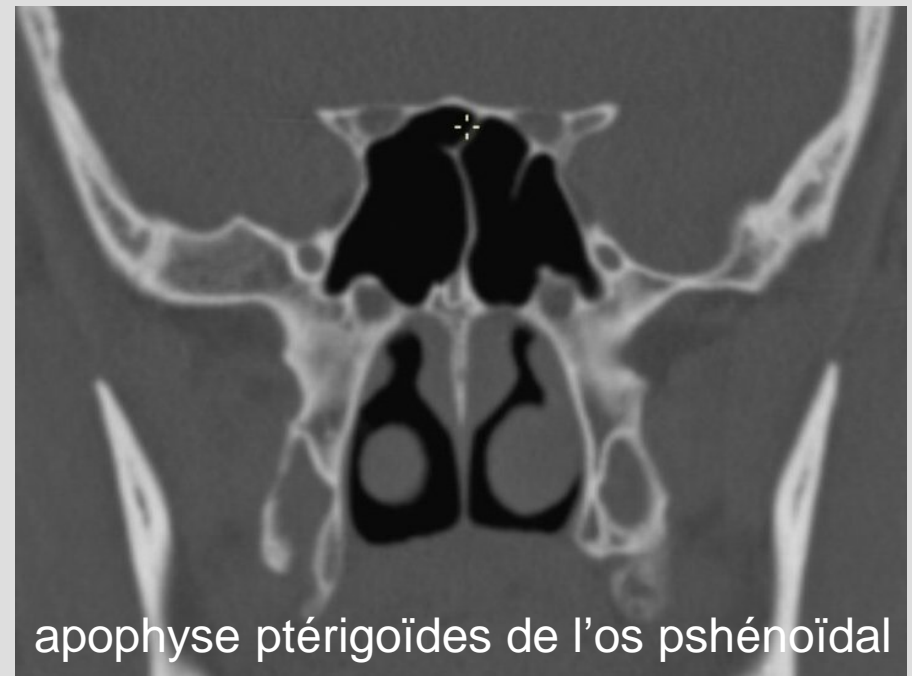
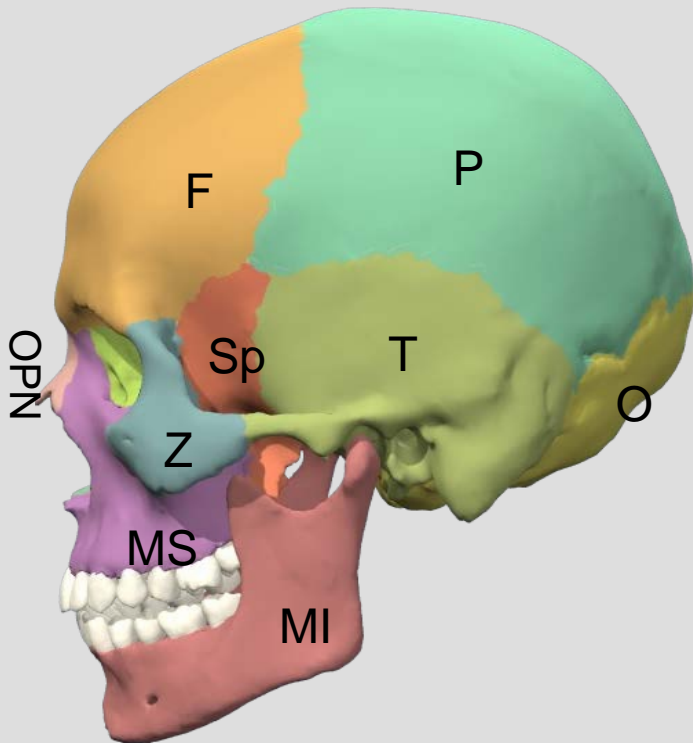
Deux
boîtes osseuses
contiguës...



crâne

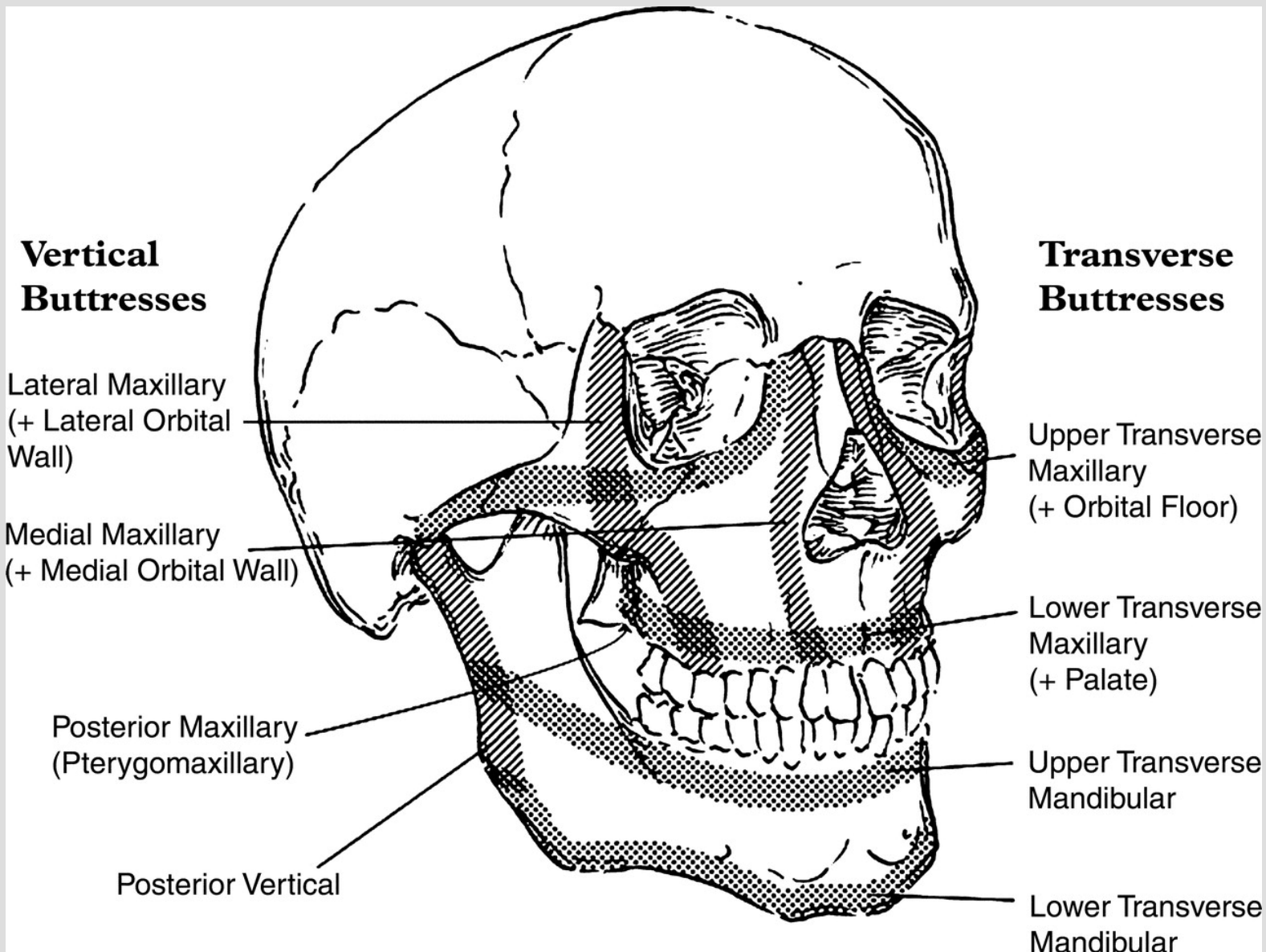


massif facial



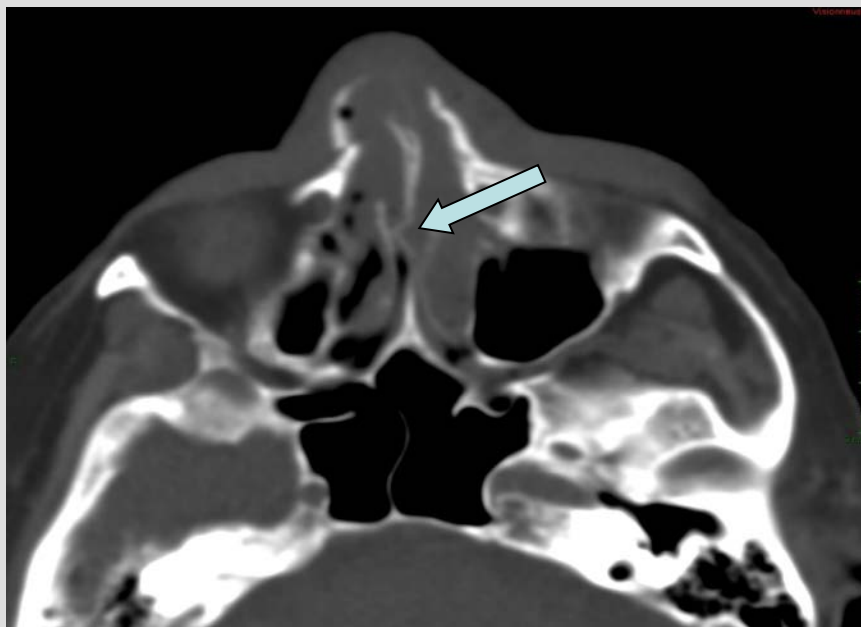
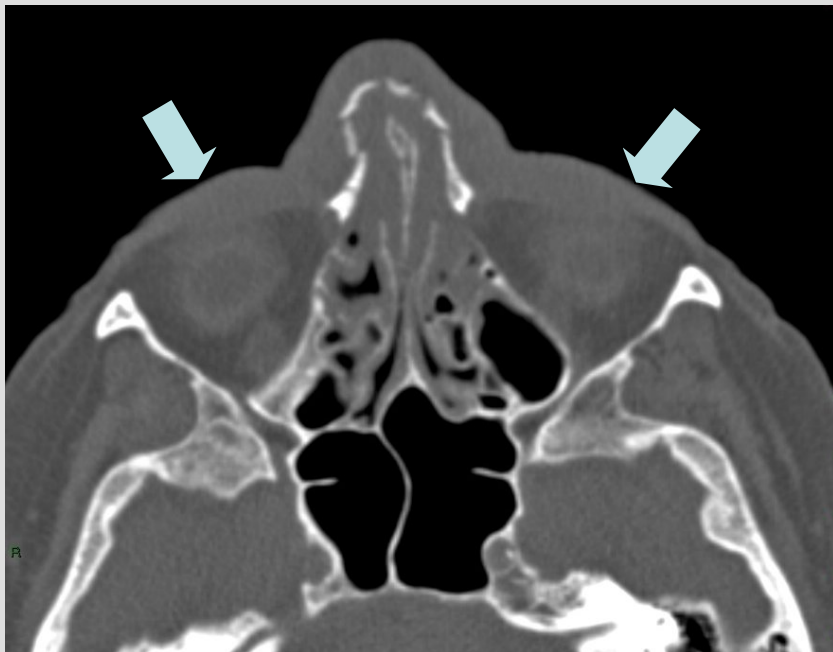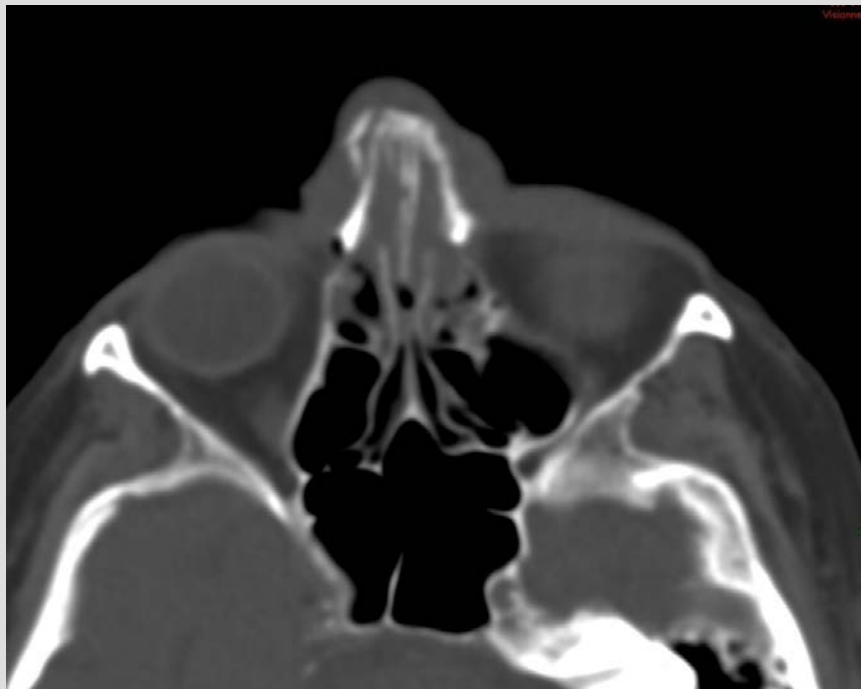
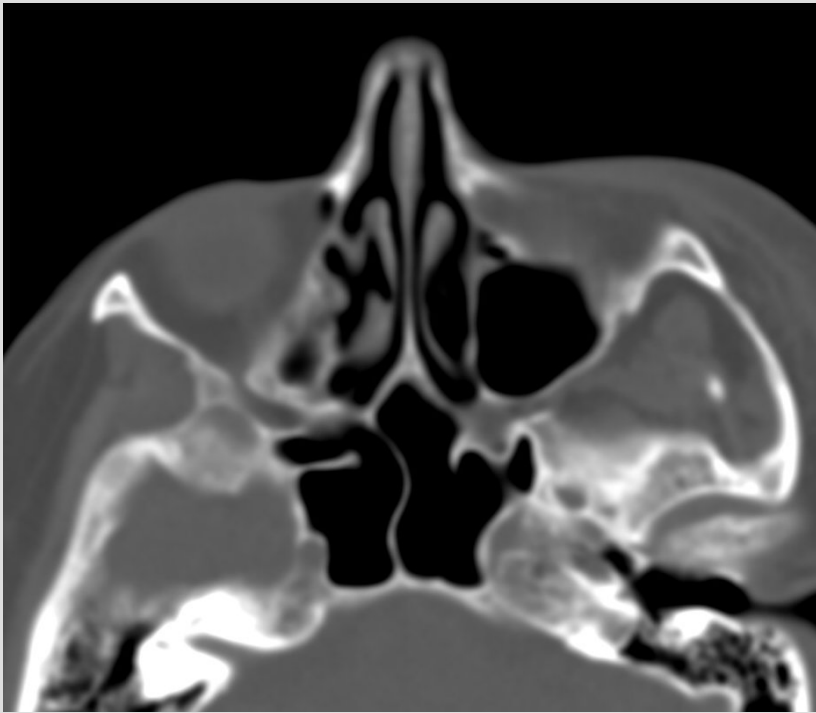
apophyse ptérigoïdes de l'os pshénoïdal

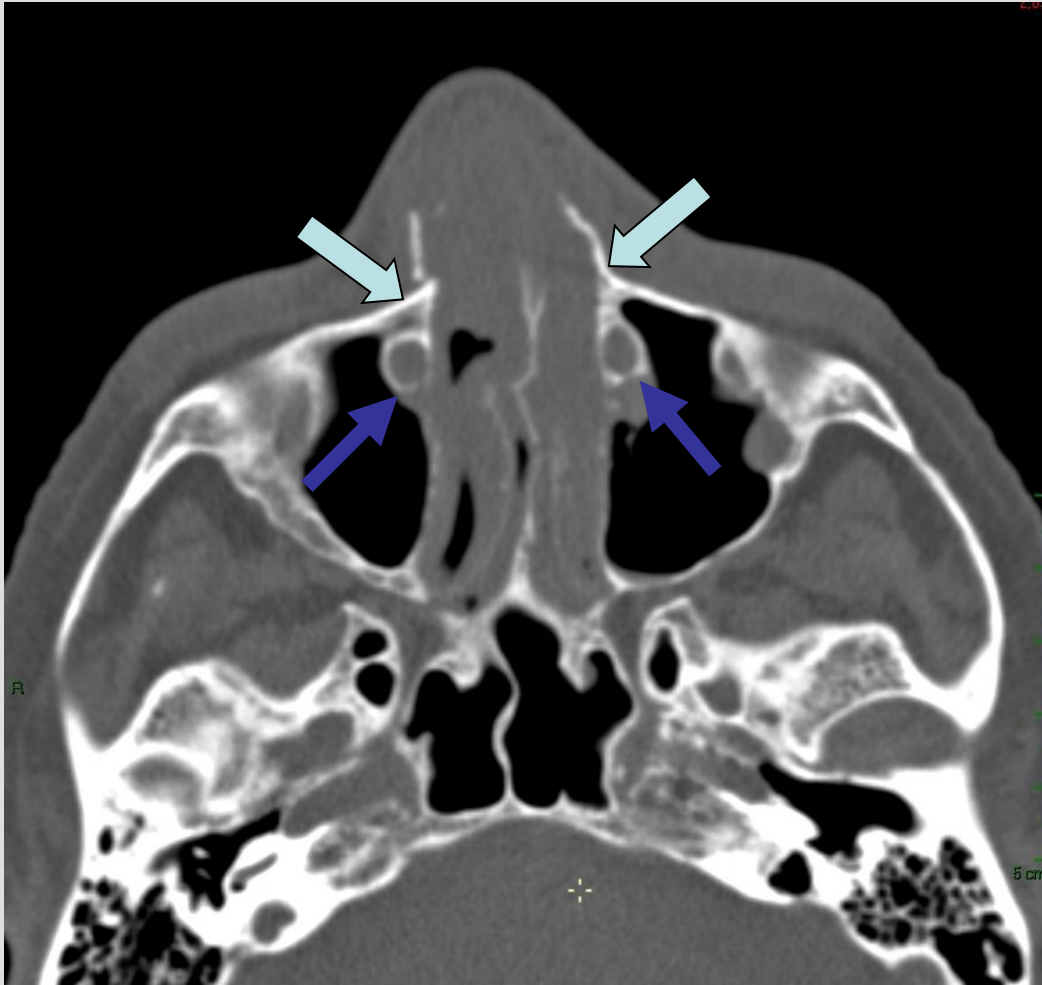
Piliers



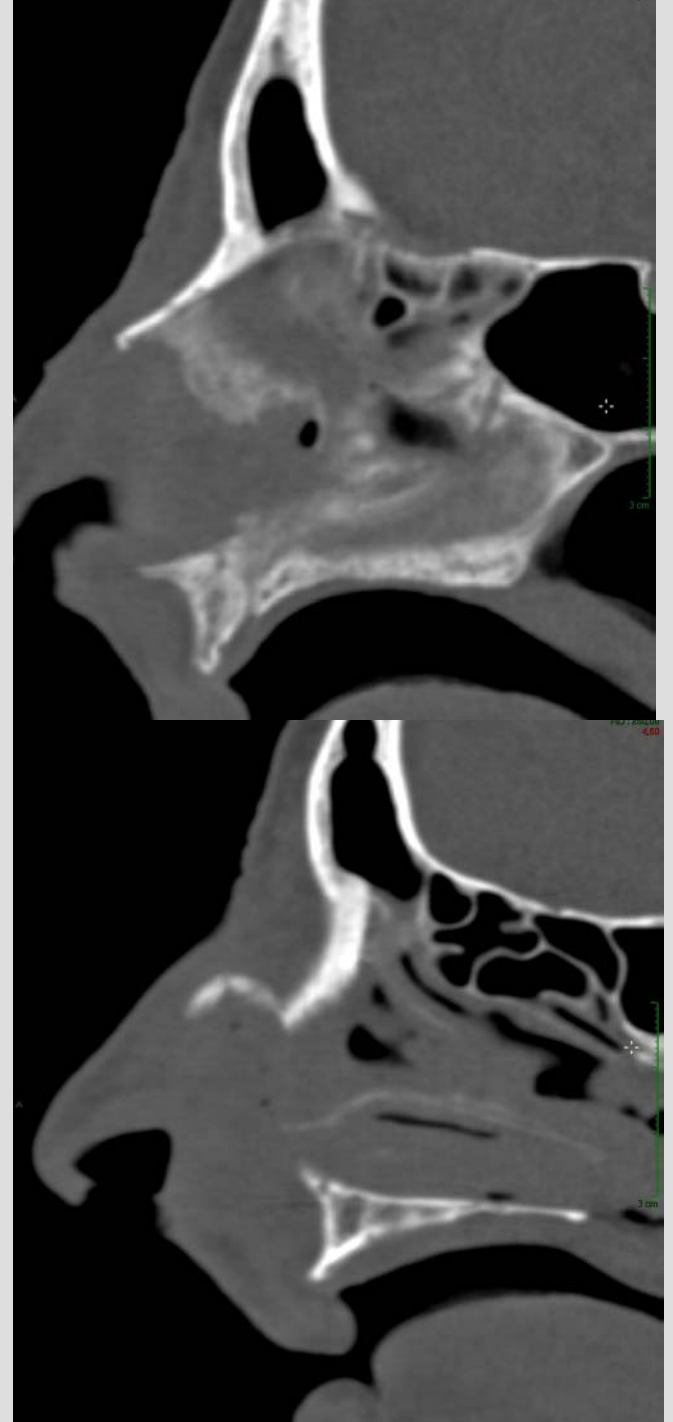
Fracture des OPN

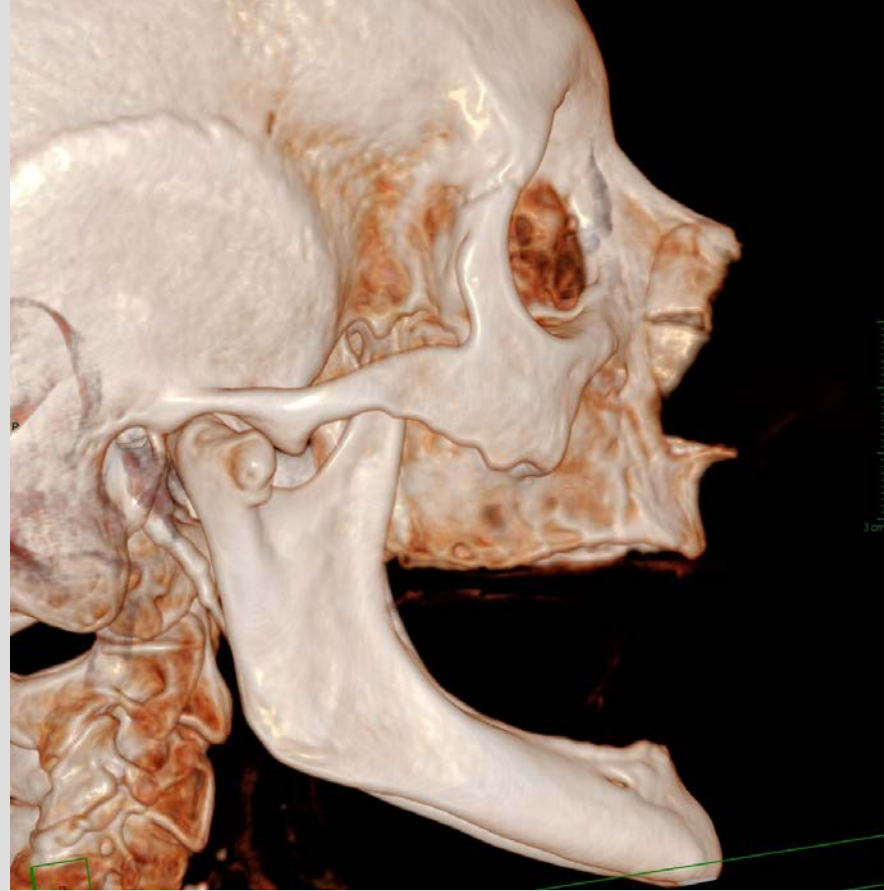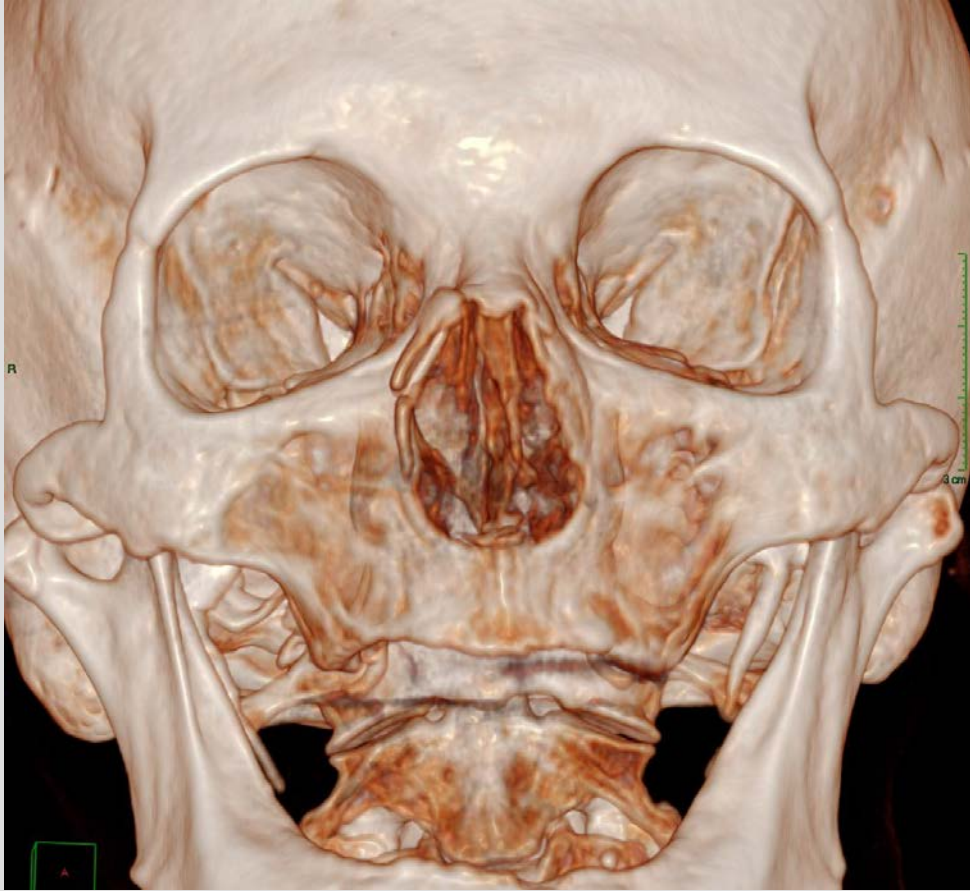
- Fracture la plus **fréquente** du massif facial (50%)
→ raisons anatomiques évidentes
- Le plus fréquemment **isolée**
→ particularisme au niveau du massif facial
- Par impact latéral (2/3) plus que frontal (1/3)






Pas de rupture du pilier maxillaire interne
Pas de fracture de l'os lacrymal

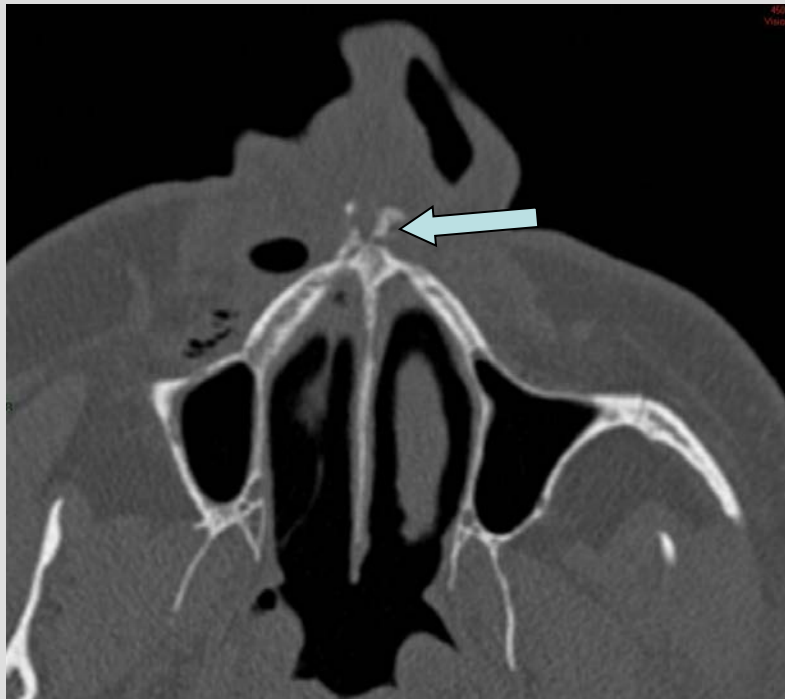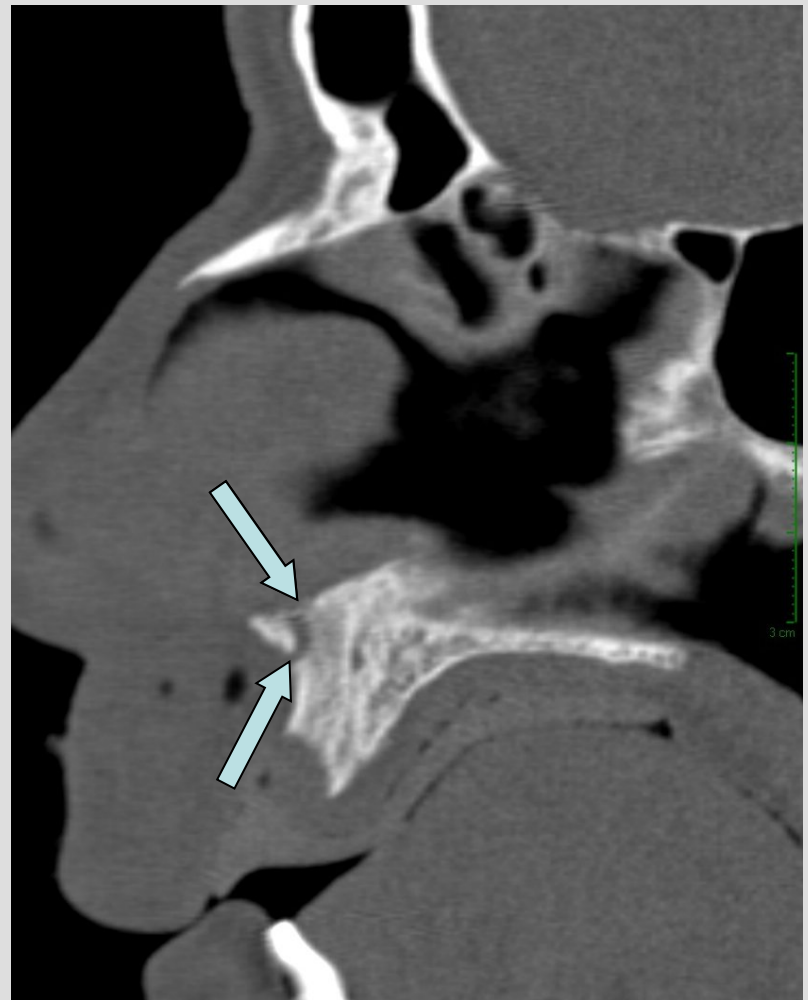

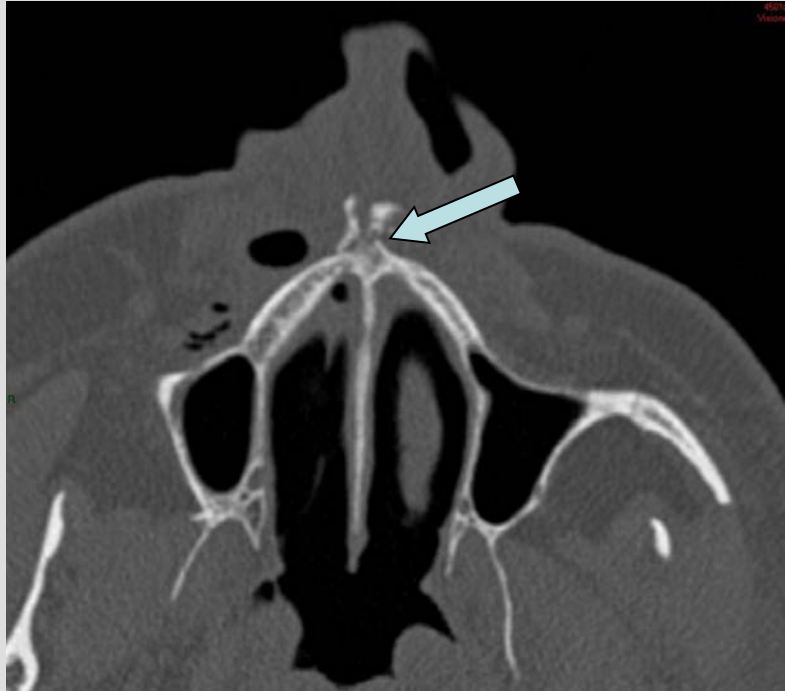


Fracture des OPN



- Deux tuyaux: rechercher
 - la fracture du **complexe naso-orbito-ethmoïdal (NEO)**
 - la fracture de l'**épine nasale inférieure et antérieure**



Epine nasale inférieure

→ (in)stabilité de la pyramide nasale ?

Disjonction du complexe naso-orbito-ethmoïdien (NOE)

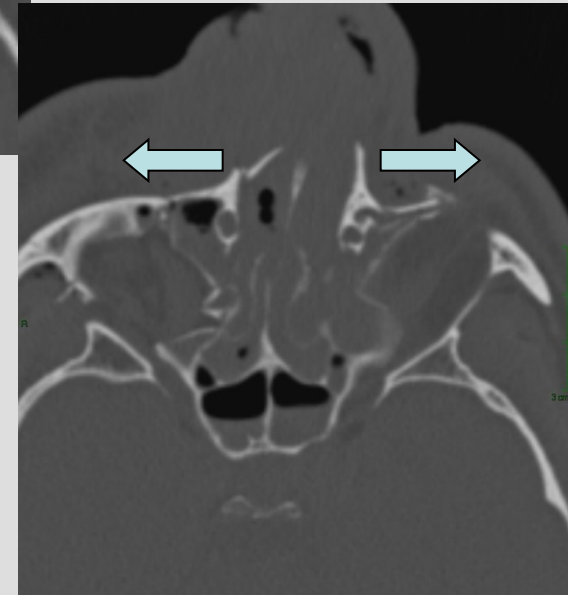
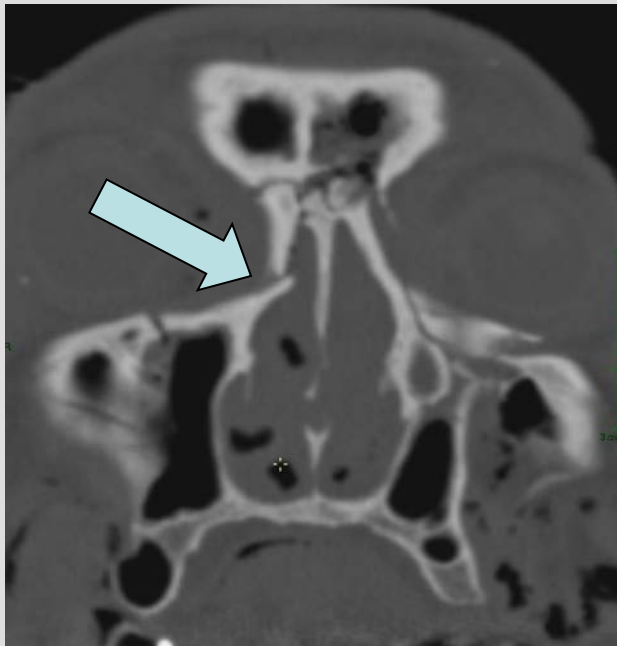
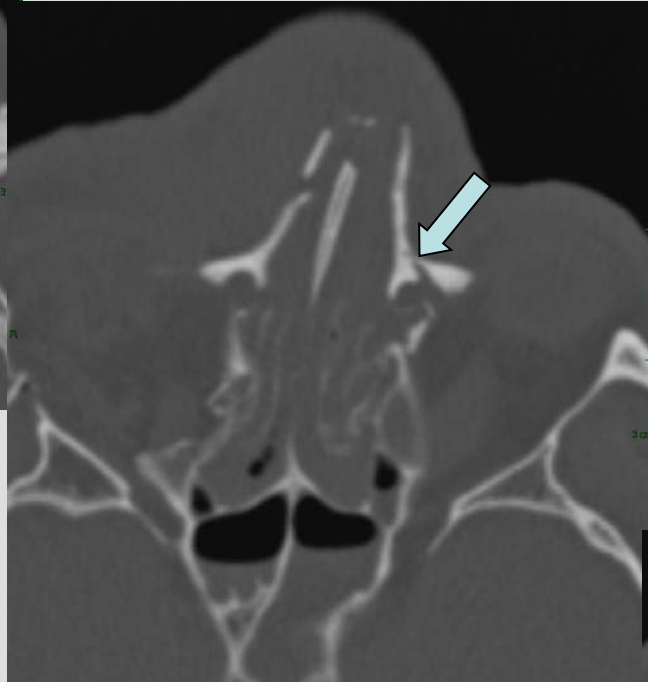
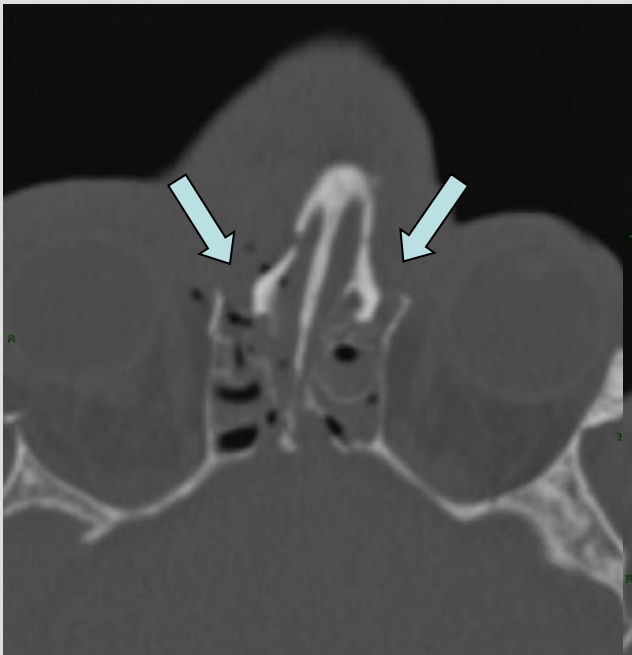
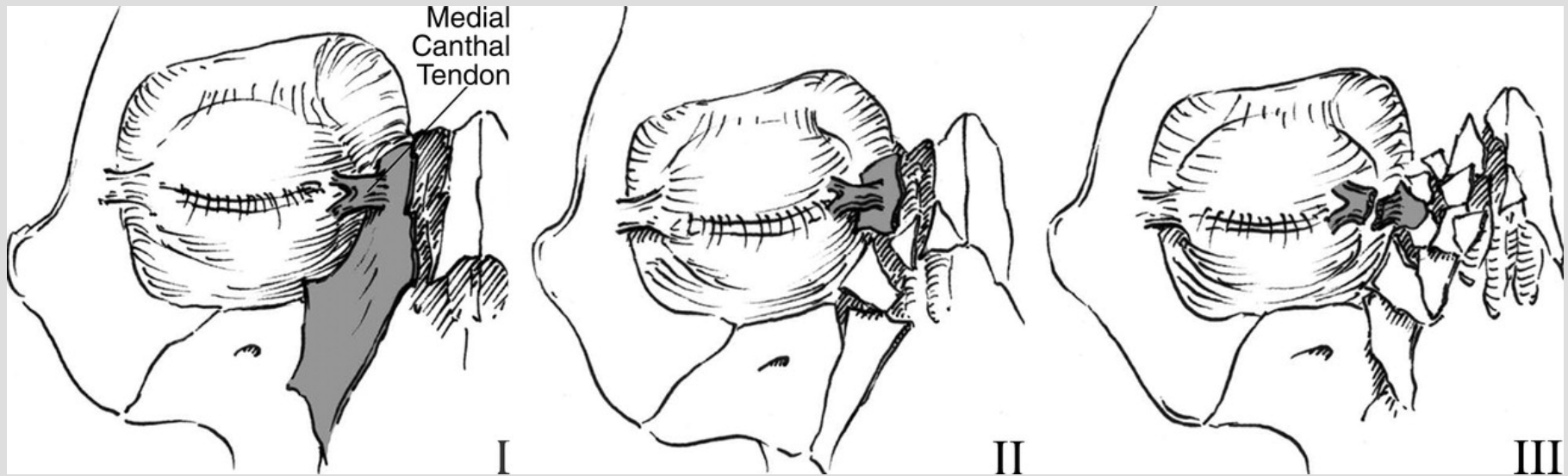


Figure 3. Drawings show the Manson classification of NOE fractures.

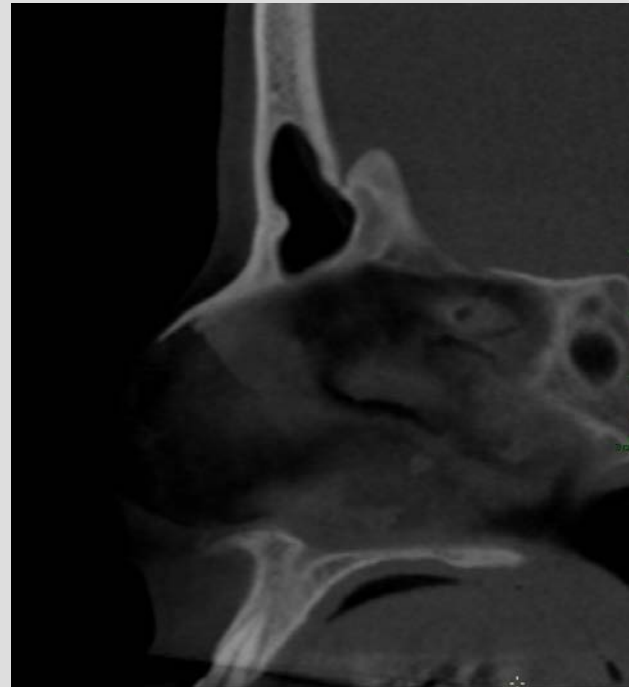
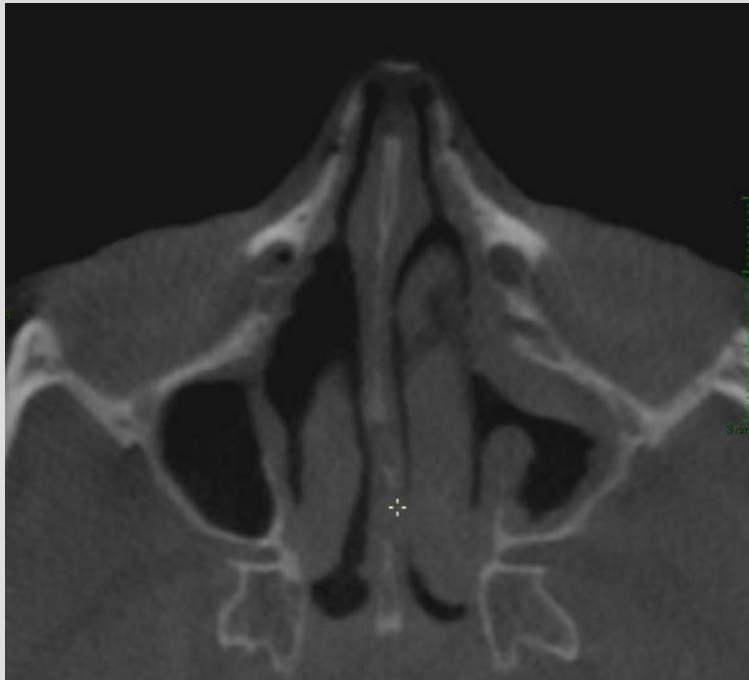
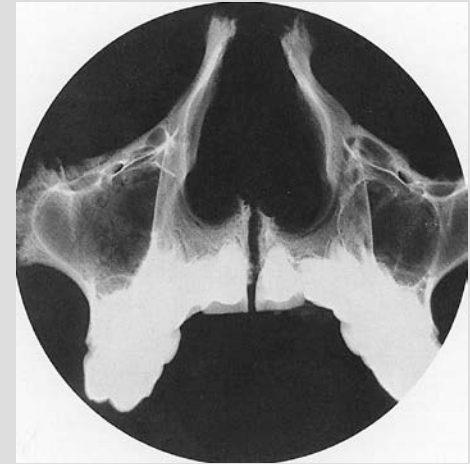


Hopper R A et al. Radiographics 2006;26:783-793

©2006 by Radiological Society of North America

Fracture des OPN

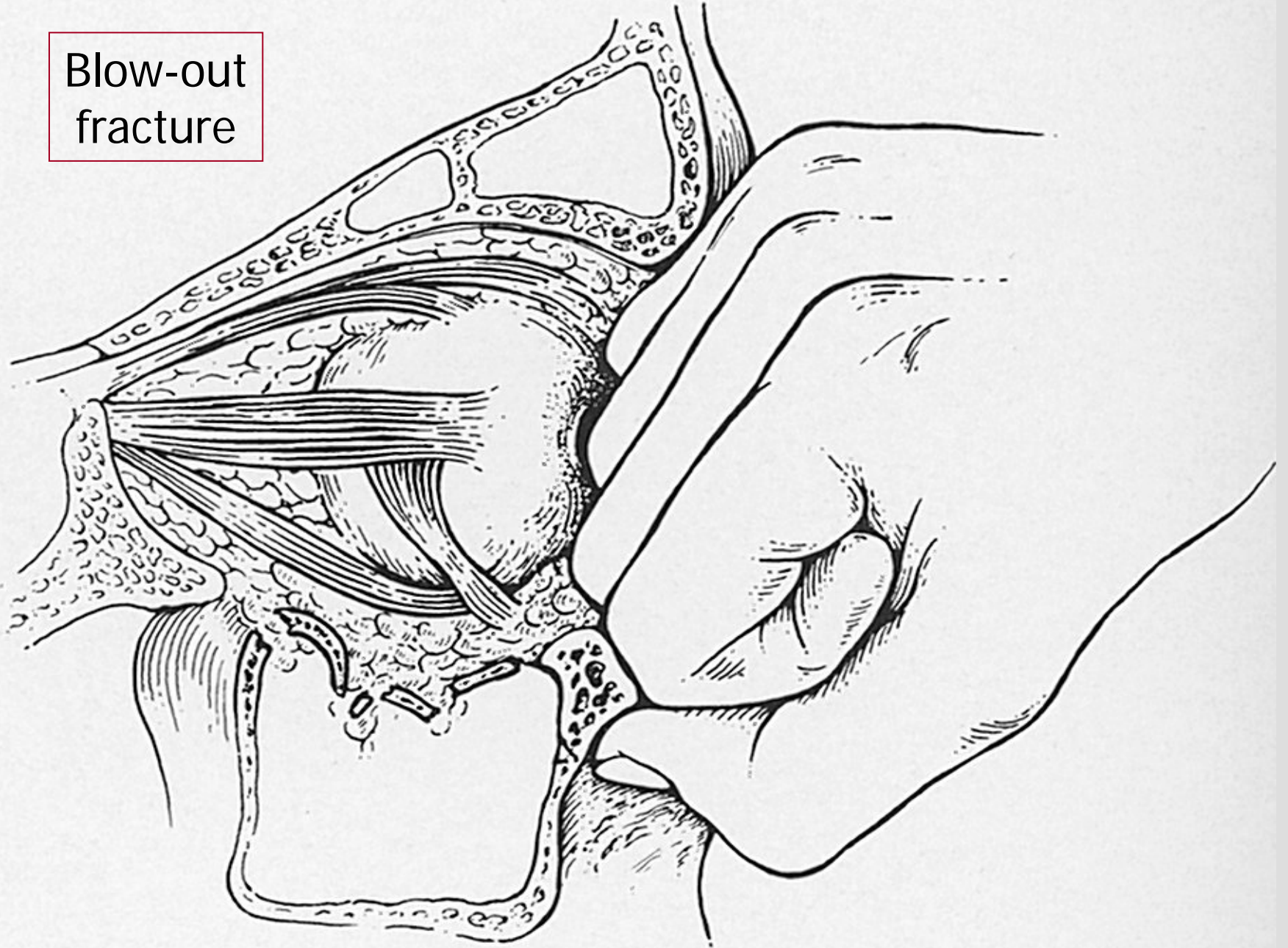
- *Place pour le cliché RX standard ?*
- *CT scanner → low-dose ou CONE-BEAM-CT*

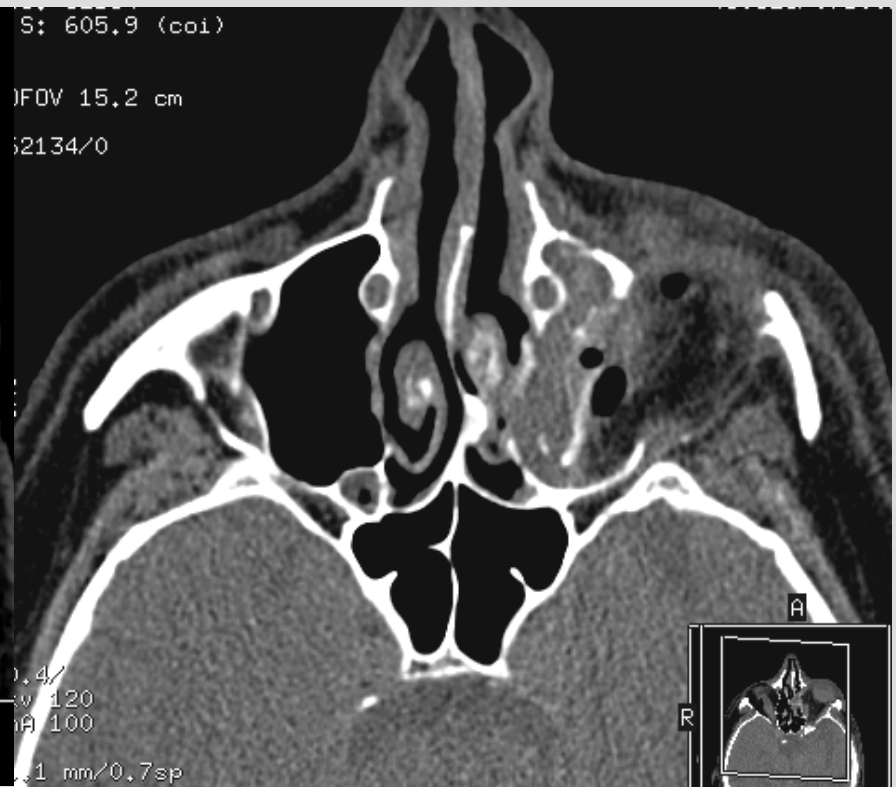
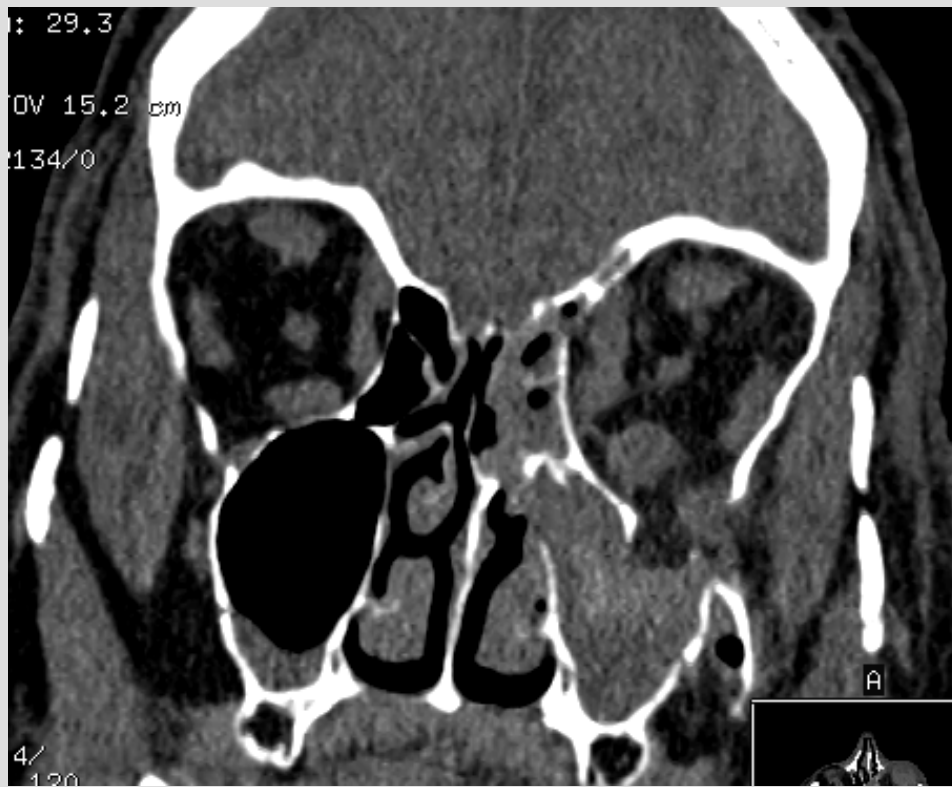
Fracture du plancher orbitaire


- plancher **isolé** ?
- ...mono-associée: autre segment du **cadre orbitaire**
- ...ou poly-associée
 - # de Le Fort
 - # du tripode malaire
- **'Blow-fracture'**
 - **Blow out** → décompression spontanée
 - traumatisme de face
 - par objet plus large que le cadre orbitaire
 - **Blow in**
 - traumatisme latéral
 - objet de plus petite dimension
 - Traumatisme pénétrant

Blow-out
fracture

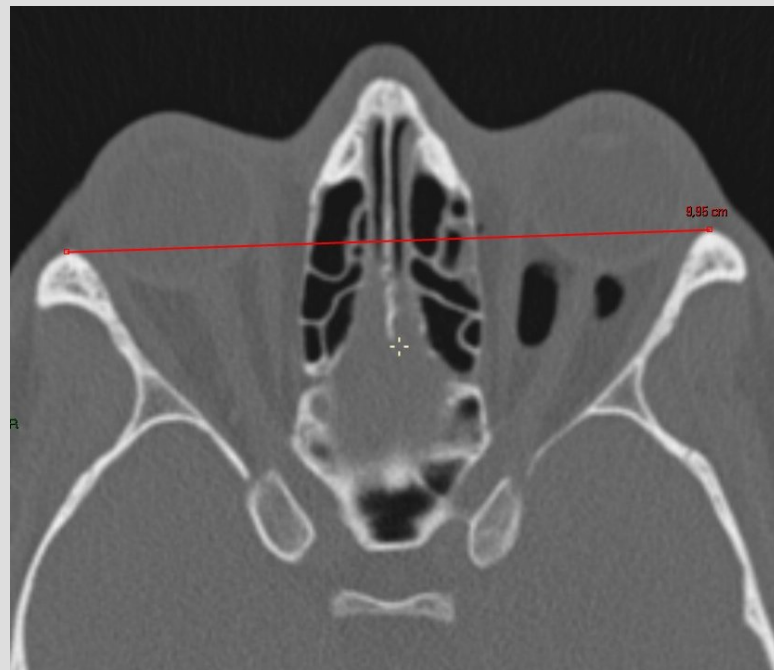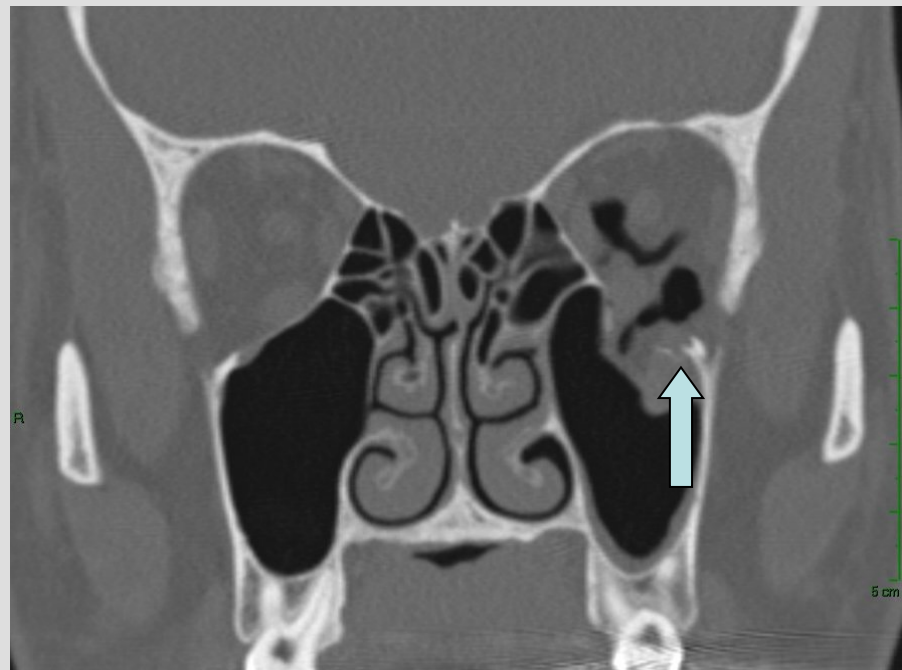
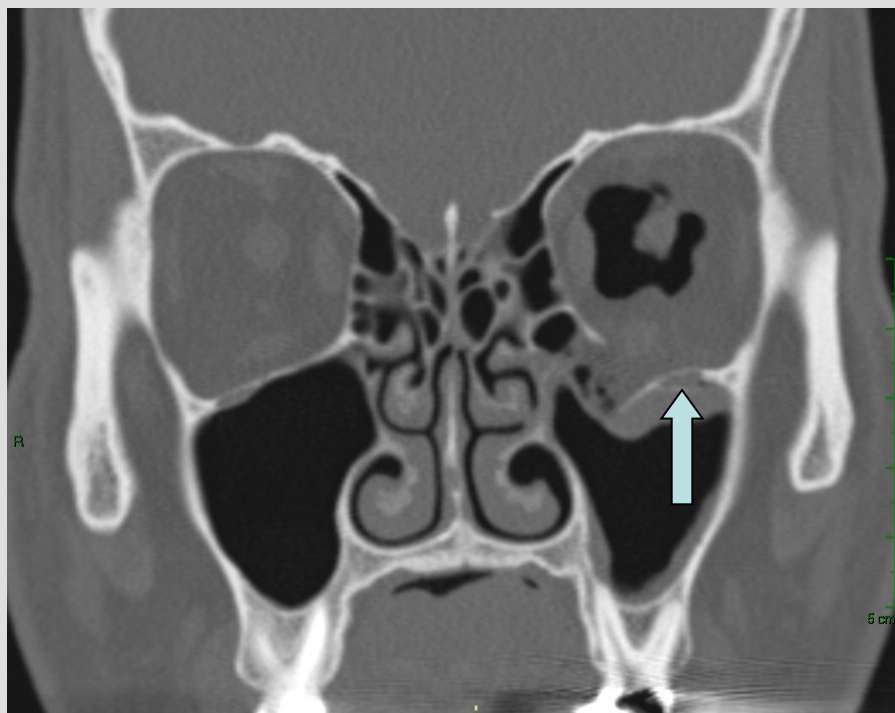
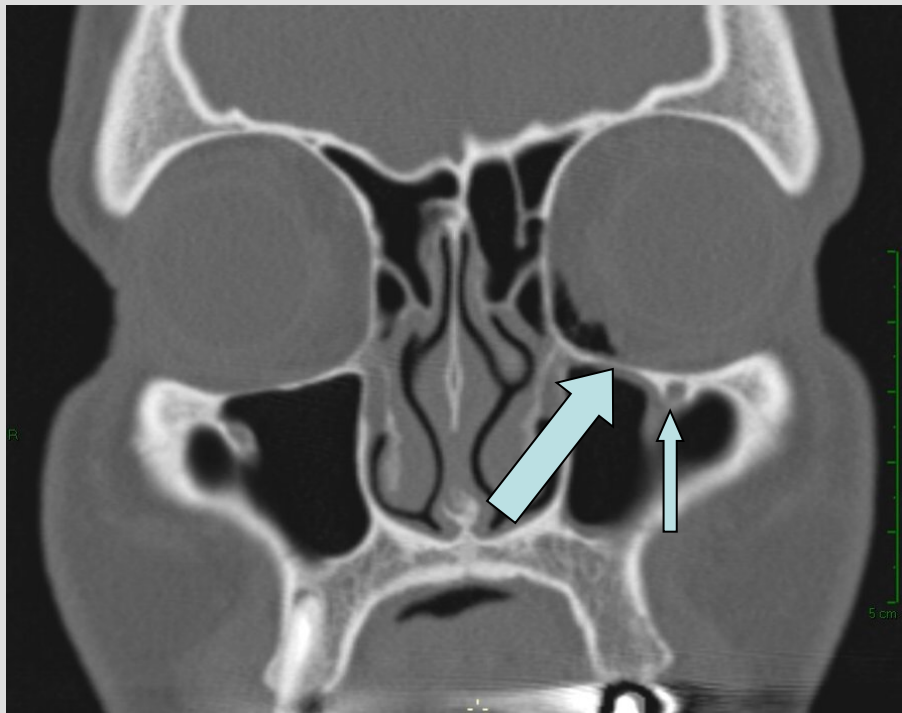




elle-même
emphysème orbito-palpébral
hémosinus
hernie de graisse orbitaire
incarcération musculaire



MPRs
en incidence *frontale* !

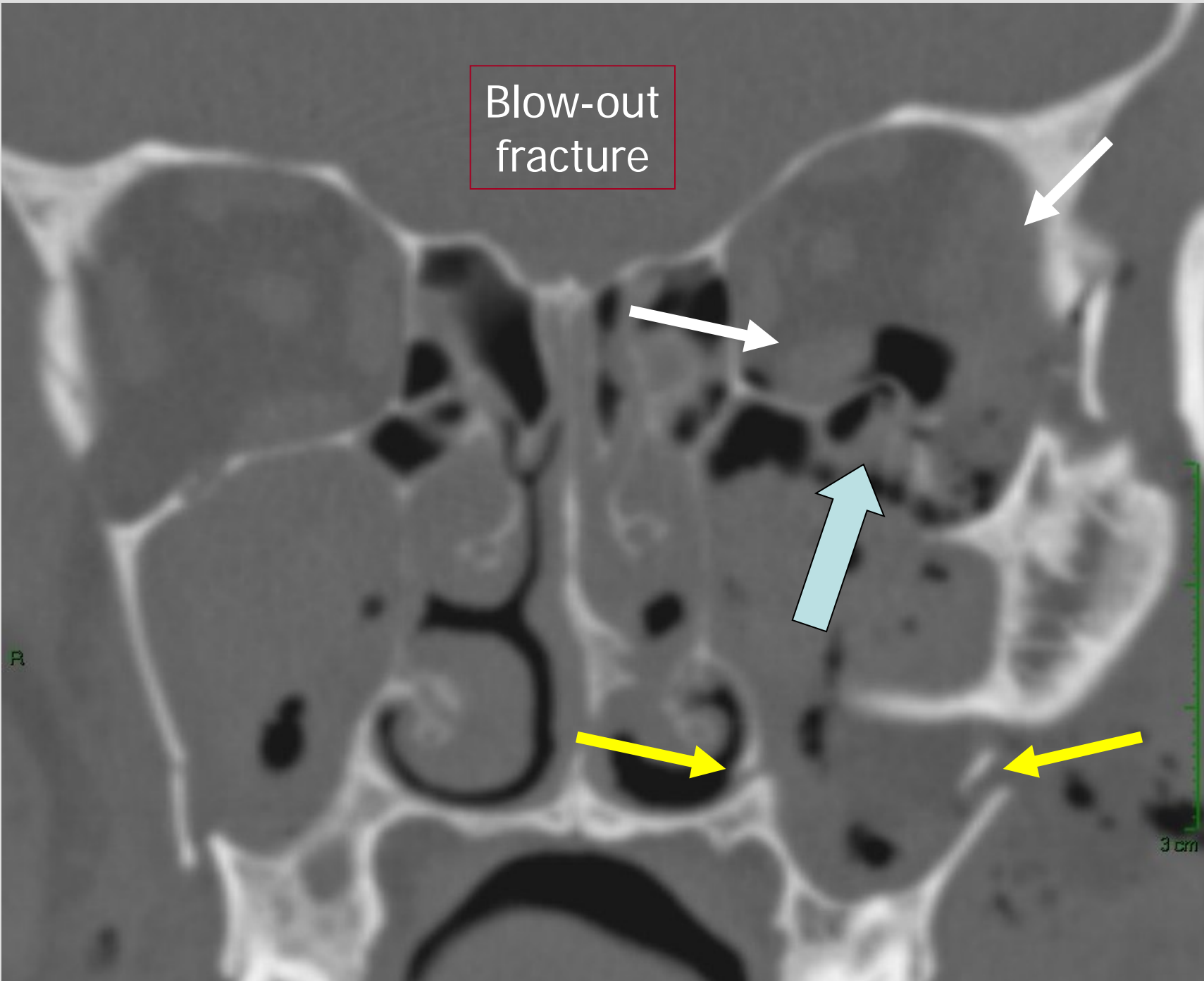


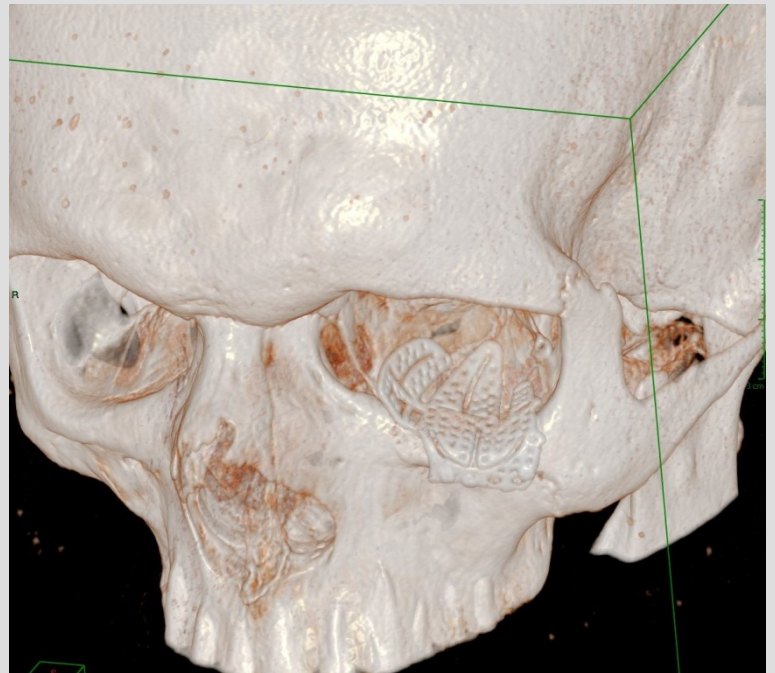
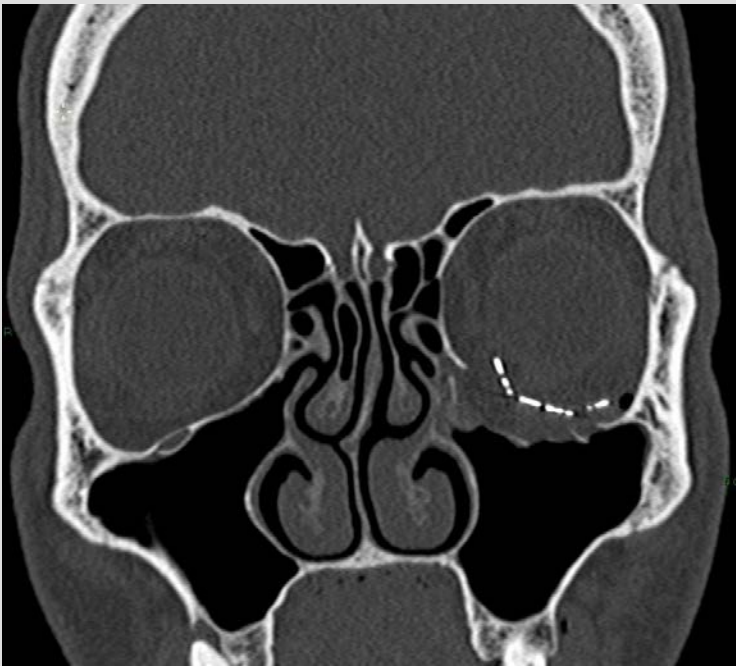
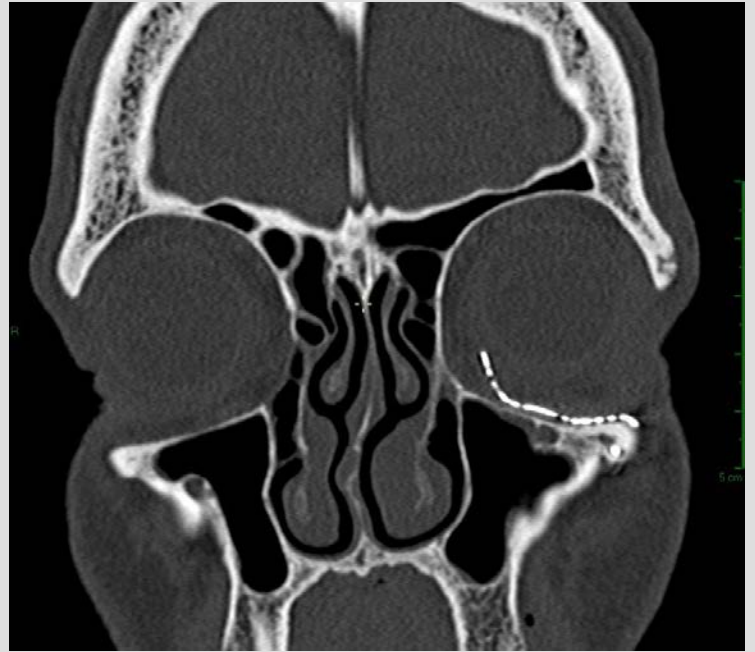
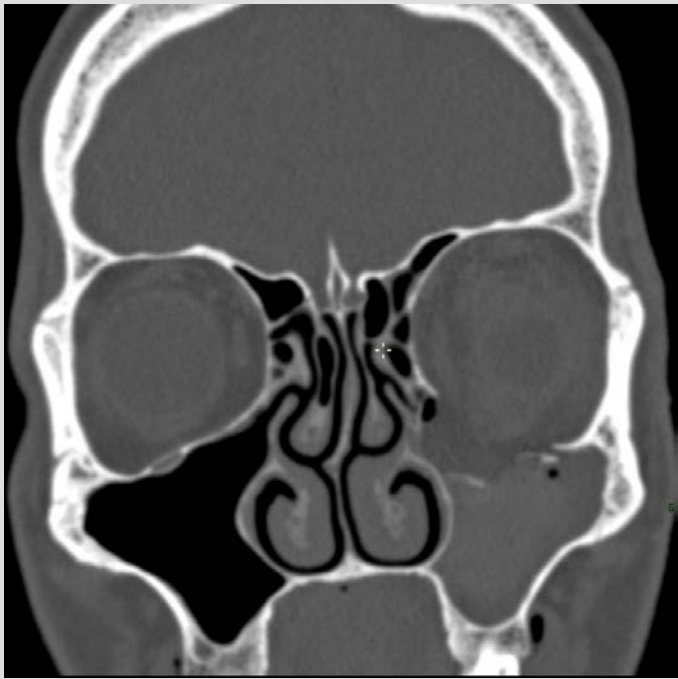
Blow-out fracture

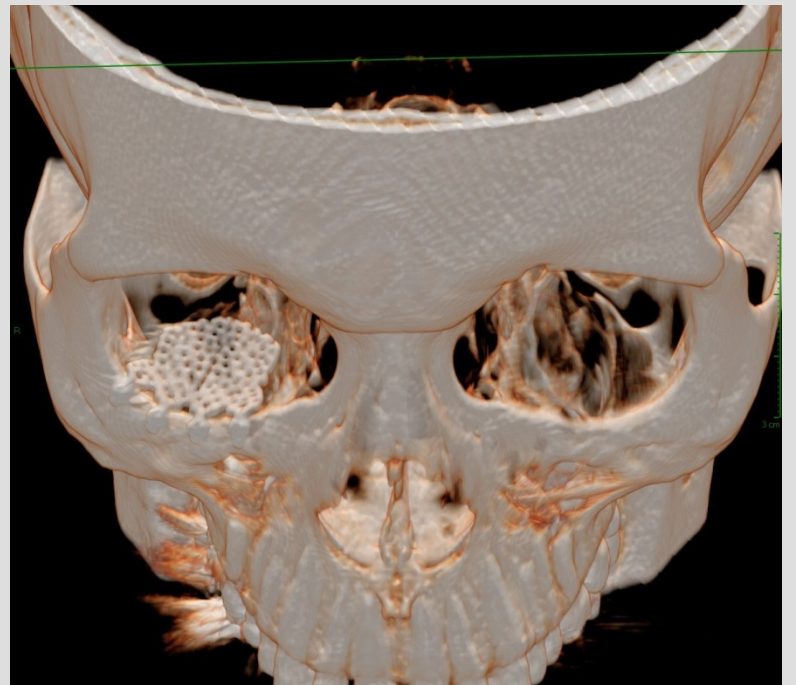
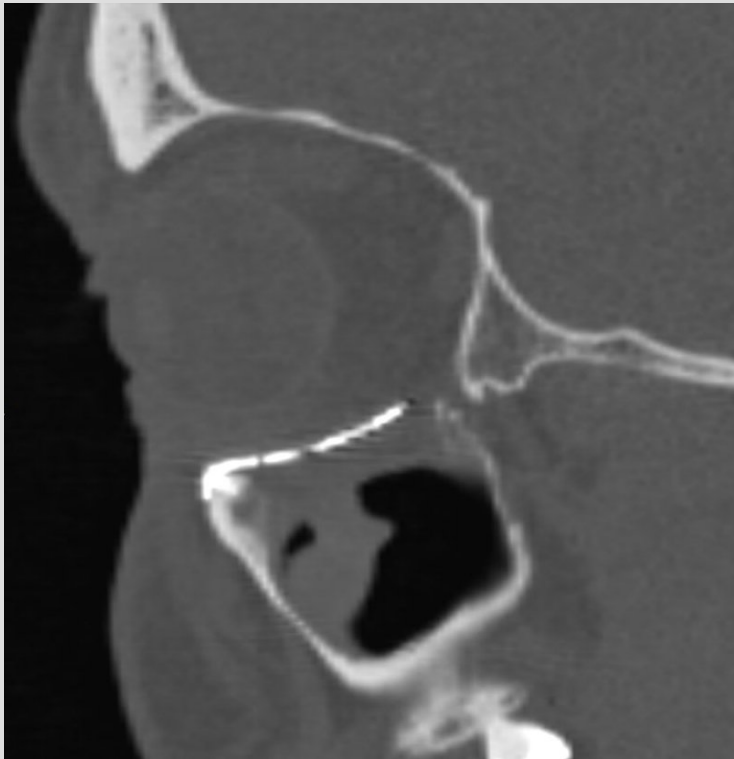
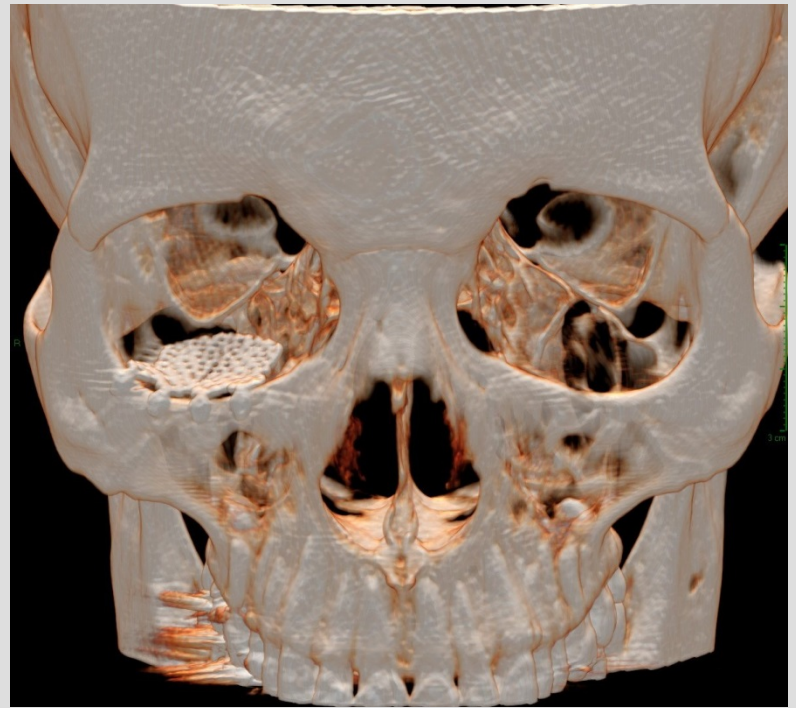
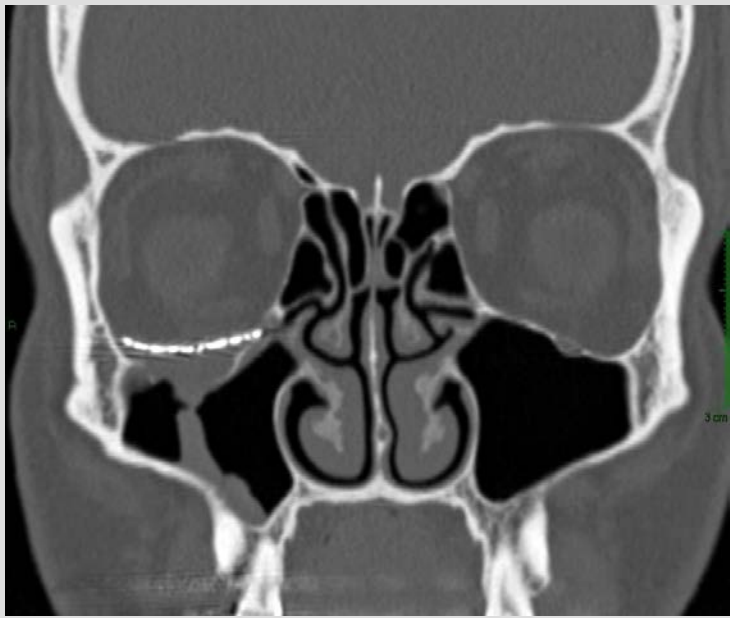


R

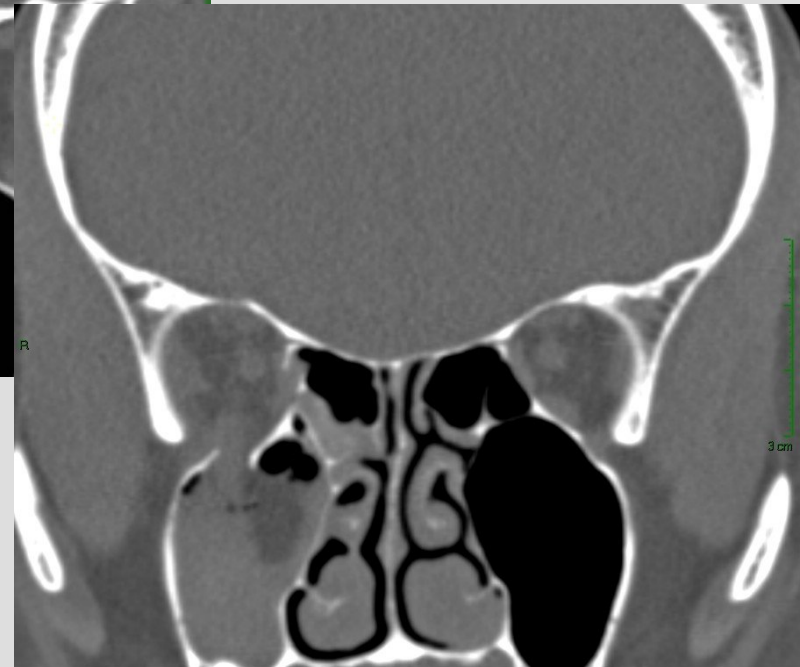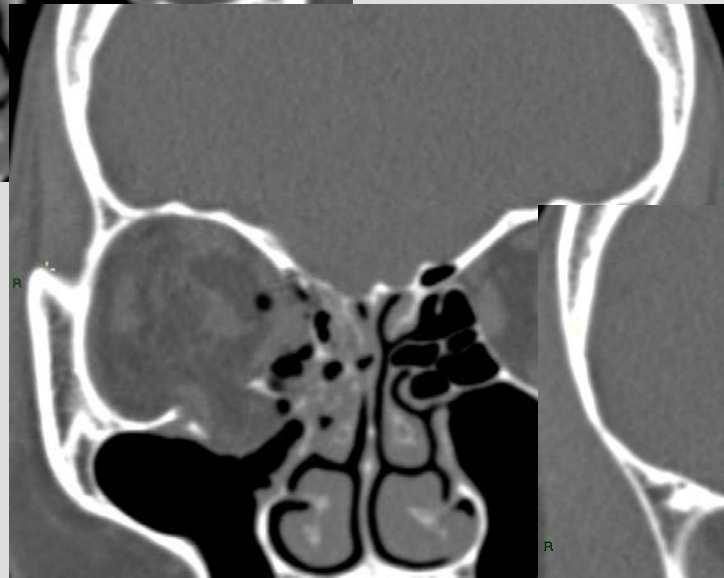
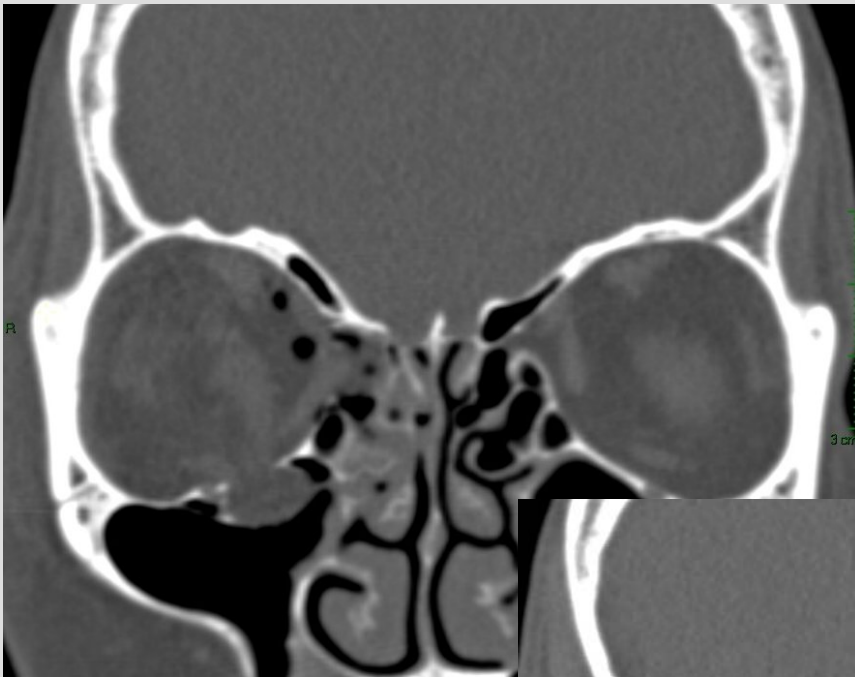3 cm





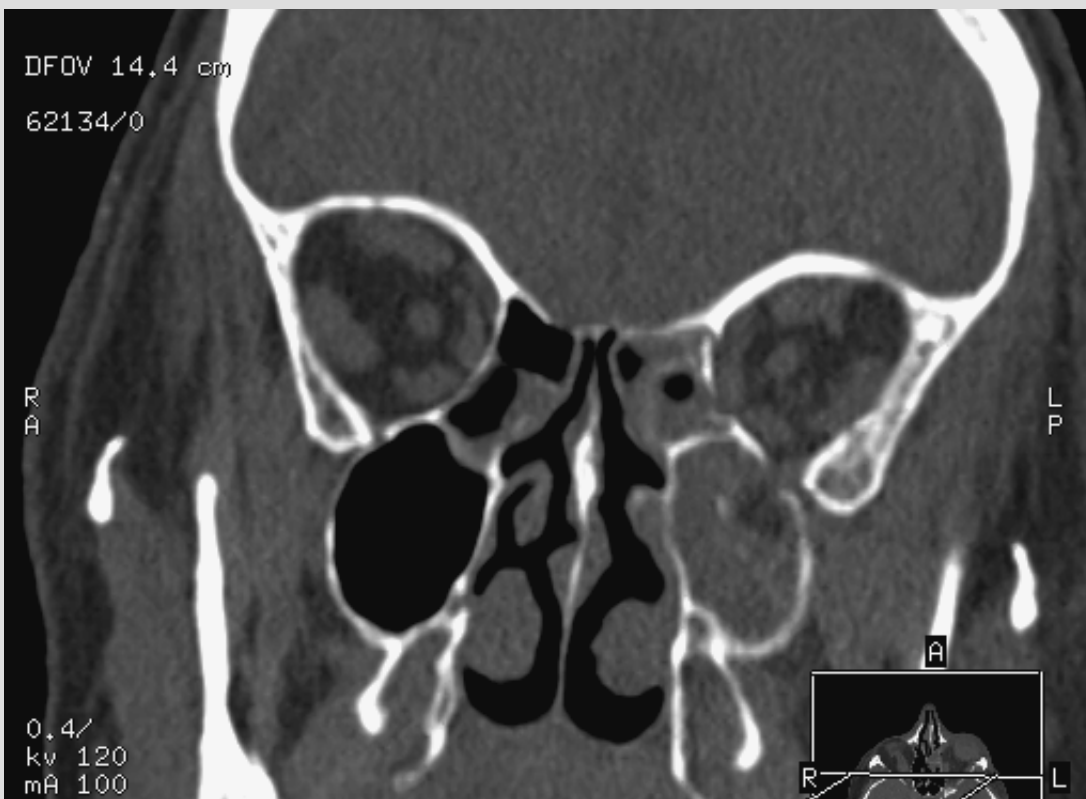


Status des muscles extra-oculaires (MEOs)



Déplacé ?
Tuméfié ?
Incarcéré ?
Embrosché ?

Diagnostic fonctionnel clinique

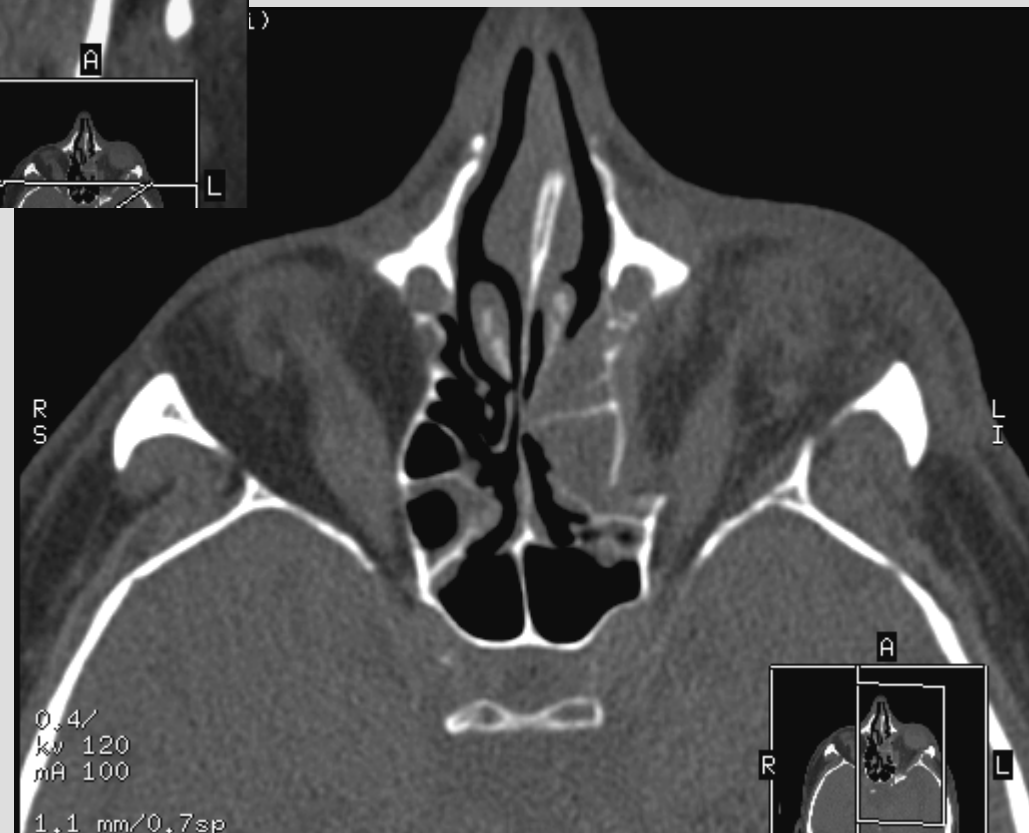

Paroi interne de l'orbite

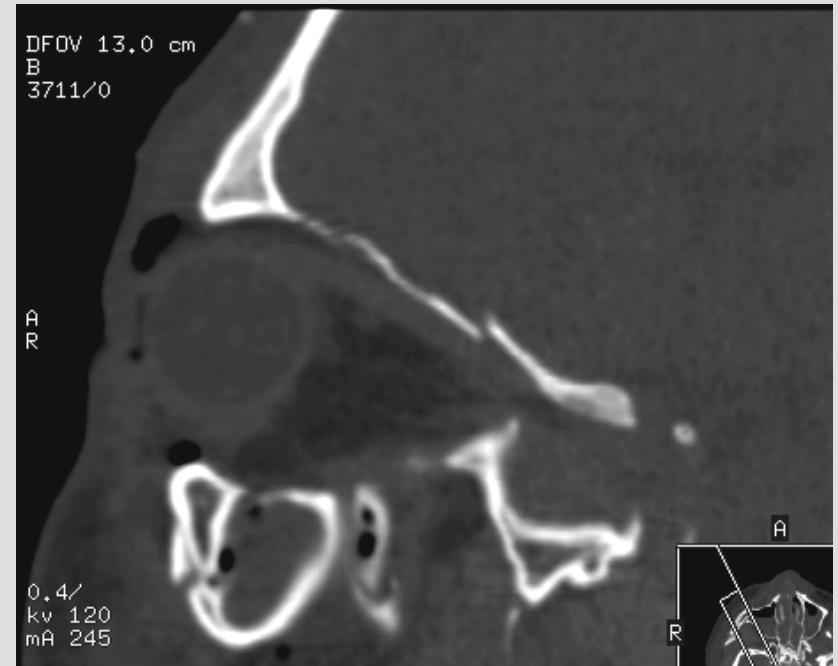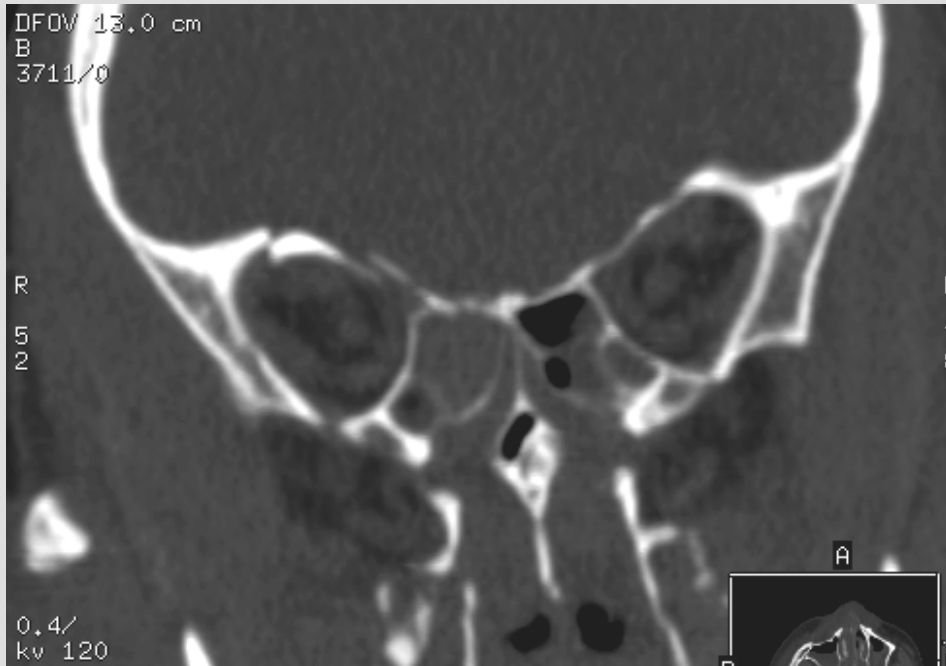
**Moins fréquente
mais fréquemment associée
à la # du plancher
(‘deuxième tampon’)**

Paroi mince mais résistante (septa)

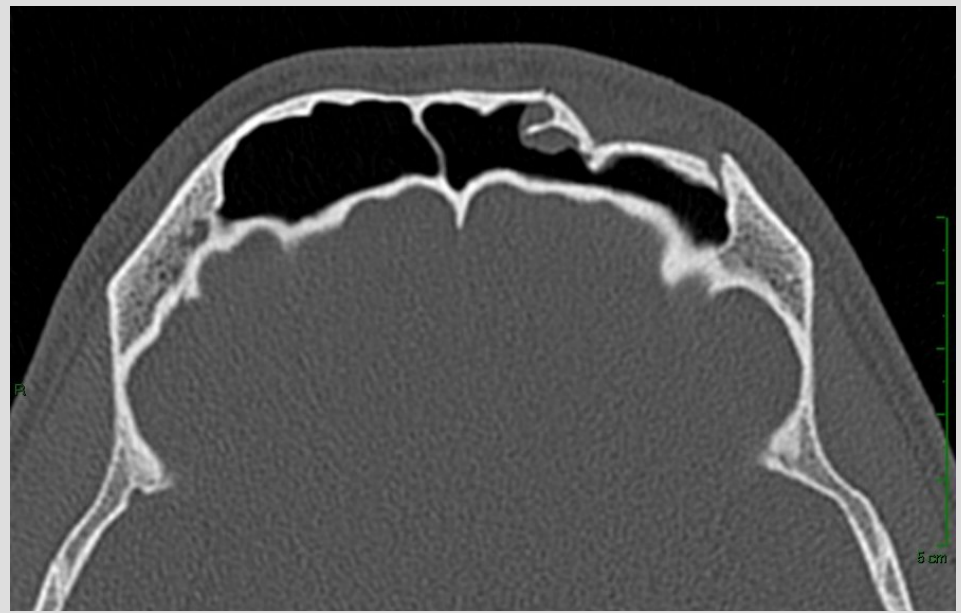
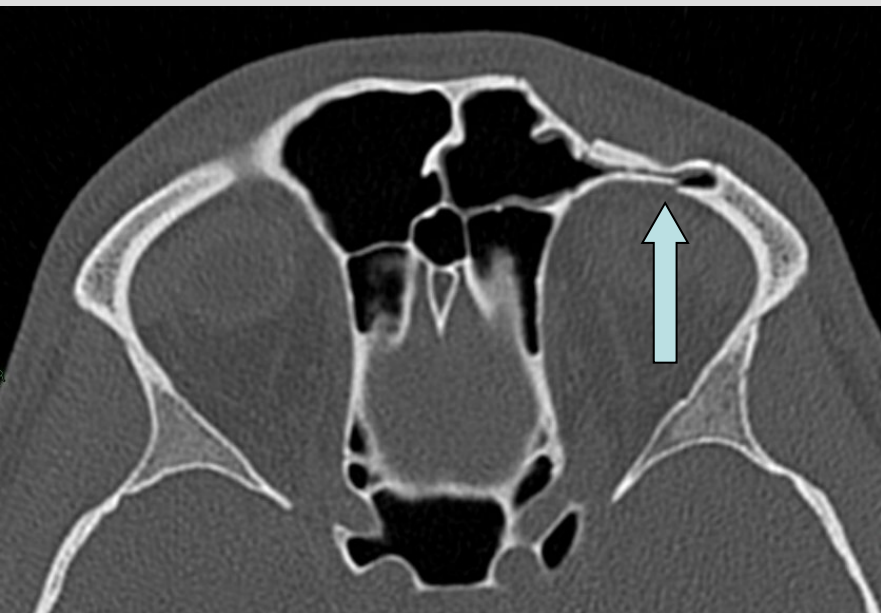**Exceptionnellement isolée
Hernie graisseuse fréquente
incarcération du D.Int. rare**



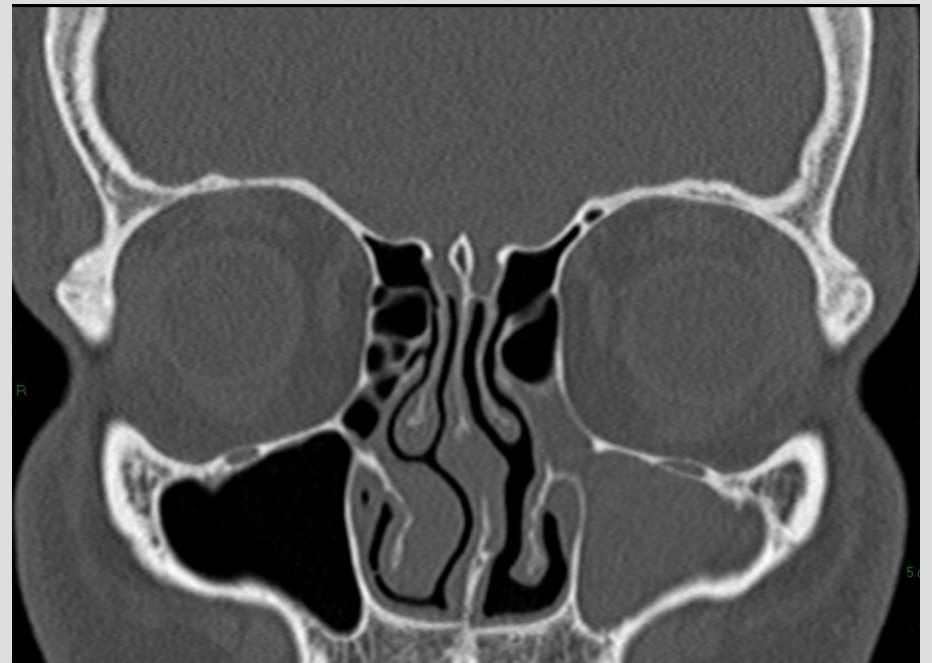
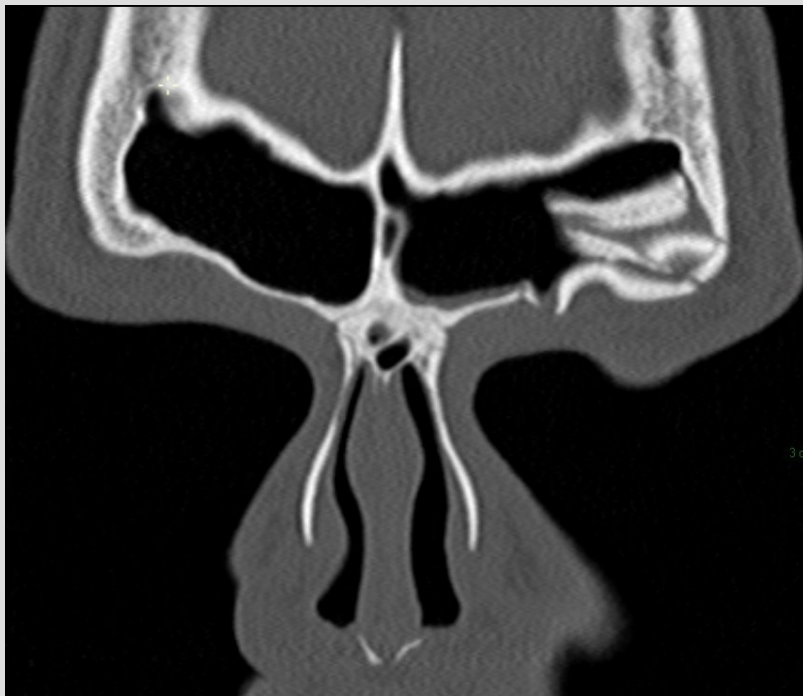Toit orbitaire

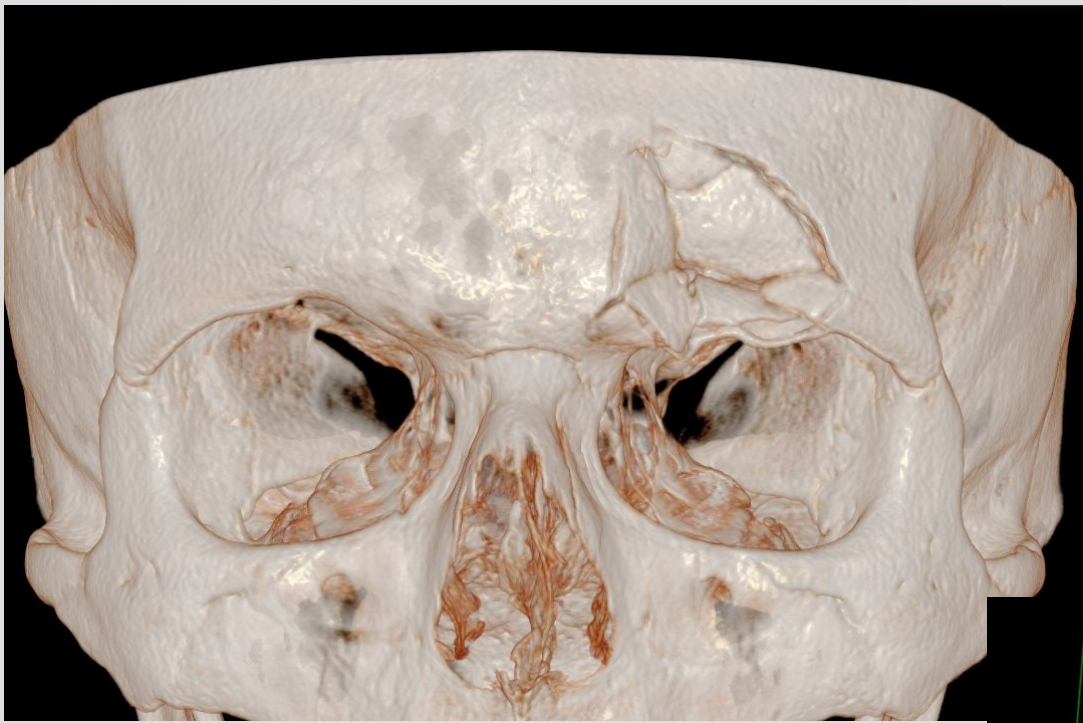


- Relativement rare (os frontal solide)**
- Le plus souvent # du rebord orbitaire et du plancher des sinus frontaux**
- Hématome sous-périosté (parfois retardé)**
- Complications cérébro-méningées**
 - Contusions parenchymateuses**
 - Brèche ostéo-dure-mérienne (fuite de LCR)**



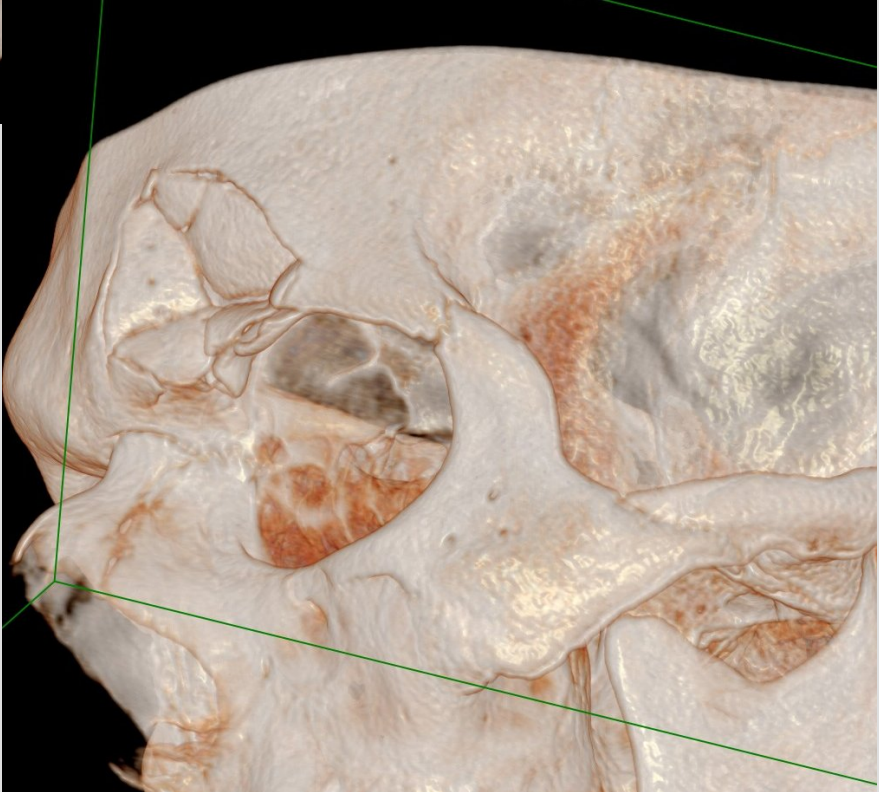
Fracture du sinus frontal





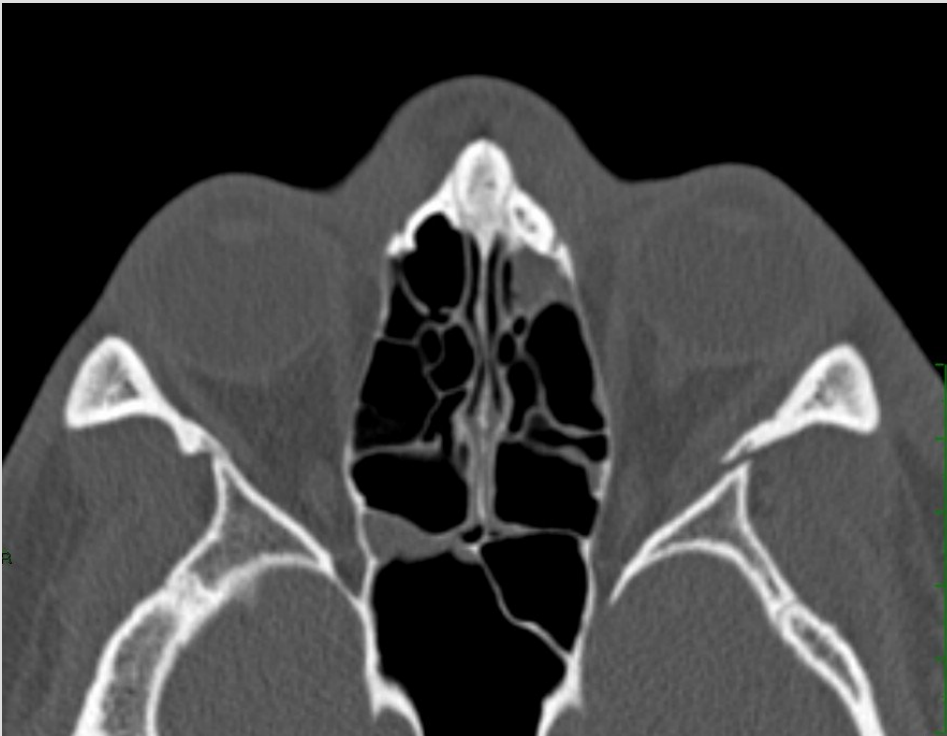Préservation du toit orbitaire

Préservation du mur postérieur du sinus frontal



la paroi orbitaire externe

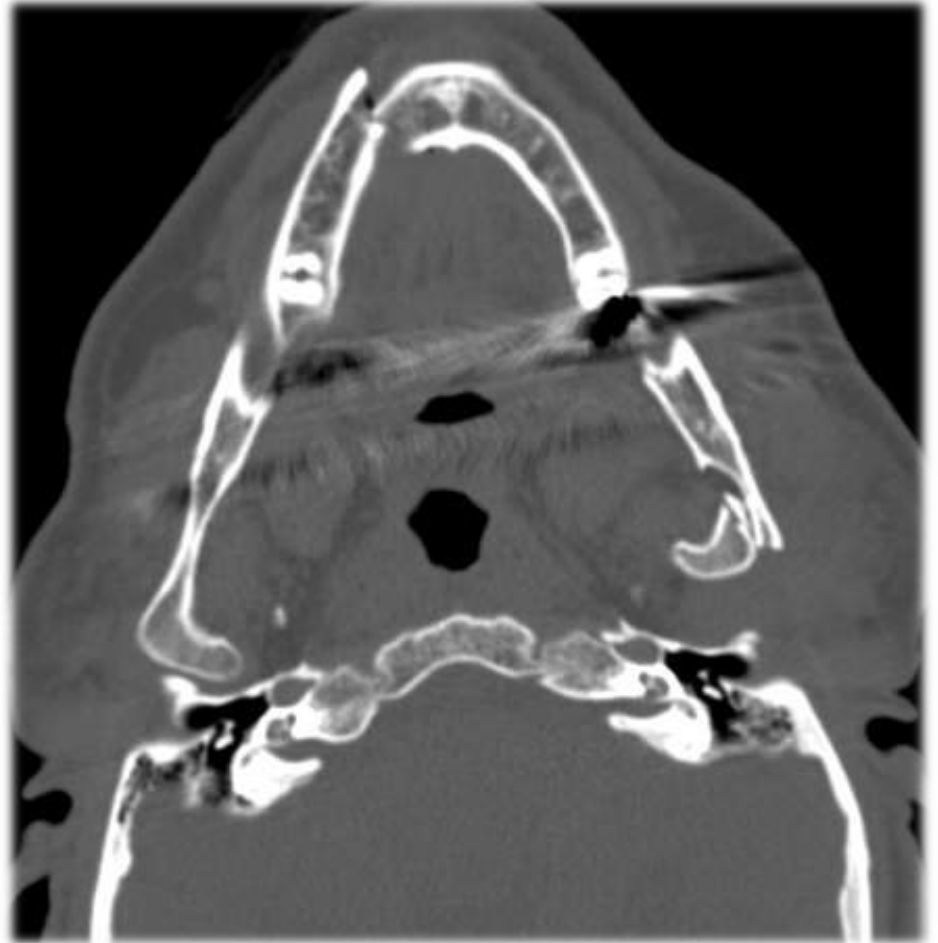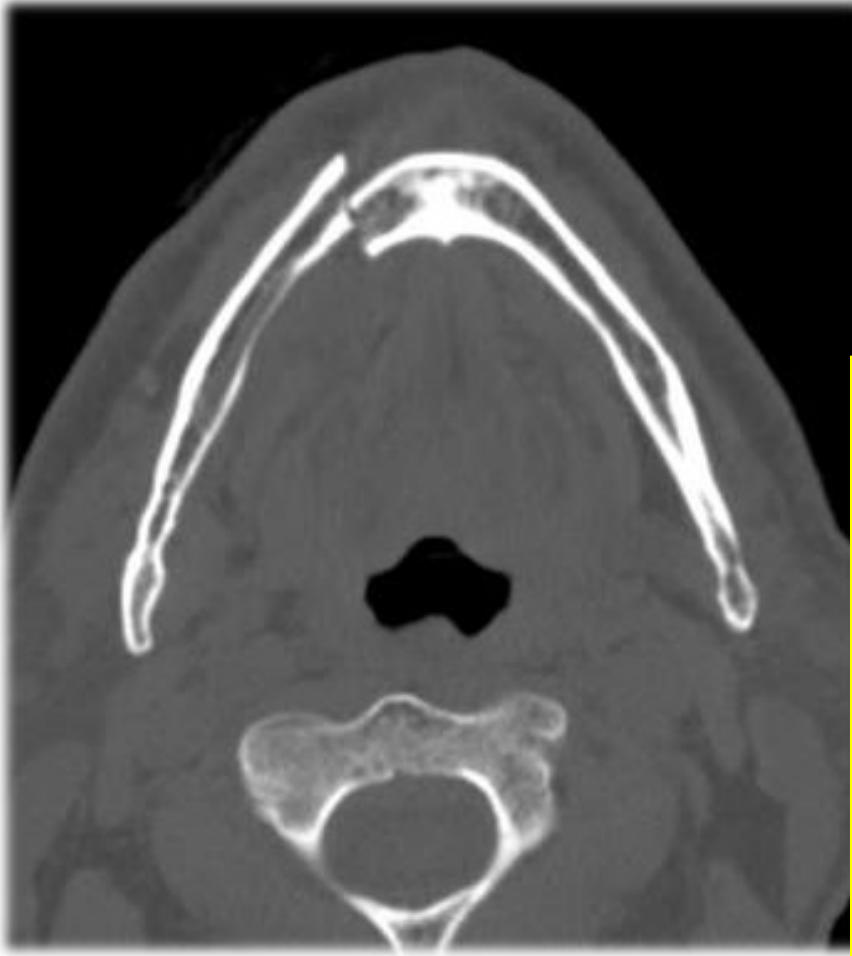- Rare isolée (os épais)
- Fréquemment combinée
 - Unilatéralement: trépied malaire
 - Bilatéralement: # Le Fort III

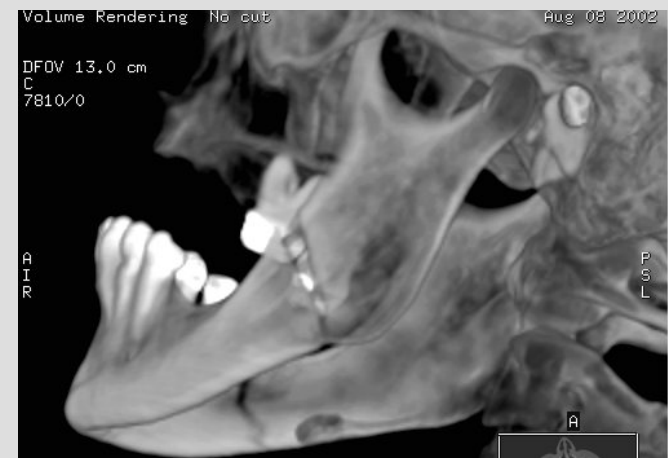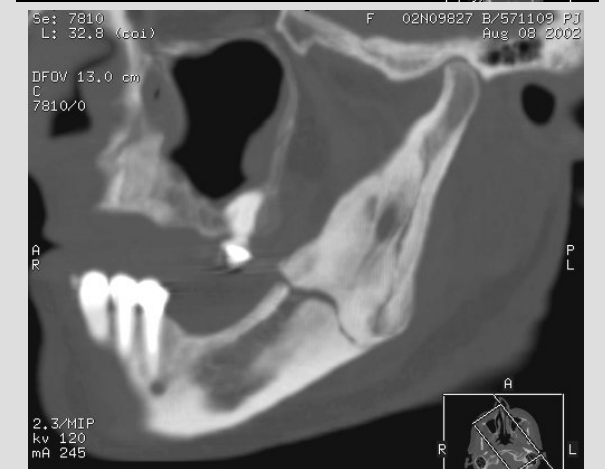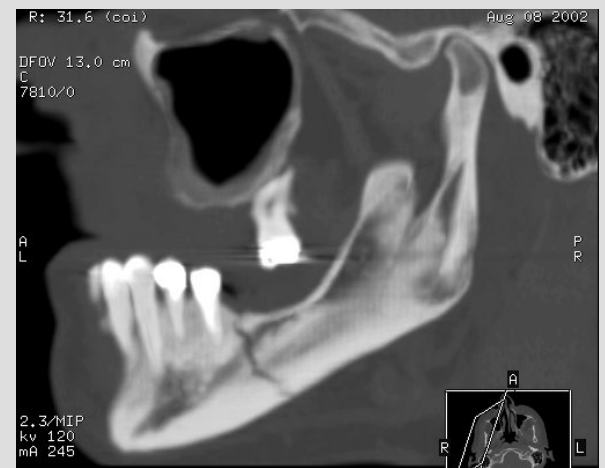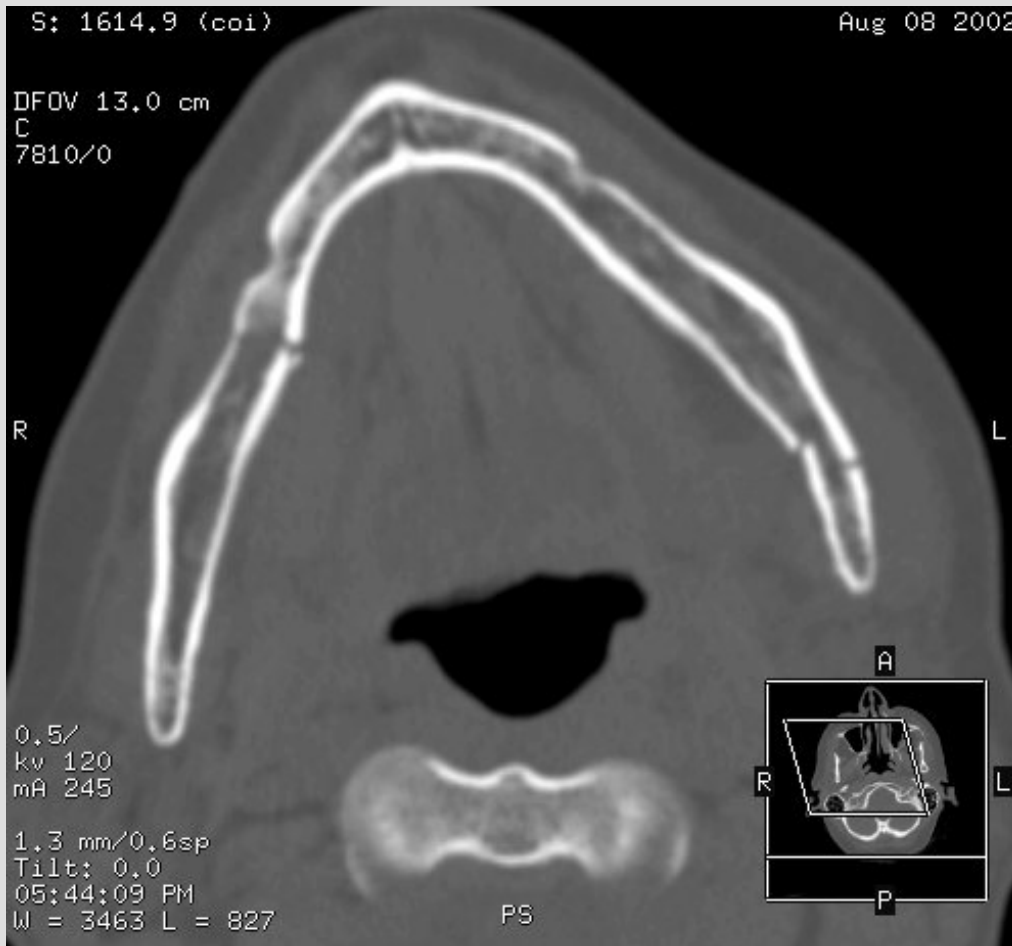


fractures
intriquées avec
disjonctions suturaires

Fractures mandibulaires

- **Seconde fracture après les OPNs**
- **‘Ring’ osseux fermé**
 - *double fracture*
- 2 ‘classiques’
 - # bi-condylienne
 - # parasymphysaire
 - + contro-latérale branche montante


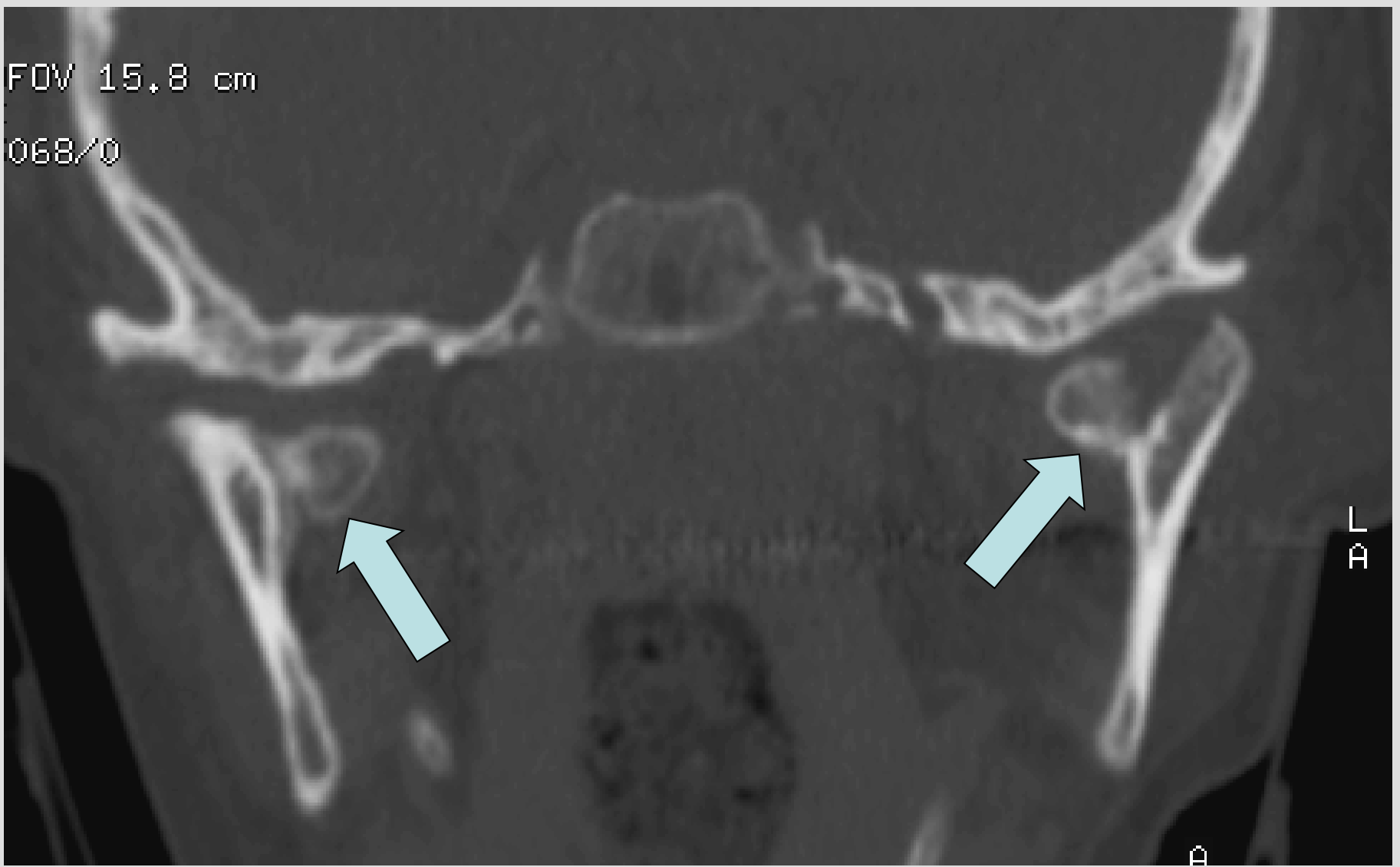




bilatéralité

FOV 15.8 cm


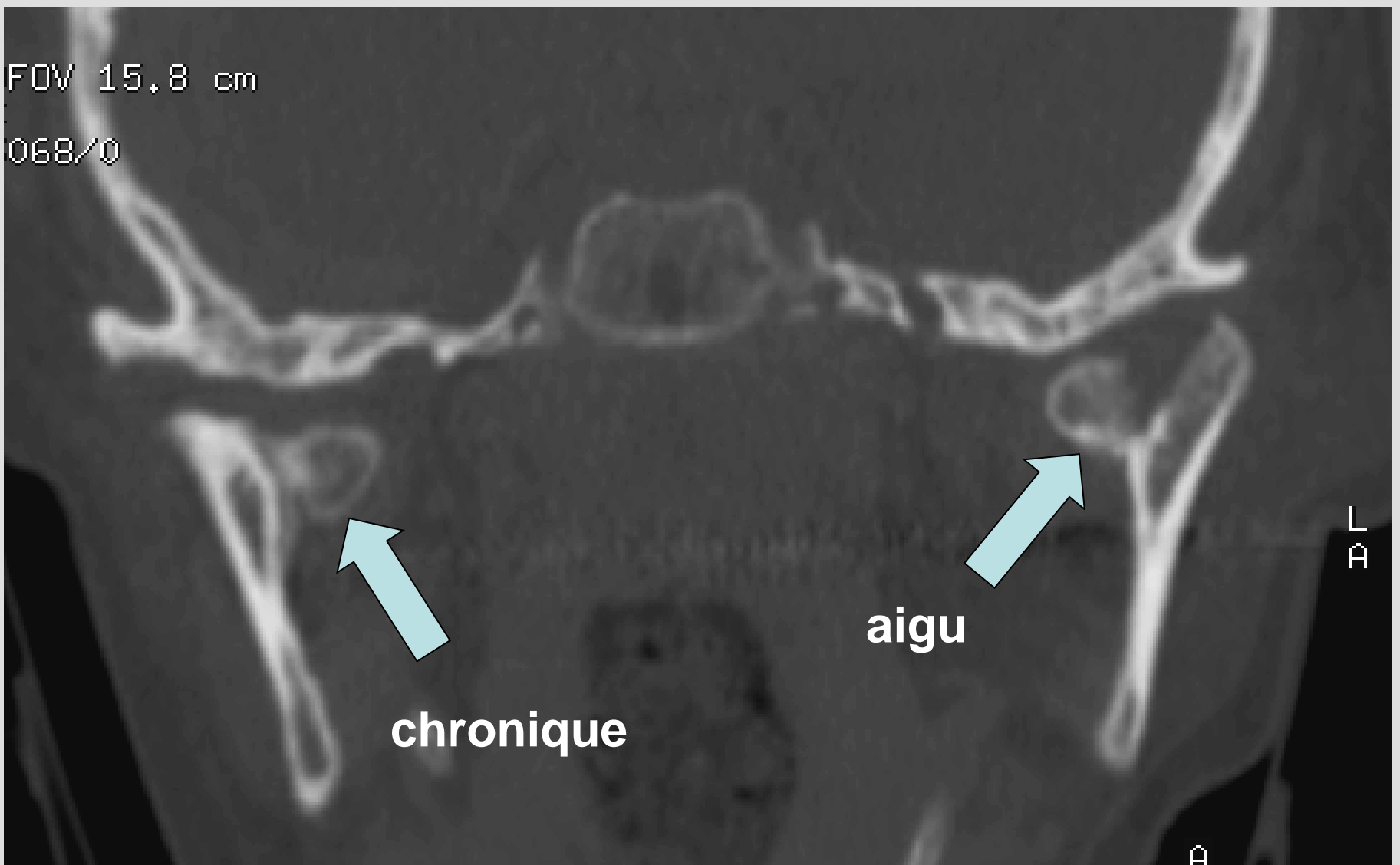
068/0



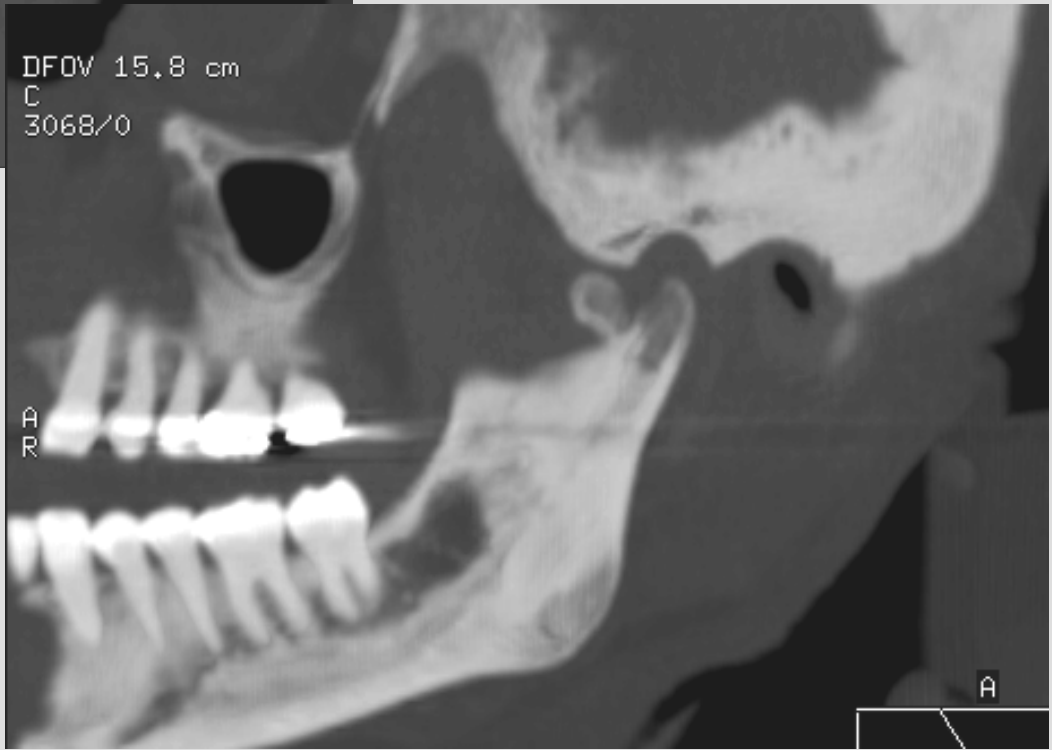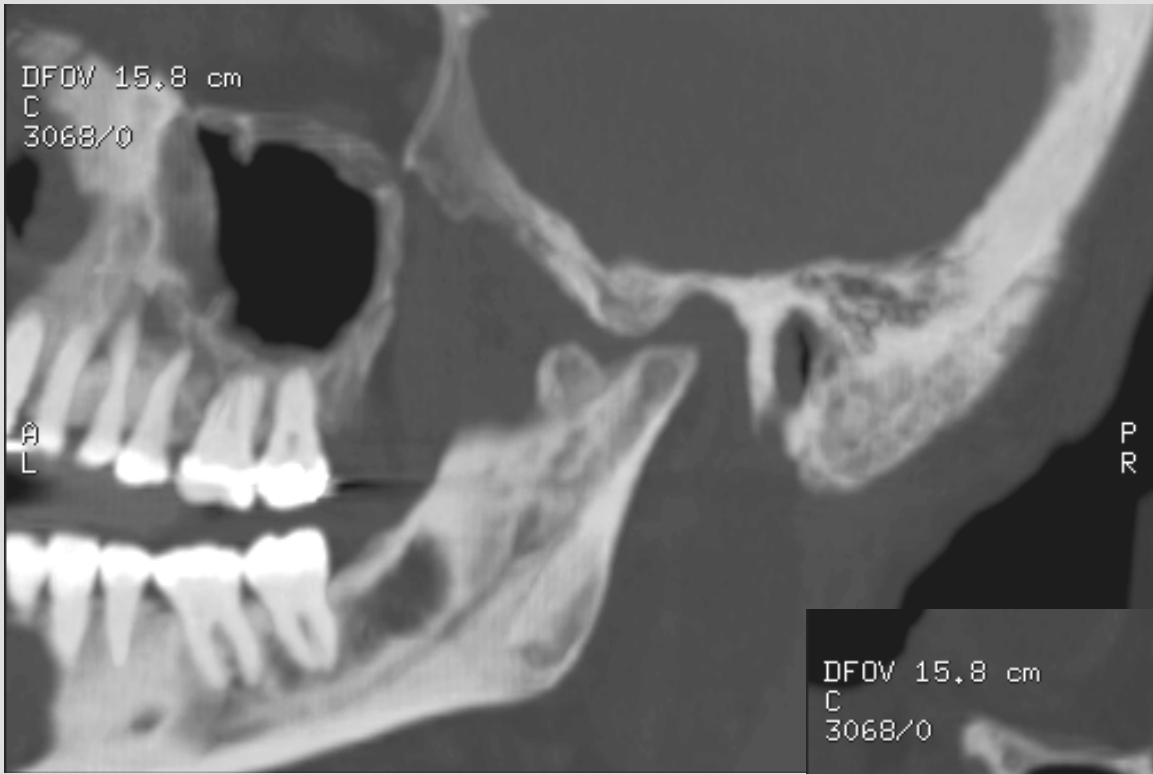bilatéralité

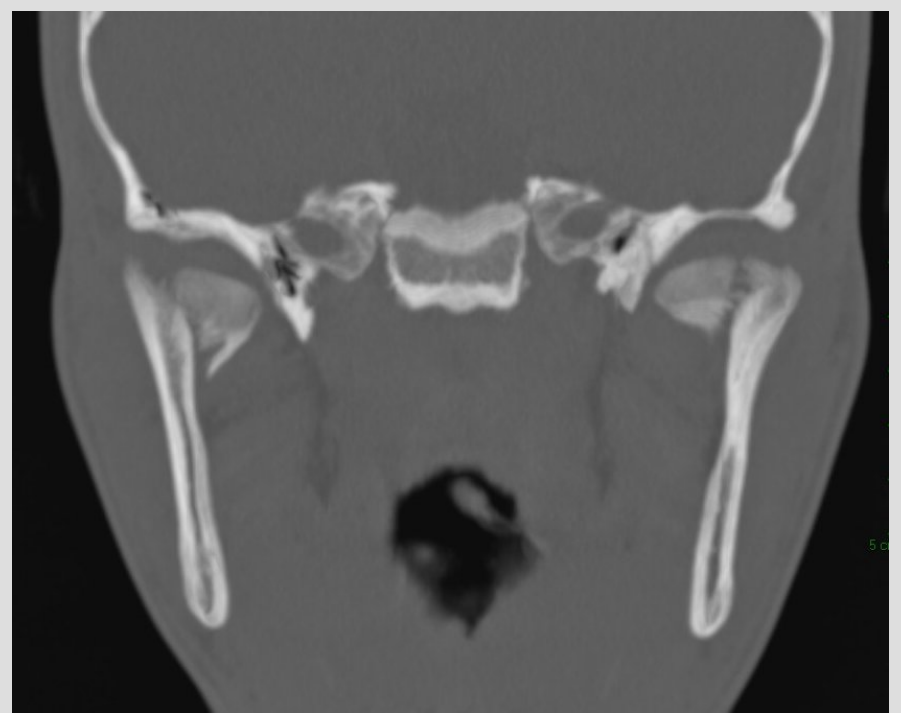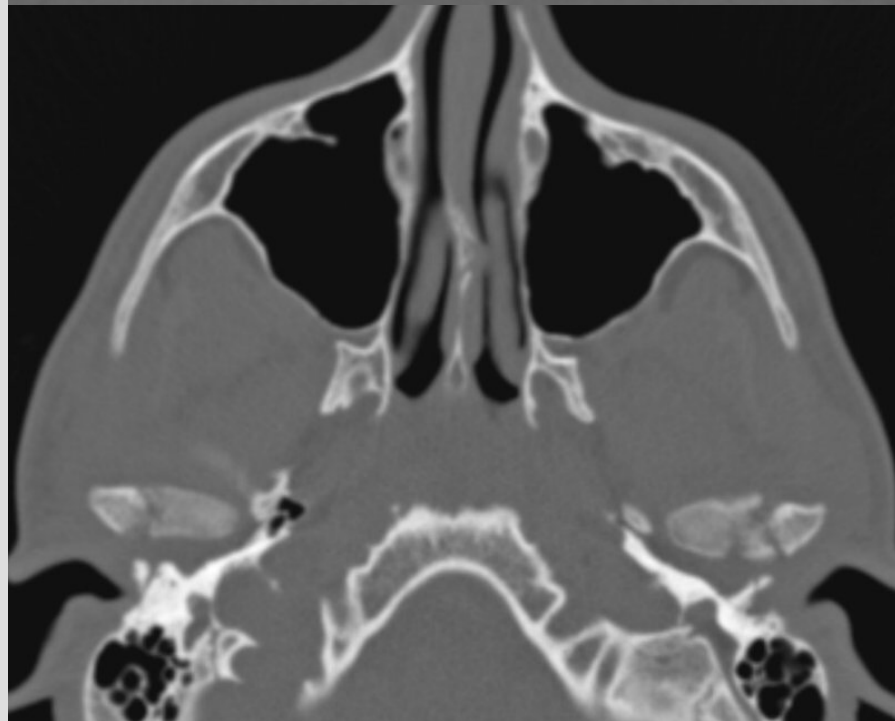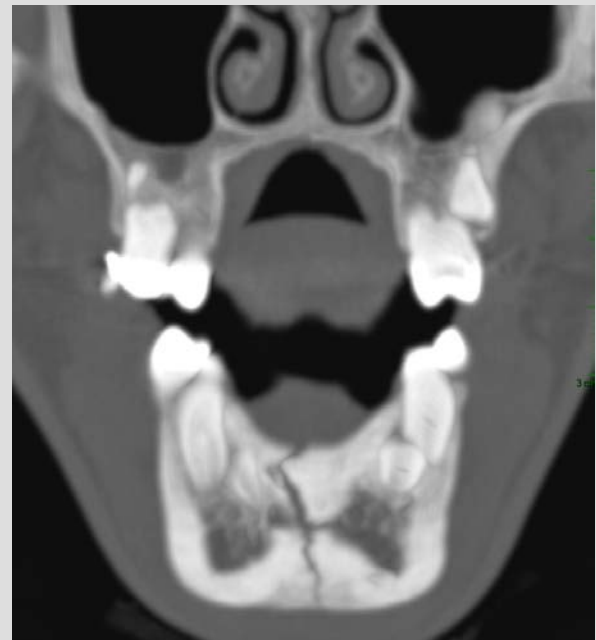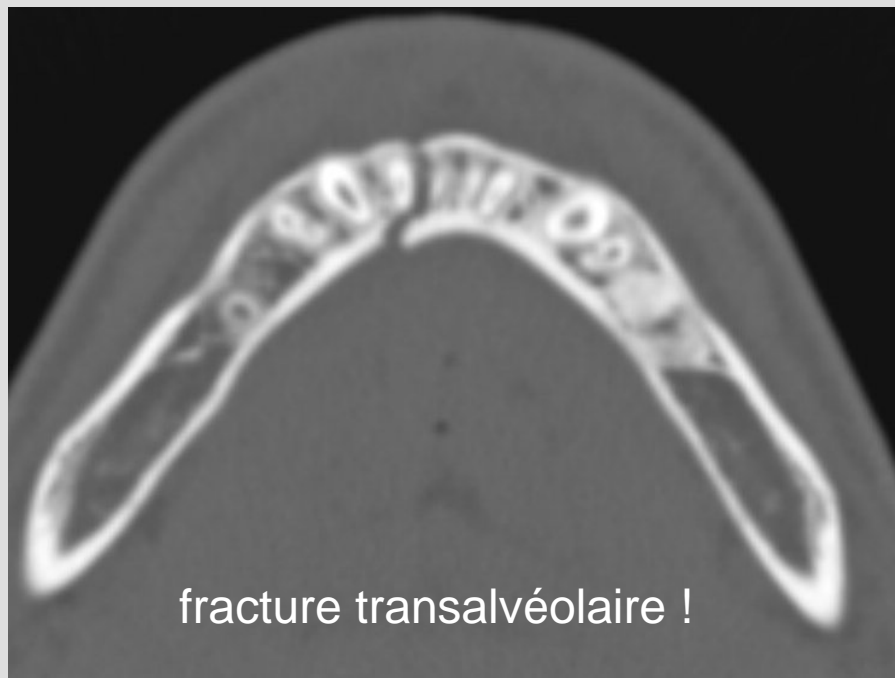
FOV 15.8 cm

068/0



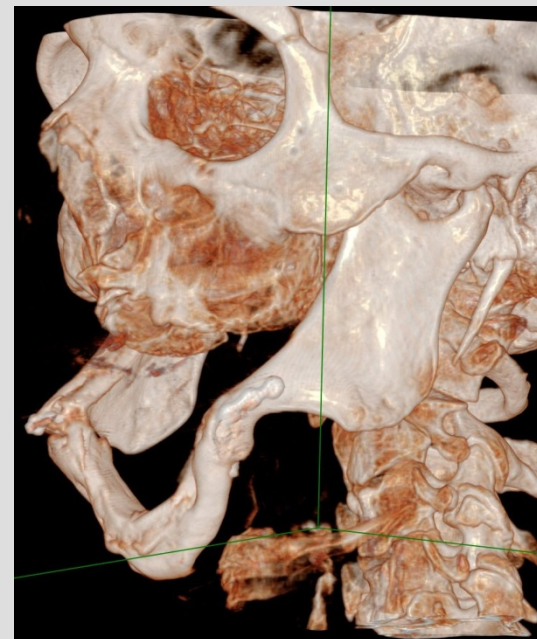
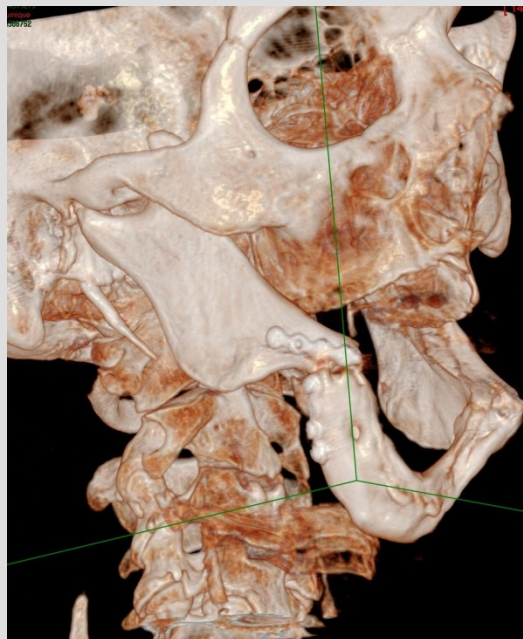
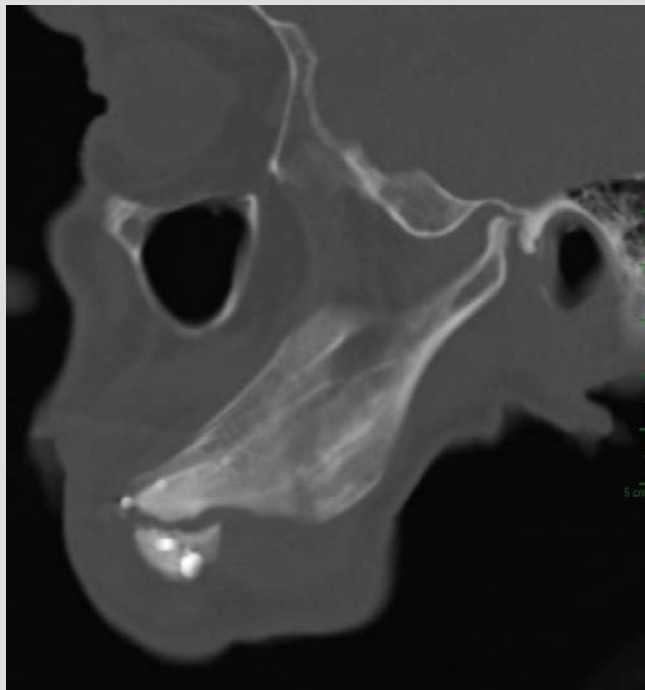
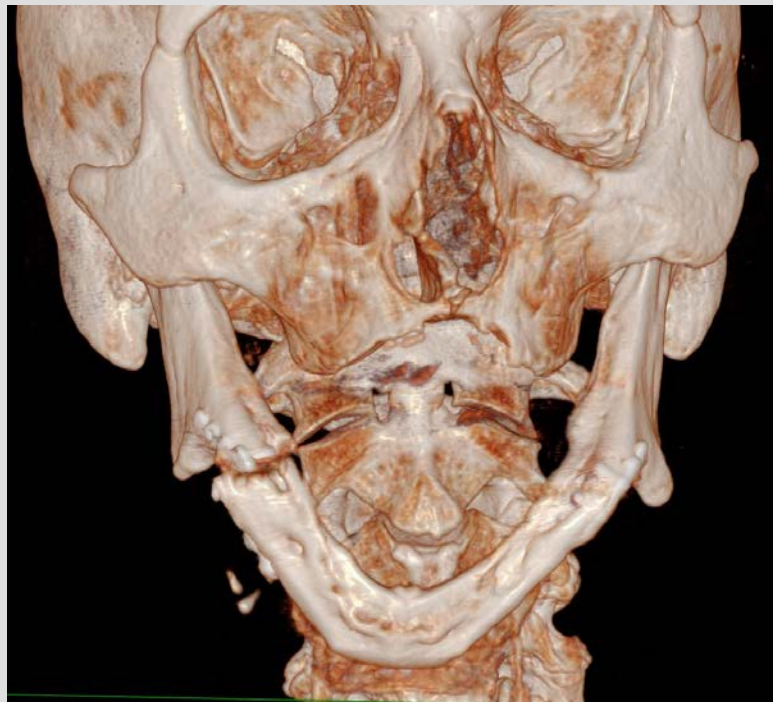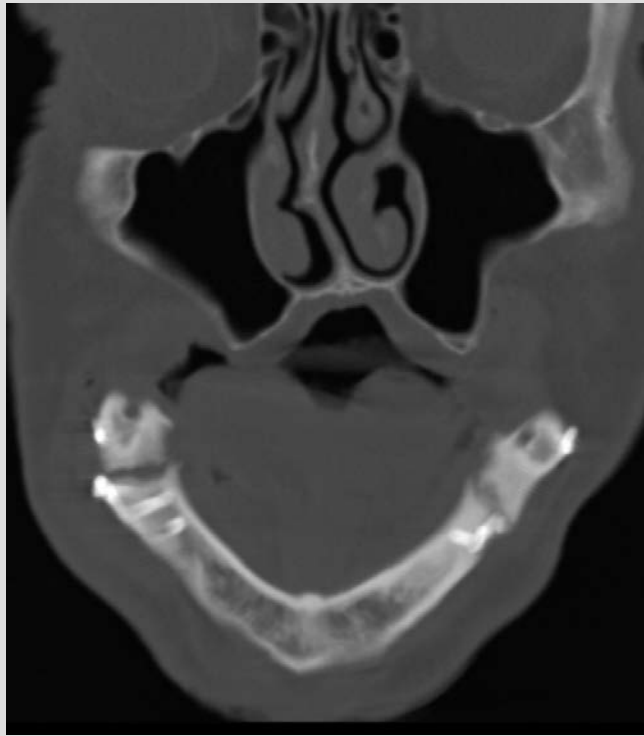
bilatéralité



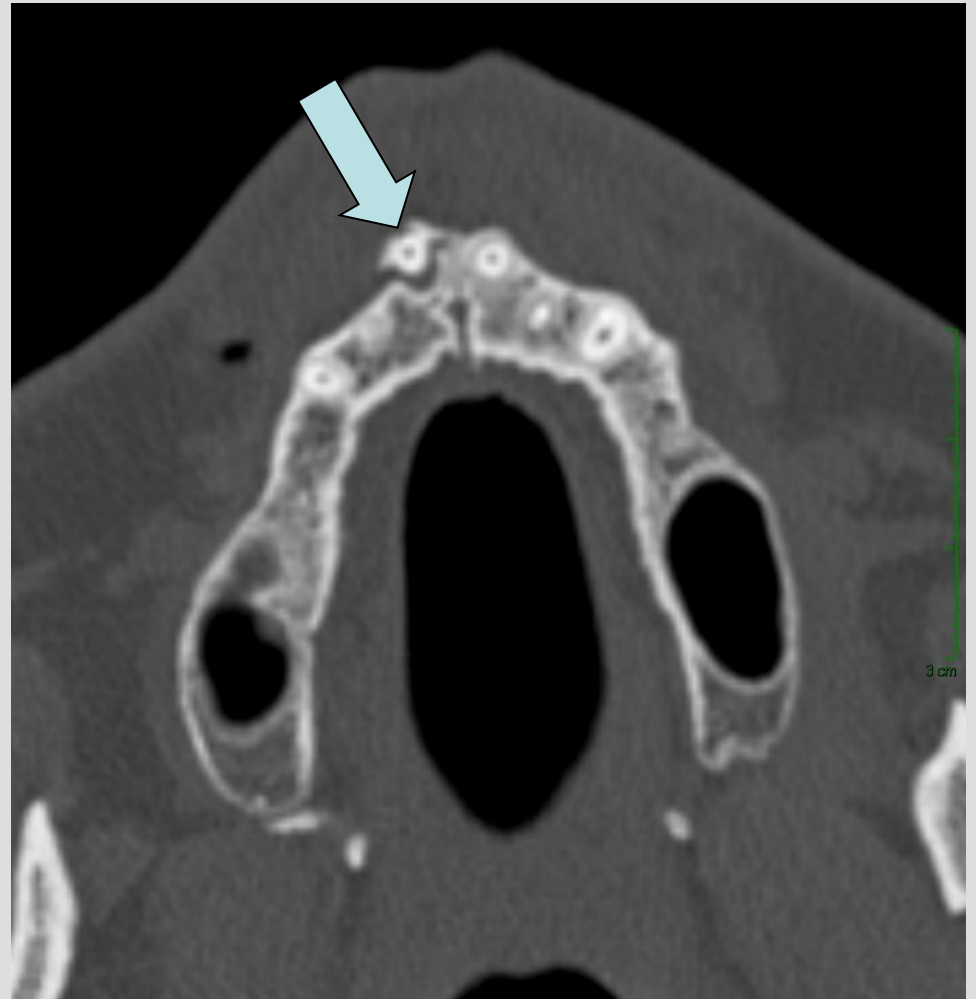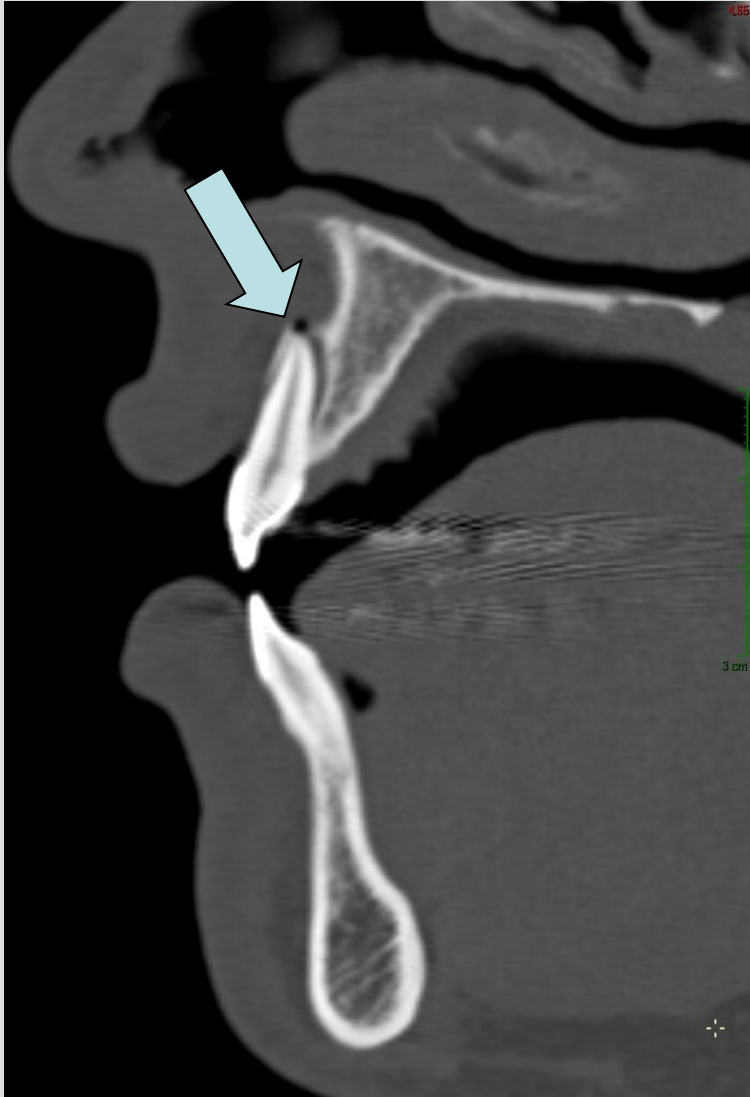


Fractures mandibulaires

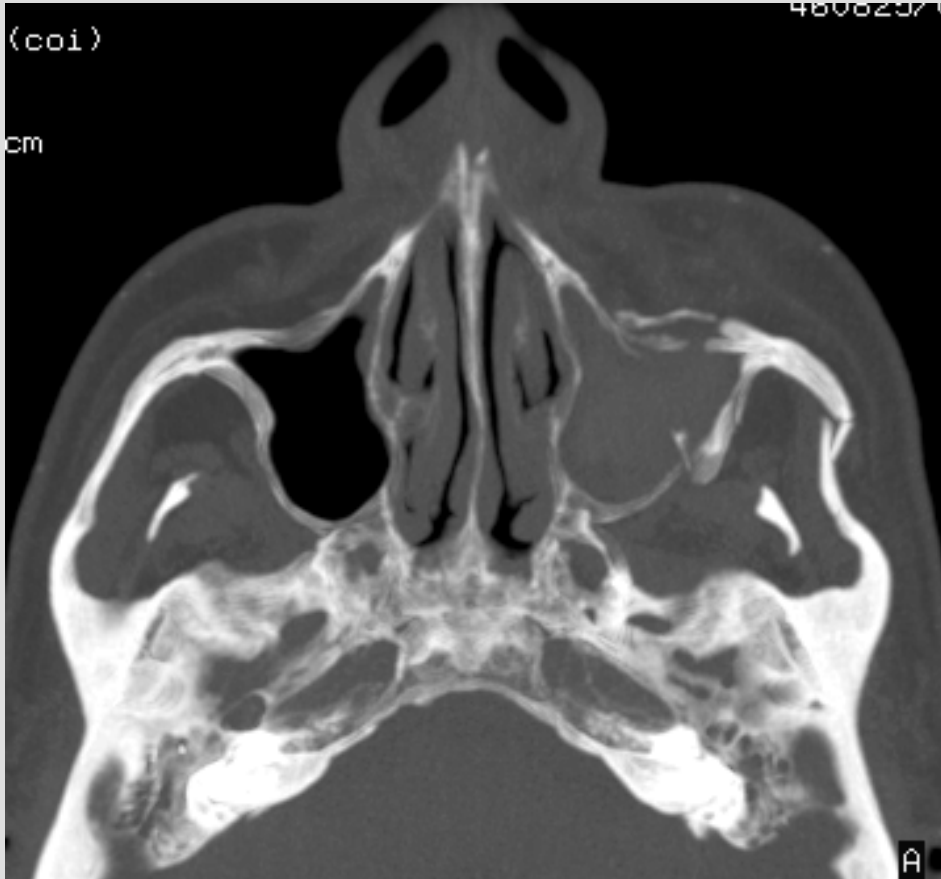- 3 complications
- ostéomyélite
- pseudarthrose → impotence fonctionnelle
- consolidation en position inadéquate → impotence fonctionnelle



Fractures alvéolaires dentaires



L'arcade zygomatic



- isolée vs combinée
trépied malaire
- simple vs comminutive
- Impact
 - Esthétique
 - Fonctionnel: insertion massétérine

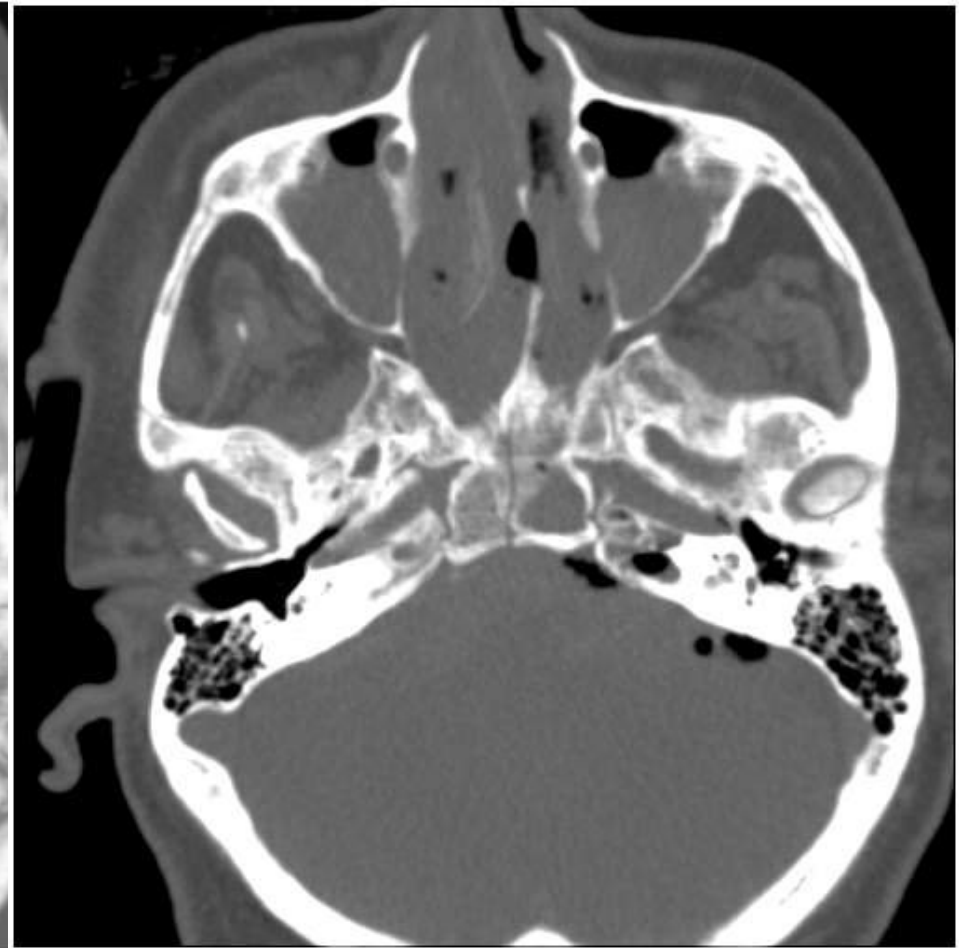
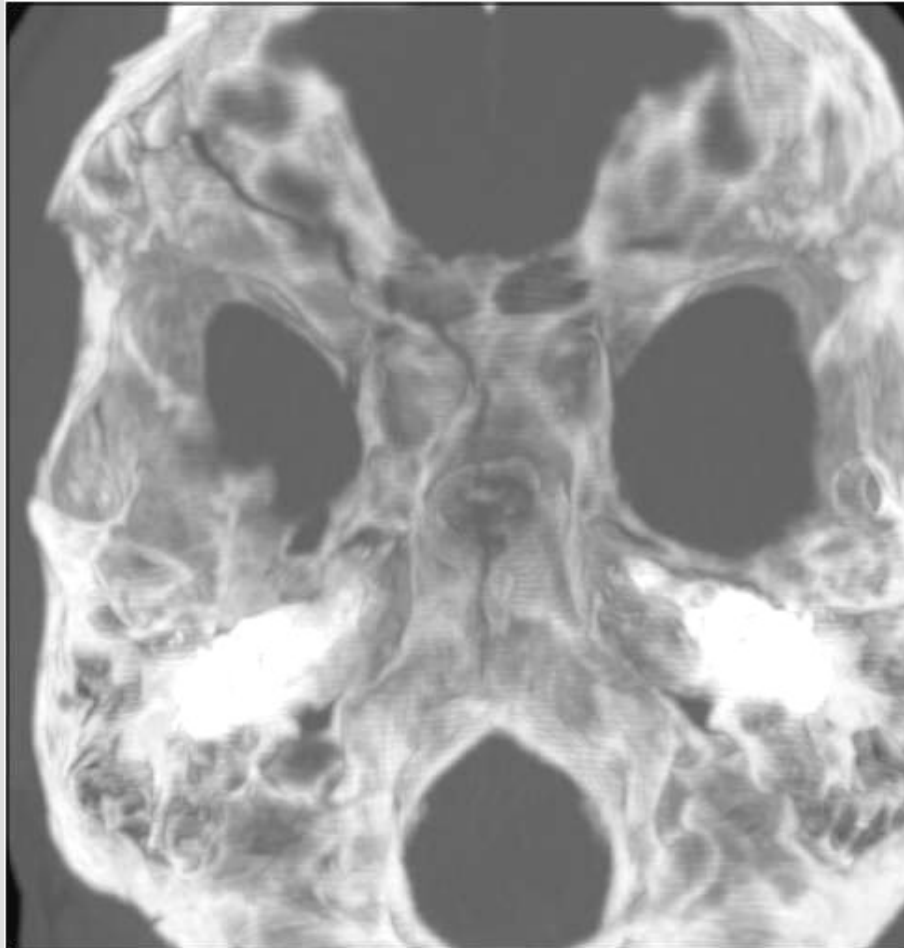
Sphénoïde

Trauma **très violent**

Souvent **non déplacées**

Génératrice de **fistules de LCR**

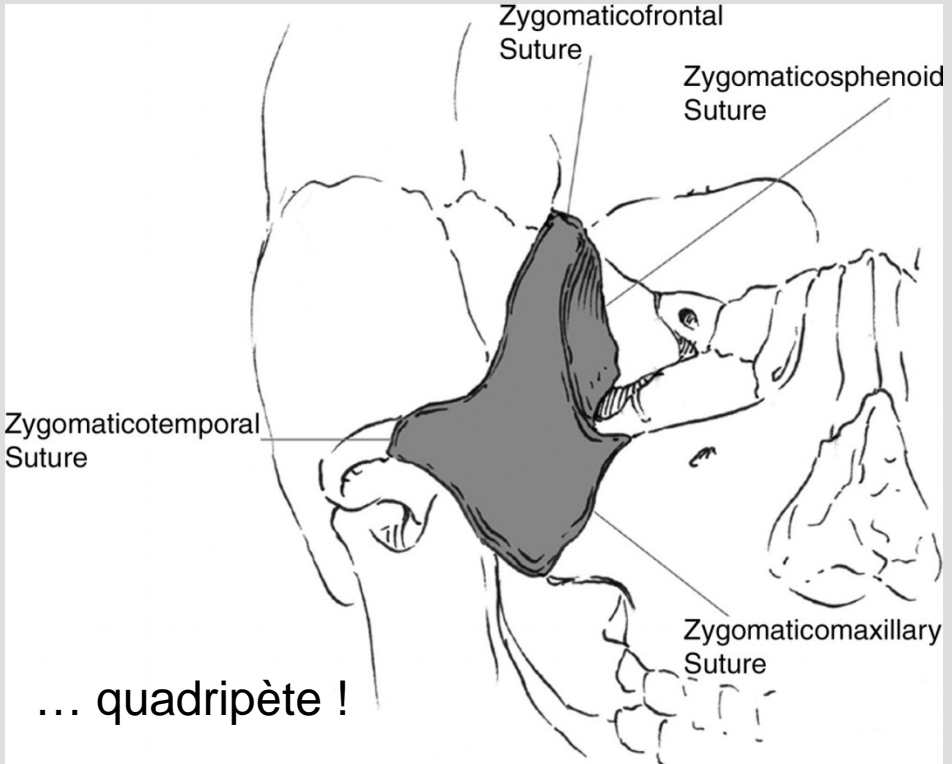
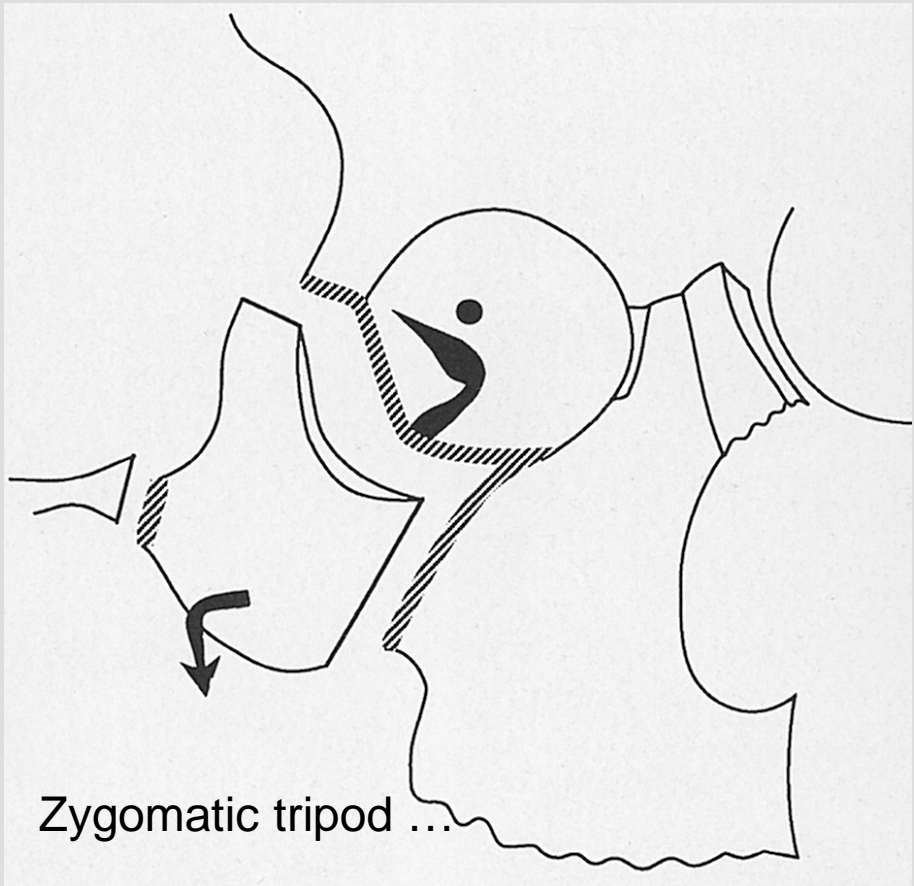
Génératrice de **complication vasculaire**
si paroi latérale atteinte



Reconnaissance des entités multi-fracturaires

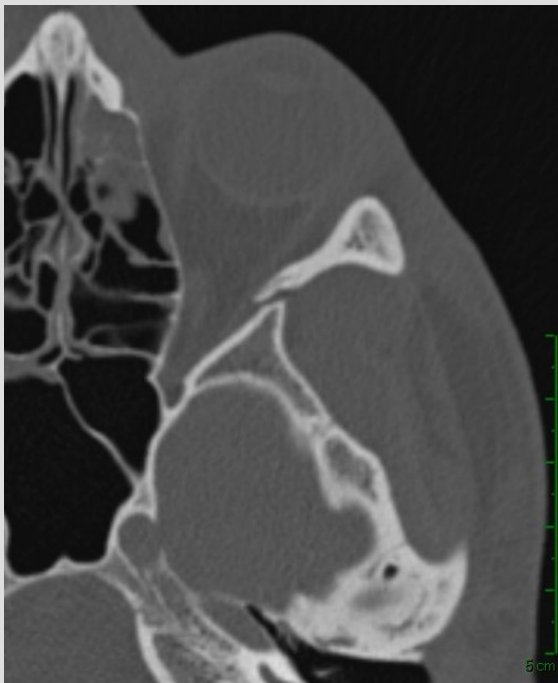
Unilatérale: « trépied » malaire

Bilatérale: fractures de le Fort

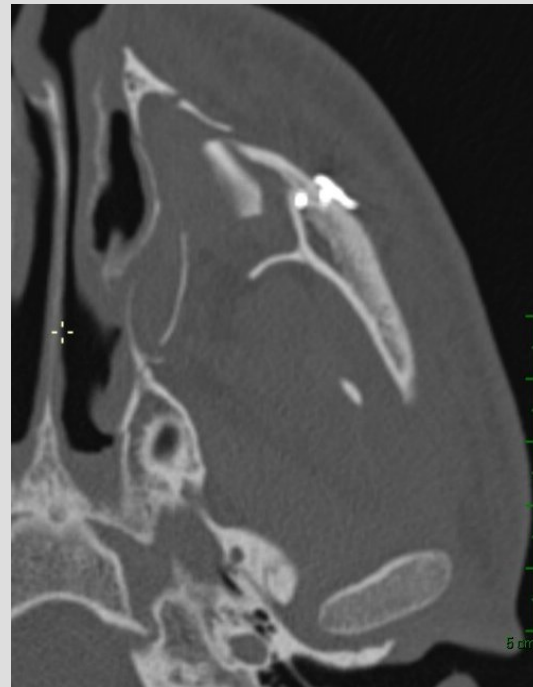


RadioGraphics

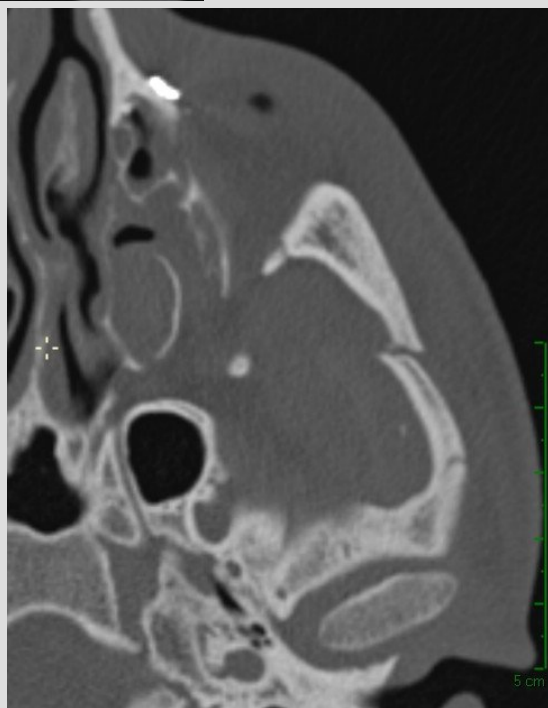
Hopper R A et al. Radiographics 2006;26:783-793



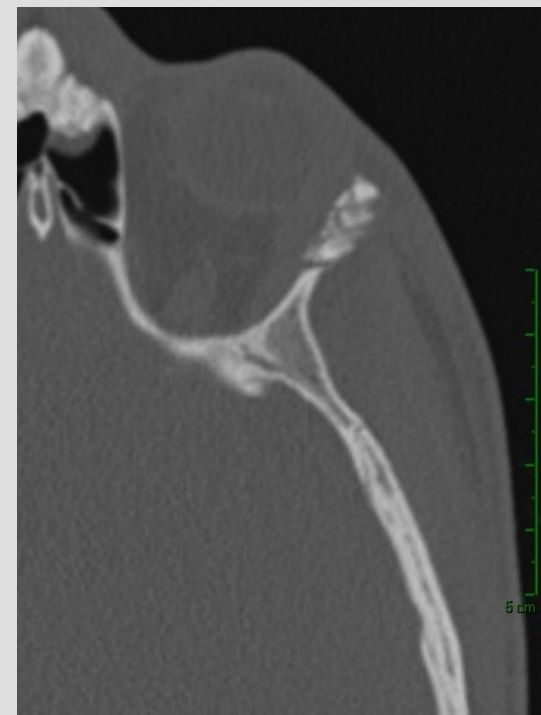1
Suture
sphéno-malaire



3
Arche
Maxillo-malaire

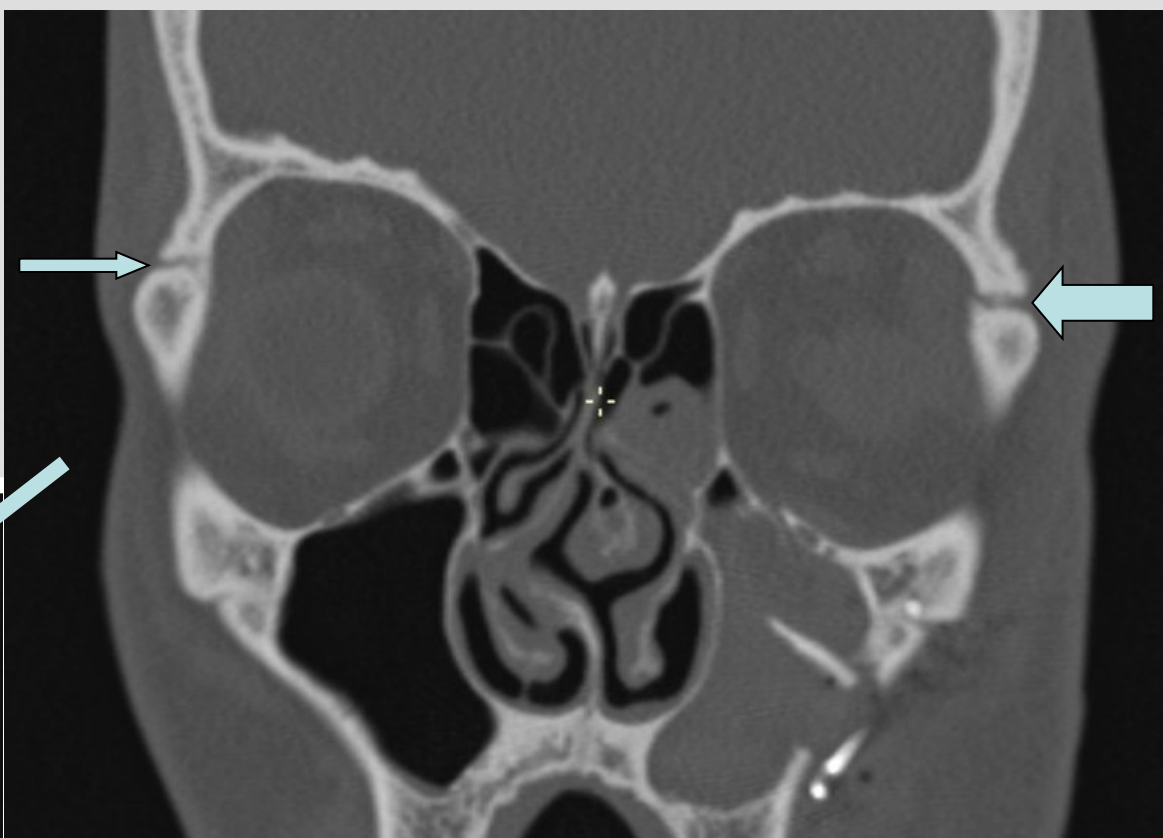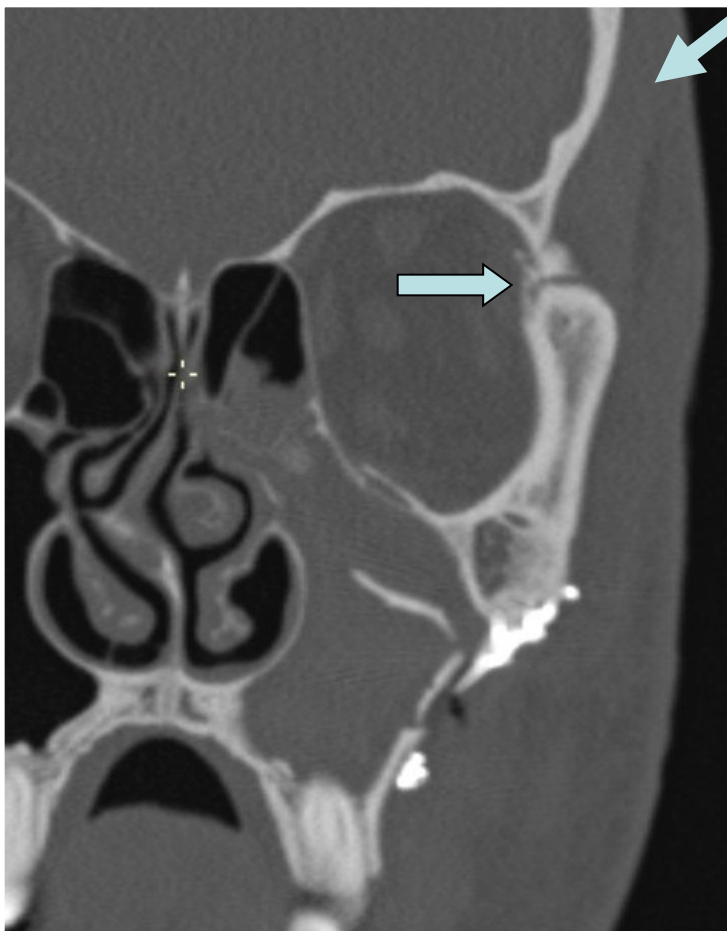


2
Arcade
zygomatique



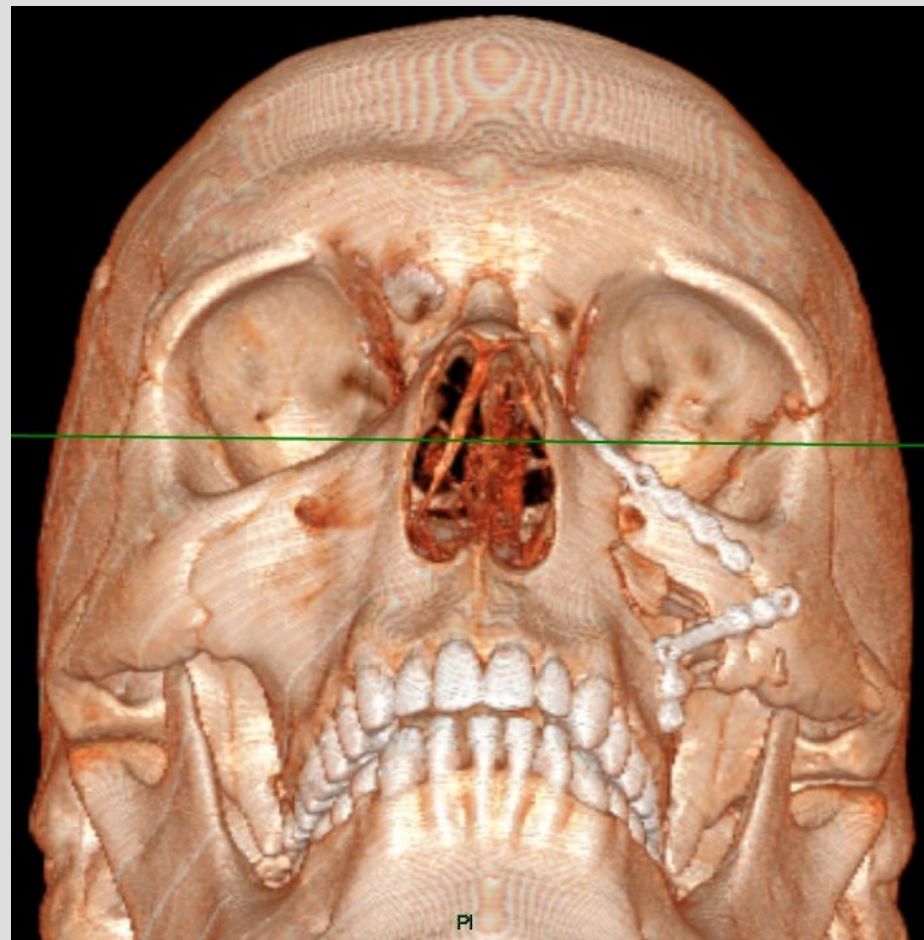
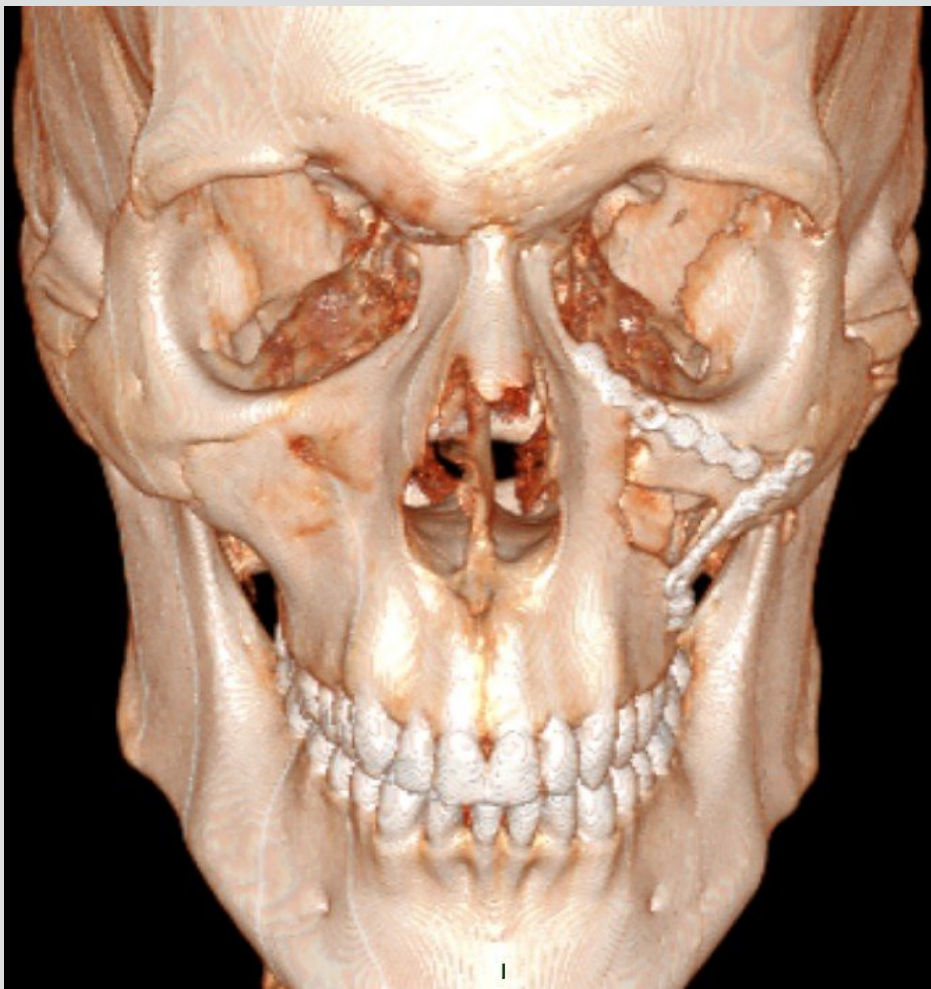4
Suture
fronto-malaire

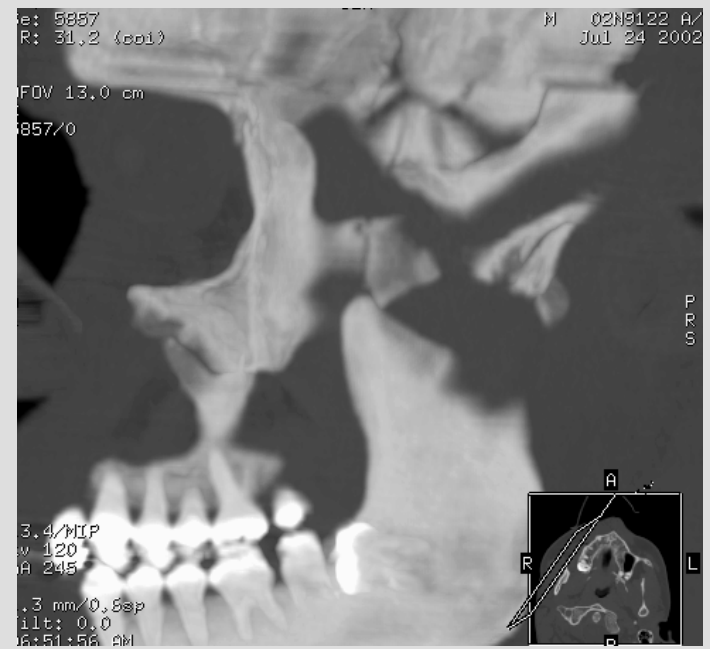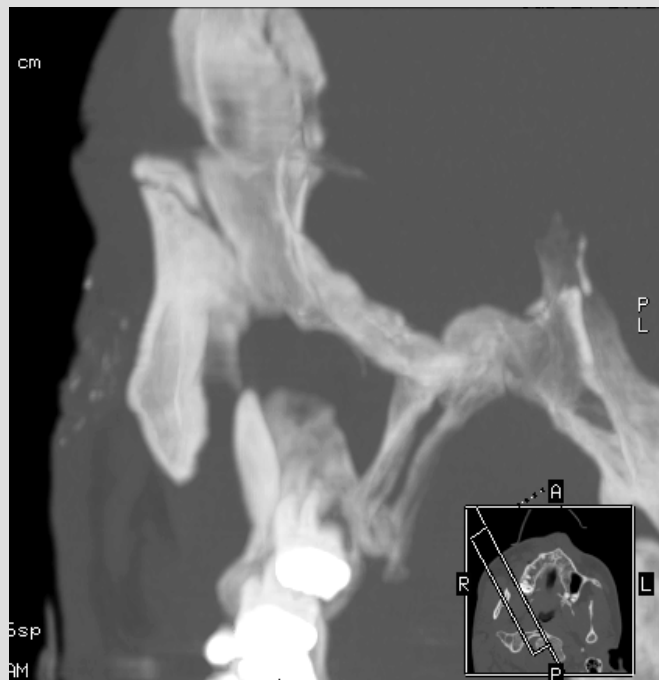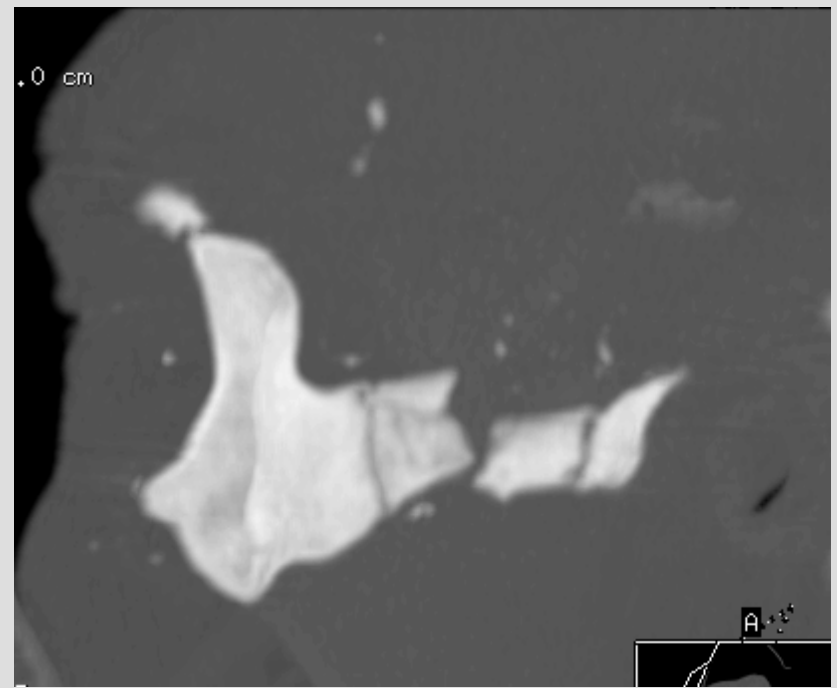
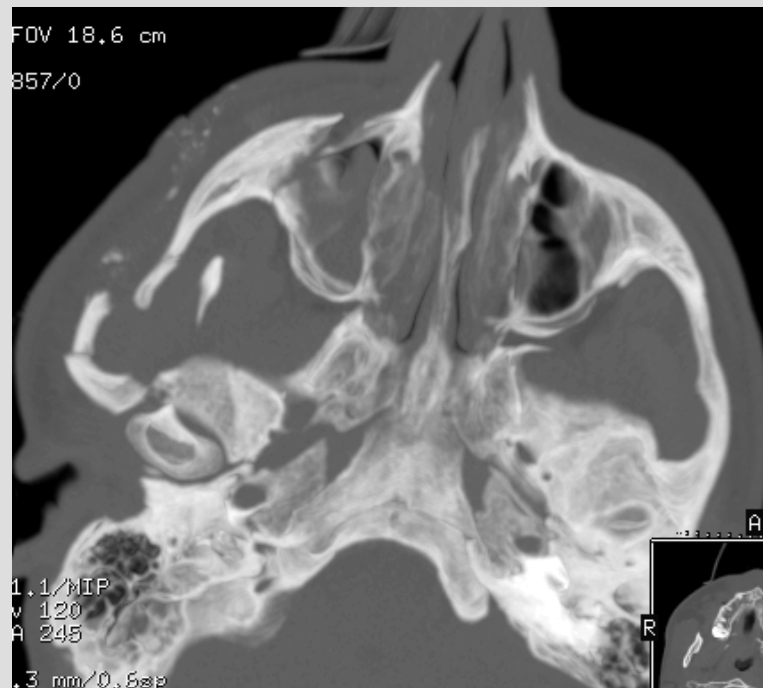**Fracture
suturale**

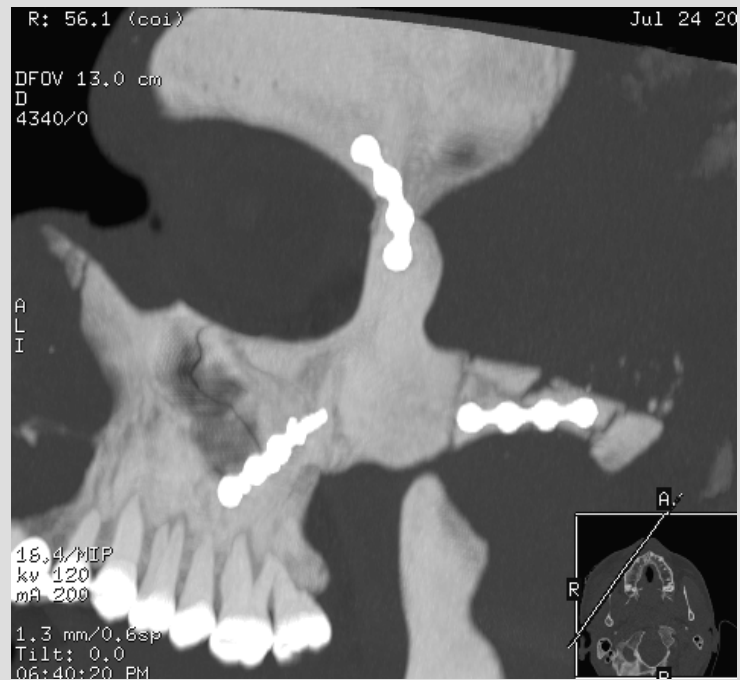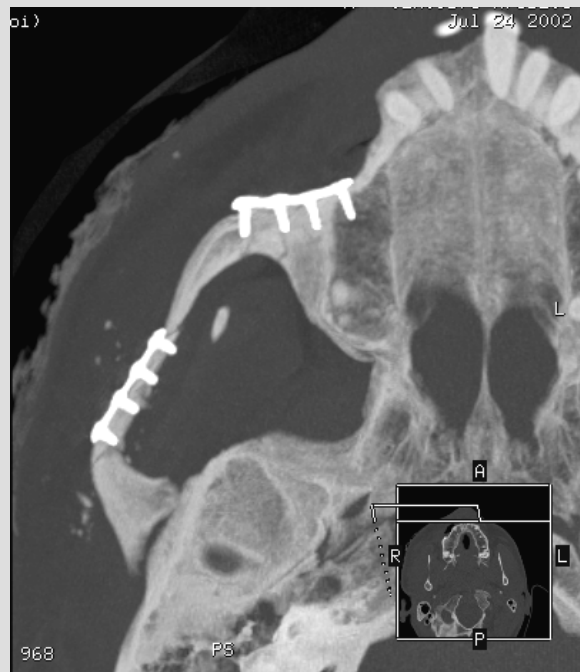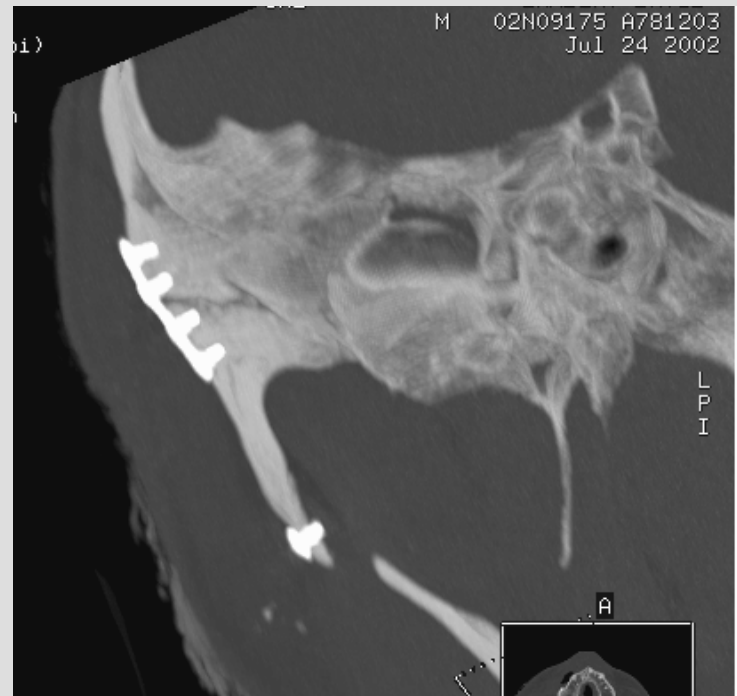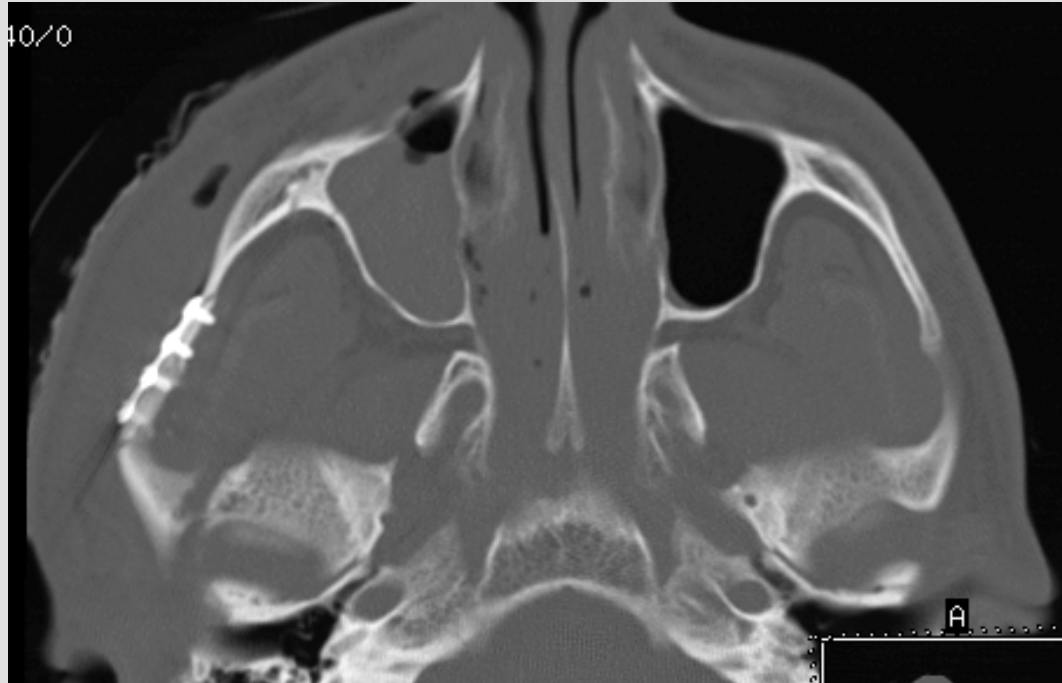


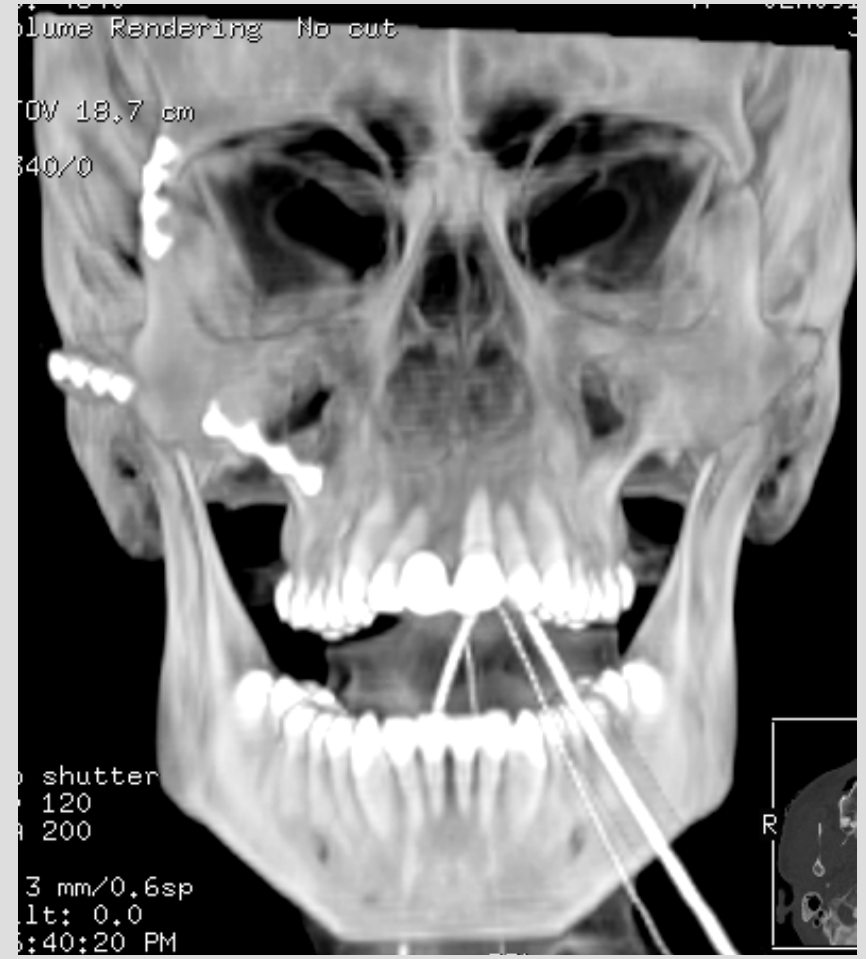
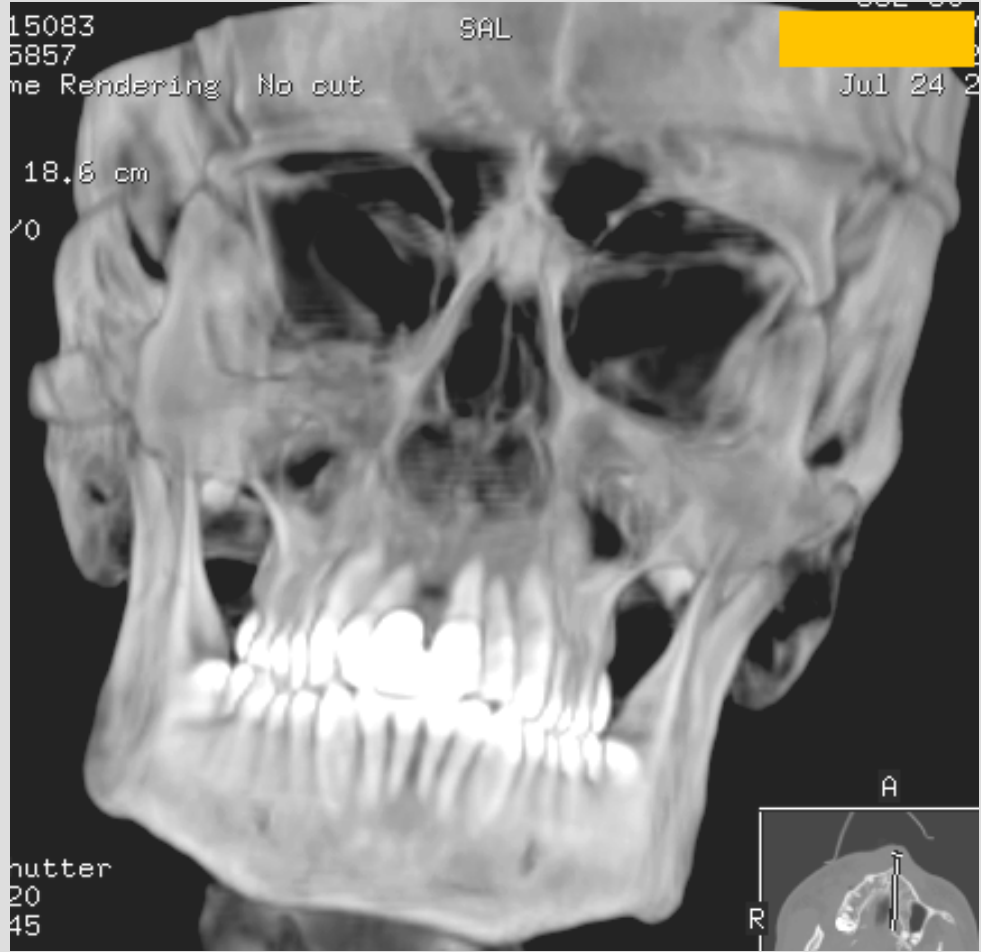
**Disjonction suturale
= baïllement**

Instabilité clinique









Fractures de Le Fort

Synonymes

Disjonctions crânio-faciales

Fractures transfaciales bilatérales

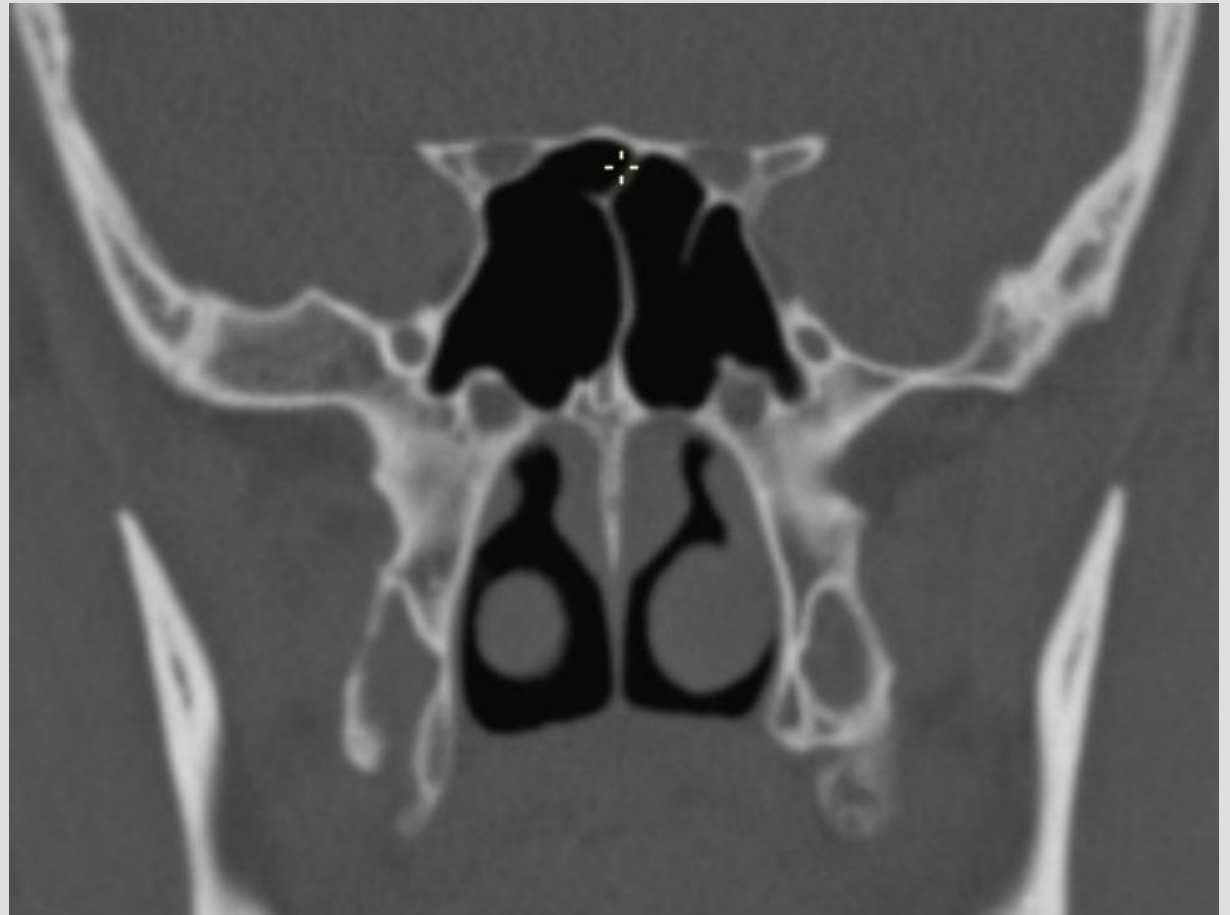

= séparation entre

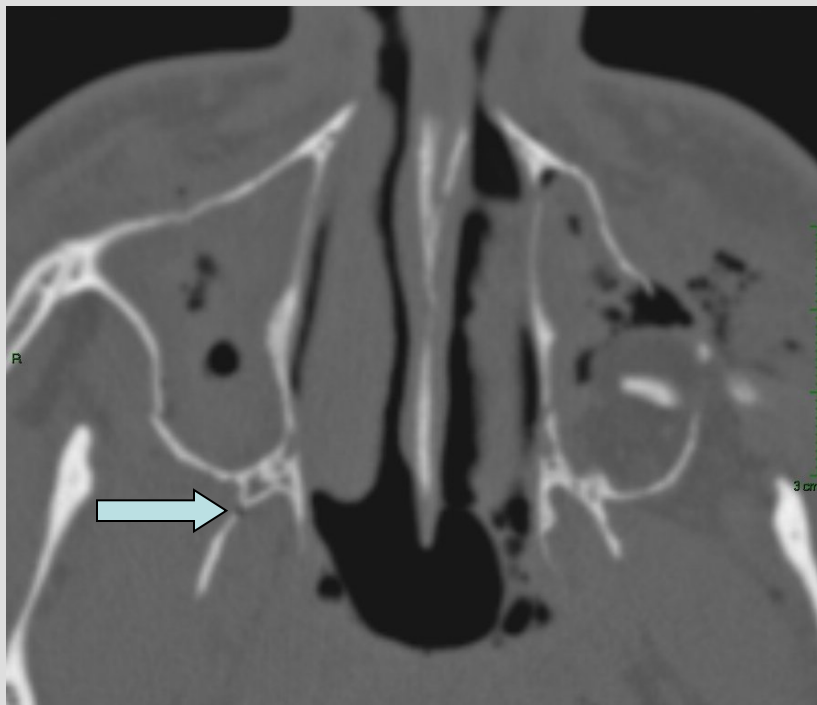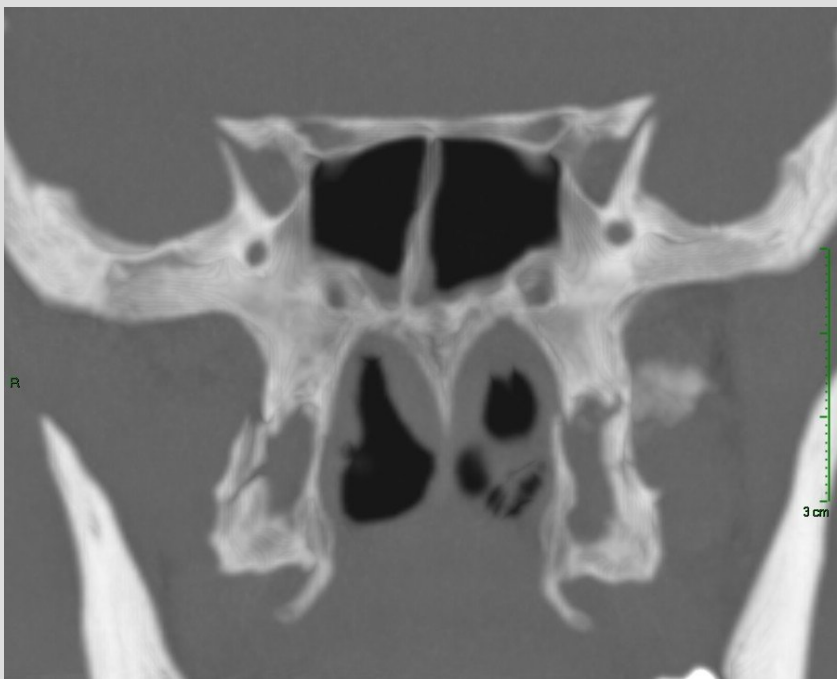
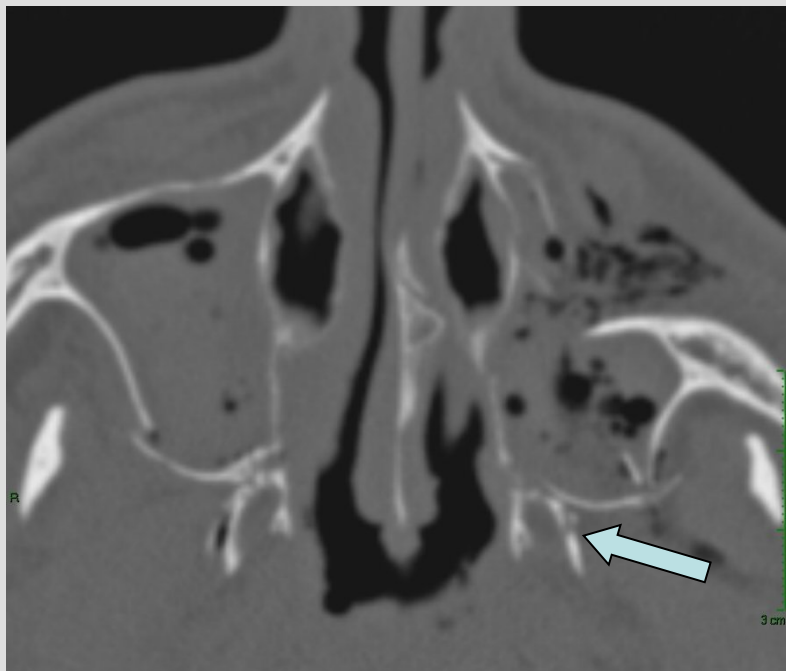
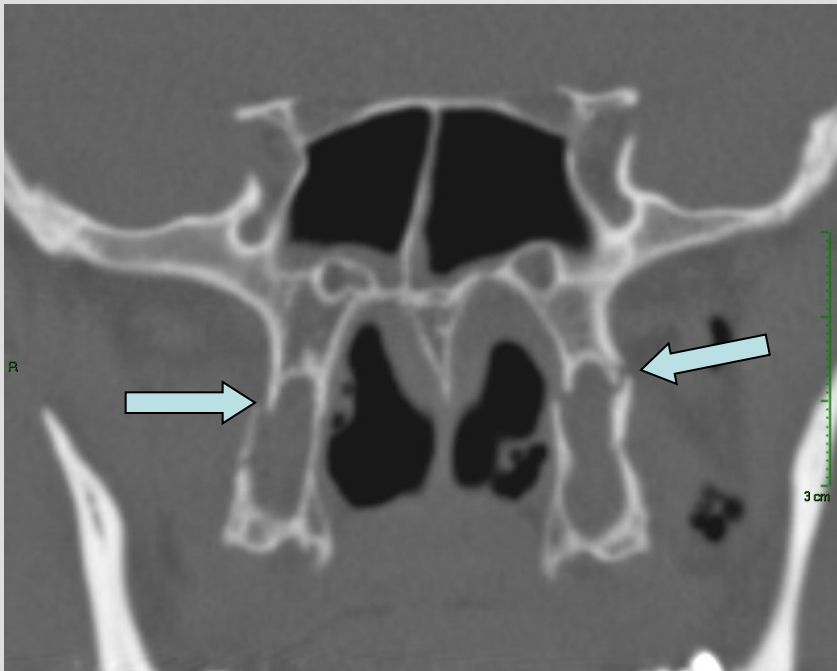
 tout (III) ou partie (I & II) du massif facial
 et

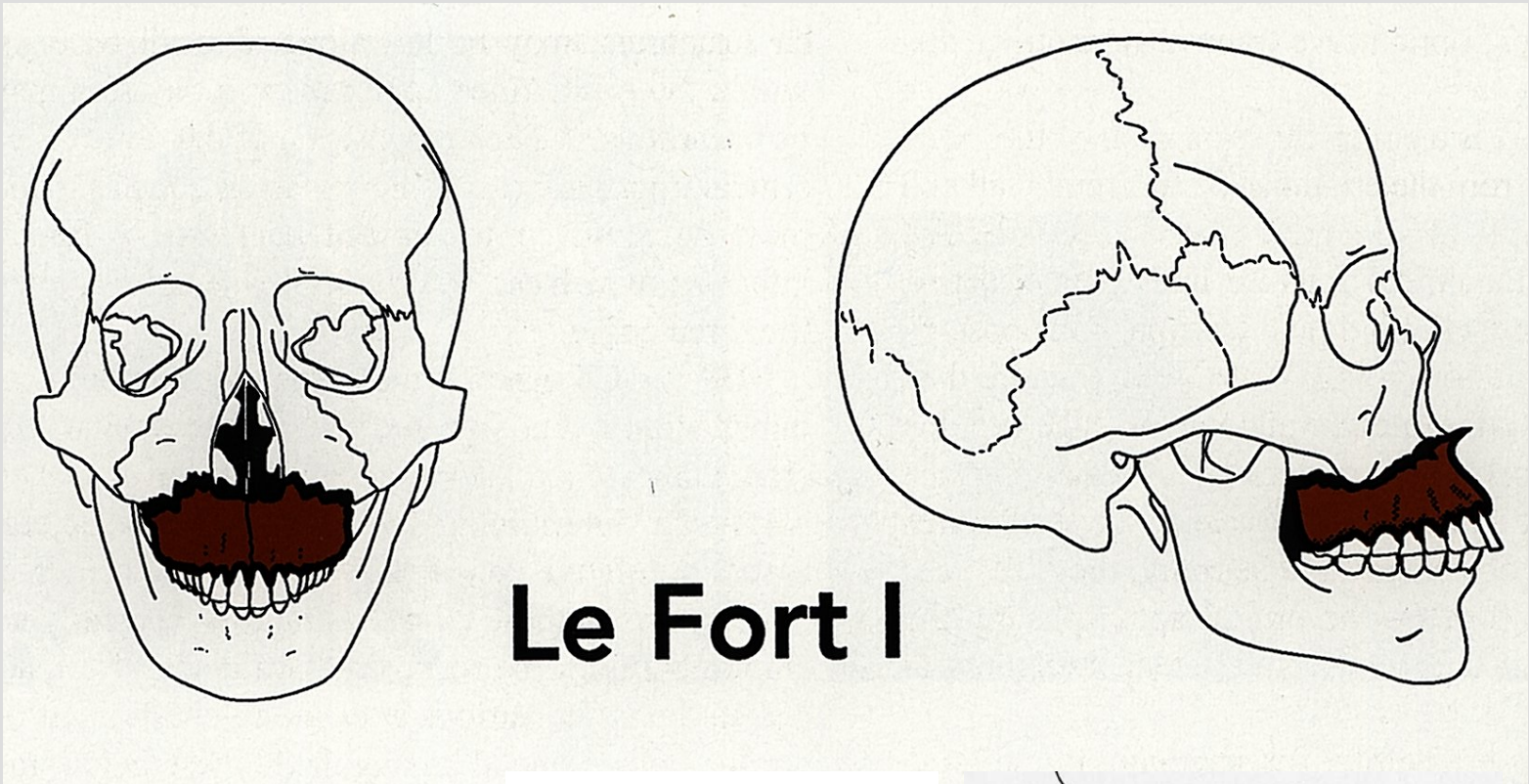
 le reste du squelette crânio-facial supérieur

URGENCE THERAPEUTIQUE de par leur INSTABILITE

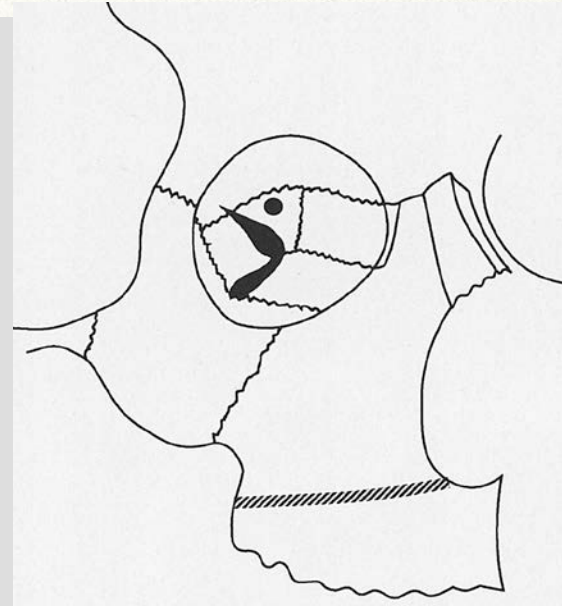
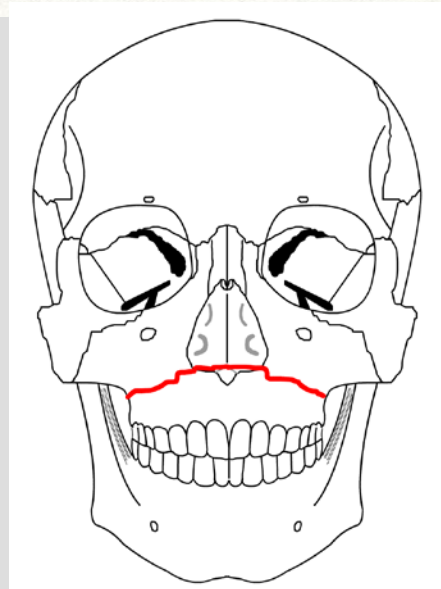
Fractures de Le Fort

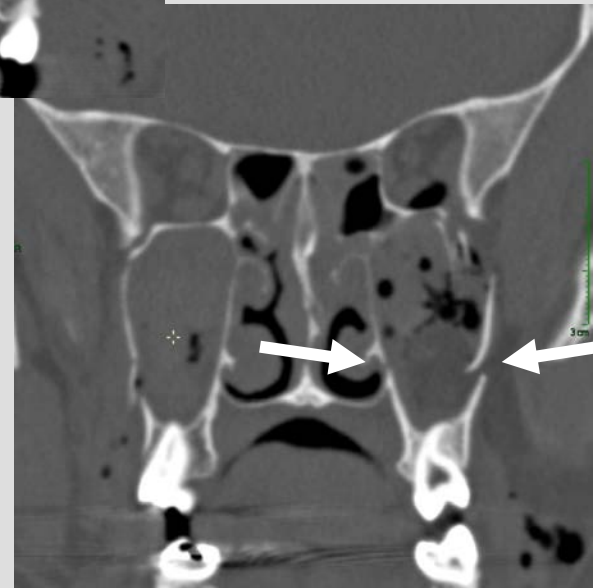
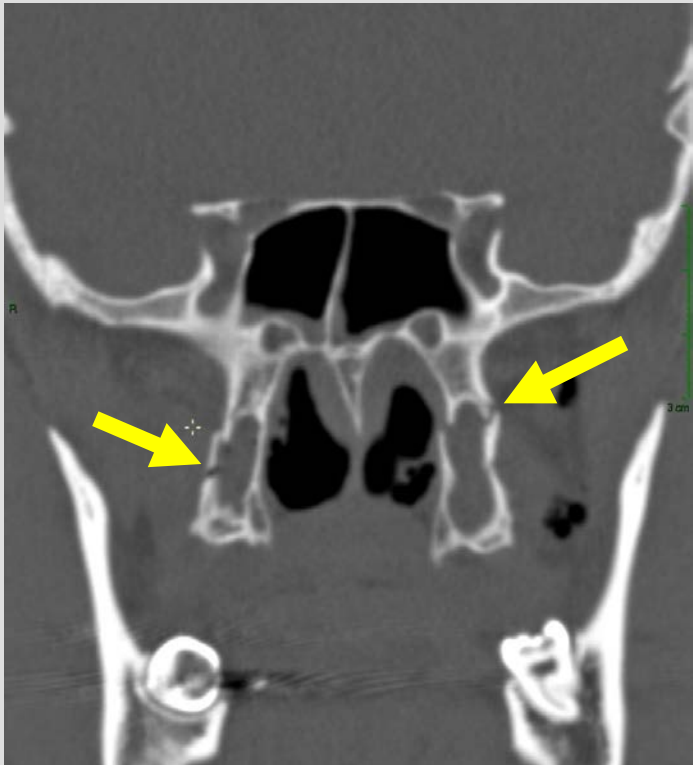
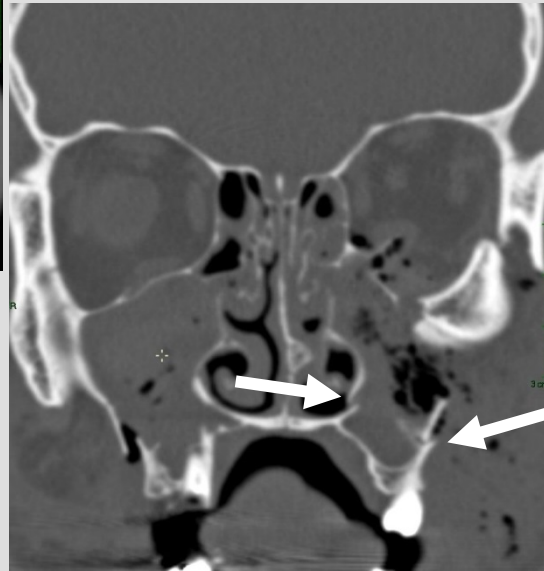
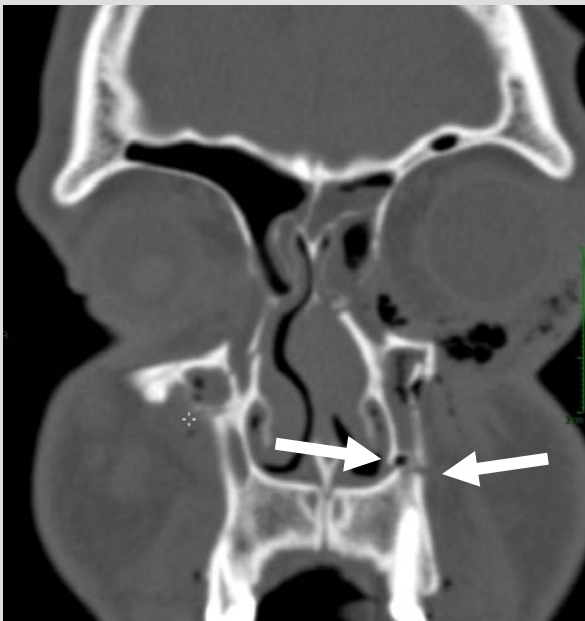


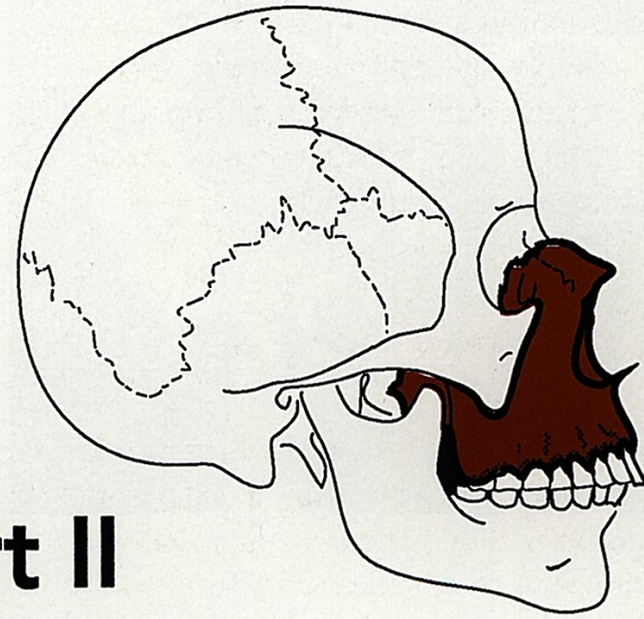
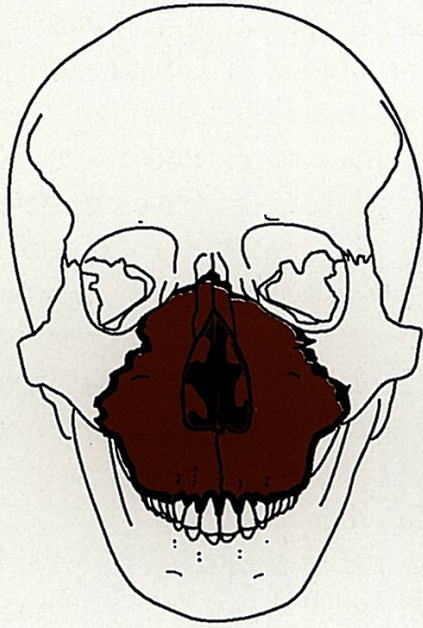




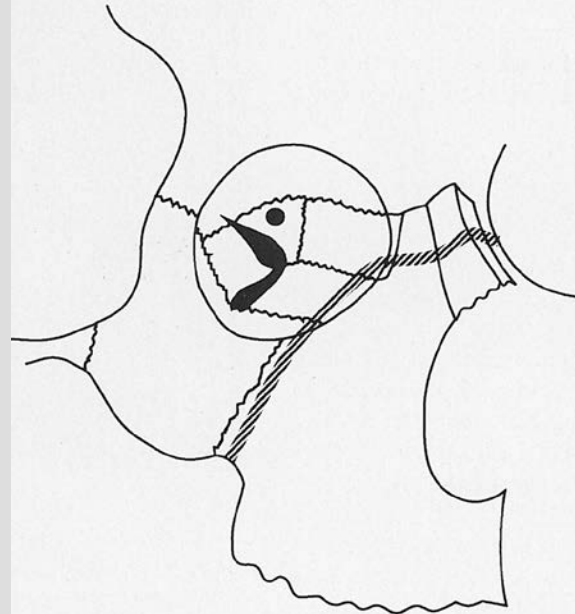
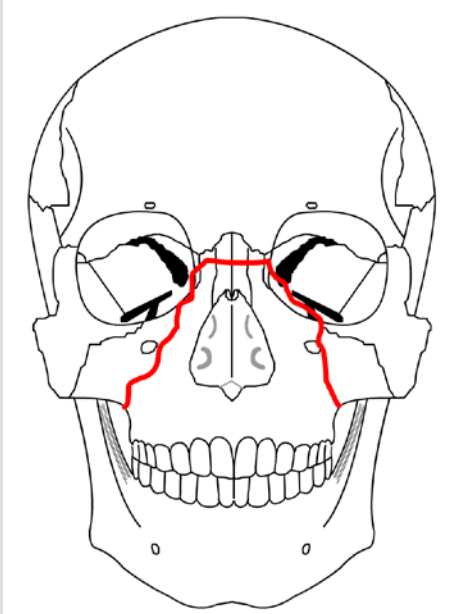
Fracture de Guérin
'Palais flottant'

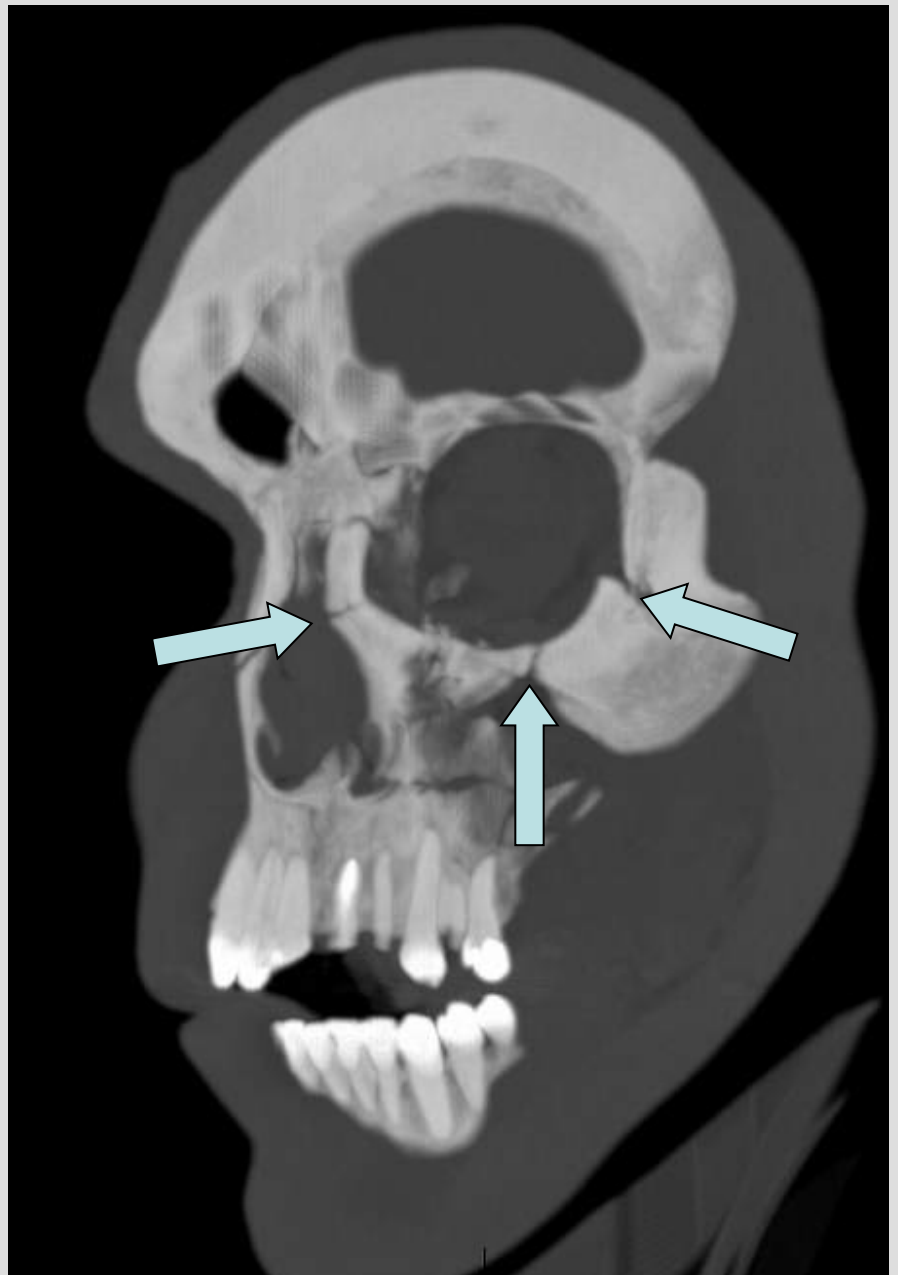
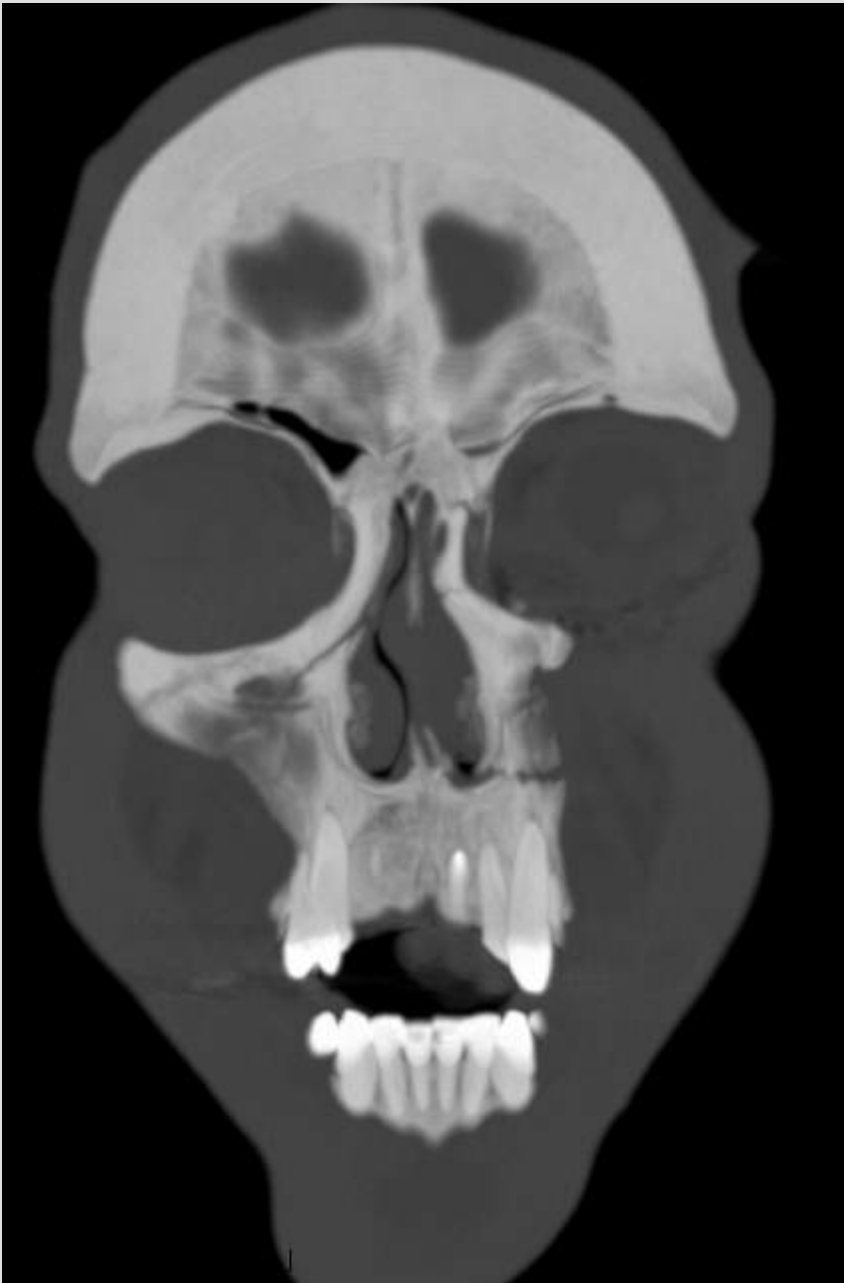

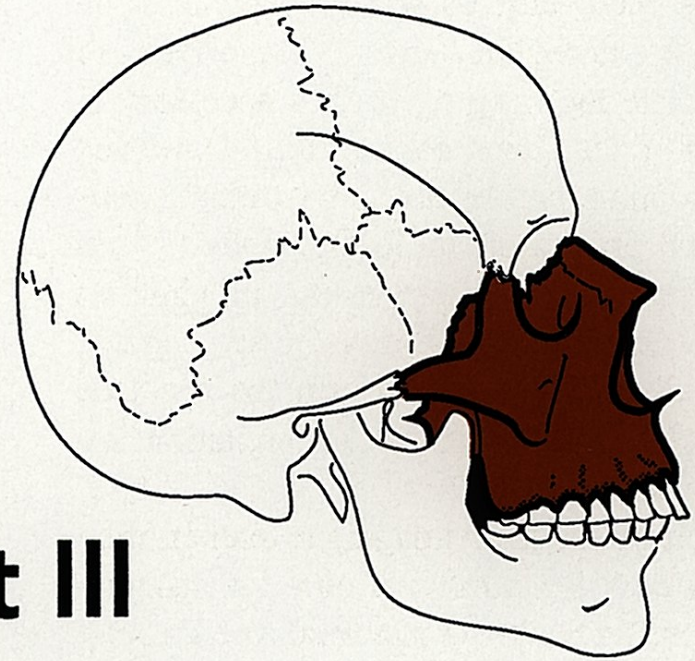
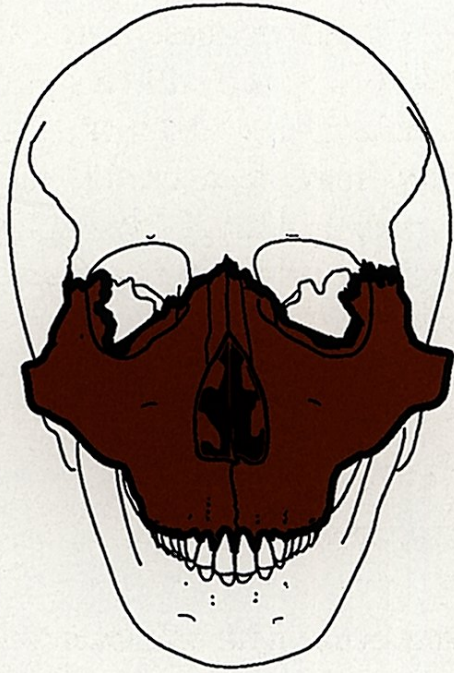




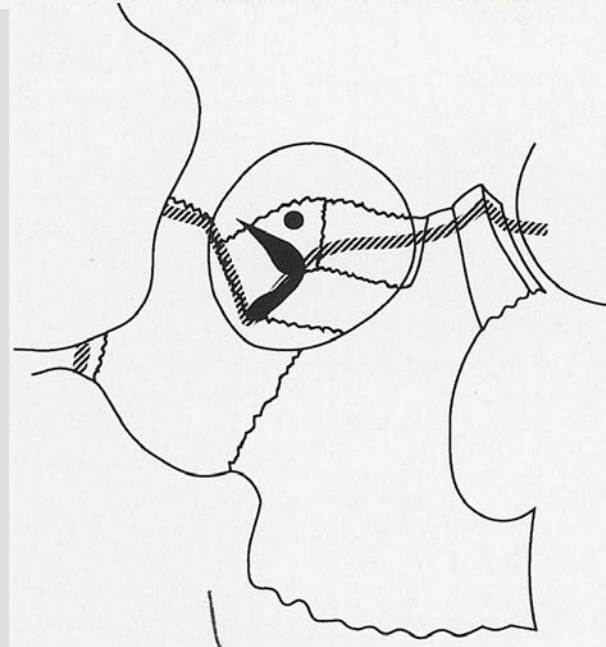
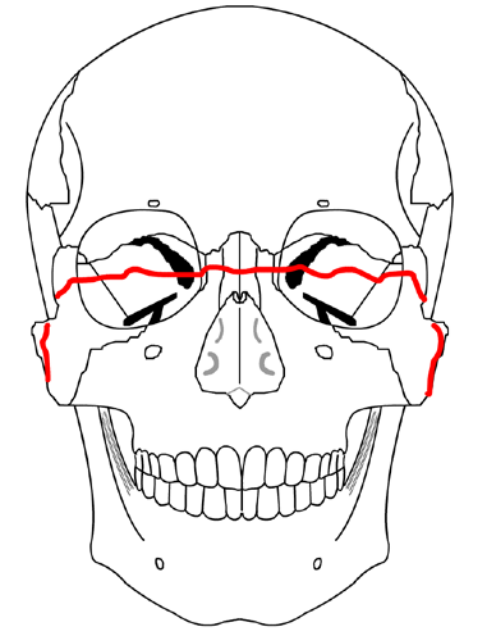
Le Fort II

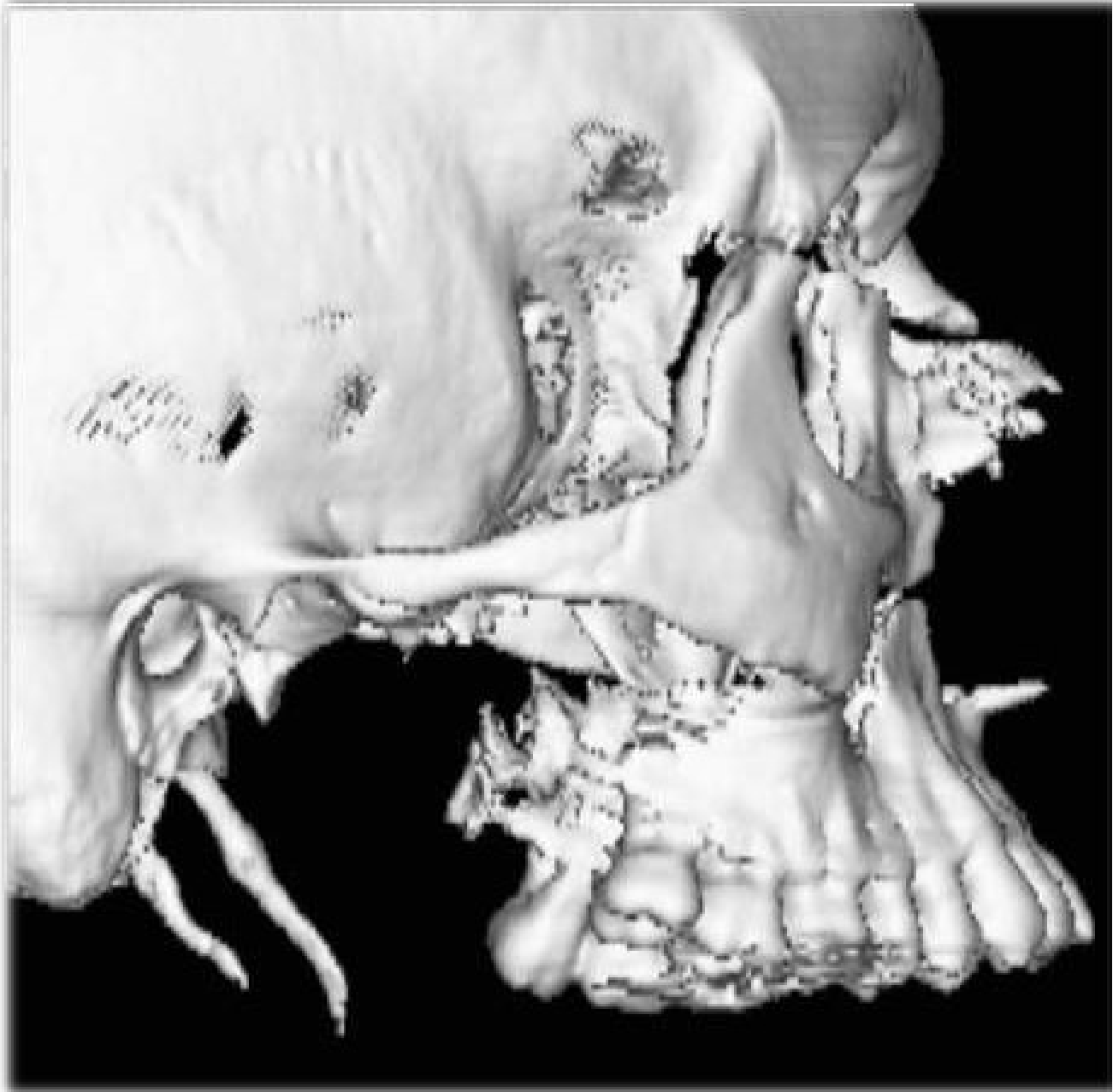





Le Fort III





Capacité régénératrices des fractures faciales

