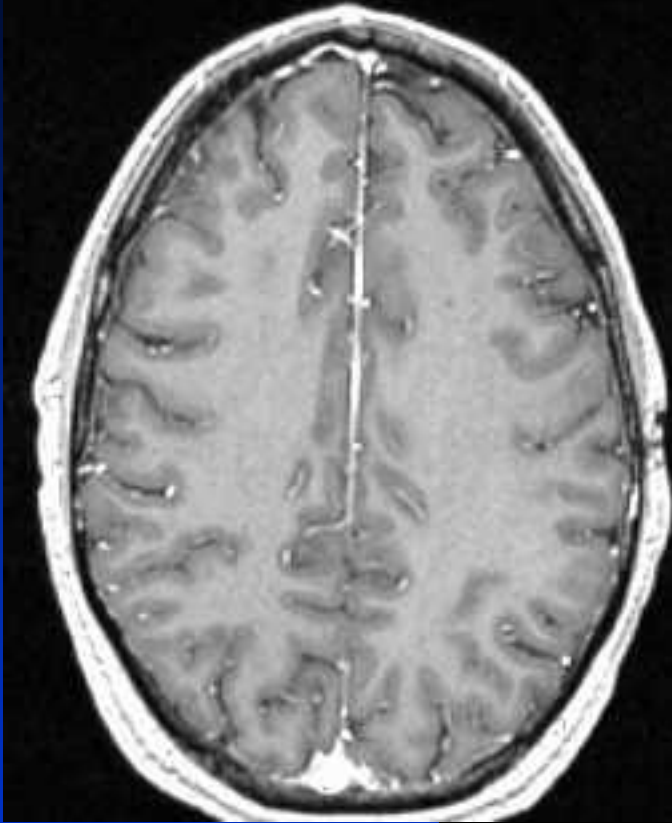
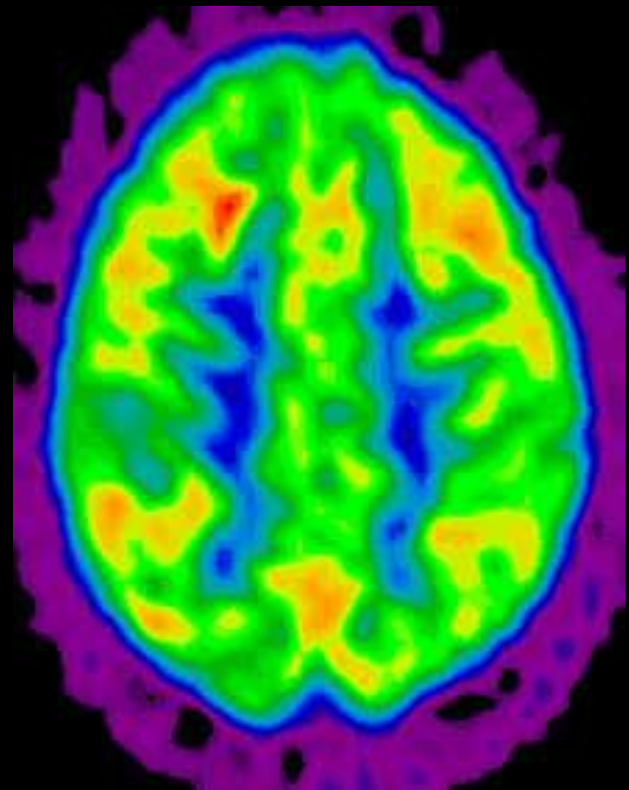


Anatomy : MRI



Fonction : Nucl Med



Nuclear Medicine – Diagnosis

- Functional imaging = distribution of a (radio)-tracer in organs
- Each tracer is a SPY of a function, usually through a metabolic pathway
 - ◆ flow
 - ◆ Bone modelling activity
 - ◆ Glomerular filtration
 - ◆ Iodine uptake and organification
 - ◆ Glucose metabolism
 - ◆

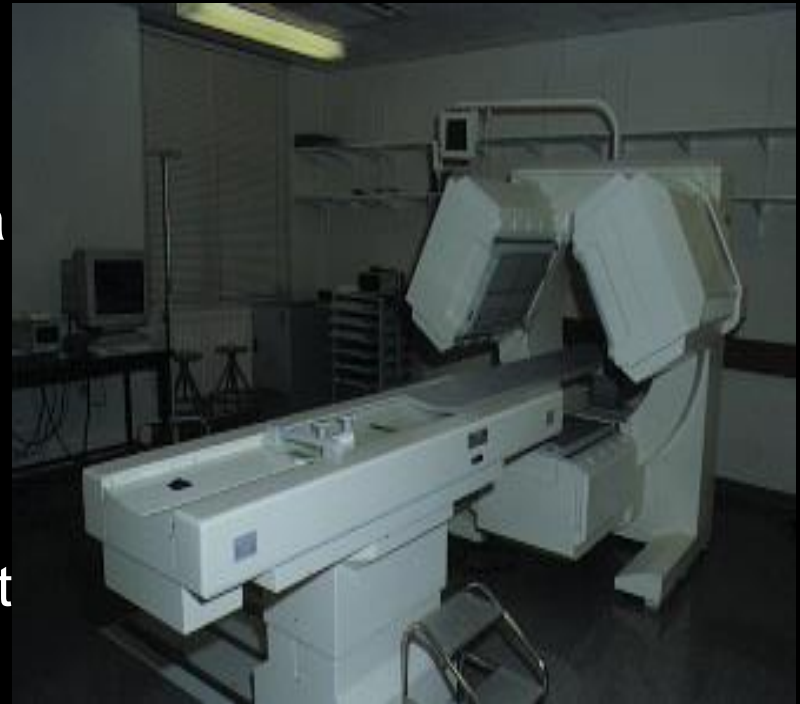Comment ?

- A l'aide de **traceurs**

- ◆ Véritables « espions » du métabolisme cellulaire
- ◆ Se concentrent dans les organes à étudier

- A l'aide de **gamma caméras**

- ◆ Détectent les zones de concentration du traceur et forment une image analysable par le médecin



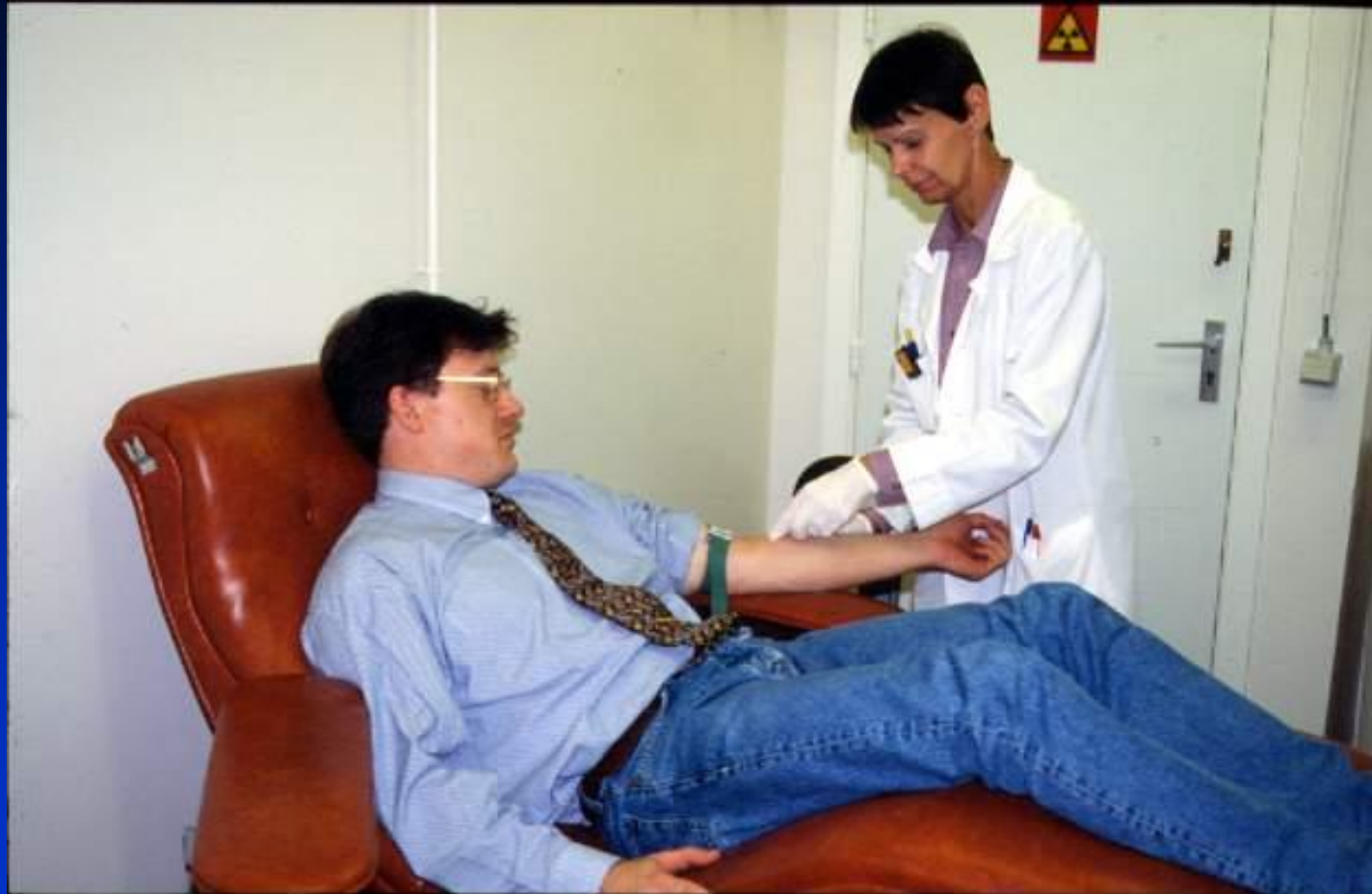Déroulement d'un examen

1. Préparation du radiotraceur



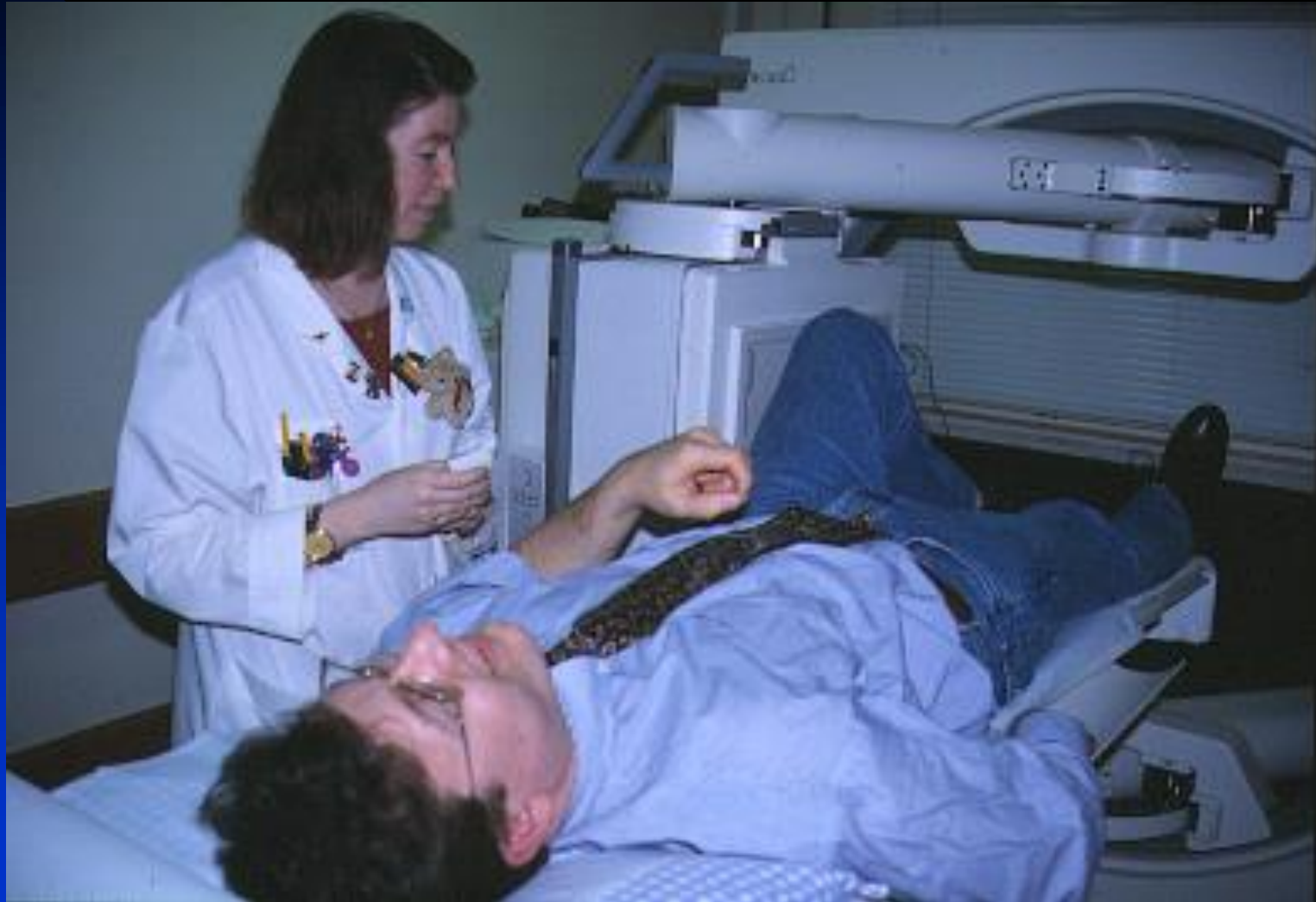Déroulement d'un examen

2. Injection



Déroulement d'un examen

3. Réalisation des images

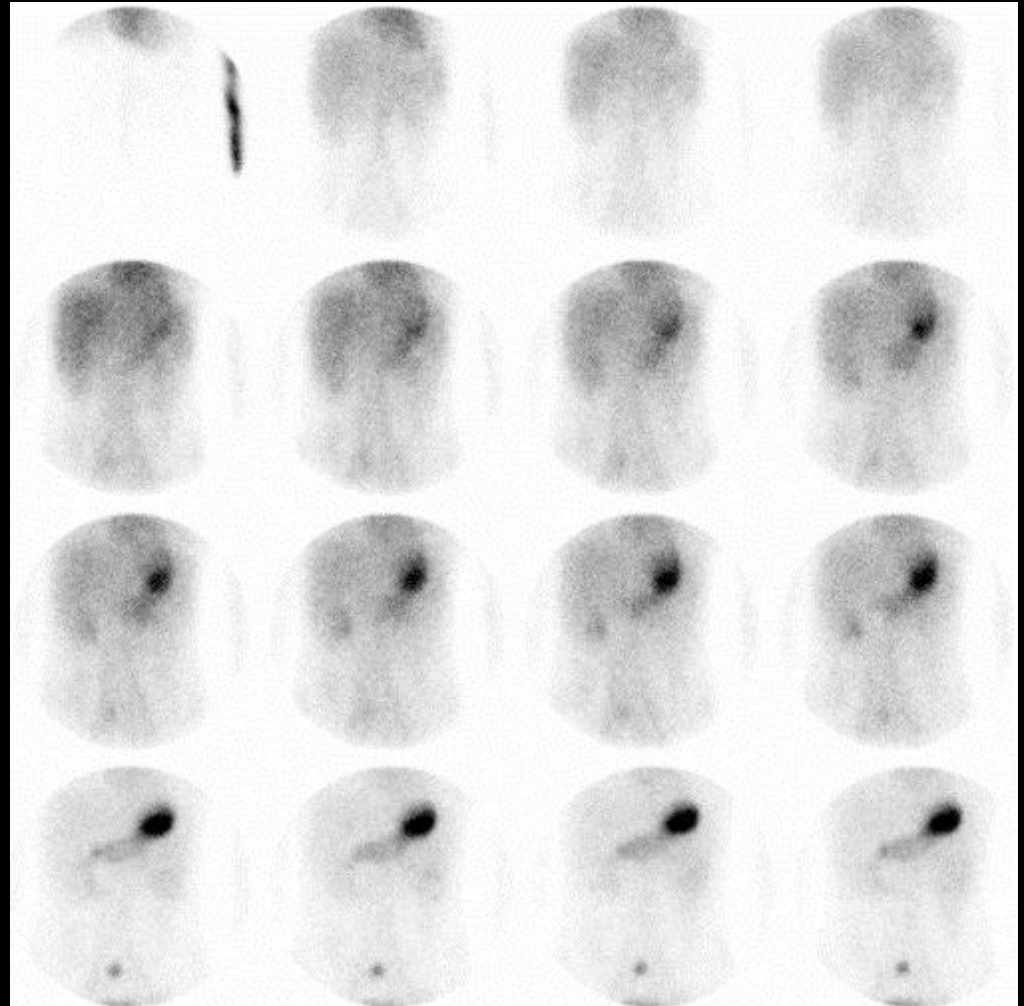


Déroulement d'un examen

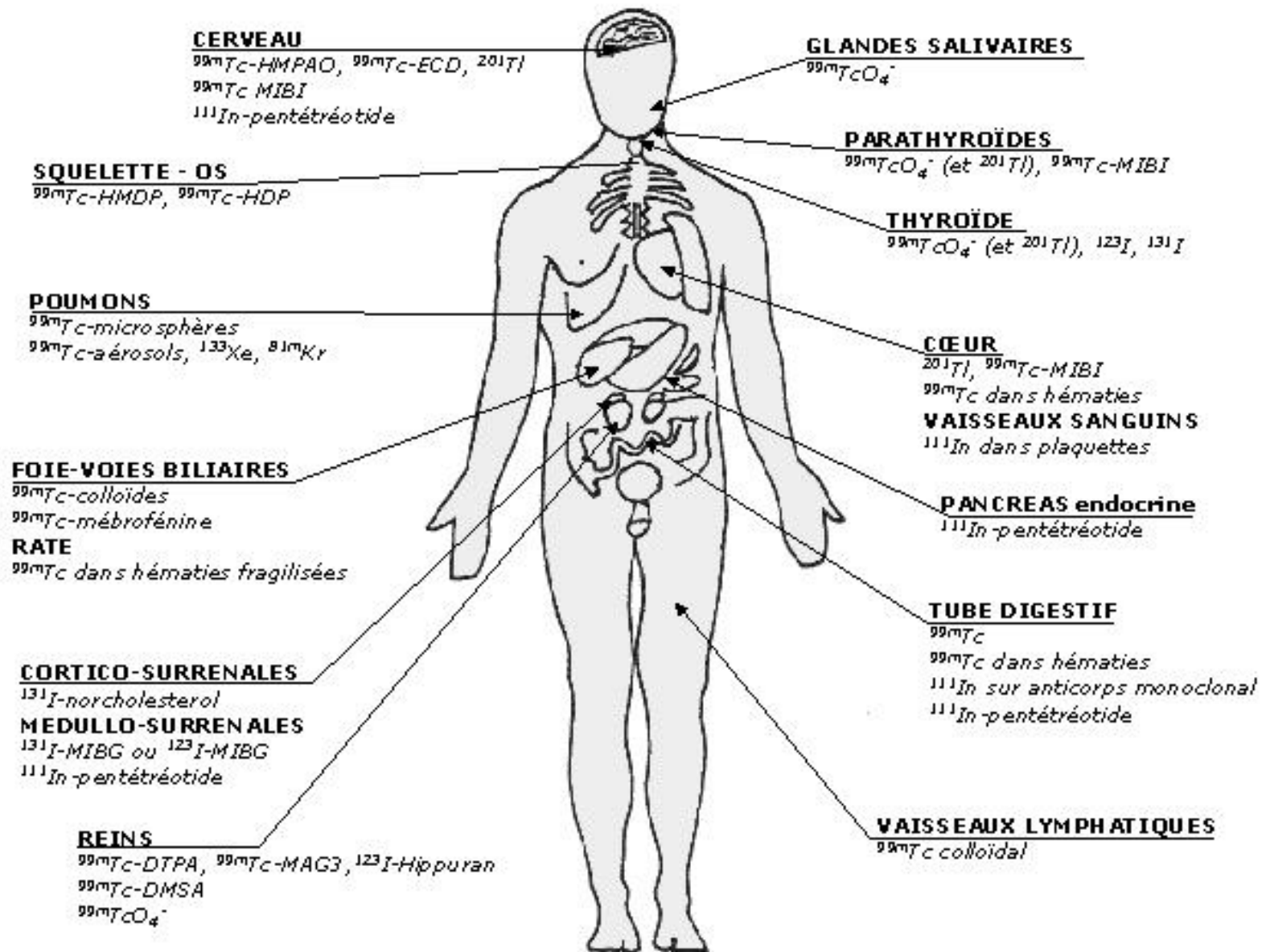
3. Réalisation des images

Dynamique, dès
l'injection du
traceur

**Diverticule de
Meckel**









Nuclear Medicine: Diagnosis









in vivo Nuclear Medicine

The ideal tracer (diagnosis)


-  Principle of tracer dose (*carrier-free*)
-  Availability, price, production
-  Chemistry simple and readily available
-  Cold kit
-  No pharmacological effect, no toxicity
-  Appropriate physical characteristics

Radioactive tracers (diagnosis)

Characteristics to observe

-  **Gamma* emission**
-  **Energy: 80-400 keV (ideal: 140 keV)***
-  **Effective half-life: < 1 week**
-  **Irradiation < 15 mSv**
-  **Availability > 1x/week**
-  **Protection of the environment**

***Exception: positron emitters**



in vivo Nuclear Medicine Technetium-99m

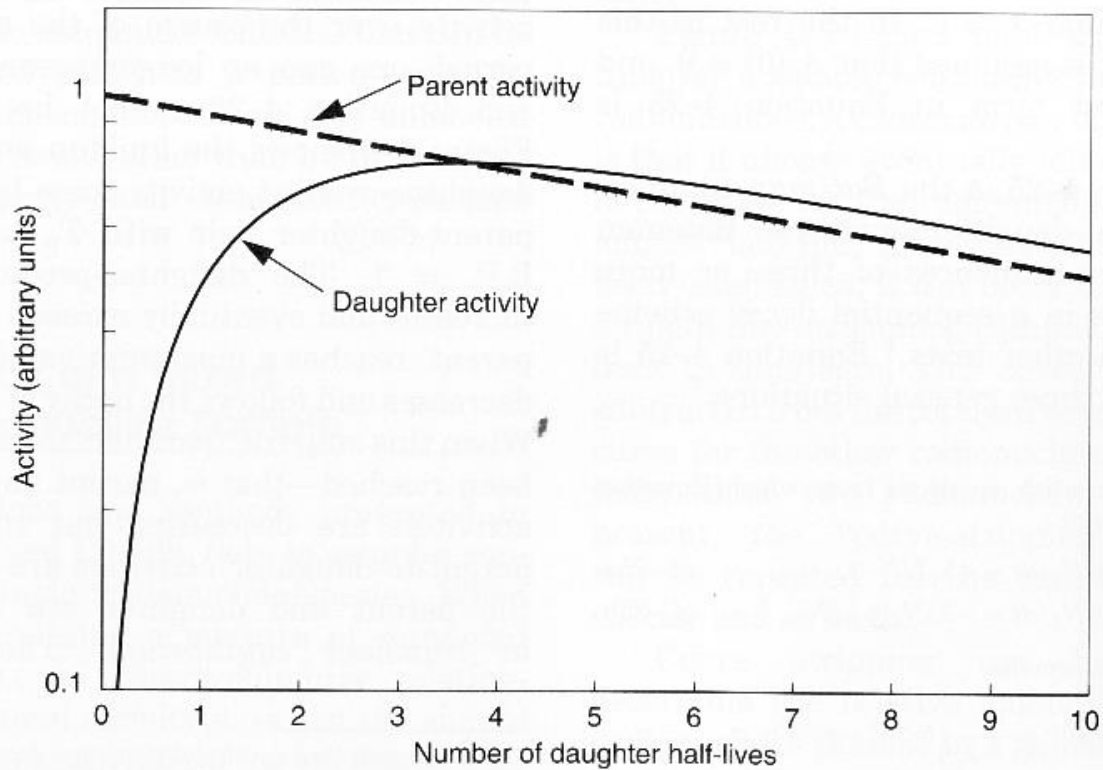
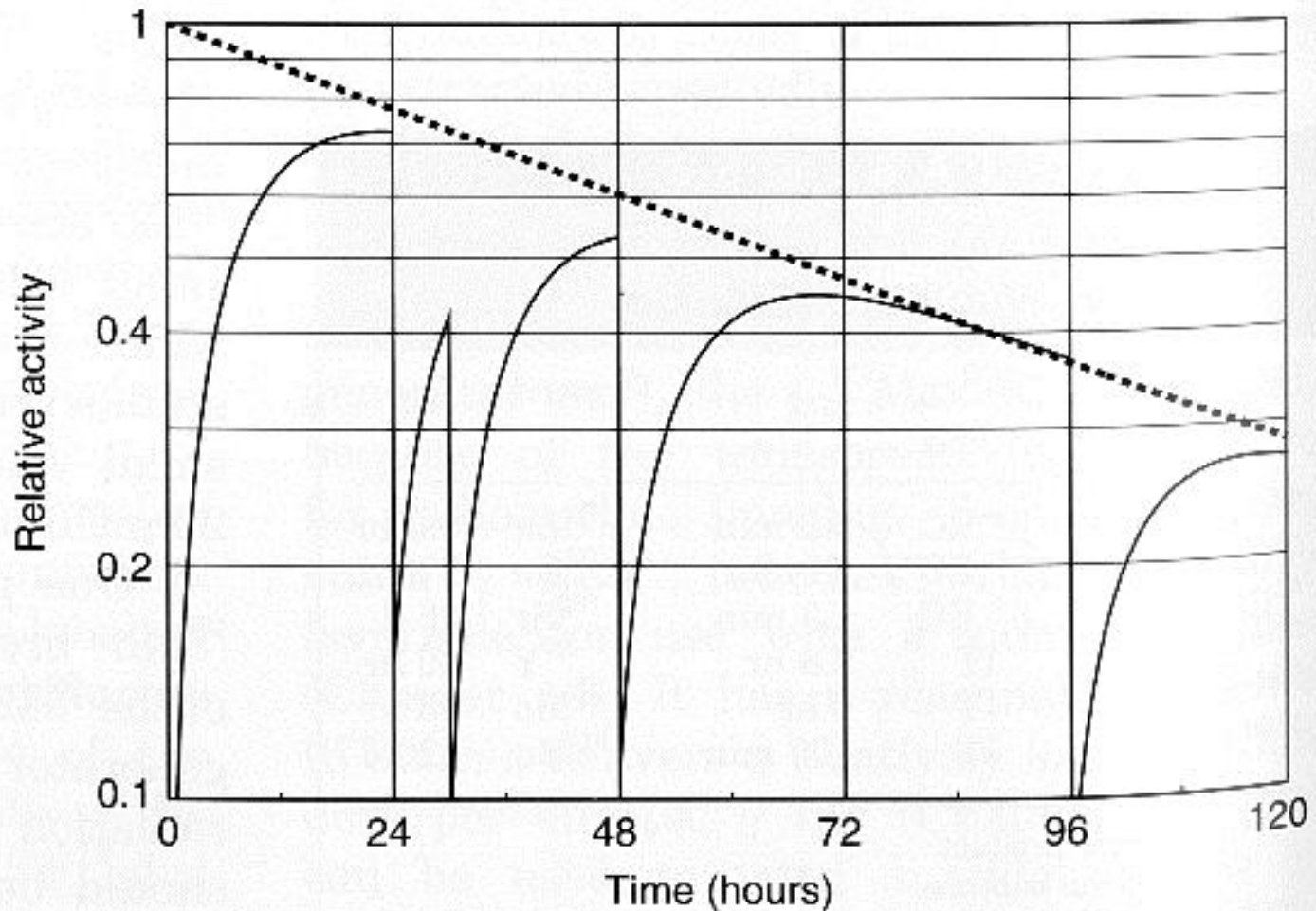
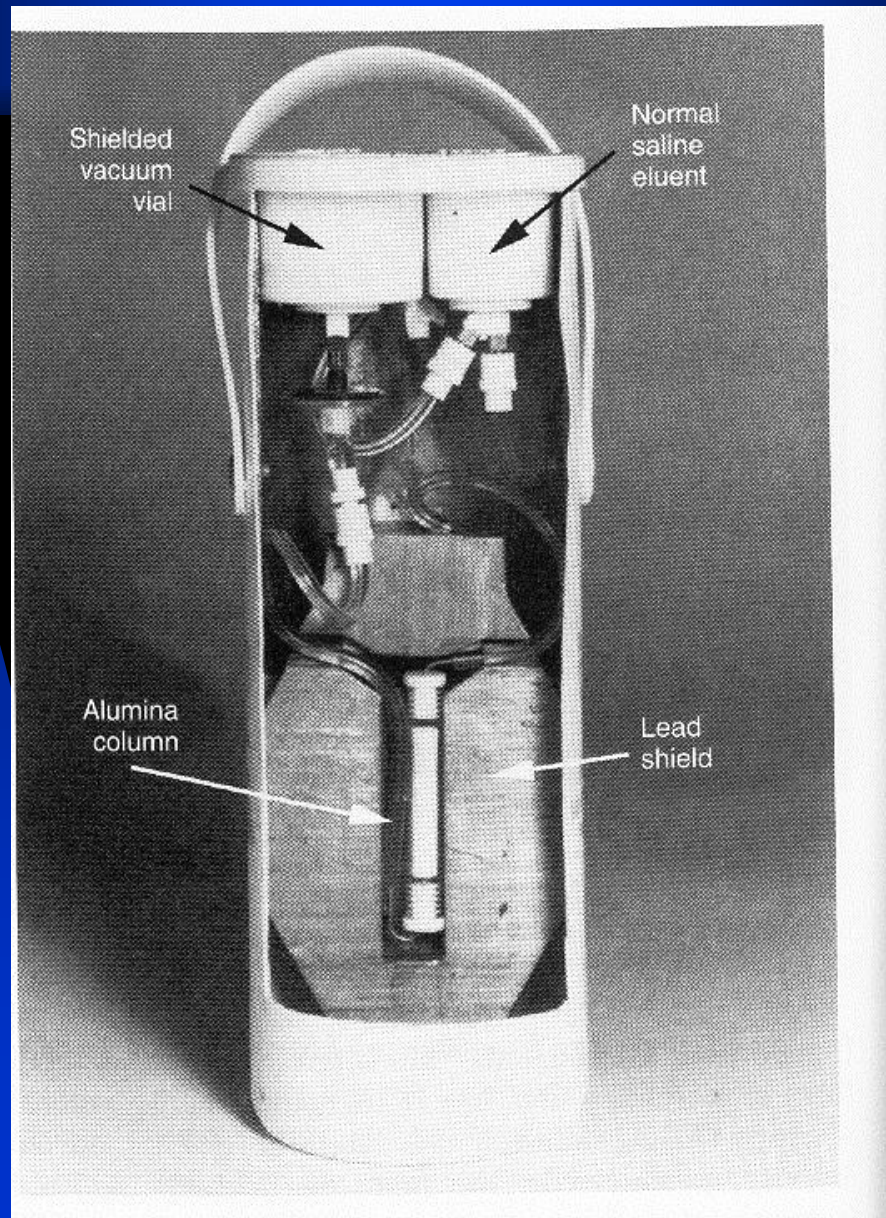


Figure 4-8. Buildup and decay of activity for $T_p = 10 T_d$, branching ratio = 1. Eventually, transient equilibrium is achieved when the parent and daughter decay curves are parallel.

in vivo Nuclear Medicine Technetium-99m



in vivo Nuclear Medicine



in vivo Diagnosis

Ligand and tracer types

 **free radioisotope** : ^{201}Tl , ^{67}Ga , $^{99\text{m}}\text{TcO}_4^-$, $^{81\text{m}}\text{Kr}$

 ***in vitro* labelling:**

small synthesis molecules : MDP, MIBI

proteins: albumine, monoclonal Ab

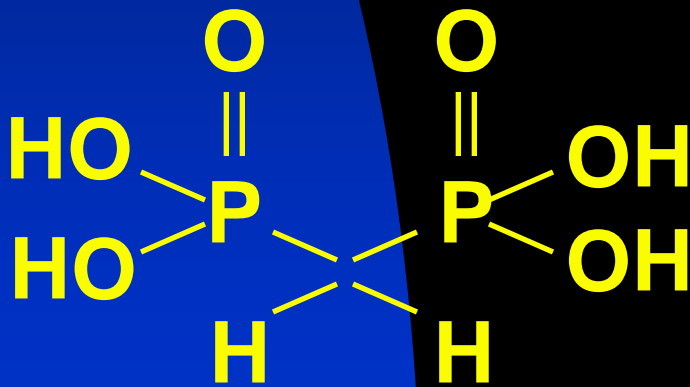
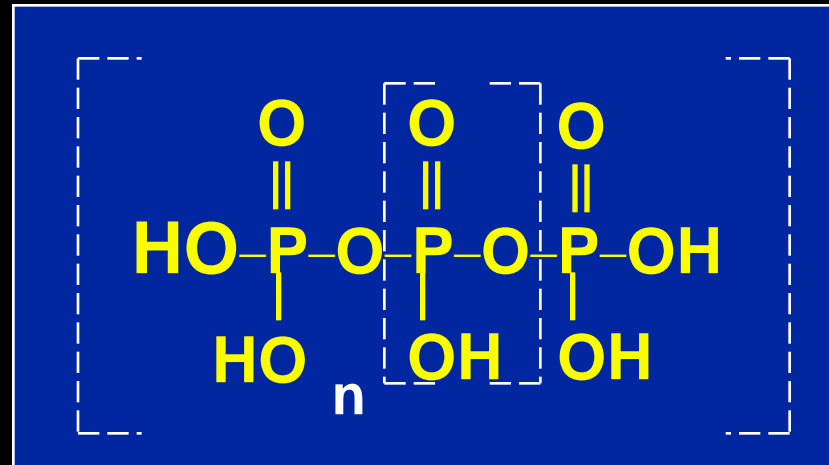
peptides or hormones: octreotide, oestrogen

particles: colloïds, macroagregates

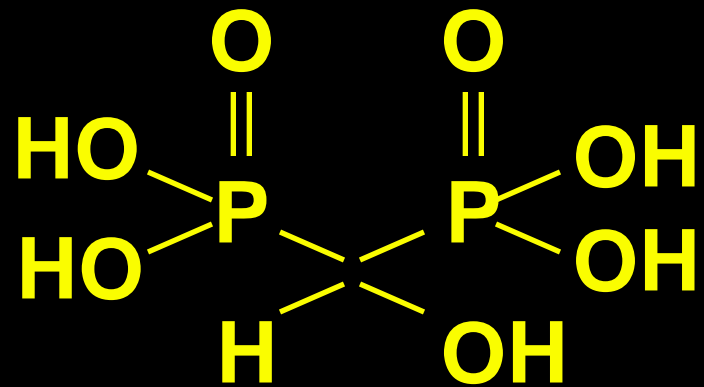
blood cells : RBC, WBC

 **(in)organic *de novo* synthesis:** PET tracers

^{99m}Tc : polyphosphates adsorption to hydroxyapatite

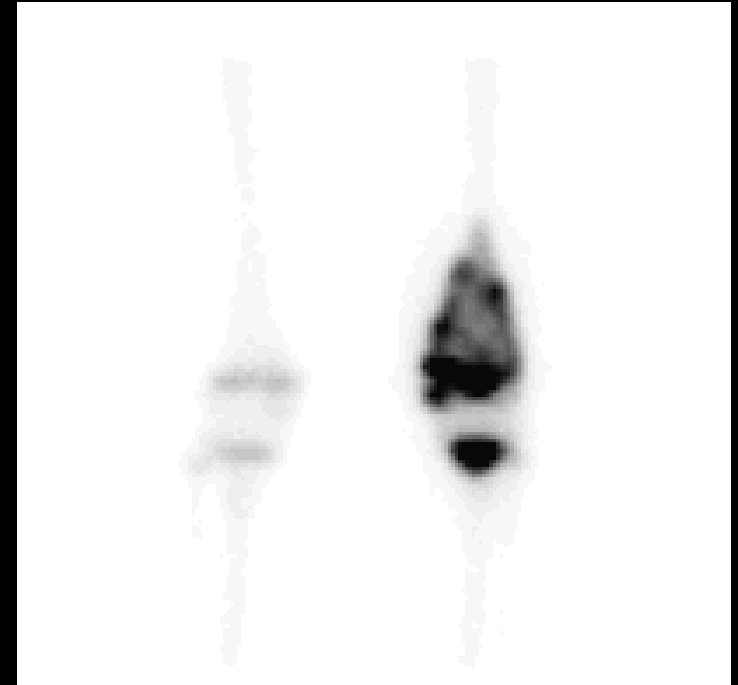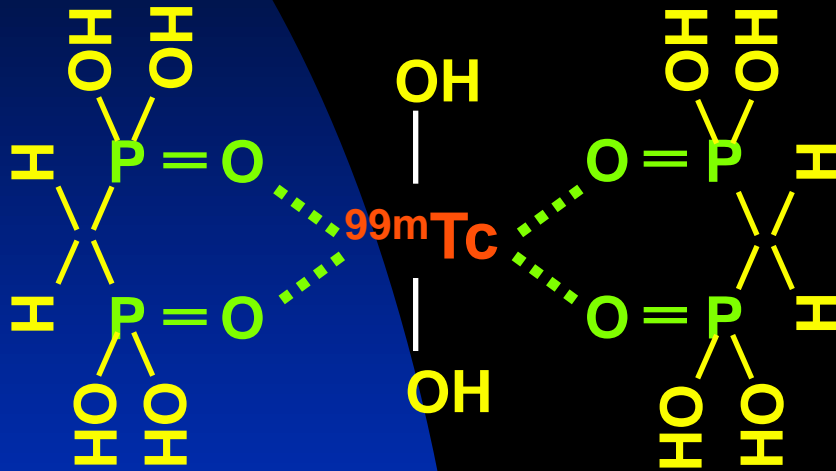


MDP



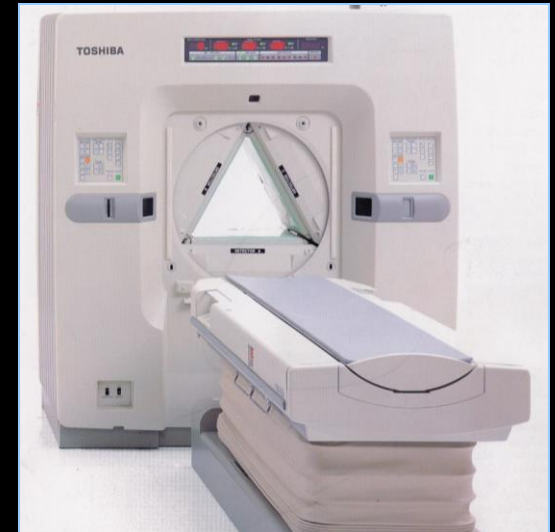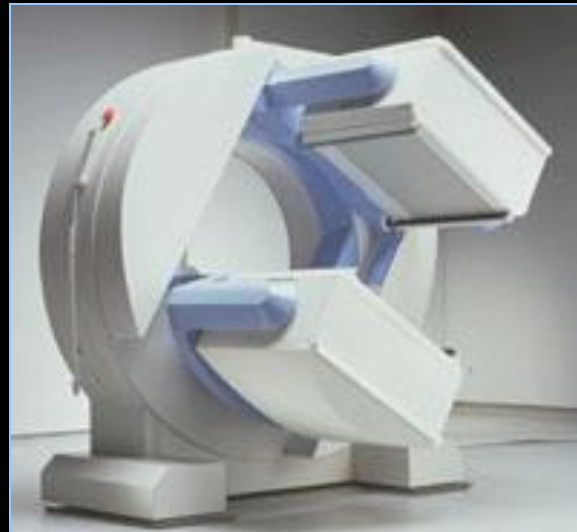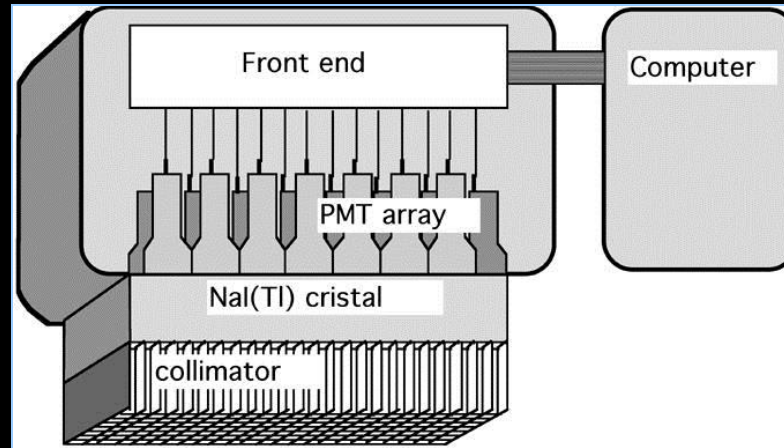
HDP

^{99m}Tc : polyphosphates methylene-diphosphonate

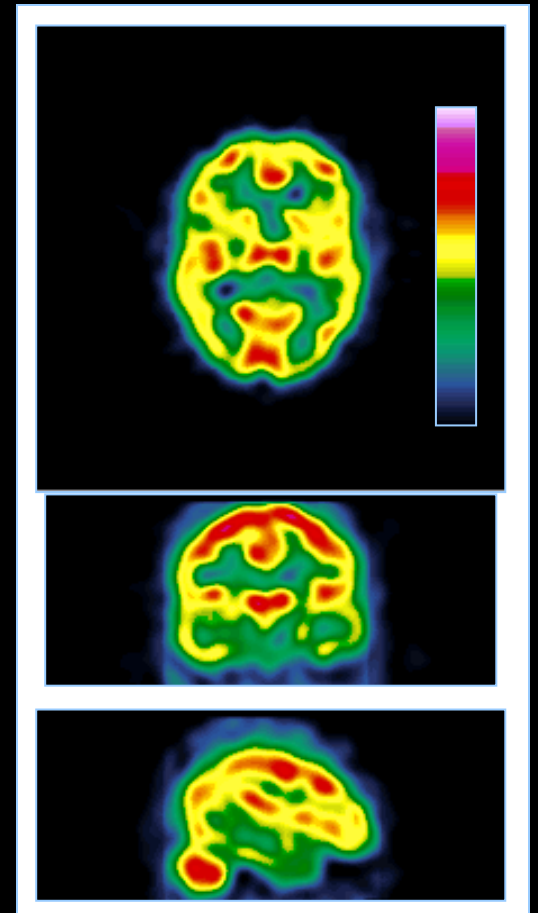
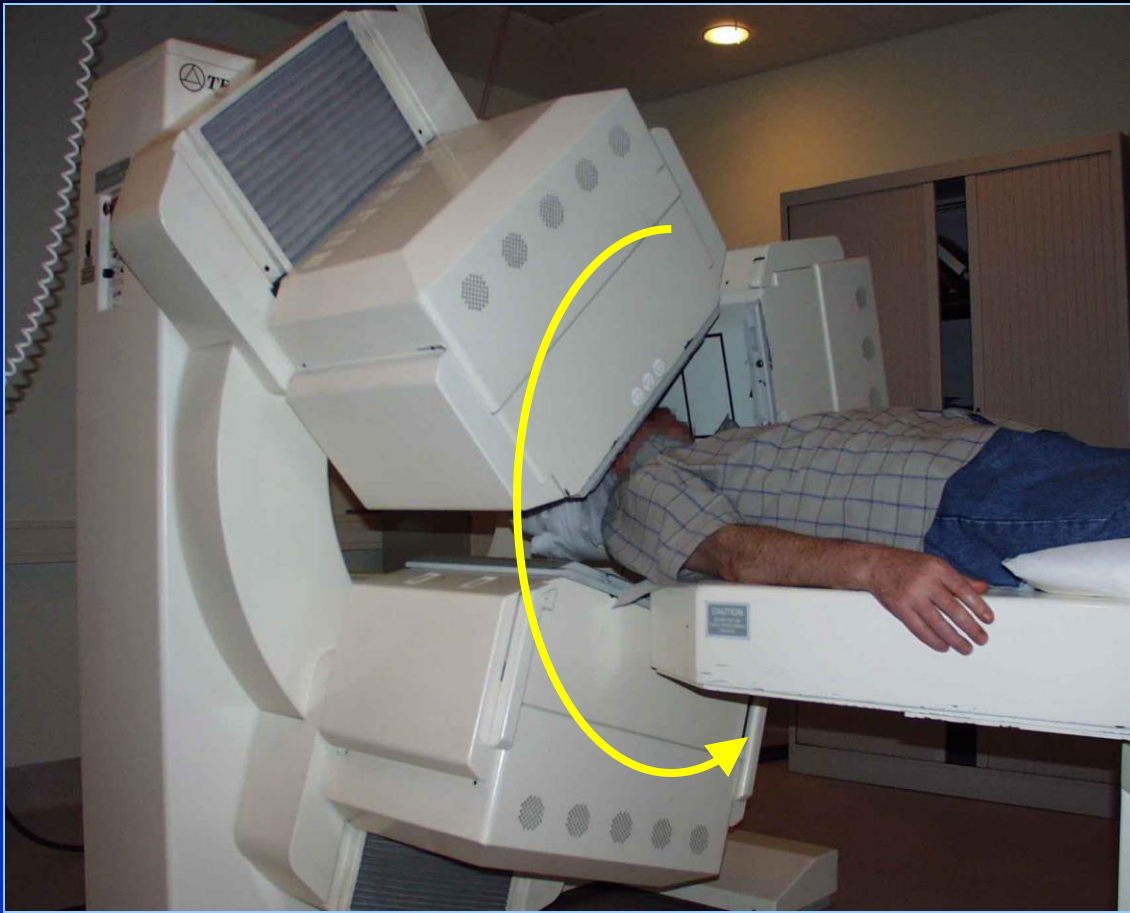

Osteosarcoma

Gamma Camera

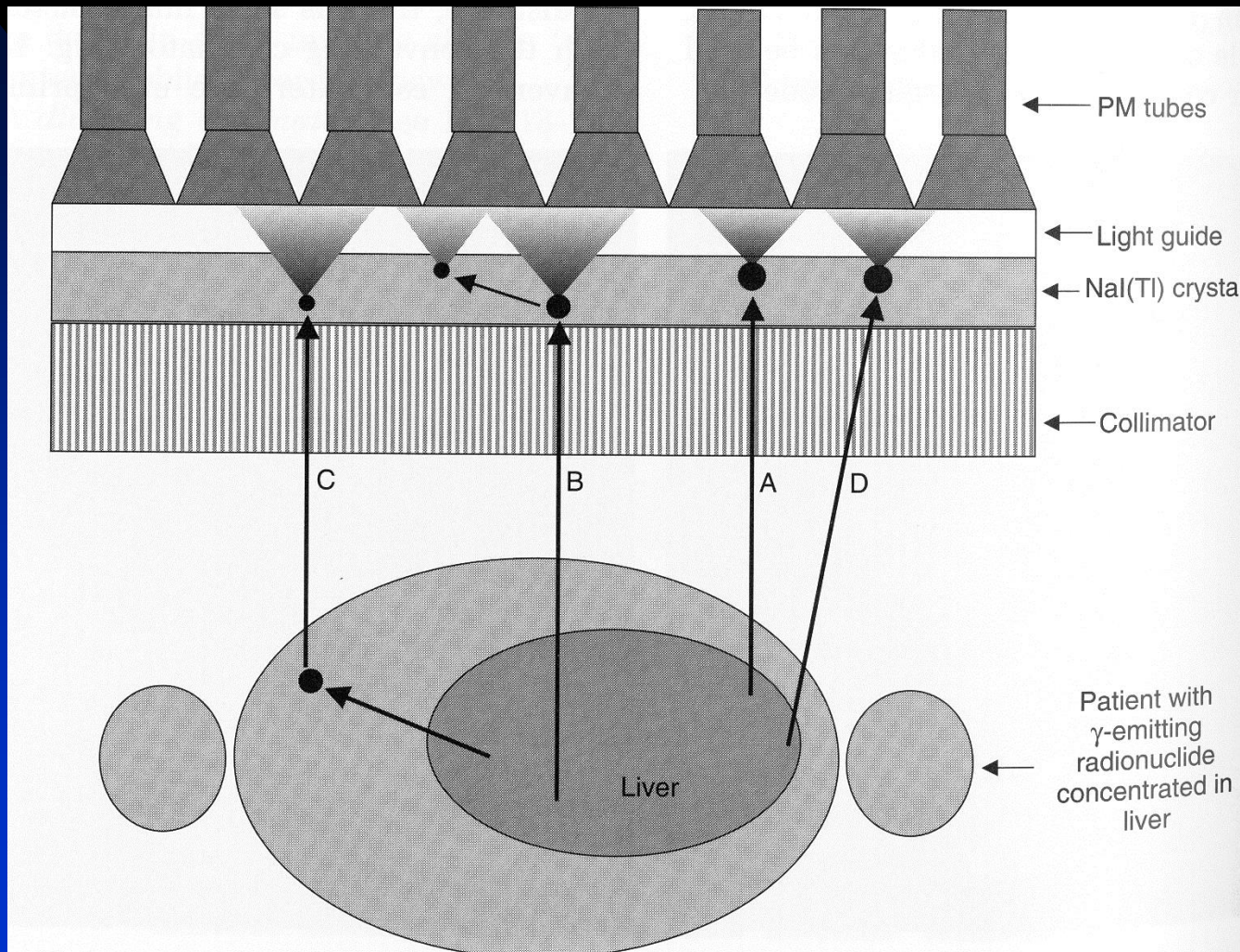


Single-Photon Computed Emission Tomography: SPECT



in vivo Nuclear Medicine

The detector (Anger/SPECT)



in vivo Nuclear Medicine

The detector (Anger/SPECT)

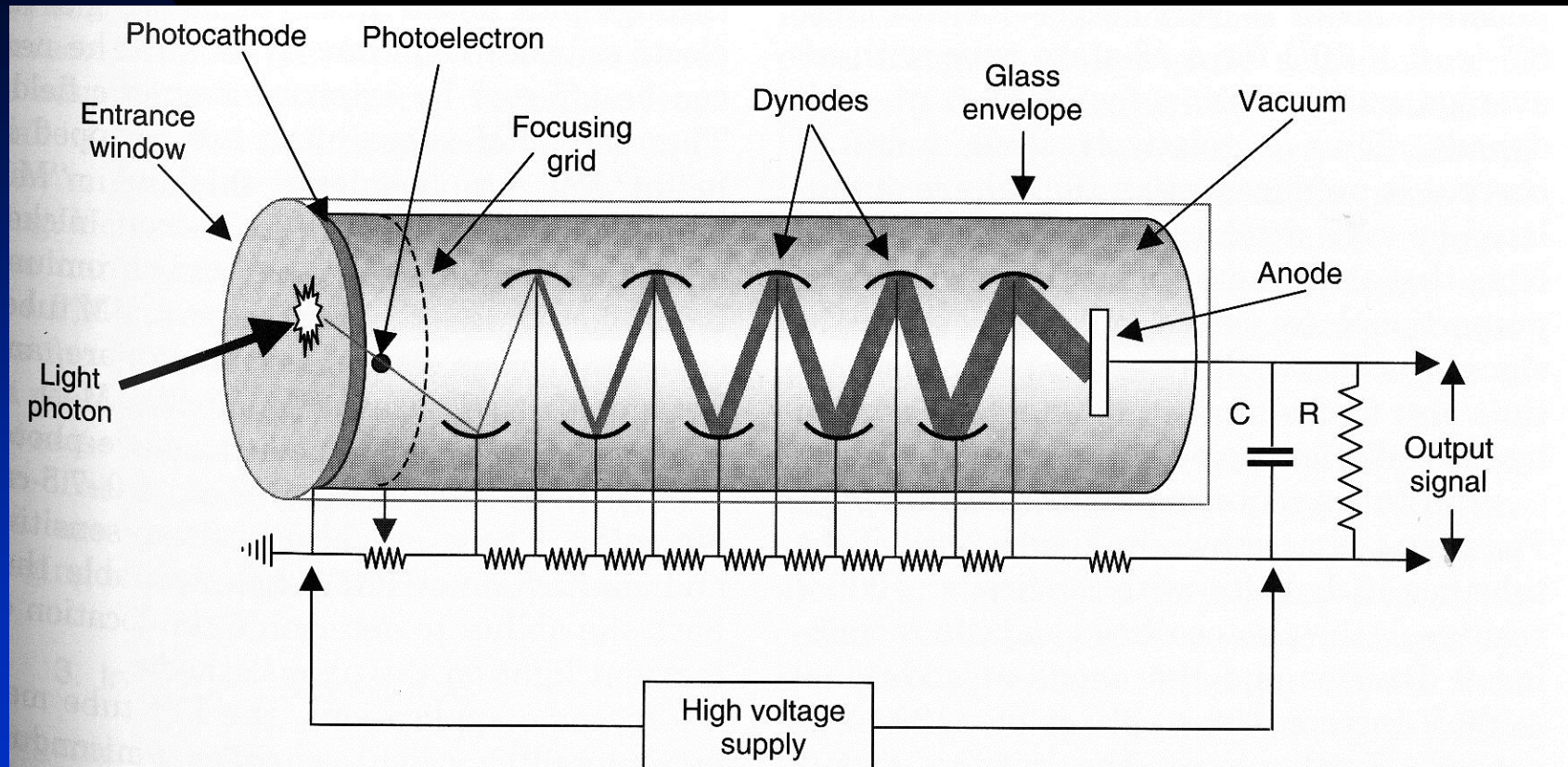
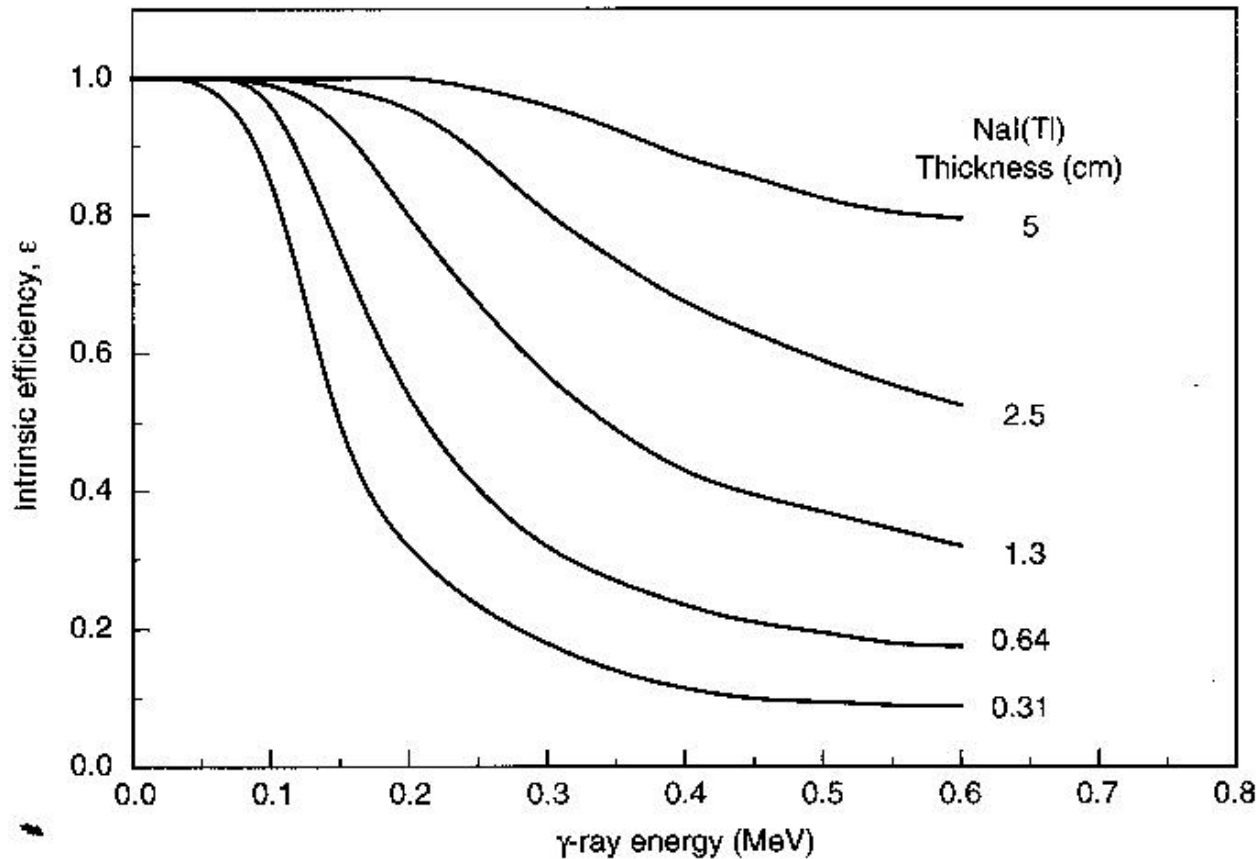


Figure 7-13. Basic principles of a photomultiplier tube.

in vivo Nuclear Medicine

The detector (Anger/SPECT)



in vivo Nuclear Medicine

The detector (Anger/SPECT)

154 • • • PHYSICS IN NUCLEAR MEDICINE

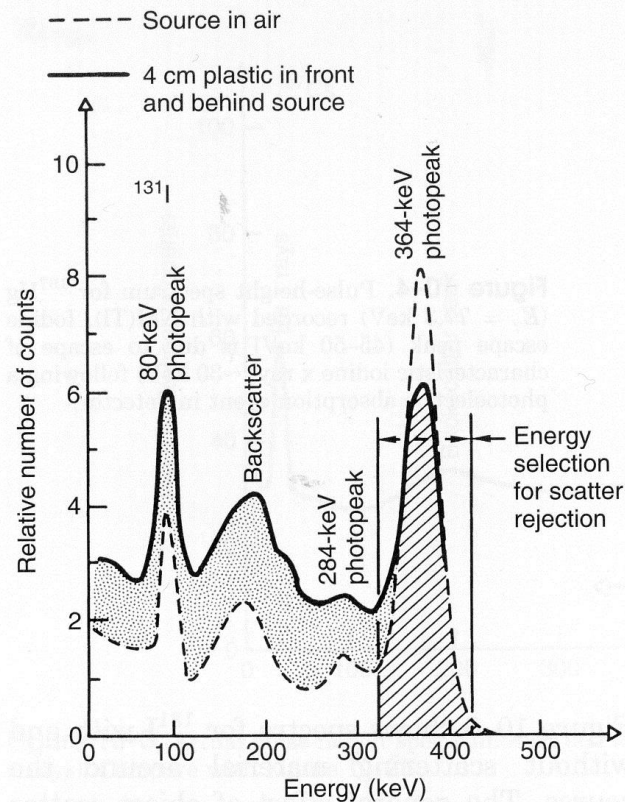
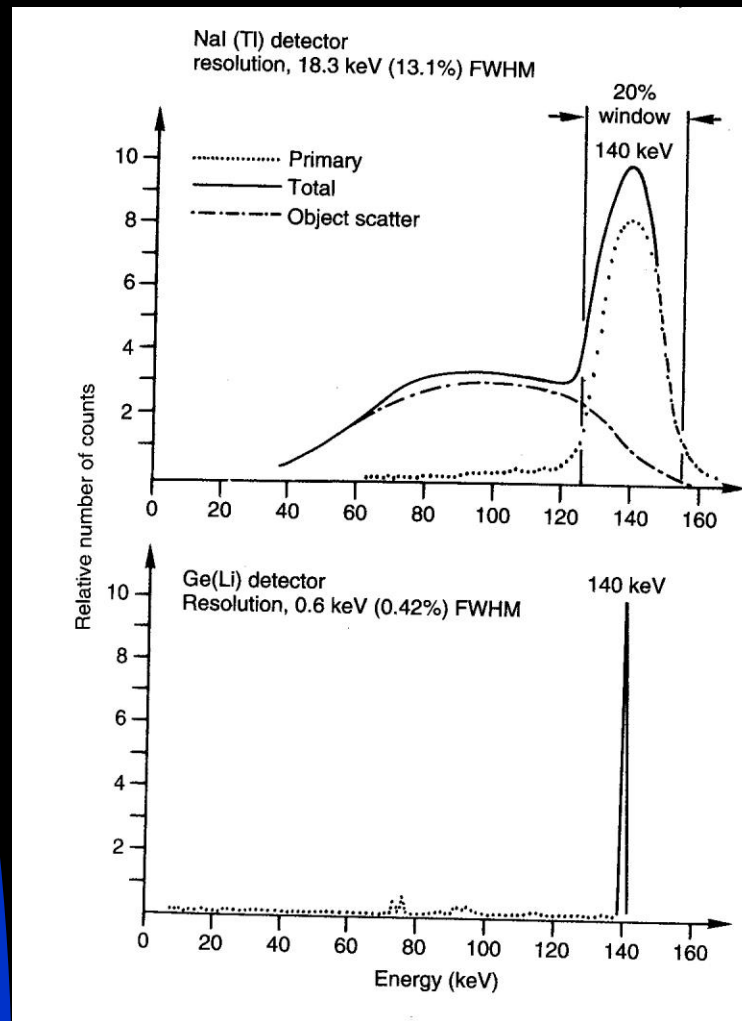


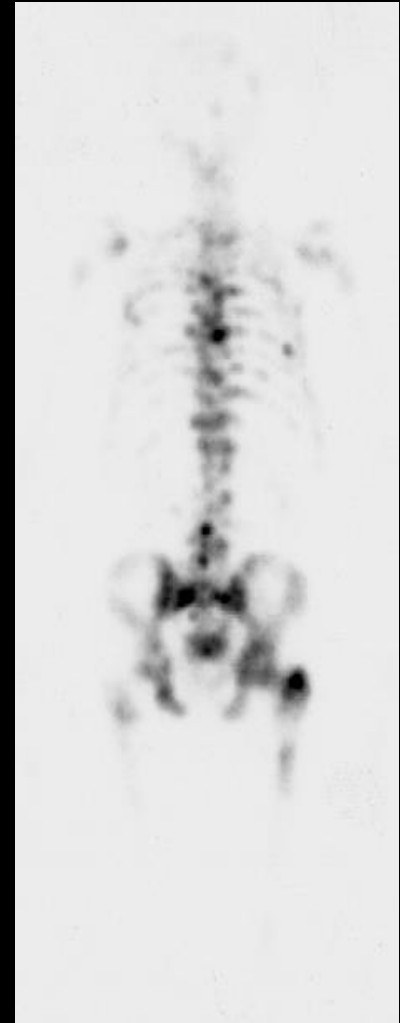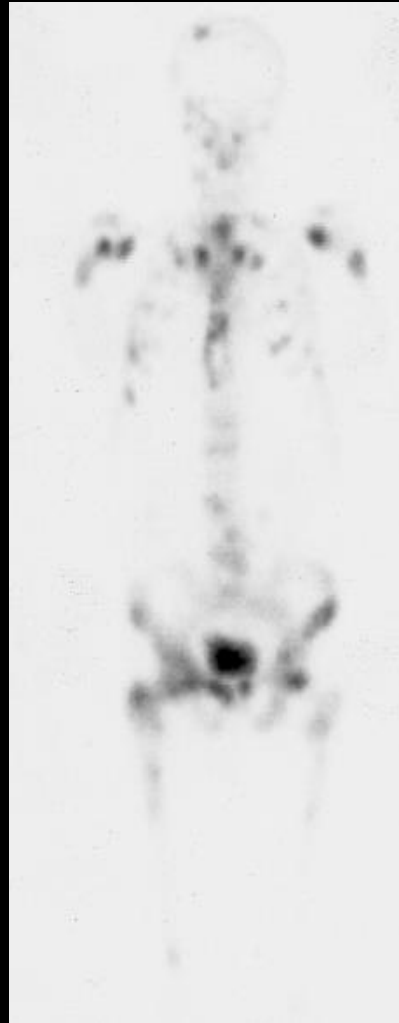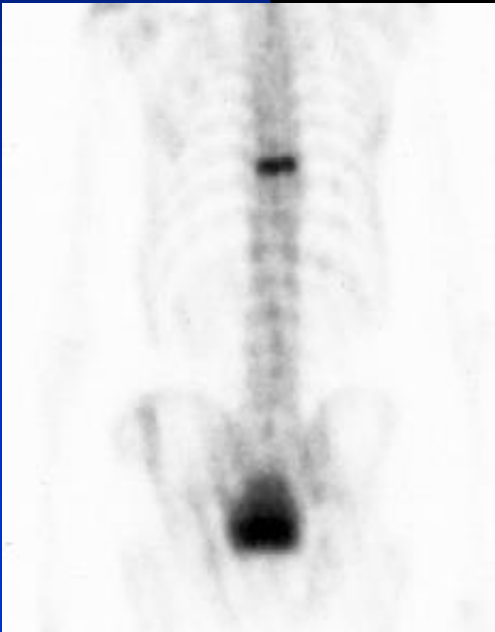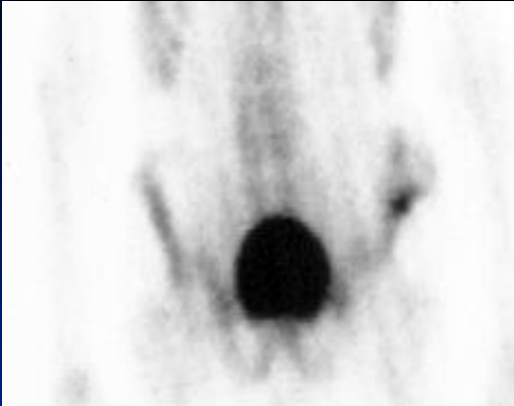
Figure 10-6. Effect of scattering material around the source on the pulse-height spectrum for ^{131}I . The *dot-shaded area* is the portion of the spectrum due to scattered γ rays.

in vivo Nuclear Medicine

The detector (Anger/SPECT)

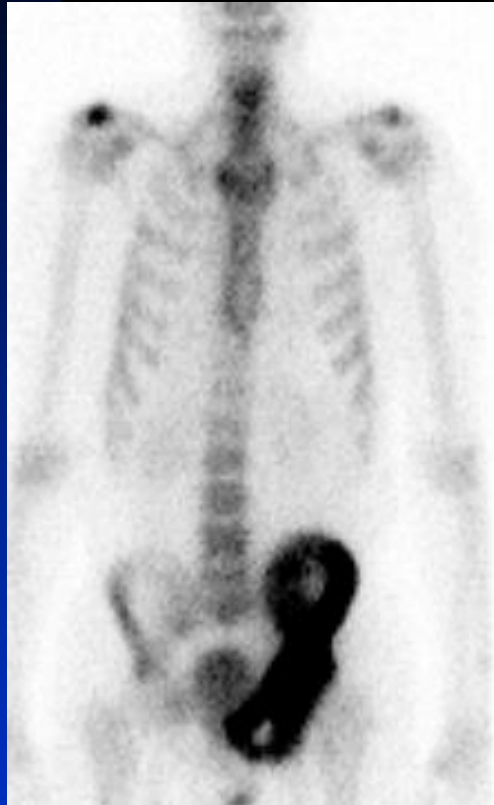

Bone Metastases: Distribution



Bone Scintigraphy - Interpretation

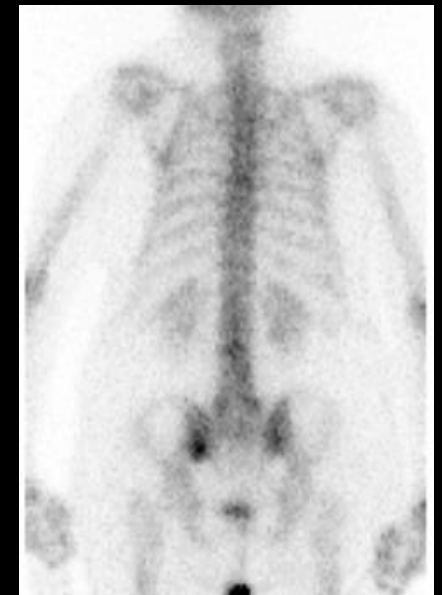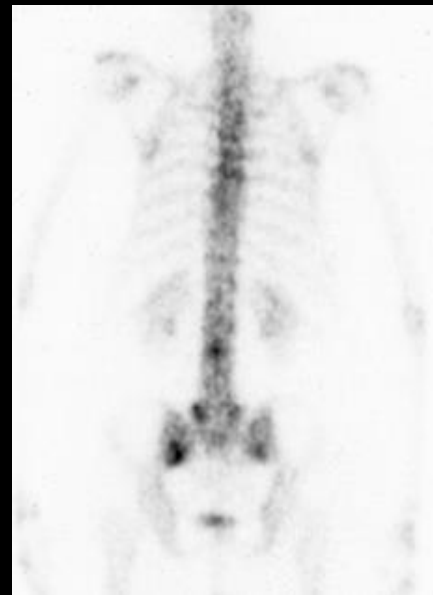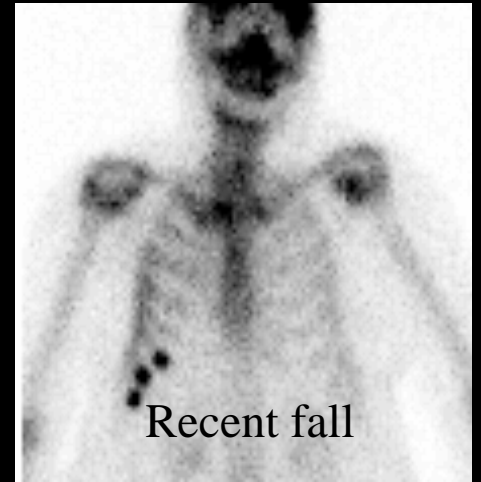
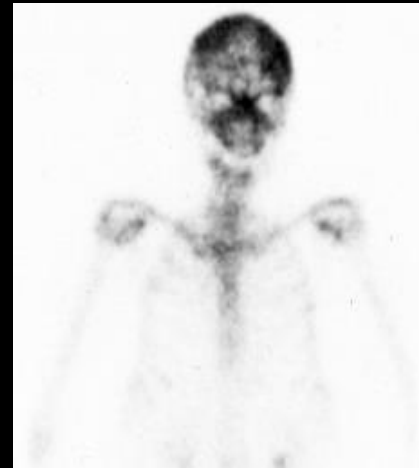Prostate Cancer



Raise Alk. Ph'ase

Paget's disease

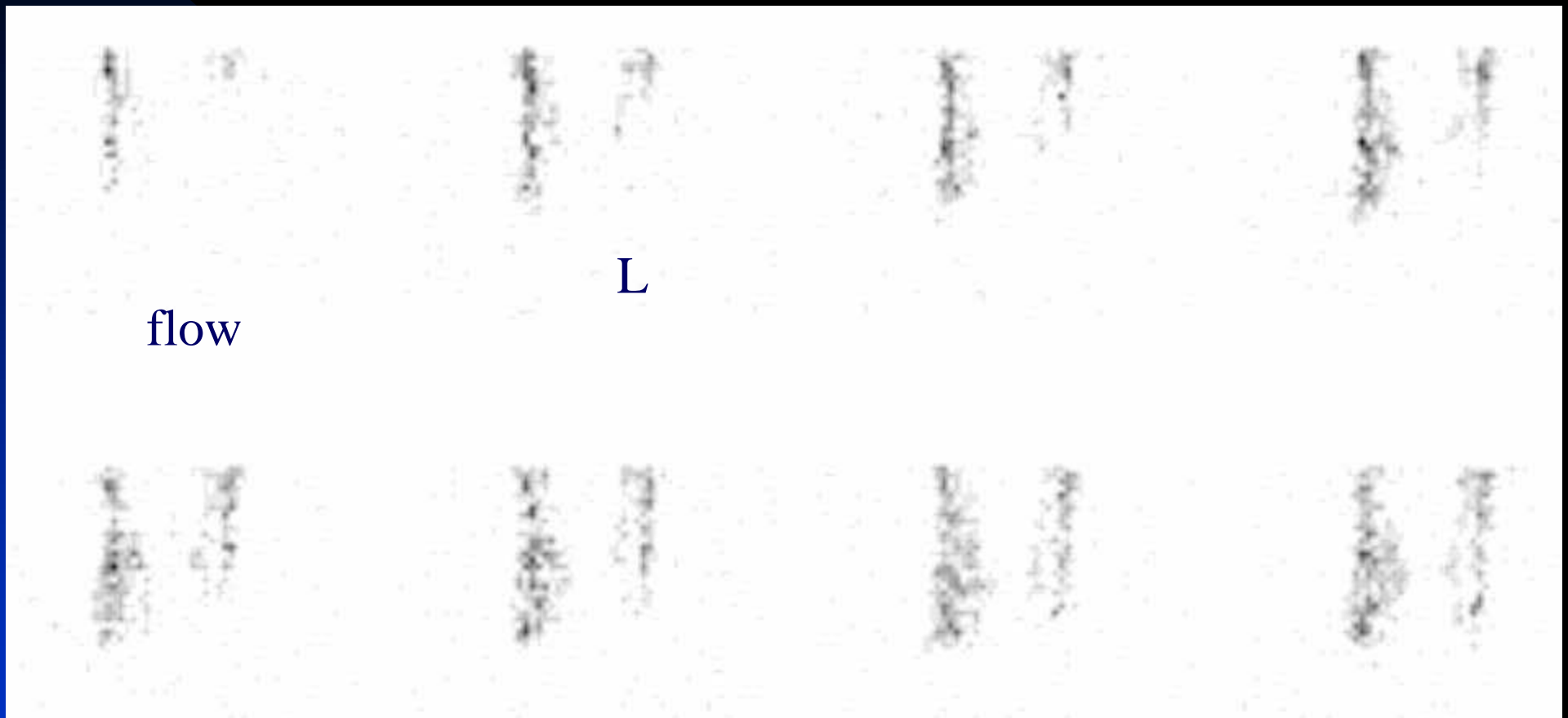
1998 Breast Cancer 2000



Bone Scintigraphy Fracture

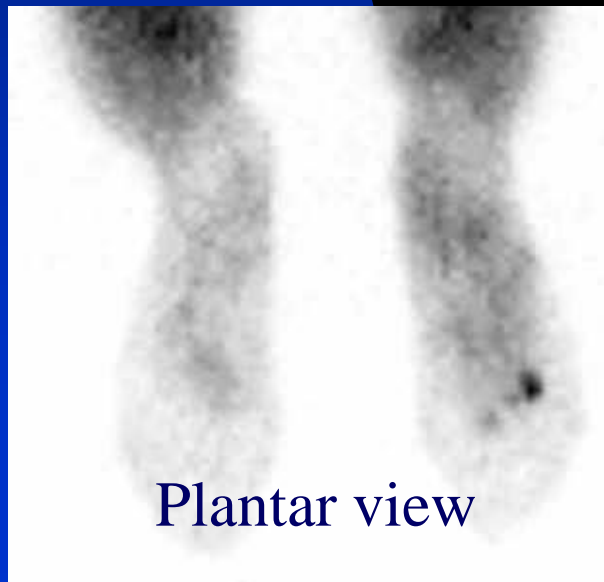
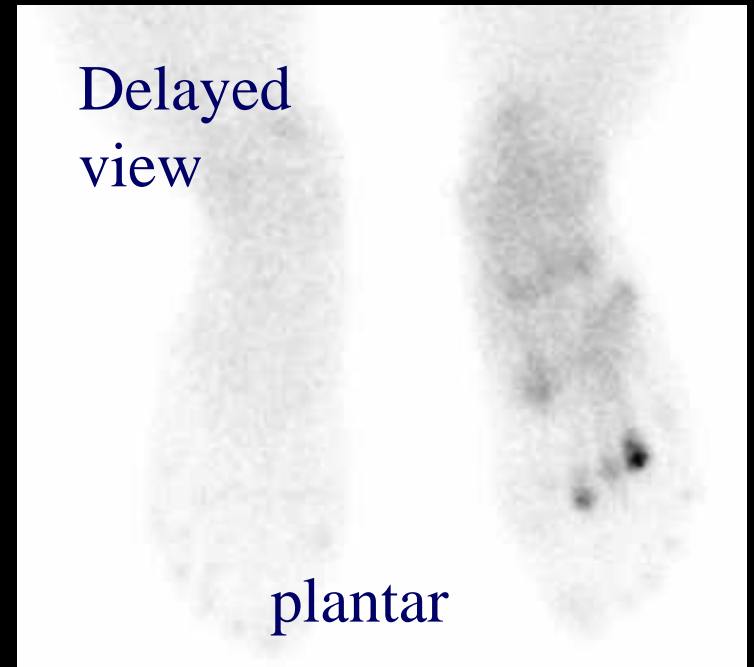
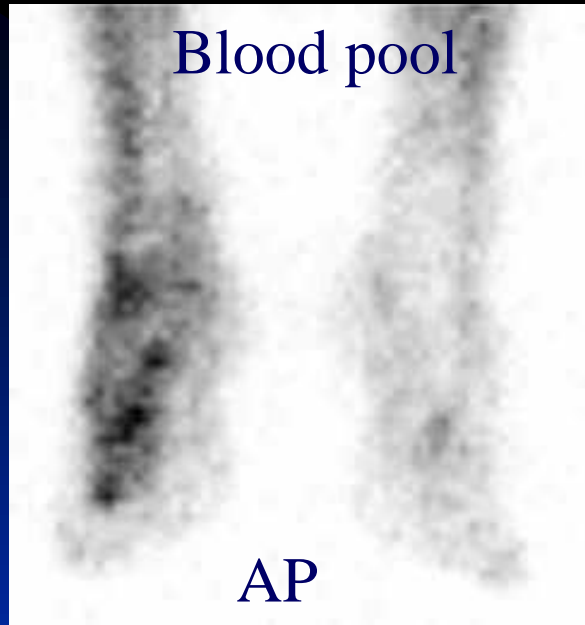
flow

L



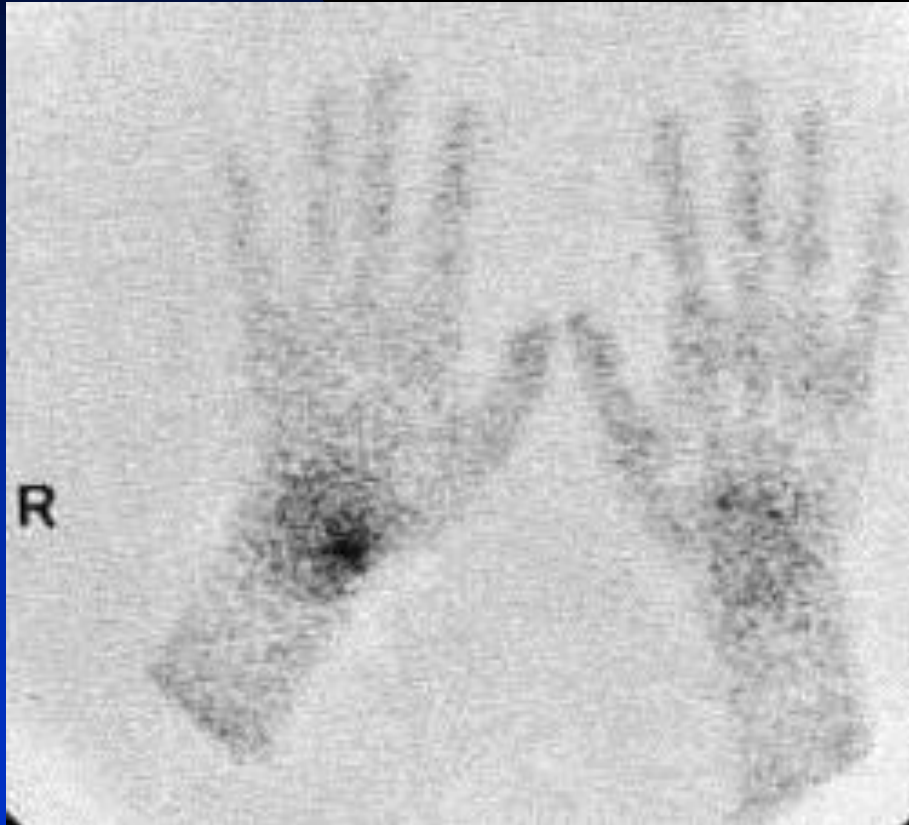Bone Scintigraphy

Fracture

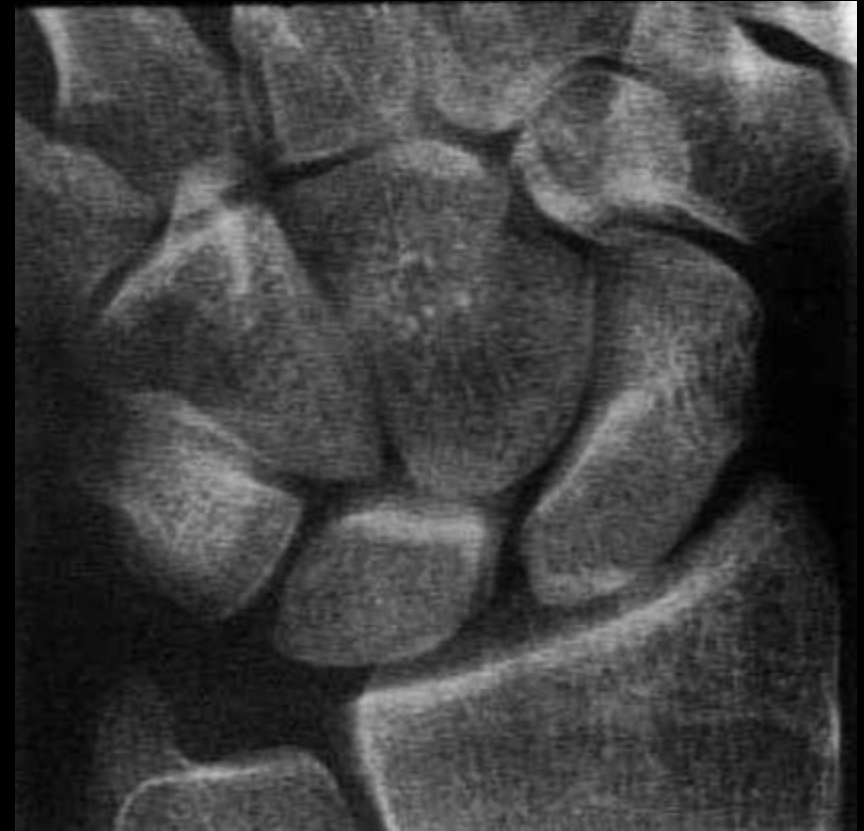

Bone Scintigraphy

Wrist Trauma



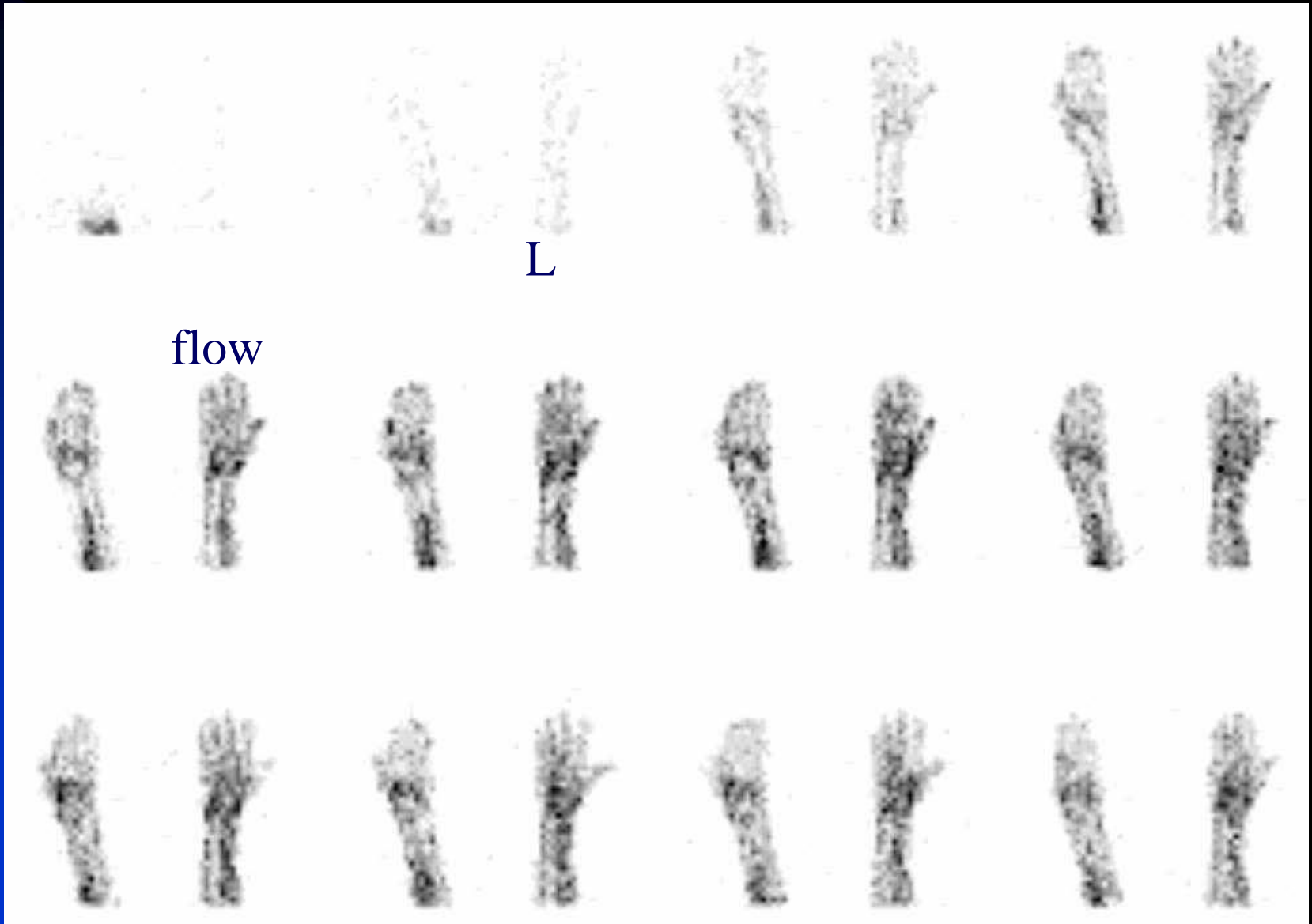
Fracture of navicular
bone



X-Ray

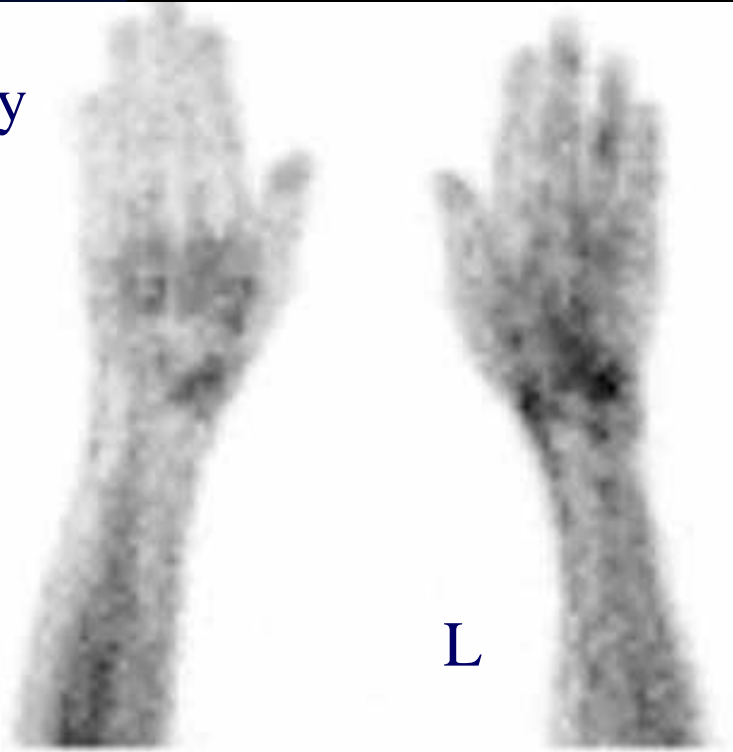Bone Scintigraphy

Algodystrophy (Sudeck's)




Bone Scintigraphy Algodystrophy (Sudeck's)

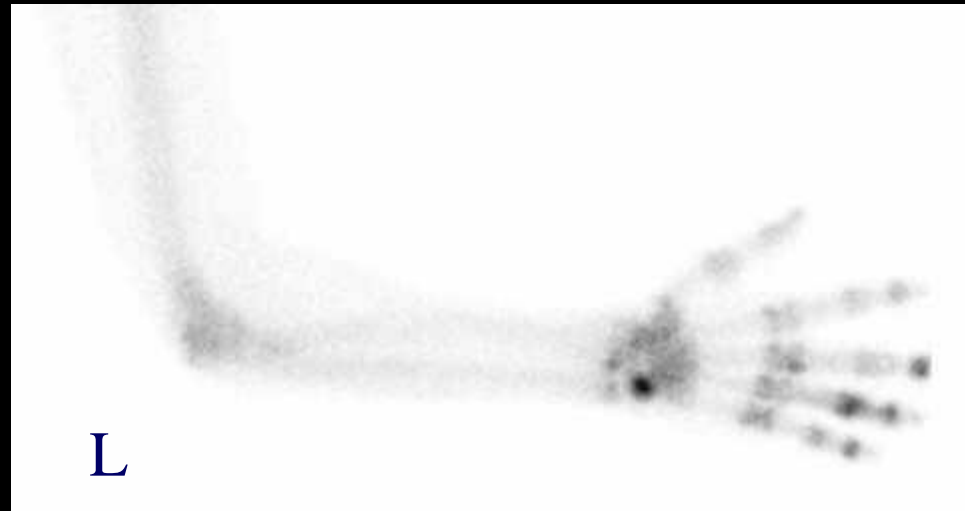
early



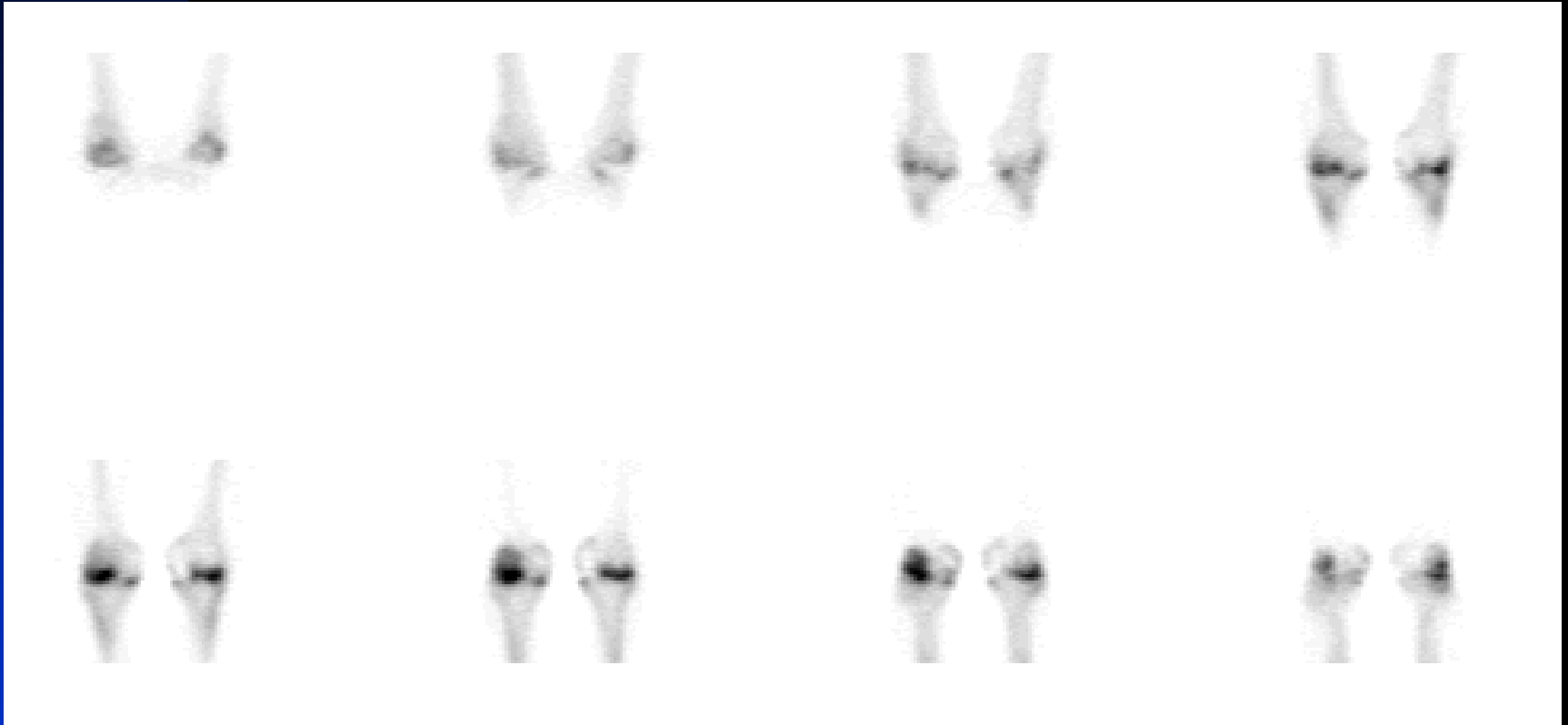delayed



L



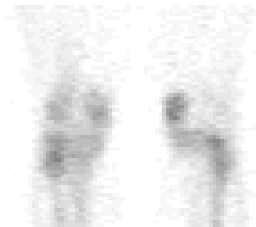
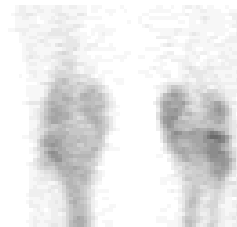
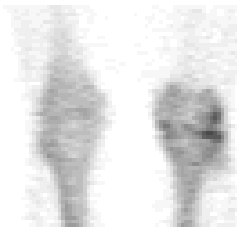
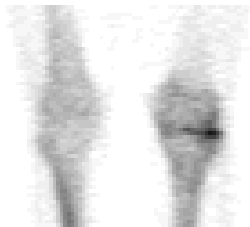
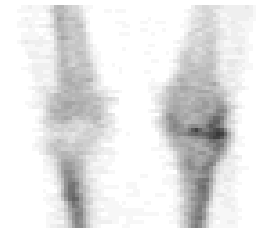
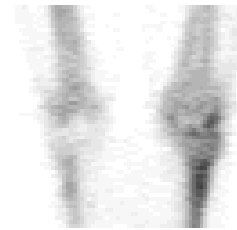
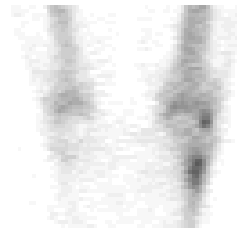
Bone Scintigraphy Osteoarthritis



SPECT : better delineation of anatomic compartments

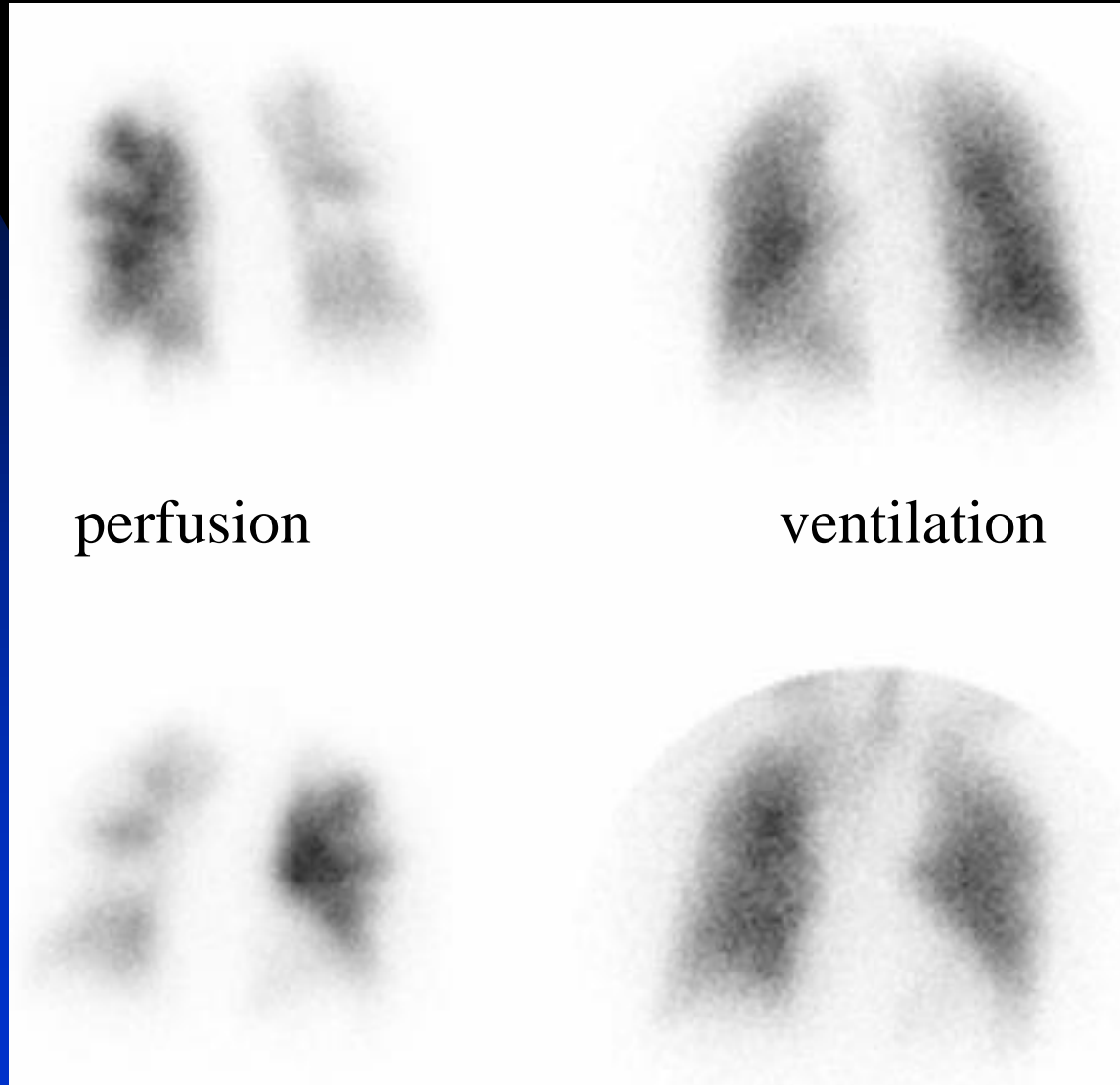
Bone Scintigraphy

Osteoarthritis: normal X-rays



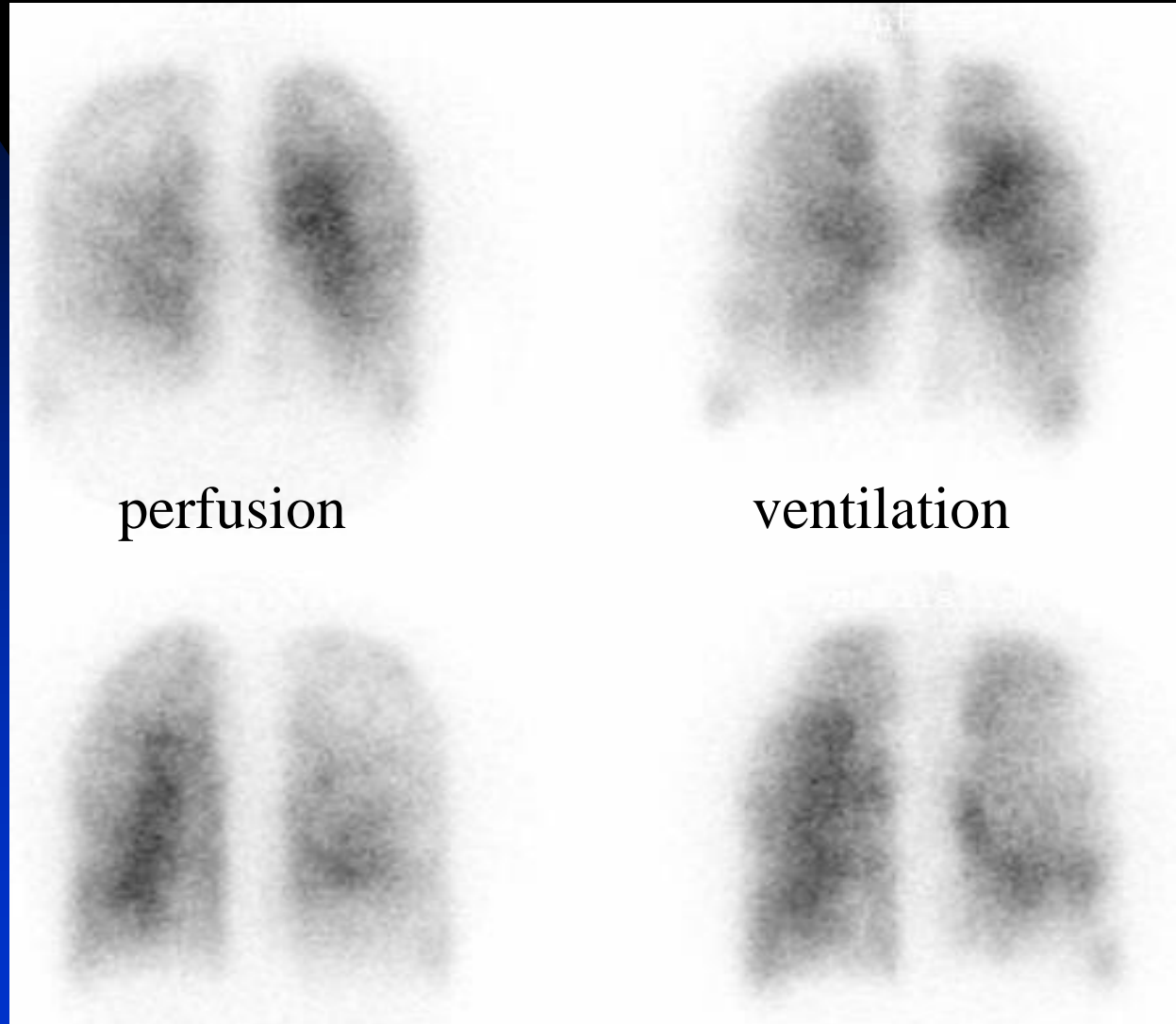
Lung Scintigraphy (V°/Q°)

Pulmonary embolism



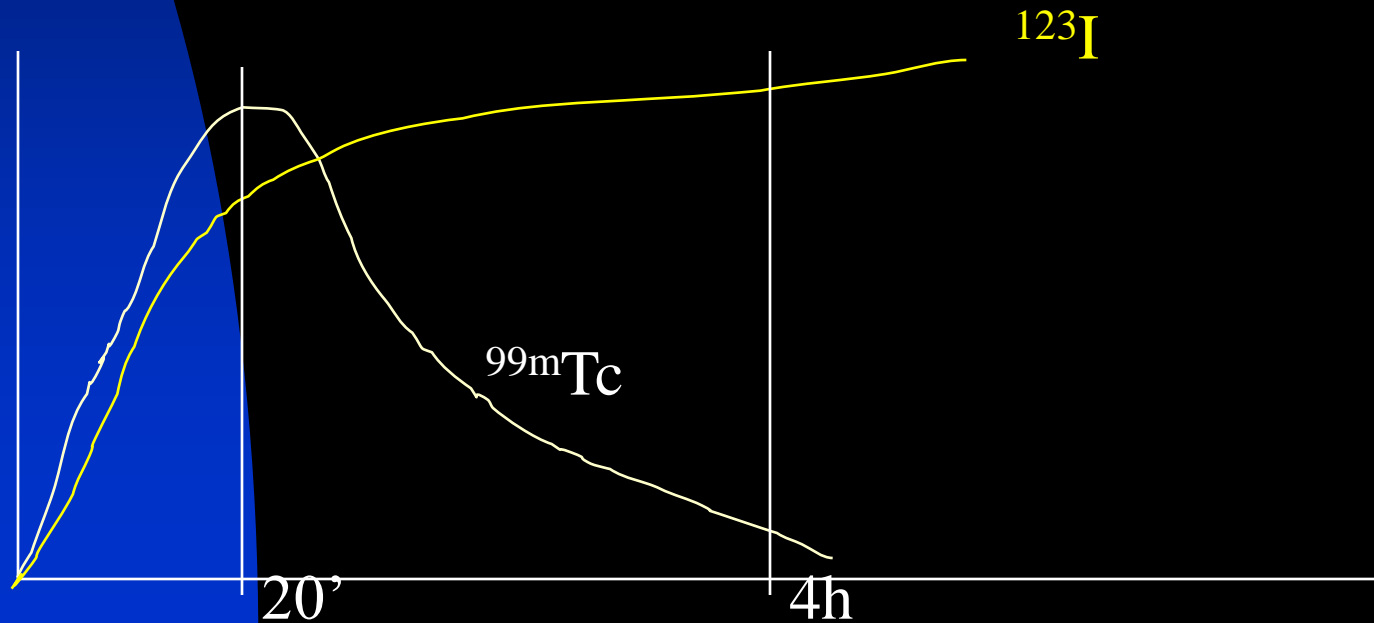
Lung Scintigraphy

Emphysema




Thyroid scanning

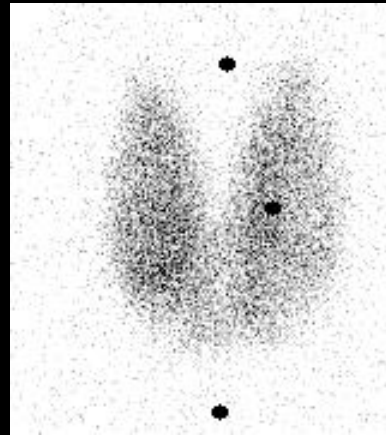
- Tracers : ^{99m}Tc or ^{123}I
 - ◆ ^{99m}Tc & ^{123}I are both taken up
 - ◆ ^{123}I only is organified




Thyroid Scintigraphy



normal



goiter (diffuse)



goiter (multi-
nodular)

Dynamic function

Ex: gastric emptying

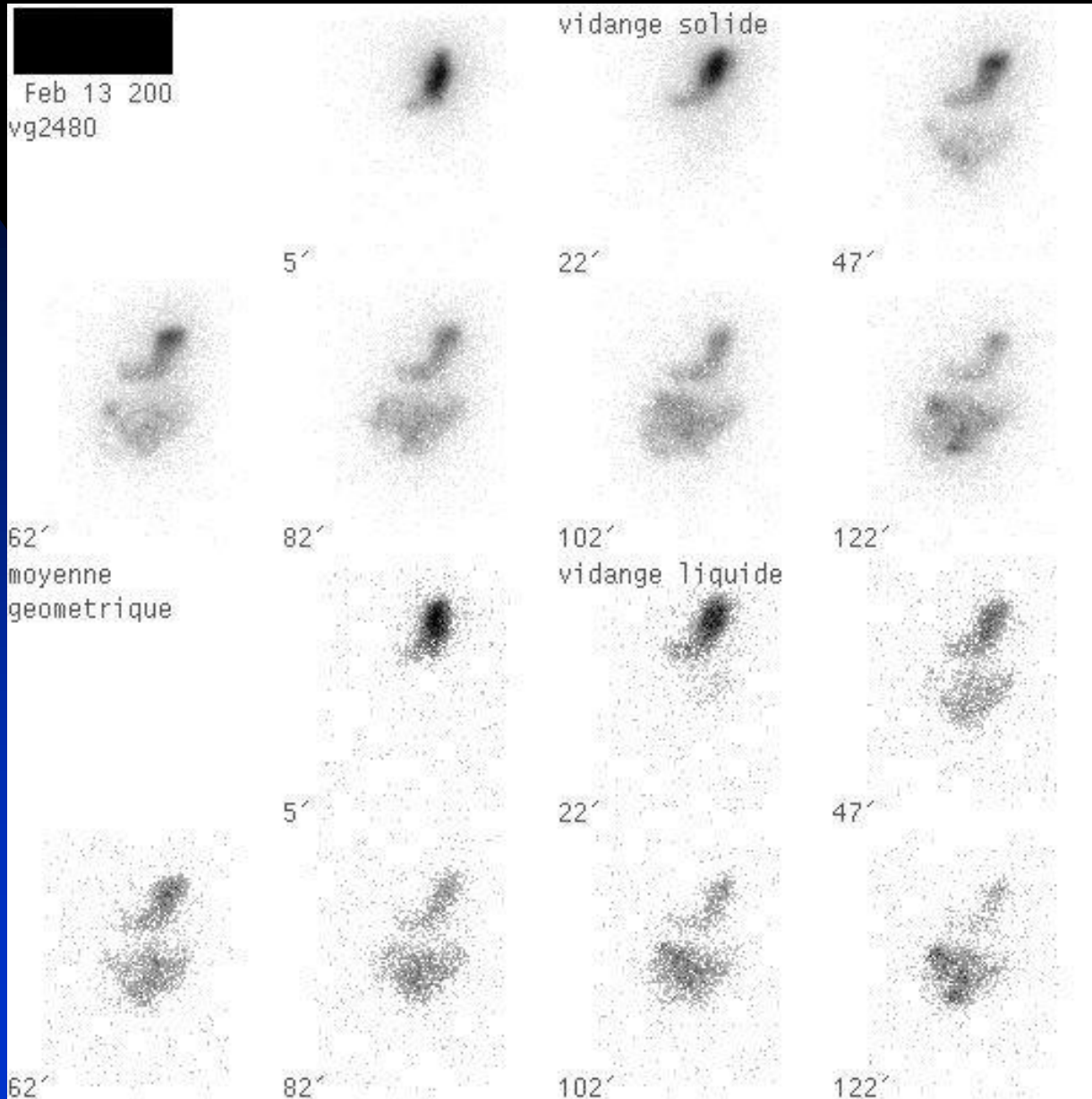
Eggs-bread + ^{99m}Tc

Water + ^{111}In

2h-imaging and quantification

Dyspepsia

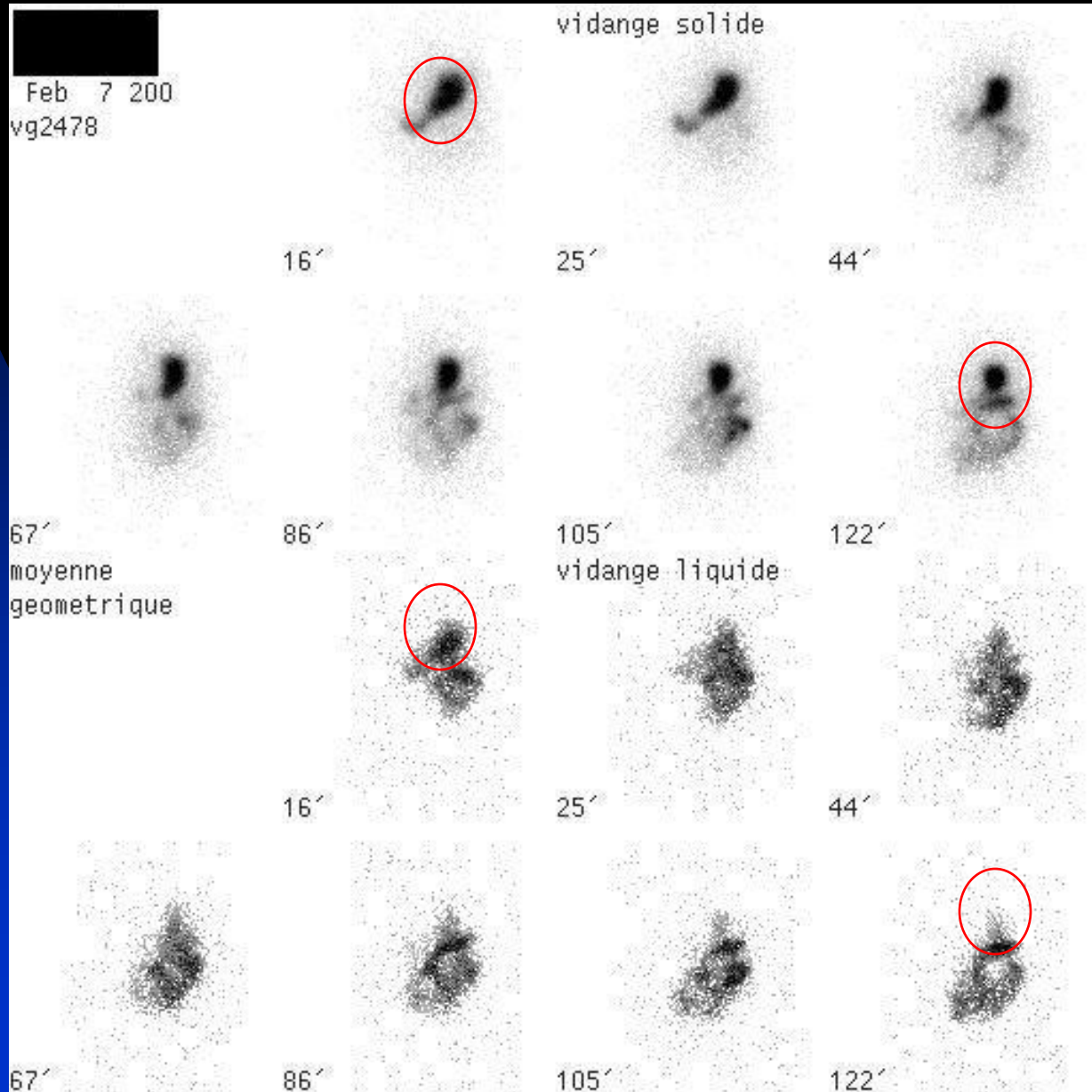
Gastric emptying



Delayed gastric emptying: diabetes mellitus

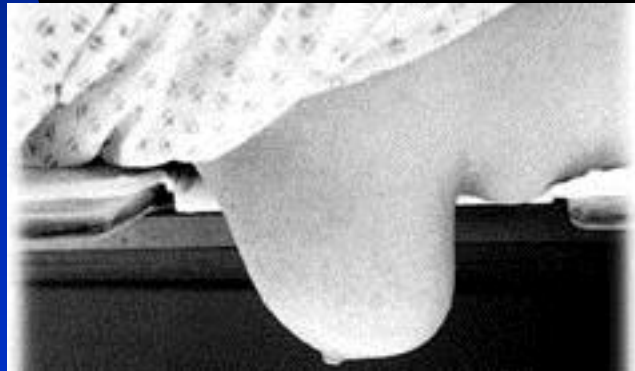T1/2 fluids :
40 minutes

T1/2 solids :
140 minutes



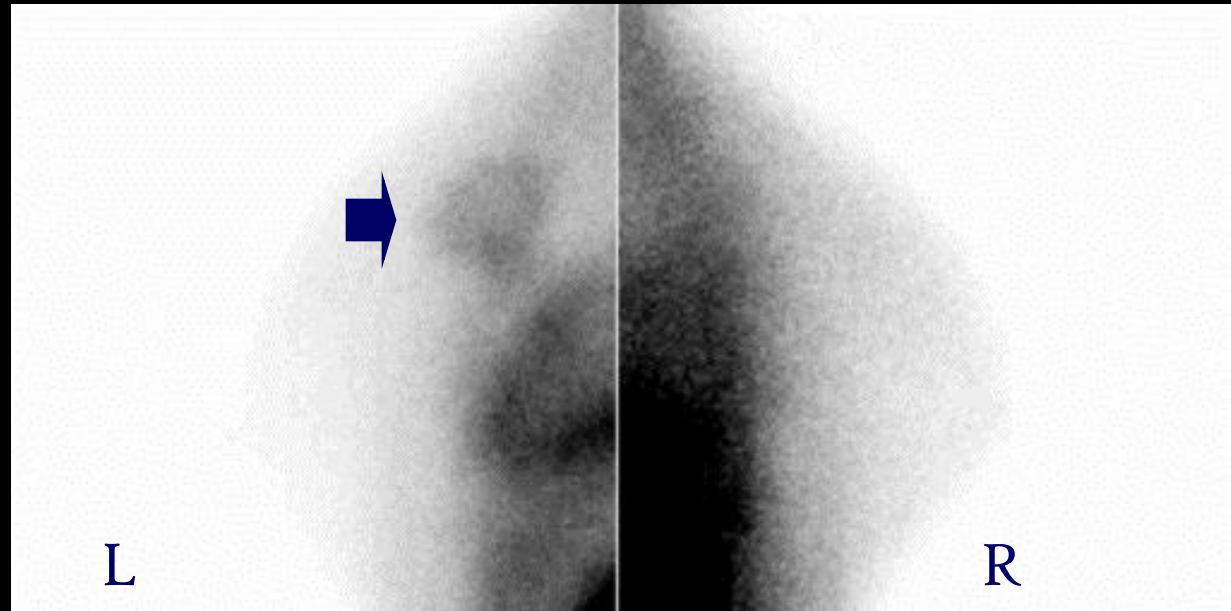
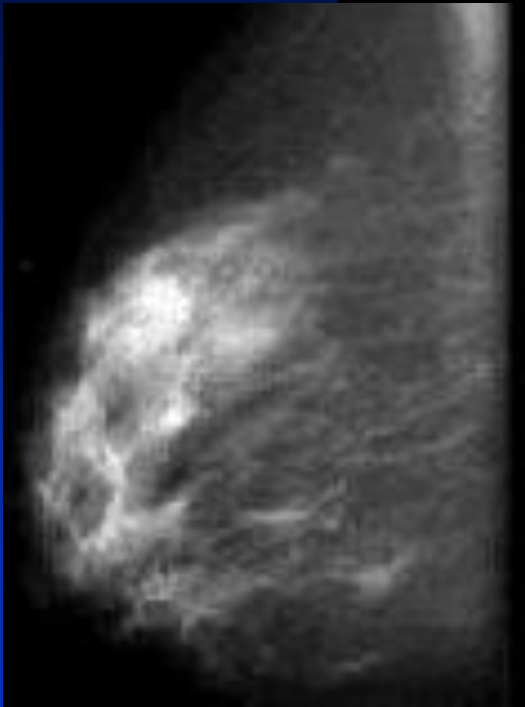
Scintimammogram

- Principe : les tumeurs malignes ont un flux plus importants que les lésions bénignes
- Avantage : pas de problème d'interprétation lié au type de sein analysé (fibrose)
- Réalisation pratique
 - ◆ injection de 20 mCi de ^{99m}Tc -MIBI dans la veine du bras controlatéral à la lésion (ou pied)
 - ◆ images après 10 minutes
 - ◆ vues planaires de profil, decubitus ventral, coussin spécial

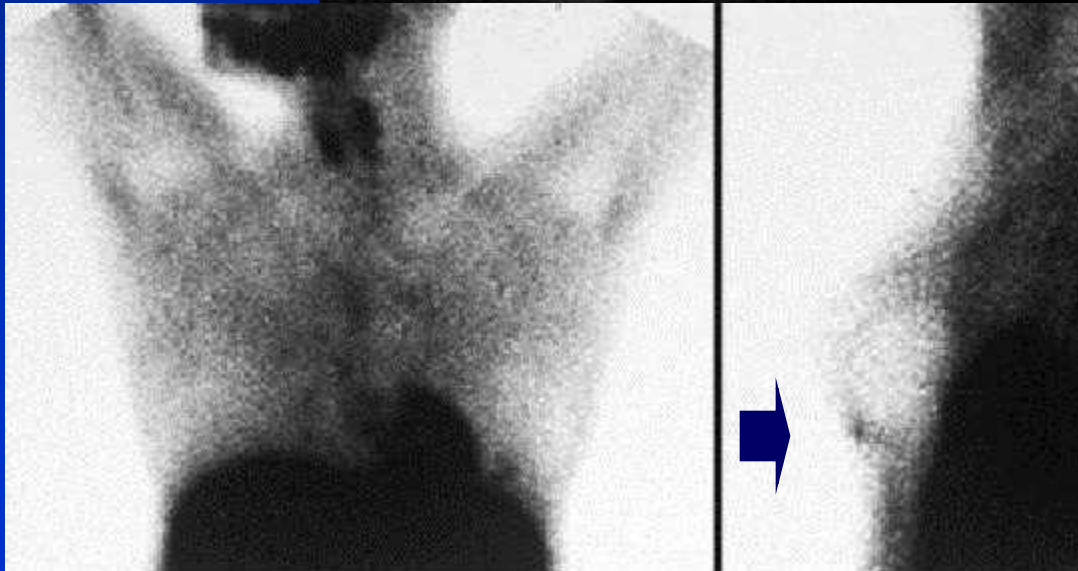
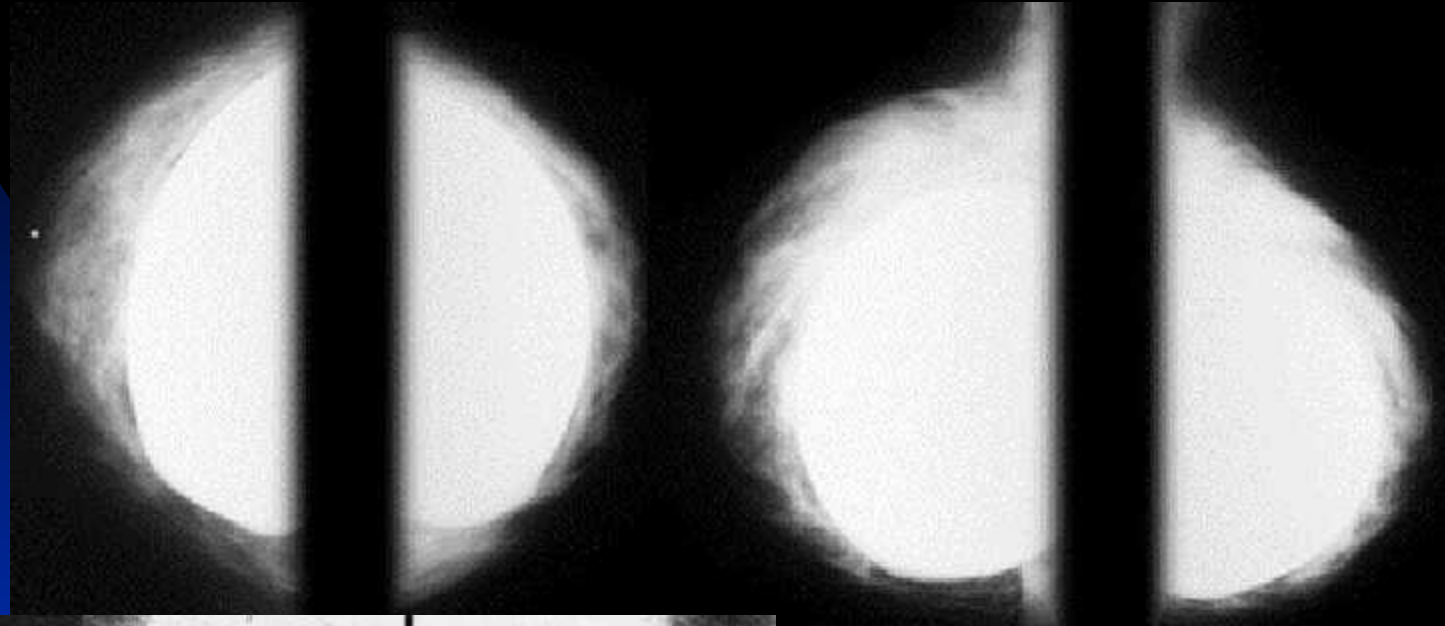


- ◆ vue planaire de face, bras relevés (creux axillaire)
- ◆ tomographie (decubitus dorsal) + reconstruction itérative

Scintimammogram

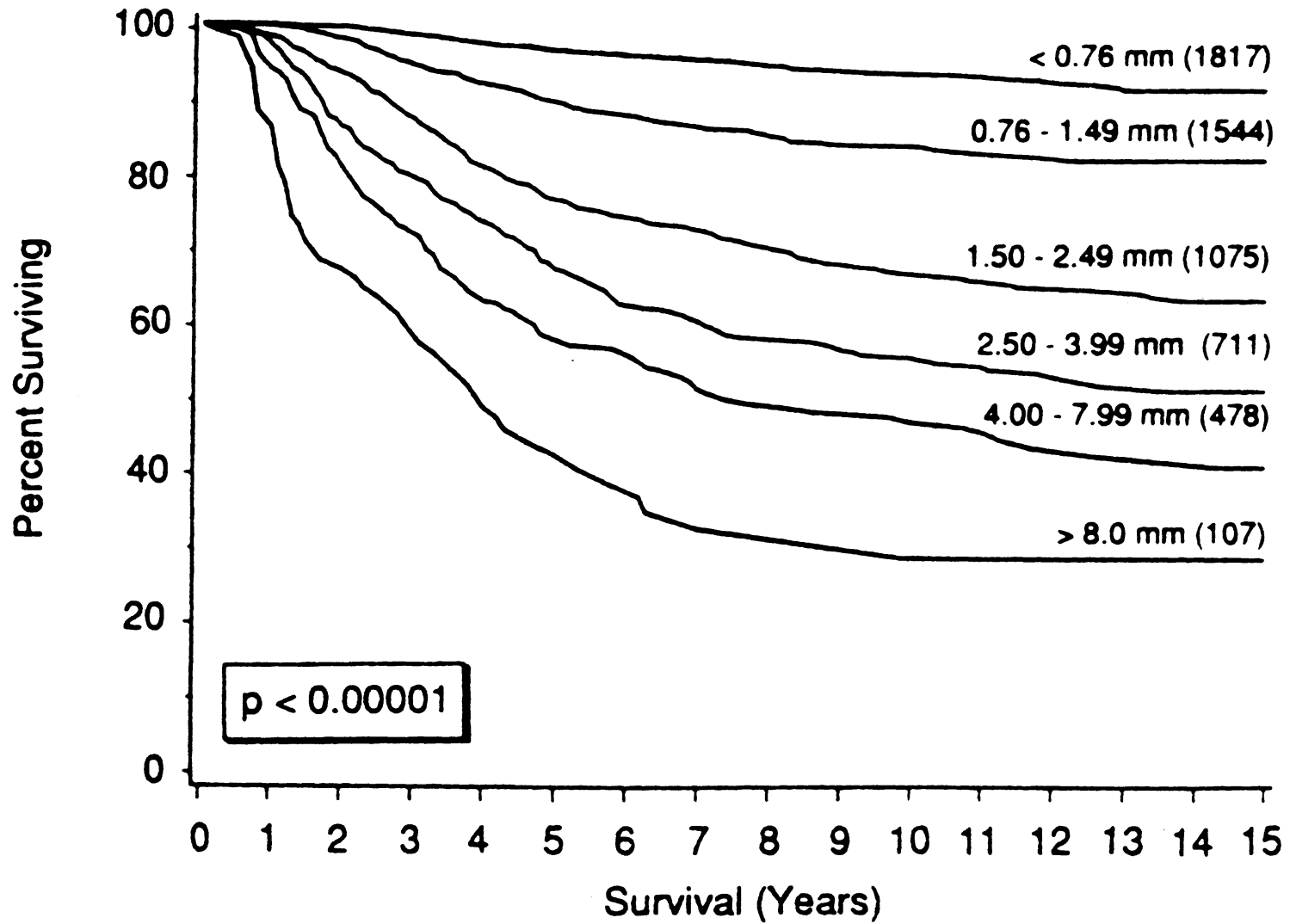


Scintimammogram Implants



Sentinel Node

Ex: malignant melanoma



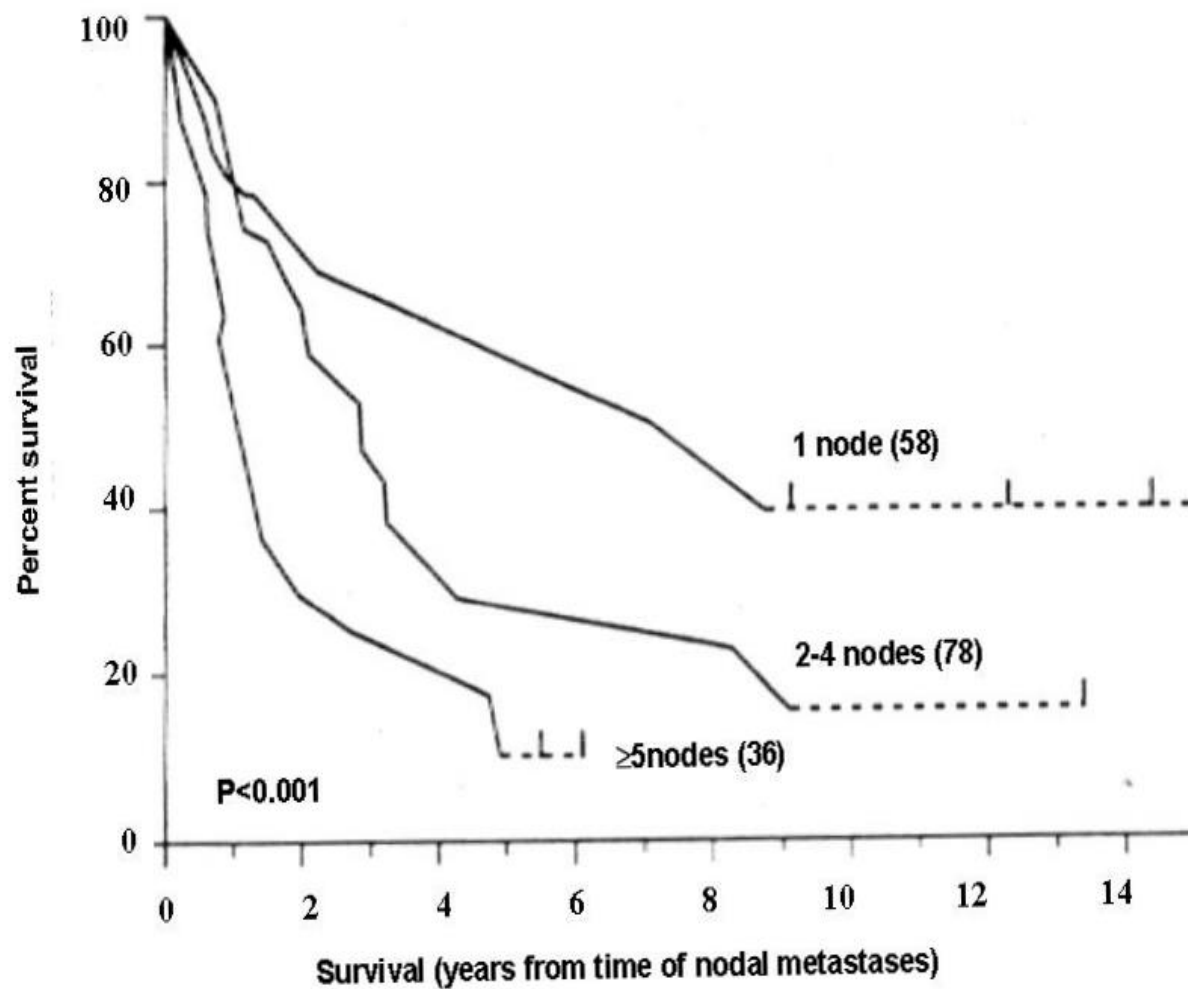


Figure 1. Correlation between survival and number of positive lymph nodes. Reprinted with permission from *Ann Surg*, 1981 [1].

INTRODUCTION

Treatment of cN0 melanoma:

1) primary resection

2) lymphadenectomy only effective if N+ (5-yr survival 13 to 45%)

⇒ Interest for detection of nodal micro-metastases

⇒ Improved survival in N+ if adjuvant therapy given

Sentinel Node

Modes of lymphatic drainage

2nd level

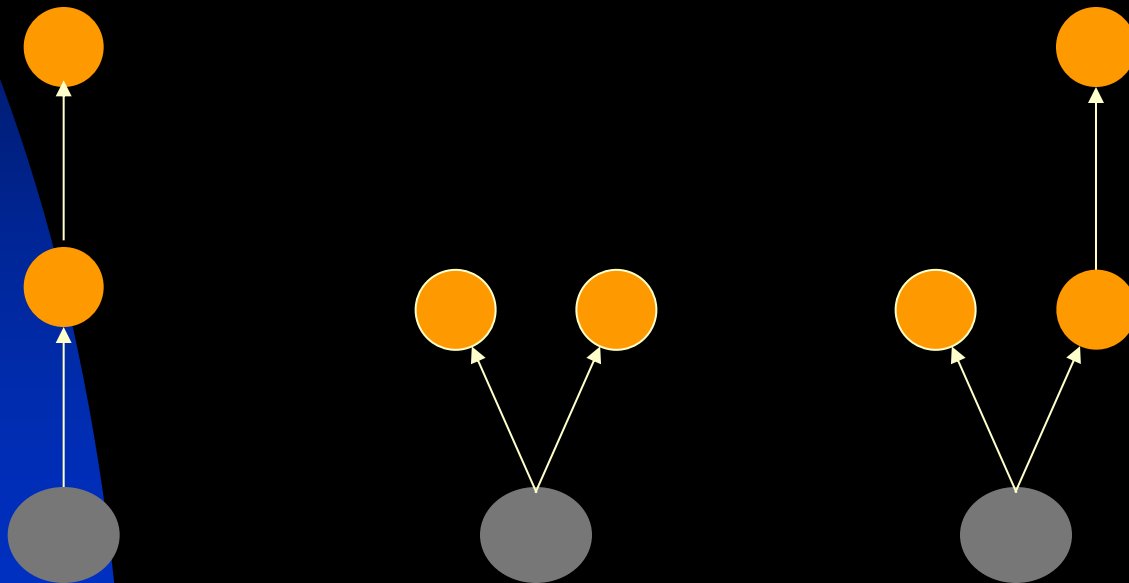
1st level

Lesion

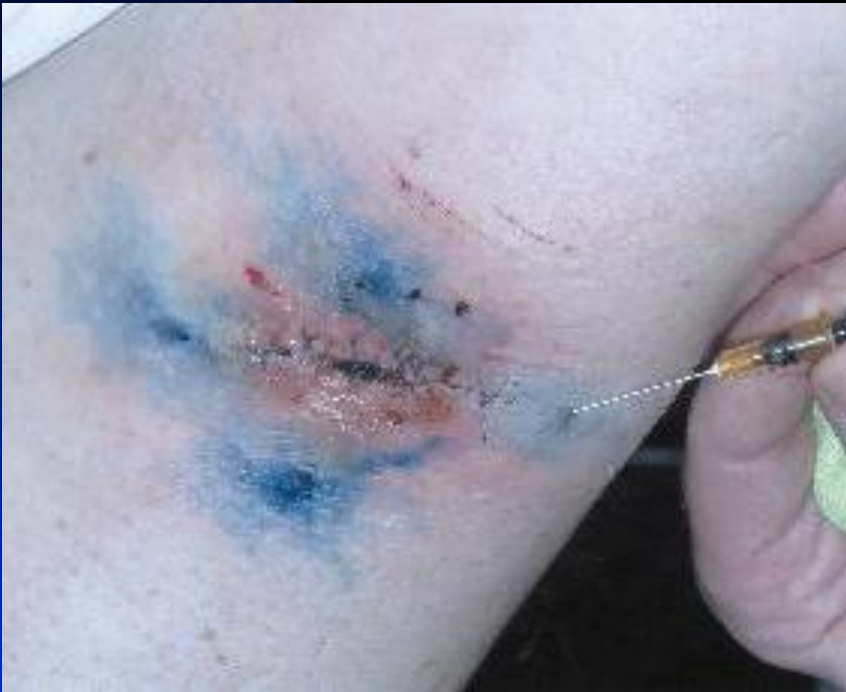Serial

Parallel

Mixed



Lymphoscintigraphy Practically

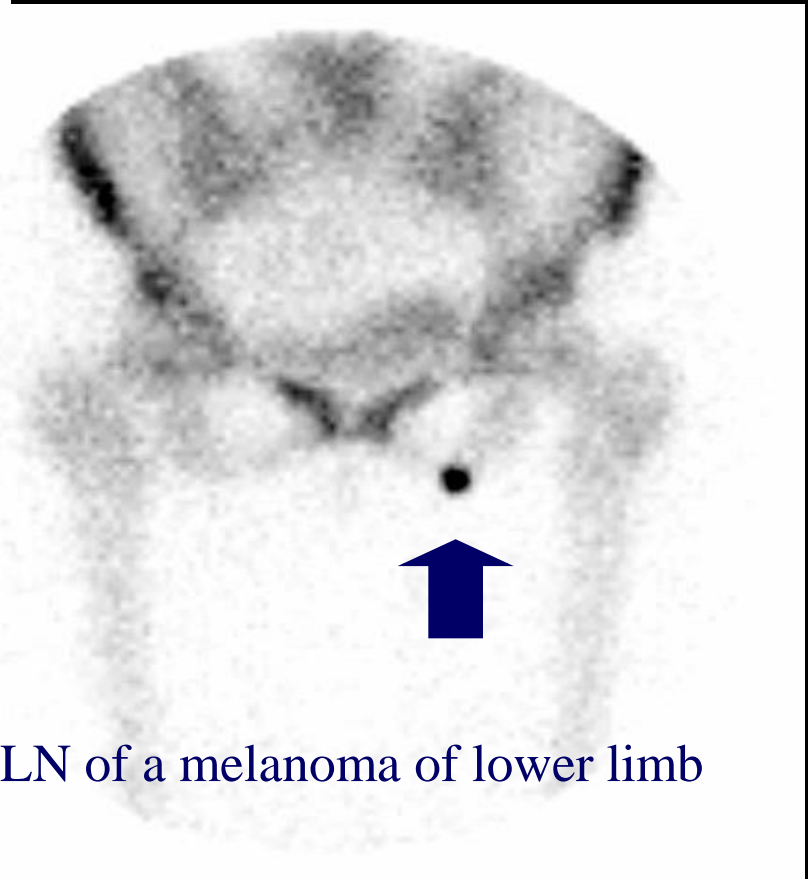
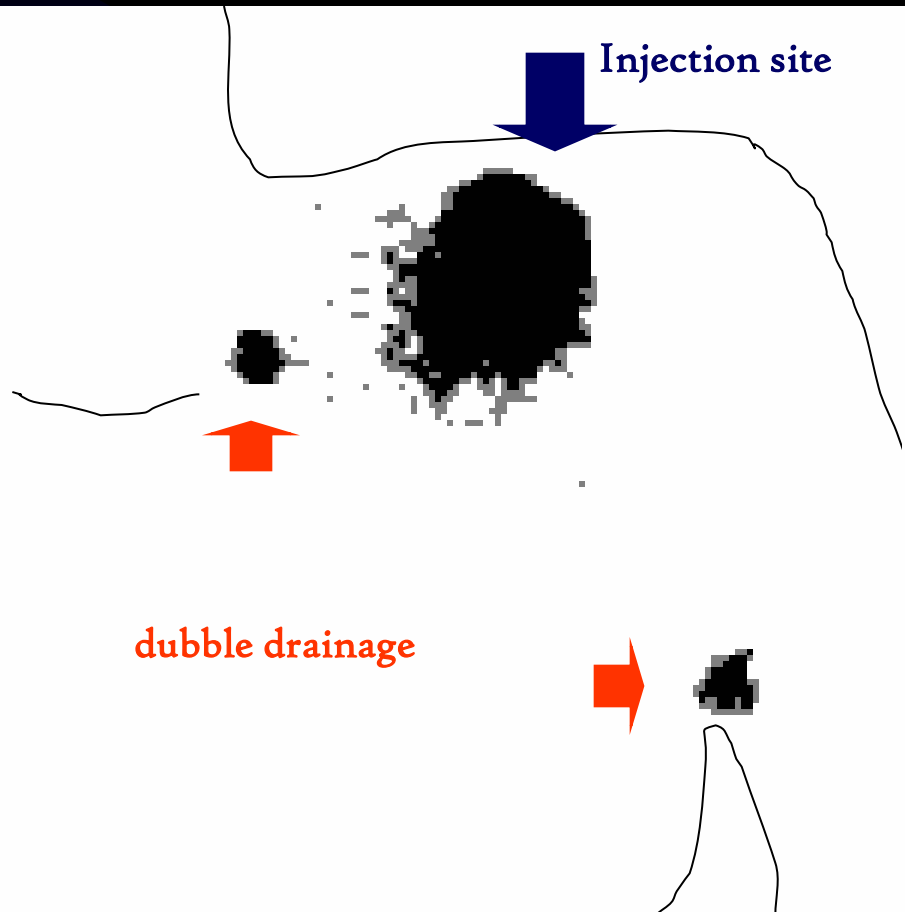


intradermal injection



Tracer migration

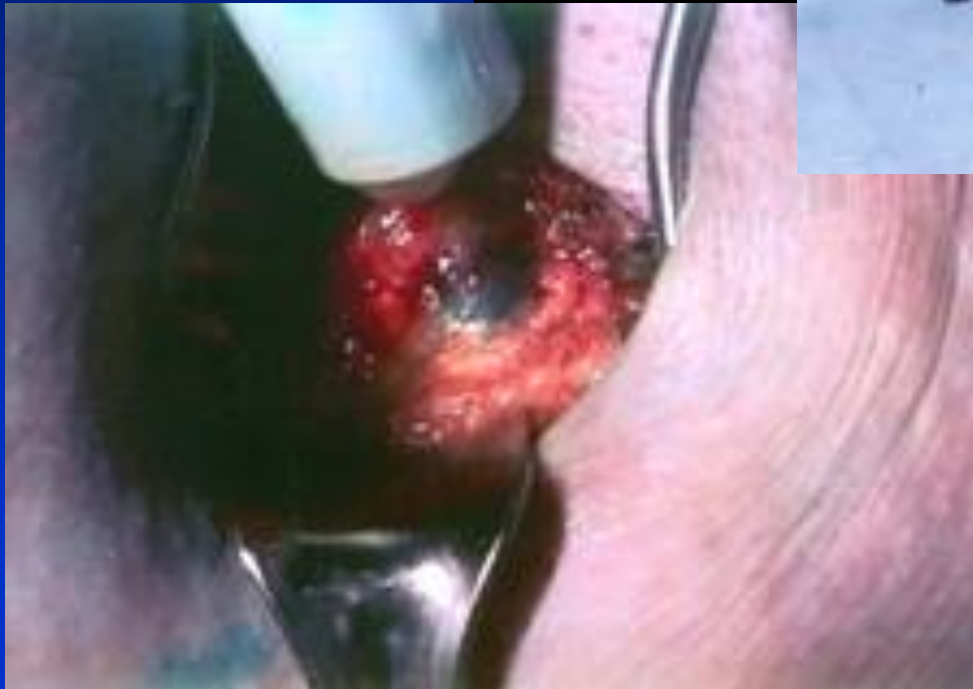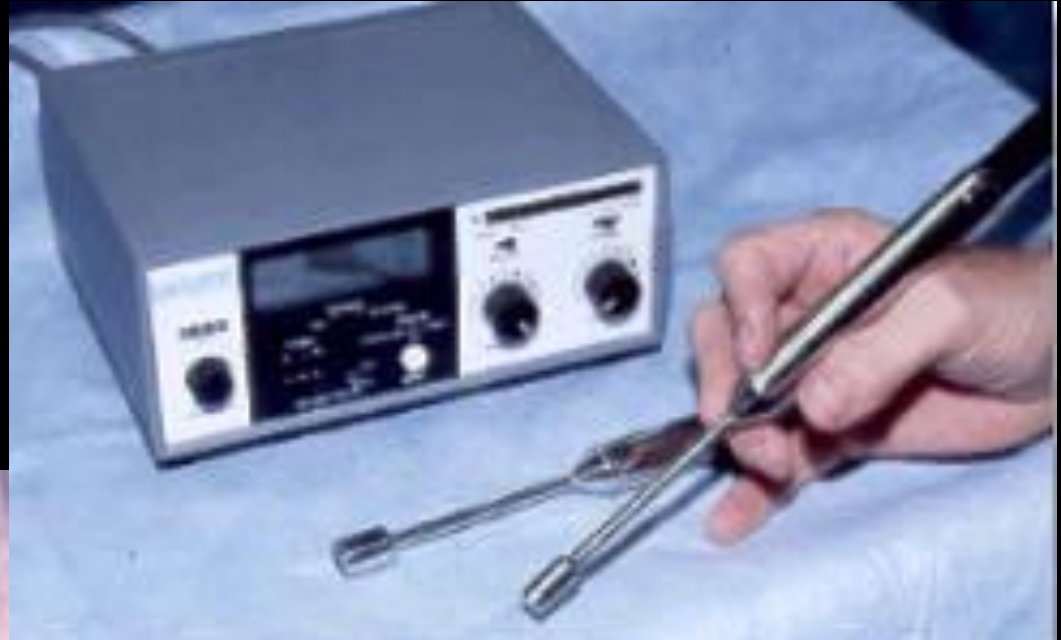Lymphoscintigraphy



SLN of a melanoma of lower limb

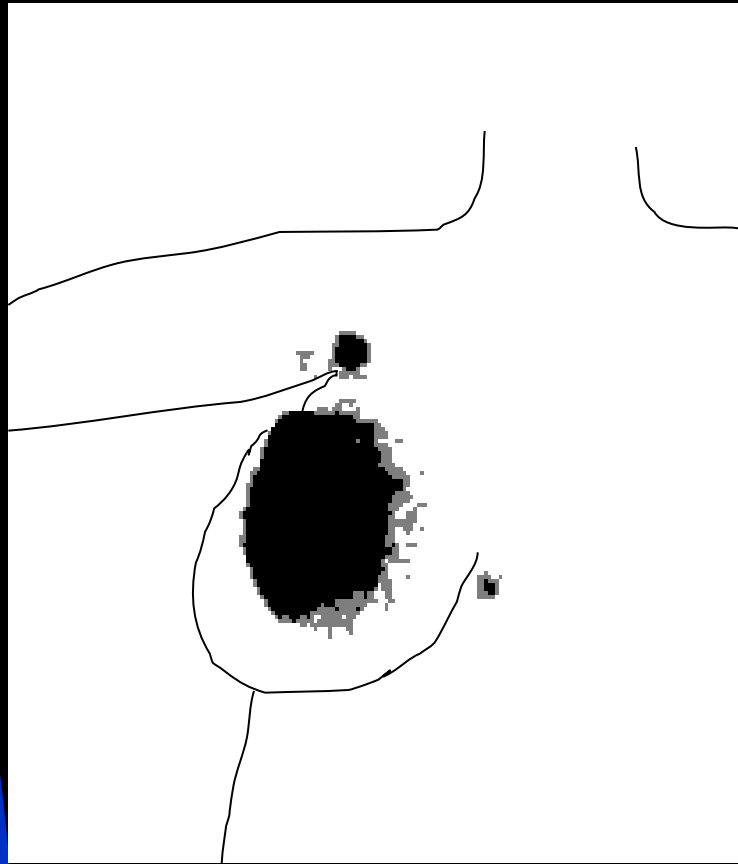
Ganglion sentinelle

Peroperative Detection



Sentinel Node

SEQ Tumor of right breast



Use of labelled cells

Platelet survival test

Usefulness:

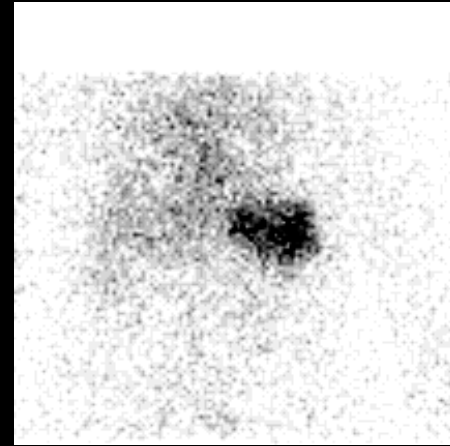
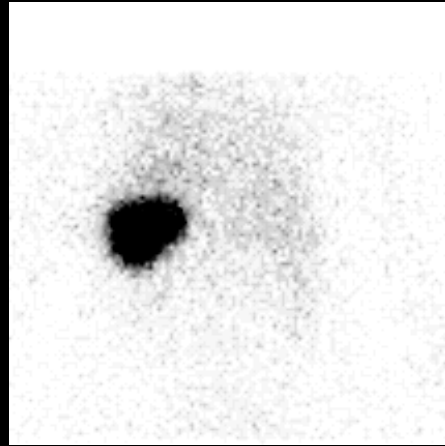
Site of destruction

Evaluate survival

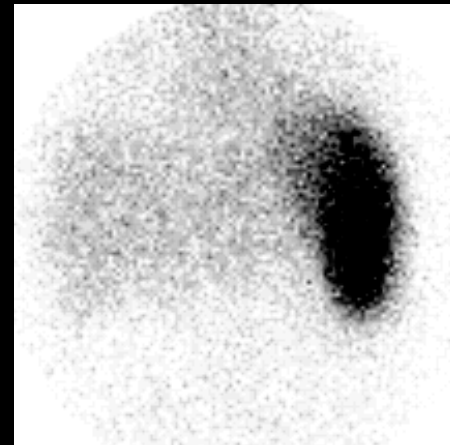
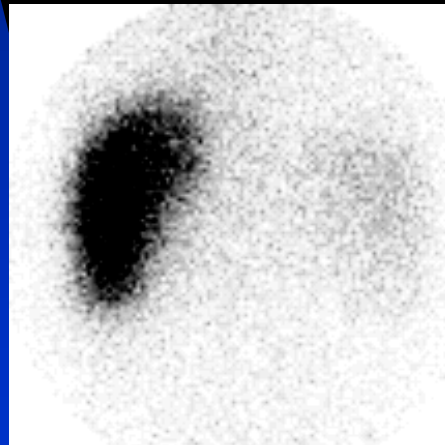
Evaluate spleen pooling

In-111-platelets: ITP

Case 1



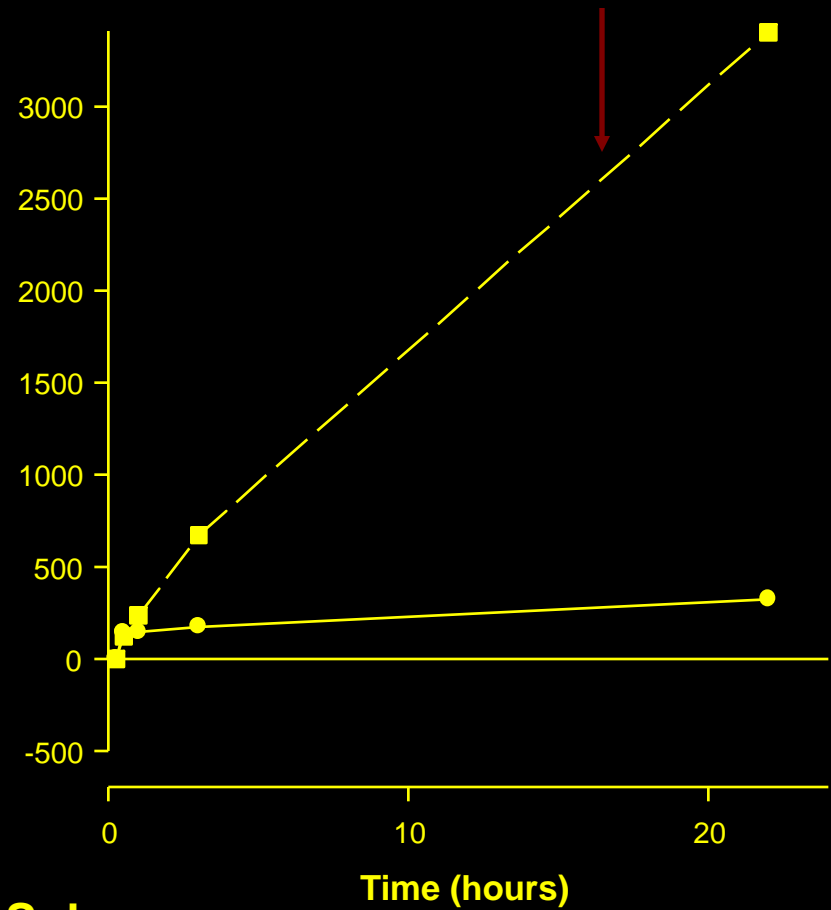
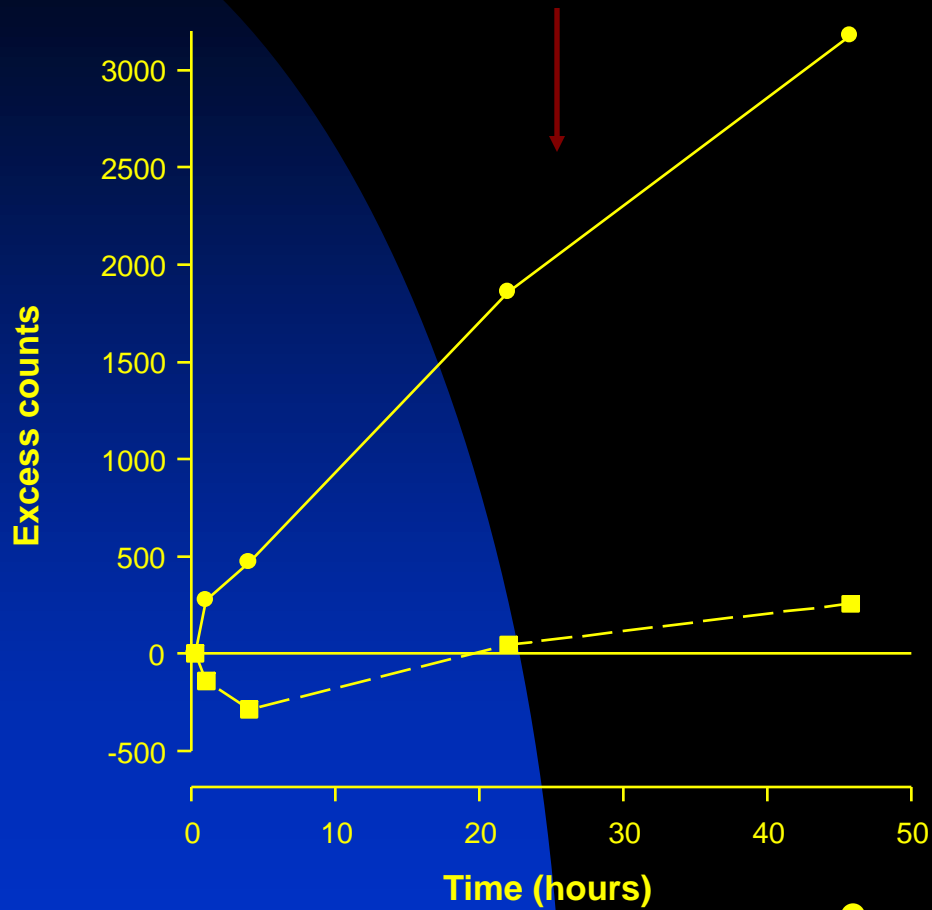
Case 2



In-111-platelets

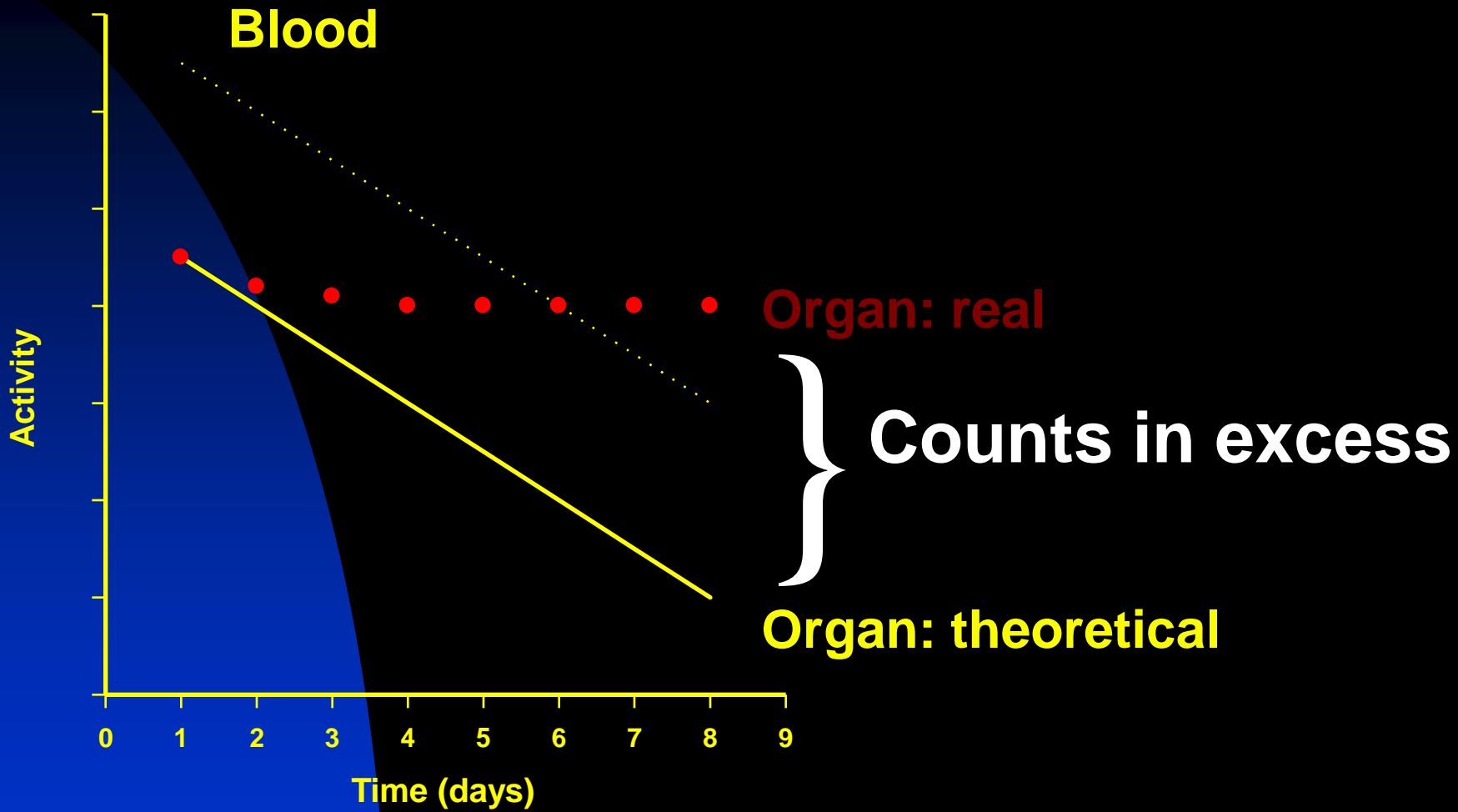
Case 1

Case 2

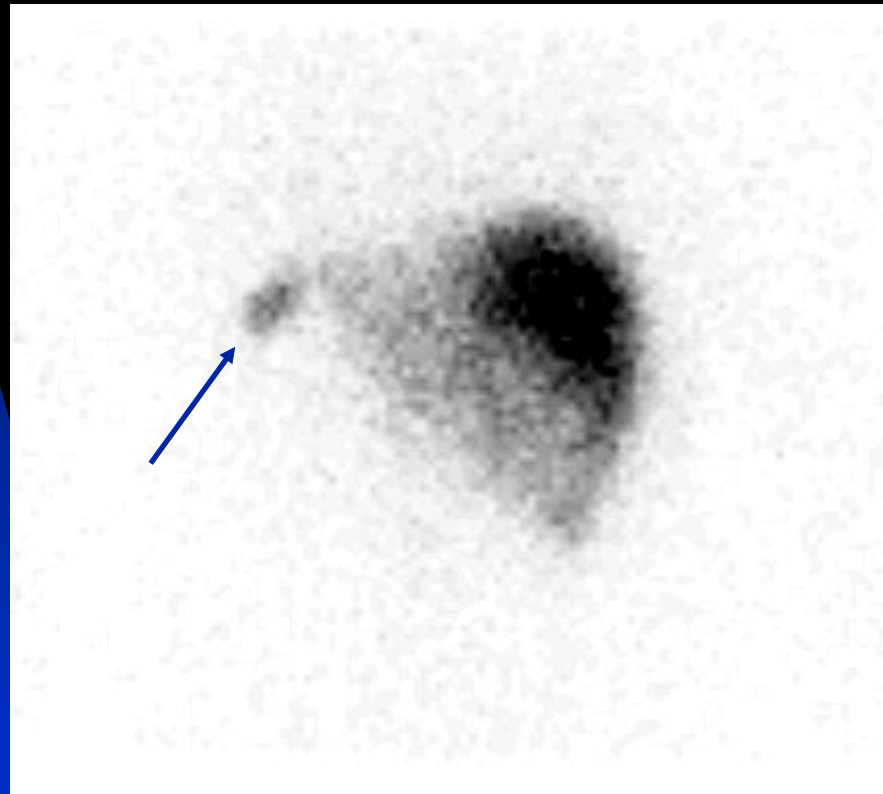


● Spleen

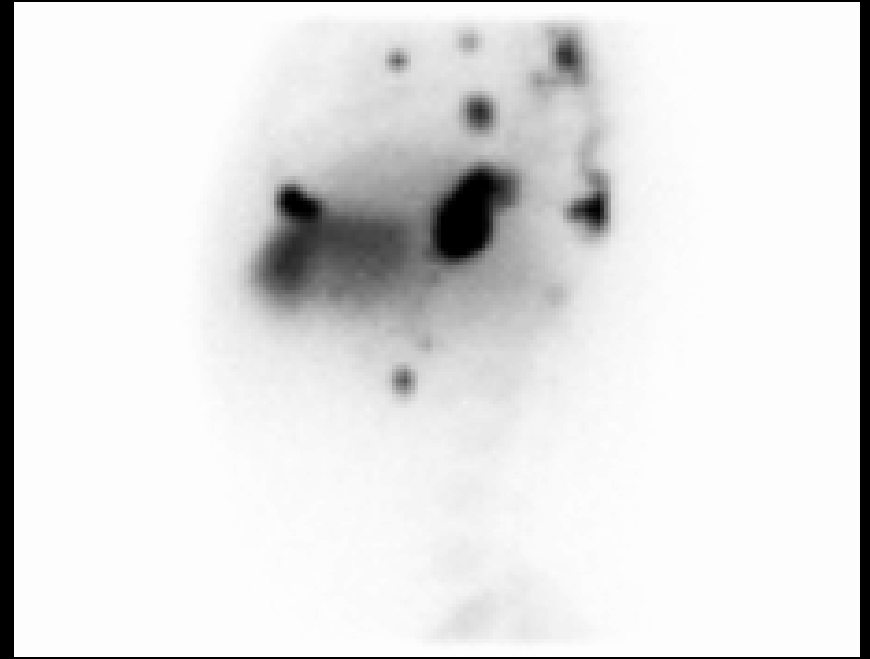
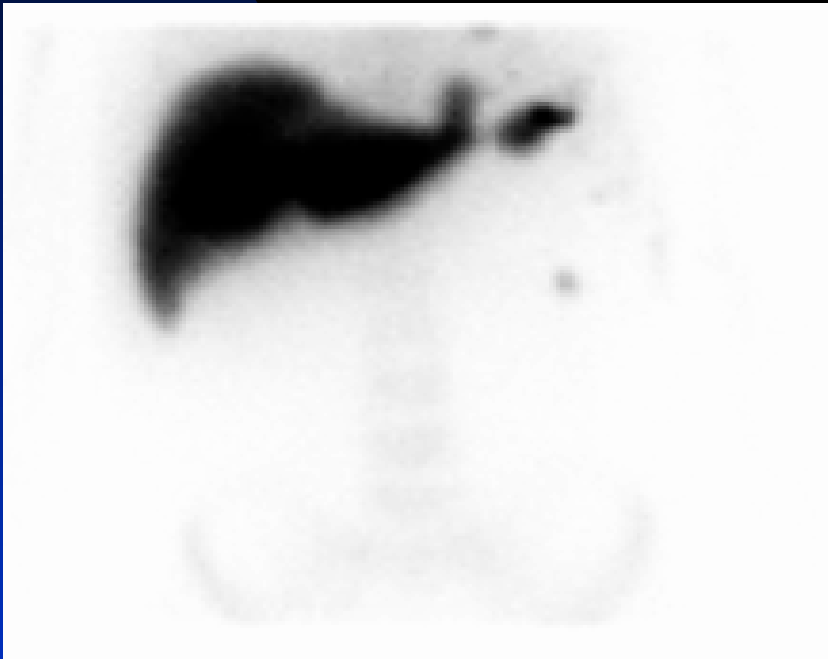
■ Liver



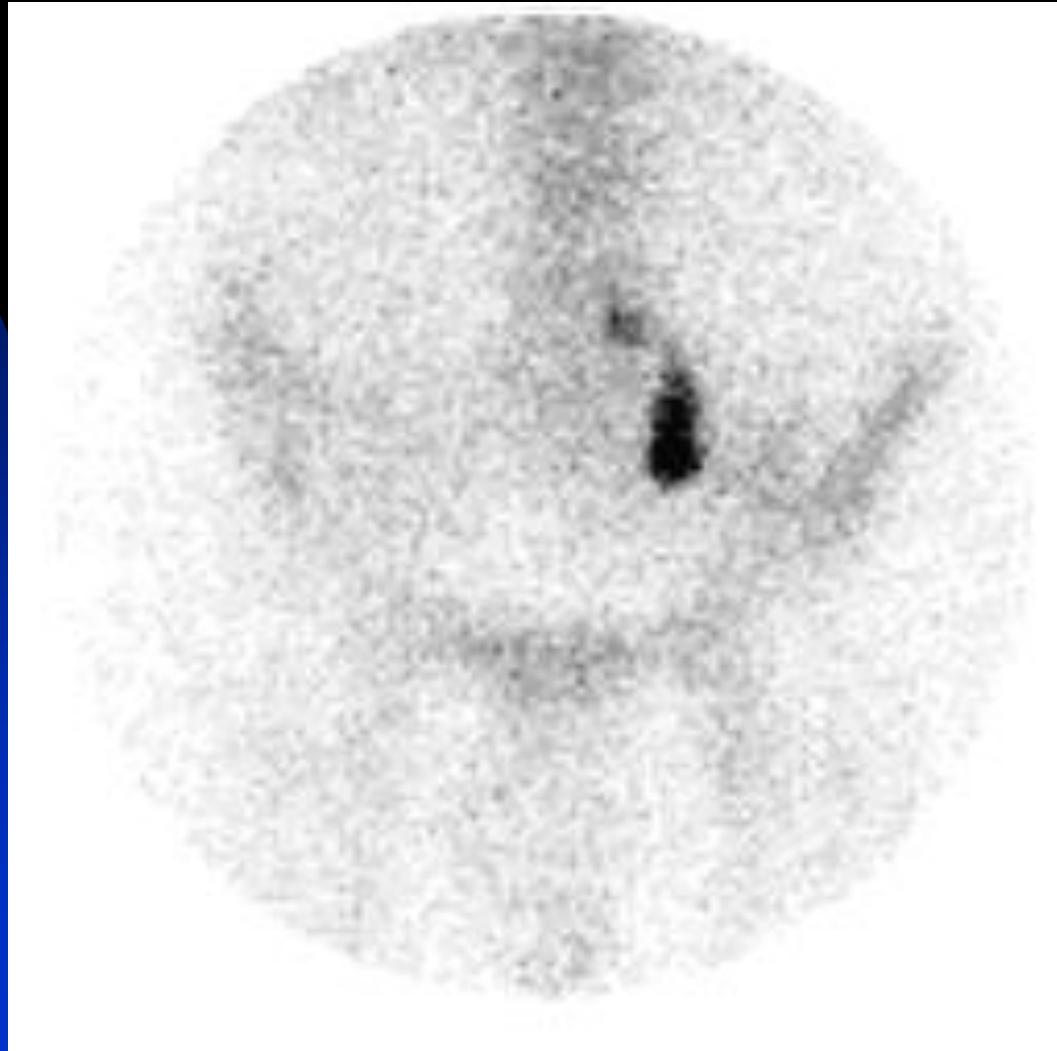
In-111-platelets: ITP residual spleen



^{99m}Tc -HDRBCs and spleen remnants

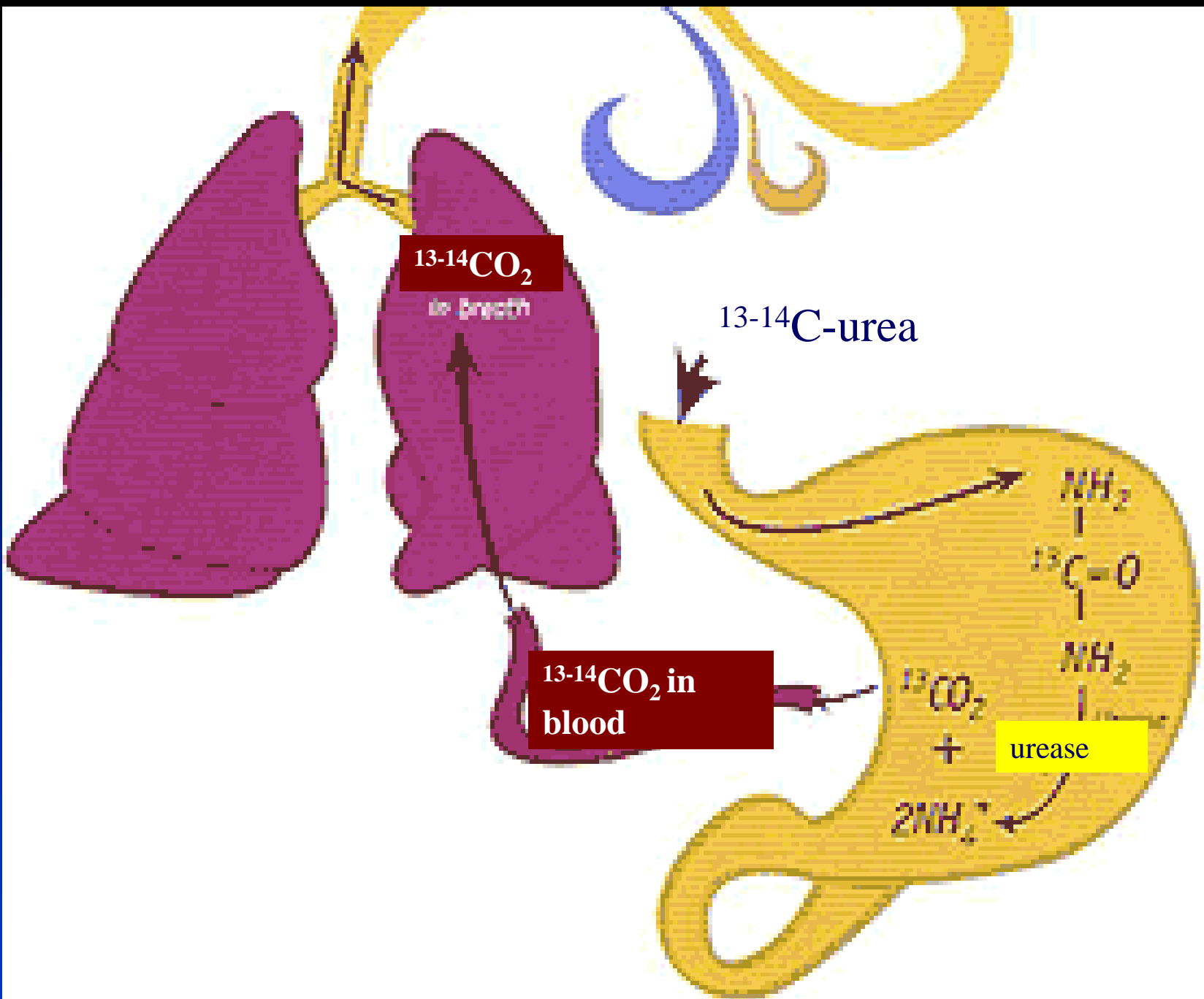


^{111}In -WBC scintigraphy: search for abscess



Breath tests

- General Principle: to assess a metabolic function through the measurement of exhaled labelled CO₂ (C¹³ or C¹⁴)
- Normal or pathological function (proportionality)
 - ◆ Enzymatic function must be present: ex: aminopyrine
 - ◆ Enzymatic activity denotes disease ex: urea



$^{13}\text{-}^{14}\text{CO}_2$

in breath

$^{13}\text{-}^{14}\text{C}$ -urea

$^{13}\text{-}^{14}\text{CO}_2$ in blood



+

urease



+