



15 / 16 janvier 2021

21<sup>e</sup> MISES AU POINT EN  
IMAGERIE OSTÉO-ARTICULAIRE  
en visio...

# Atelier

## « Vendredi, 18h30 »

Bruno Vande Berg et l'équipe de St Luc



Cliniques universitaires

**SAINT-LUC**

UCL

BRUSSELS

# IRM, le vendredi 18h30

- Je
  - suis fatigué
  - pense à demain
- Les collègues
  - sont partis
- Le malade
  - arrive
- Le clinicien
  - j'en fais quoi ? je le mets où ?



*Préviens moi quand t'auras fini ! Je rentre !*

# Gammes diagnostiques

---

## En semaine

- Traumatique
- Tumoral
- Métabolique
- Malformatif
- Septique
- Inflammatoire / AI
- Dégénératif
- Vasculaire
- ....

## En garde

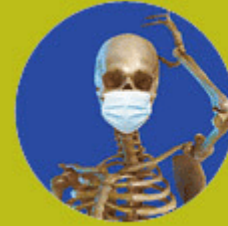- Septique
- Vasculaire
- Traumatique
- Tumoral
- Inflammatoire  
(calcification..)

# EXCLURE

---

- Discite
- ~~Arthrite~~
- ~~Fasciite~~





15 / 16 janvier 2021

21<sup>e</sup> MISES AU POINT EN  
IMAGERIE OSTÉO-ARTICULAIRE  
en visio...

Mme L., 76 ans

Diabète; Post-op valve cardiaque

Pic fièvre à 39° et frisson

Septicémie à staphylo doré

J2 : Augmentation CRP

J3 : apparition lombalgies

J5 : **Exclure discite !**

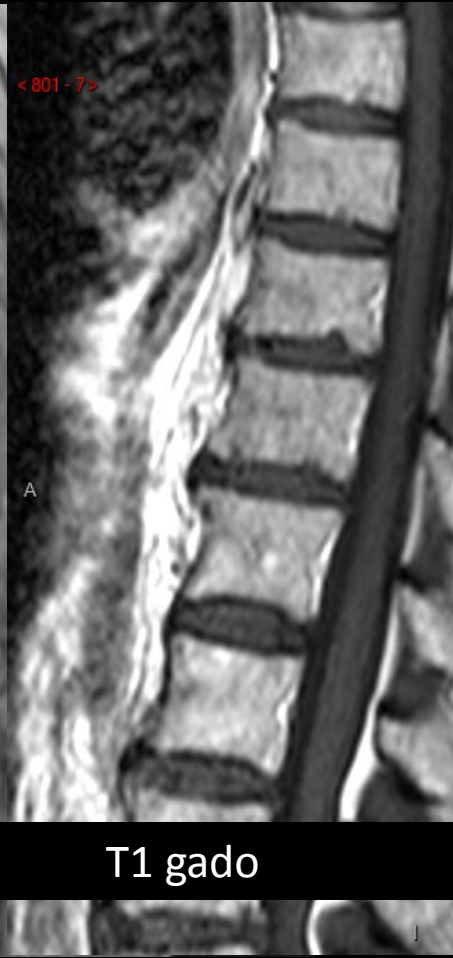
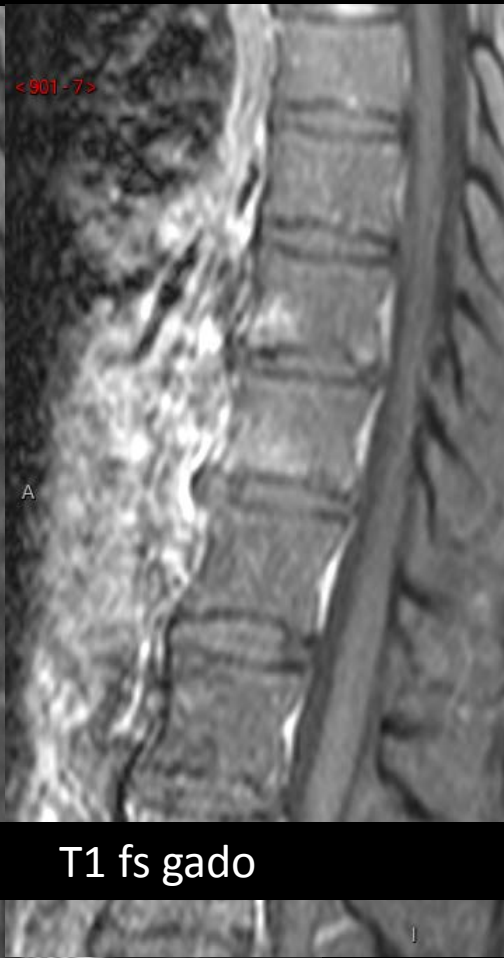
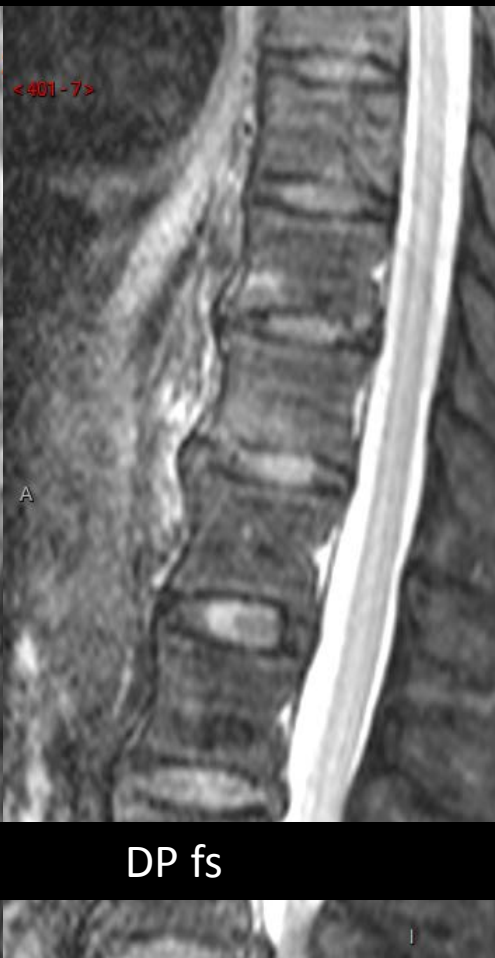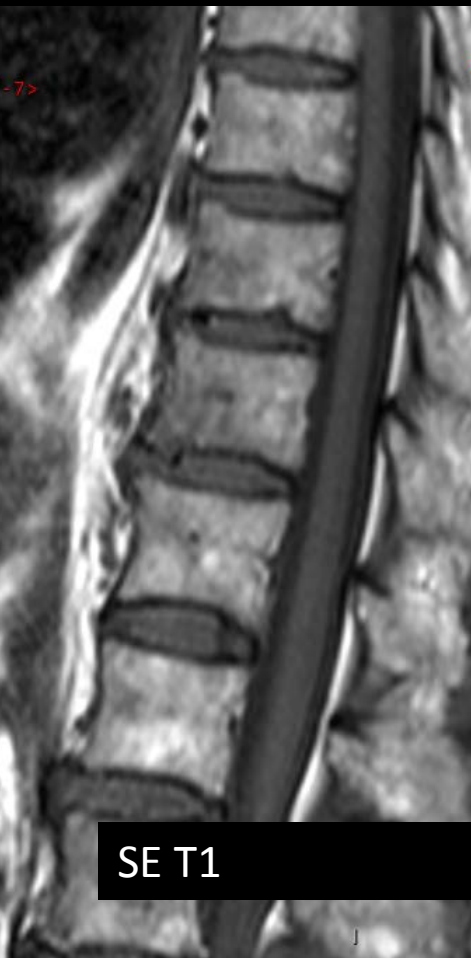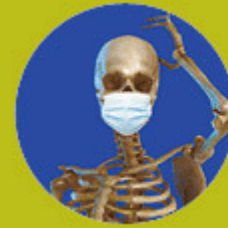Cliniques universitaires

**SAINT-LUC**

UCL

BRUSSELS





15 / 16 janvier 2021

21<sup>e</sup> MISES AU POINT EN  
IMAGERIE OSTÉO-ARTICULAIRE  
en visio...

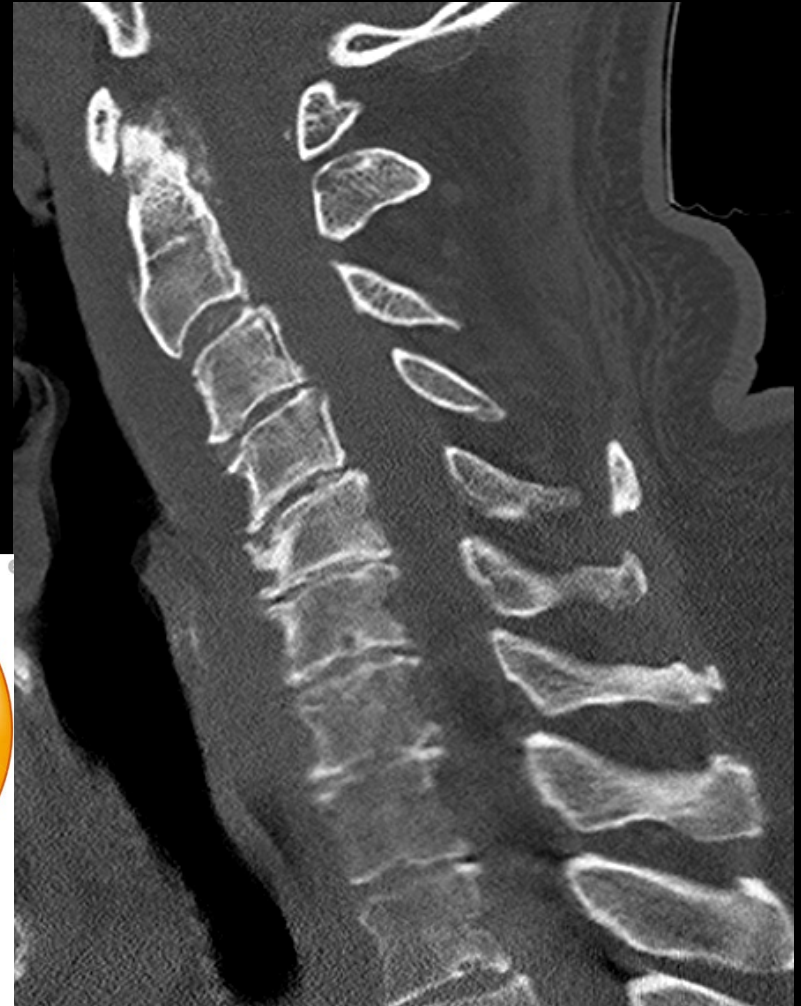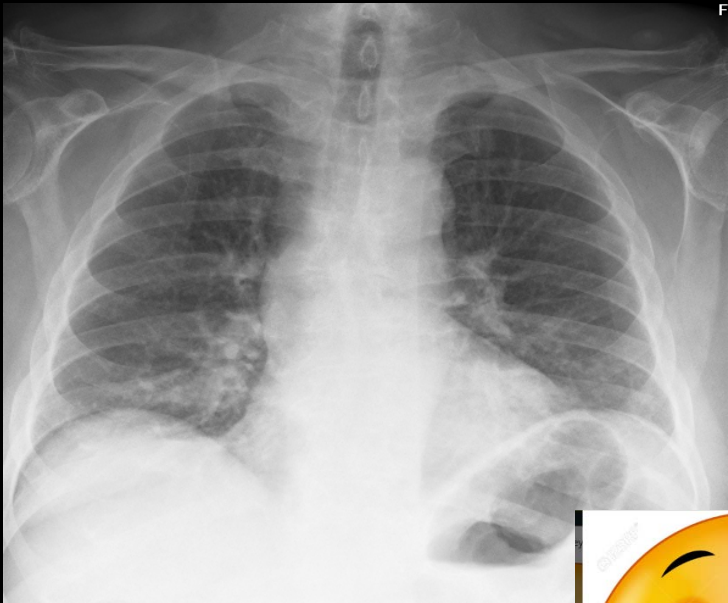
Mr V. 61 ans , grossiste en boules de Noël  
Diabète, HTA, mal perforant plantaire  
1déc. : cervicalgie; kiné « remet deux vertèbres »  
Apparition paresthésies des 2 mb sup  
19 déc. : parésie des mains  
CT cérébral et C. cerv. :



Cliniques universitaires  
**SAINT-LUC**  
UCL BRUSSELS

# Paraplégie flasque – infection ?

---







15 / 16 janvier 2021

21<sup>e</sup> MISES AU POINT EN  
IMAGERIE OSTÉO-ARTICULAIRE  
en visio...

Mr V. 61 ans , grossiste en boules de Noël  
Diabète, HTA, mal perforant plantaire  
1déc. : cervicalgie; kiné « remet deux vertèbres »  
Apparition paresthésies des 2 mb sup  
19 déc. : parésie des mains  
CT cérébral et C. cerv. : non contributifs  
20 déc. : Paraplégie flasque  
Dim. 20 déc 20h : IRM



Cliniques universitaires

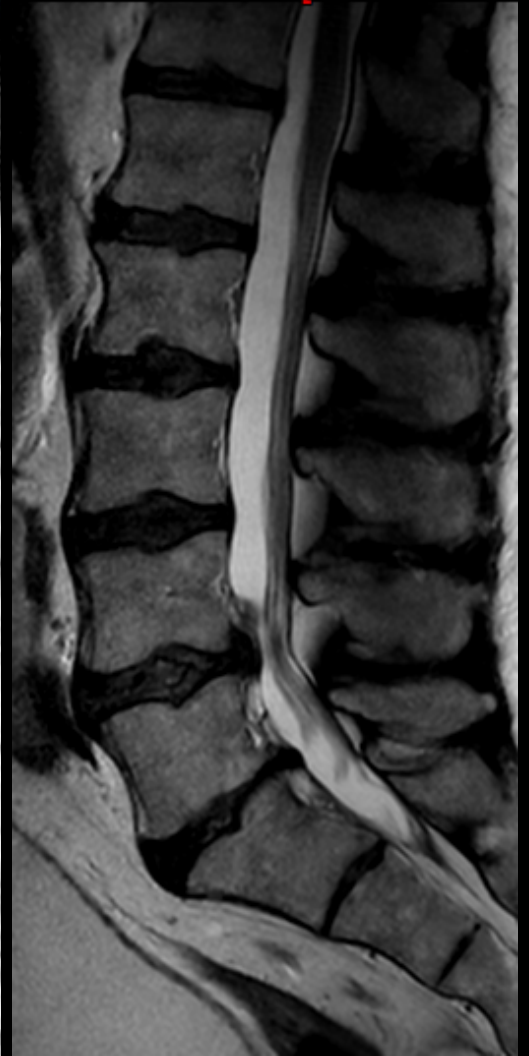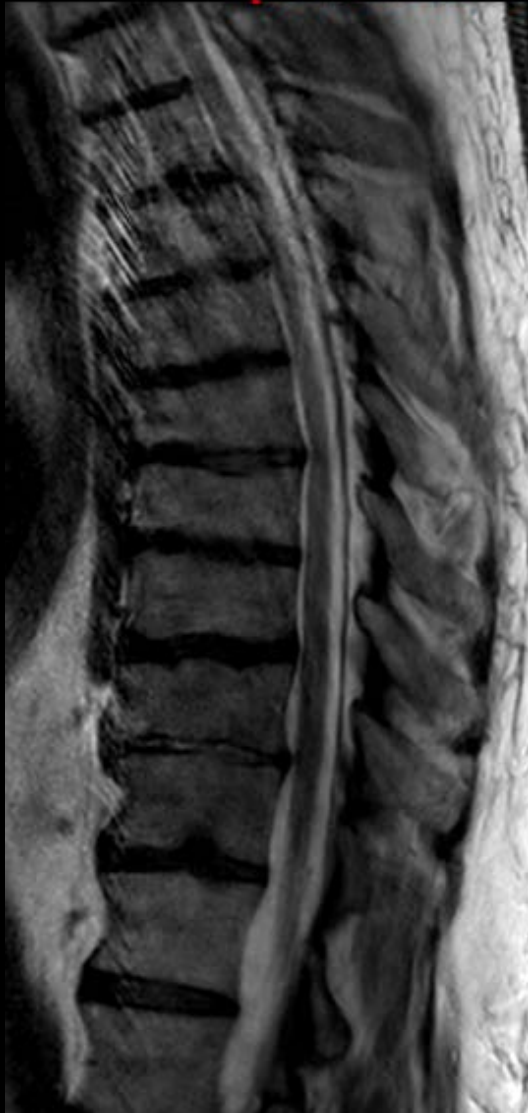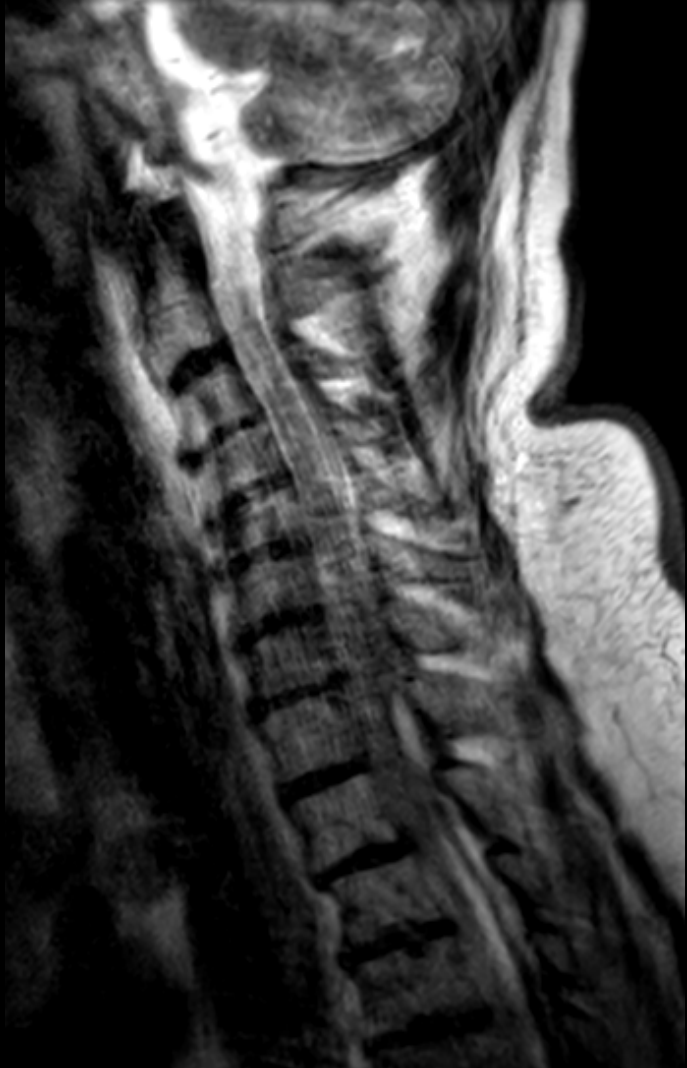**SAINT-LUC**

UCL

BRUSSELS

# Paraplégie flasque – infection ?

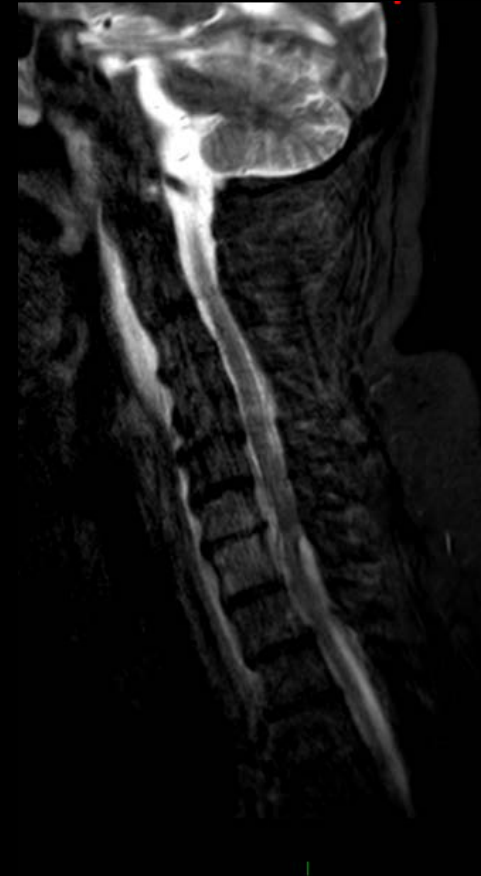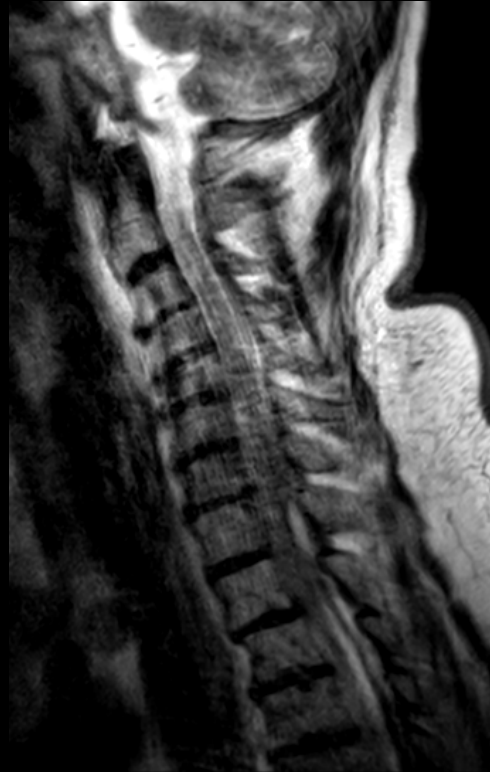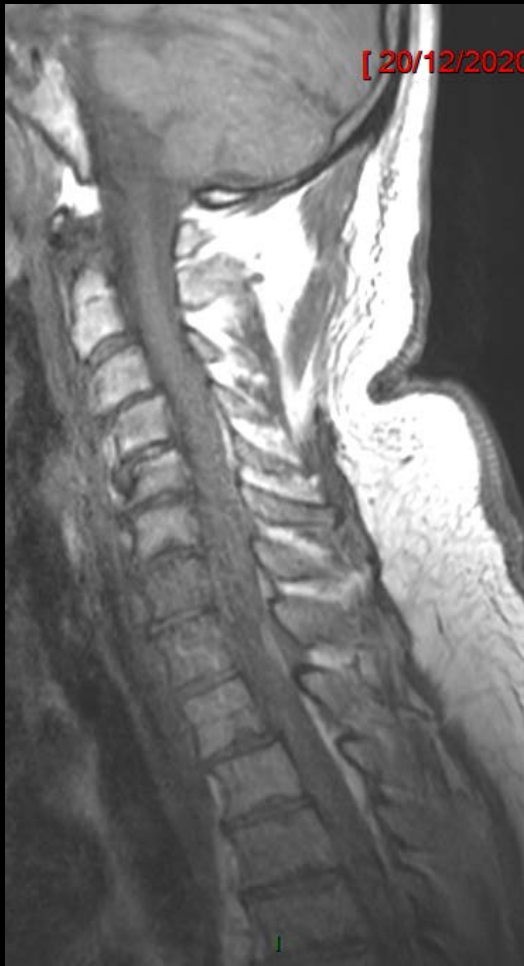---



# Paraplégie flasque – infection ?

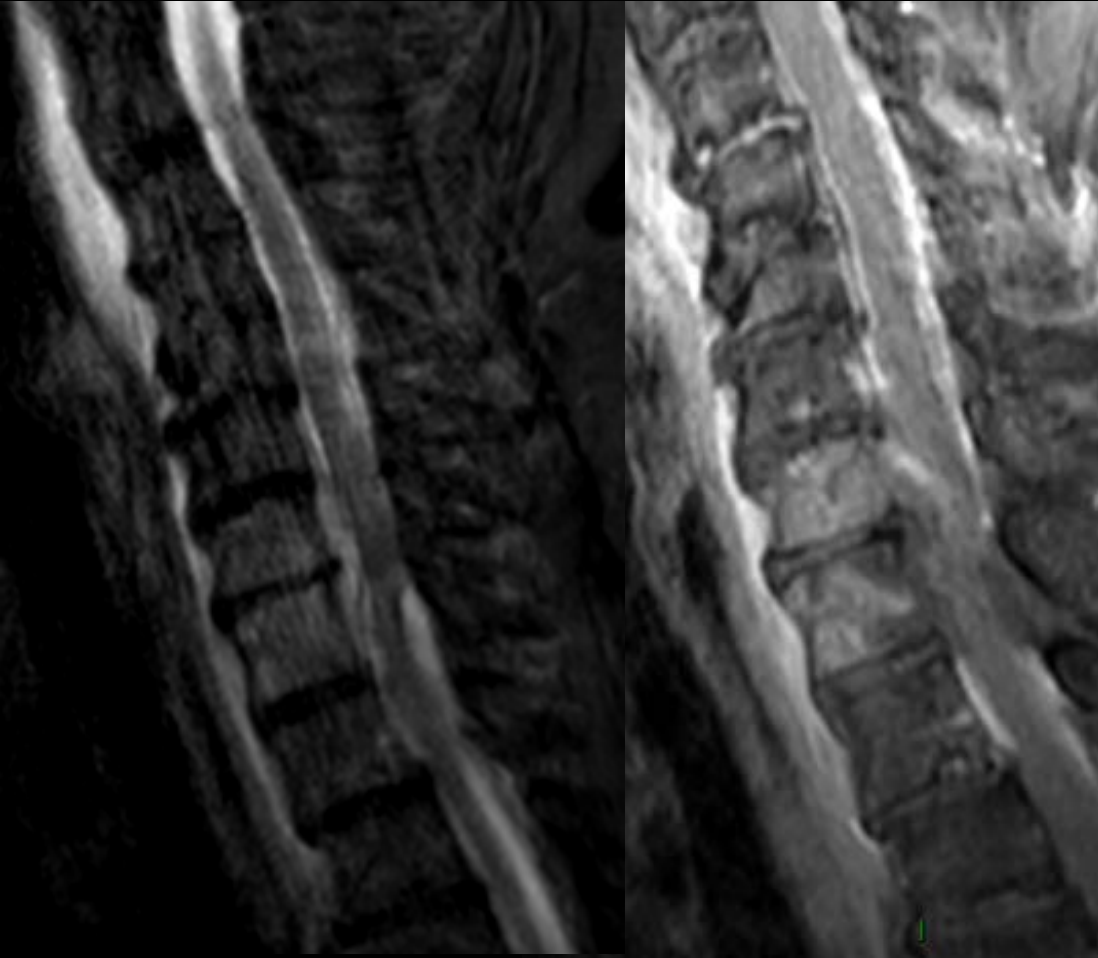
---

Dimanche 20/12 20h30



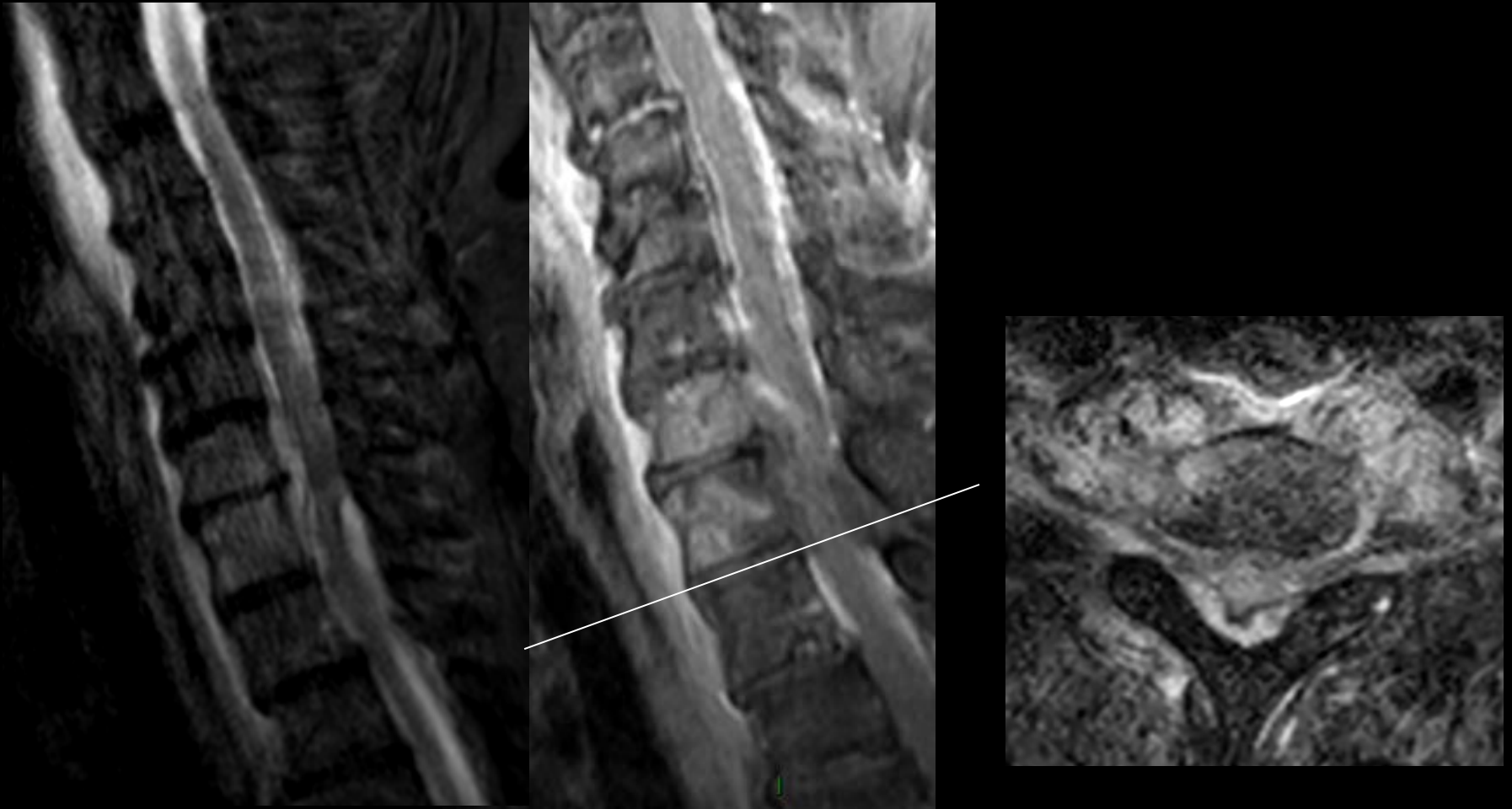
# Paraplégie flasque – infection ?

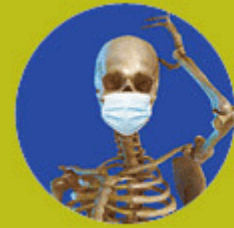---



# Paraplégie flasque – infection ?

---





15 / 16 janvier 2021

21<sup>e</sup> MISES AU POINT EN  
IMAGERIE OSTÉO-ARTICULAIRE  
en visio...

Mme D., 48 ans

Antécédent: Abscess orteil depuis 5 sem. sous Ab, Stop

Salle d'urgence: douleur et raideur cervicale spontanées

Irradiation hémicrane et œil gauche, vision floue

Sudations nocturnes mais ni frisson ni fièvre

CRP 1,58

Hyperleucocytose (12,500)

**Exclure discite !**

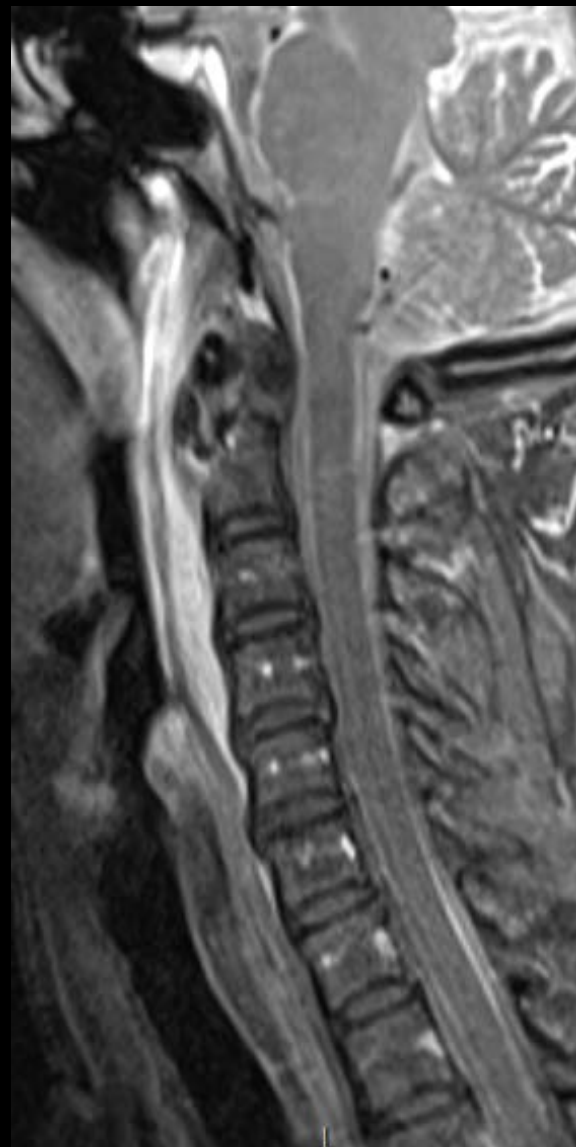
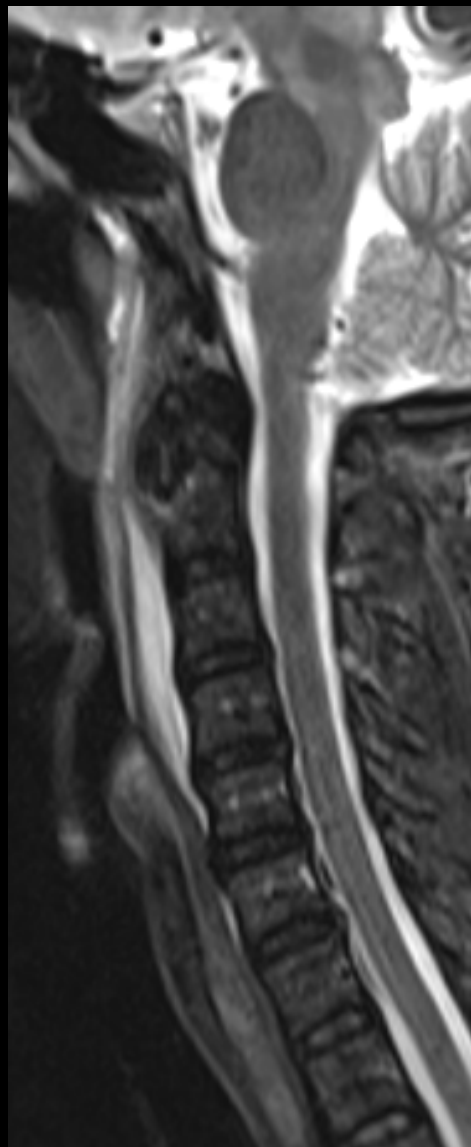
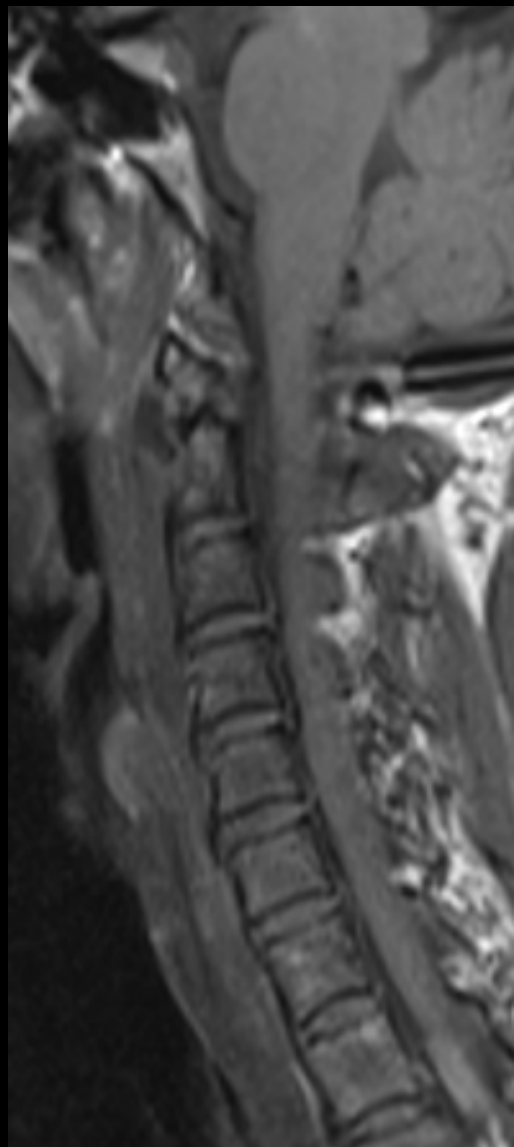


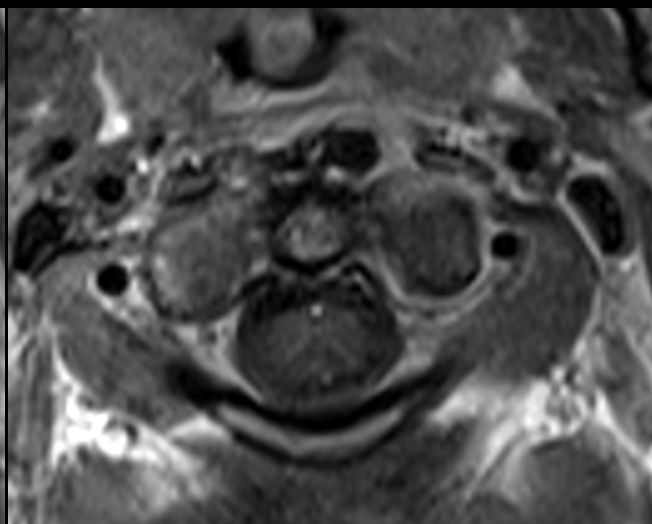
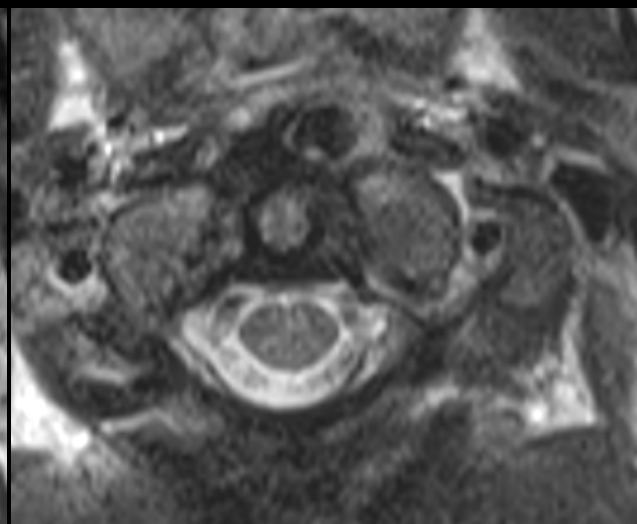
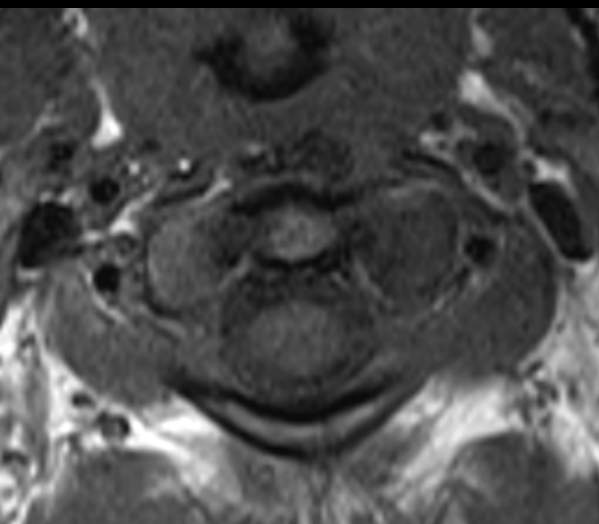
Cliniques universitaires

**SAINT-LUC**

UCL

BRUSSELS









15 / 16 janvier 2021

21<sup>e</sup> MISES AU POINT EN  
IMAGERIE OSTÉO-ARTICULAIRE  
en visio...

Mme N., 67 ans

Antécédent: RAS

Salle d'urgence: douleur ++ et raideur cervicale  
39°, CRP 1,58 , formule sanguine normale  
hémocultures négatives

**Exclure discite !**

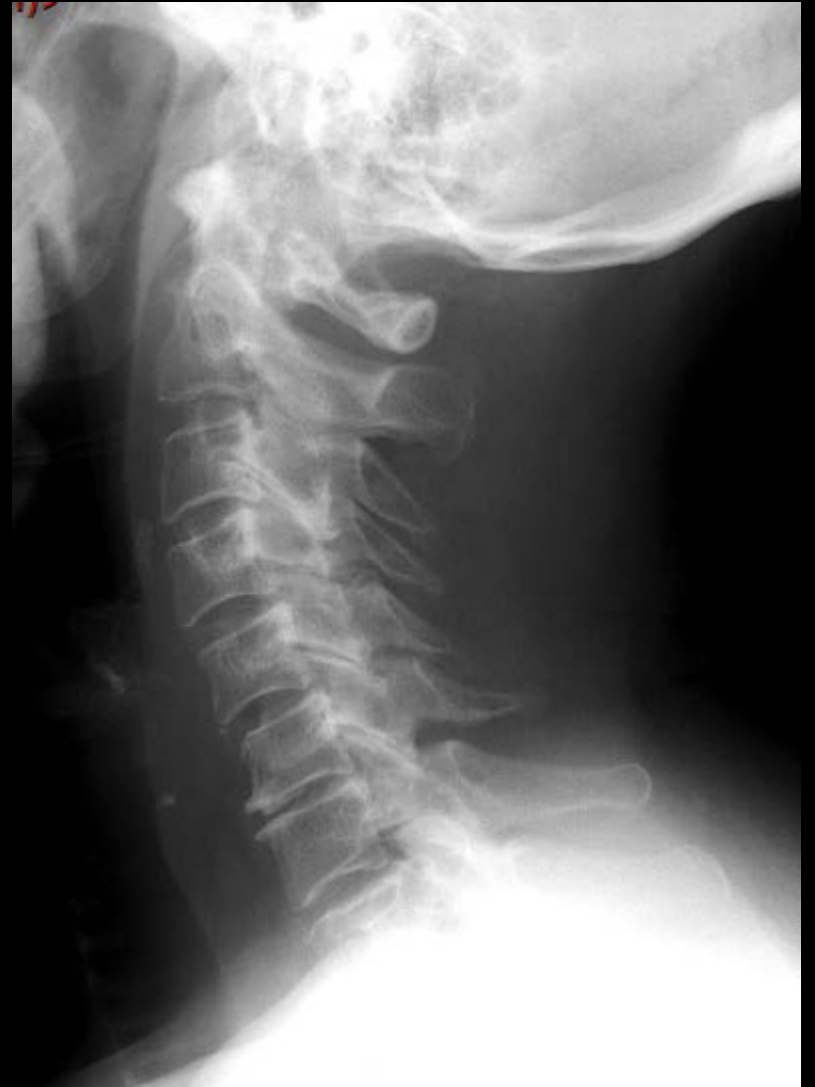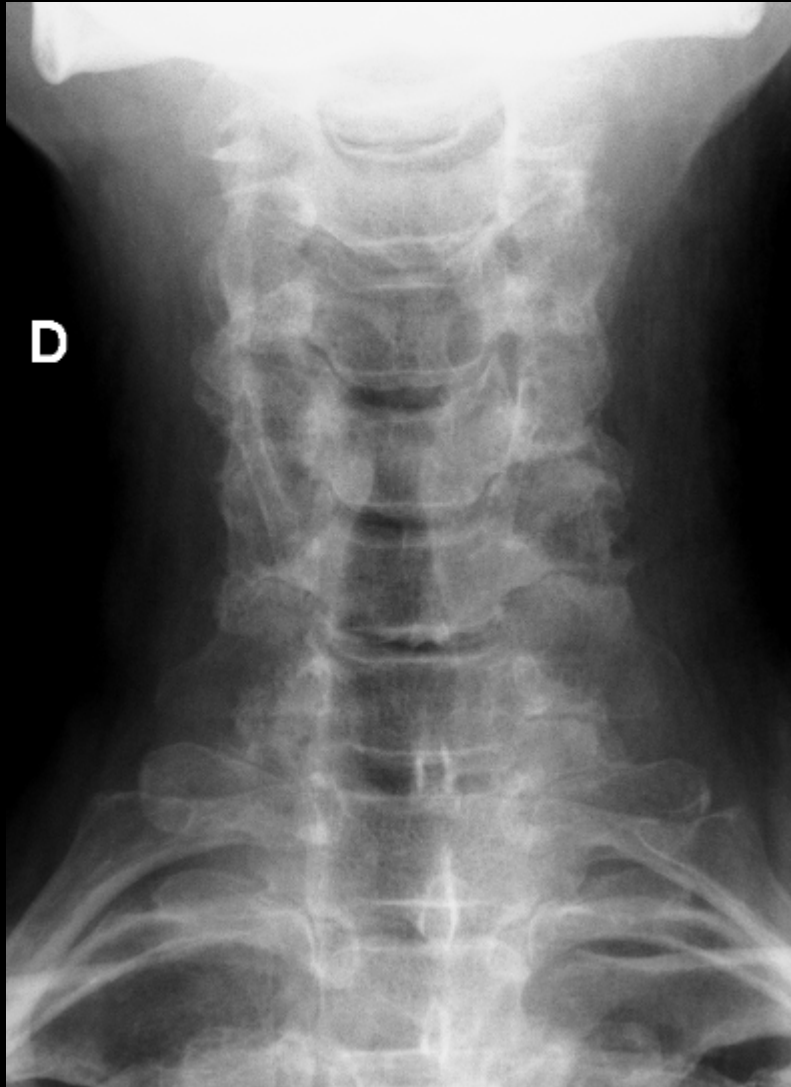


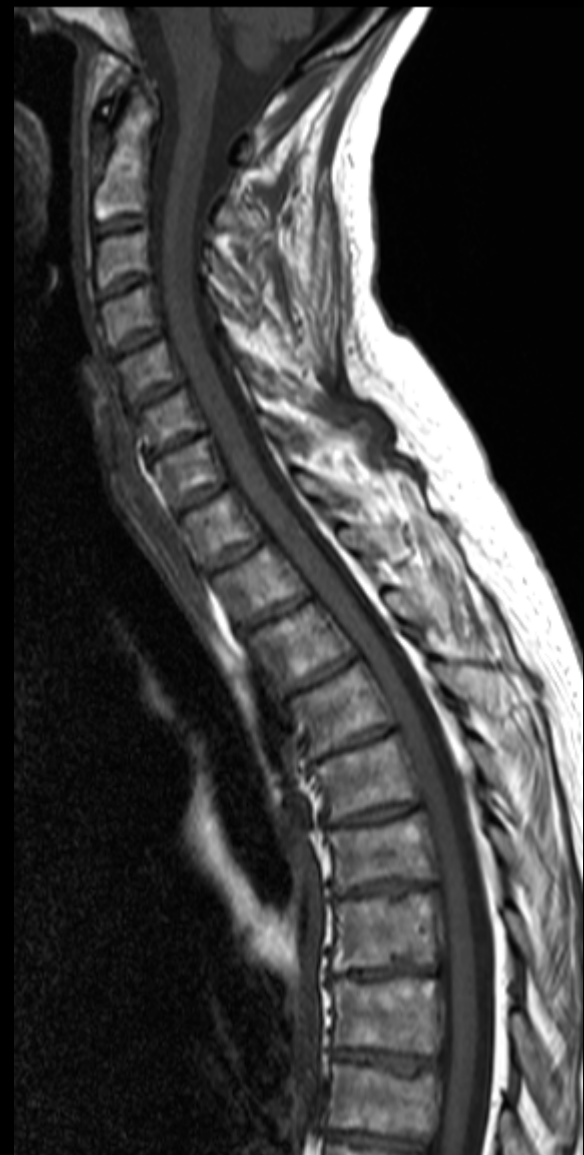Cliniques universitaires

**SAINT-LUC**

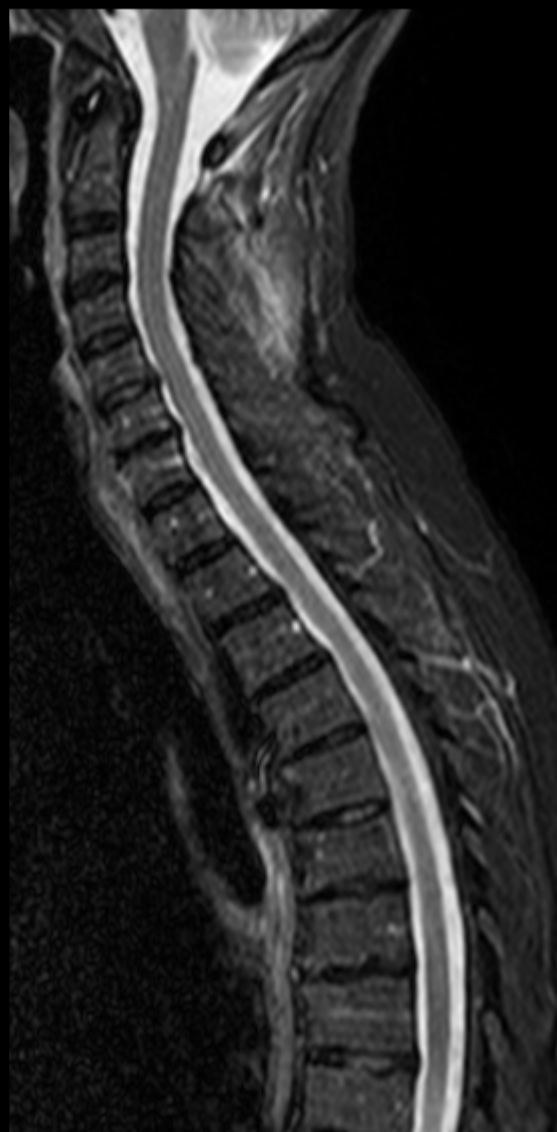UCL

BRUSSELS

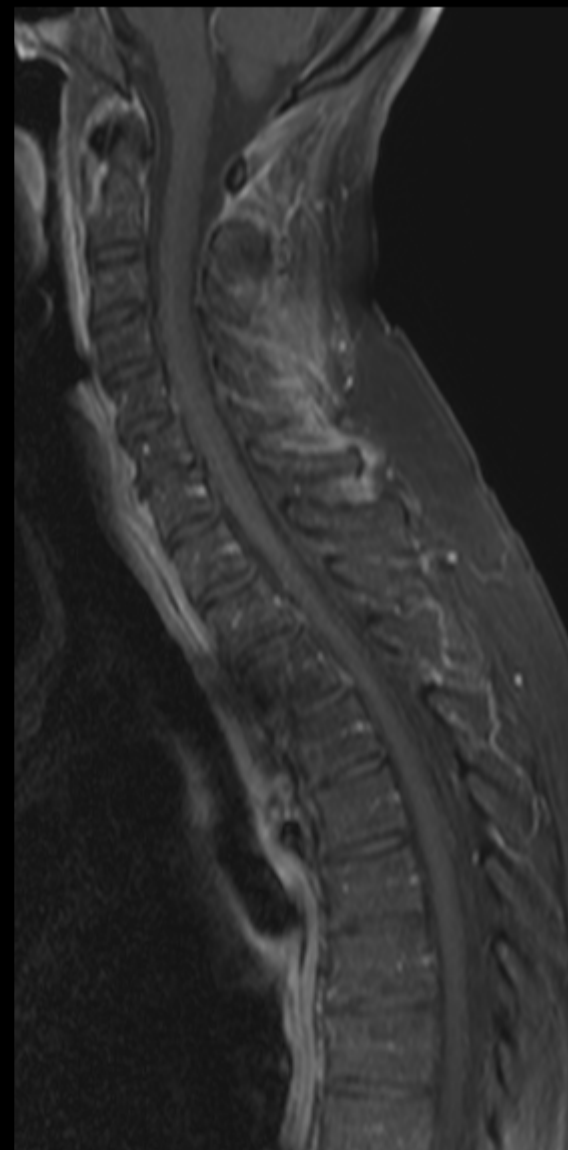




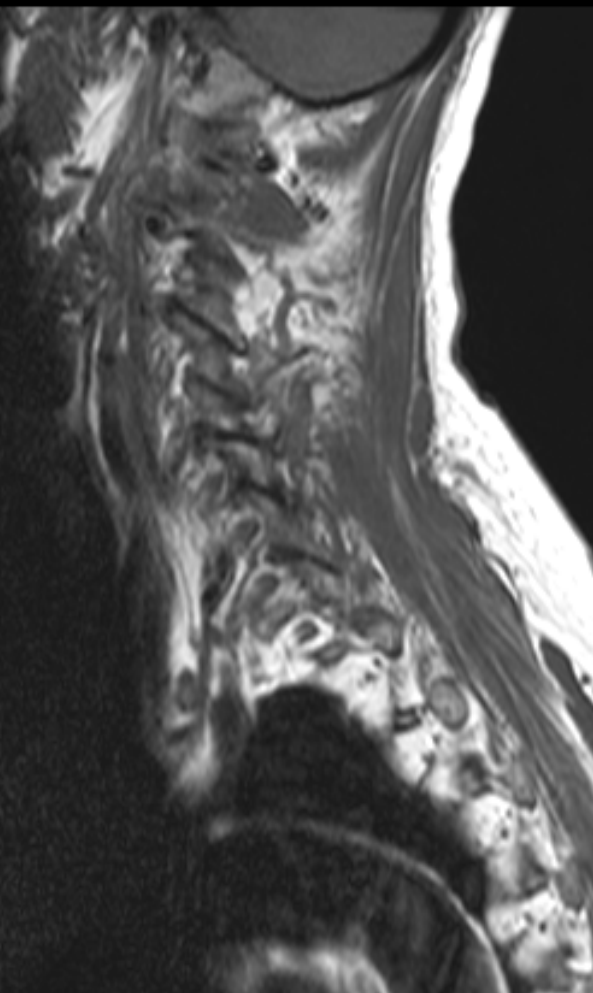
SE T1



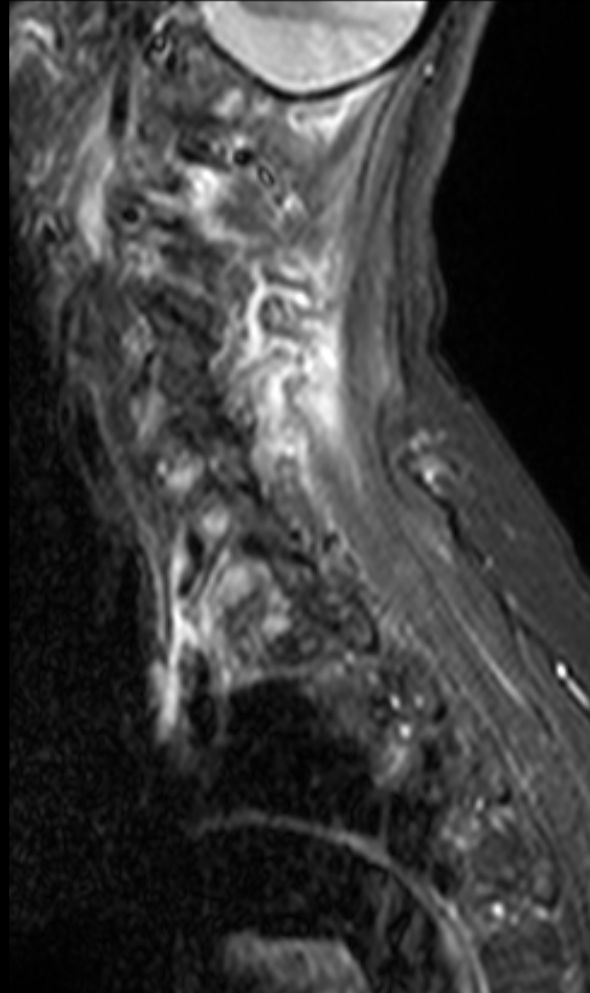
T2 fs



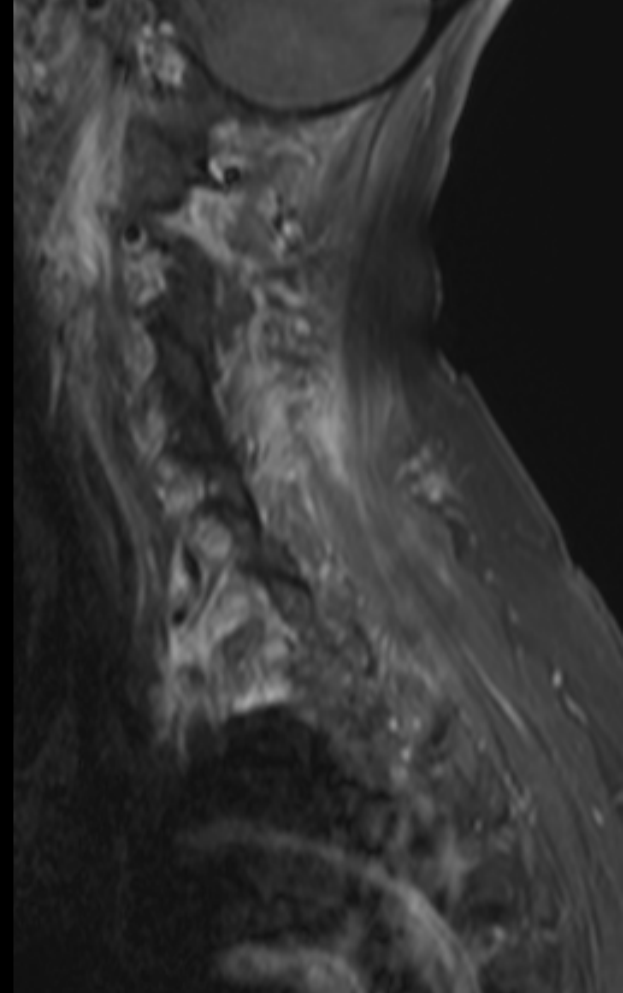
T1 fat sat gado



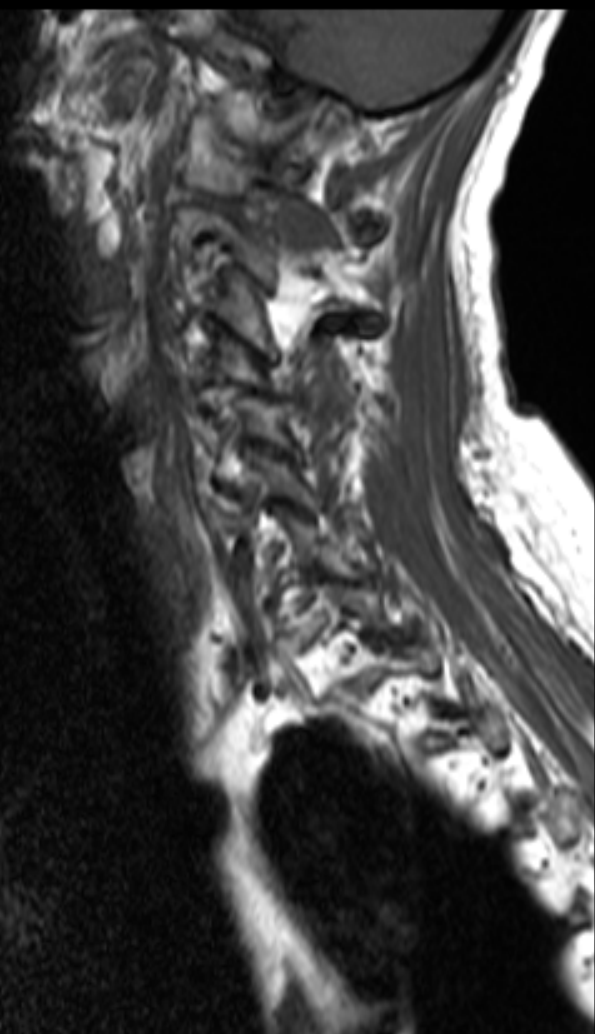
Para médian gauche SE T1



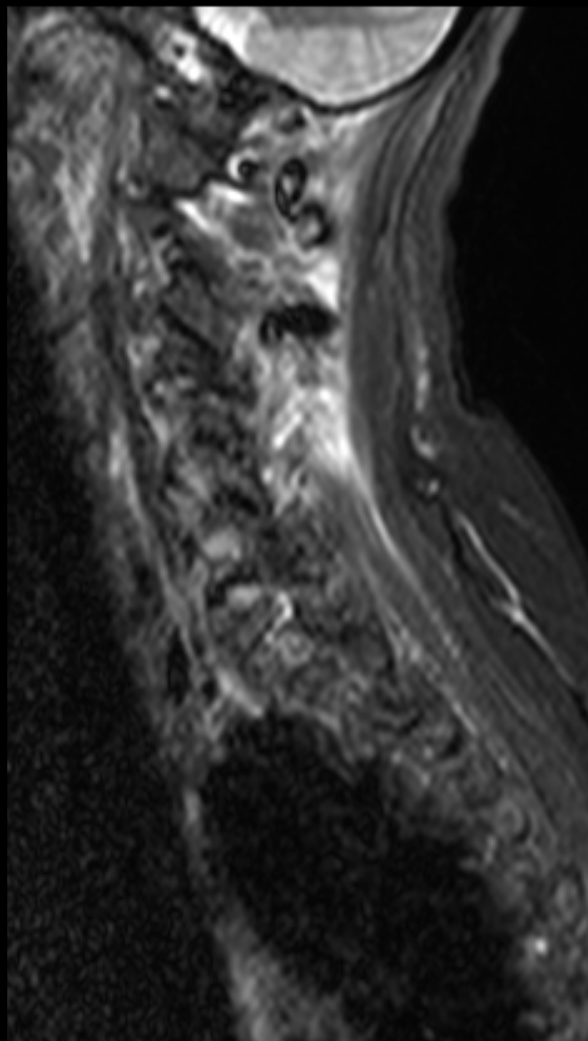
T2 fs



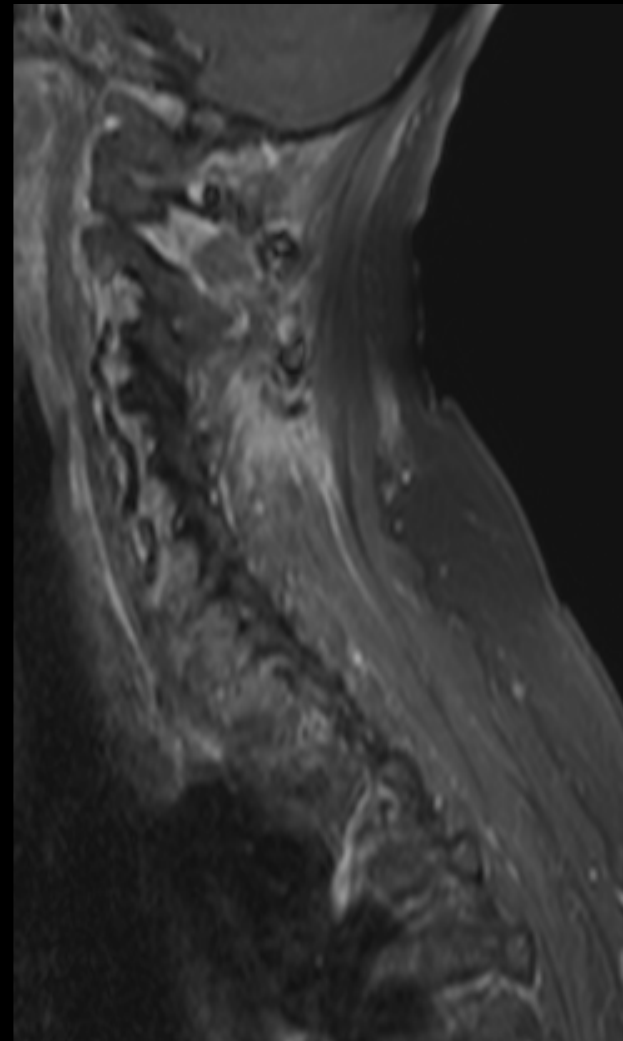
T1 fat sat gado



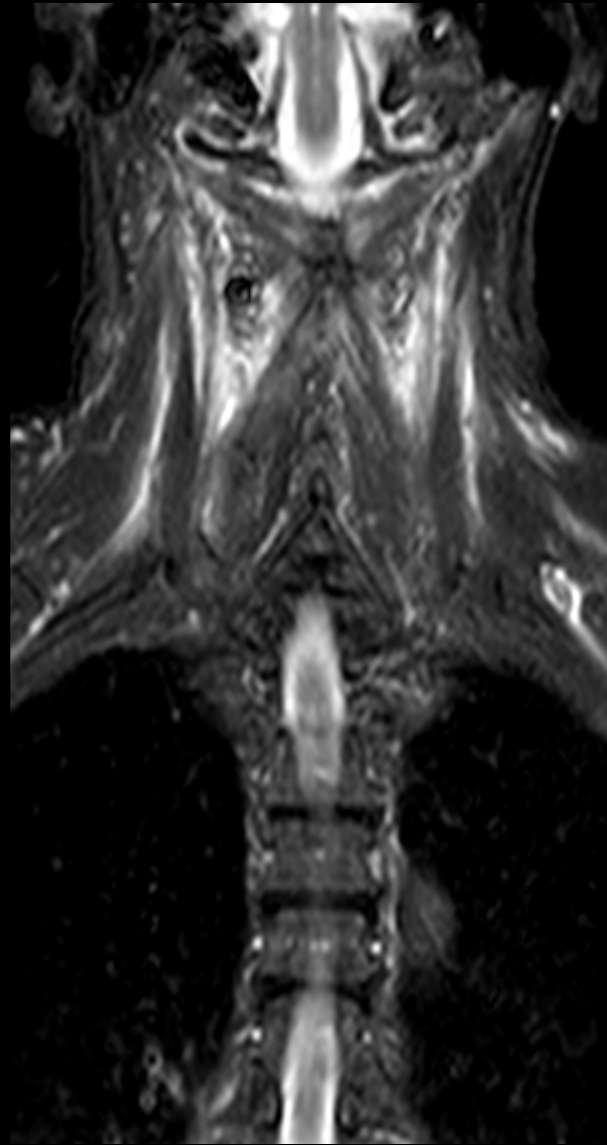
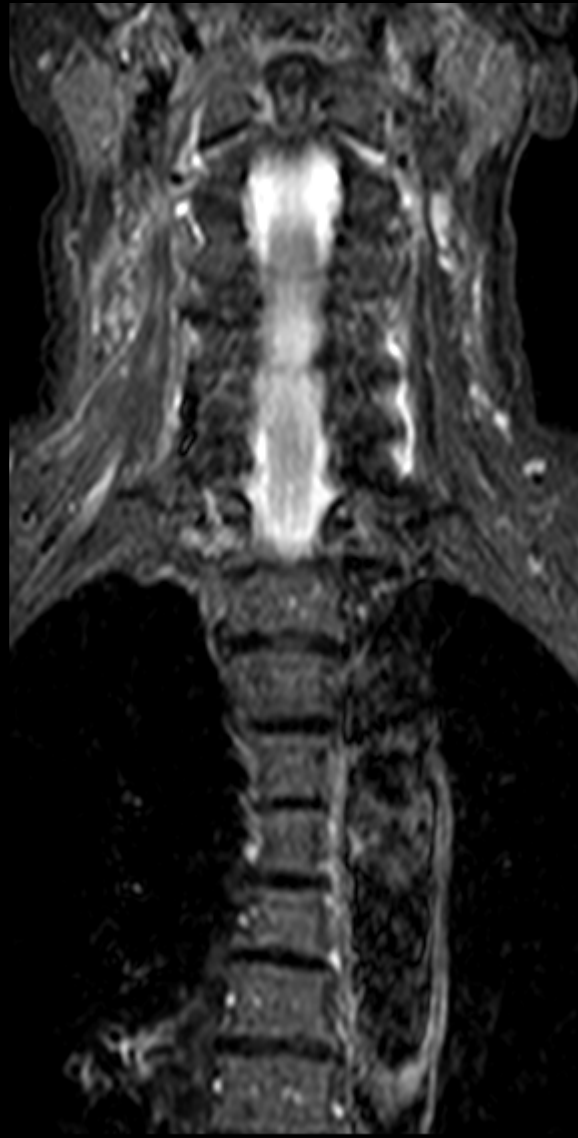
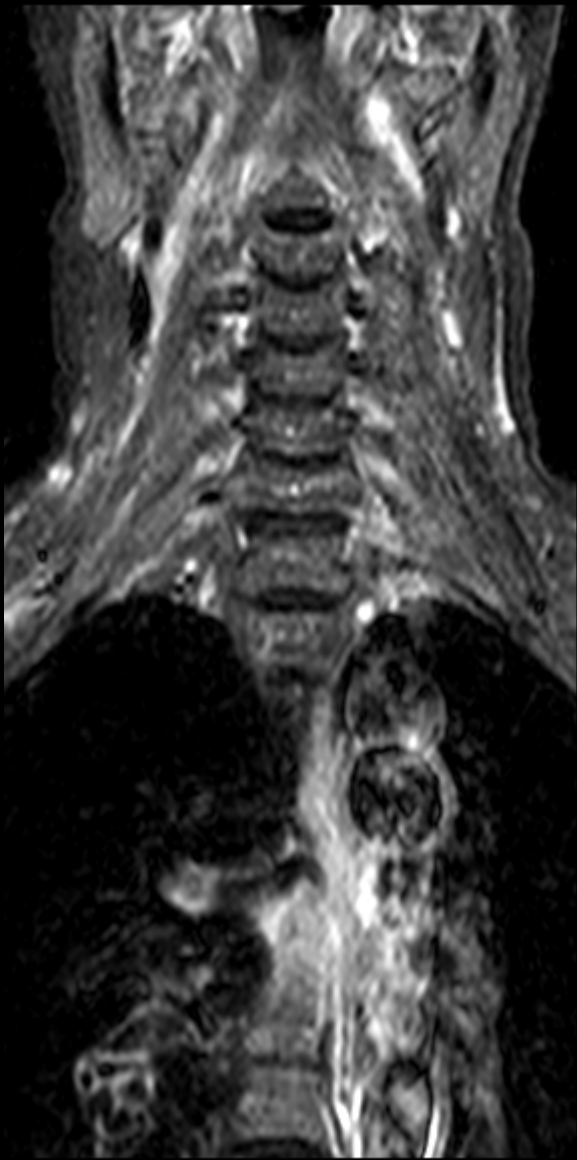
Para médian droit SE T1

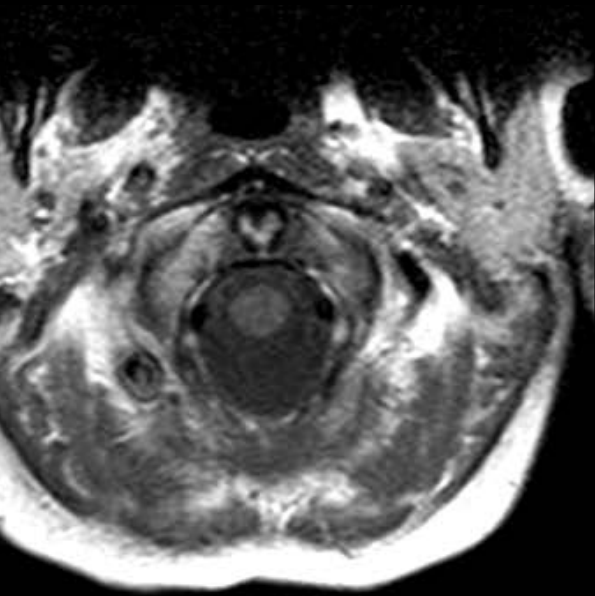


T2 fs

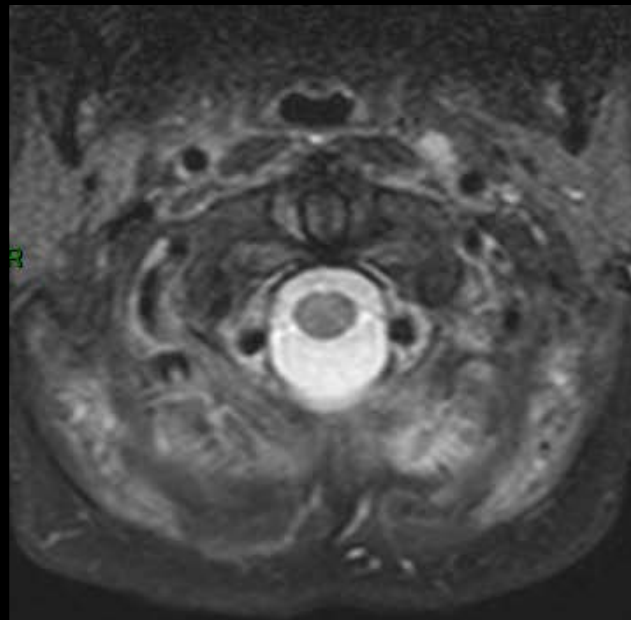


T1 fat sat gado

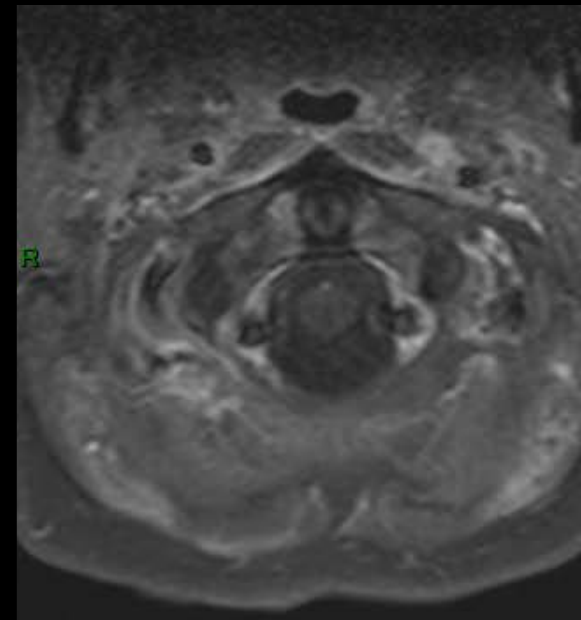




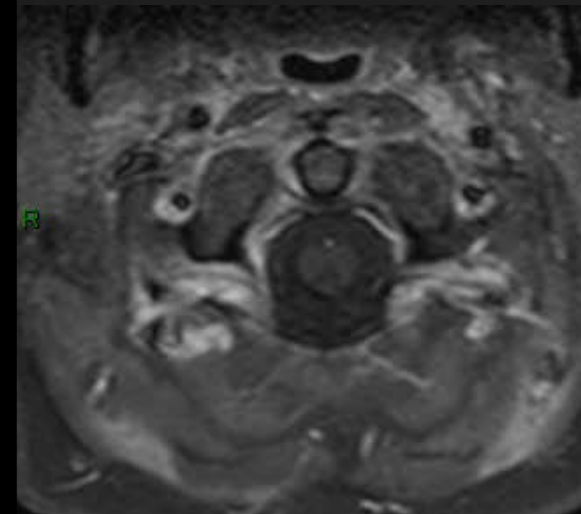
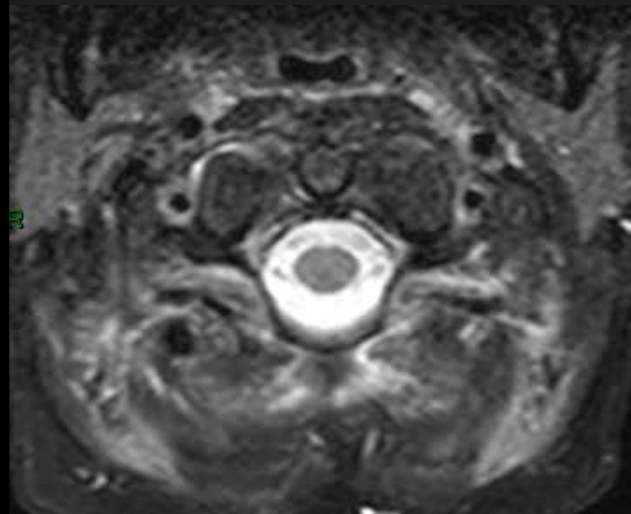
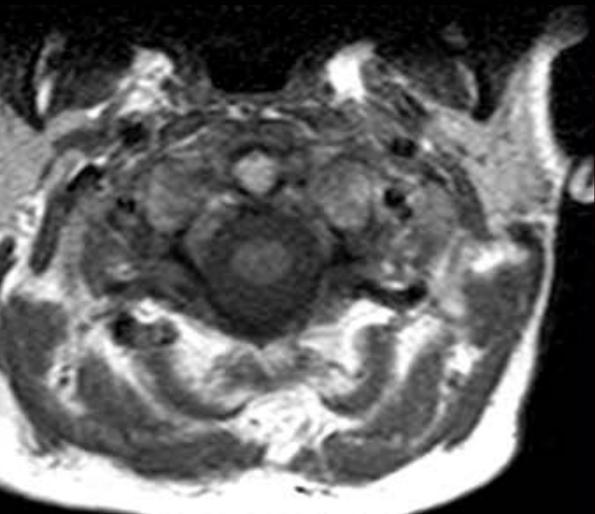
SE T1



T2 fs



T1 fat sat gado





15 / 16 janvier 2021

21<sup>e</sup> MISES AU POINT EN  
IMAGERIE OSTÉO-ARTICULAIRE  
en visio...

Mme M. 77 ans

Diabète, neuropathies et infections

Discopathies lombaires +++ bien connues

Scepticémie,

lombalgies basses en recrudescence aigue

Infection ?



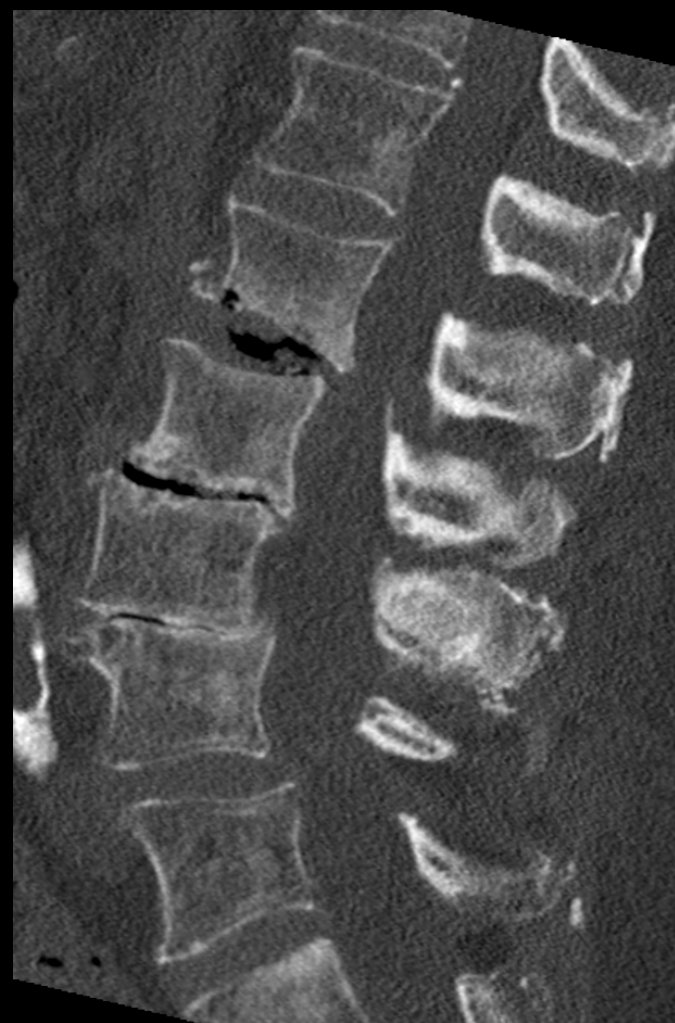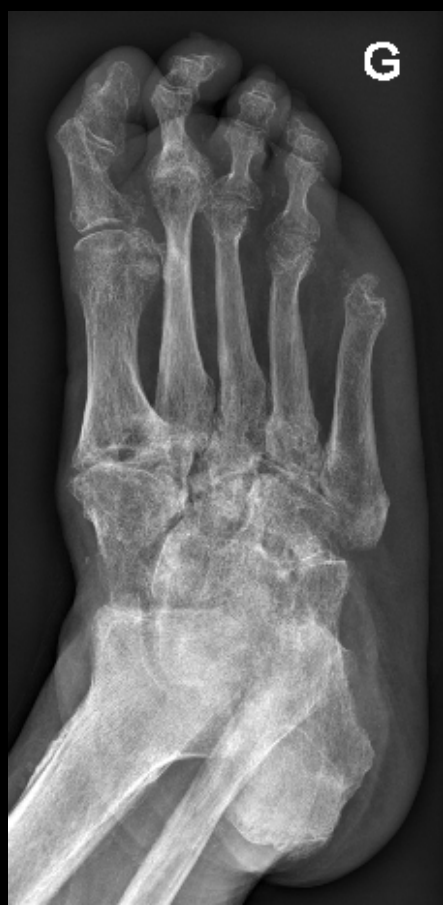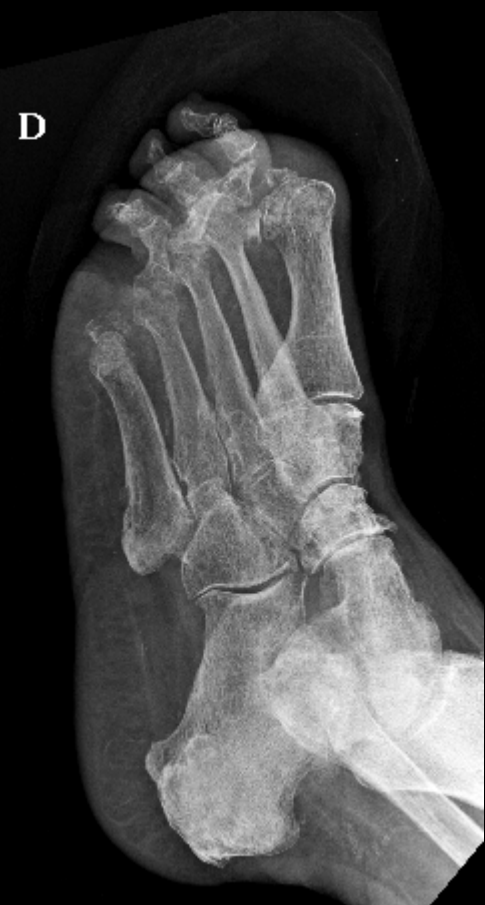Cliniques universitaires

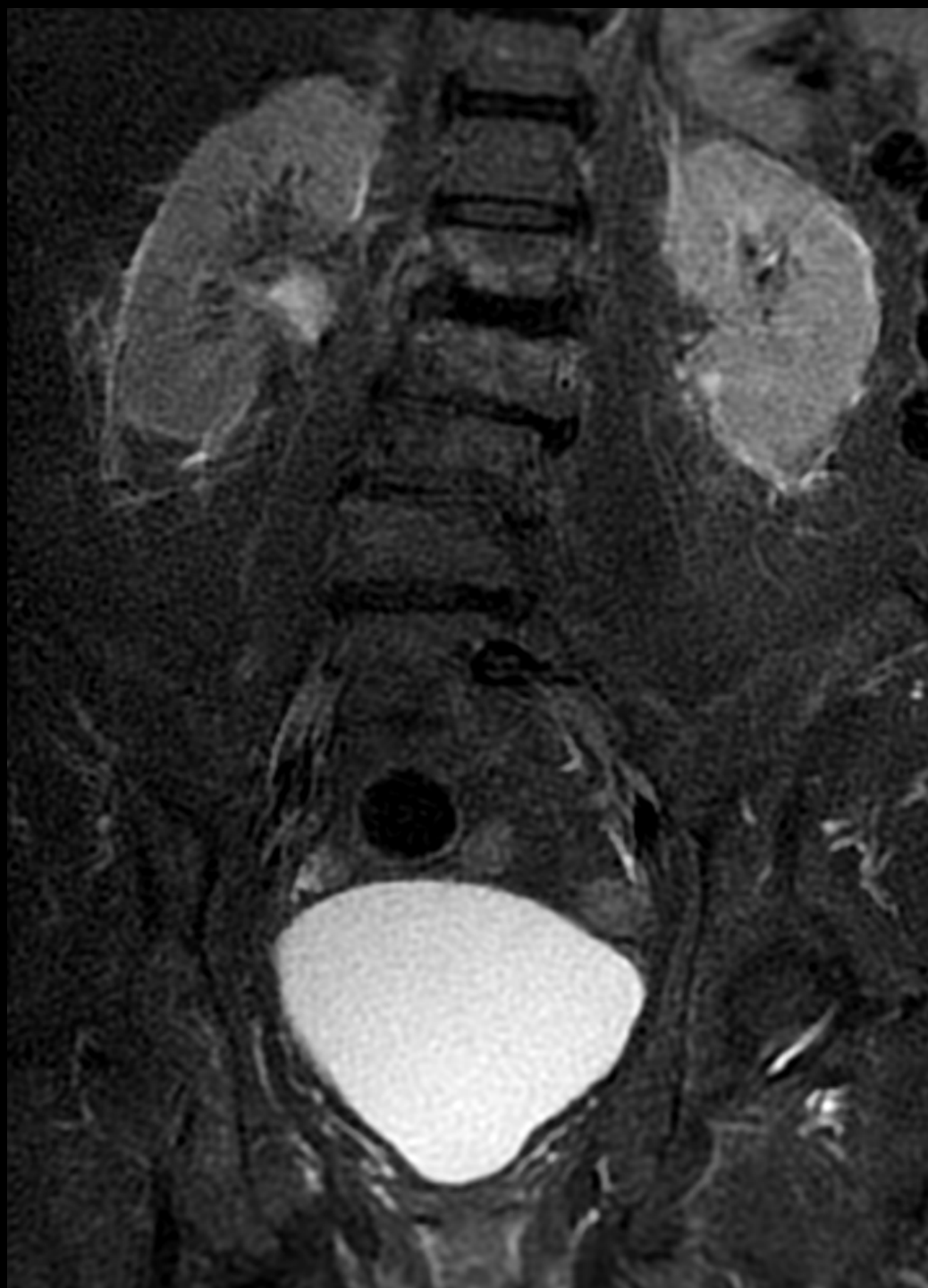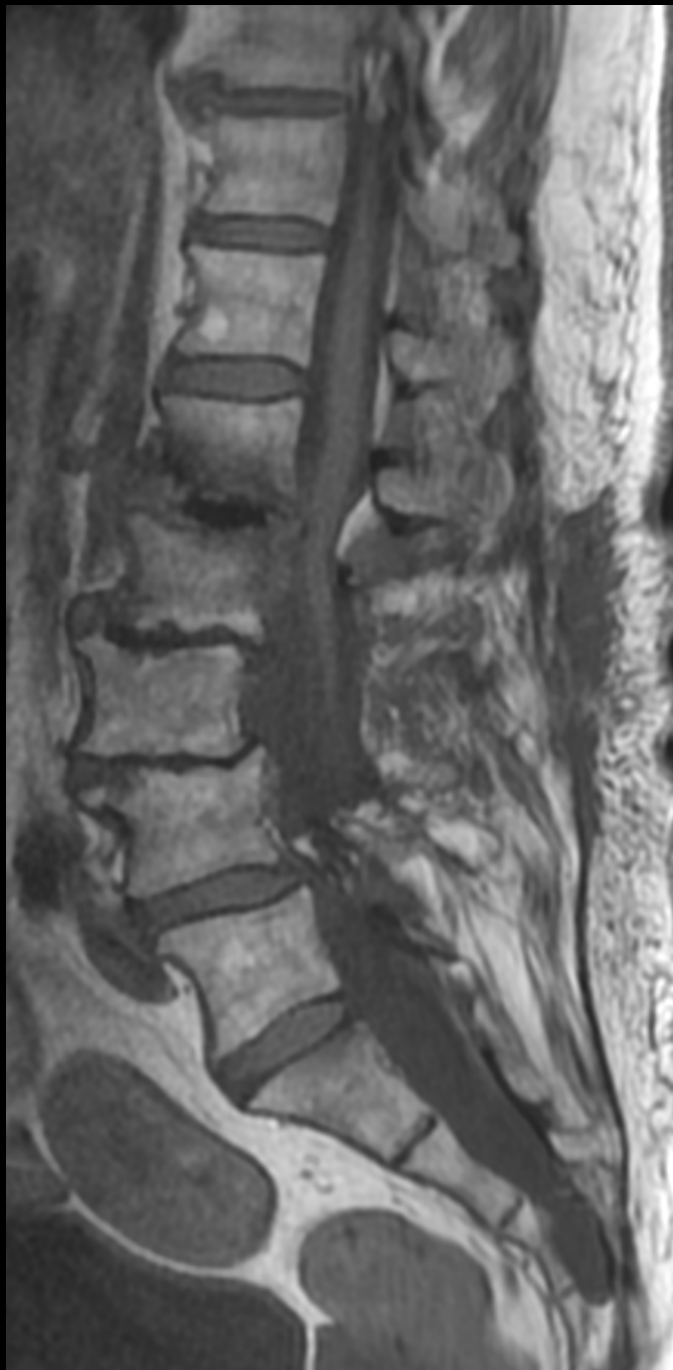**SAINT-LUC**

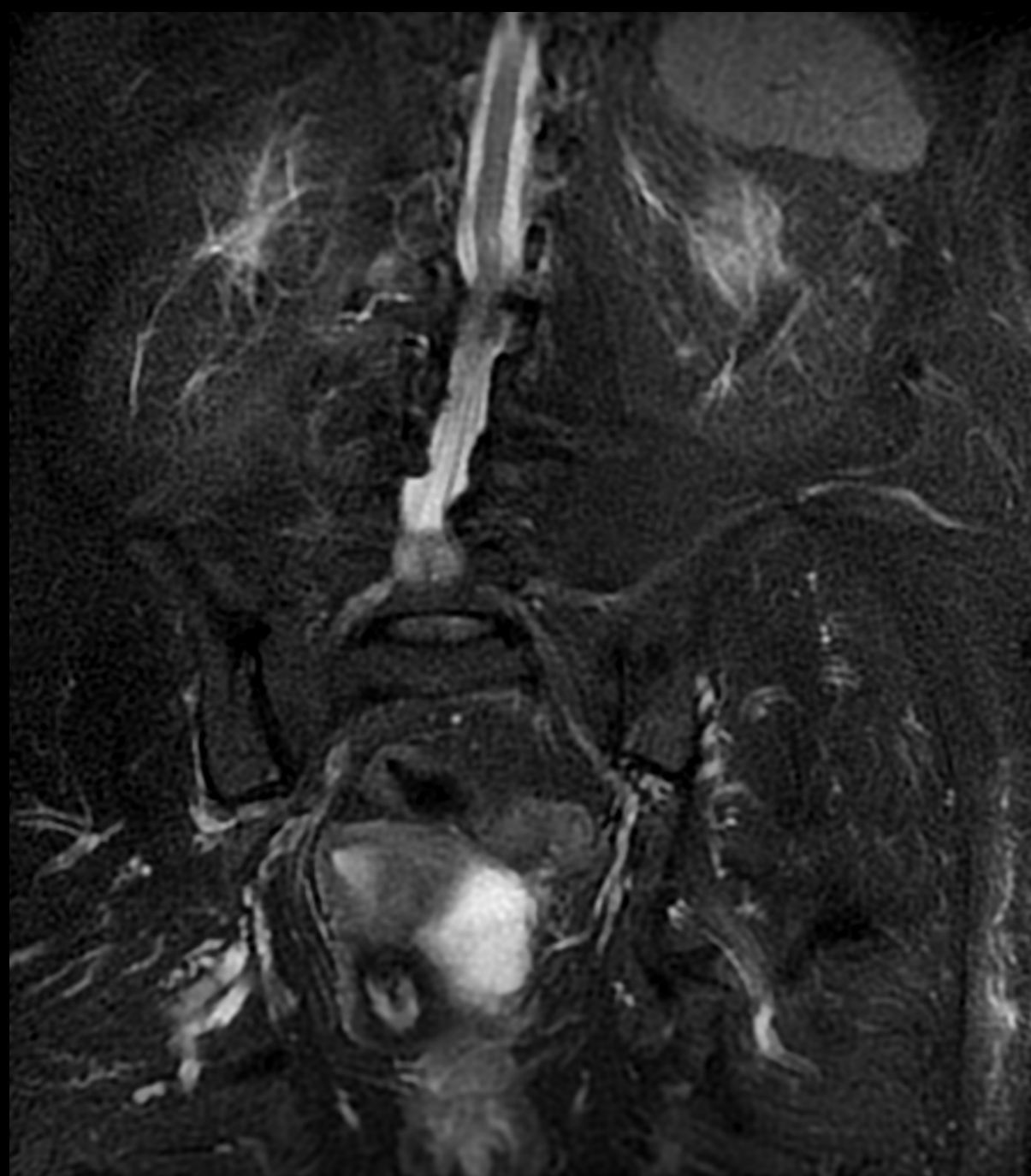UCL

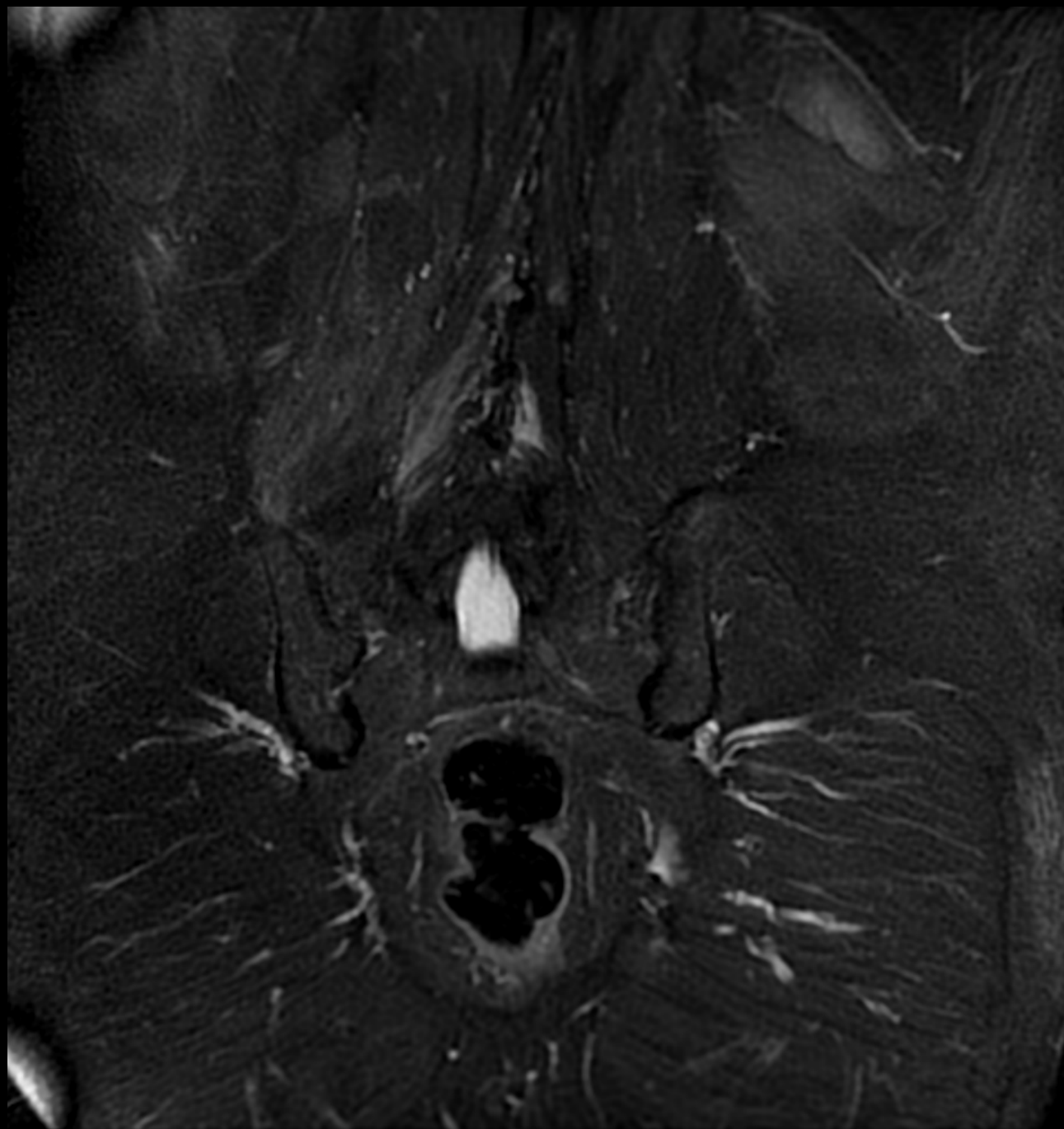BRUSSELS

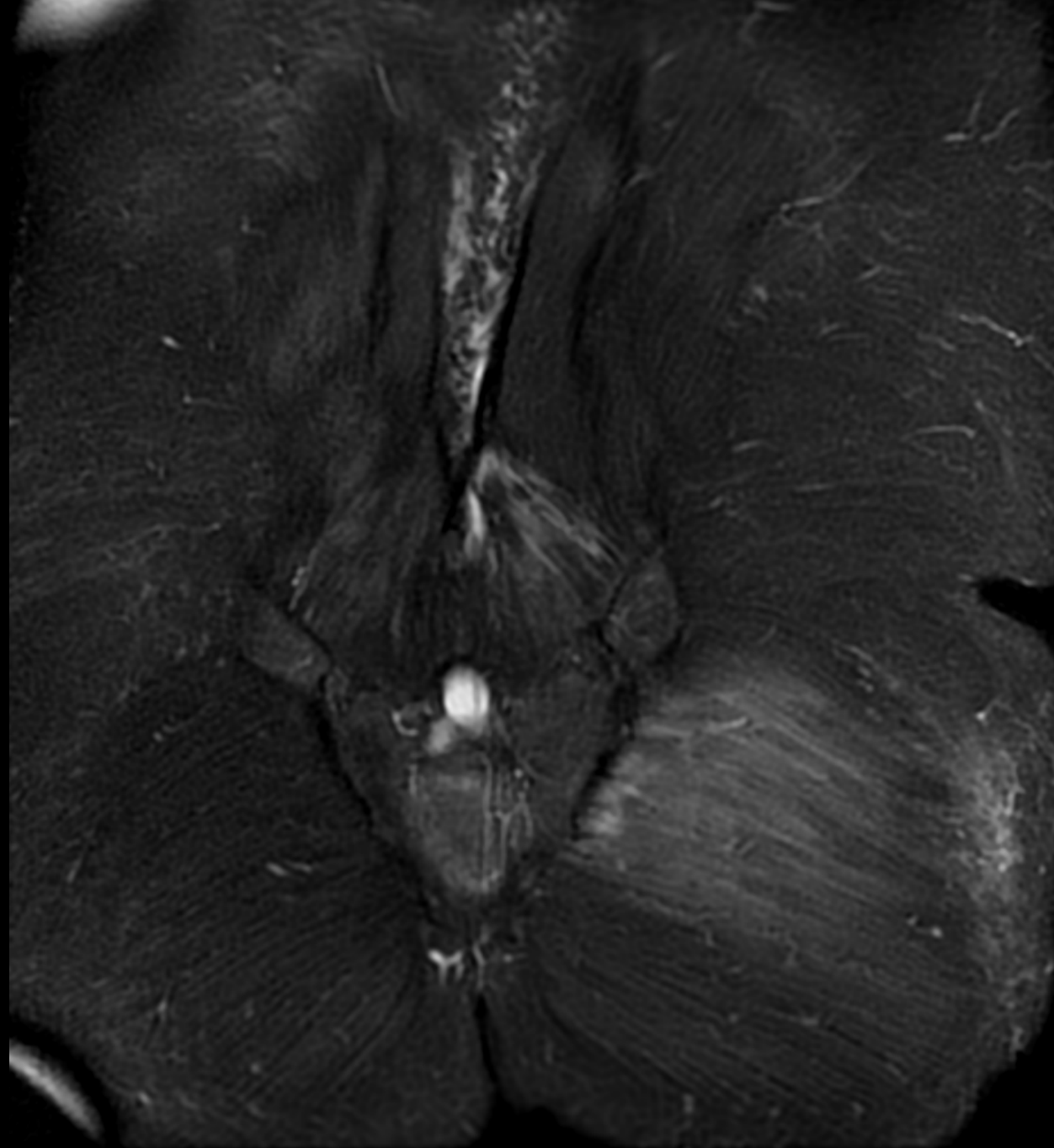


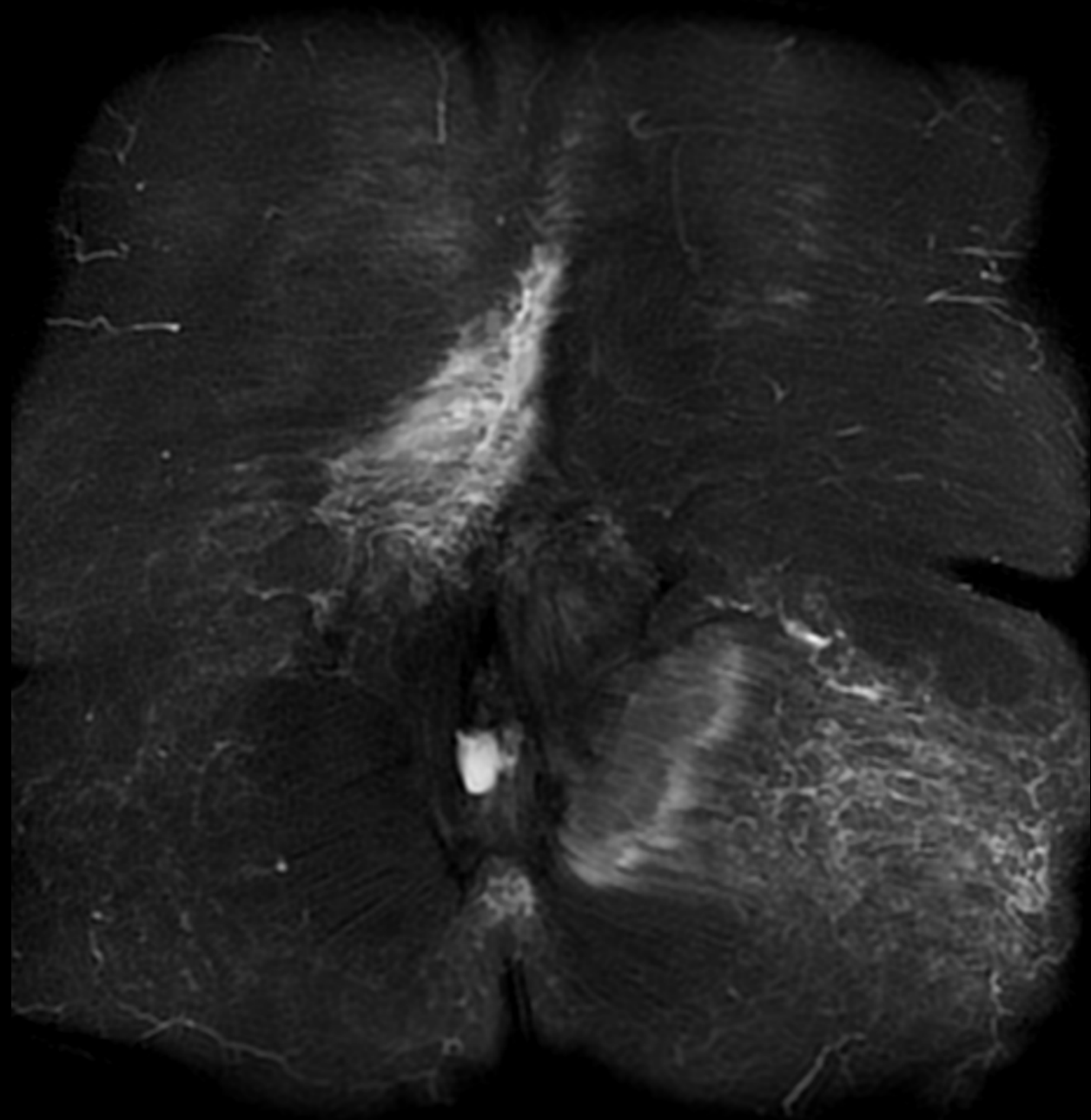




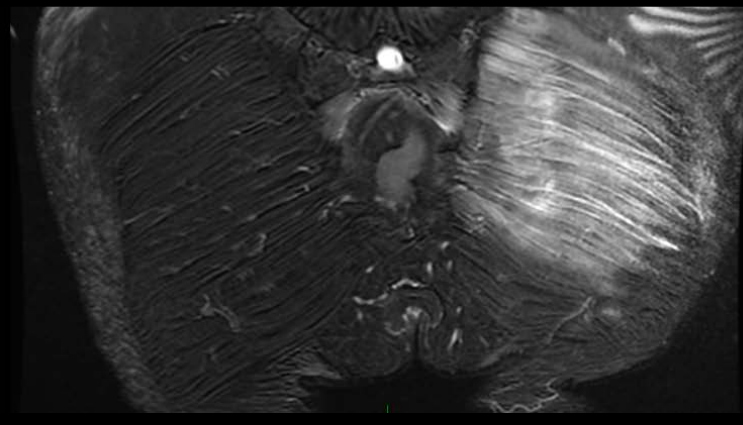
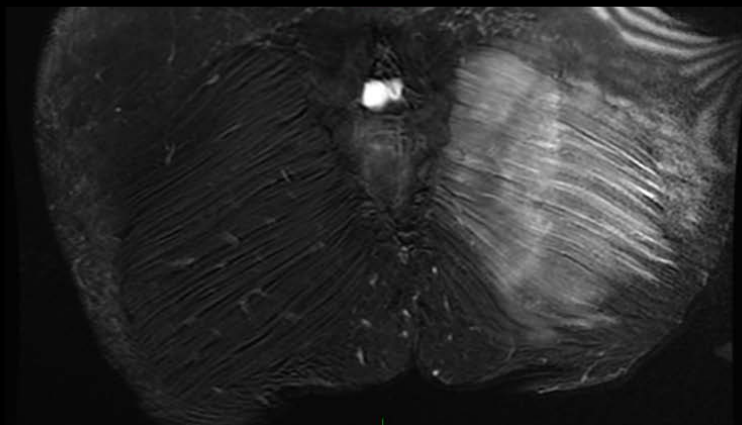
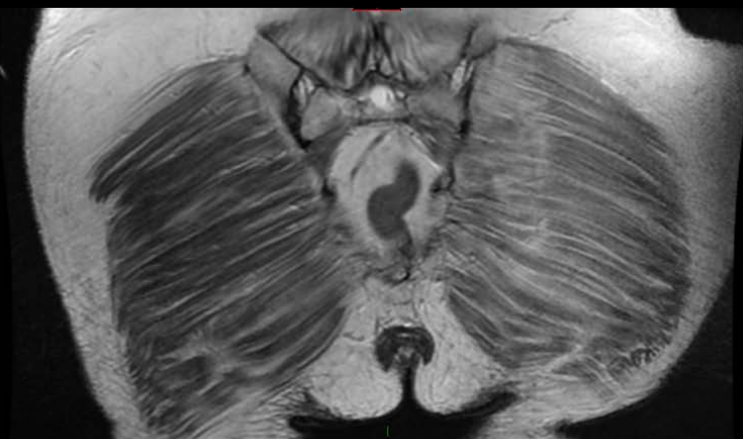
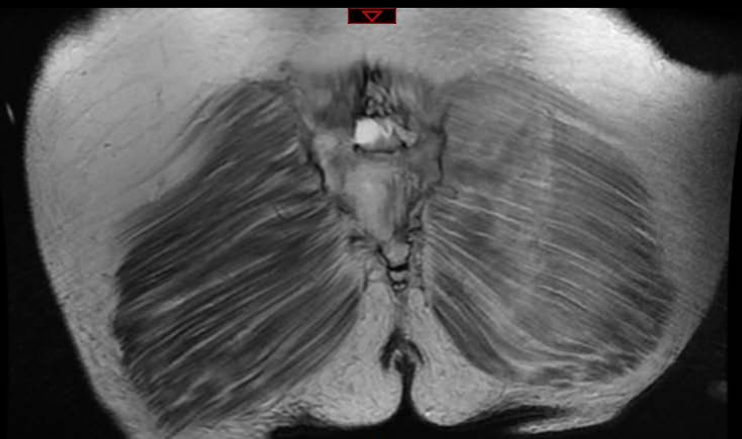
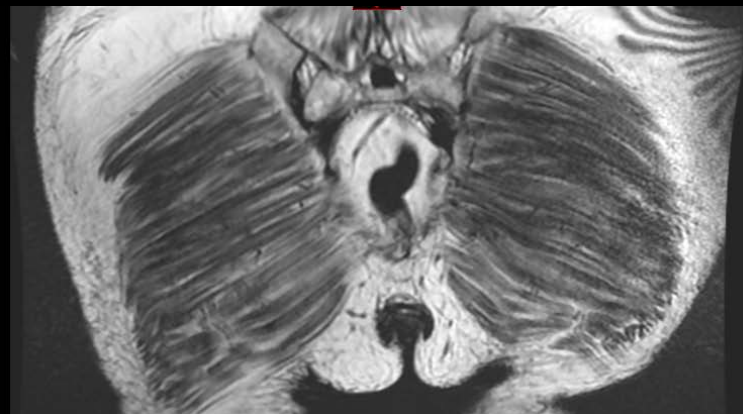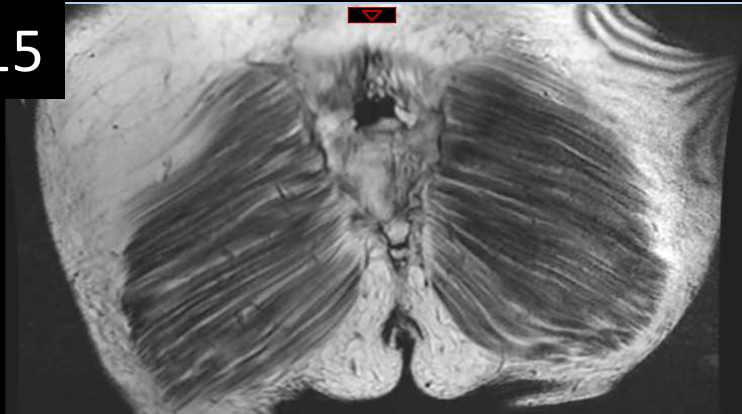




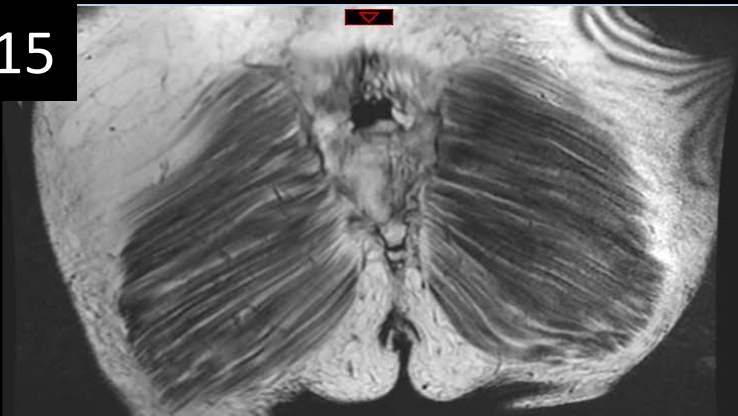




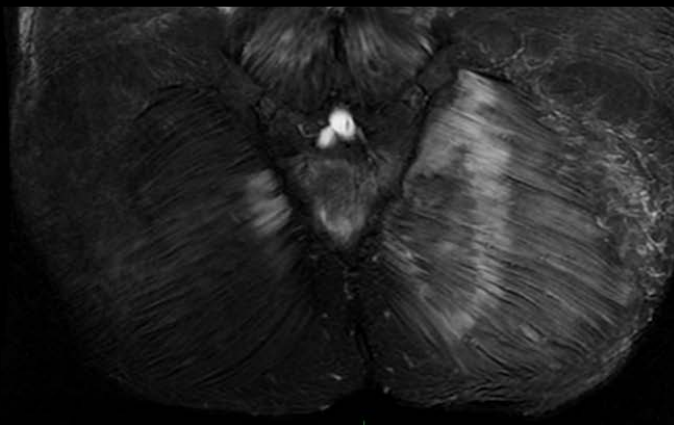
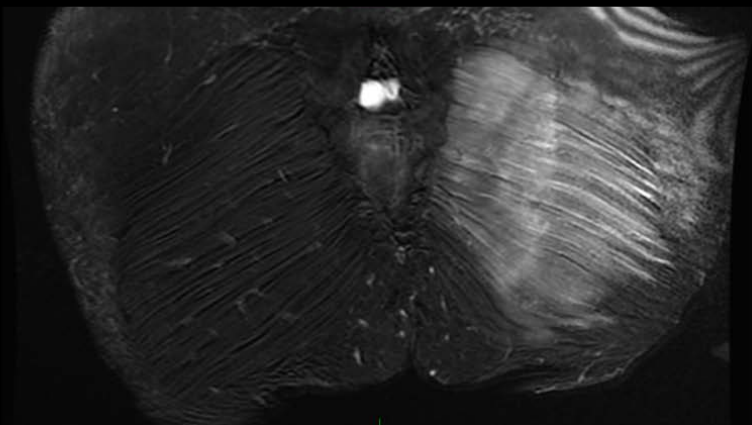
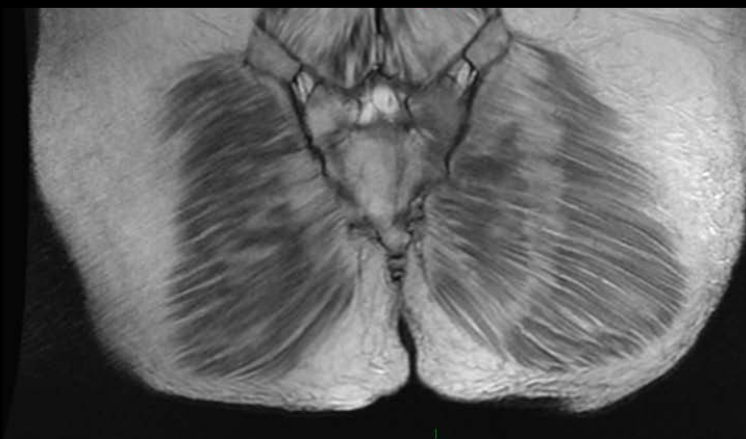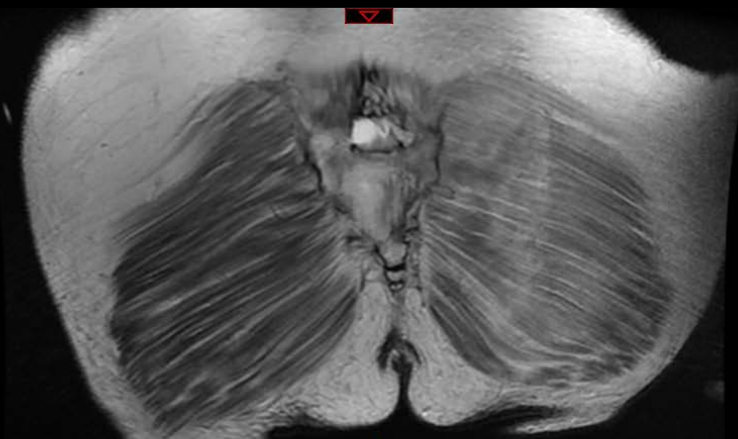
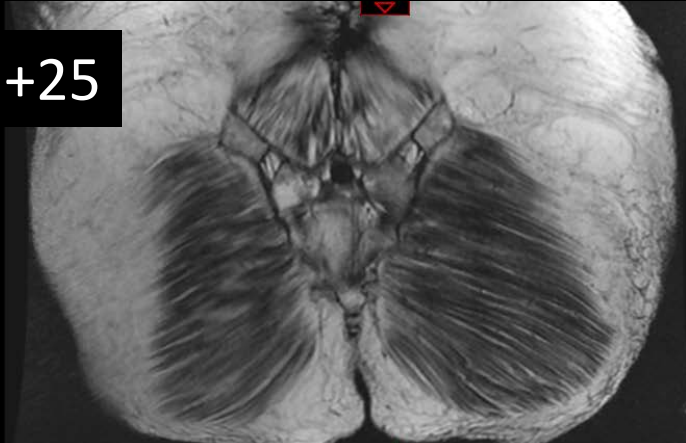
J+15



J+15



J+25







15 / 16 janvier 2021

21<sup>e</sup> MISES AU POINT EN  
IMAGERIE OSTÉO-ARTICULAIRE  
en visio...

Mr D., 16 ans

Lombalgies +++ depuis 5 jours

Ne peut plus se tenir debout, va mieux couché

37,2°, frissons

CRP 55

Hyperleucocytose modérée

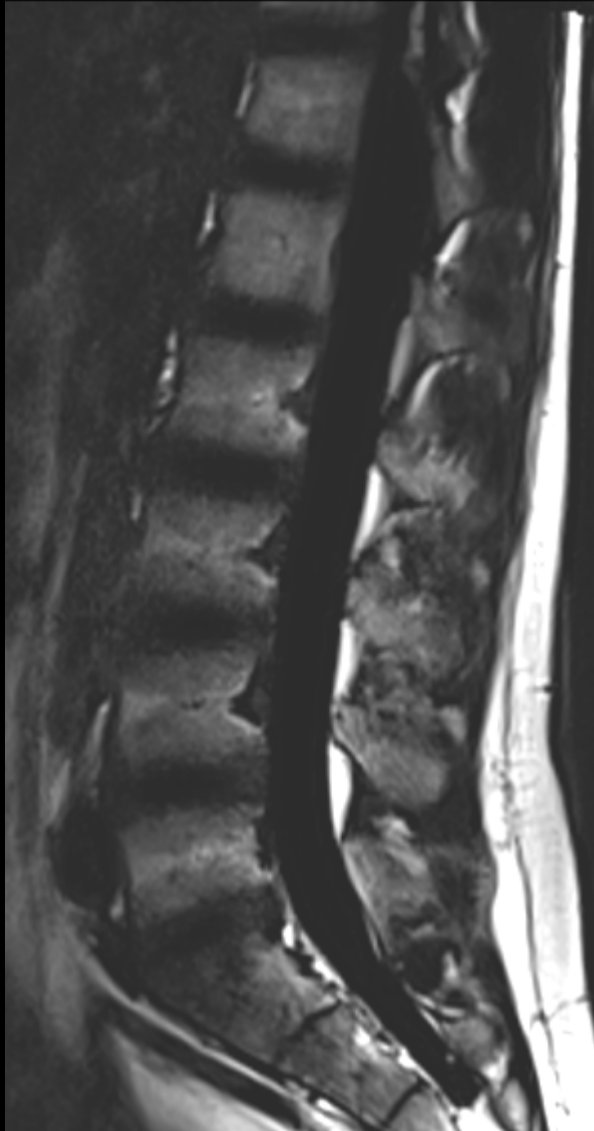


Cliniques universitaires

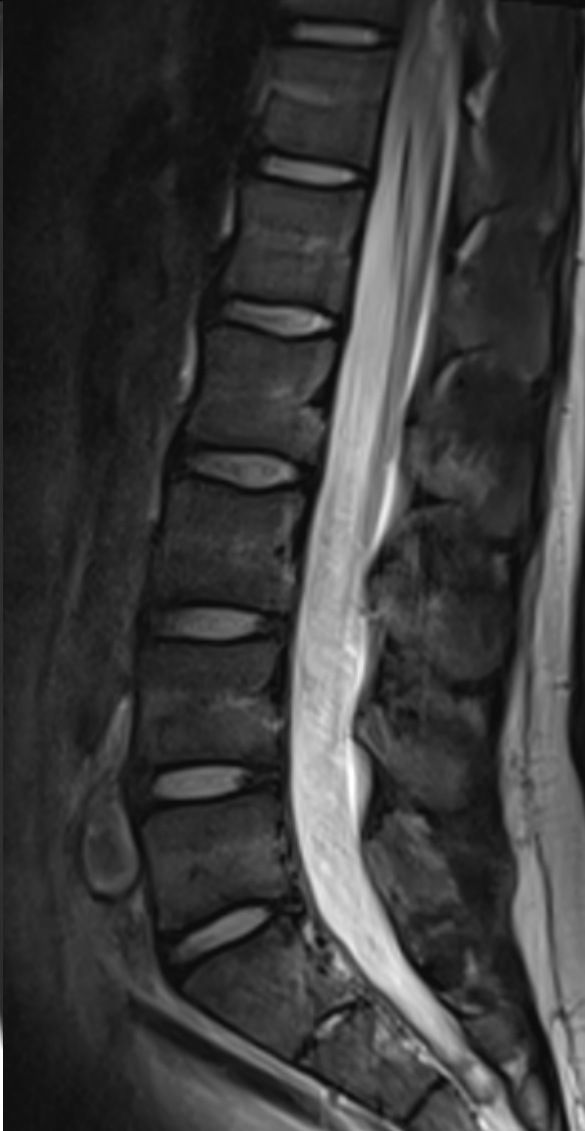
**SAINT-LUC**

UCL

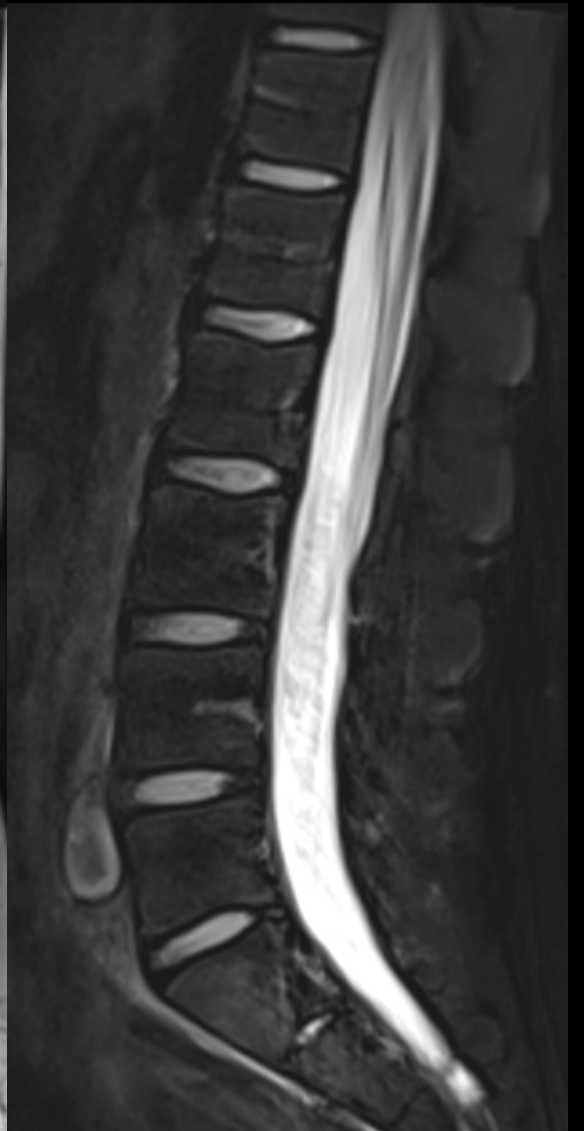BRUSSELS



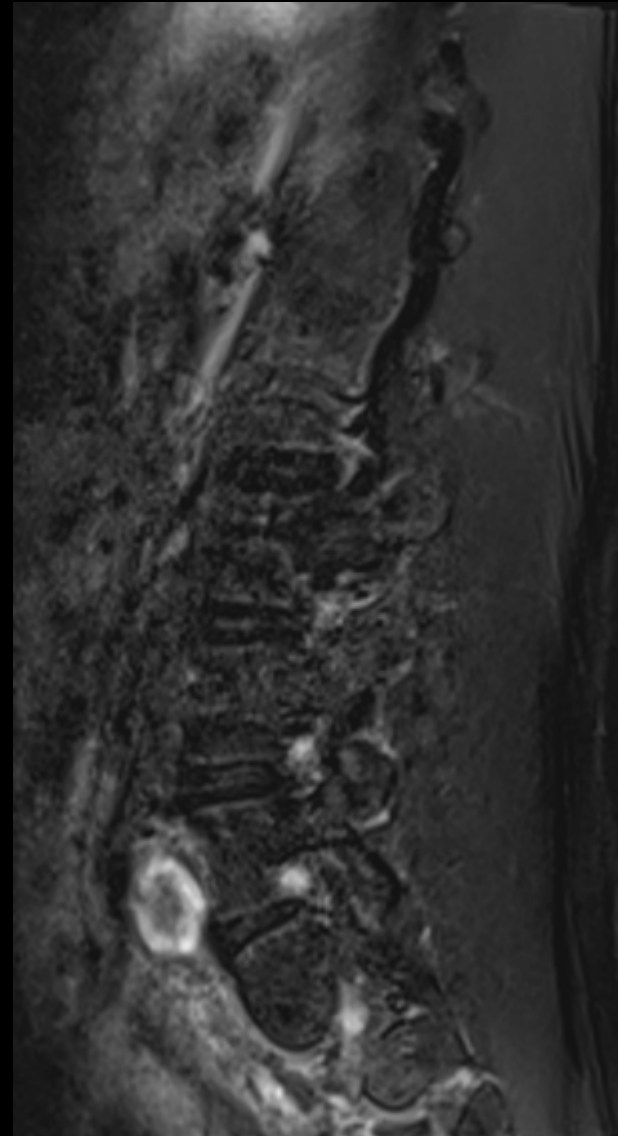
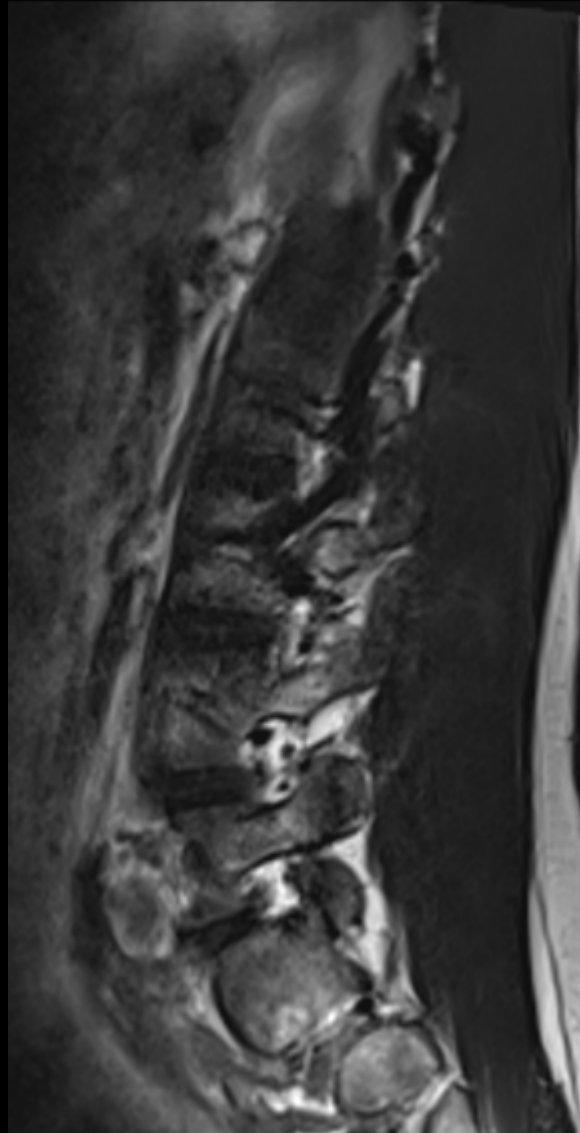
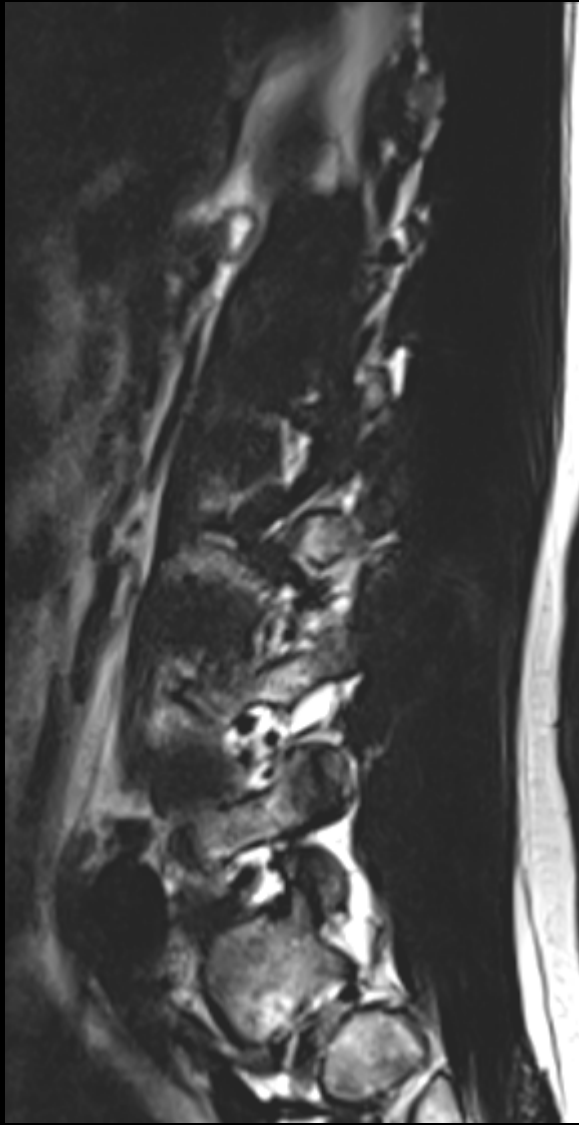
Fat only T2 dixon



T2 dixon In



water only T2 dix

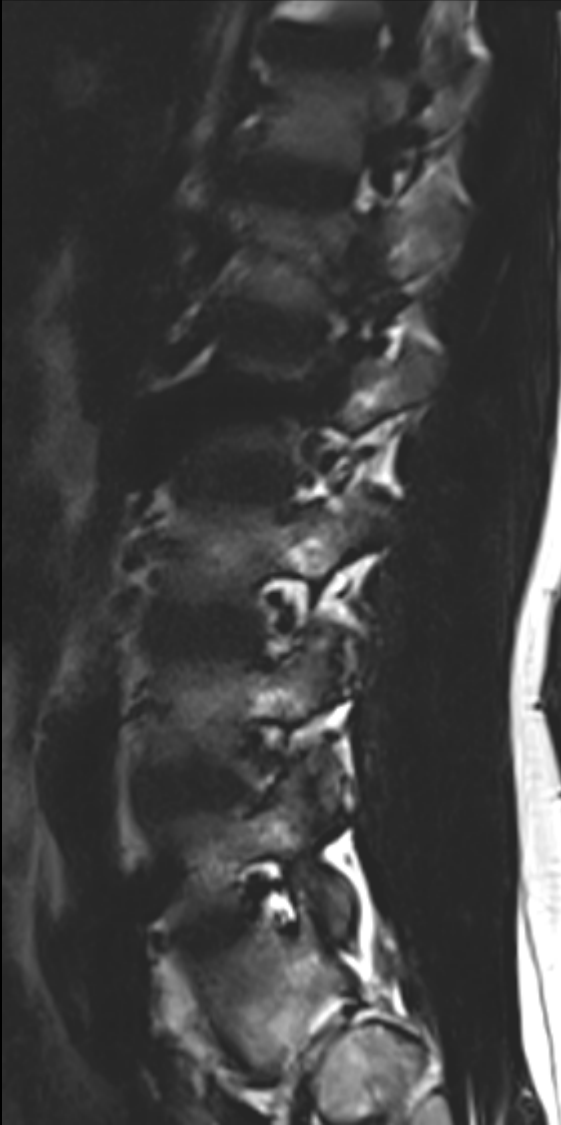


para médian Gauche  
Fat only T2 dixon

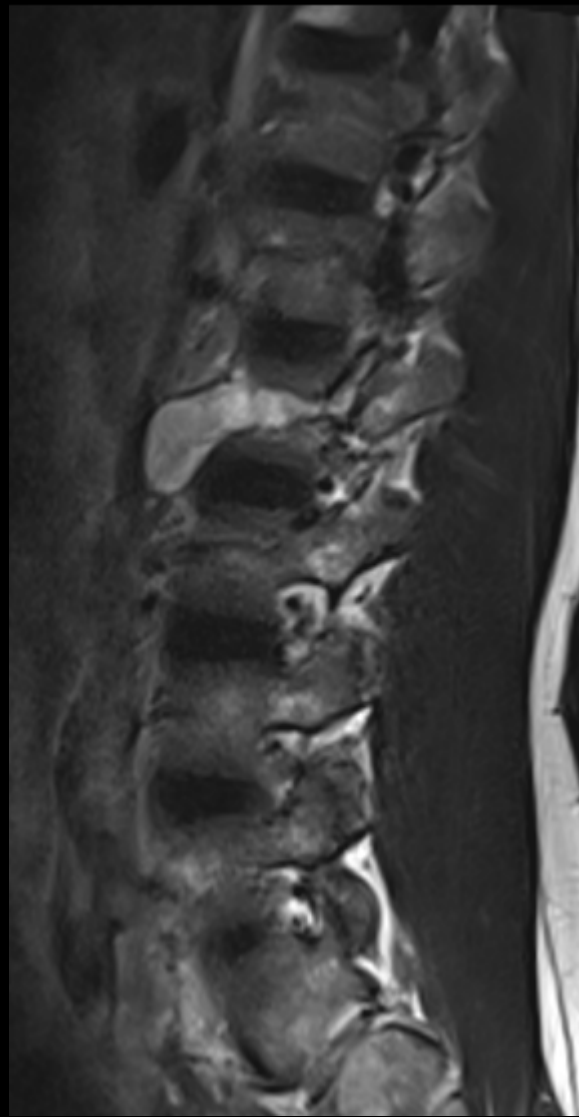
T2 dixon In

water only T2 dix

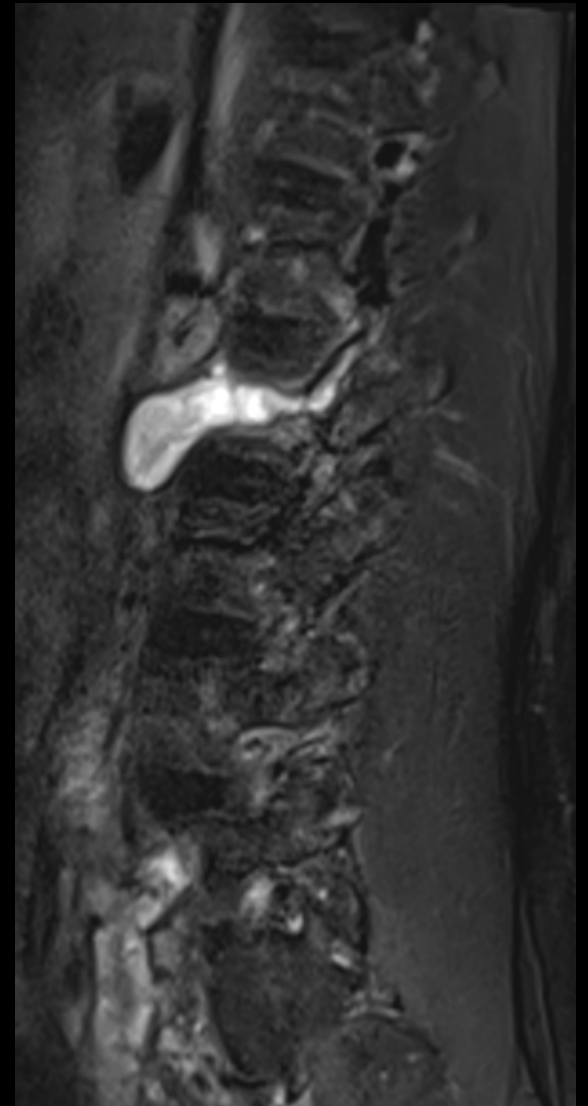27/01/2020



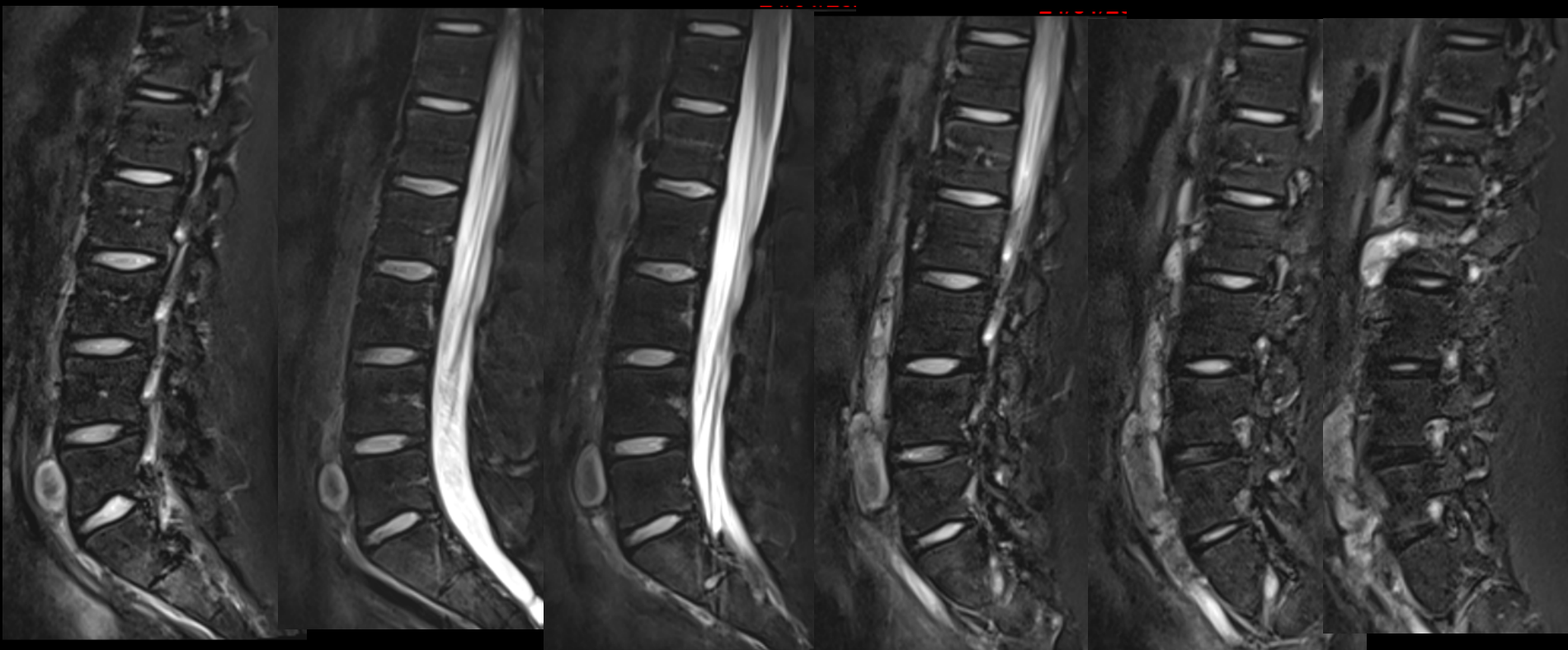
para médian droit  
Fat only T2 dixon



T2 dixon In



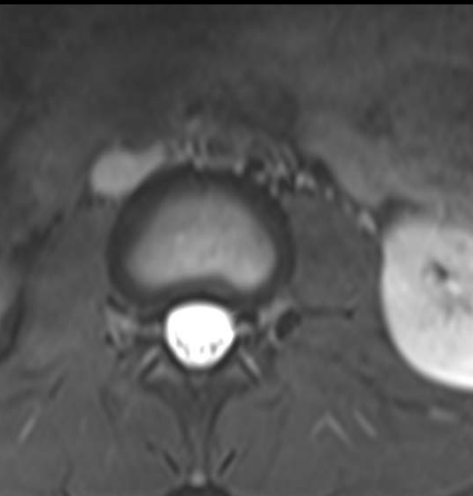
water only T2 dix



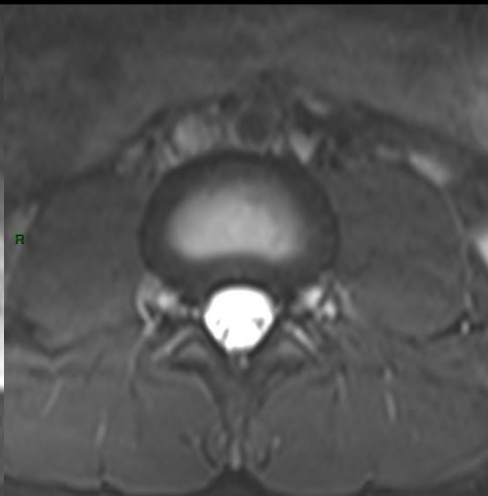
Para médian gauche

medial

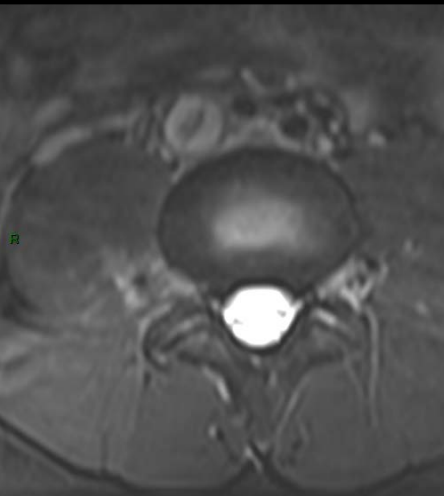
paramédian droit



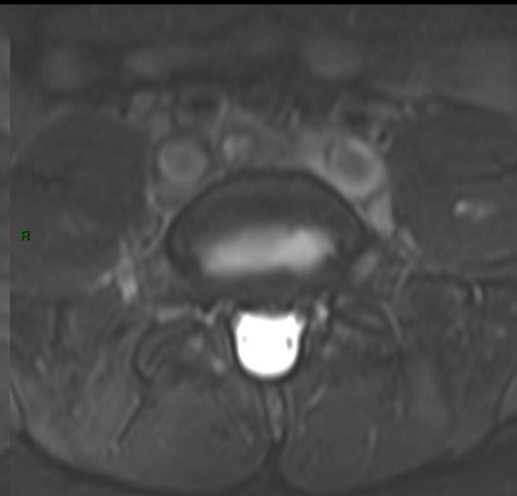
L2-L3



L3-L4



L4-L5



L5-S1

