

# SEMEIOLOGIE DE BASE DES ARTHROPATHIES

*T. Kirchgesner, S. Acid, J. Malghem, F. Lecouvet, B. Vande Berg*

Unité d'imagerie ostéo-articulaire des Cliniques universitaires Saint-Luc, Bruxelles




Cliniques universitaires  
**SAINT-LUC**  
UCL BRUXELLES

# OBJECTIF

- Savoir différencier deux grands cadres nosologiques:
  - Arthropathies mécaniques
  - Arthropathies inflammatoires
- Par une analyse des lésions élémentaires
- En se basant sur des cas cliniques illustratifs


# ARTHROPATHIE

ARTHROPATHIE




MECANIQUE

ARTHROPATHIE



MECANIQUE



INFLAMMATOIRE

ARTHROPATHIE

MECANIQUE

INFLAMMATOIRE

**ARTHROSE**

ARTHROPATHIE

MECANIQUE

INFLAMMATOIRE

**ARTHROSE**

**ARTHRITE**

# ARTHROPATHIE

MECANIQUE

INFLAMMATOIRE

**ARTHROSE**

**ARTHRITE**

TYPIQUE

ATYPIQUE

- Érosive
- Destructrice rapide



# ARTHROPATHIE

MECANIQUE

INFLAMMATOIRE

**ARTHROSE**

**ARTHRITE**

TYPIQUE

ATYPIQUE

- Érosive
- Destructrice rapide

SEPTIQUE

- germe classique
- mycobactéries

RHUMATISMALE

- PR
- séronégative

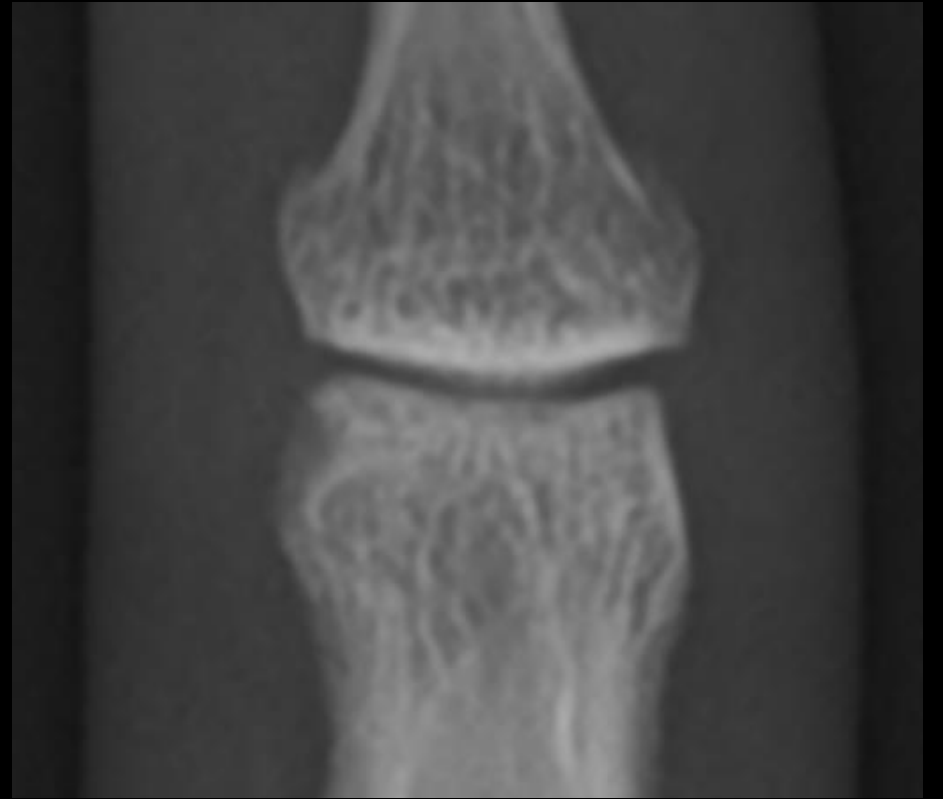
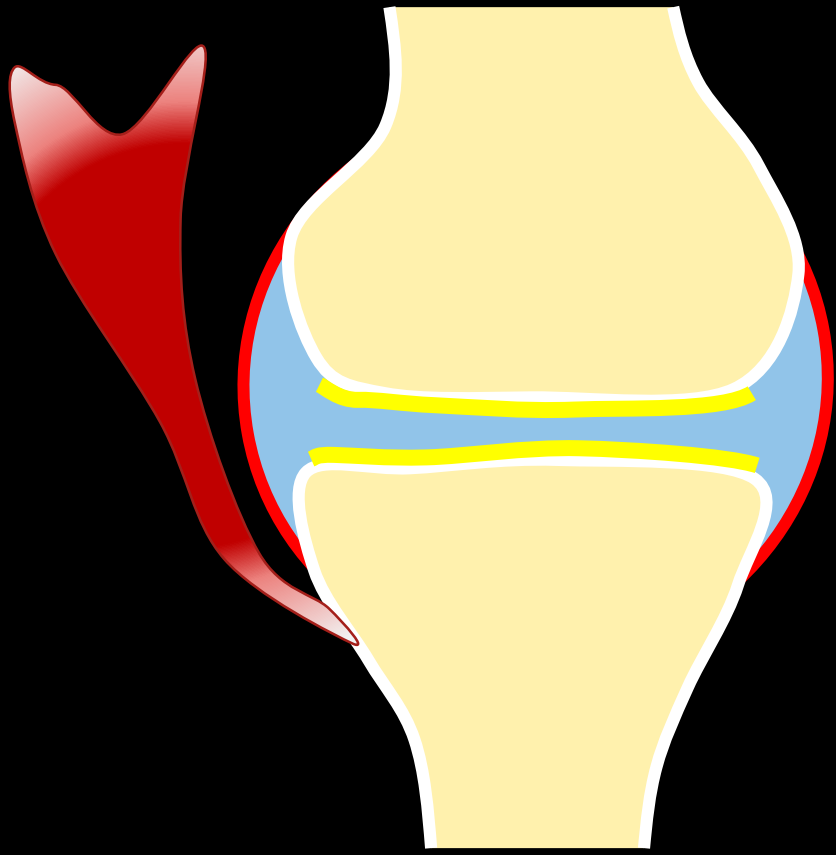
MICROCRISTALLINE

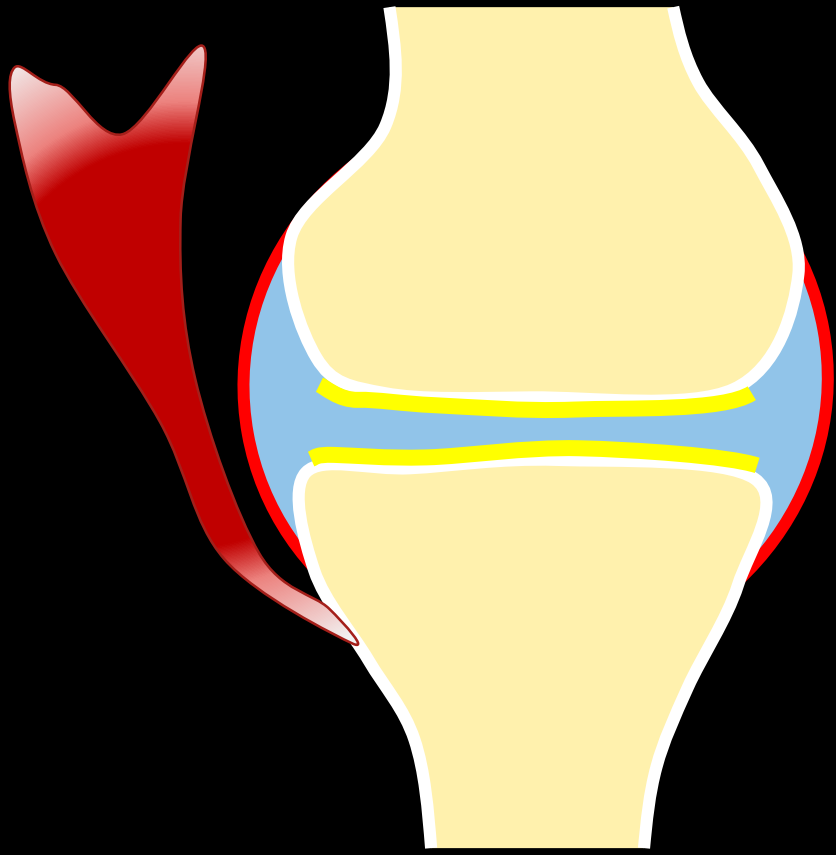
- Goutte
- Chondrocalcinose

**ARTHROSE**

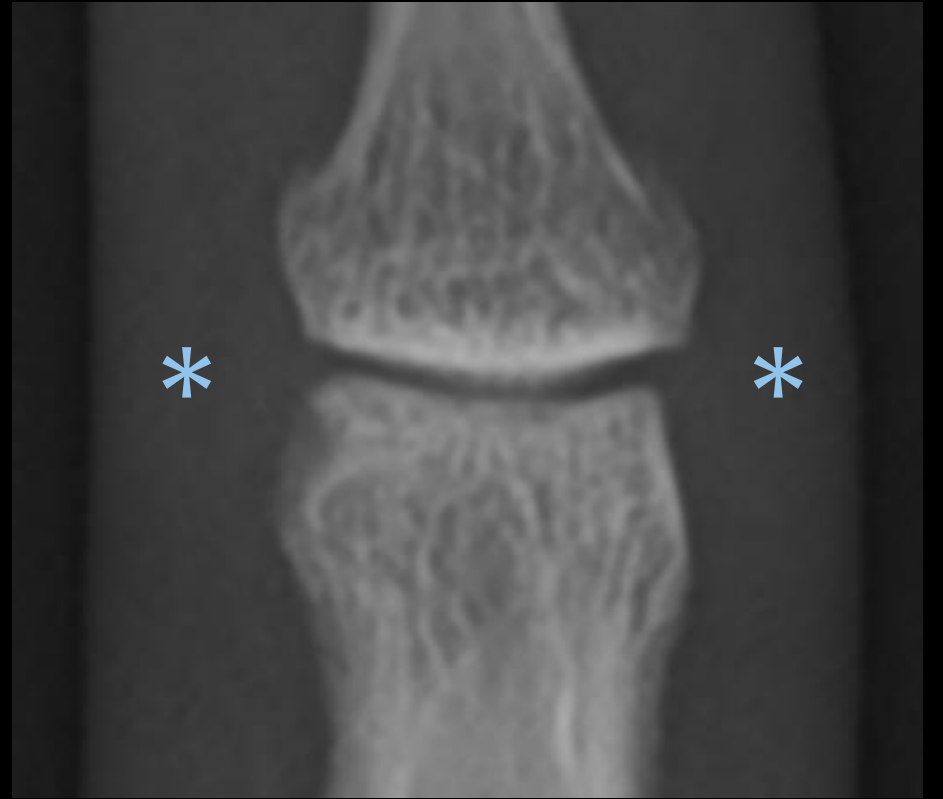
?

**ARTHRITE**

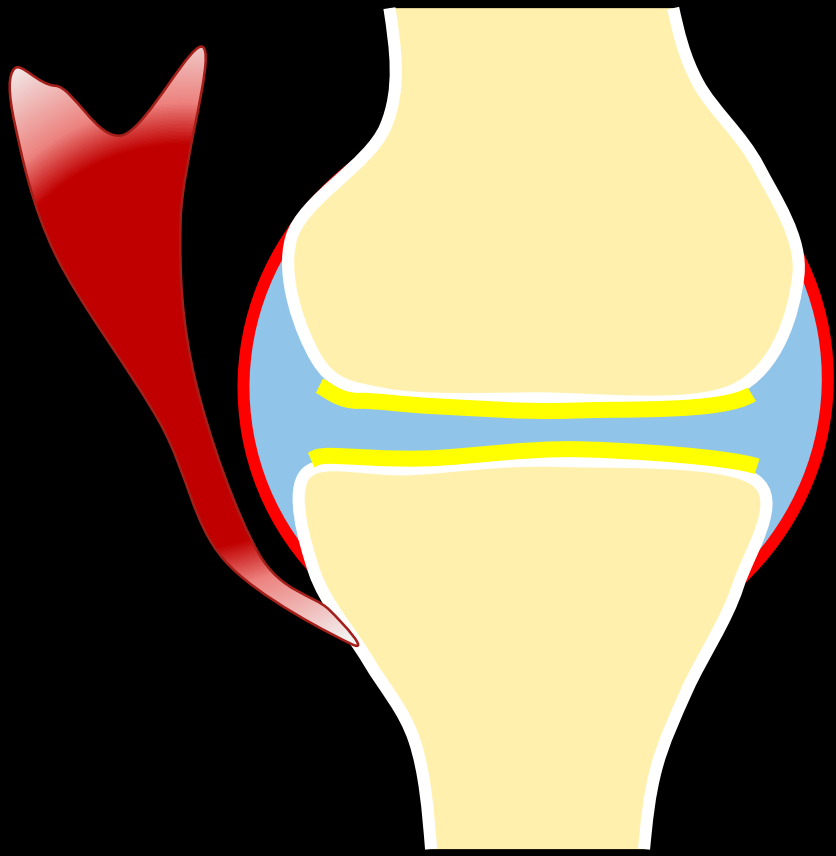




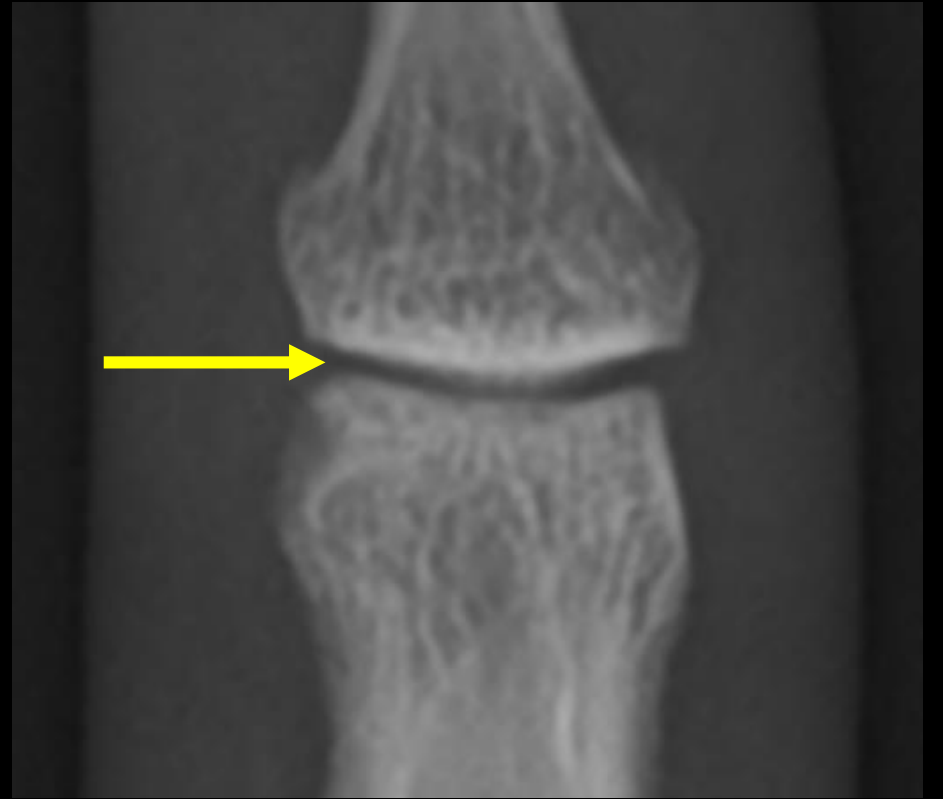
Synoviale (capsule et liquide articulaire,  
gaine tendineuse...)



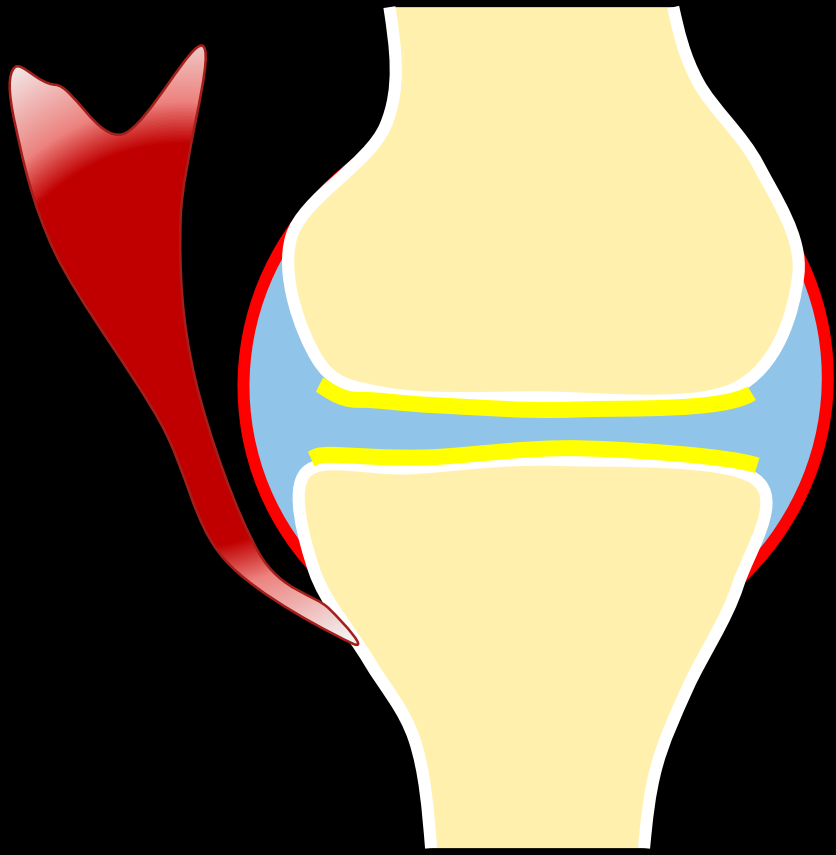
TISSUS MOUS



Synoviale  
Cartilage



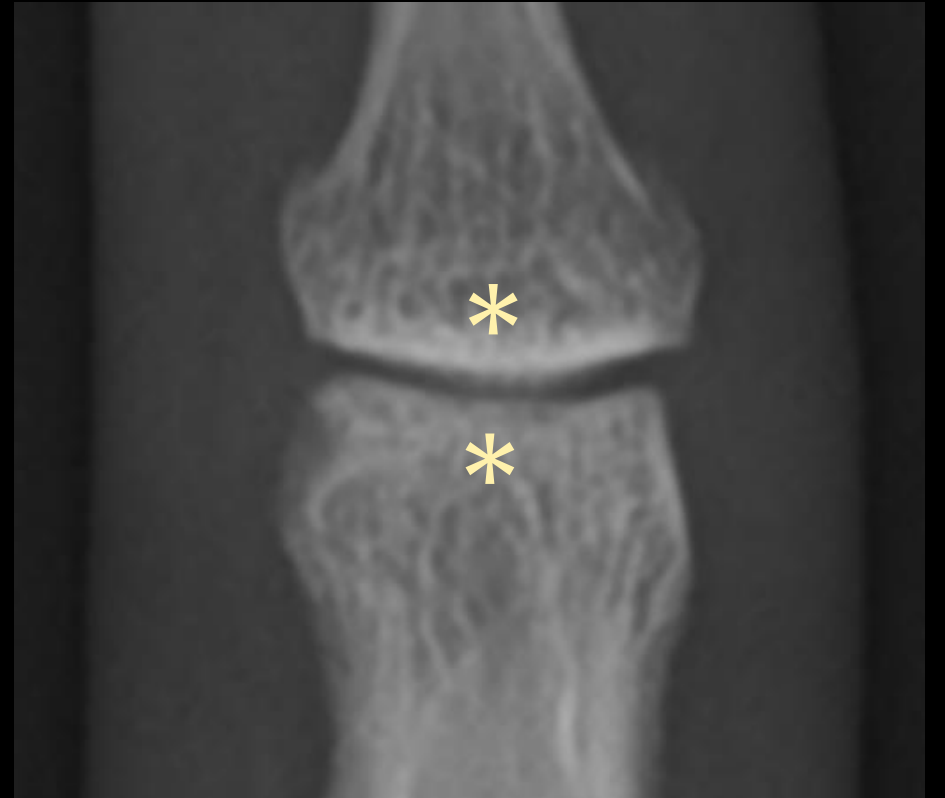
TISSUS MOUS  
INTERLIGNE ARTICULAIRE



Synoviale

Cartilage

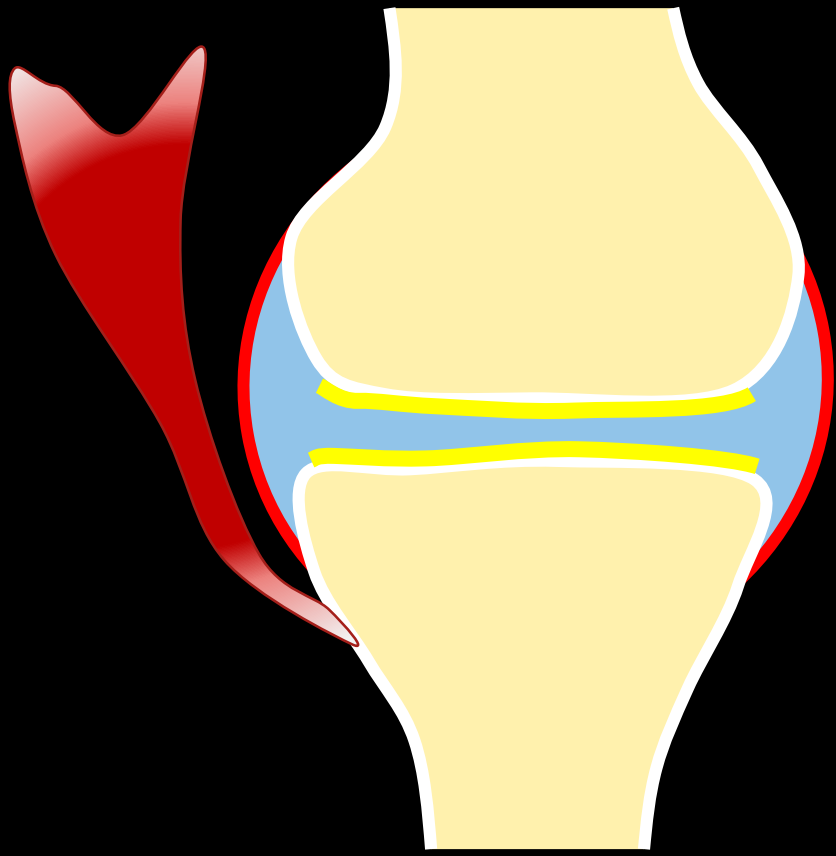
Os sous-chondral



TISSUS MOUS

INTERLIGNE ARTICULAIRE

OS SOUS-CHONDRALE

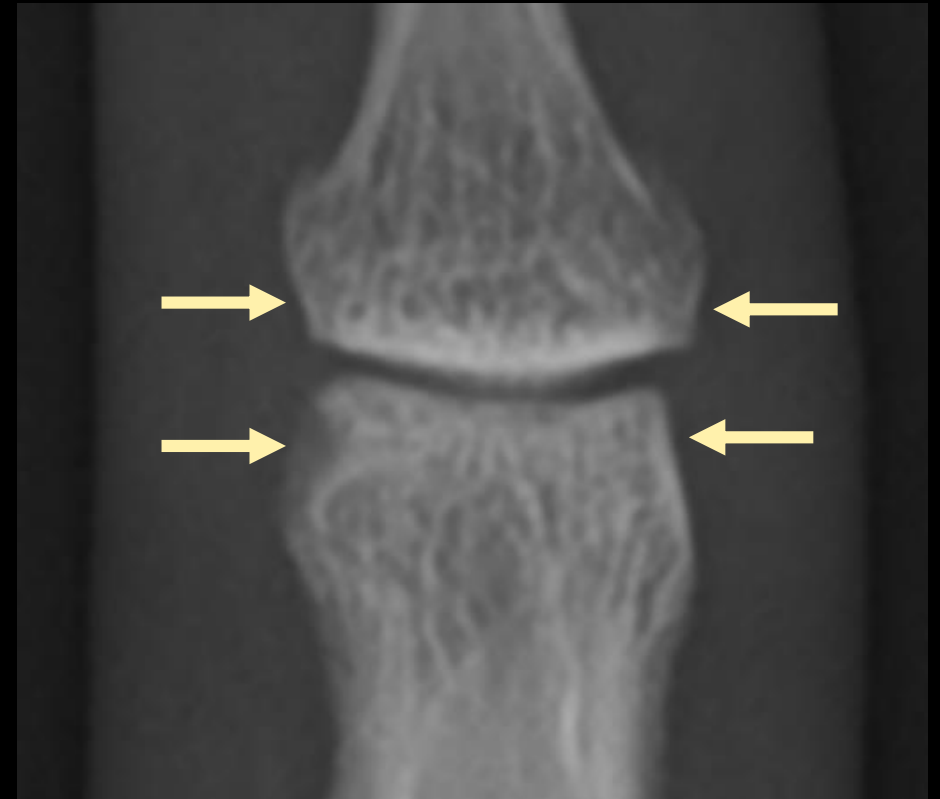


Synoviale

Cartilage

Os sous-chondral

Os marginal

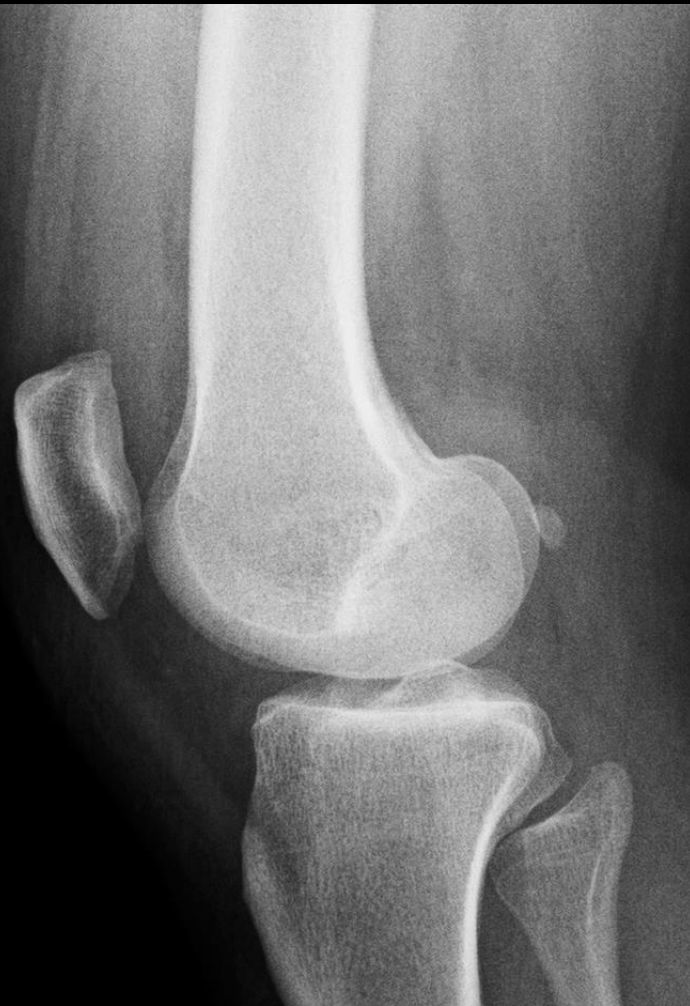

TISSUS MOUS

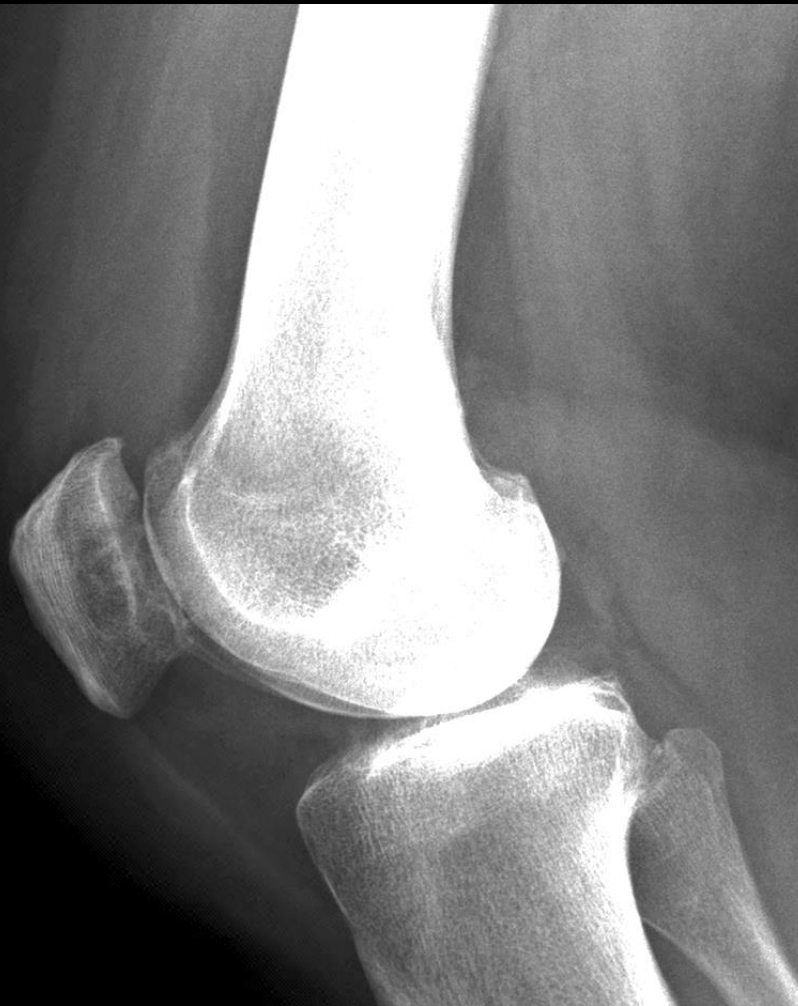INTERLIGNE ARTICULAIRE

OS SOUS-CHONDRAL

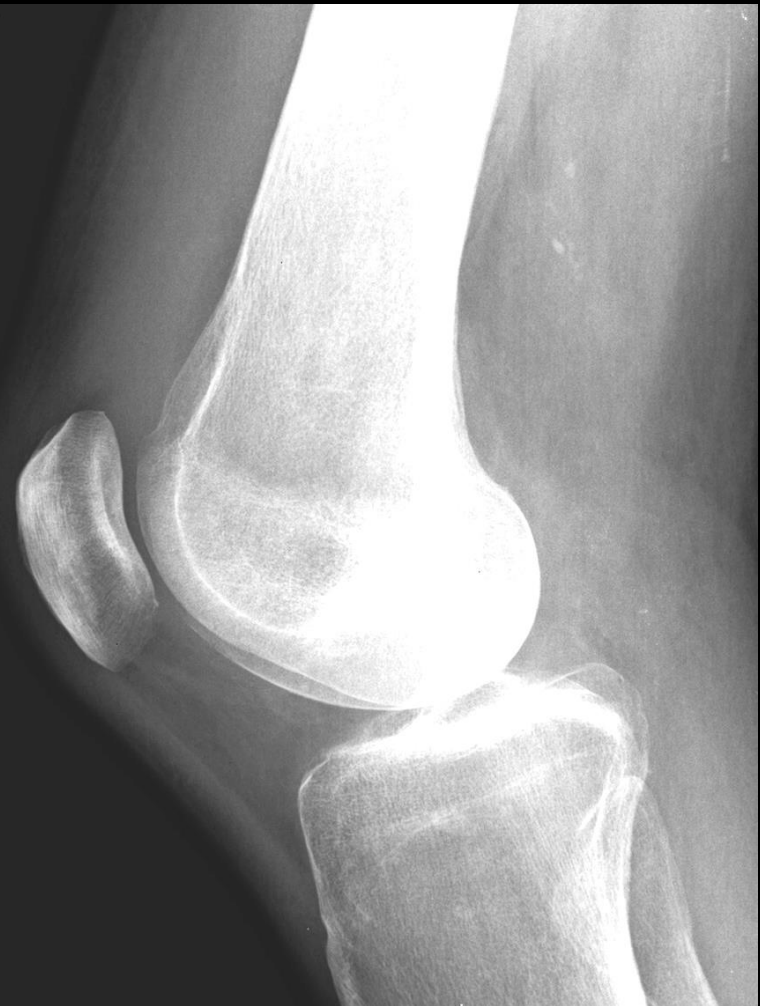OS MARGINAL



Tuméfaction articulaire?  
A – Oui  
B – Non

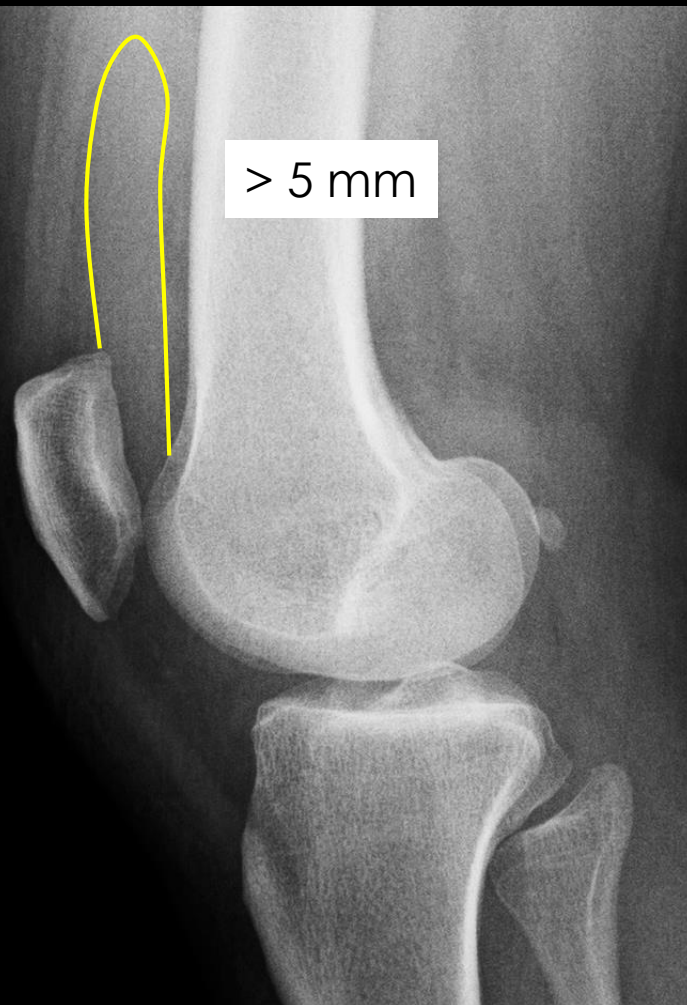


Tuméfaction articulaire?  
A – Oui  
B – Non

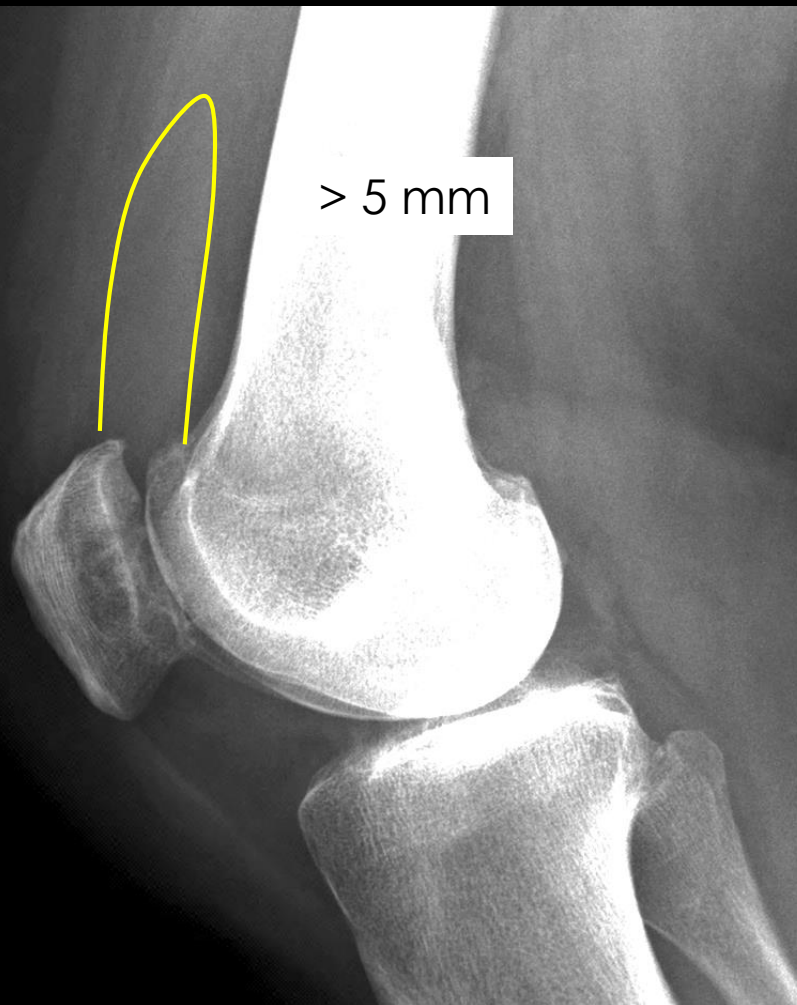


Tuméfaction articulaire?  
A – Oui  
B – Non

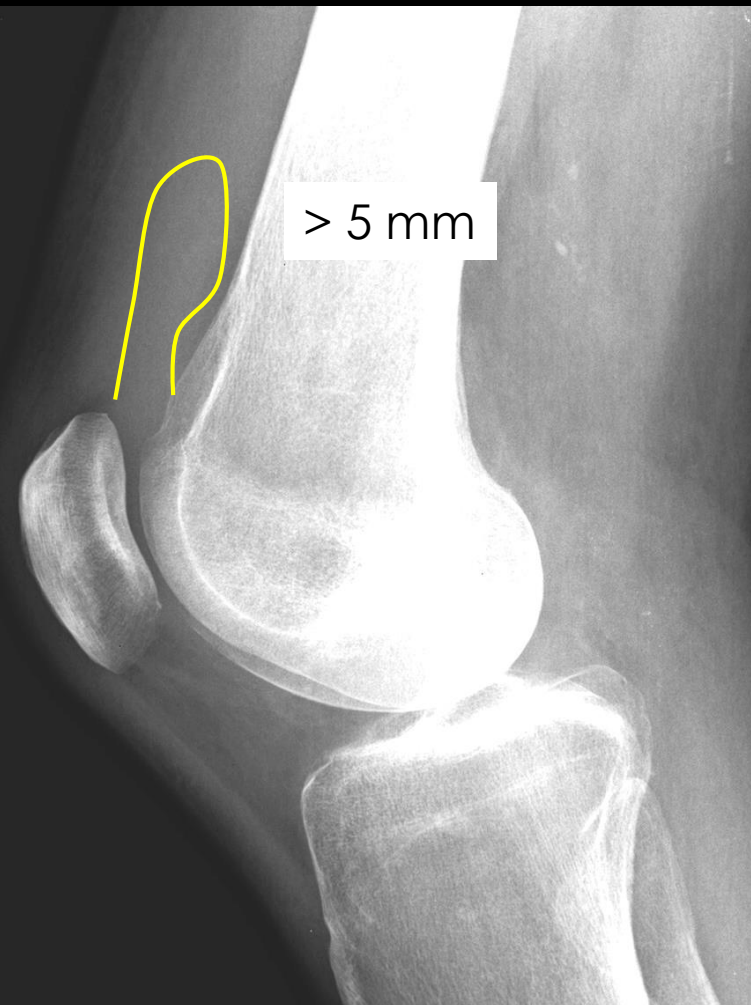




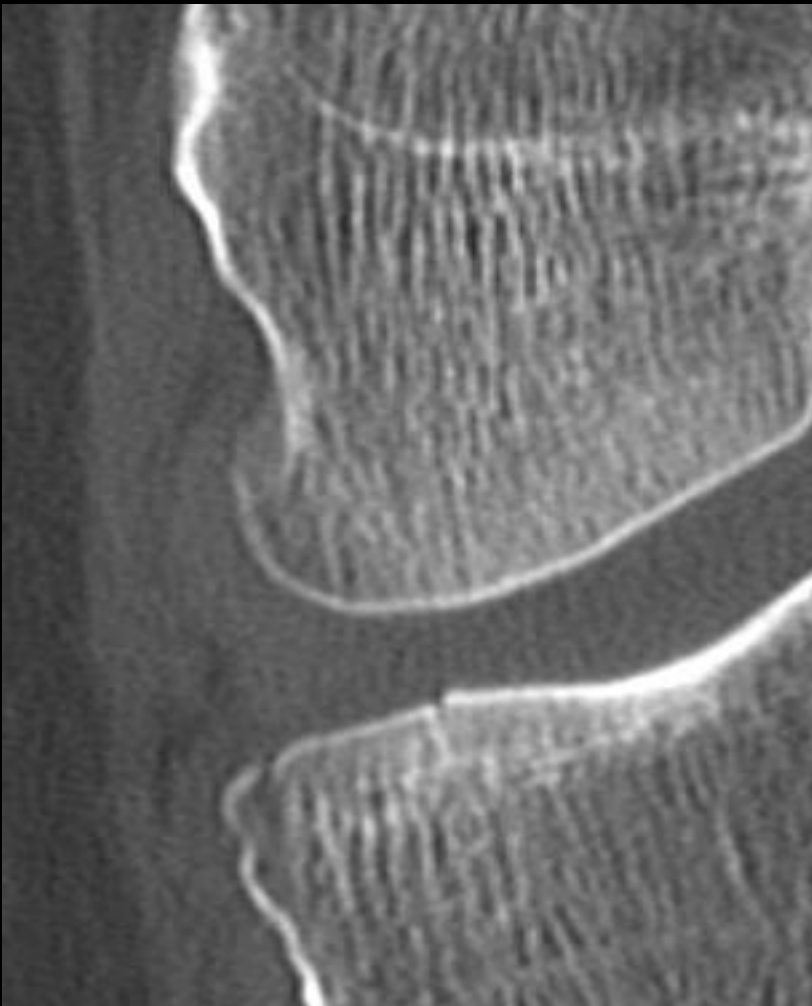
Tuméfaction articulaire?  
A – Oui  
B – Non



Tuméfaction articulaire?  
A – Oui  
B – Non



Tuméfaction articulaire?  
A – Oui  
B – Non

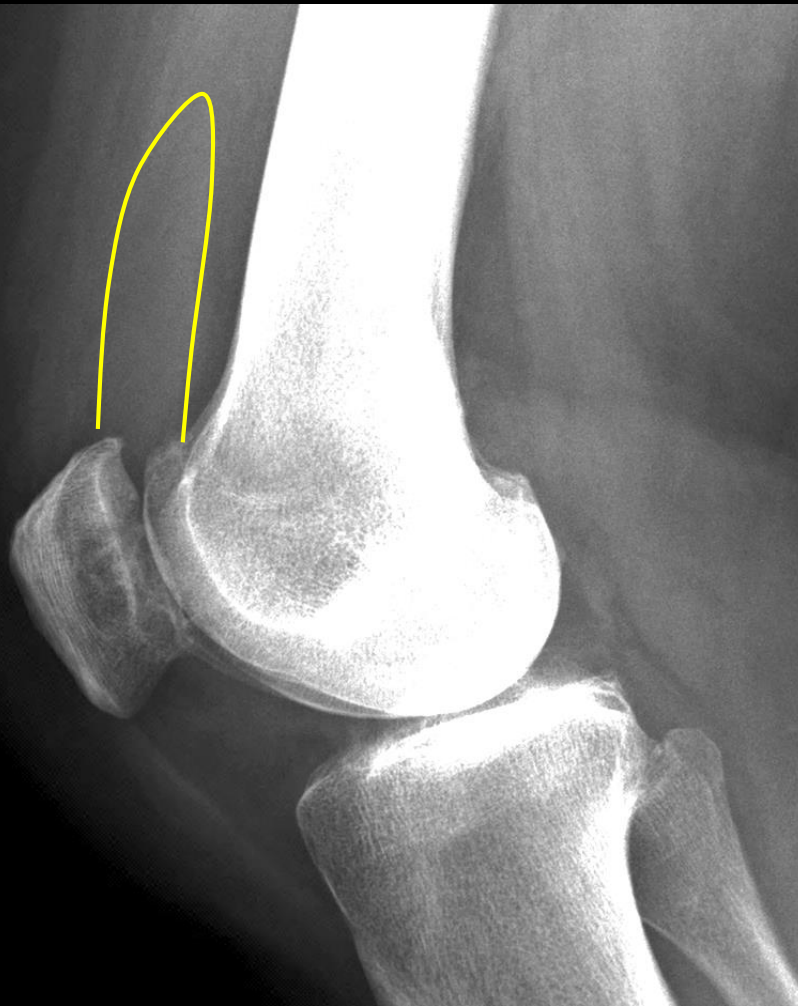

Tuméfaction articulaire?

A – Oui

B – Non

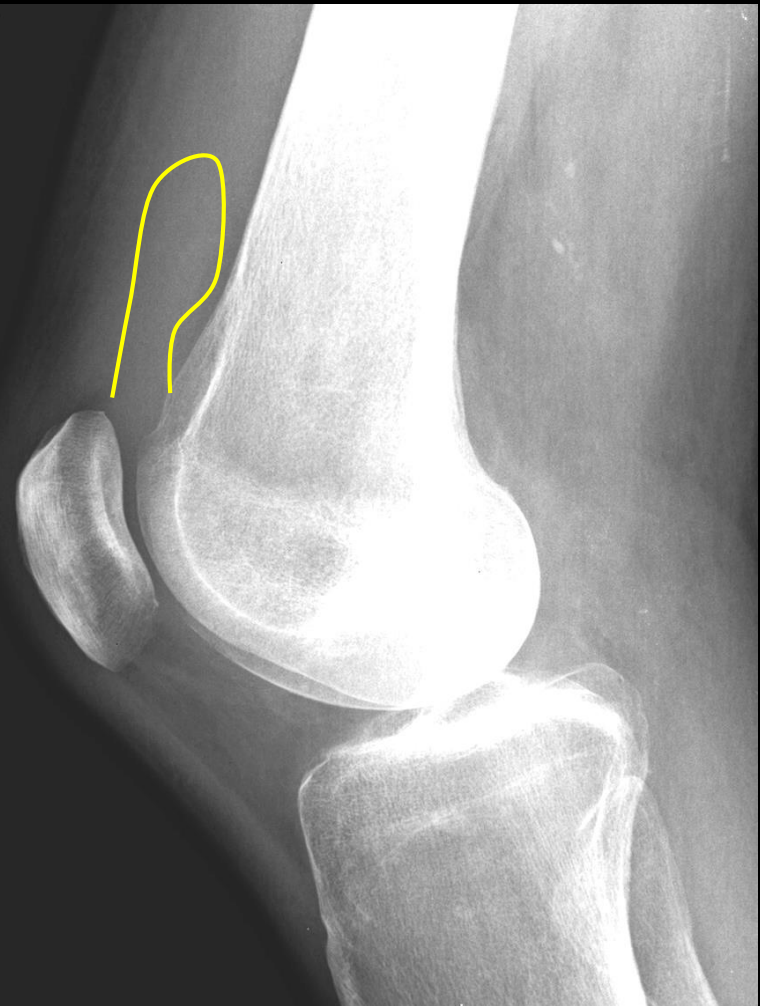*fracture*



Tuméfaction articulaire?

A – Oui

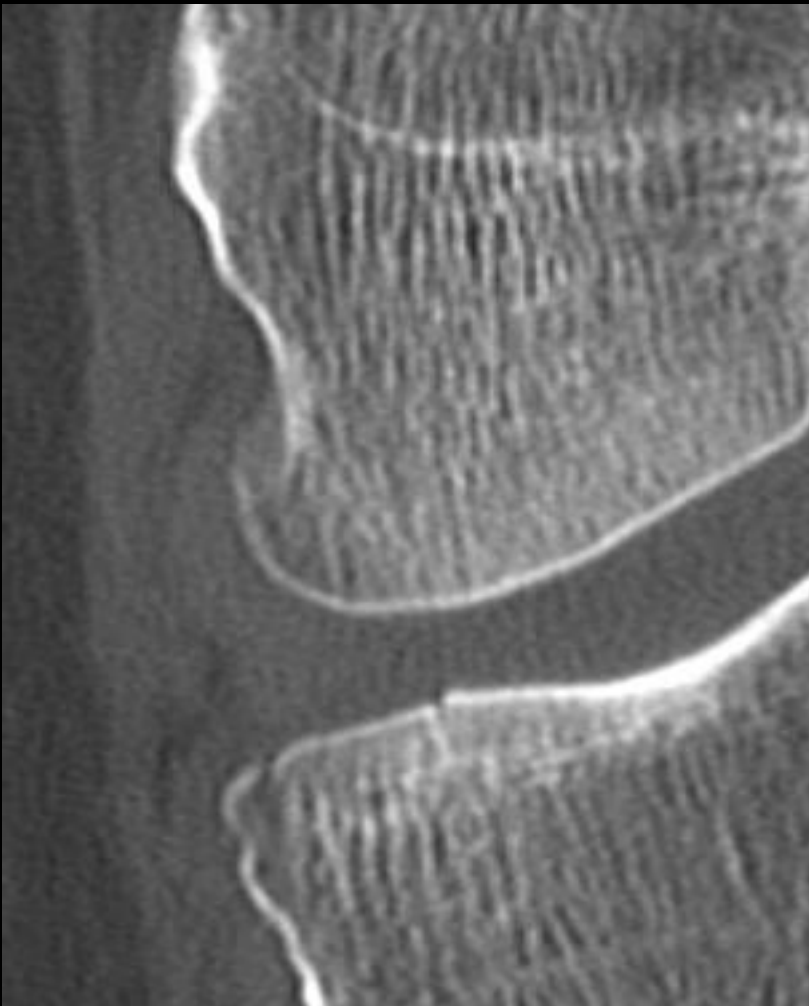
B – Non



Tuméfaction articulaire?

A – Oui

B – Non

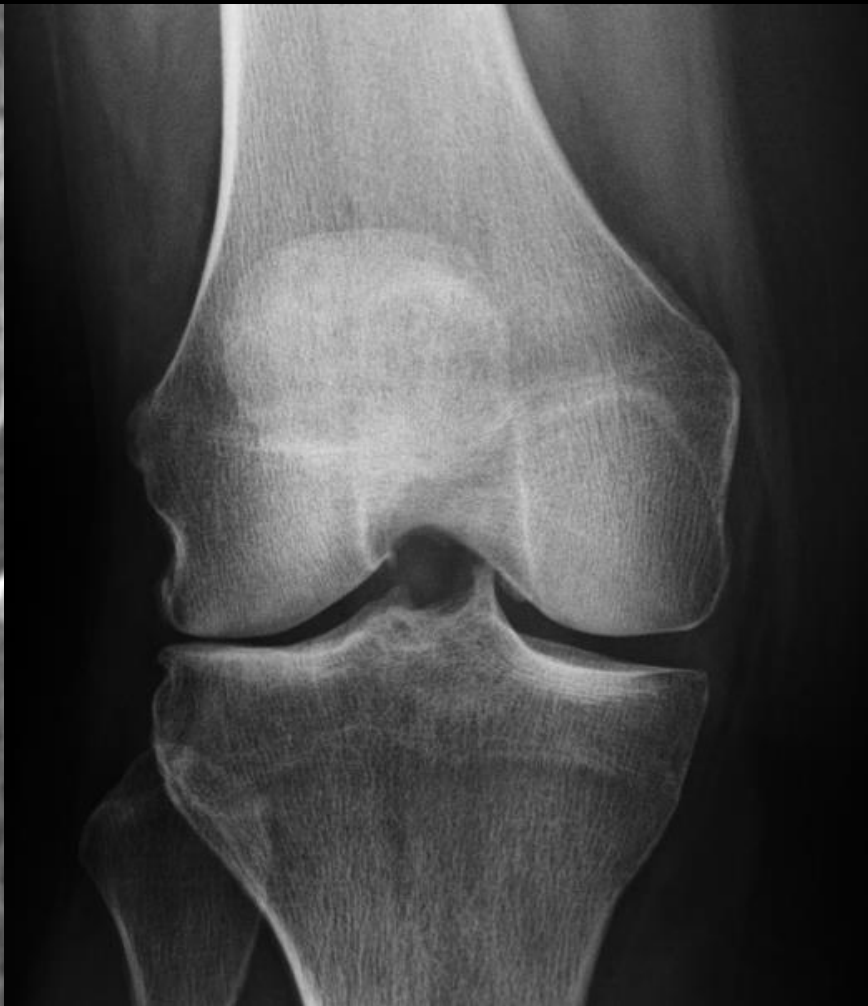

Tuméfaction articulaire?

A – Oui

B – Non

*fracture*

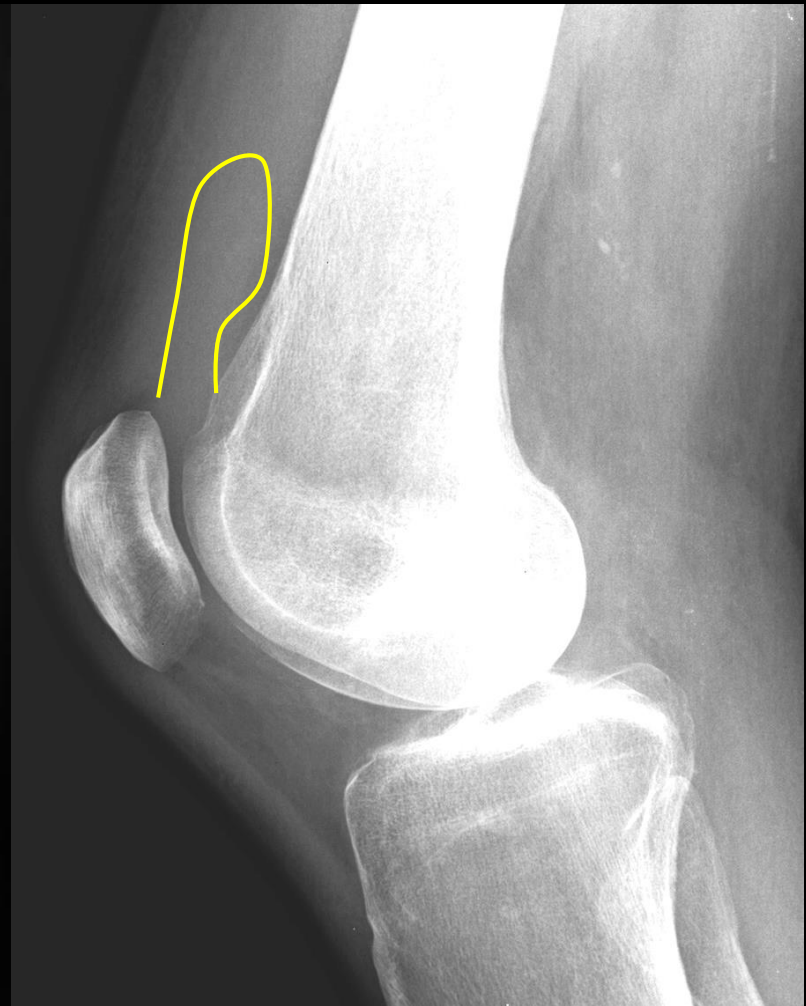

Tuméfaction articulaire?

A – Oui

B – Non

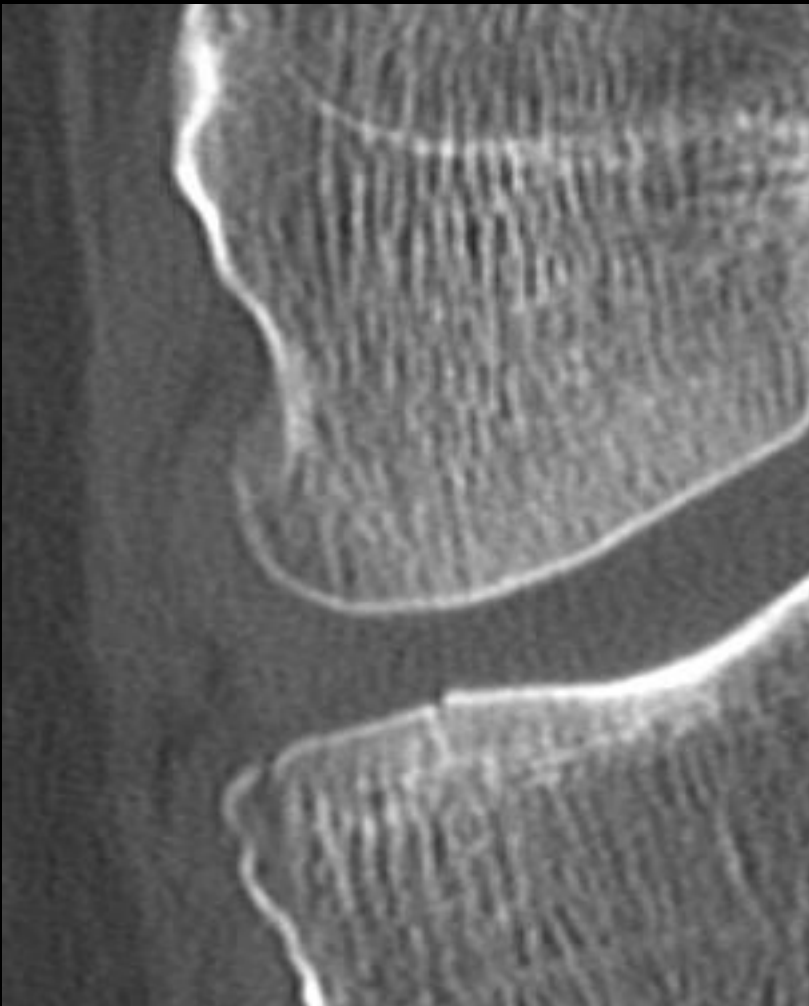
*arthrose*



Tuméfaction articulaire?

A – Oui

B – Non



Tuméfaction articulaire?

A – Oui

B – Non

*fracture*

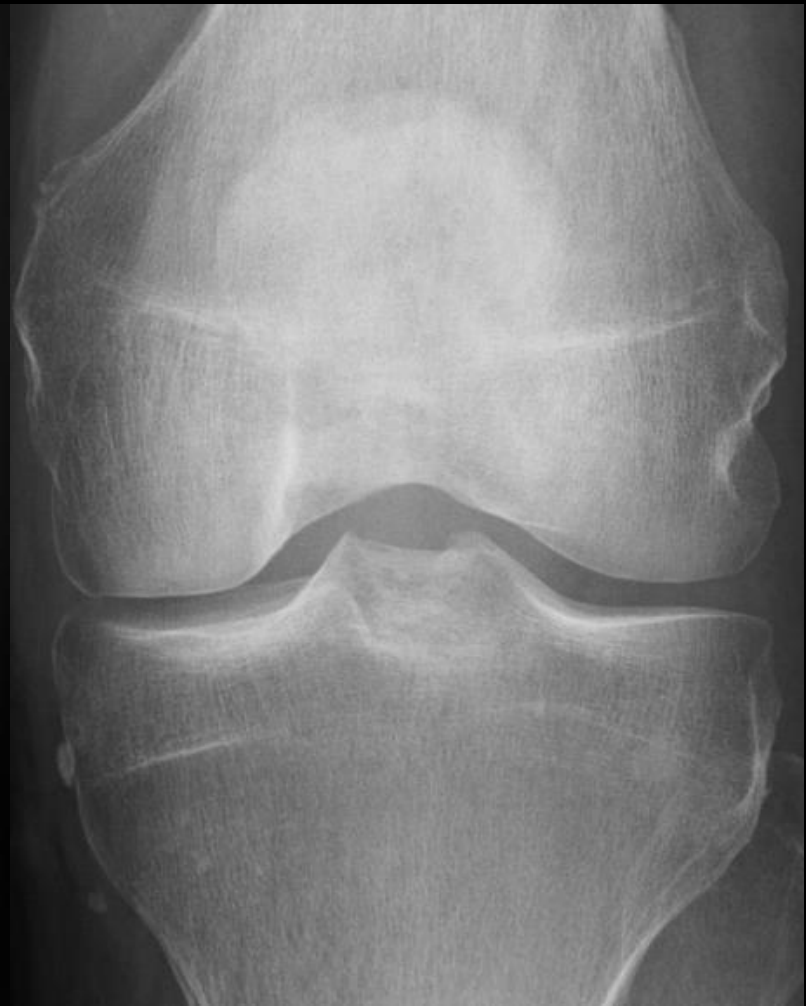

Tuméfaction articulaire?

A – Oui

B – Non

*arthrose*

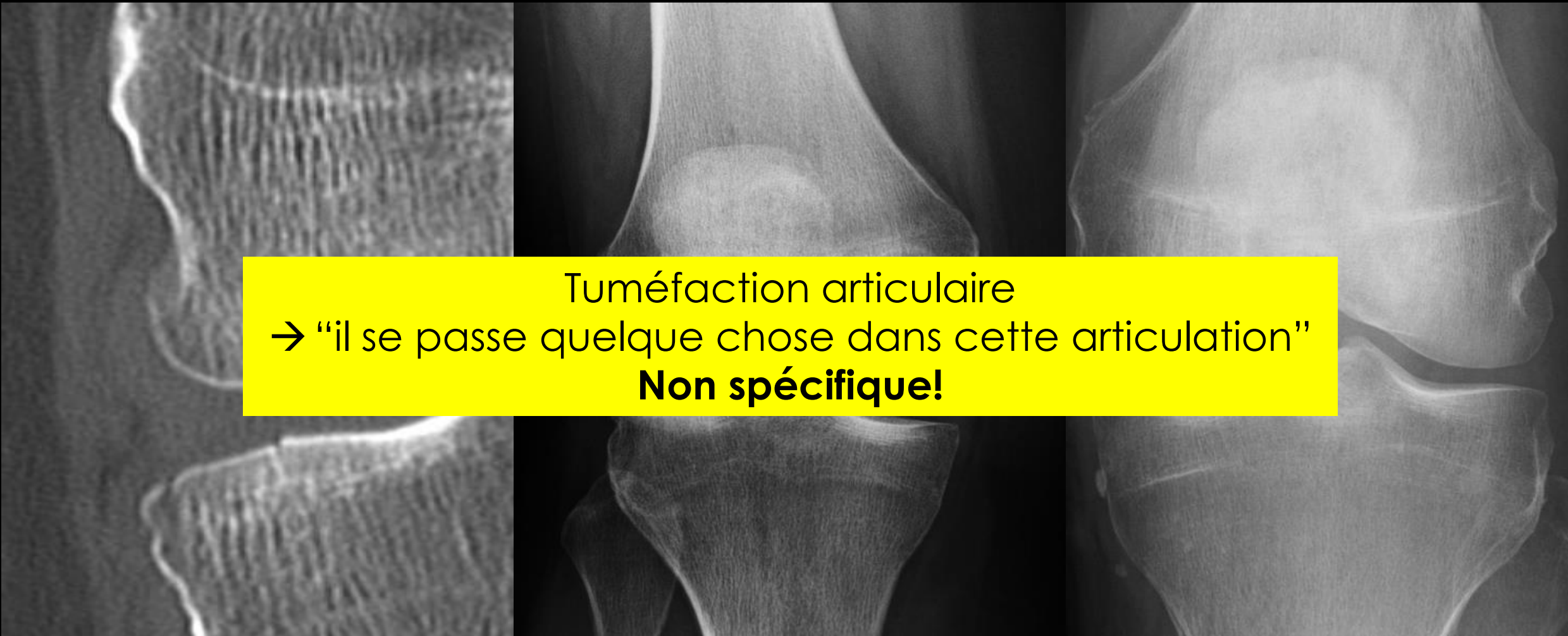


Tuméfaction articulaire?

A – Oui

B – Non

*arthrite*



Tuméfaction articulaire  
→ “il se passe quelque chose dans cette articulation”  
**Non spécifique!**

Tuméfaction articulaire?

A – **Oui**

B – Non

*fracture*

Tuméfaction articulaire?

A – **Oui**

B – Non

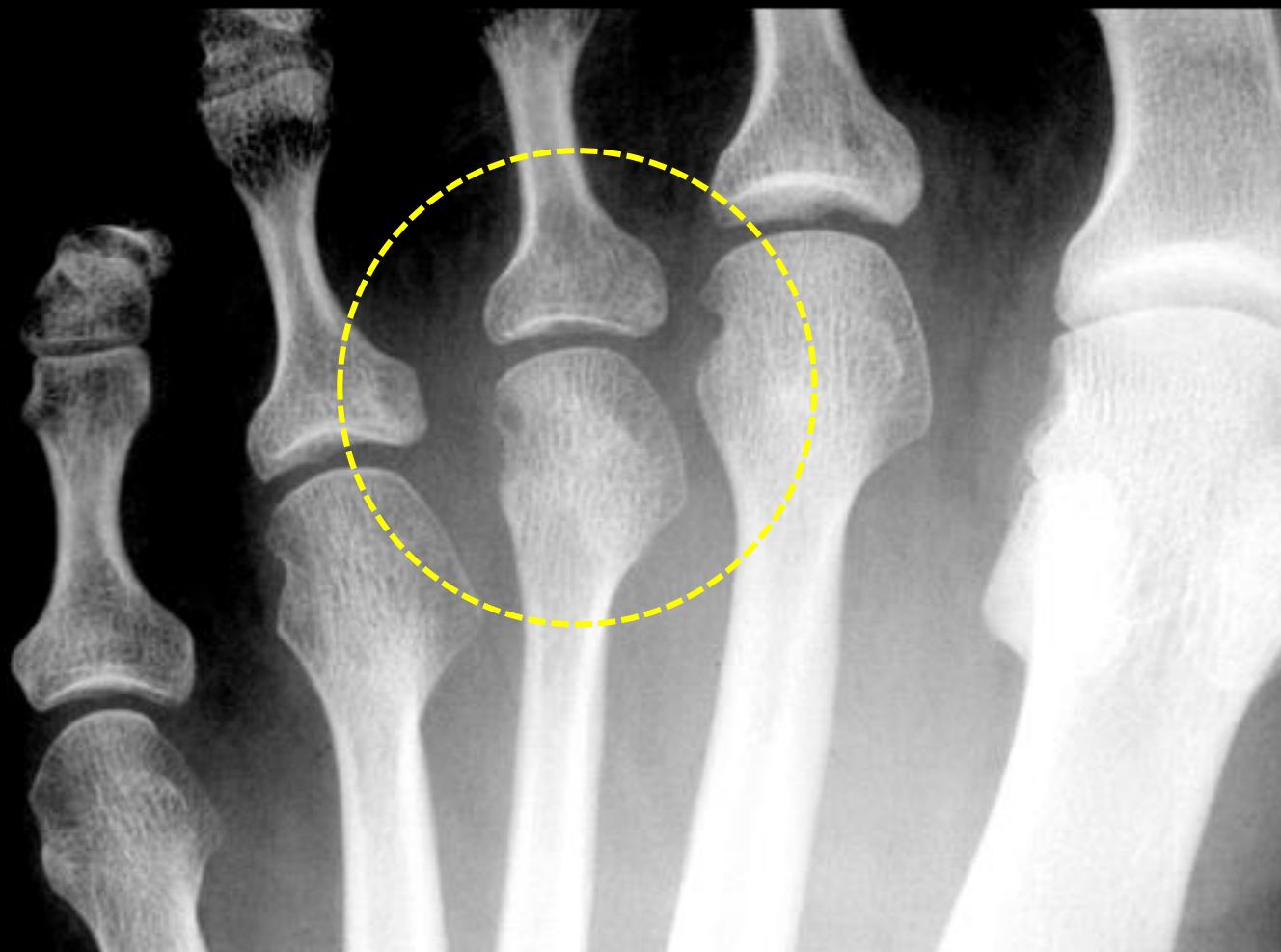
*arthrose*

Tuméfaction articulaire?

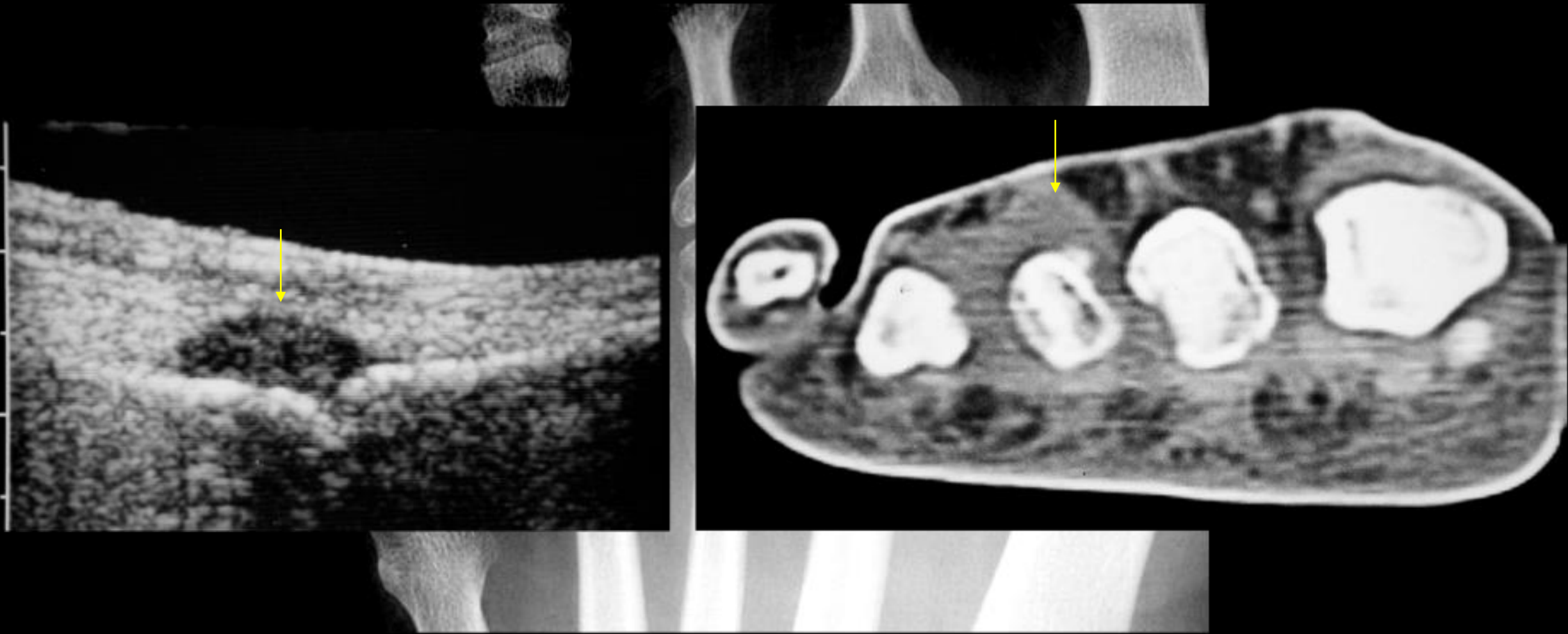
A – **Oui**

B – Non

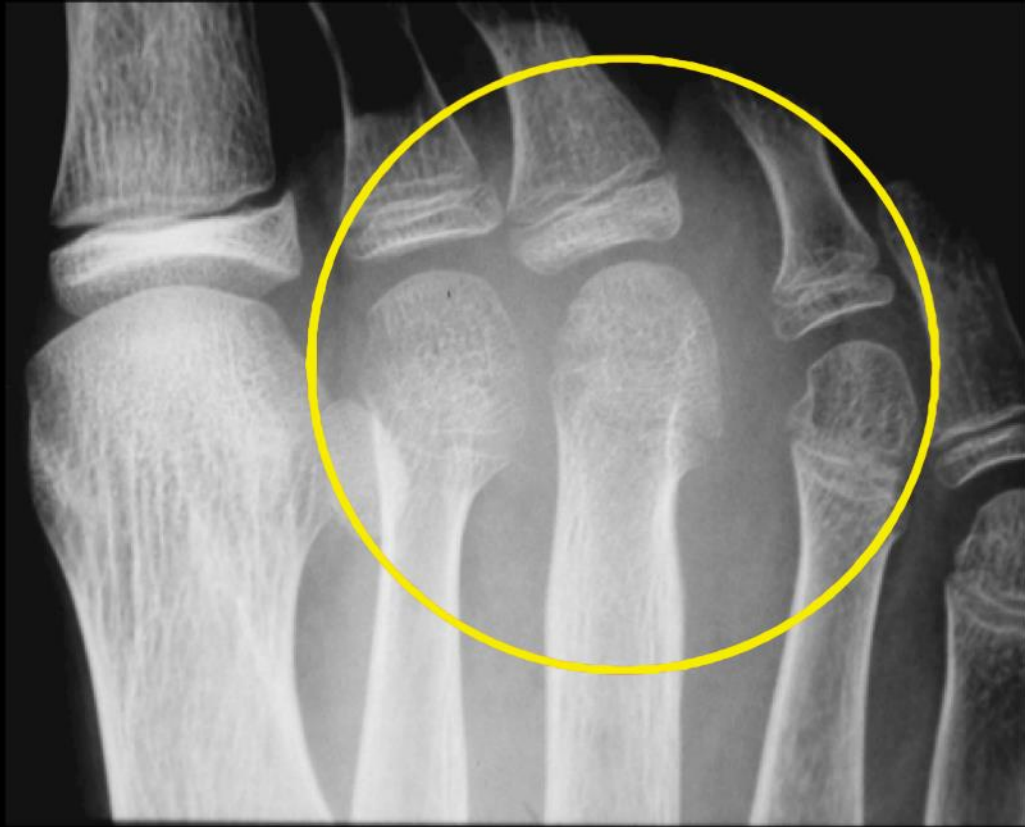*arthrite*



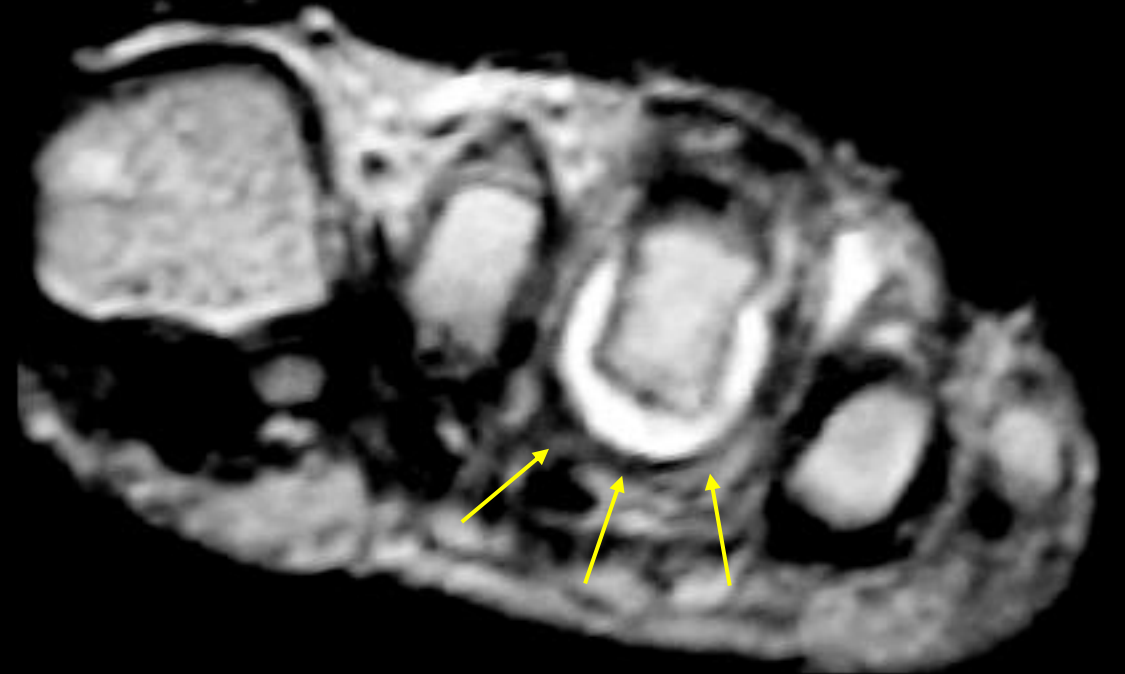Tuméfaction?



*Tuméfaction MTP R3D en US & CT*

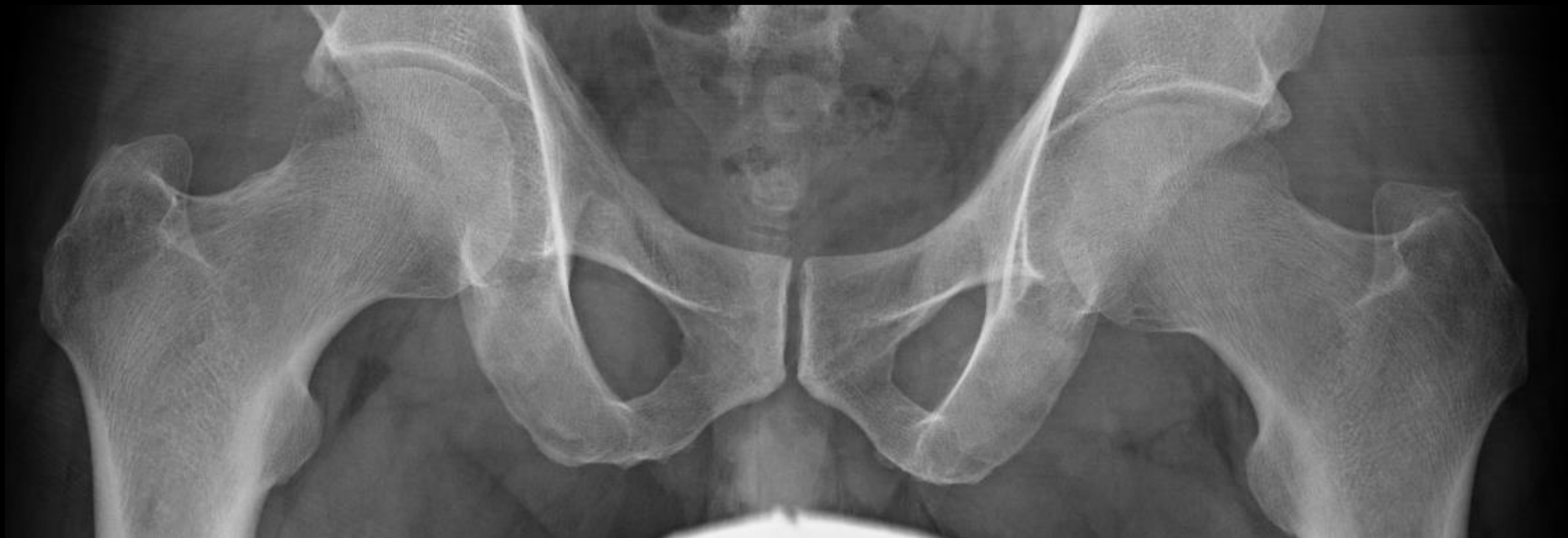

RX (chondrolyse)



IRM (tuméfaction)





Quelle est la hanche pathologique?

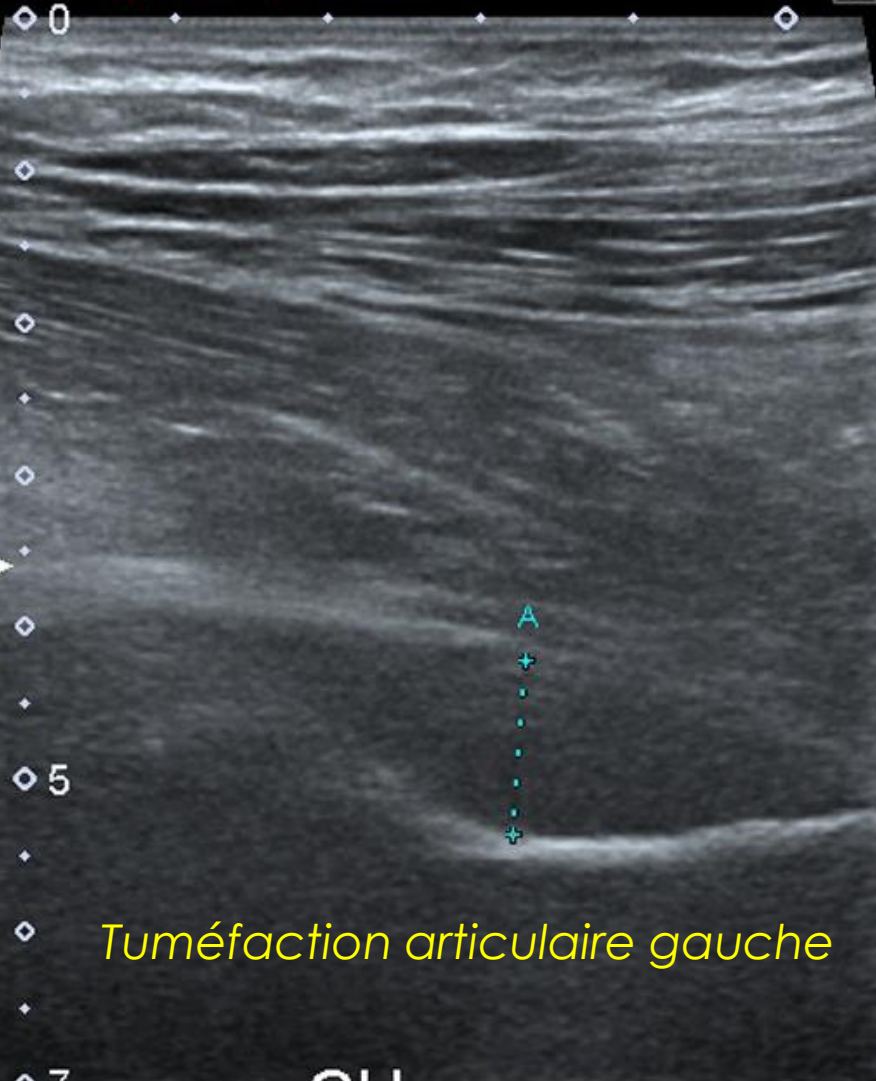
A Pure+ Precision

T

Precision A Pure+

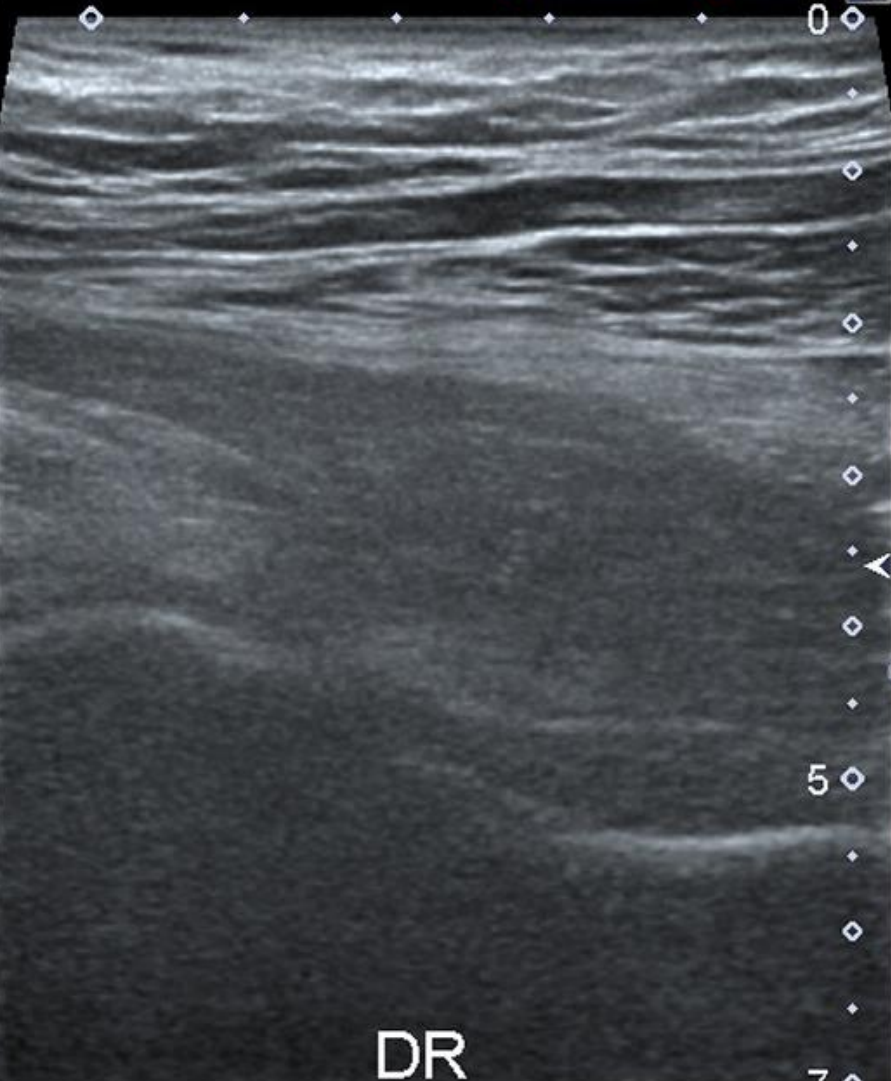
T

12L5  
diffT8.0  
23 fps  
G:92  
DR:70  
A:5  
P:2



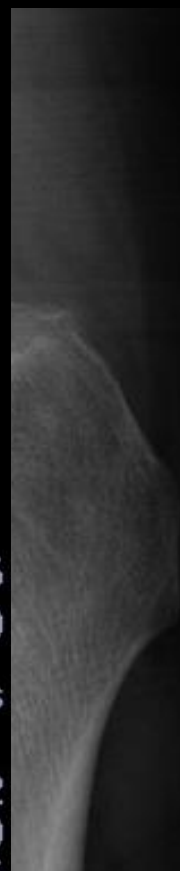*Tuméfaction articulaire gauche*

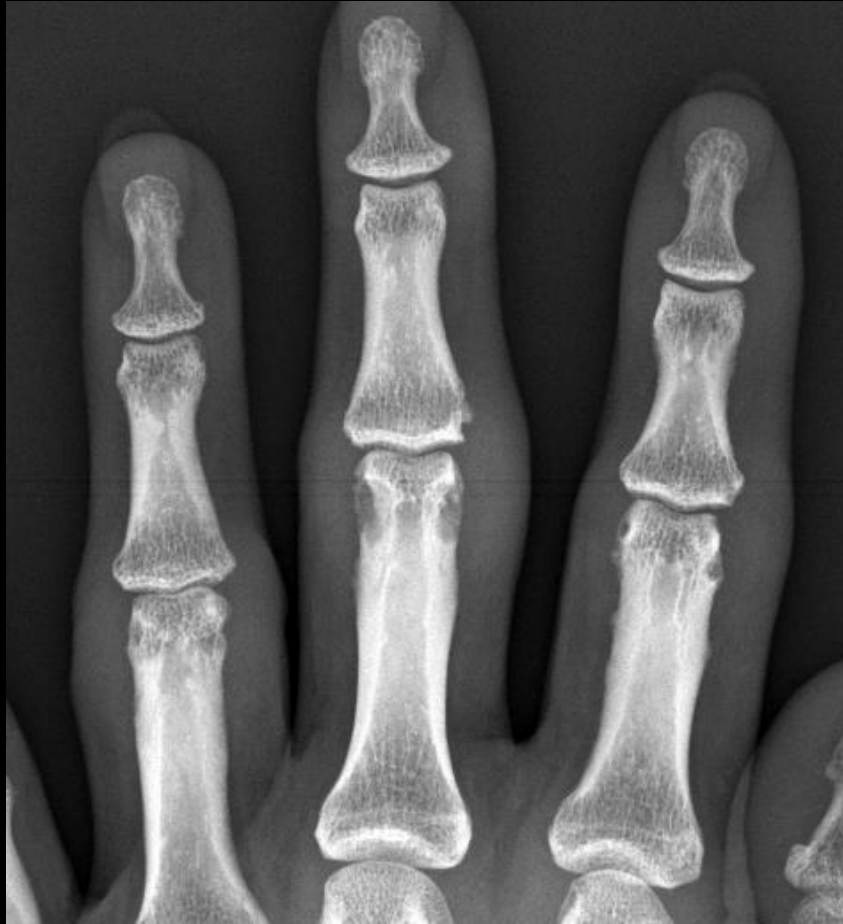GH



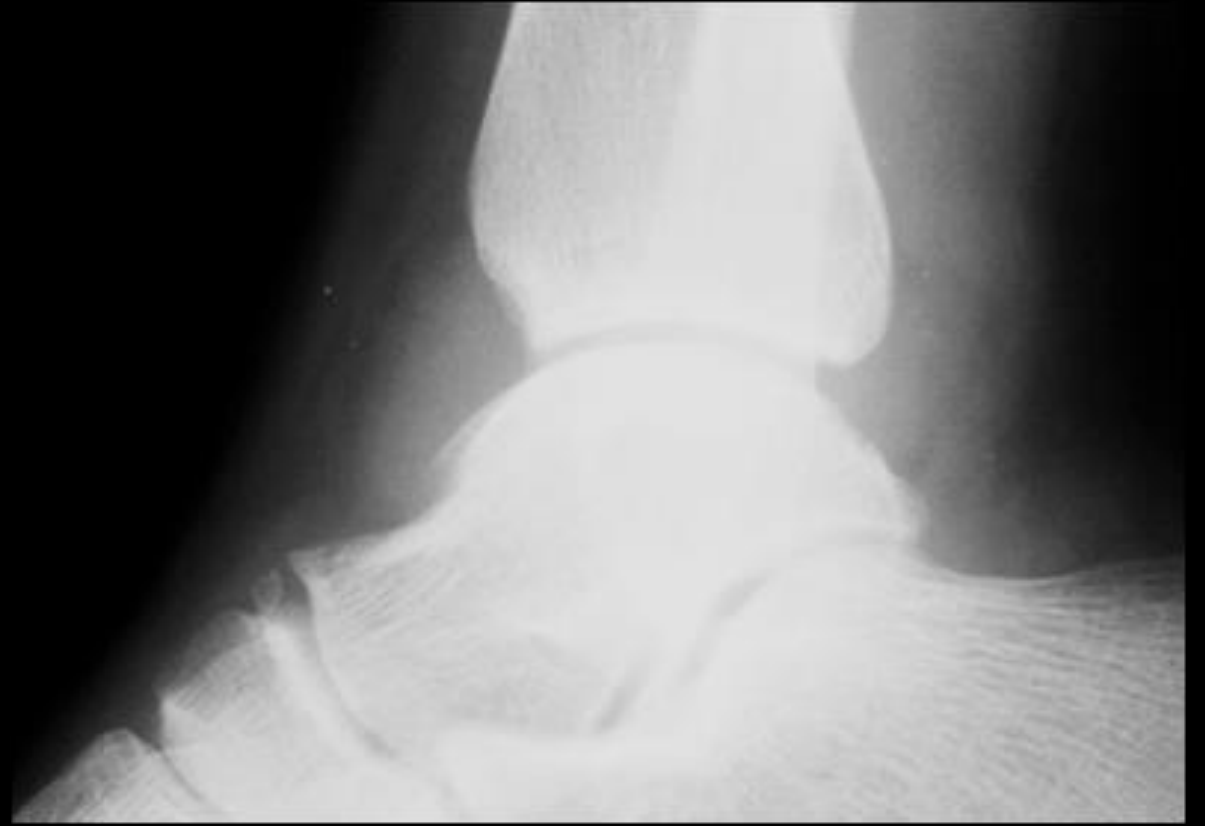
DR

12L5  
diffT8.0  
23 fps  
G:92  
DR:70  
A:5  
P:2

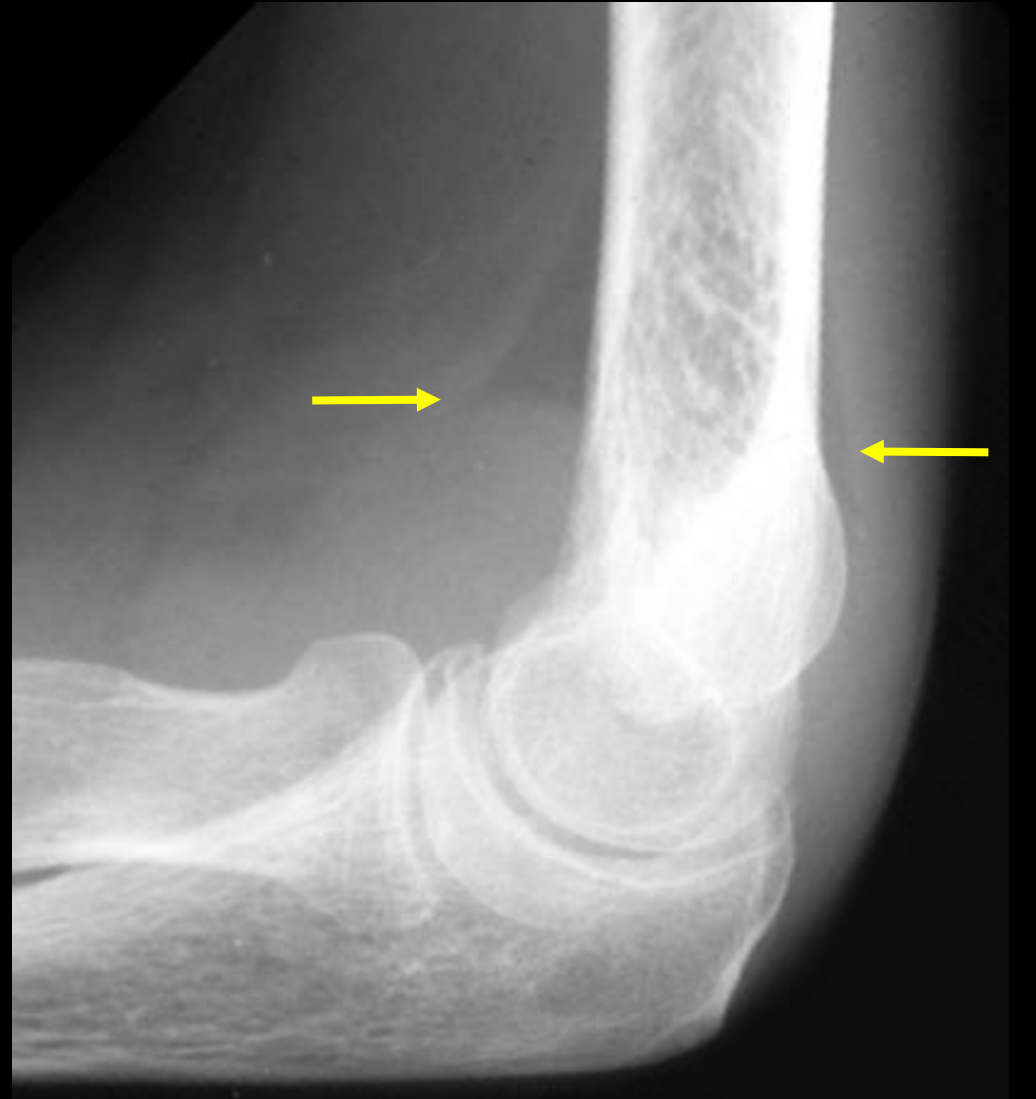
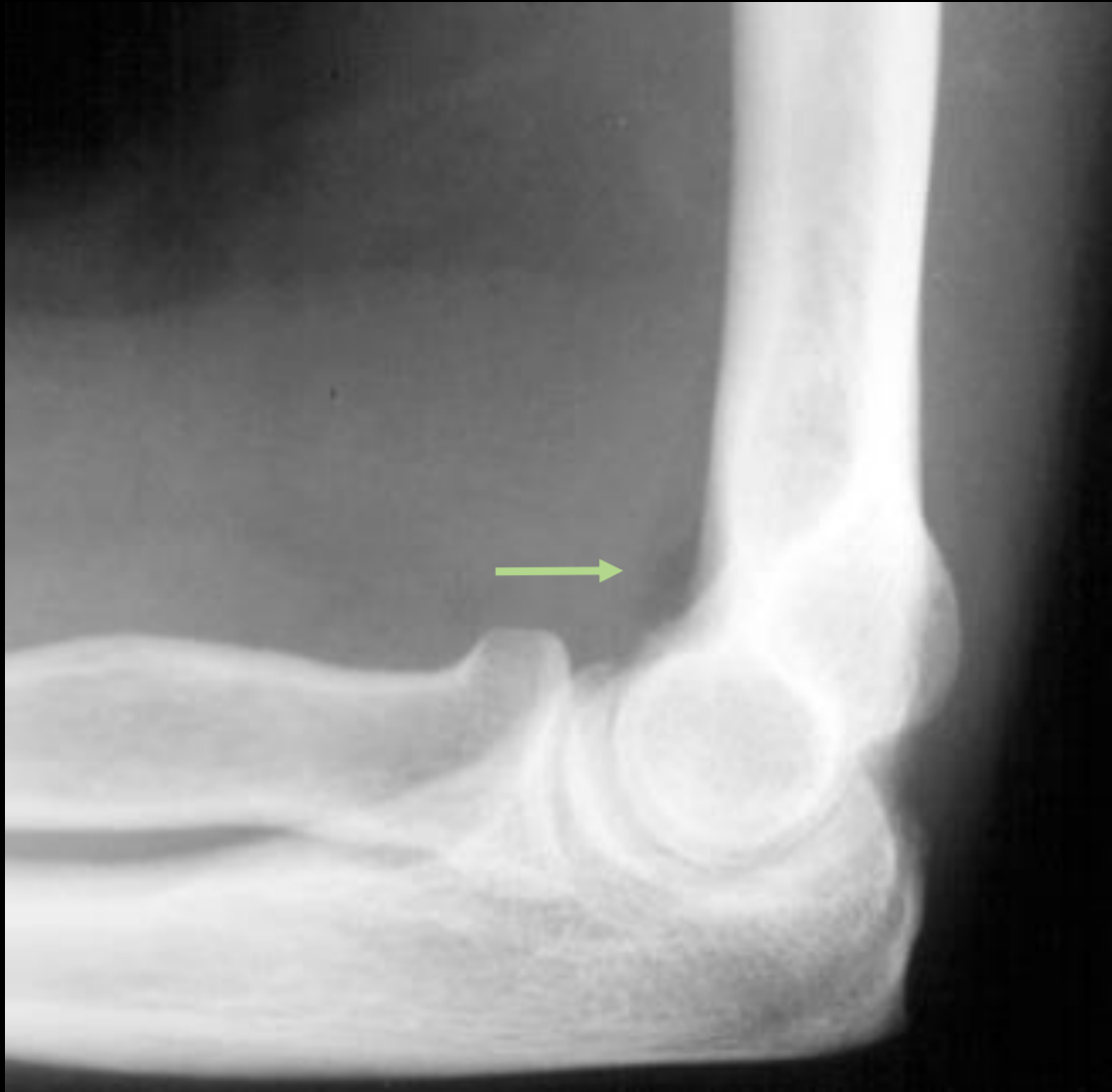
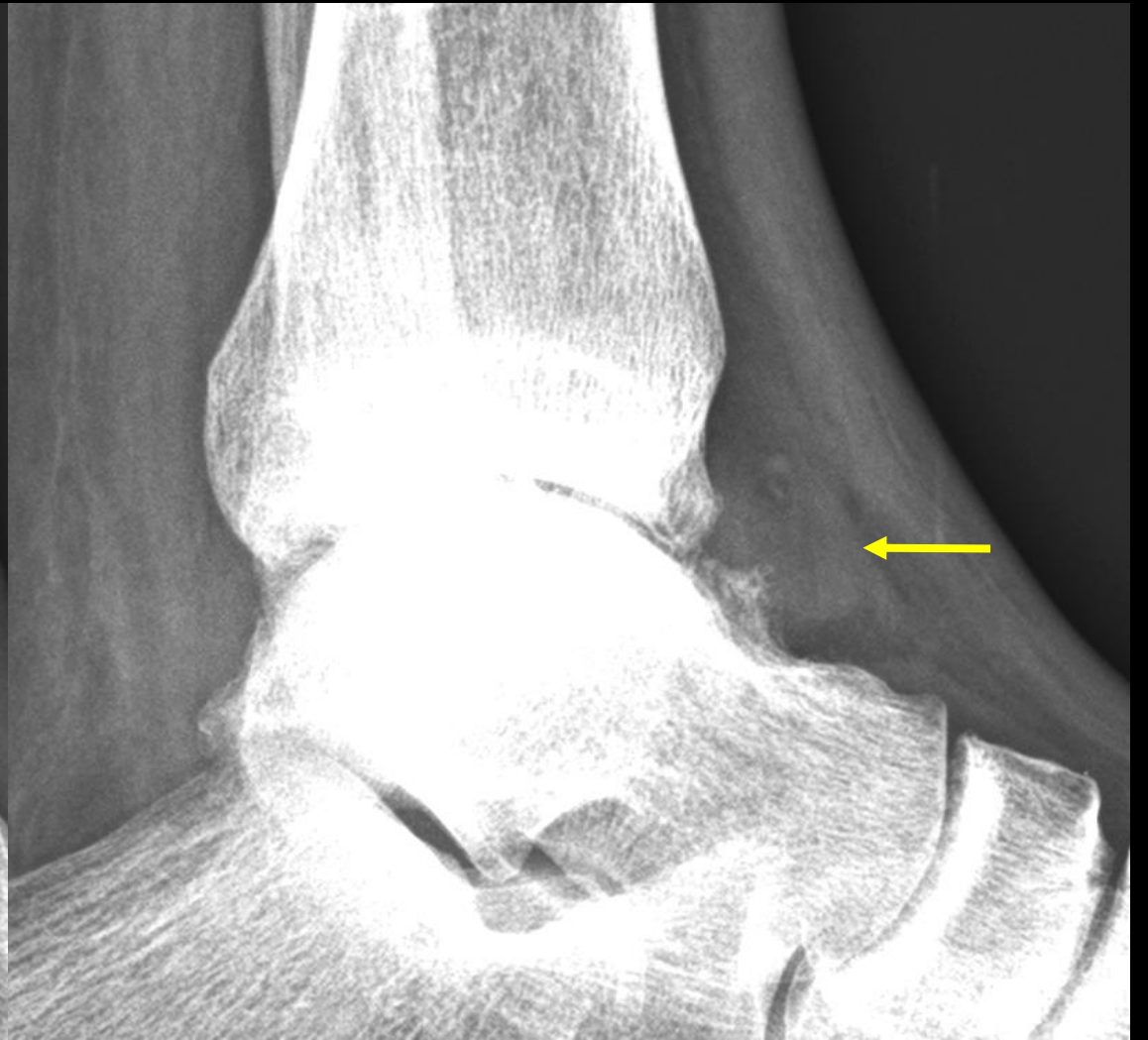


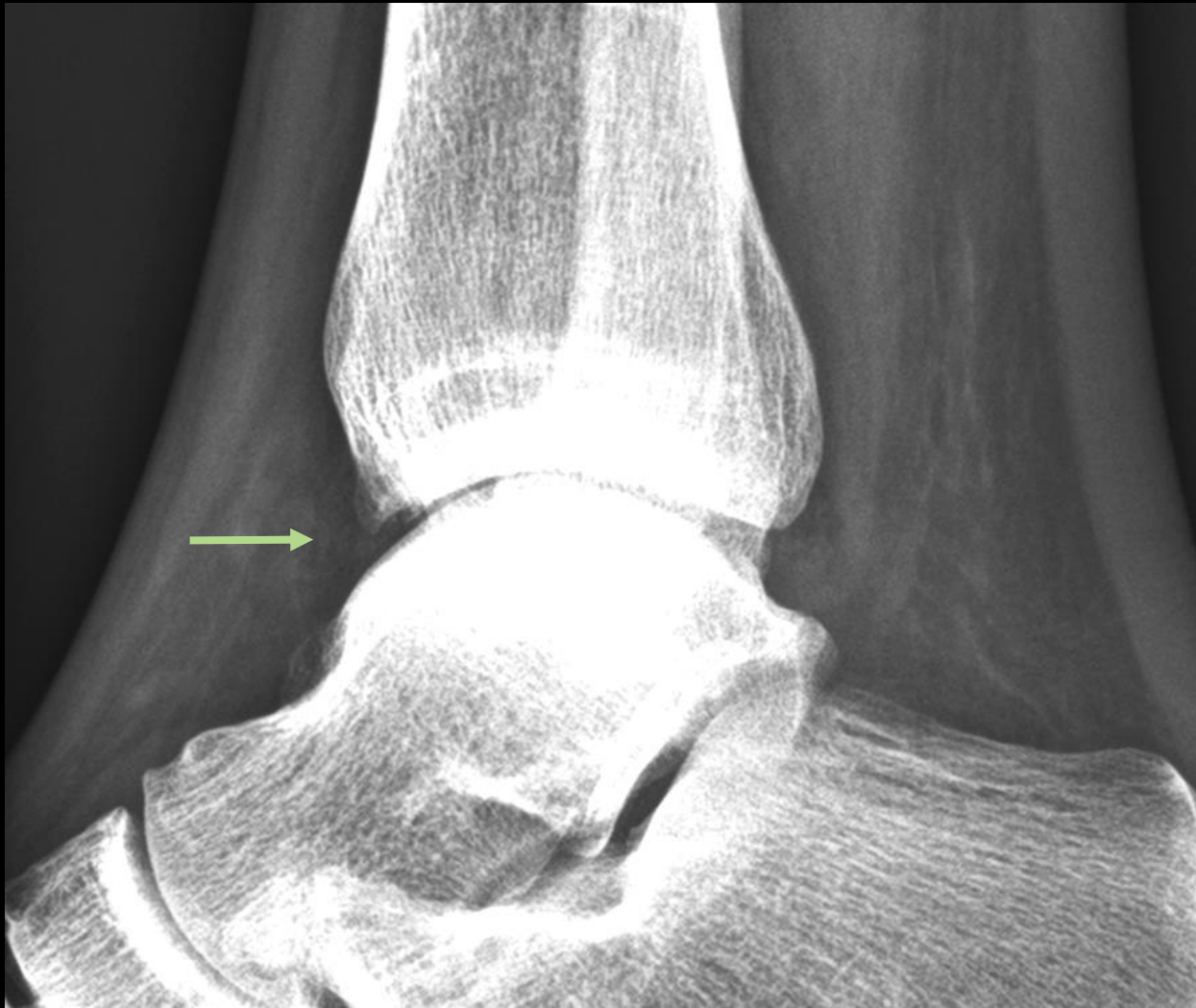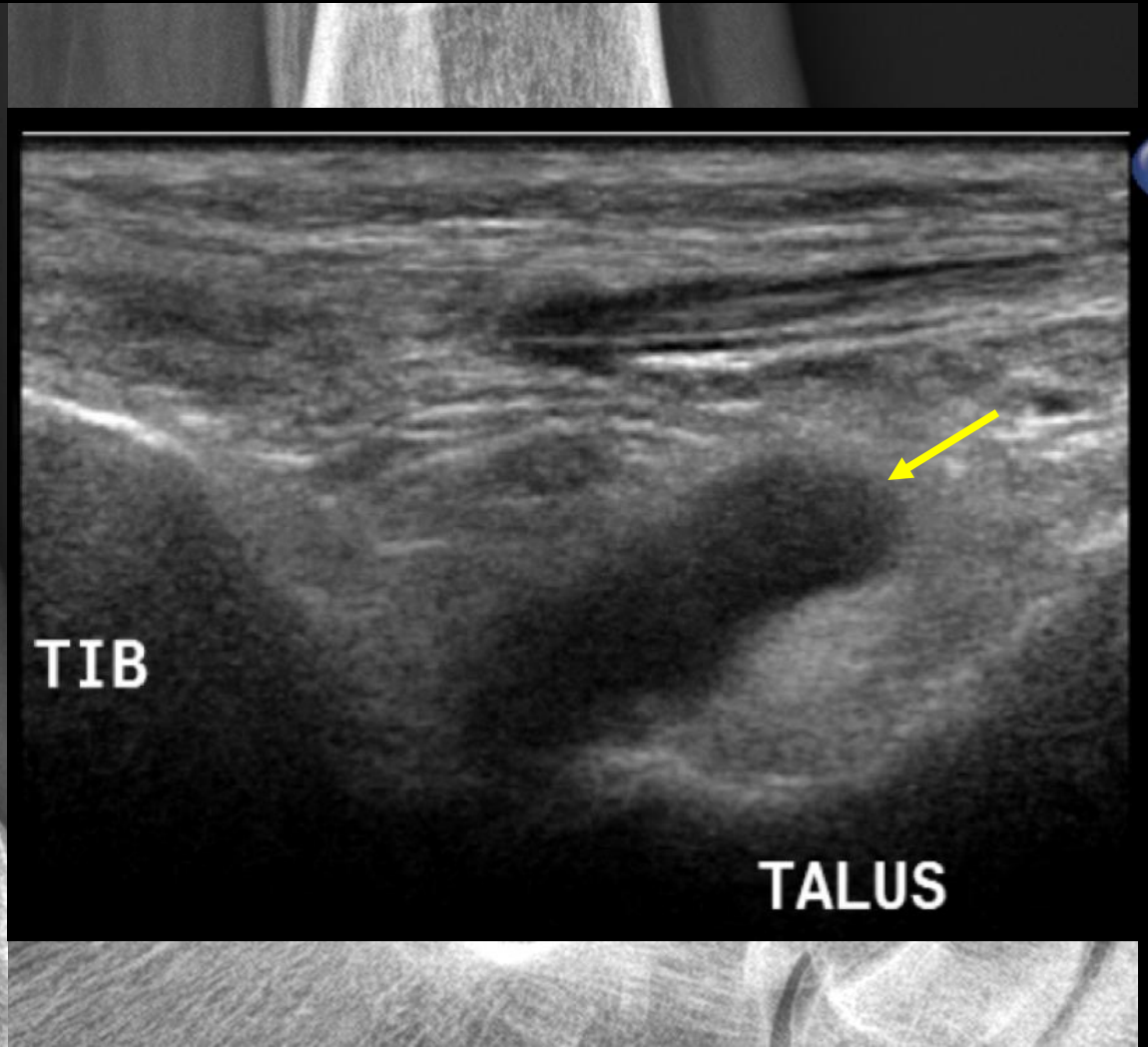
articulations superficielles



contraste graisseux







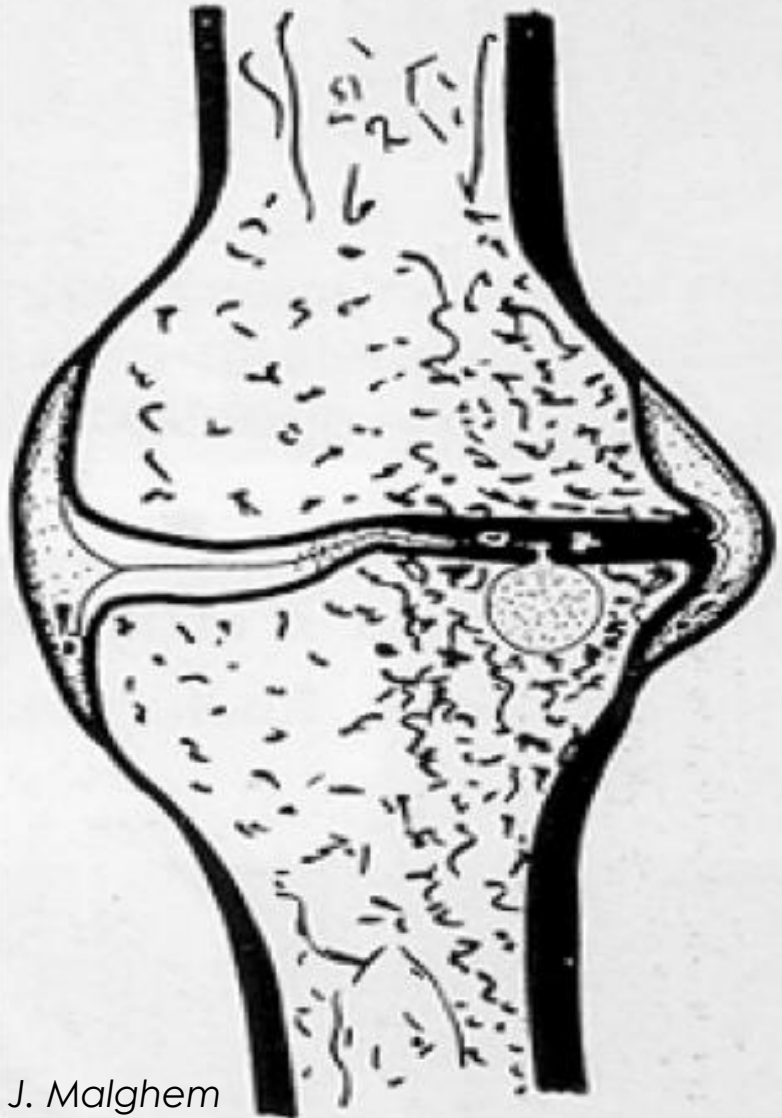


**Tuméfaction articulaire visible en RX:**

- Genoux
- Chevilles
- Doigts et orteils
- Coudes

TALUS

# ARTHROSE



TISSUS MOUS

Gonflement inconstant

INTERLIGNE  
ARTICULAIRE

Pincement **focal**

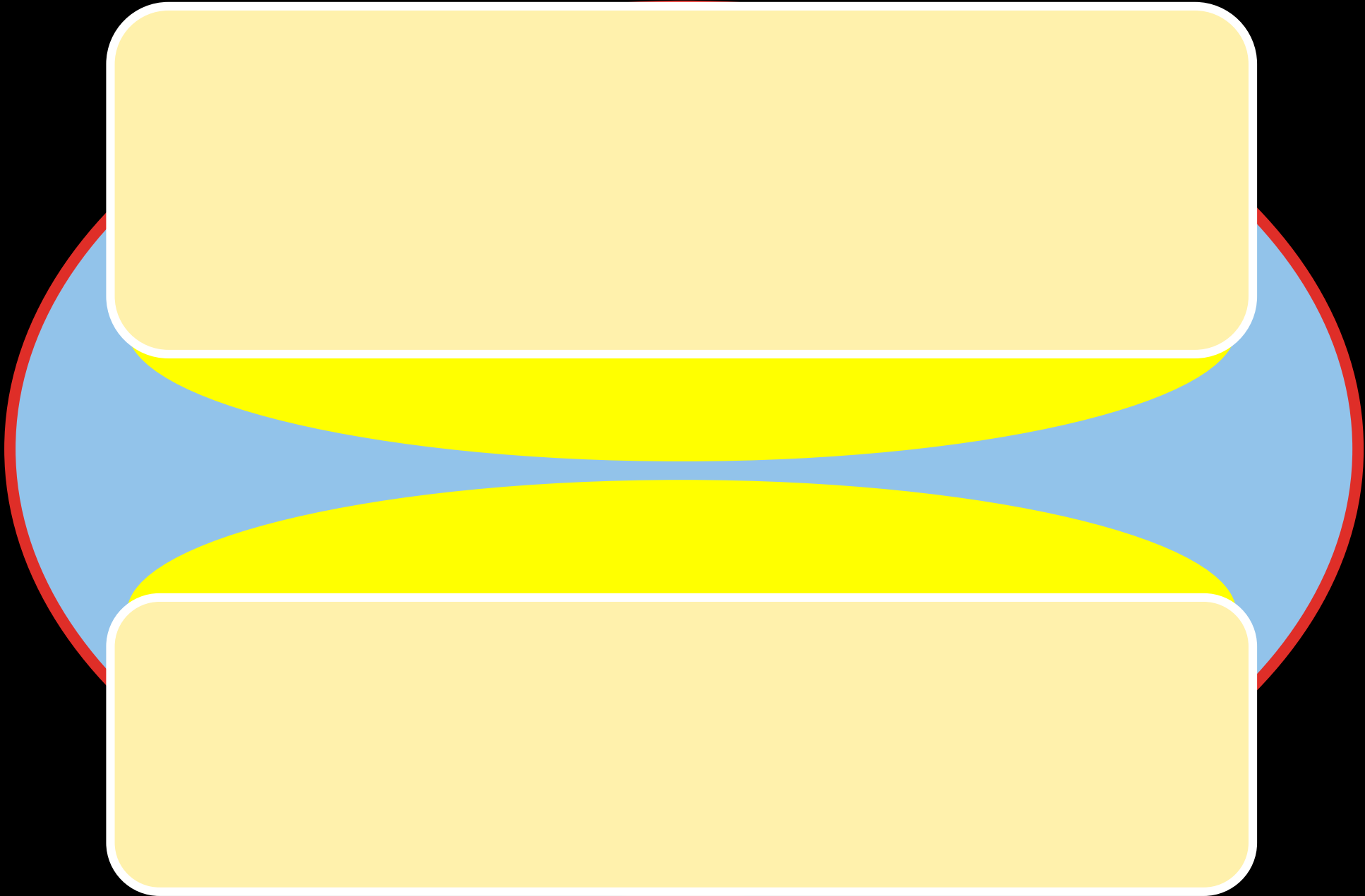
OS SOUS-CHONDRAL

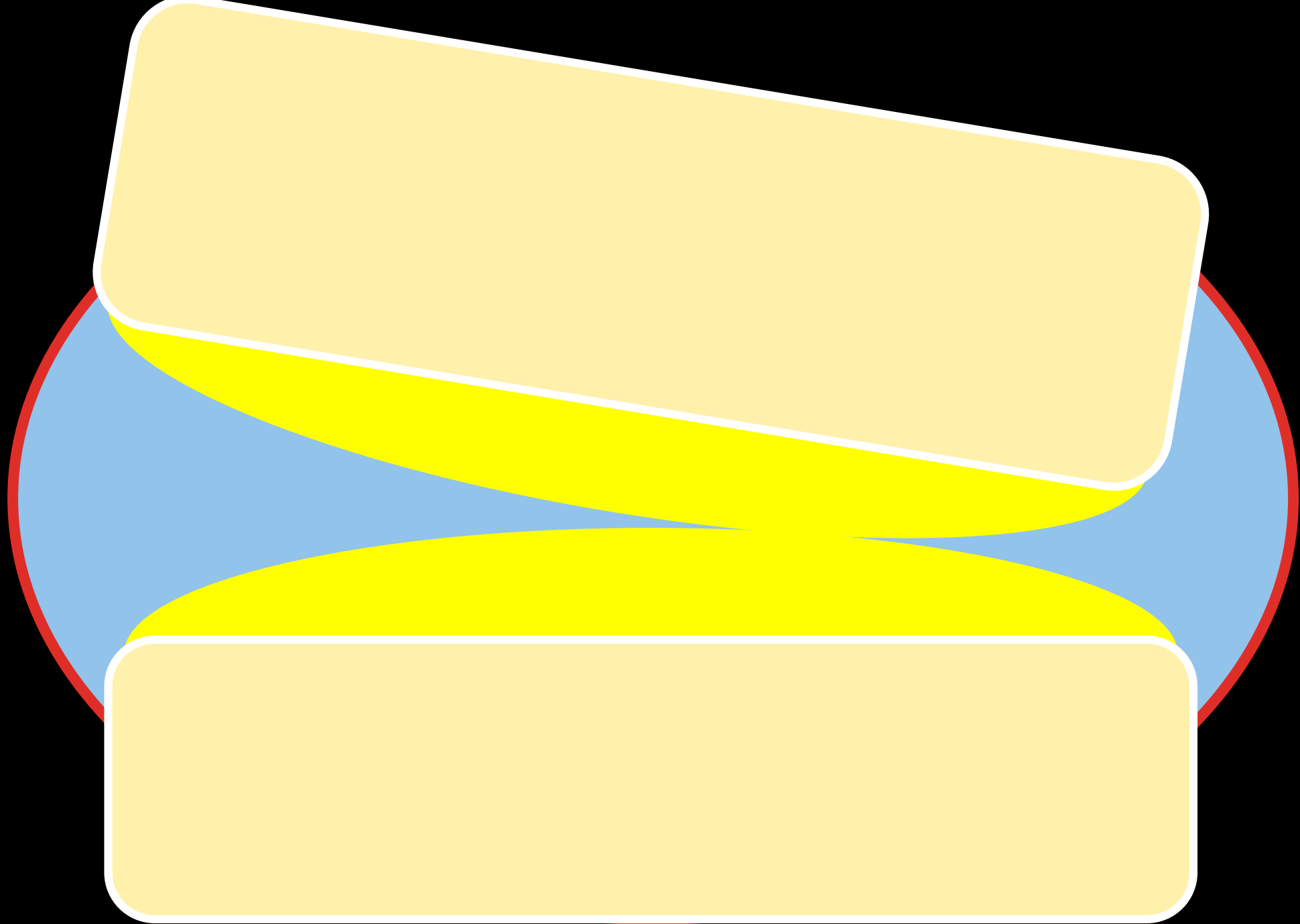
Erosions  
Géodes  
Hyperostose

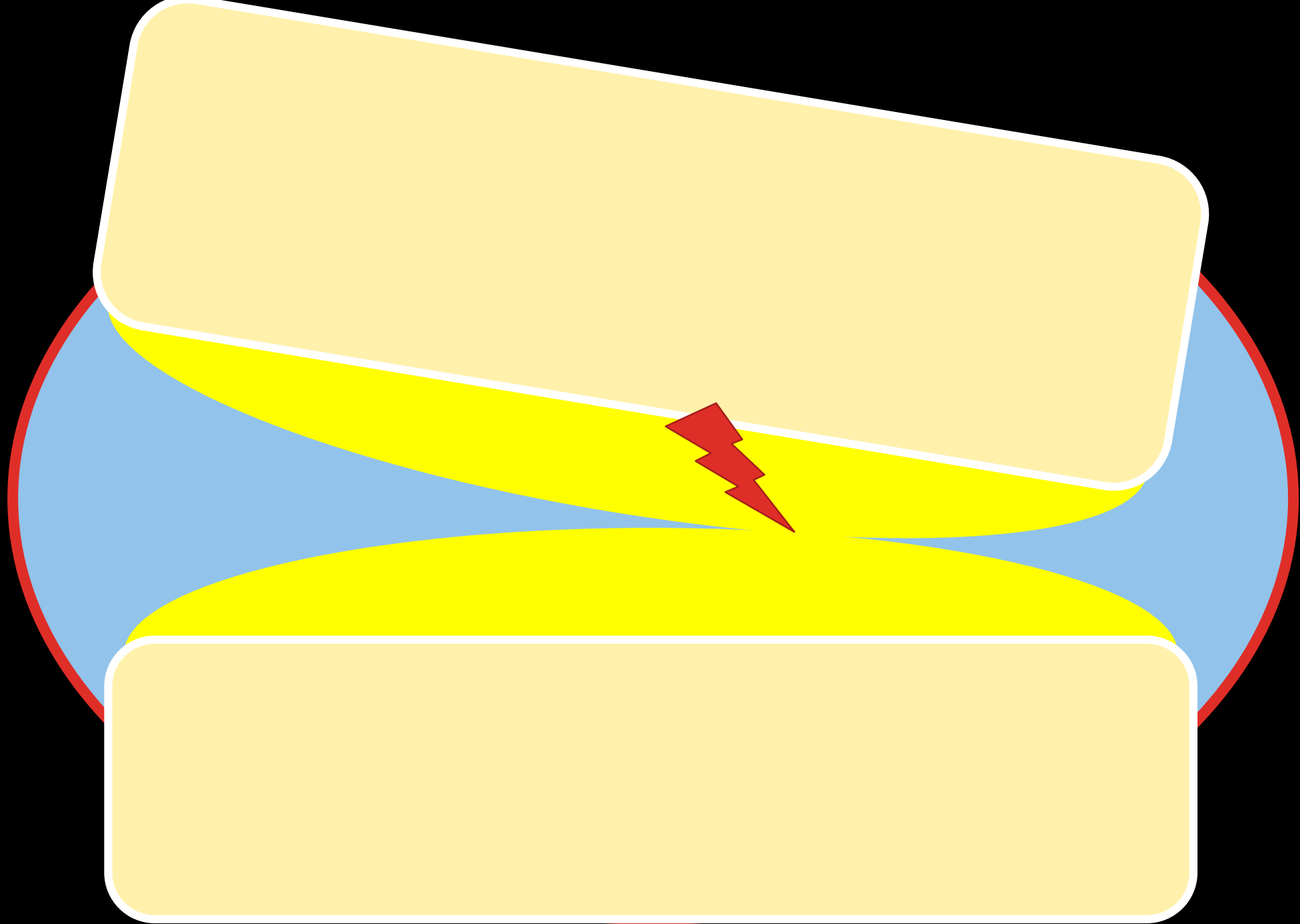
OS MARGINAL

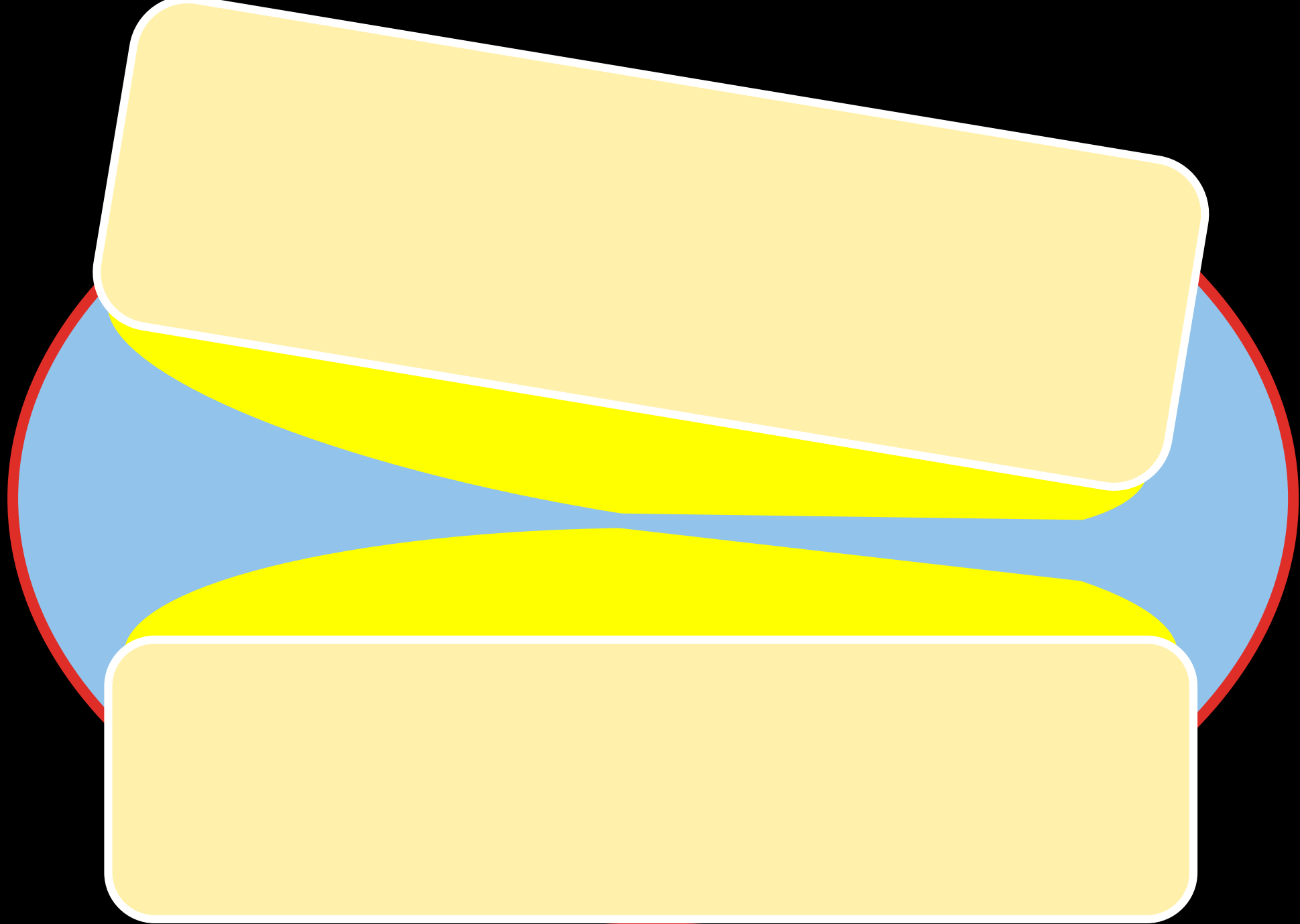
Ostéophytes




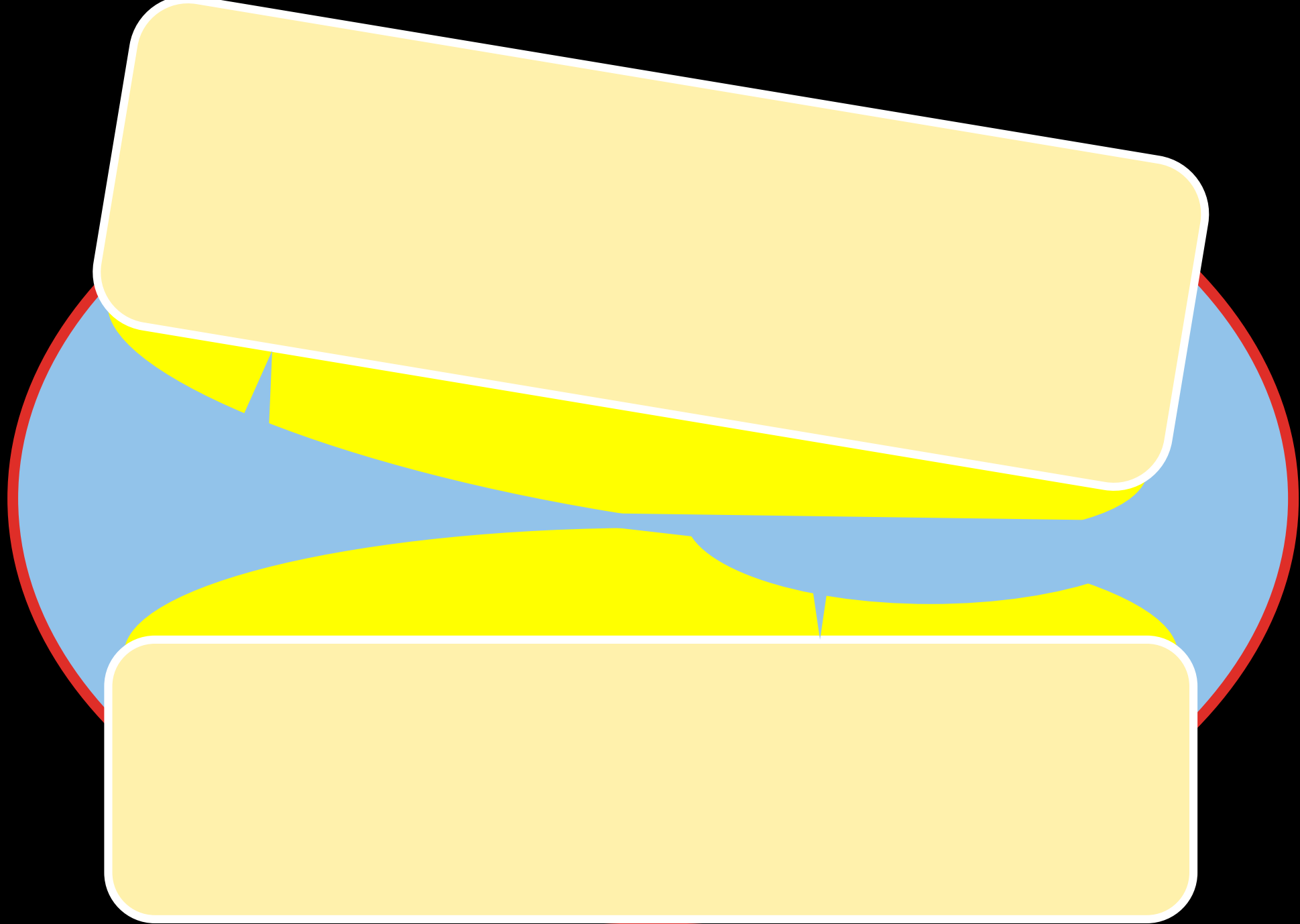


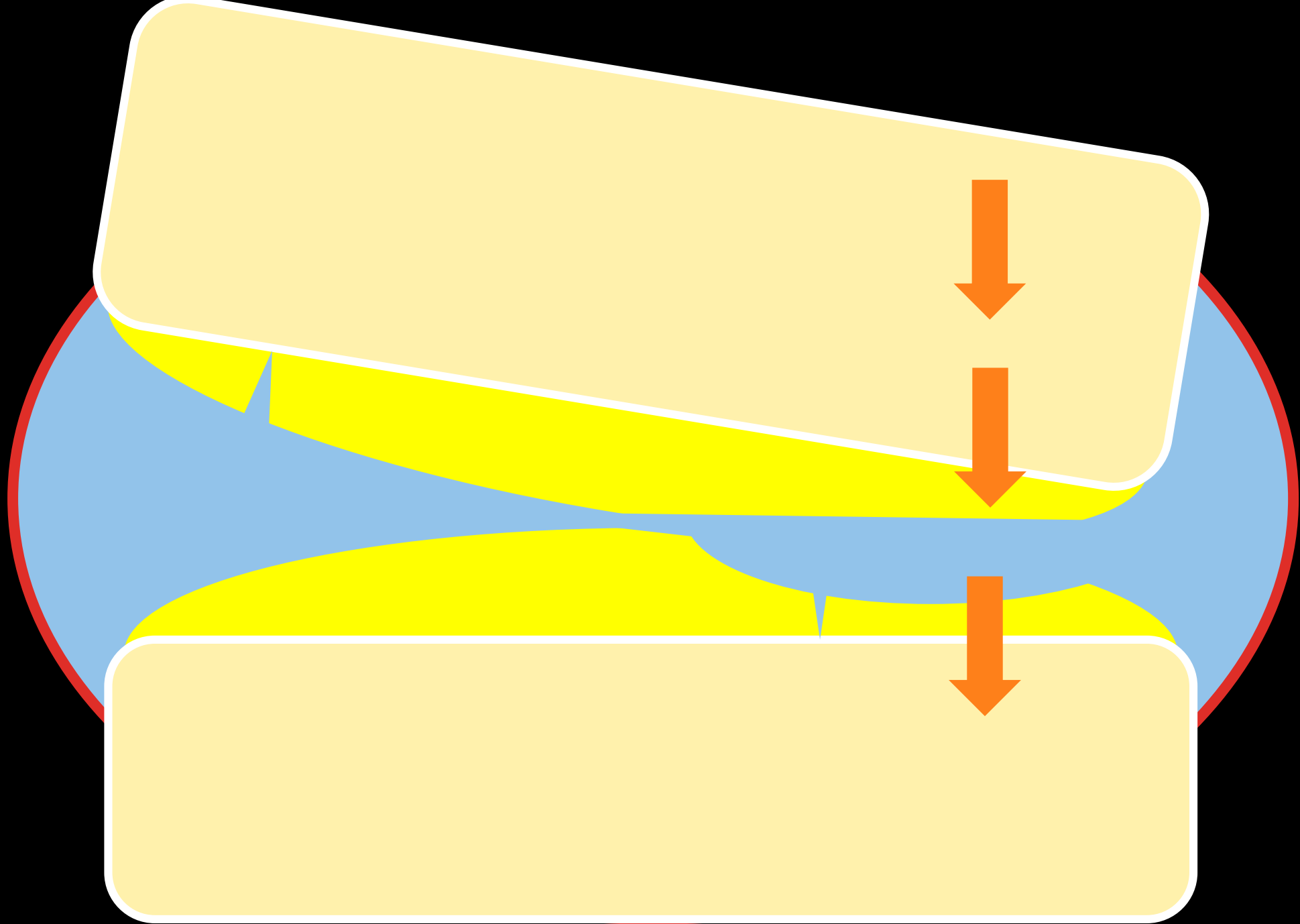


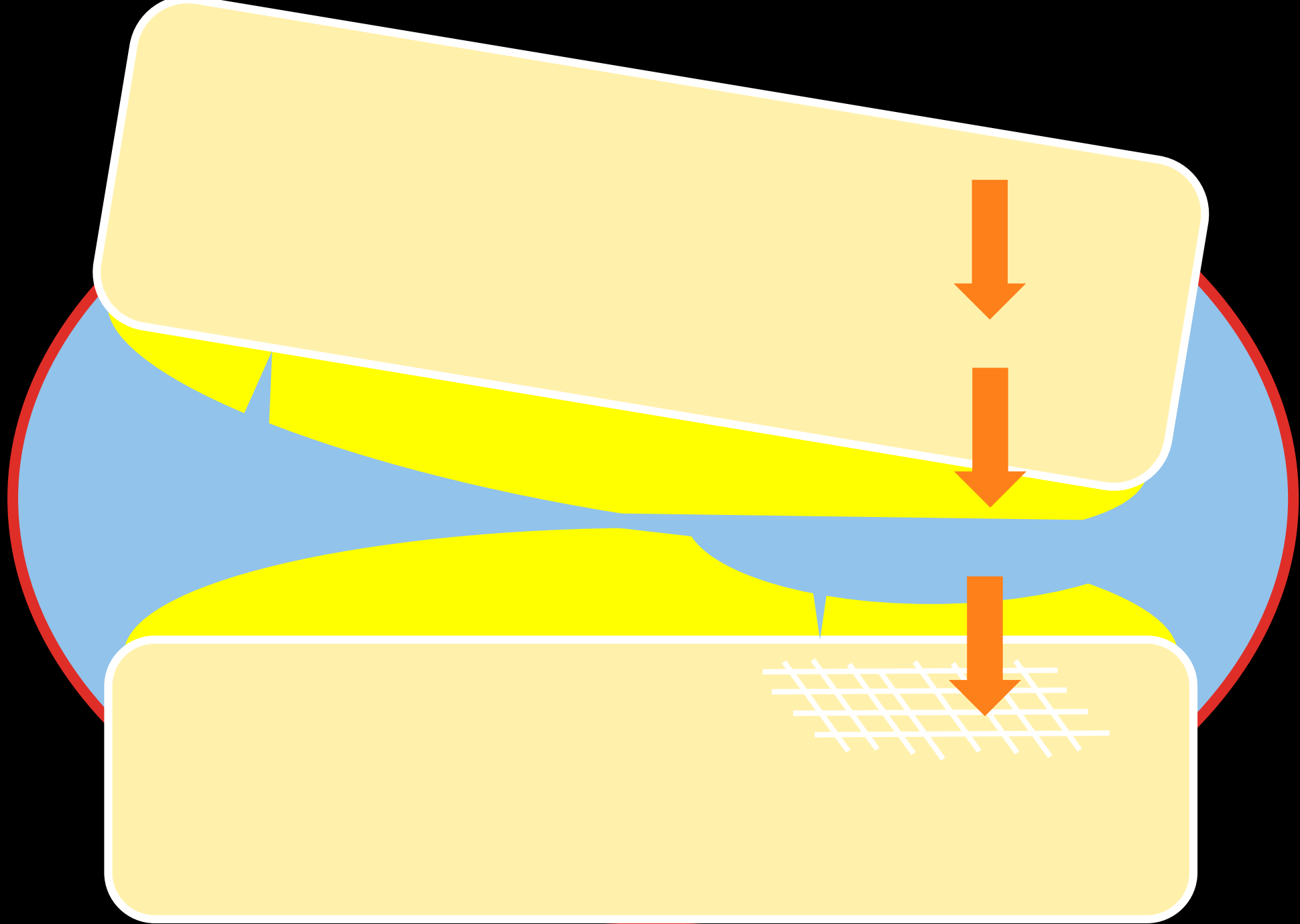




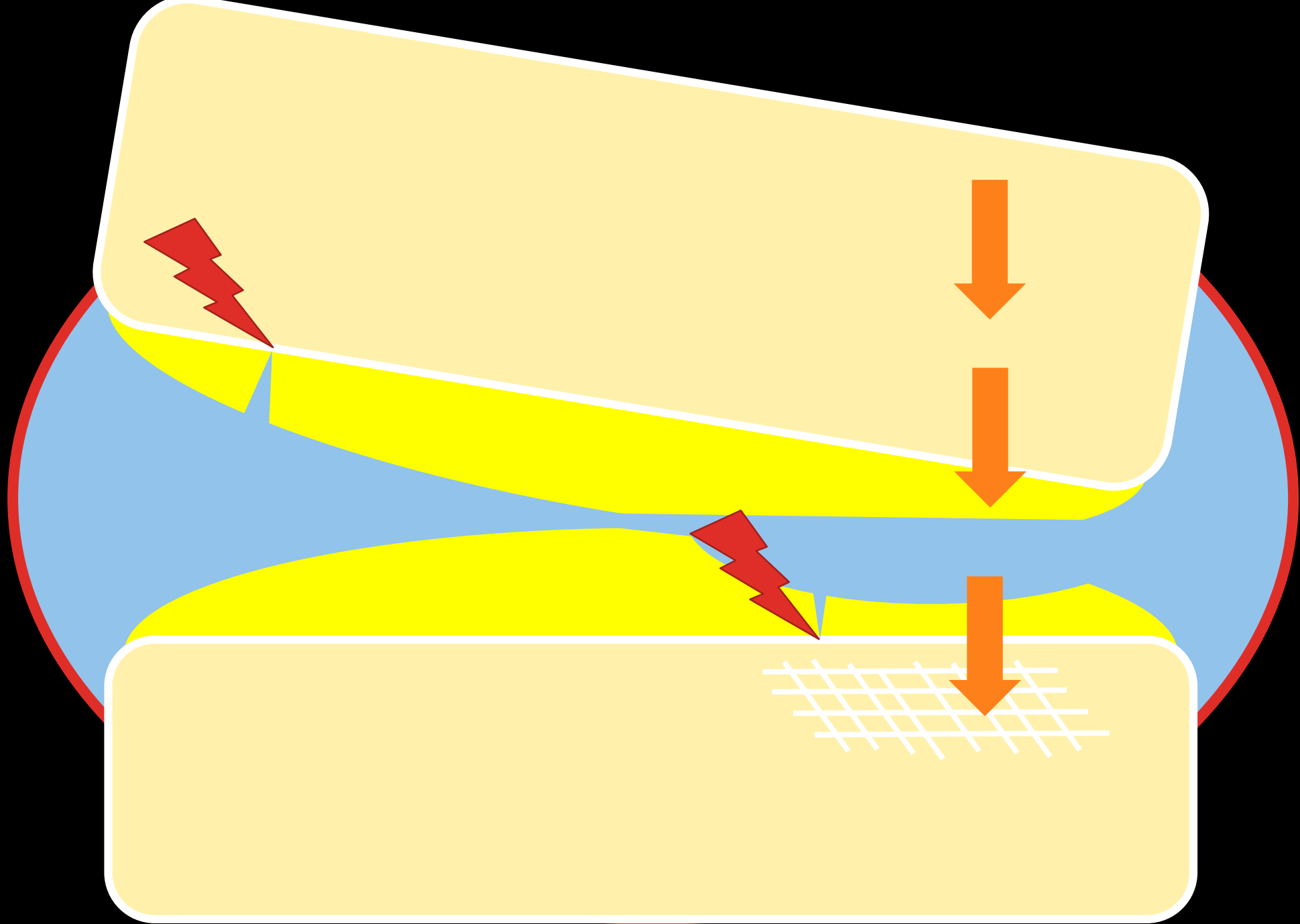


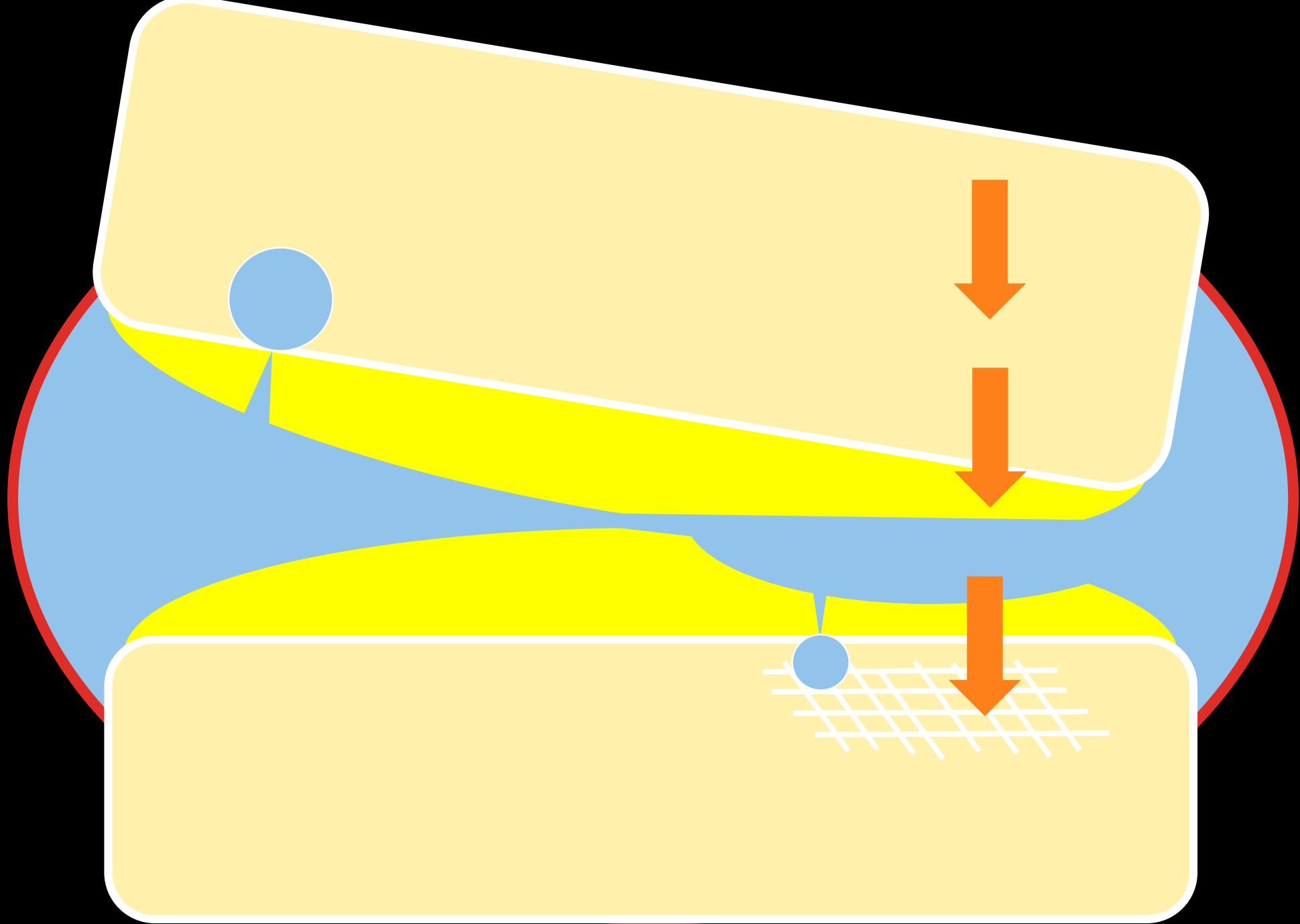


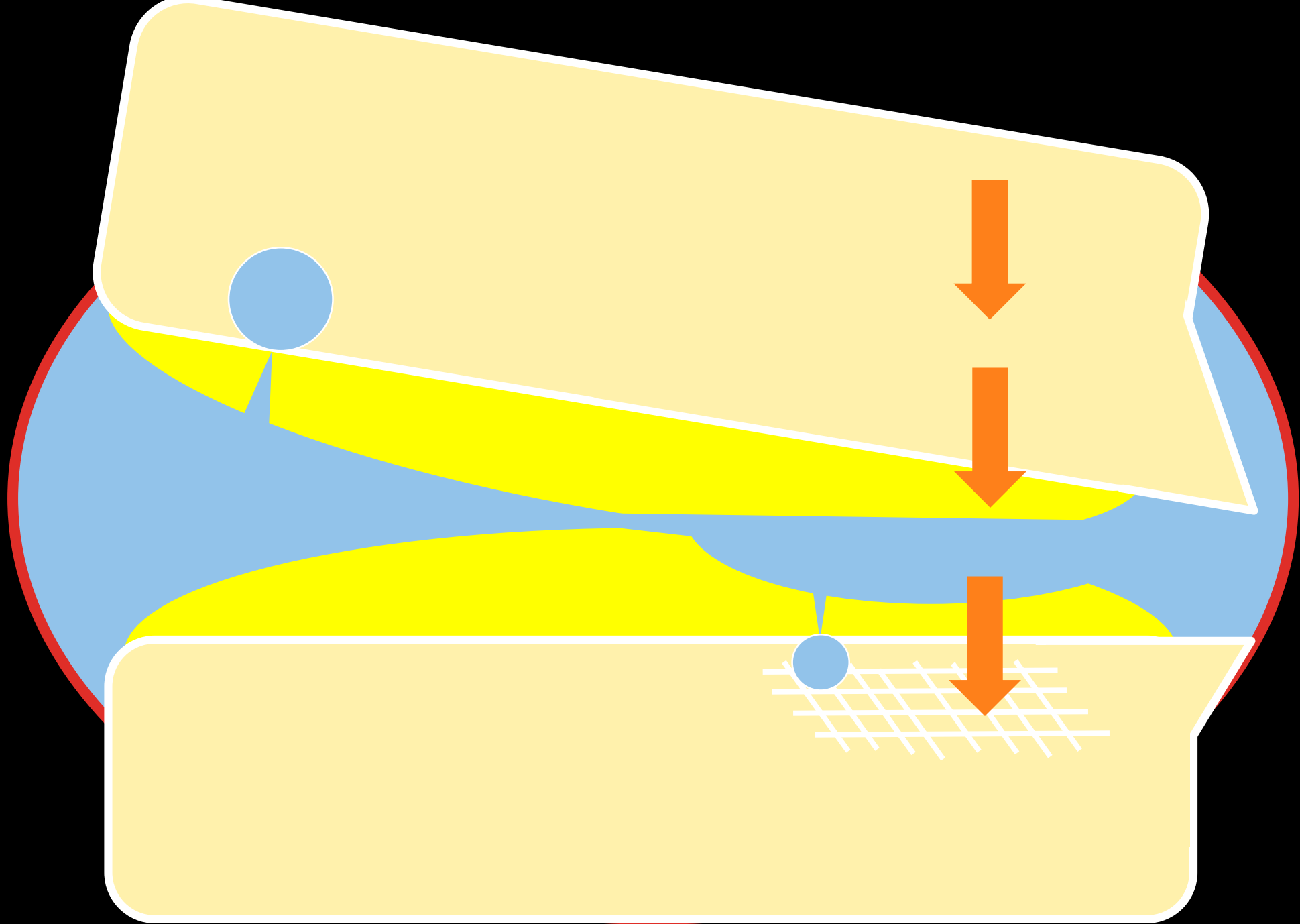


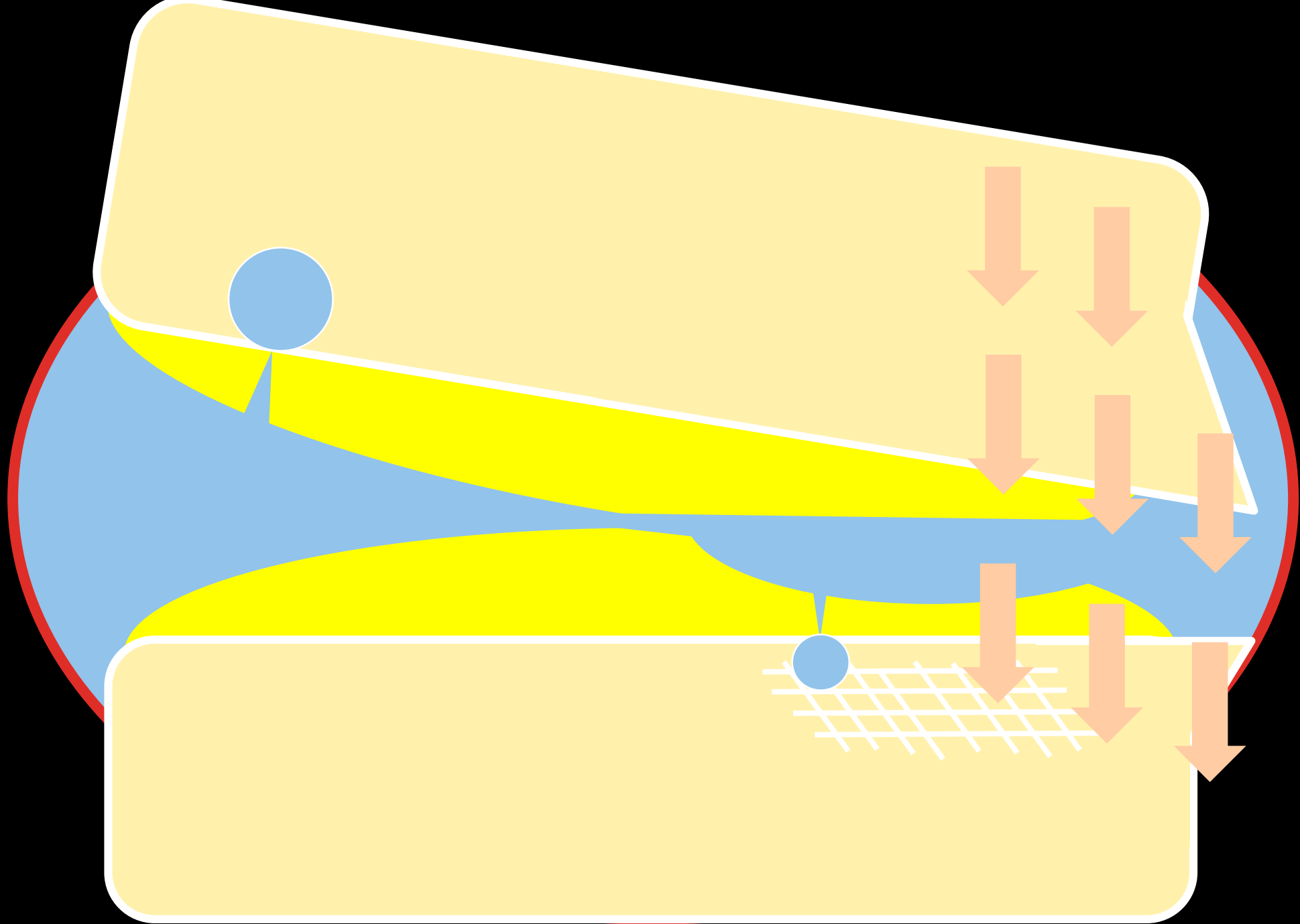


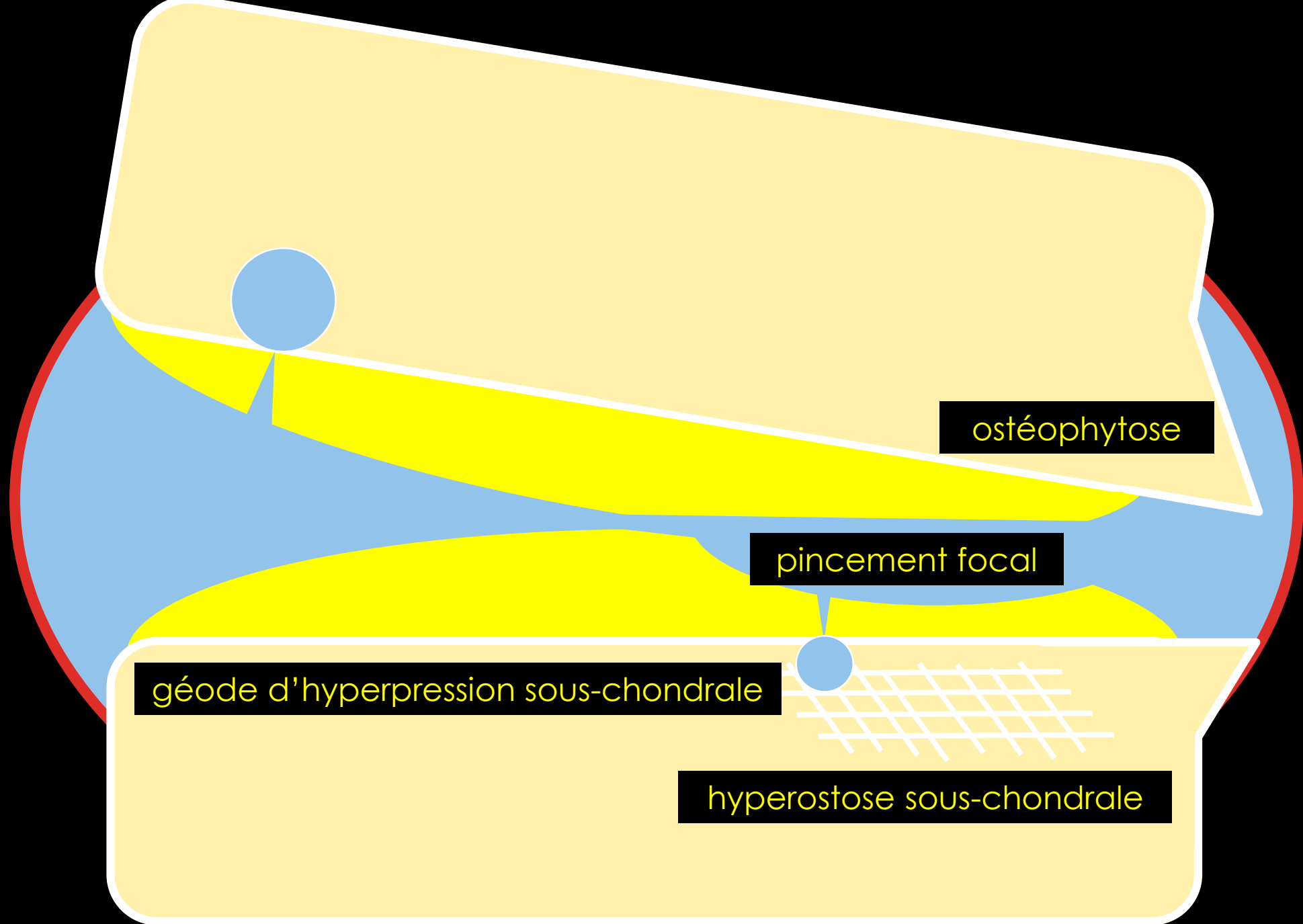












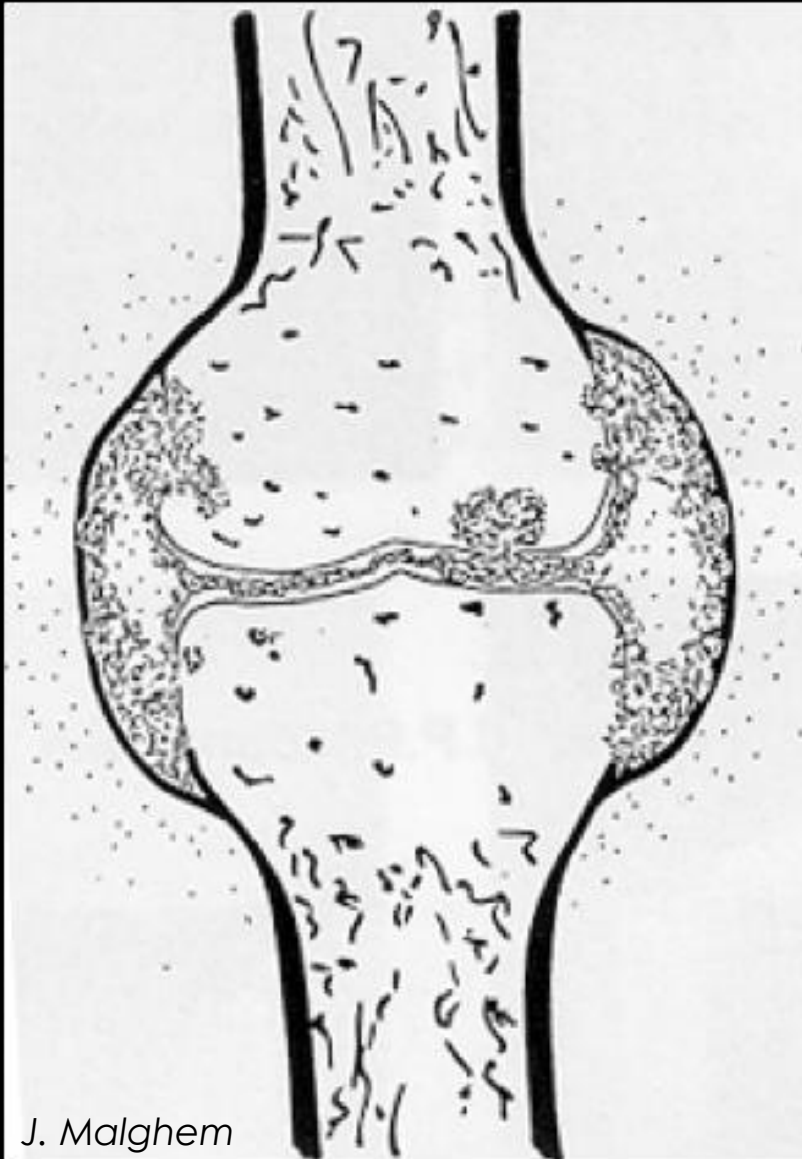
ostéophytose

pincement focal

géode d'hyperpression sous-chondrale

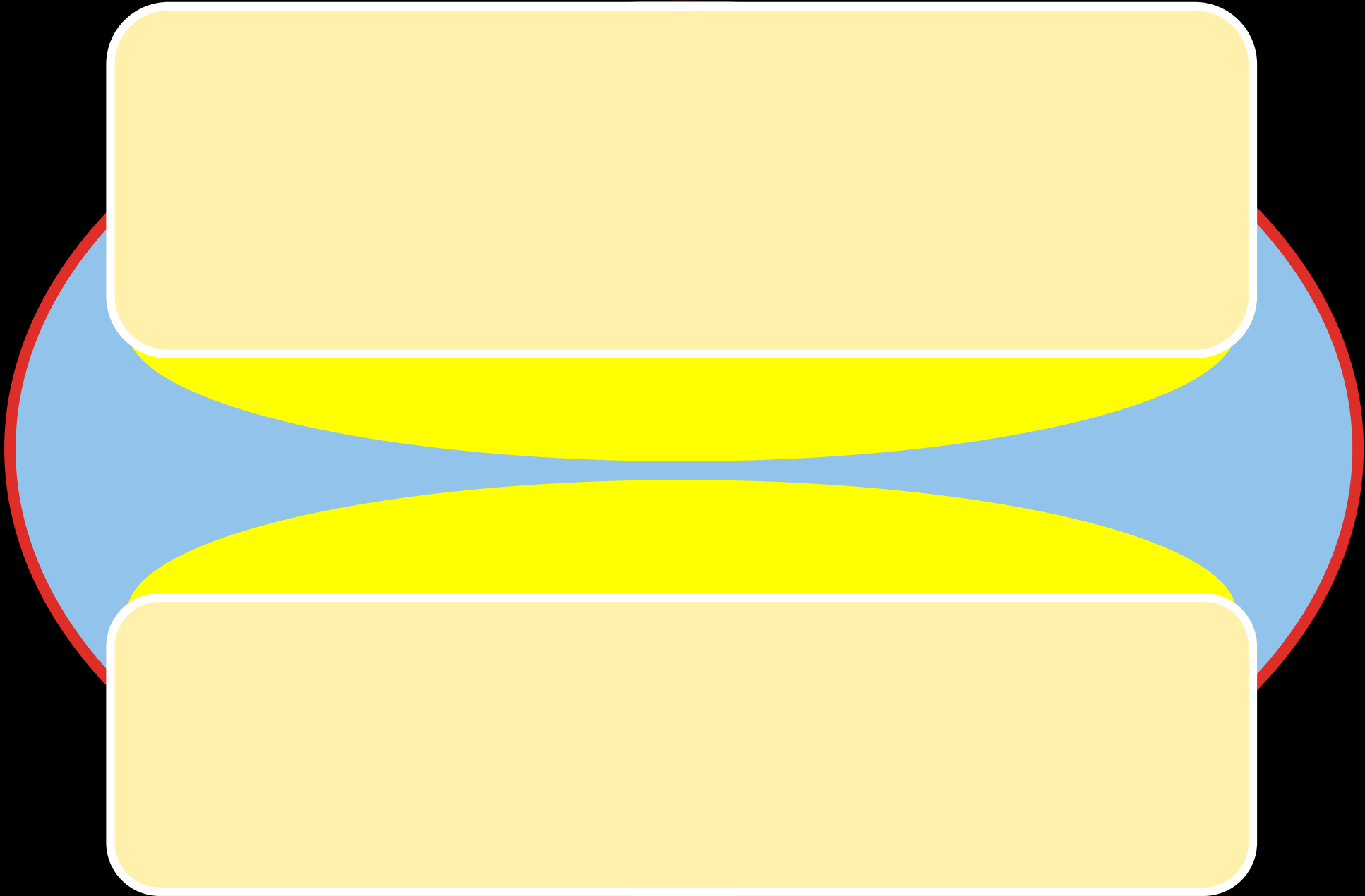
hyperostose sous-chondrale

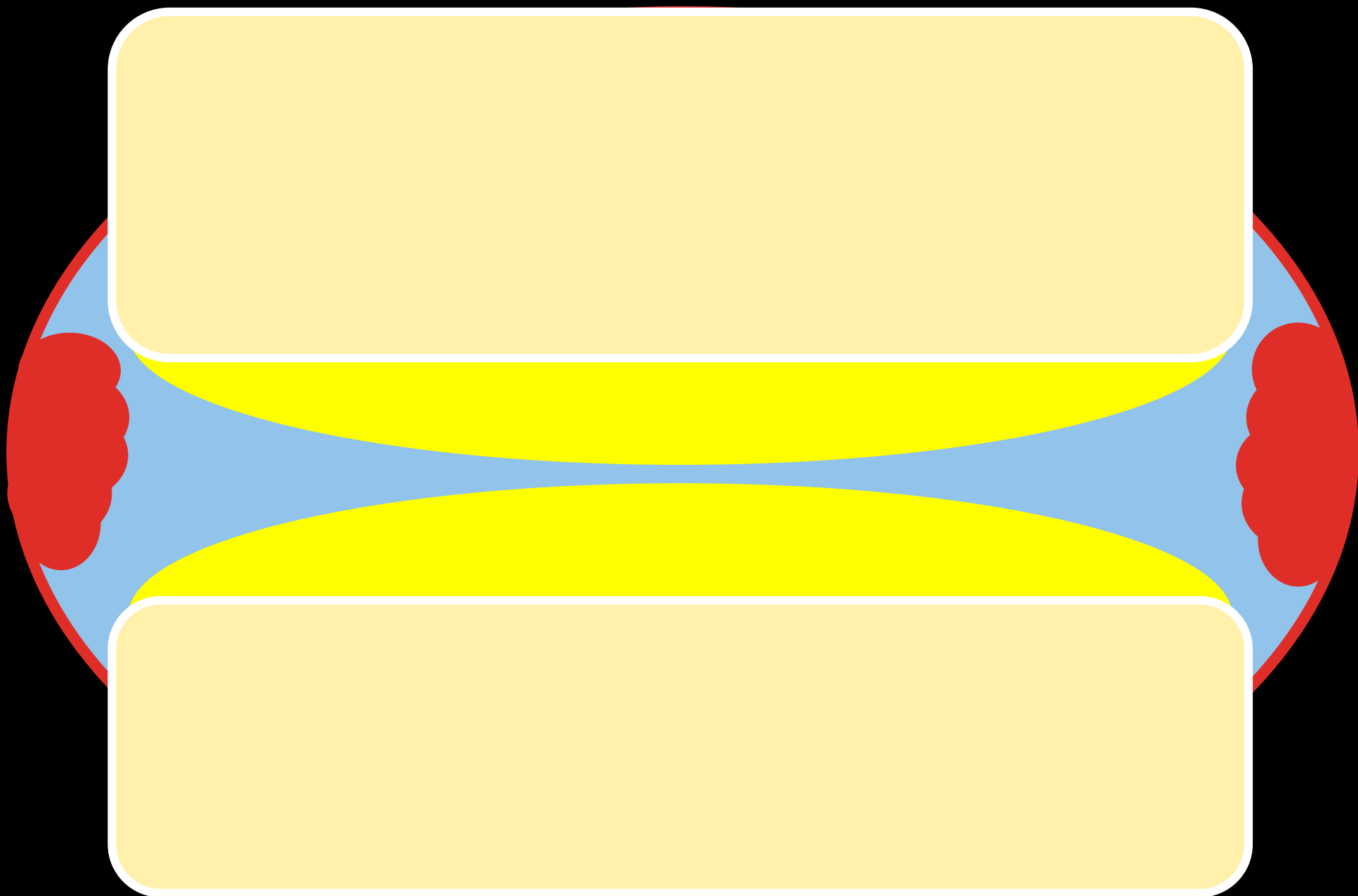
# ARTHRITE



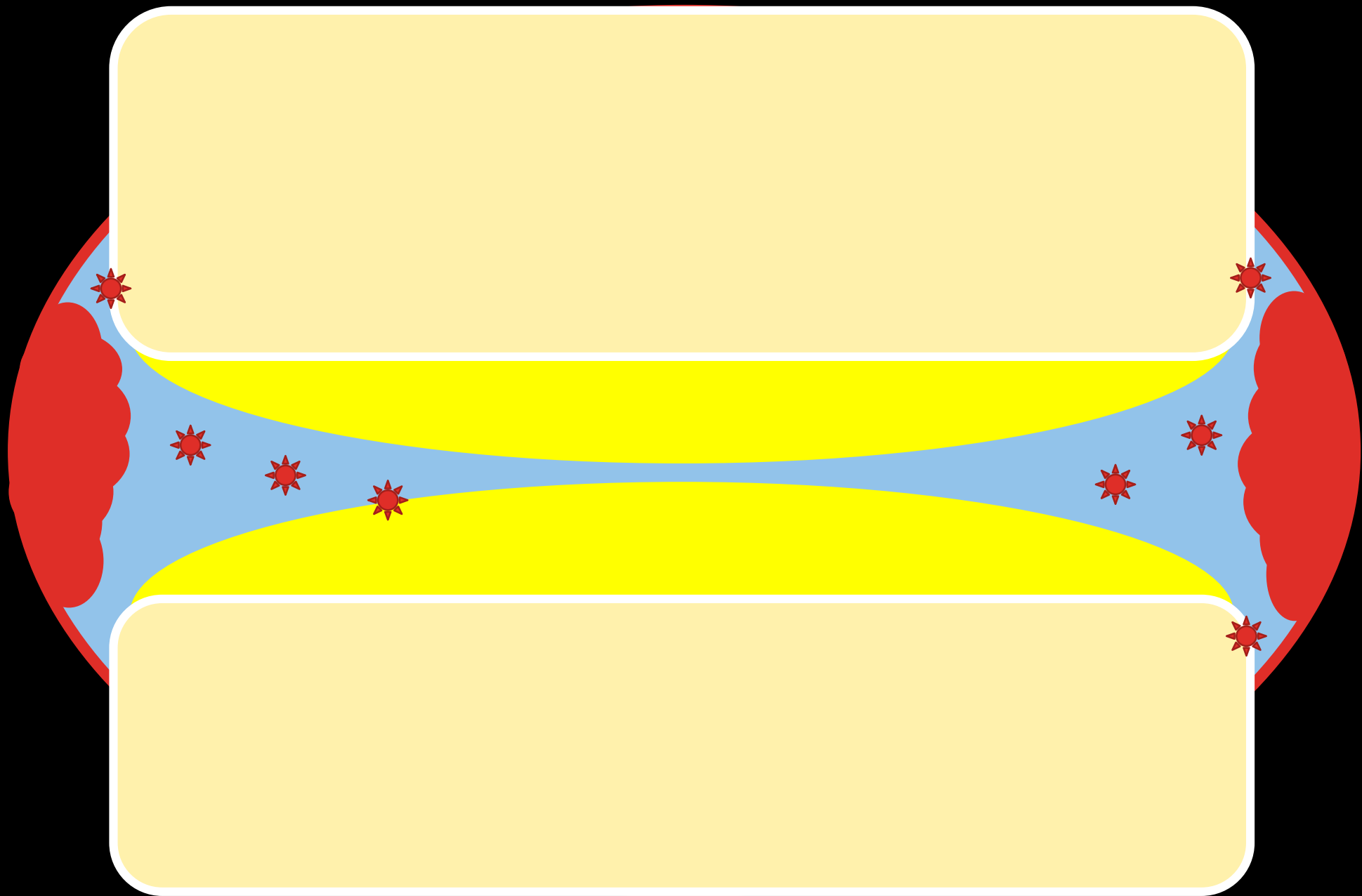
J. Malghem

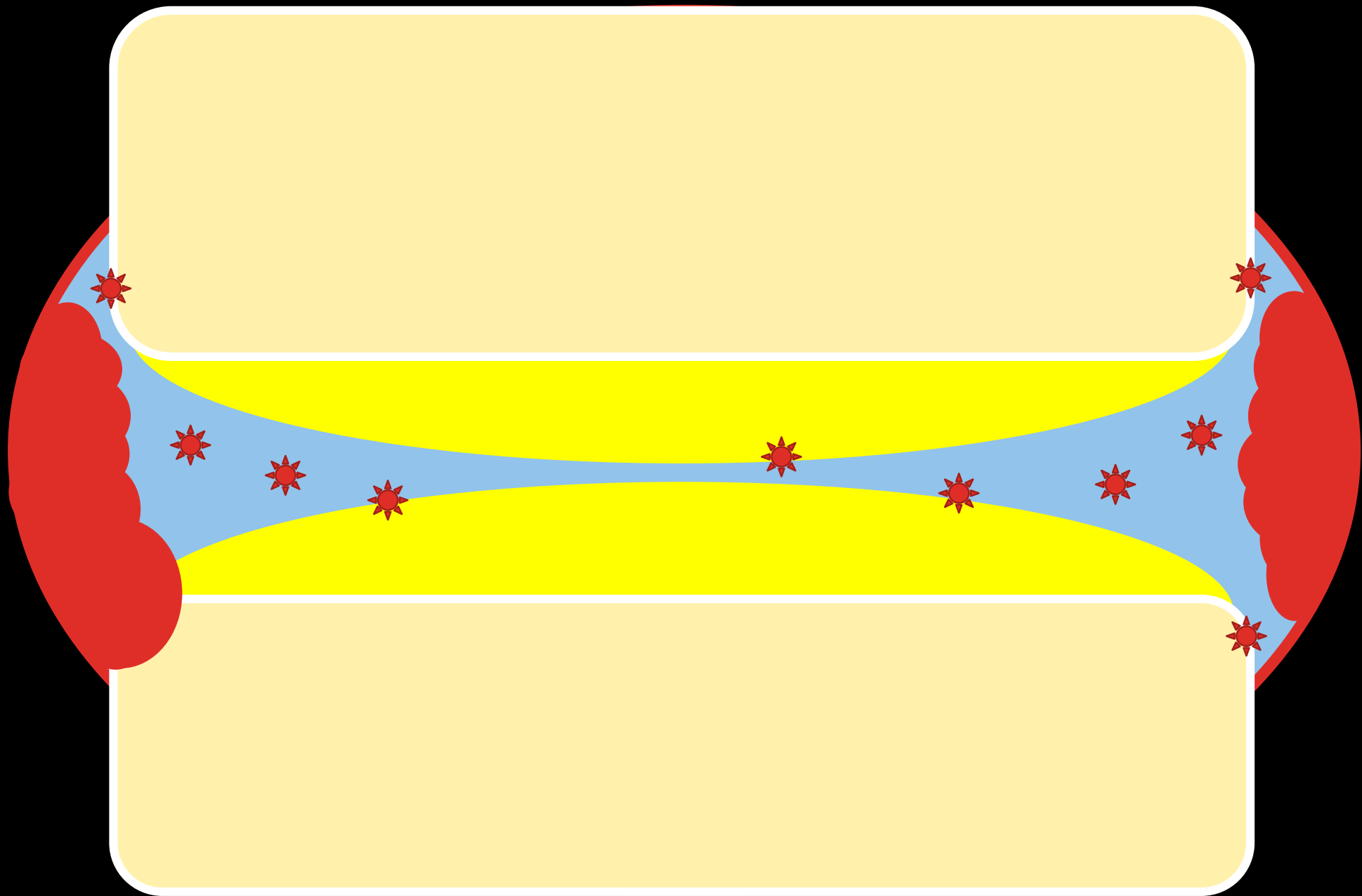
TISSUS MOUS	Gonflement fréquent
INTERLIGNE ARTICULAIRE	Pincement <b>global</b>
OS SOUS-CHONDRAL	Erosions Géodes
OS MARGINAL	<b>Erosions</b>

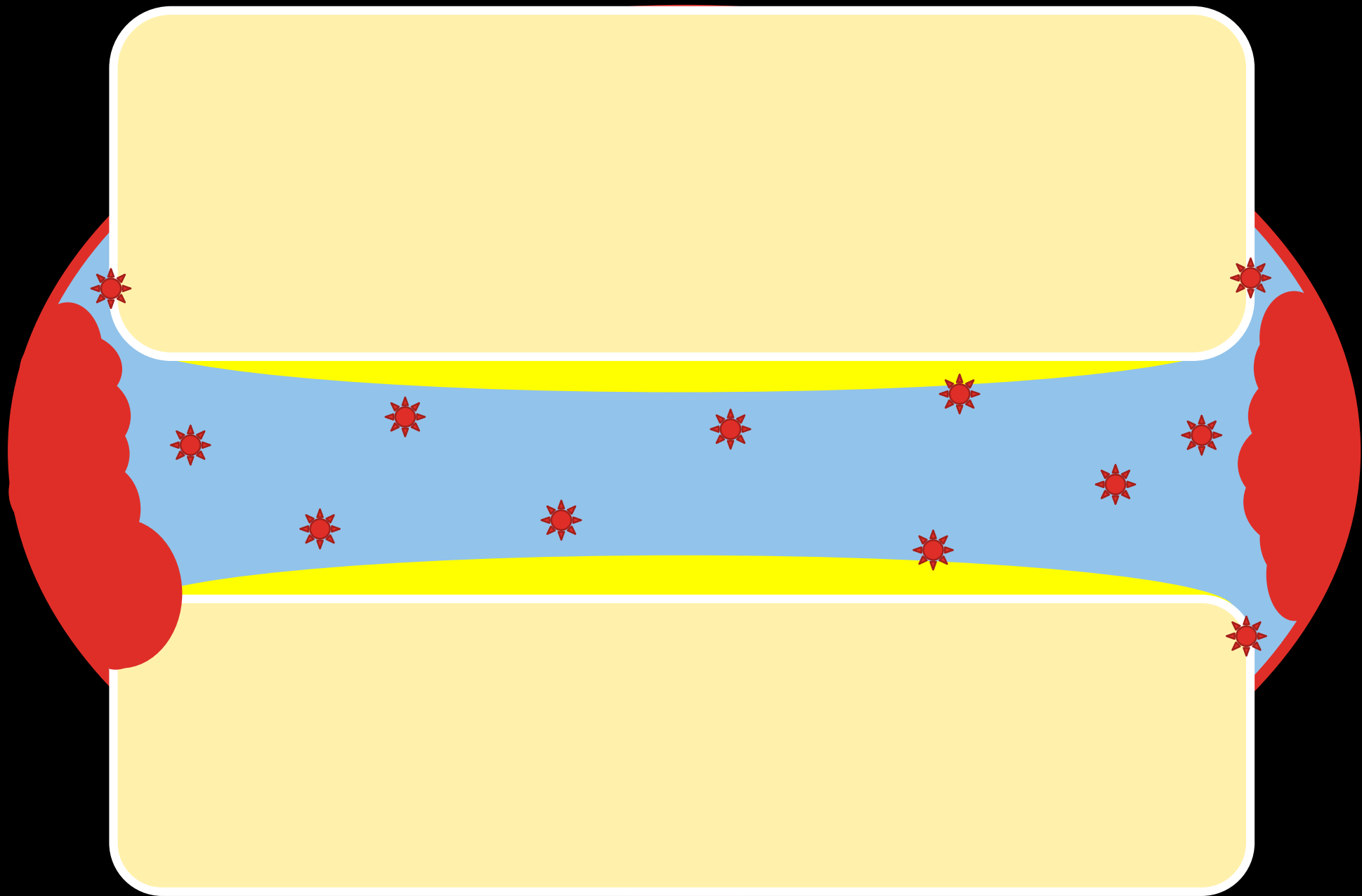


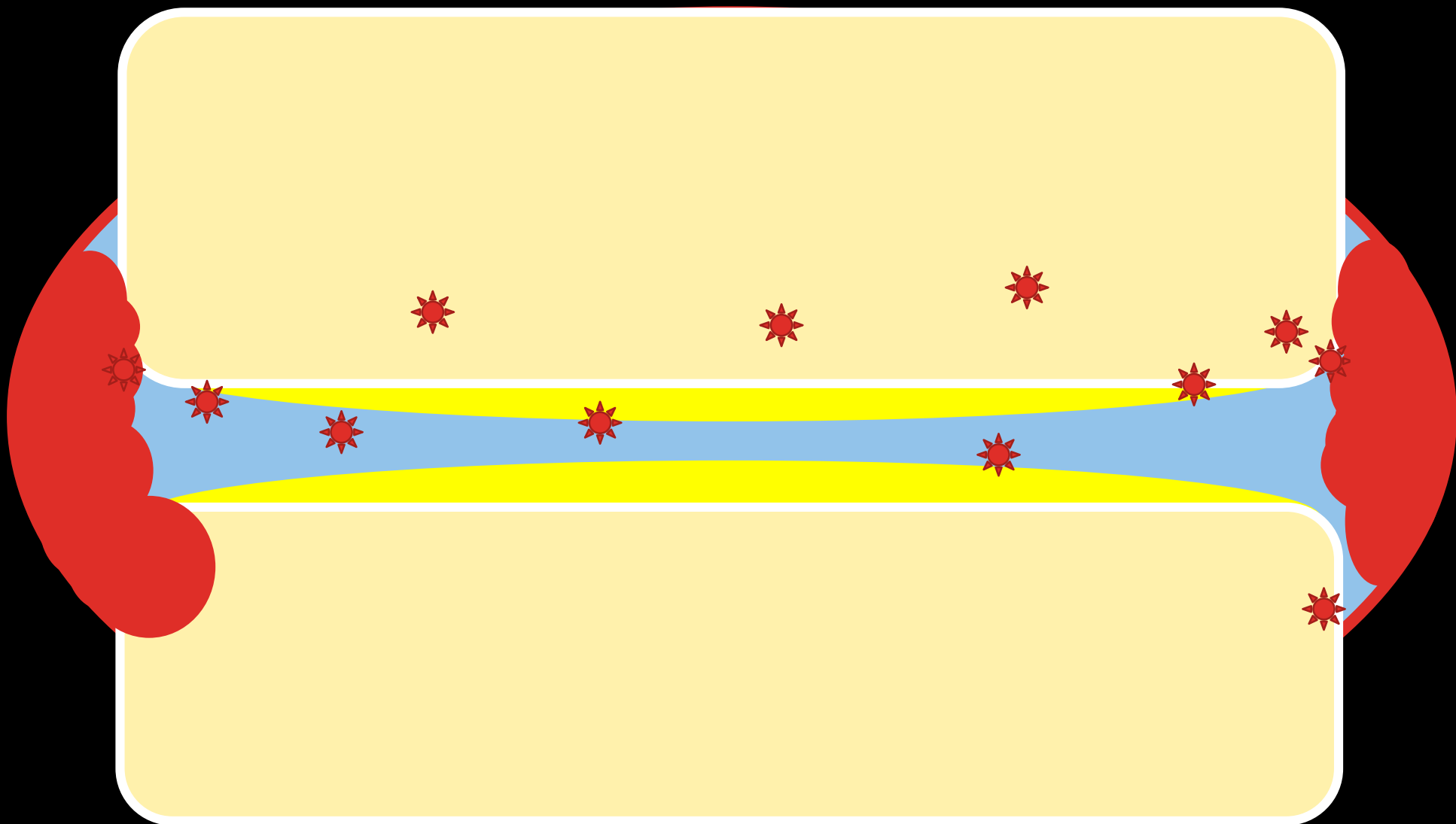








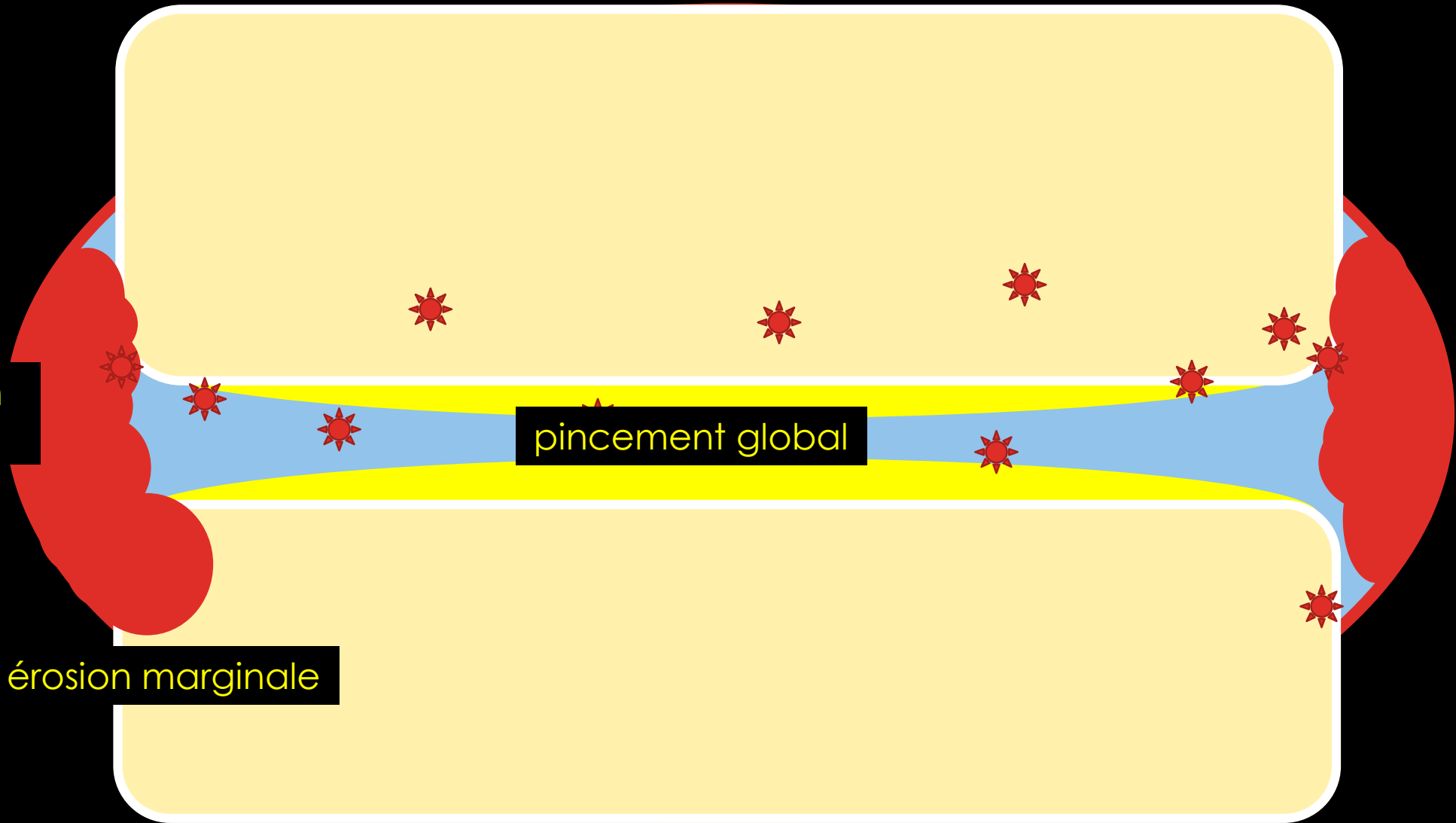


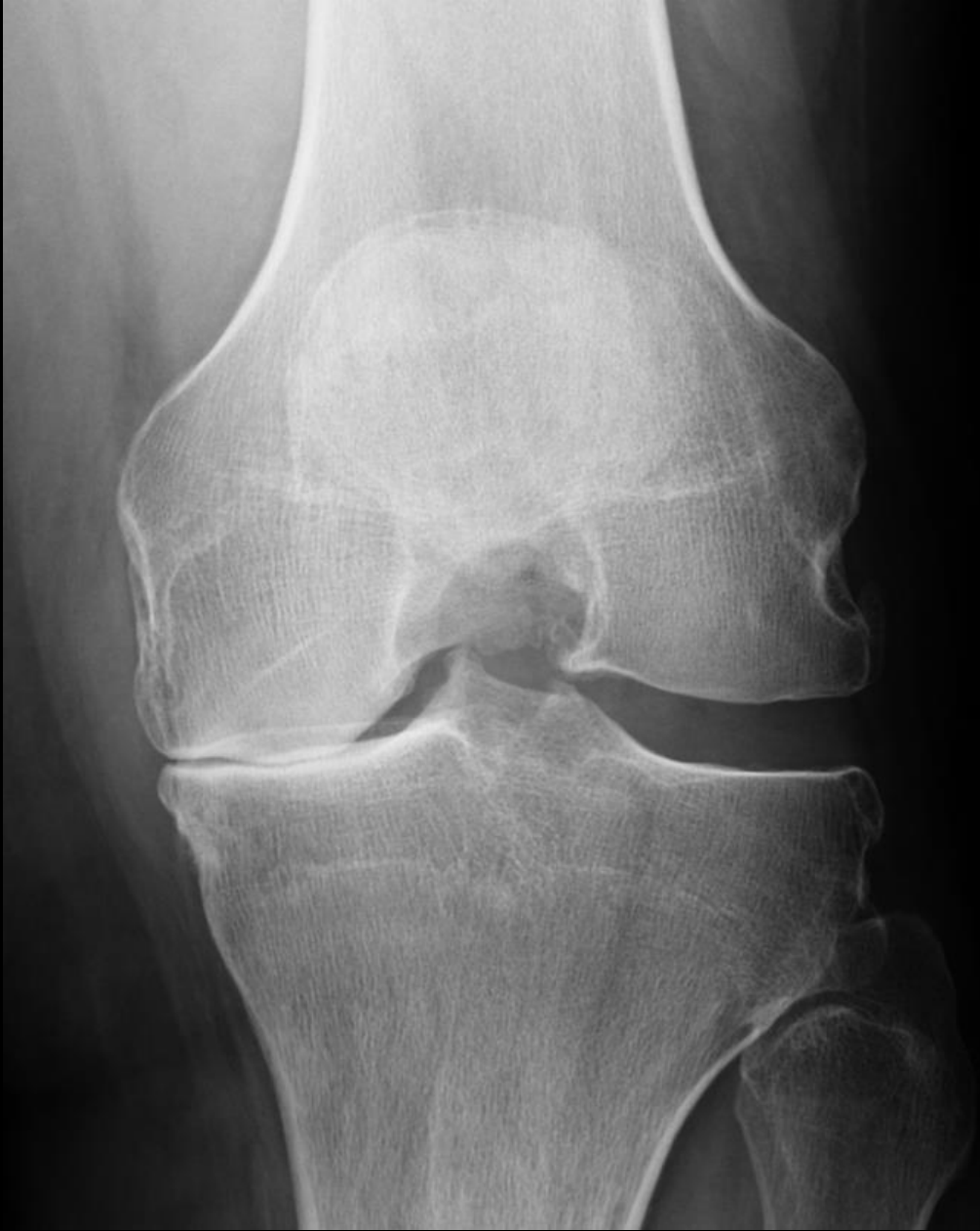

tuméfaction  
synoviale

érosion marginale

pincement global



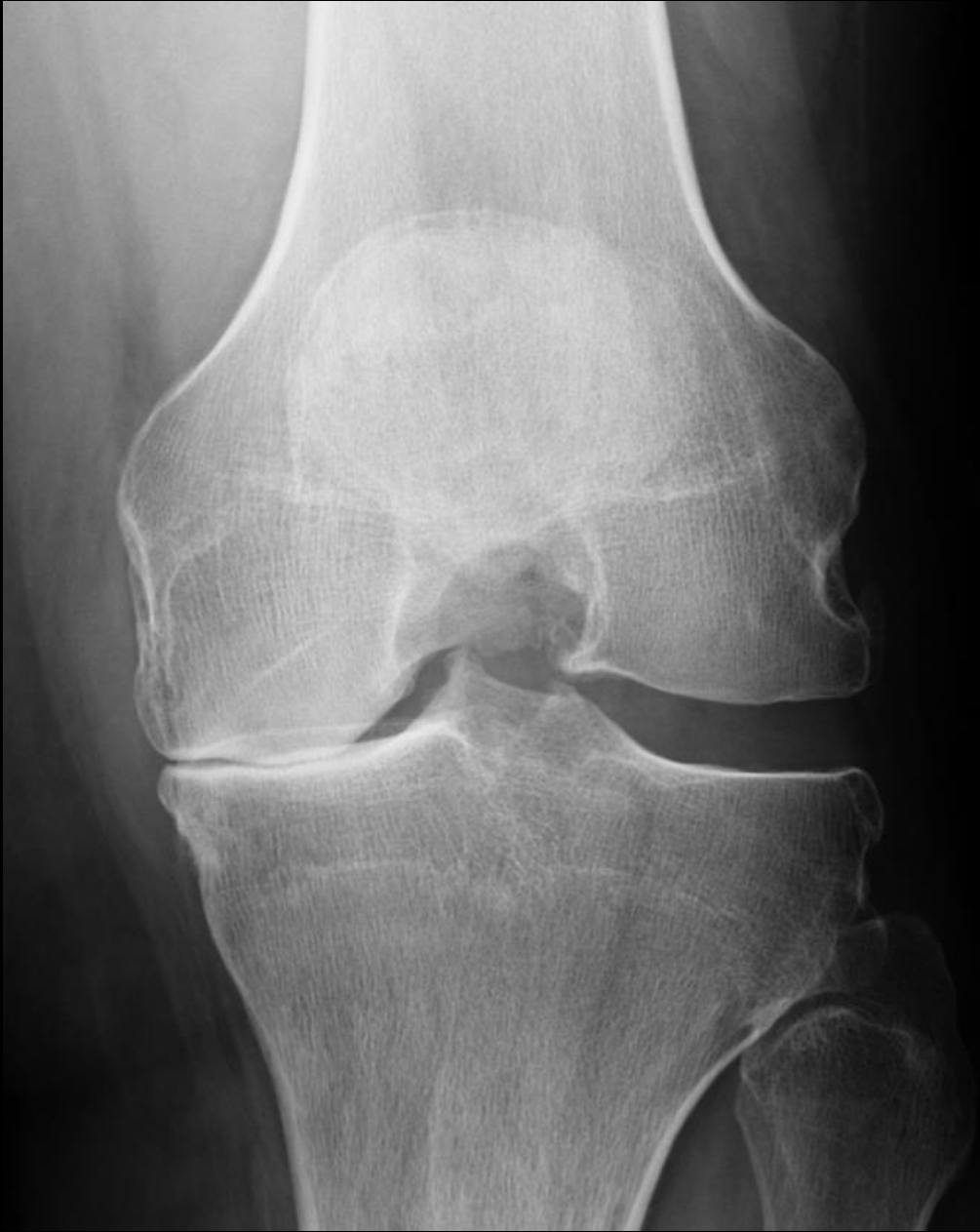

Interligne articulaire?

A – Pincement focal

B – Pincement global

C – Pas de pincement



Interligne articulaire?

A – Pincement focal

B – Pincement global

C – Pas de pincement



Interligne articulaire?

A – Pincement focal

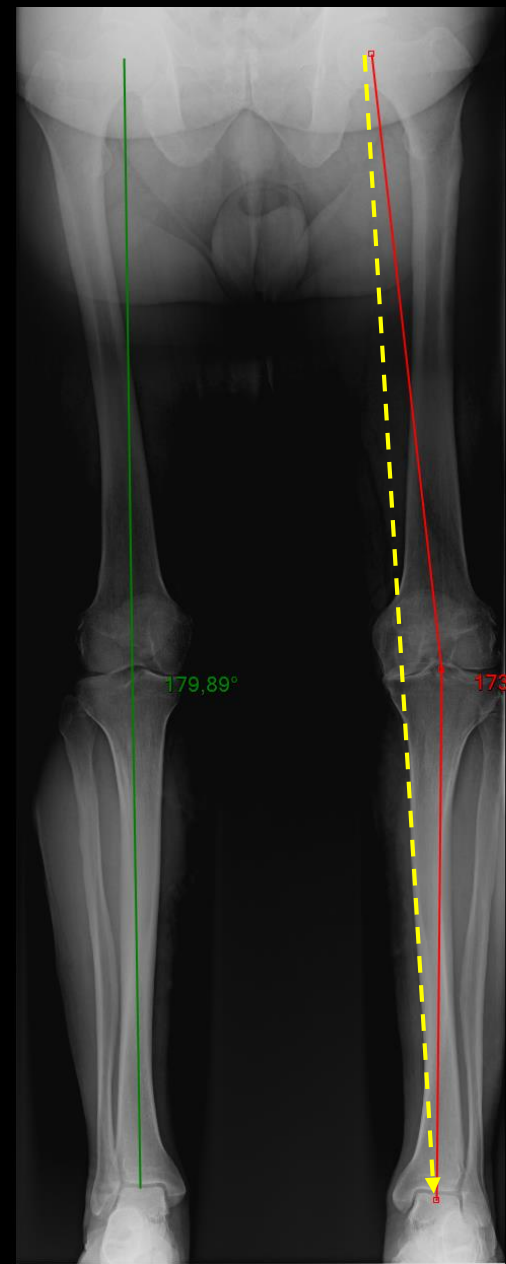
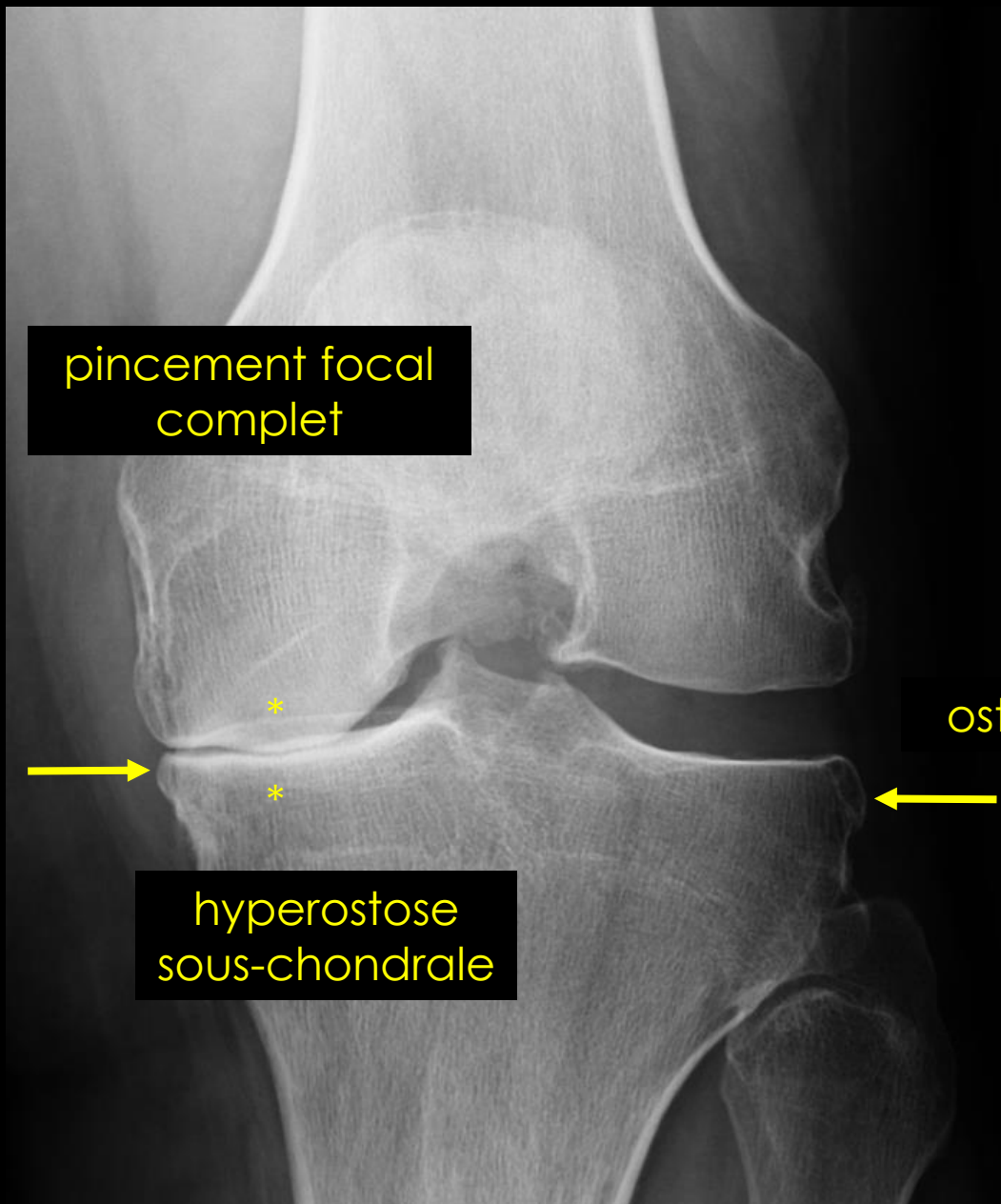
B – Pincement global

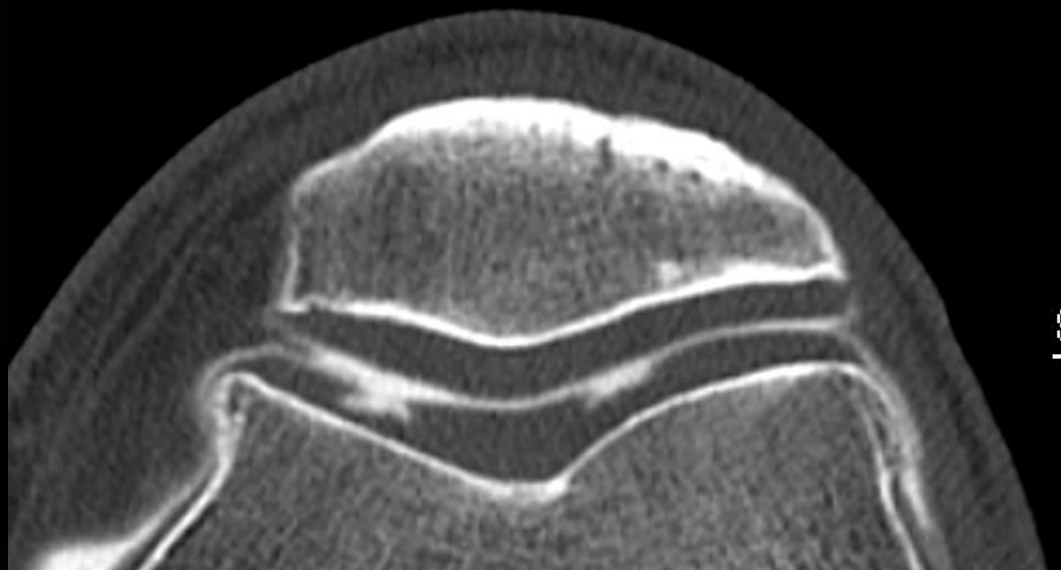
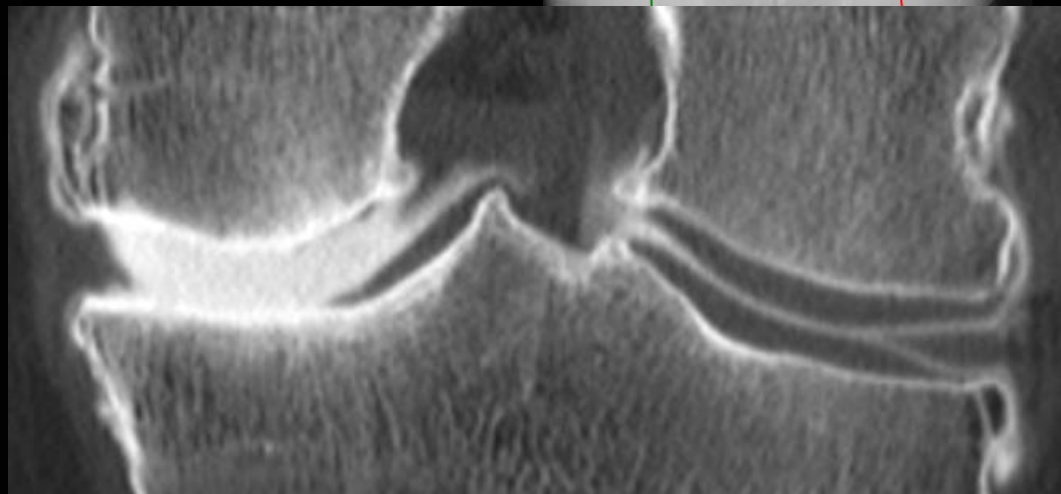
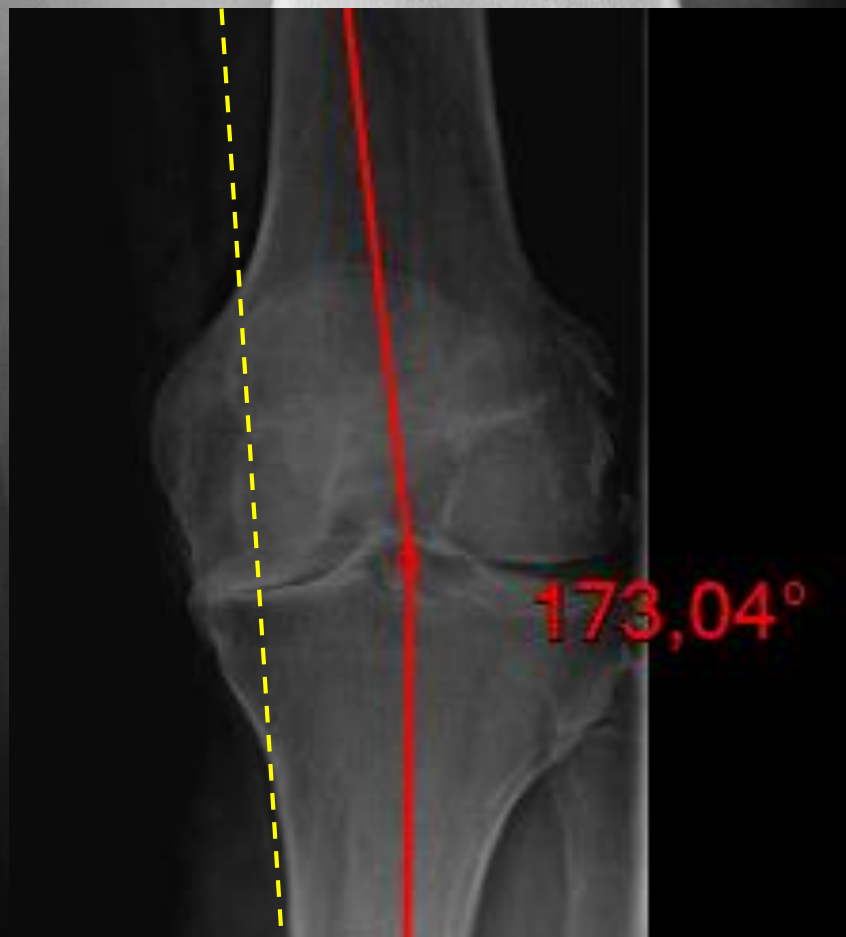C – Pas de pincement

Ostéophyte?

Erosion?

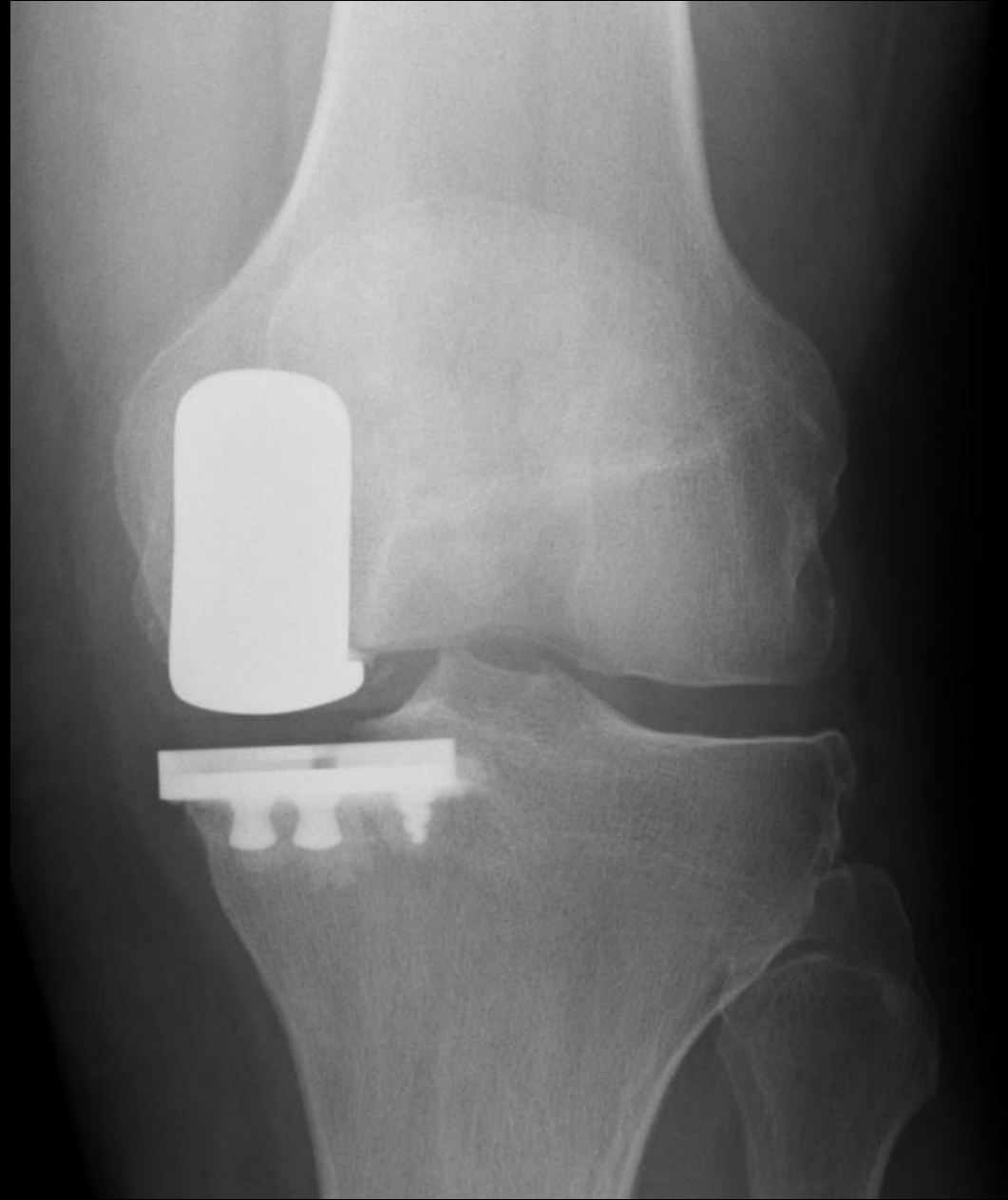
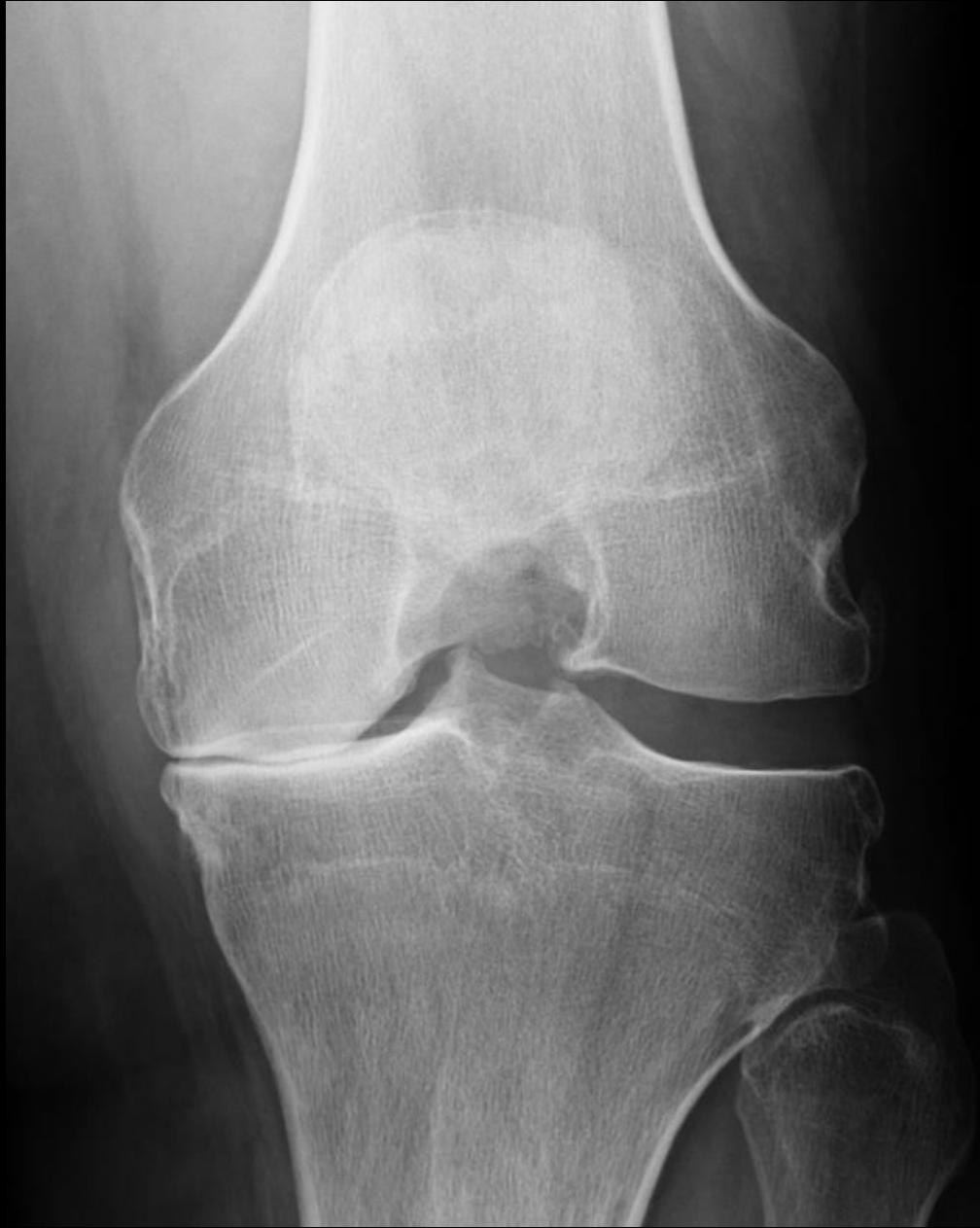


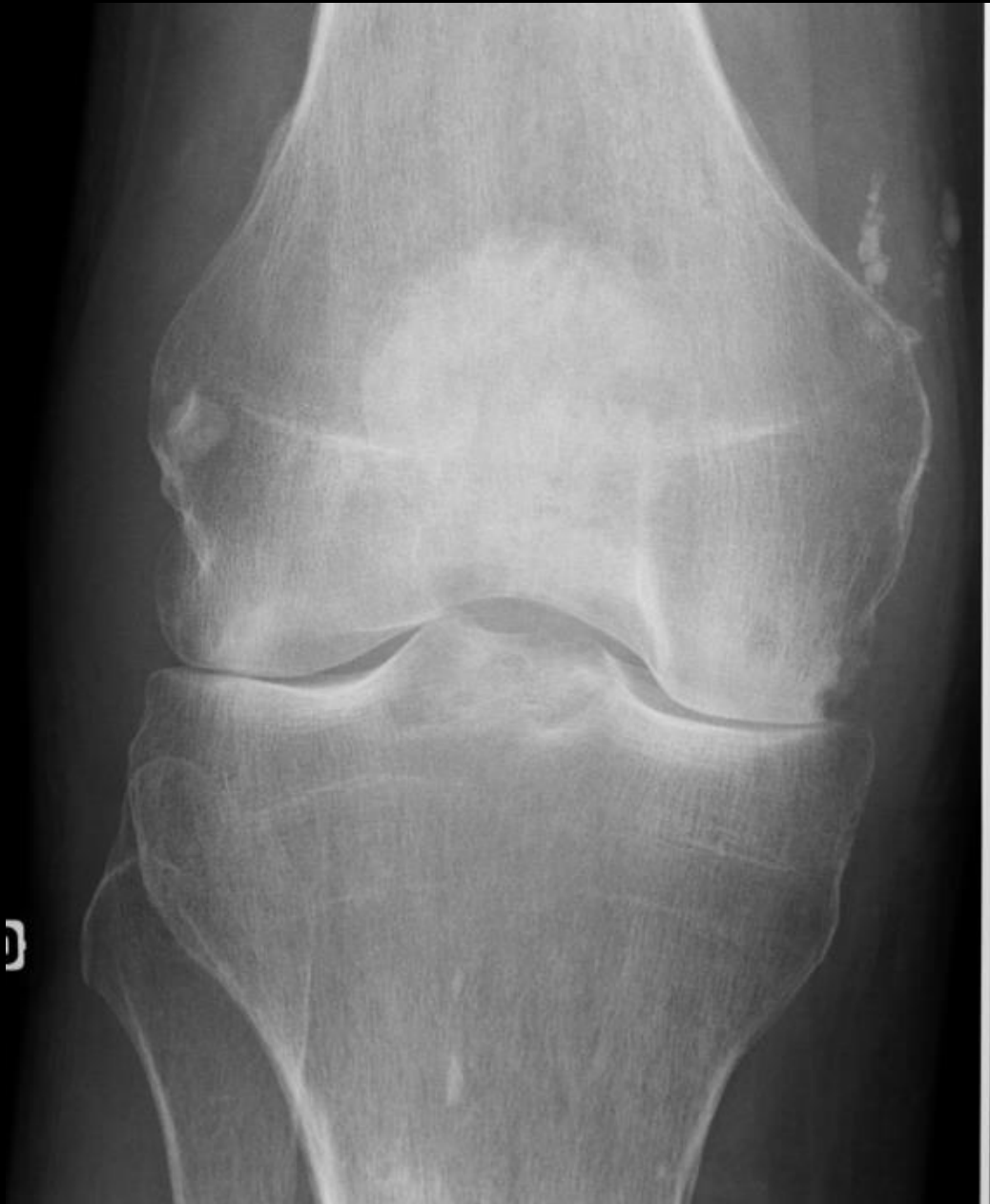




**Traitement de l'arthrose?**





Interligne articulaire?

A – Pincement focal

B – Pincement global

C – Pas de pincement



Interligne articulaire?

A – Pincement focal

B – **Pincement global**

C – Pas de pincement



Interligne articulaire?

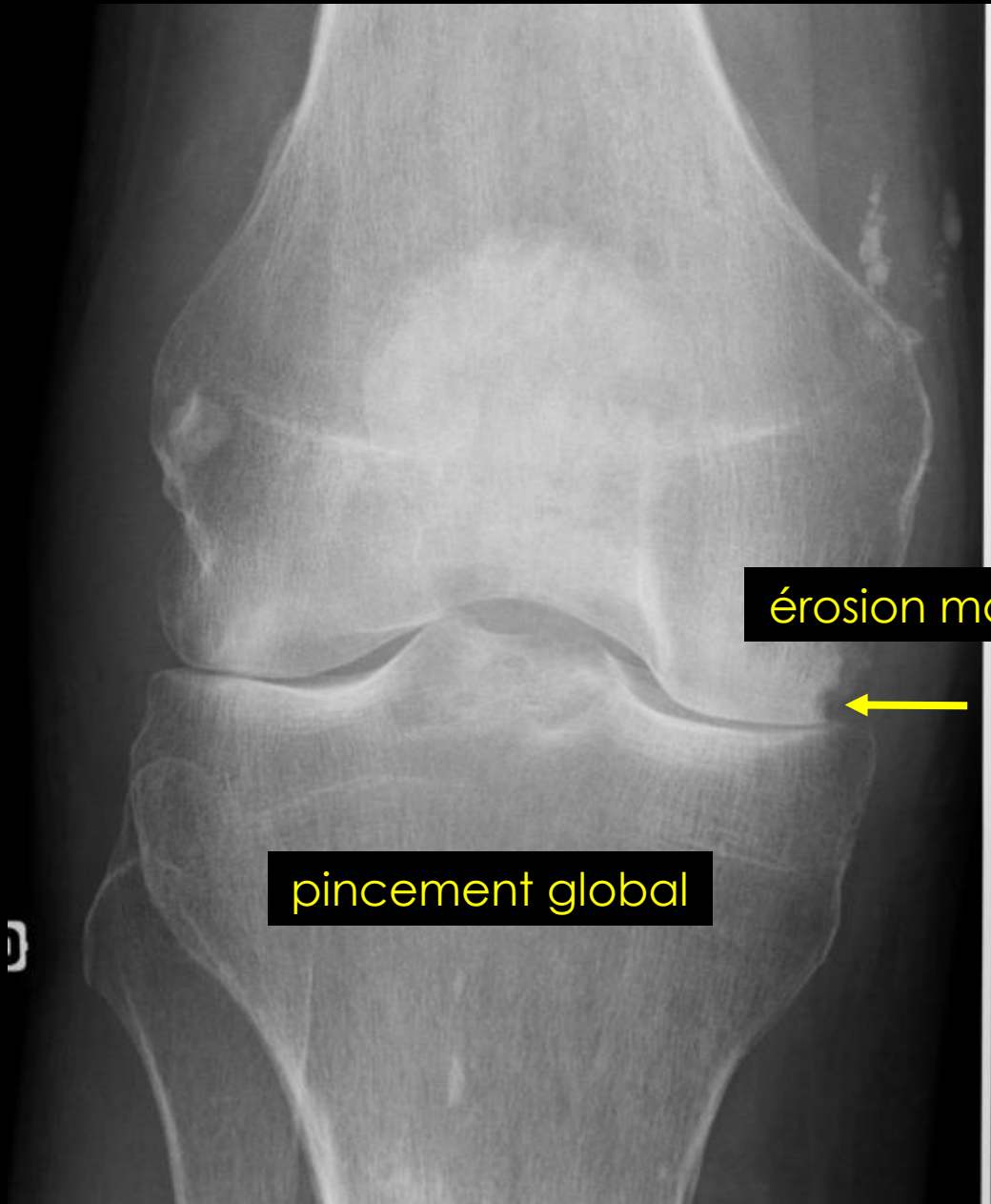
A – Pincement focal

B – **Pincement global**

C – Pas de pincement

Ostéophyte?

Erosion?



Interligne articulaire?

A – Pincement focal

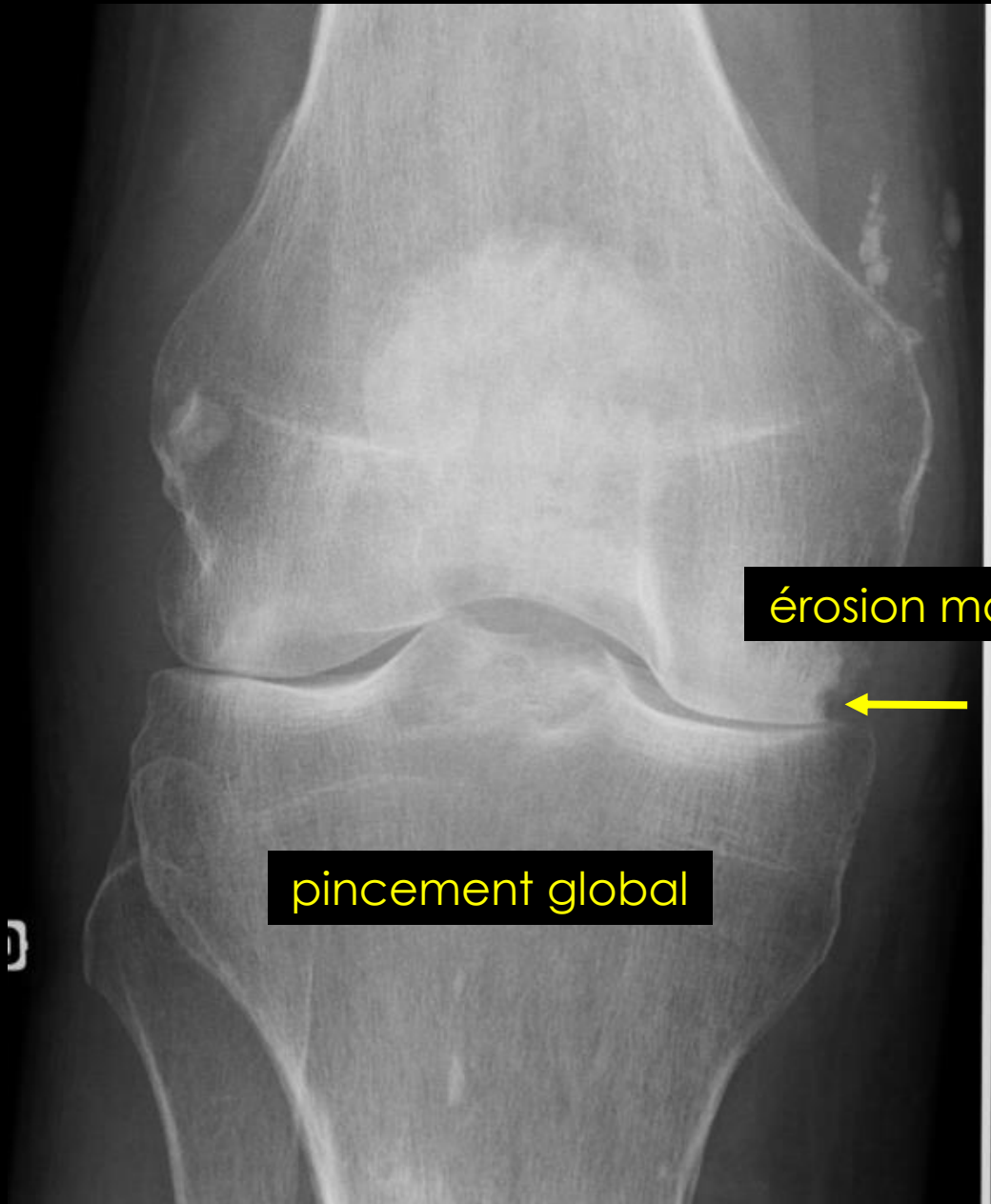
B – **Pincement global**

C – Pas de pincement

Ostéophyte?

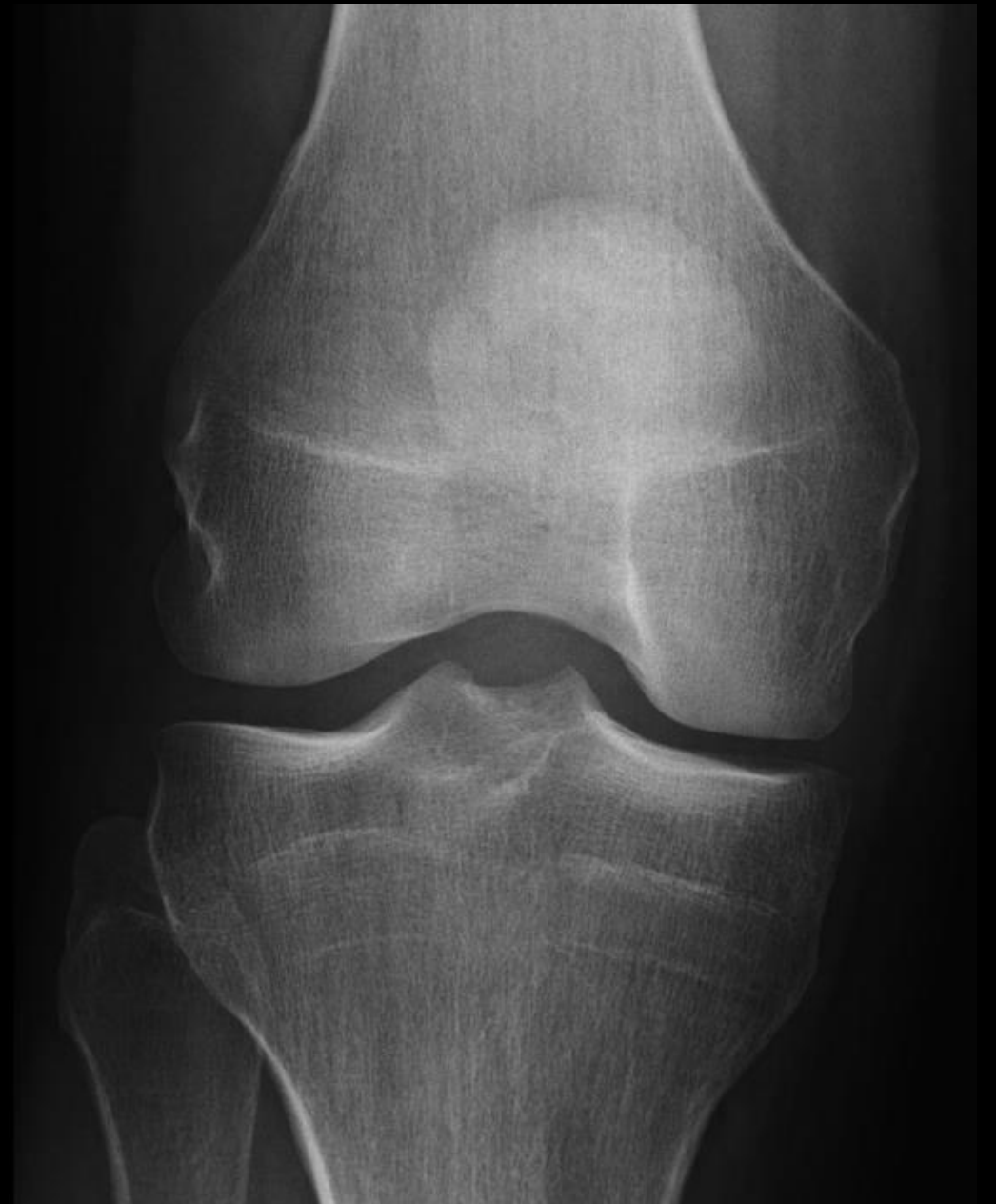Erosion?



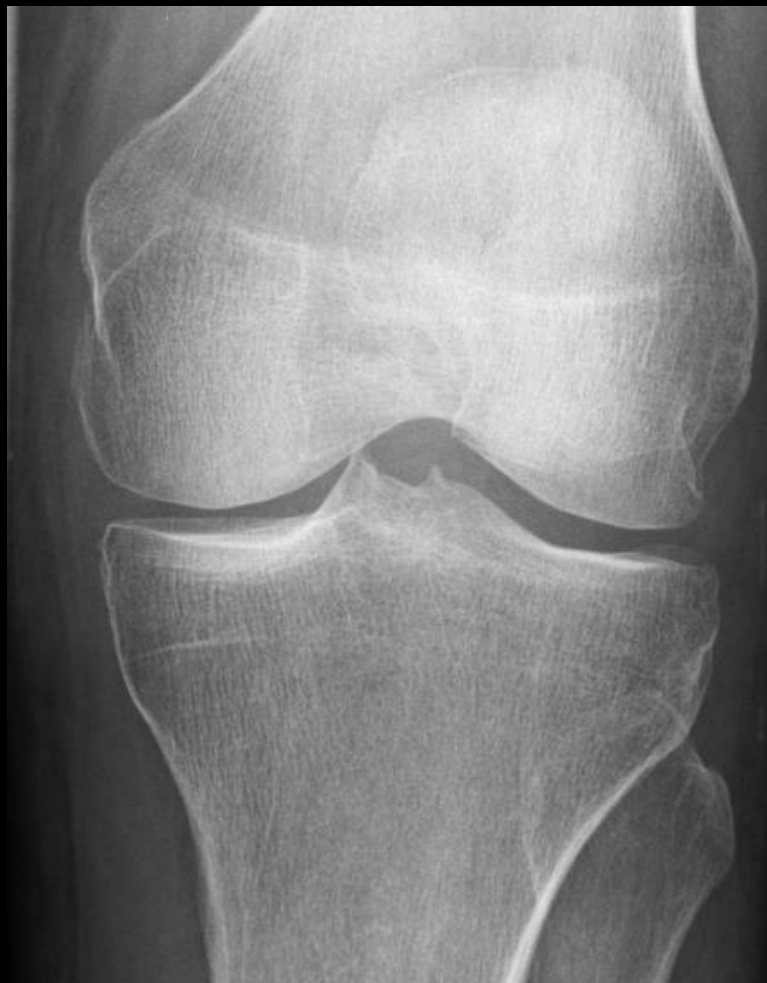

érosion marginale

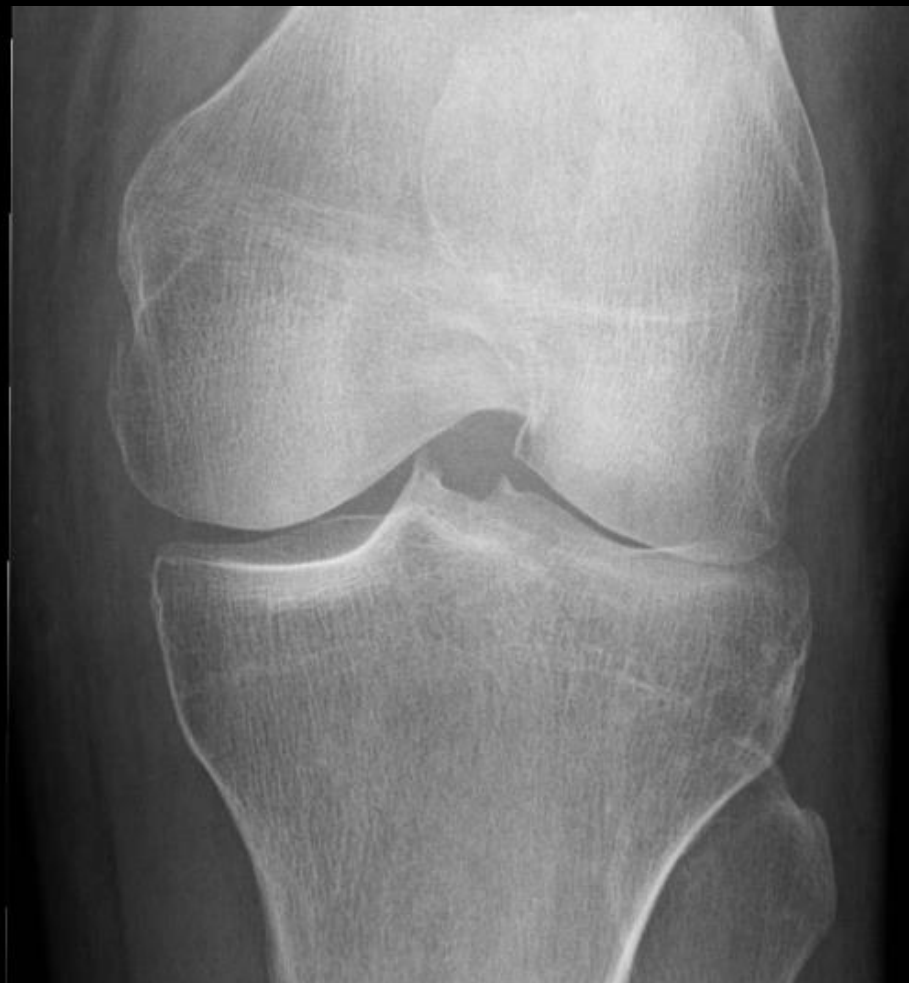pincement global



5 ans plus tôt

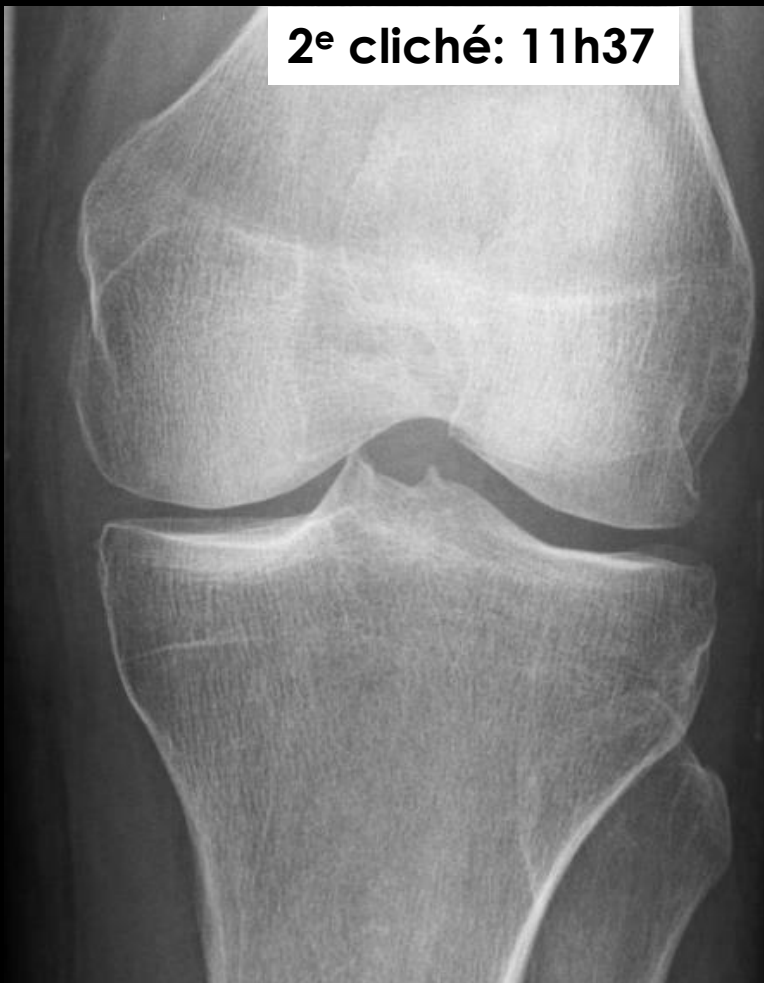

G

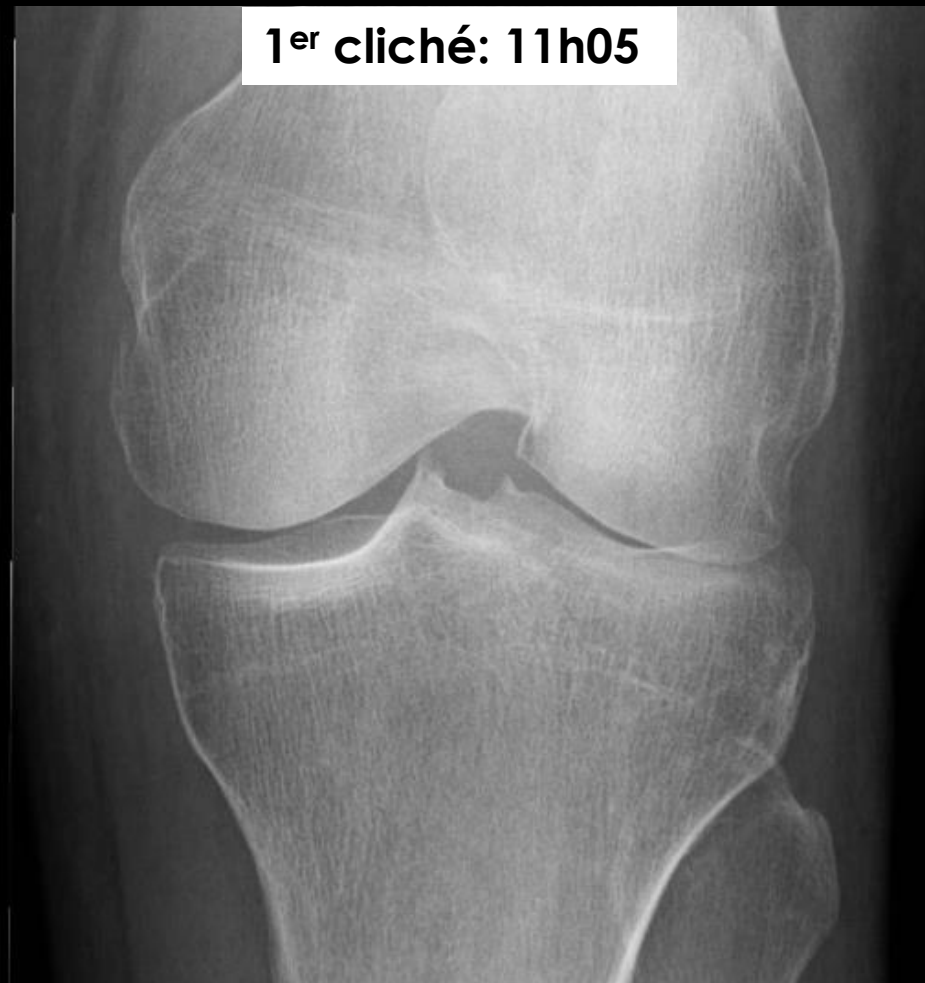

Quel délai entre ces deux examens?

2<sup>e</sup> cliché: 11h37

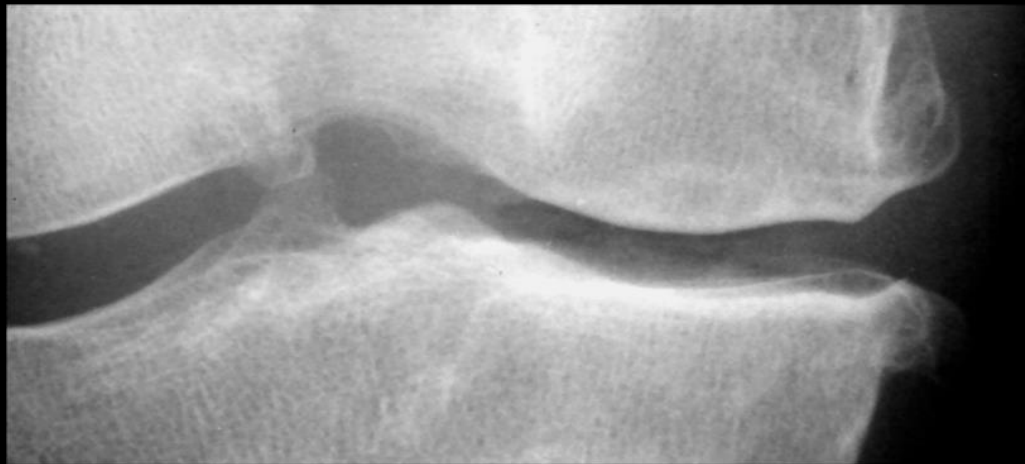


1<sup>er</sup> cliché: 11h05



*artefact technique*

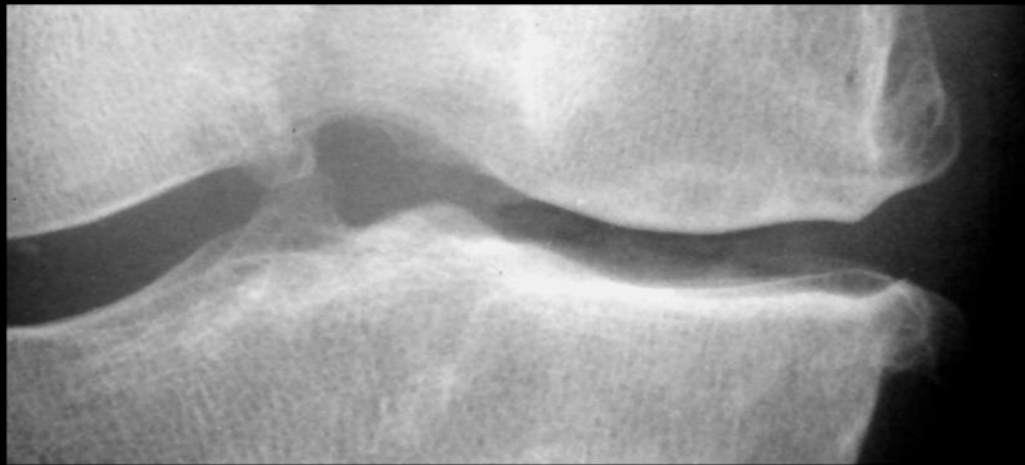
Quel délai entre ces deux examens?



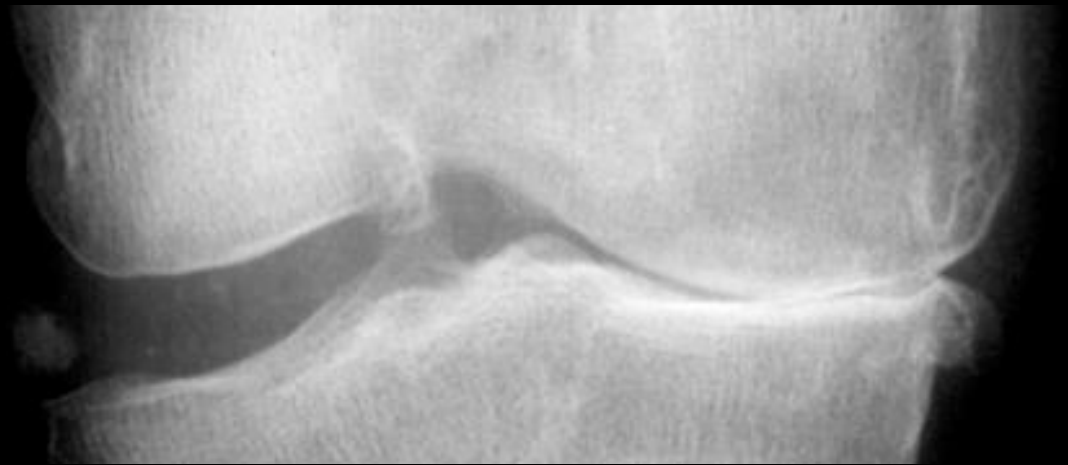
Interligne normal?

A – Oui

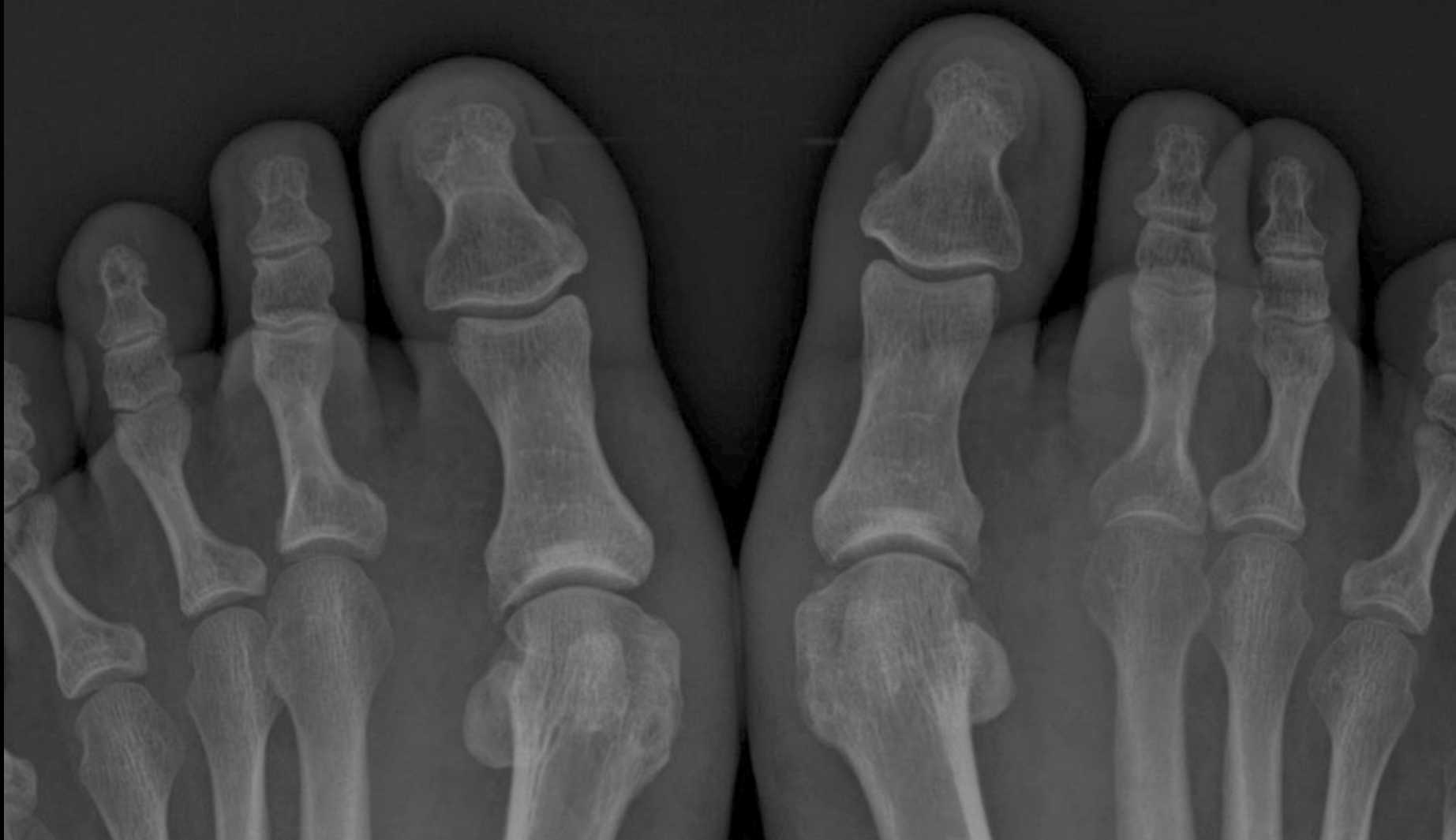B – Non



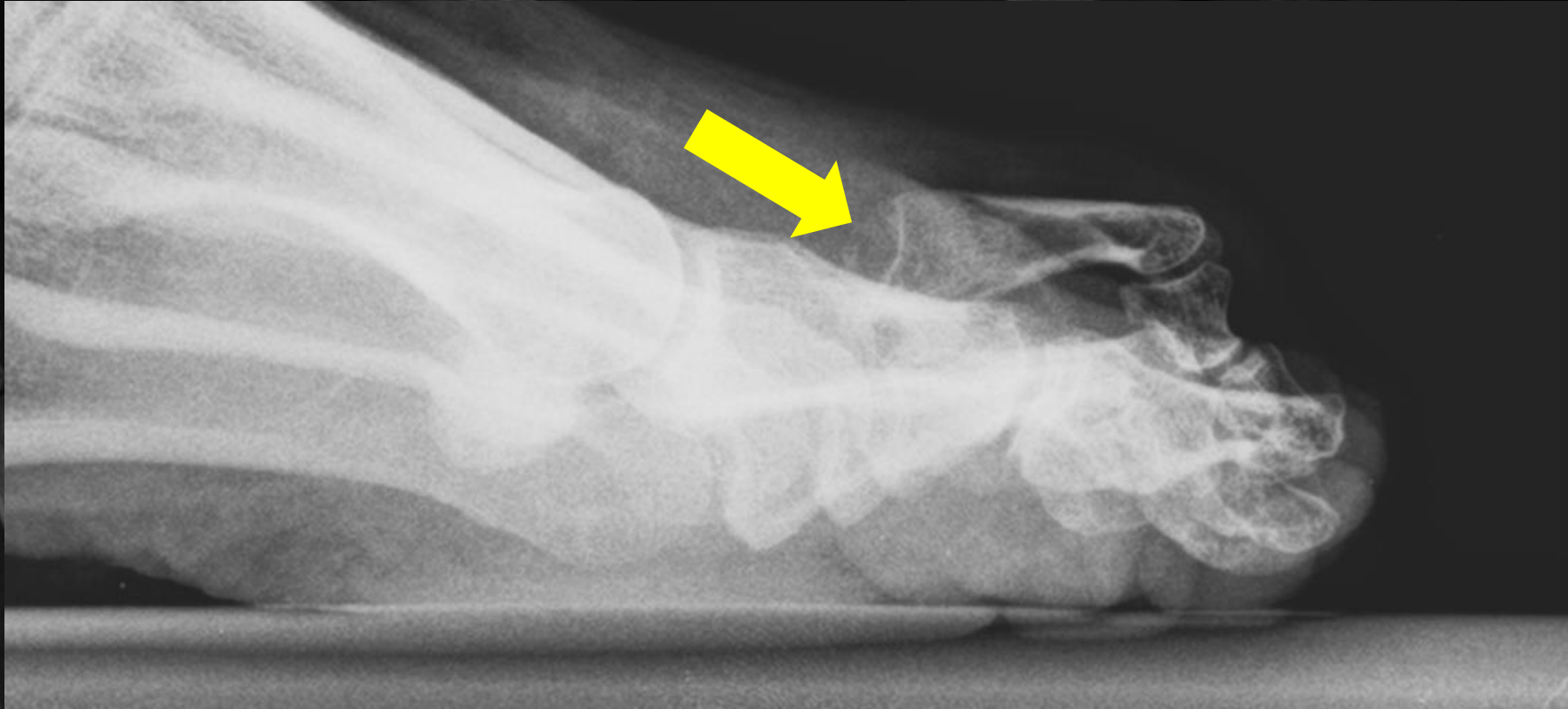
COUCHE



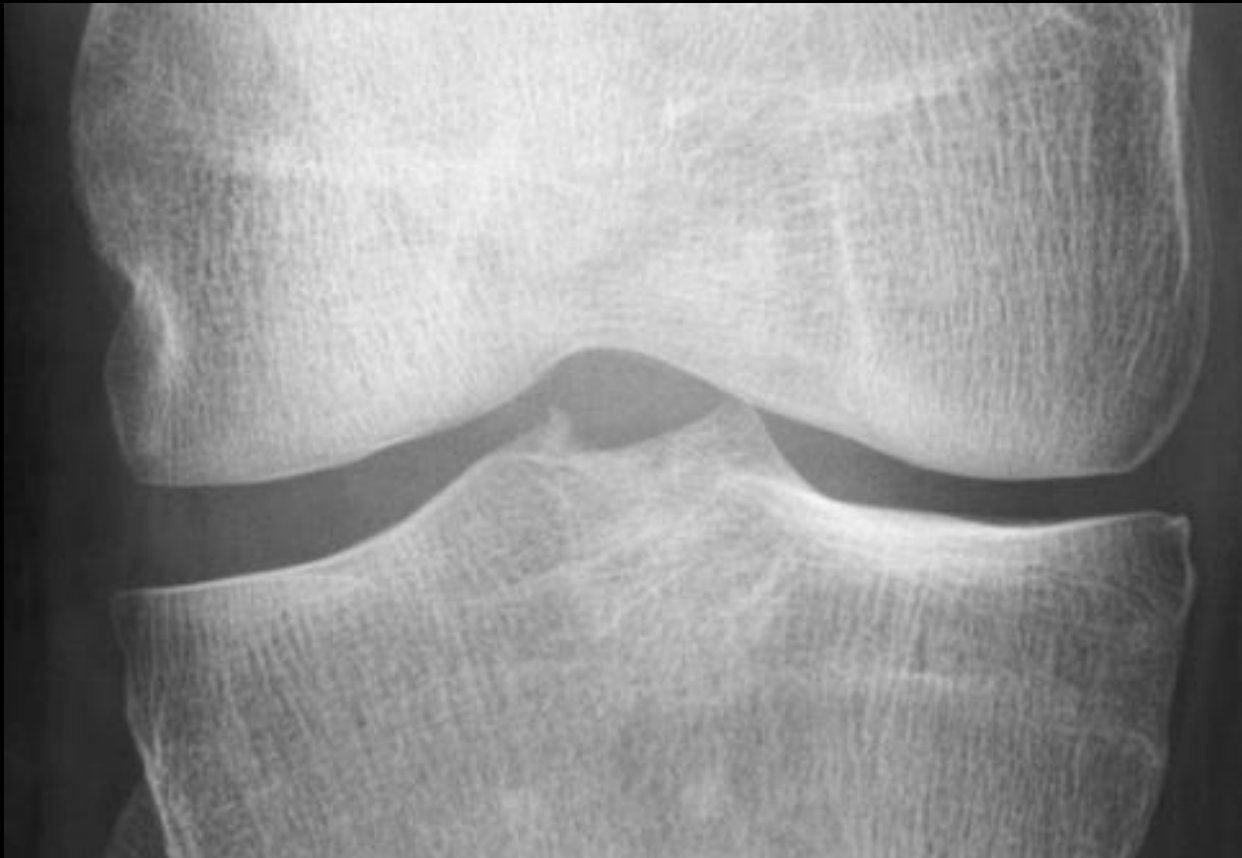DEBOUT



Pincement de l'interligne MTP R2G?



Pincement de l'interligne MTP R2G? *luxation*



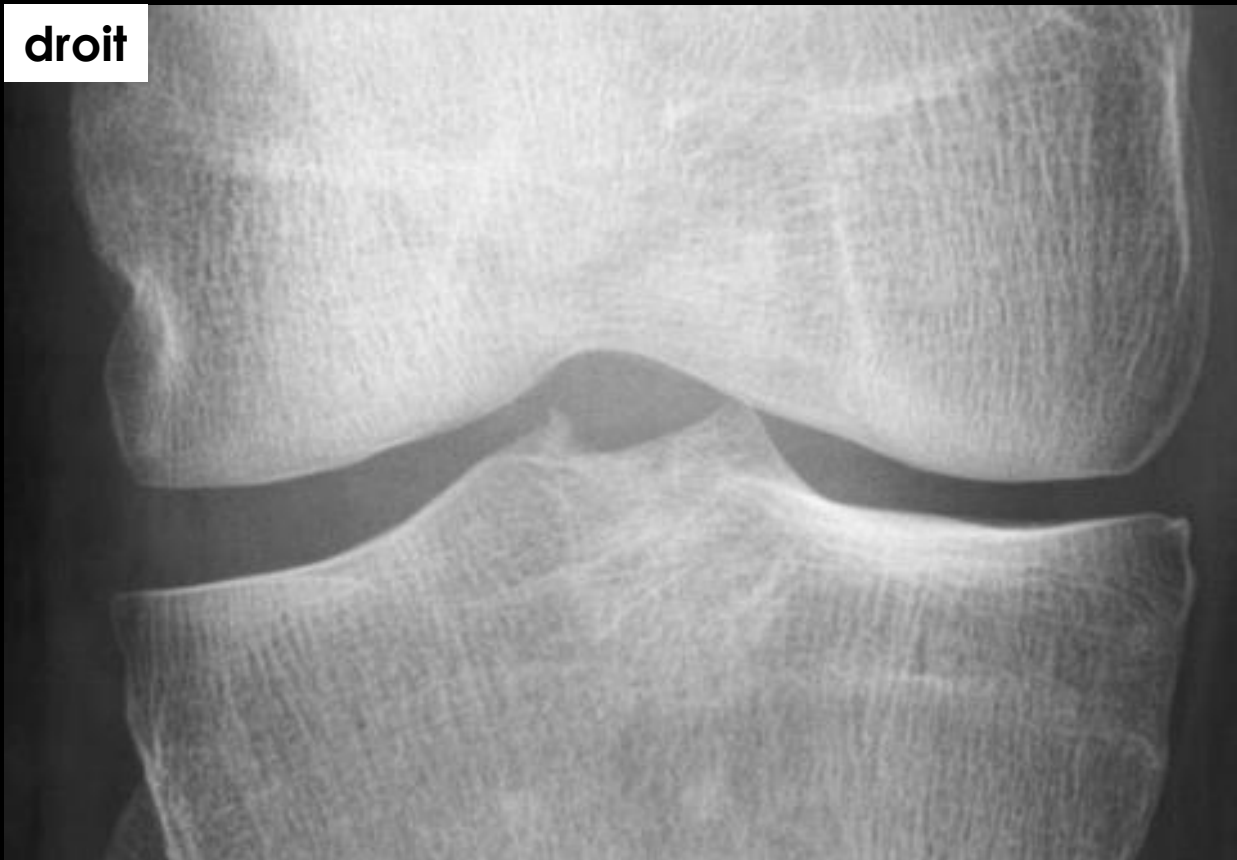Pincement médial?

A – Oui

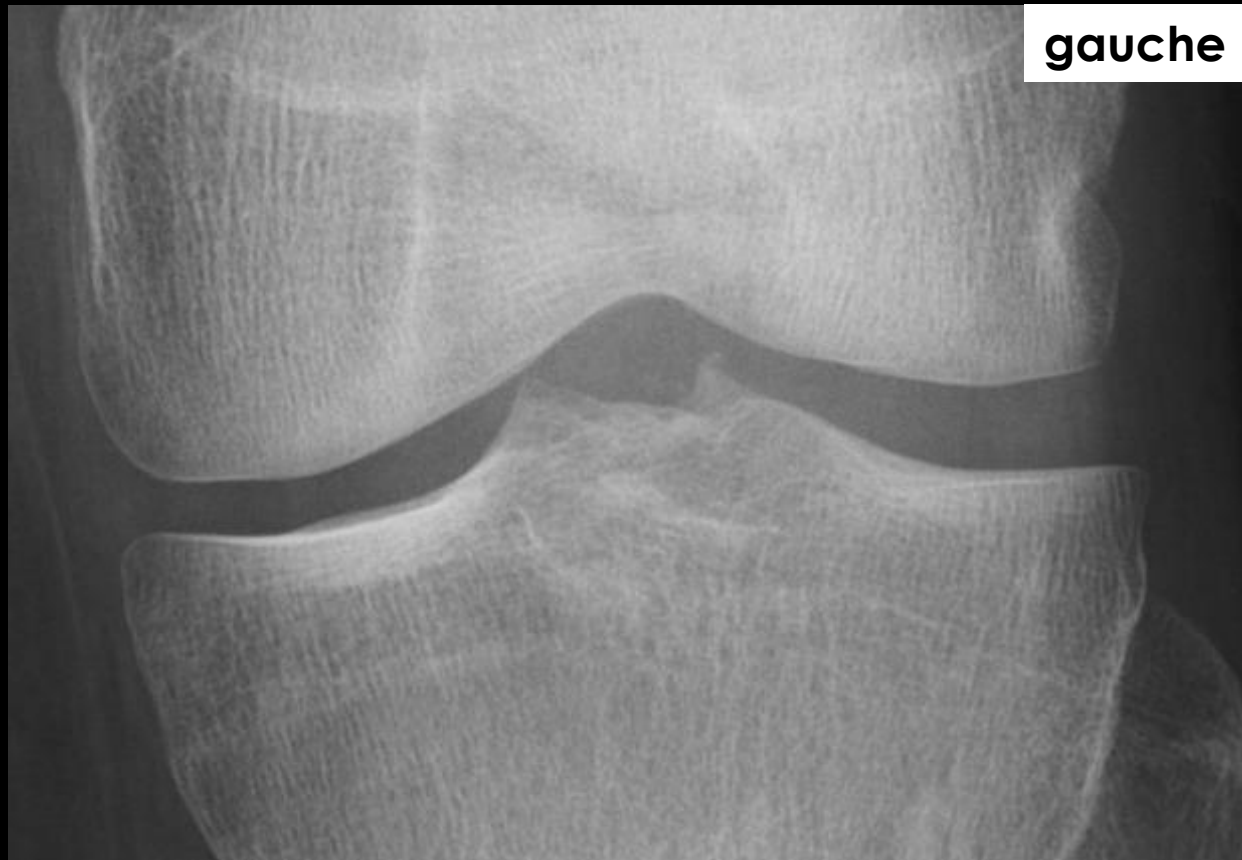B – Non



droit

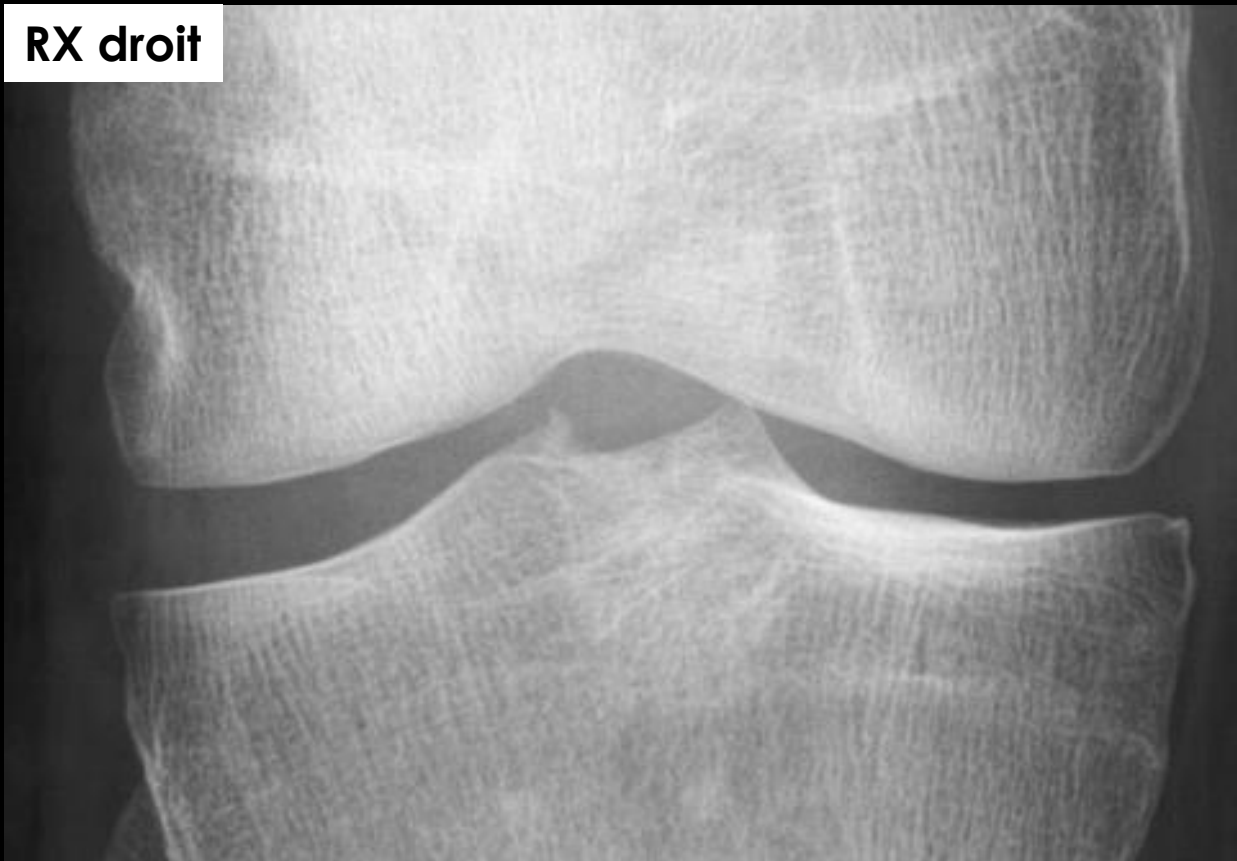

gauche

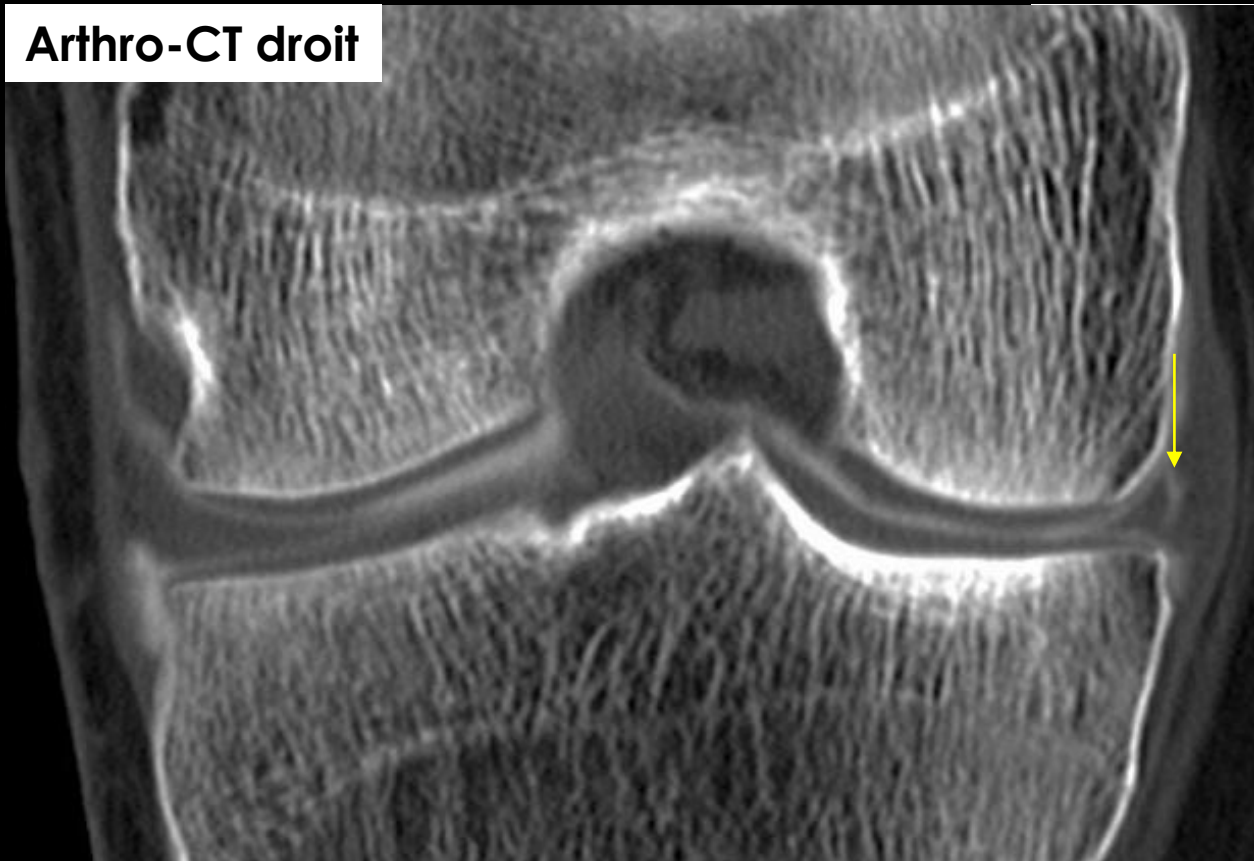


*intérêt des clichés comparatifs*

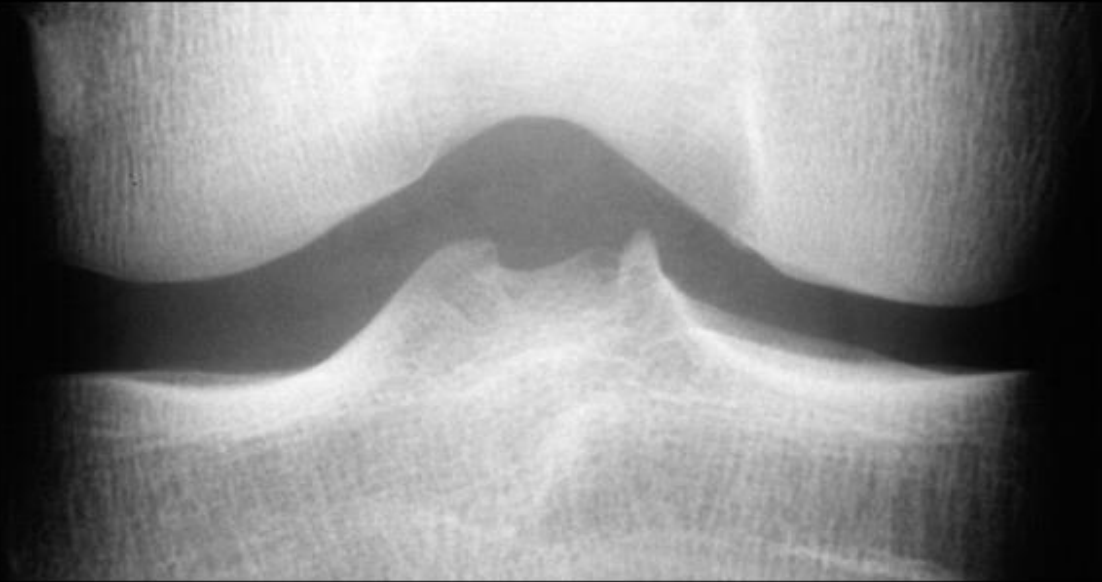**RX droit**



**Arthro-CT droit**



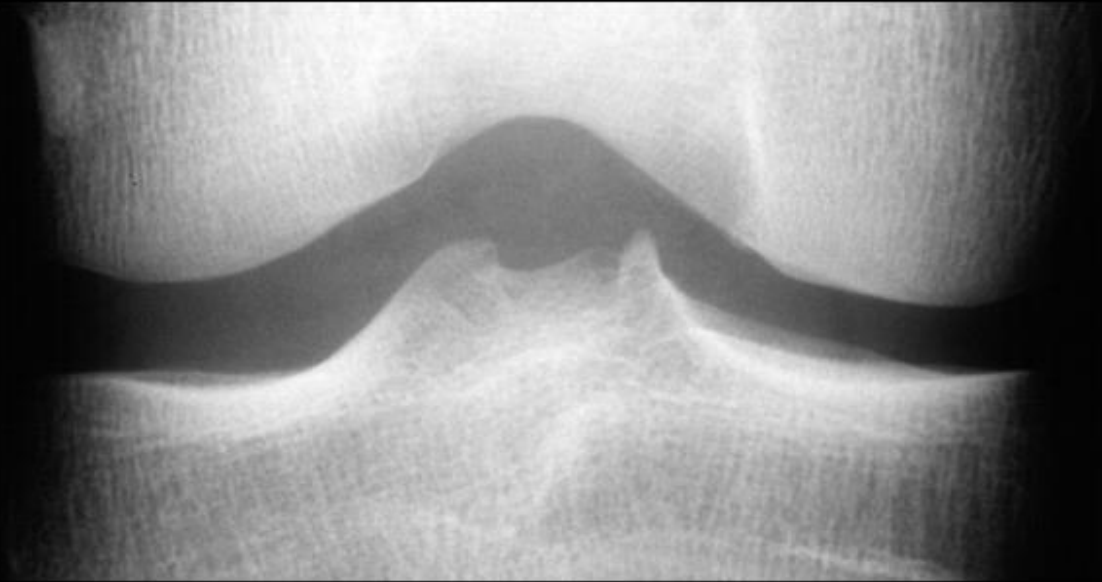
*intérêt des clichés comparatifs*



Interligne normal?

A – Oui

B – Non



Interligne normal?

A – Oui

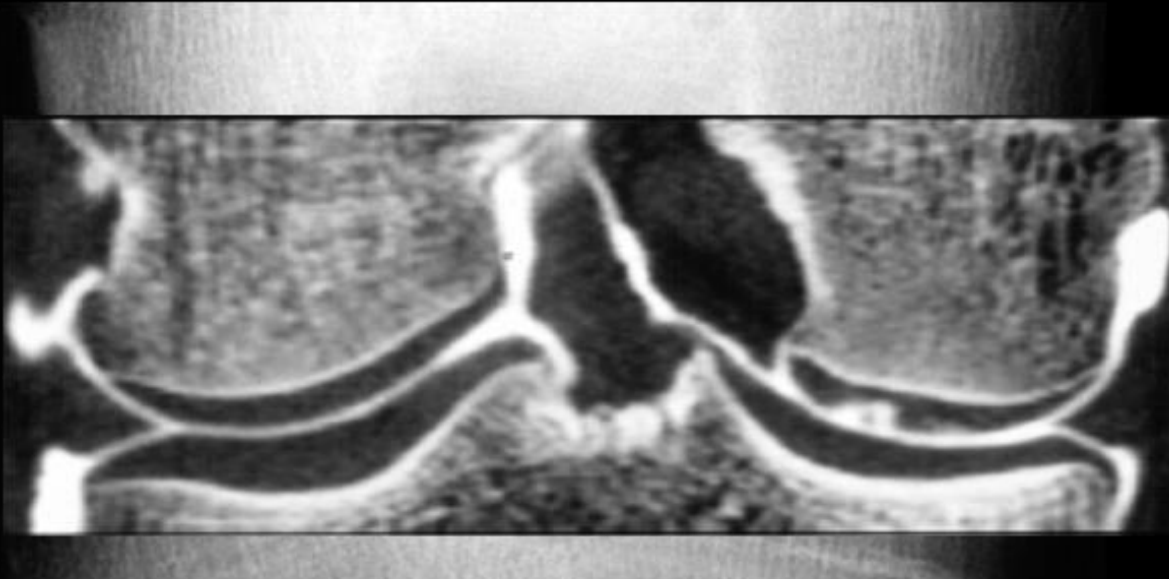B – Non



Cartilage normal?

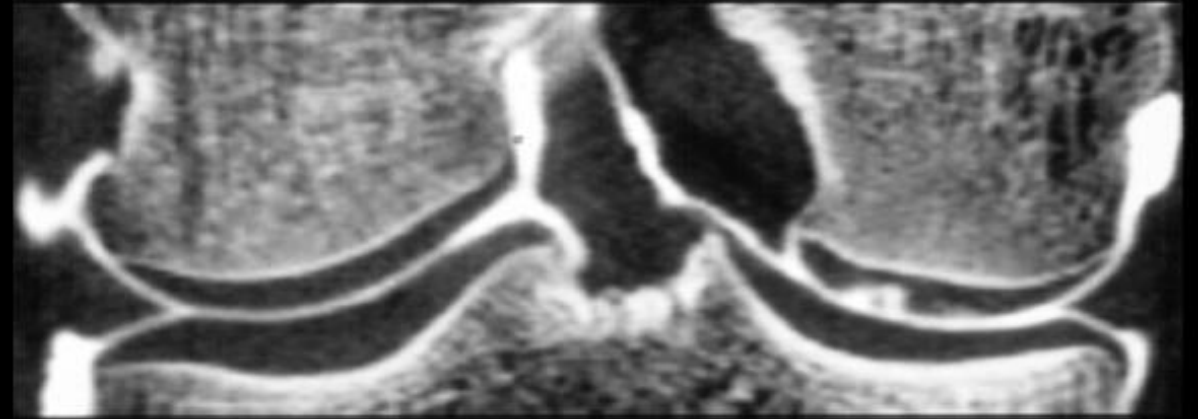
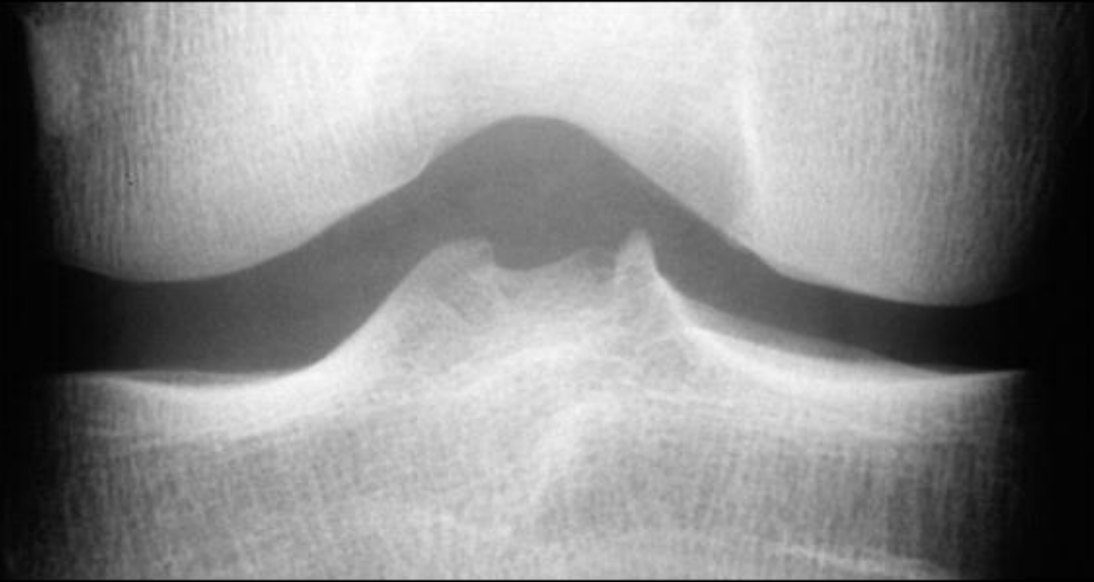
A – Oui

B – Non



Cartilage normal?

A – Oui  
B – **Non**



interligne articulaire en RX = reflet indirect du cartilage

interligne normal  $\neq$  cartilage normal

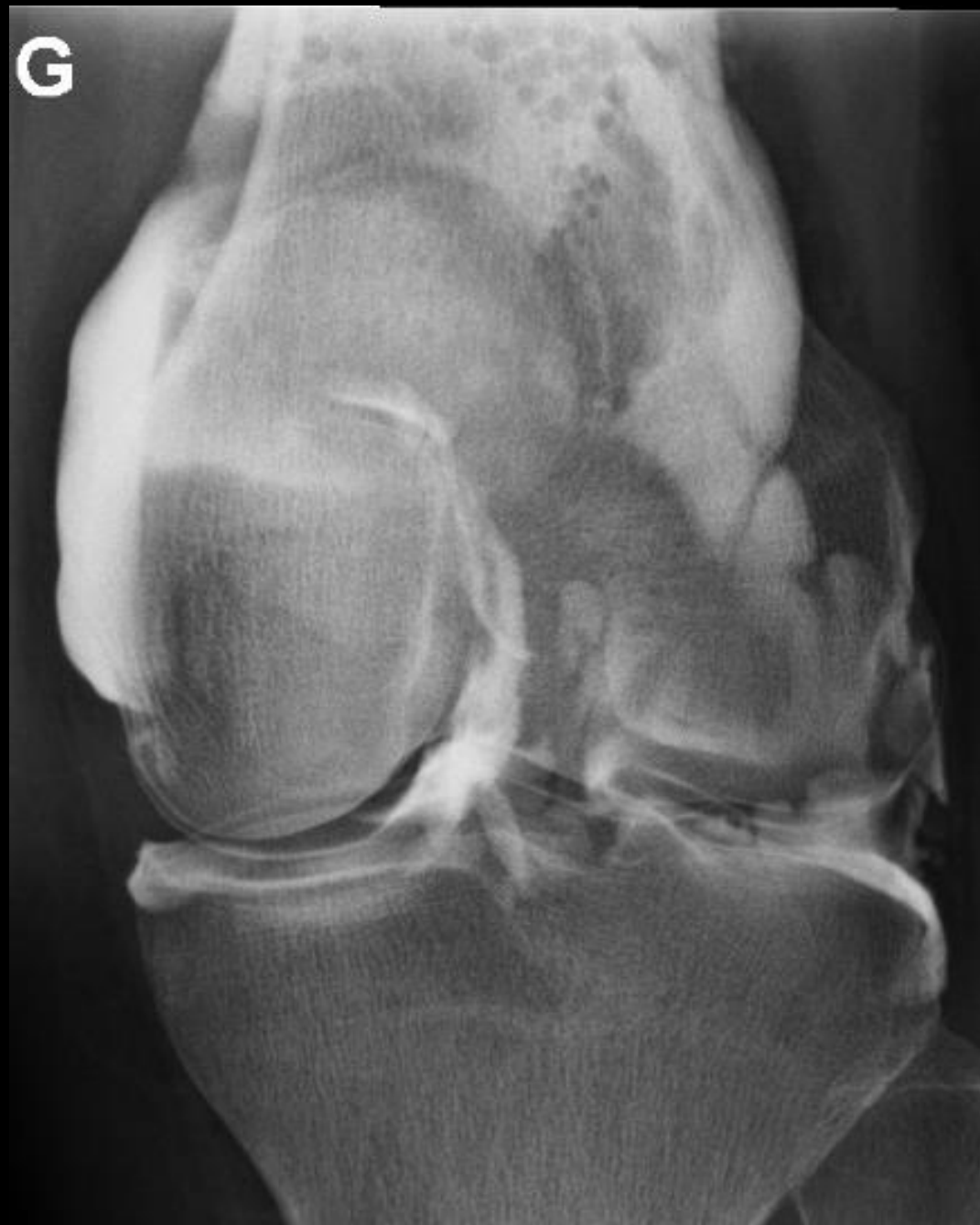
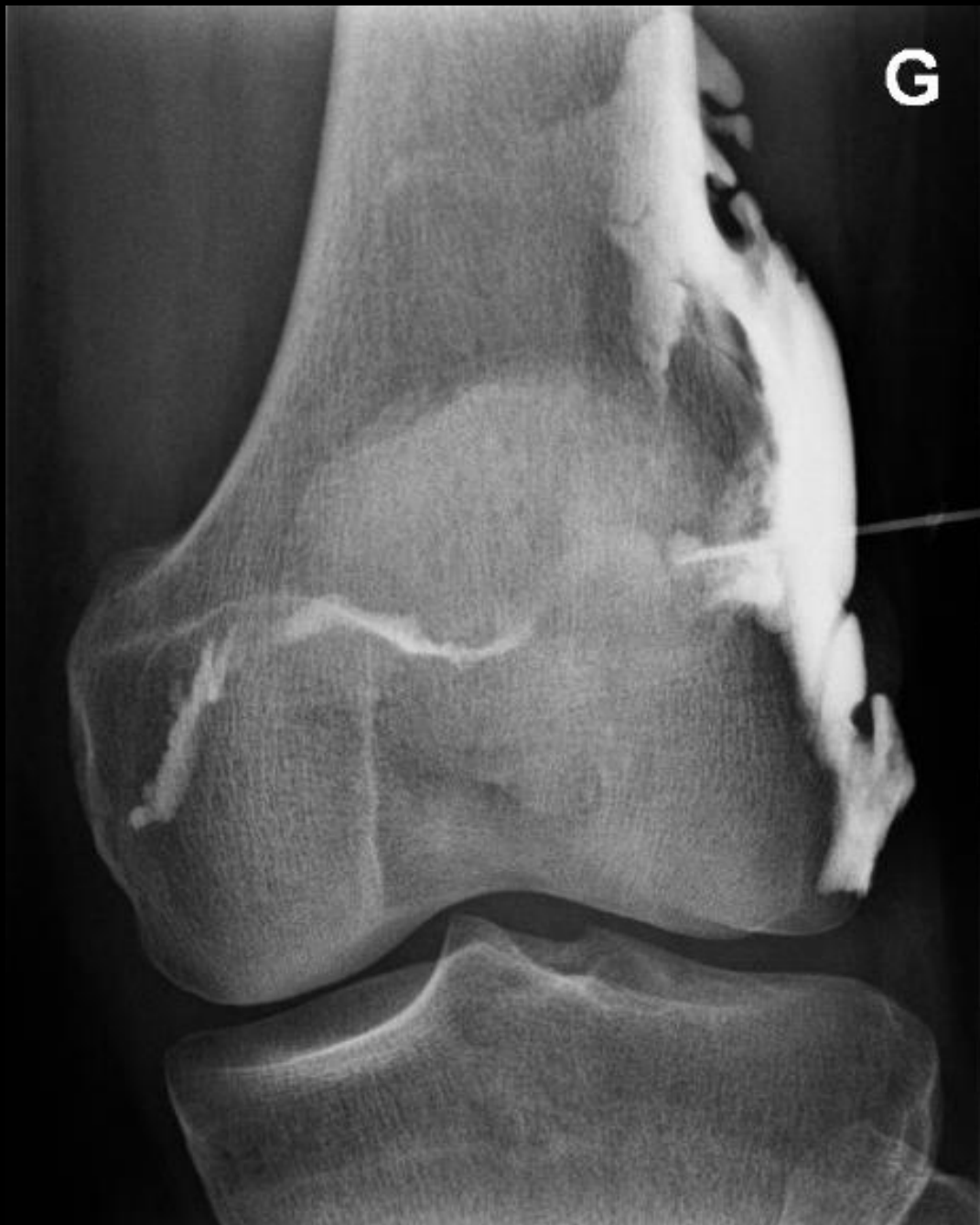
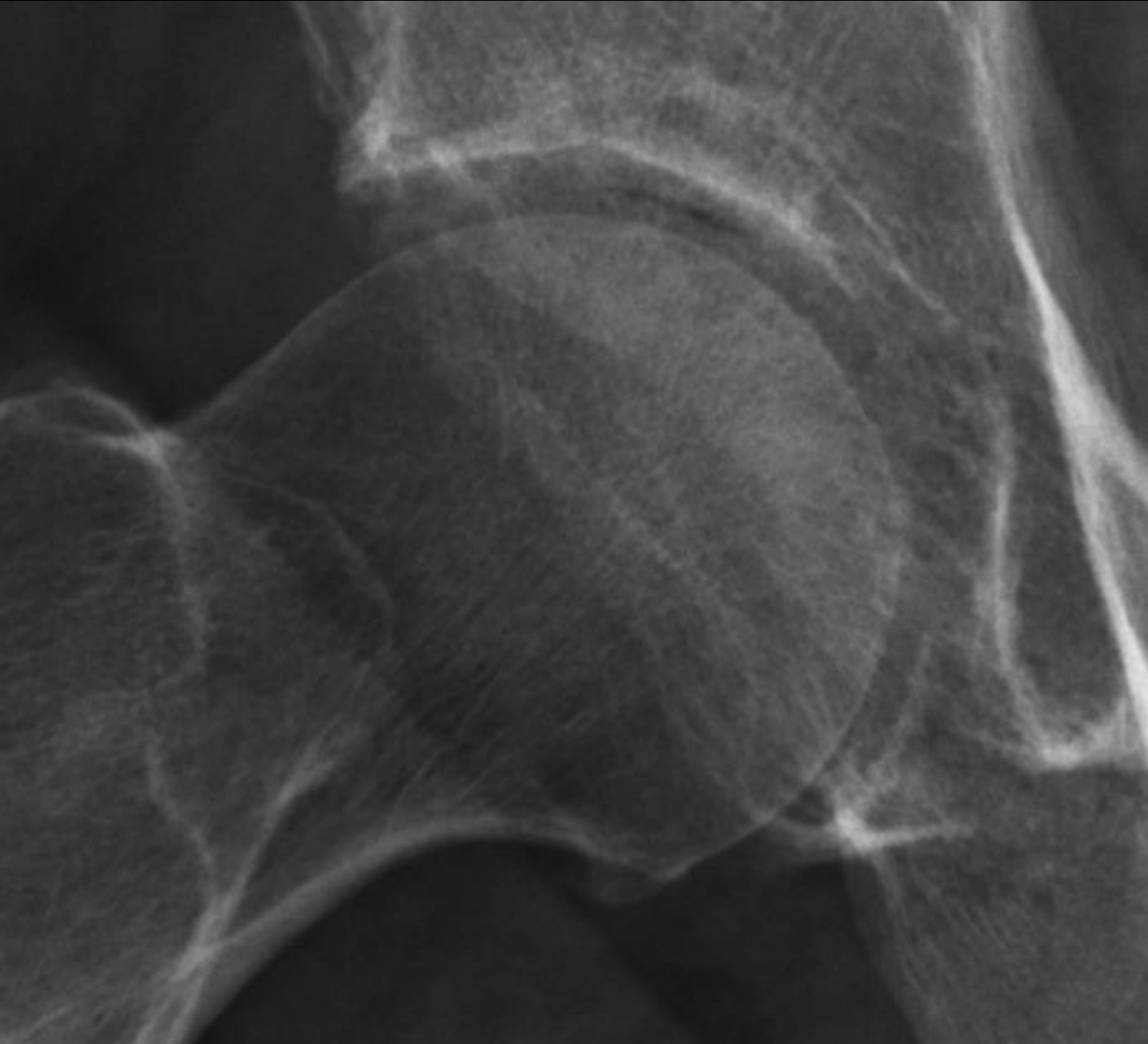
**Peut on voir le cartilage en RX?**

interligne articulaire en RX = reflet indirect du cartilage

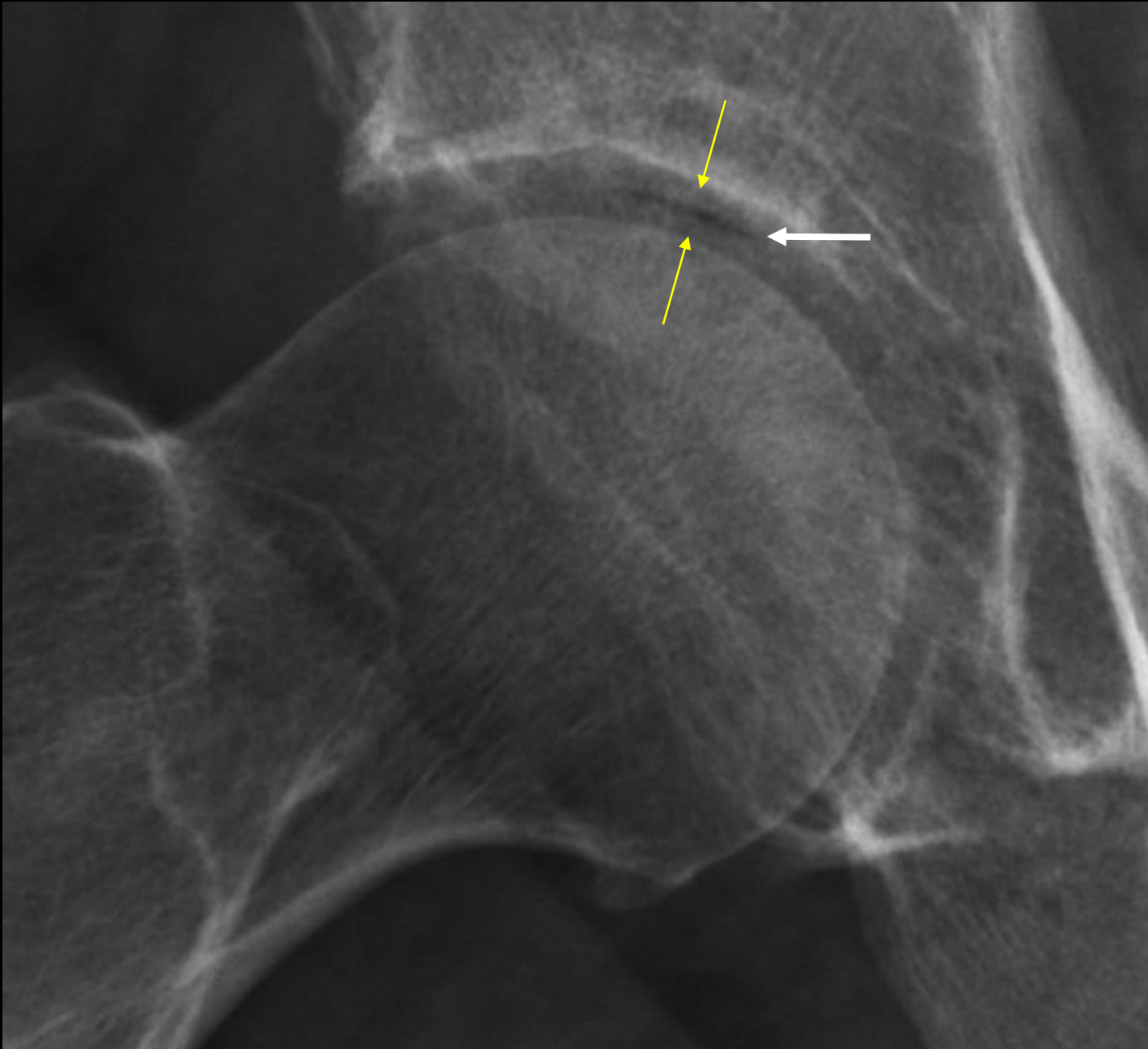
interligne normal  $\neq$  cartilage normal





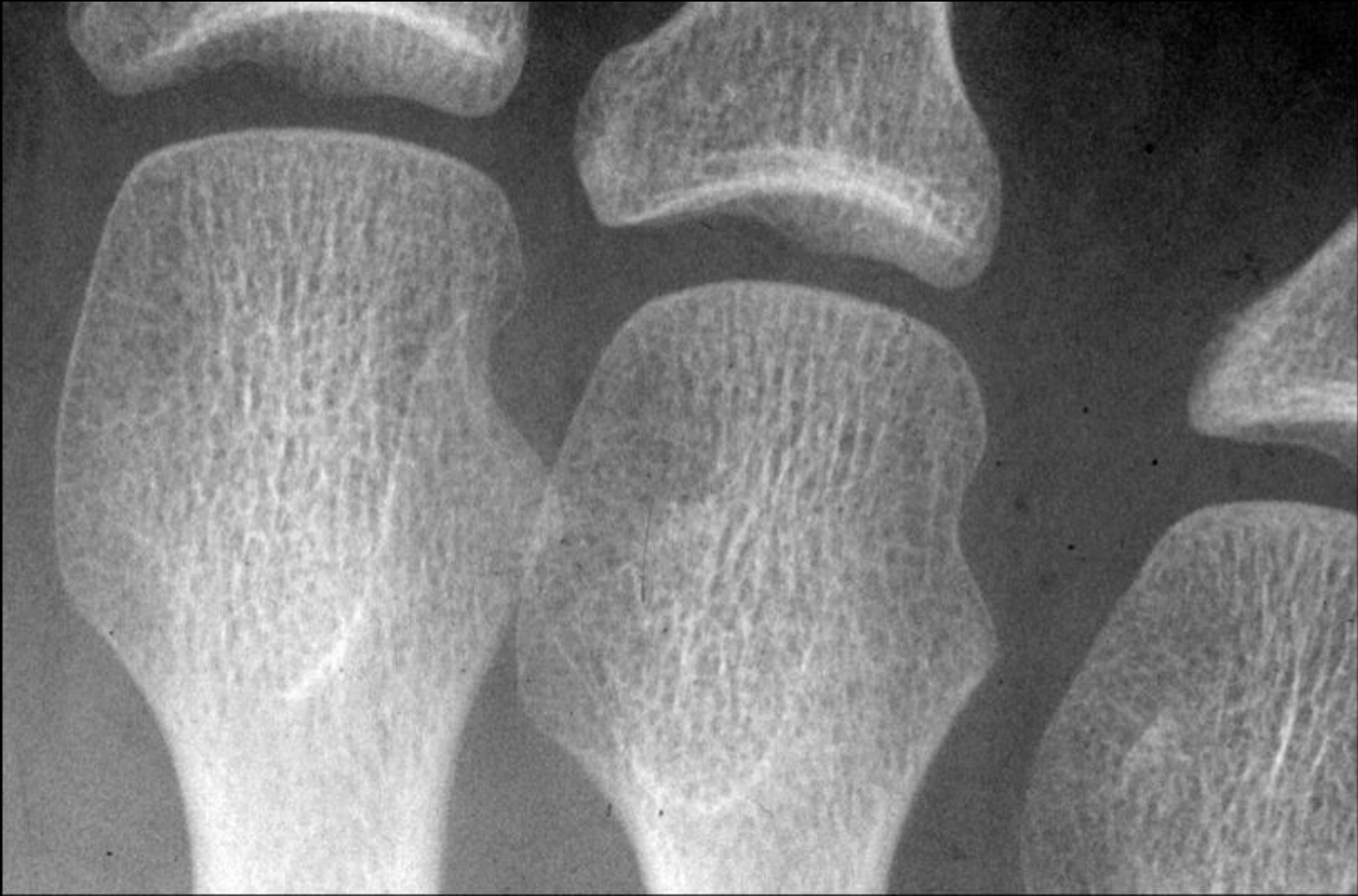

2.

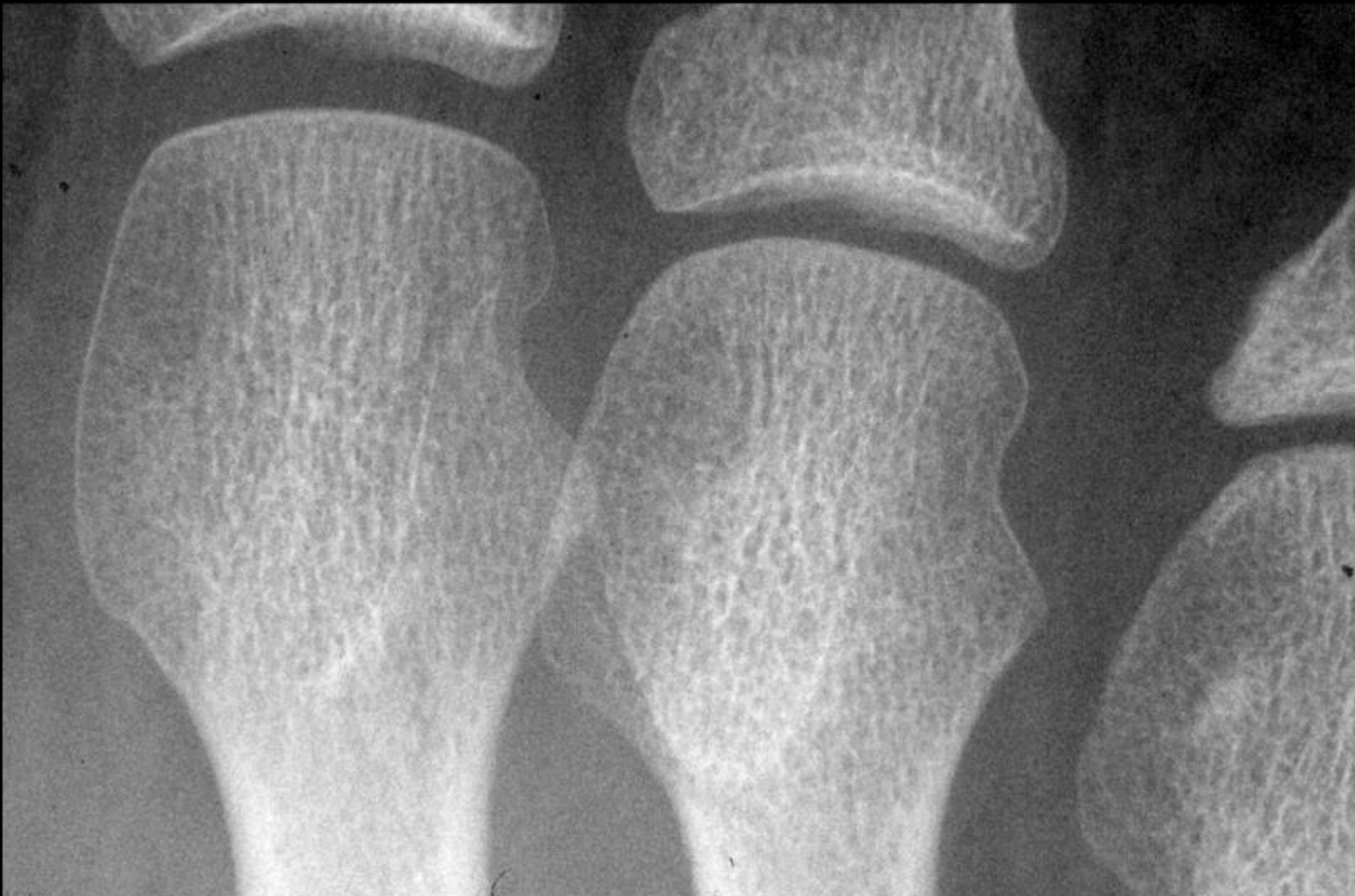

phénomène du vide intra-articulaire

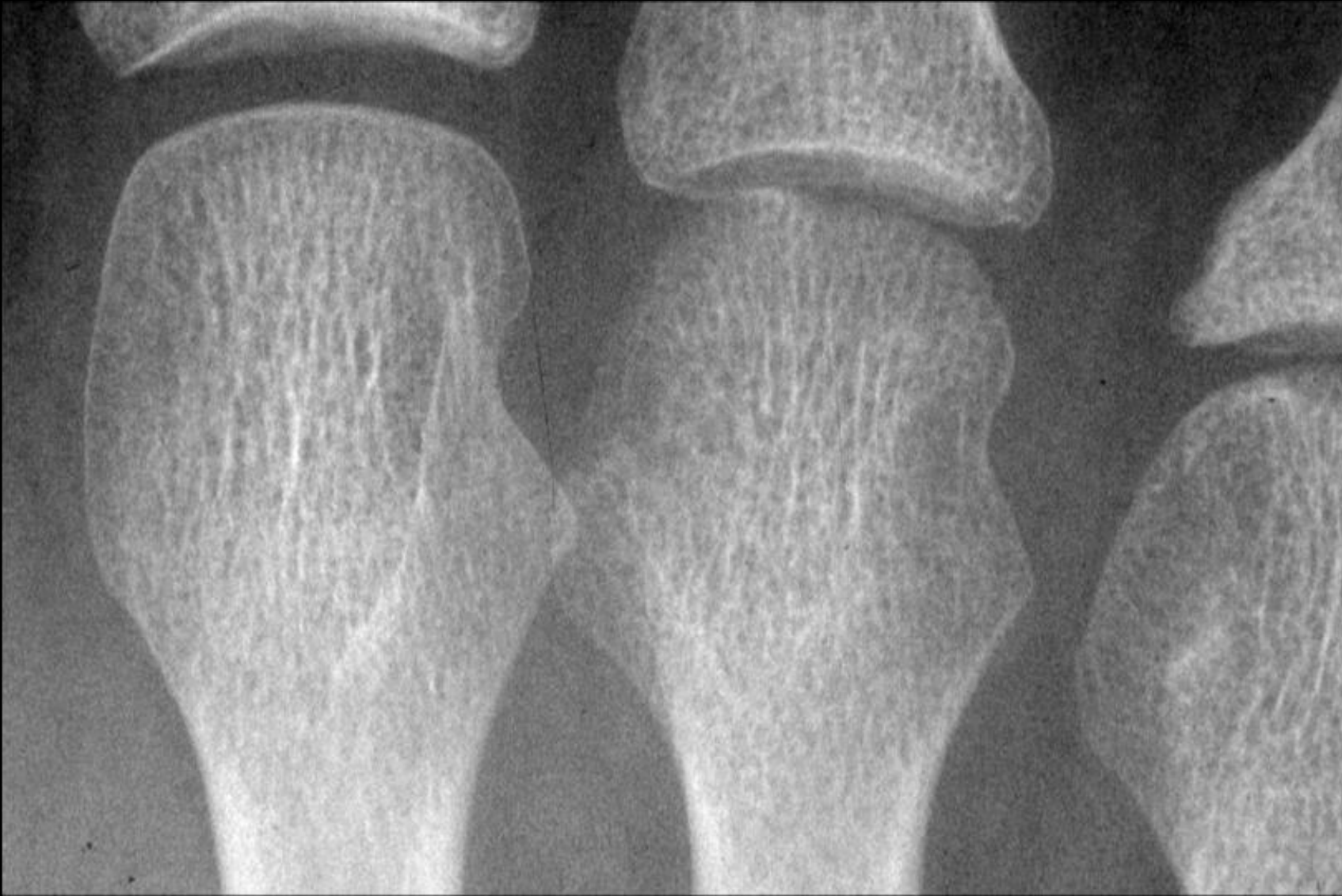visibilité indirecte du cartilage



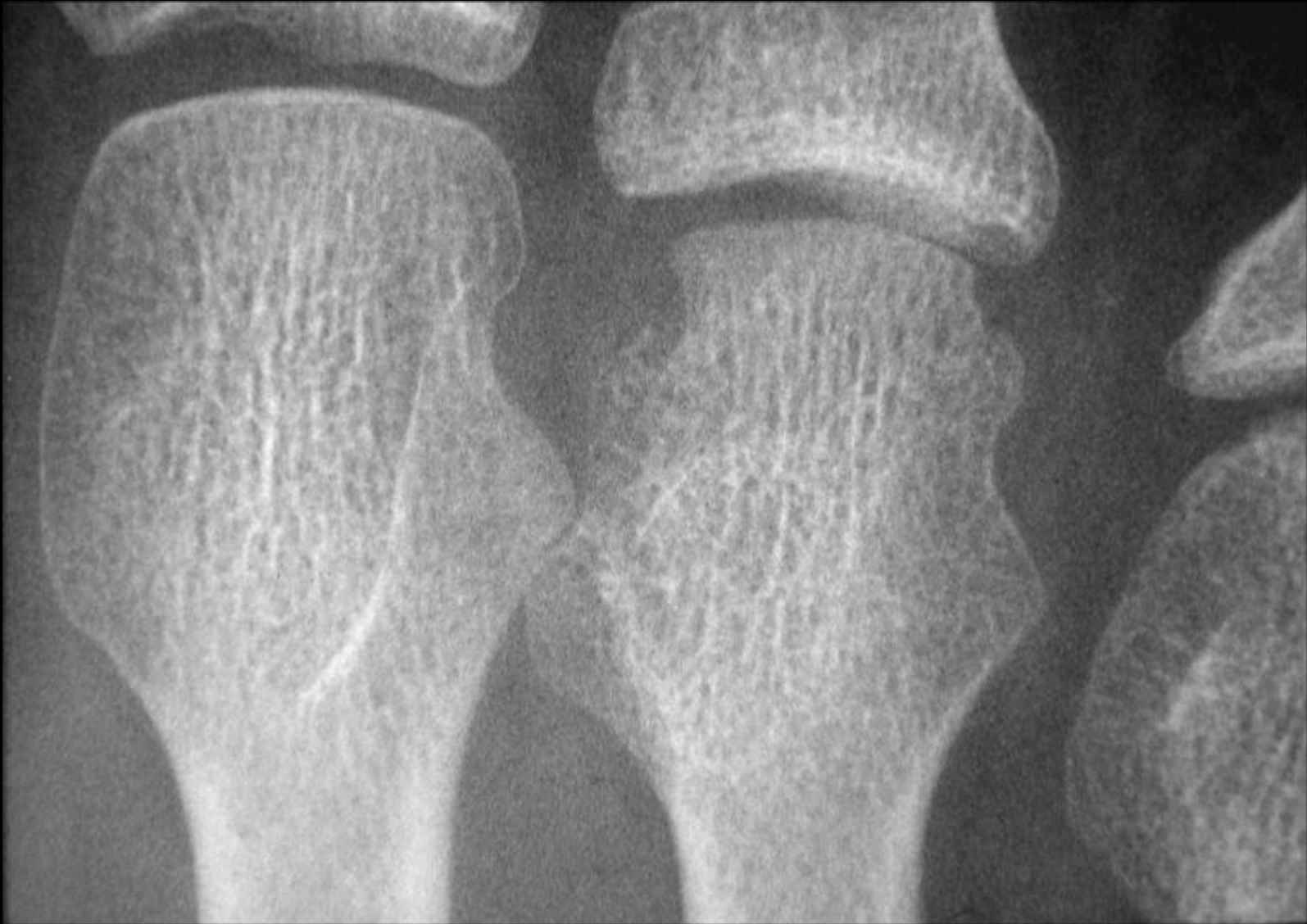Normal?



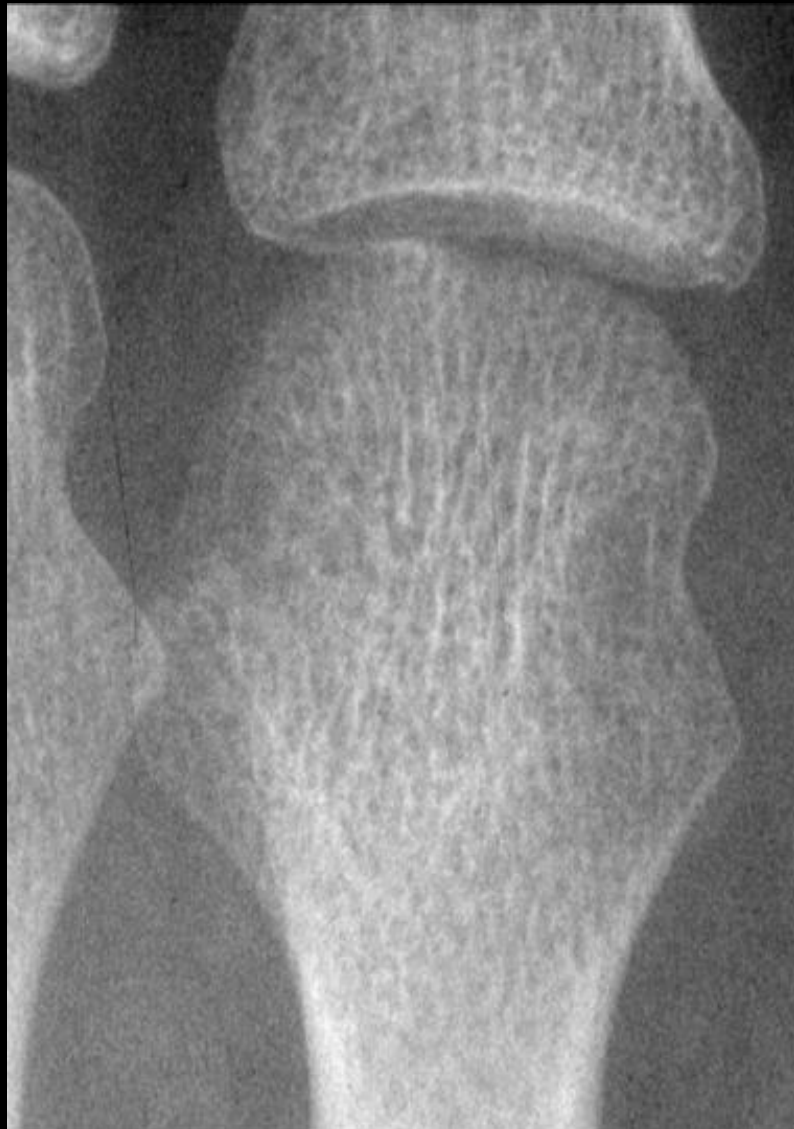6 mois plus tard... Toujours normal?



6 mois plus tard...

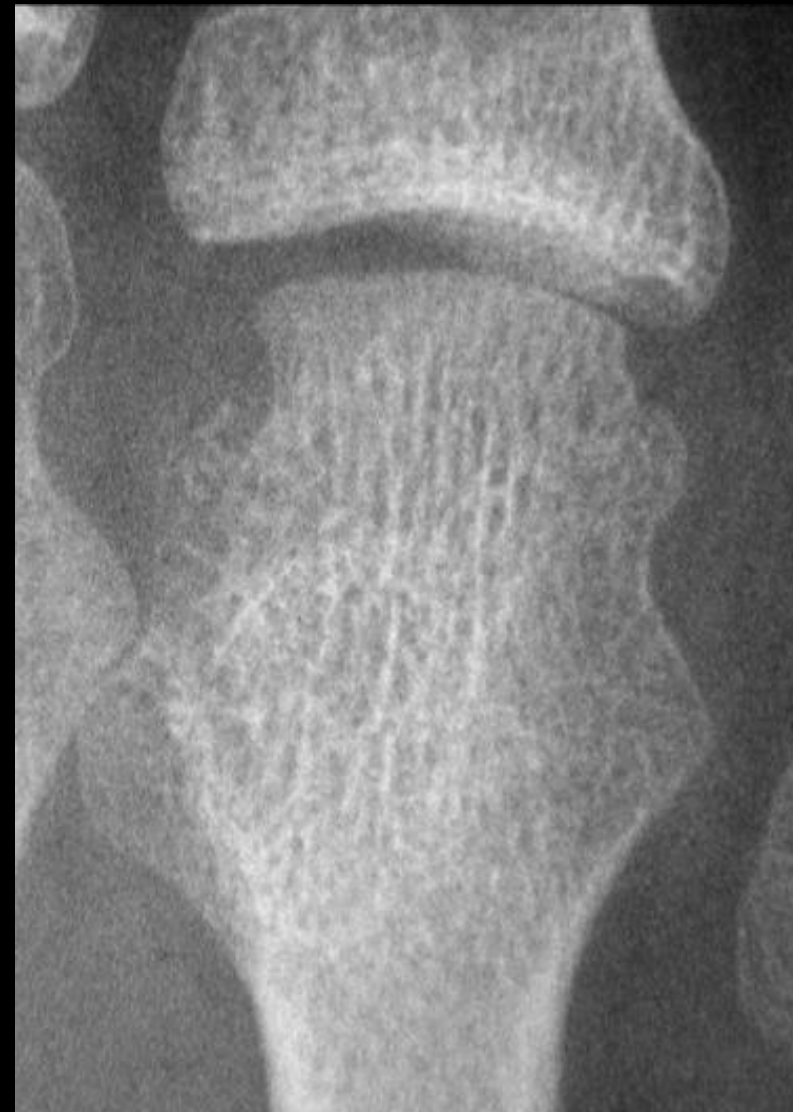

6 mois plus tard...



Pré-érosif

+ 6 mois

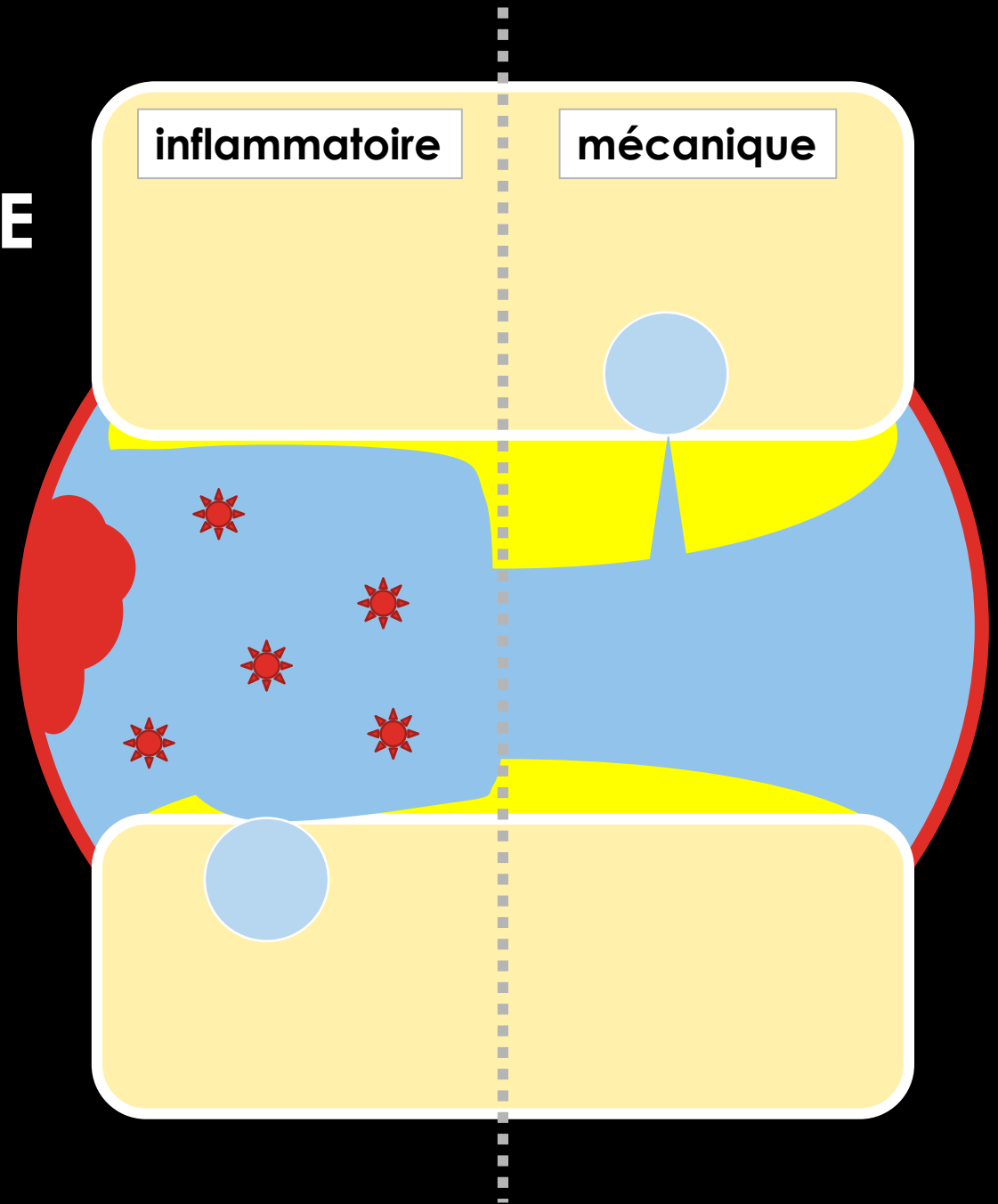


Erosif



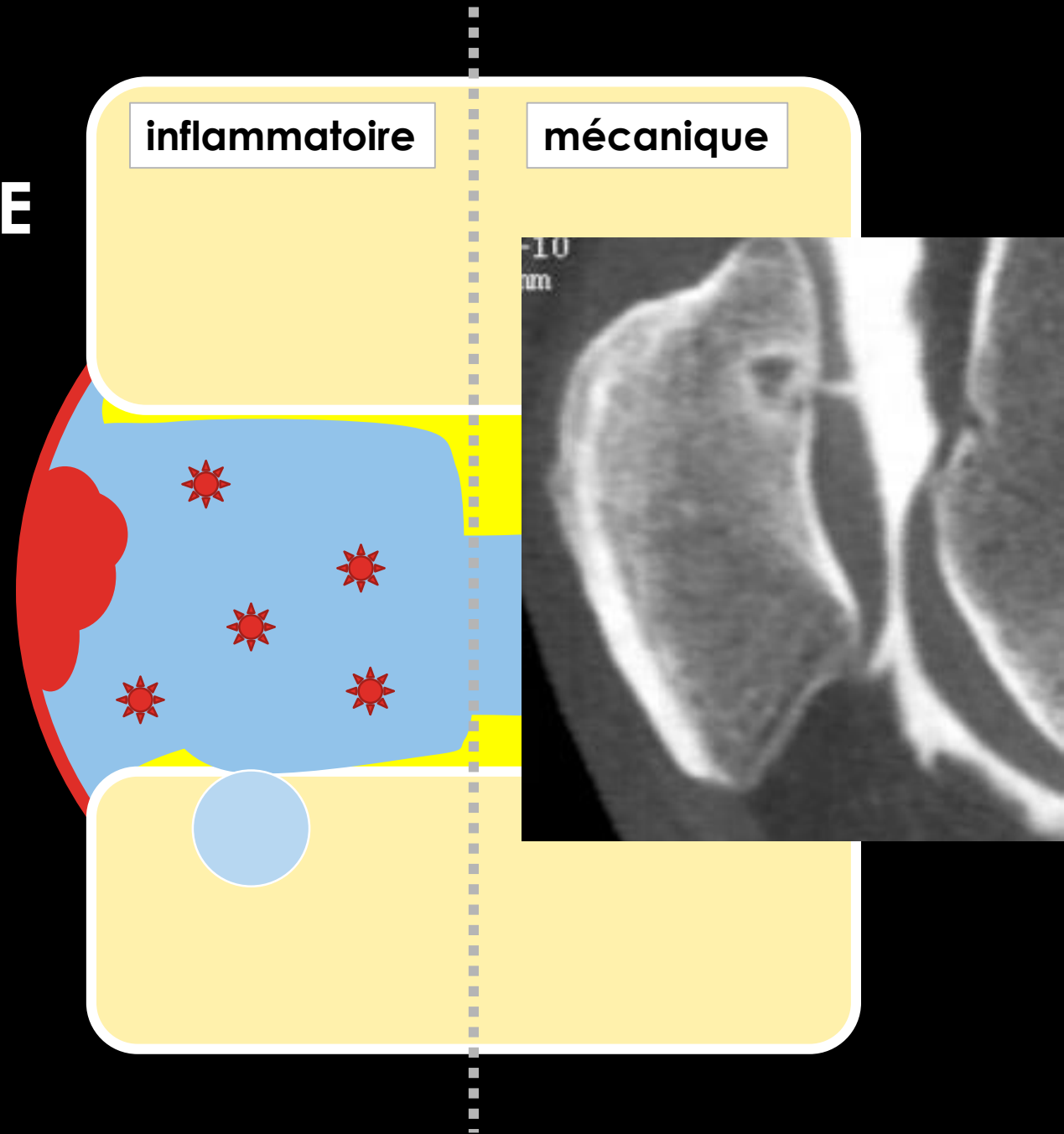
# EROSION SOUS-CHONDRALE

- Zone de contact, d'hyperpression
- Pathologie du cartilage qu'elle soit mécanique ou inflammatoire....
- Non spécifique



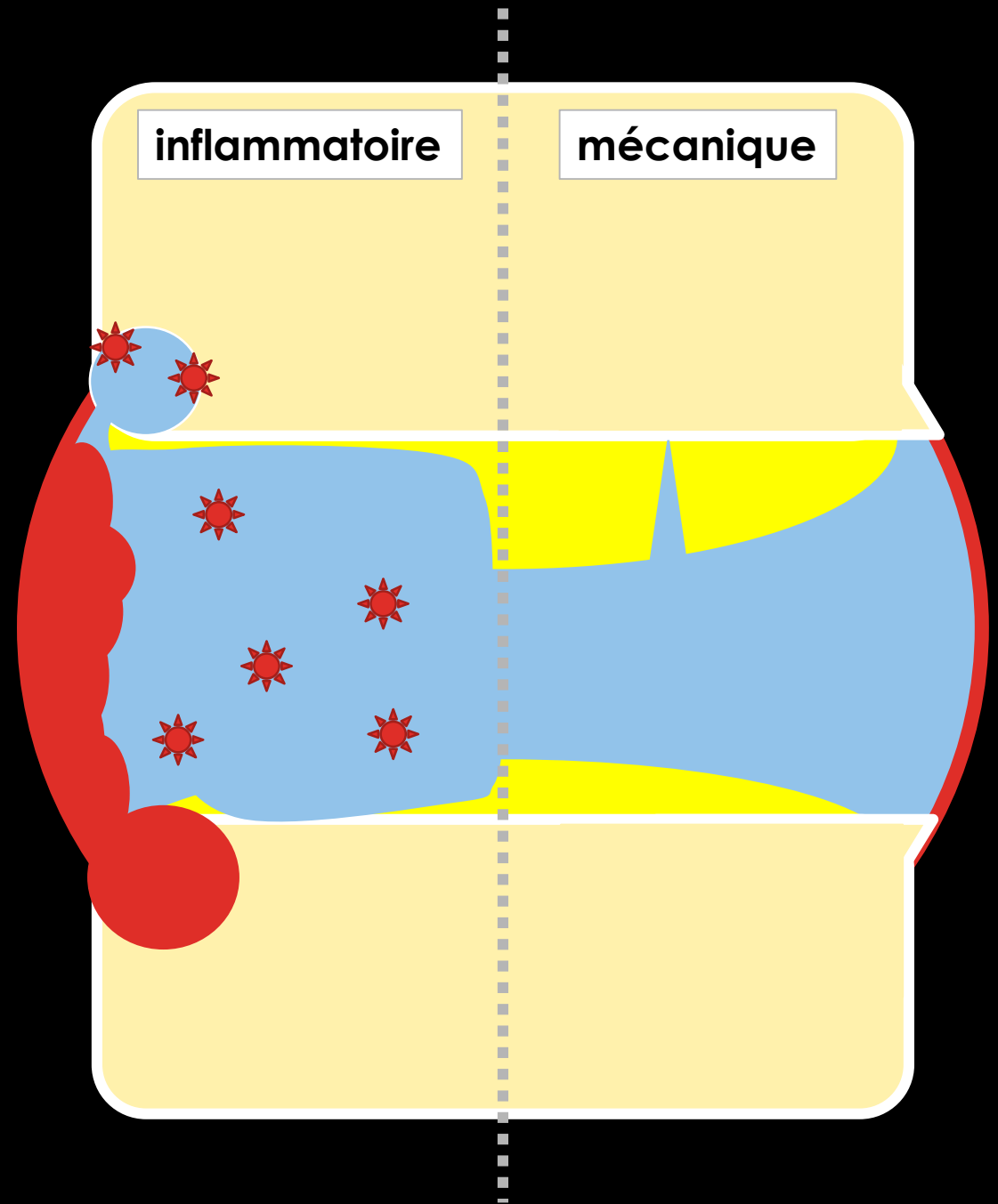
# EROSION SOUS-CHONDRALE

- Zone de contact, d'hyperpression
- Pathologie du cartilage qu'elle soit mécanique ou inflammatoire....
- Non spécifique



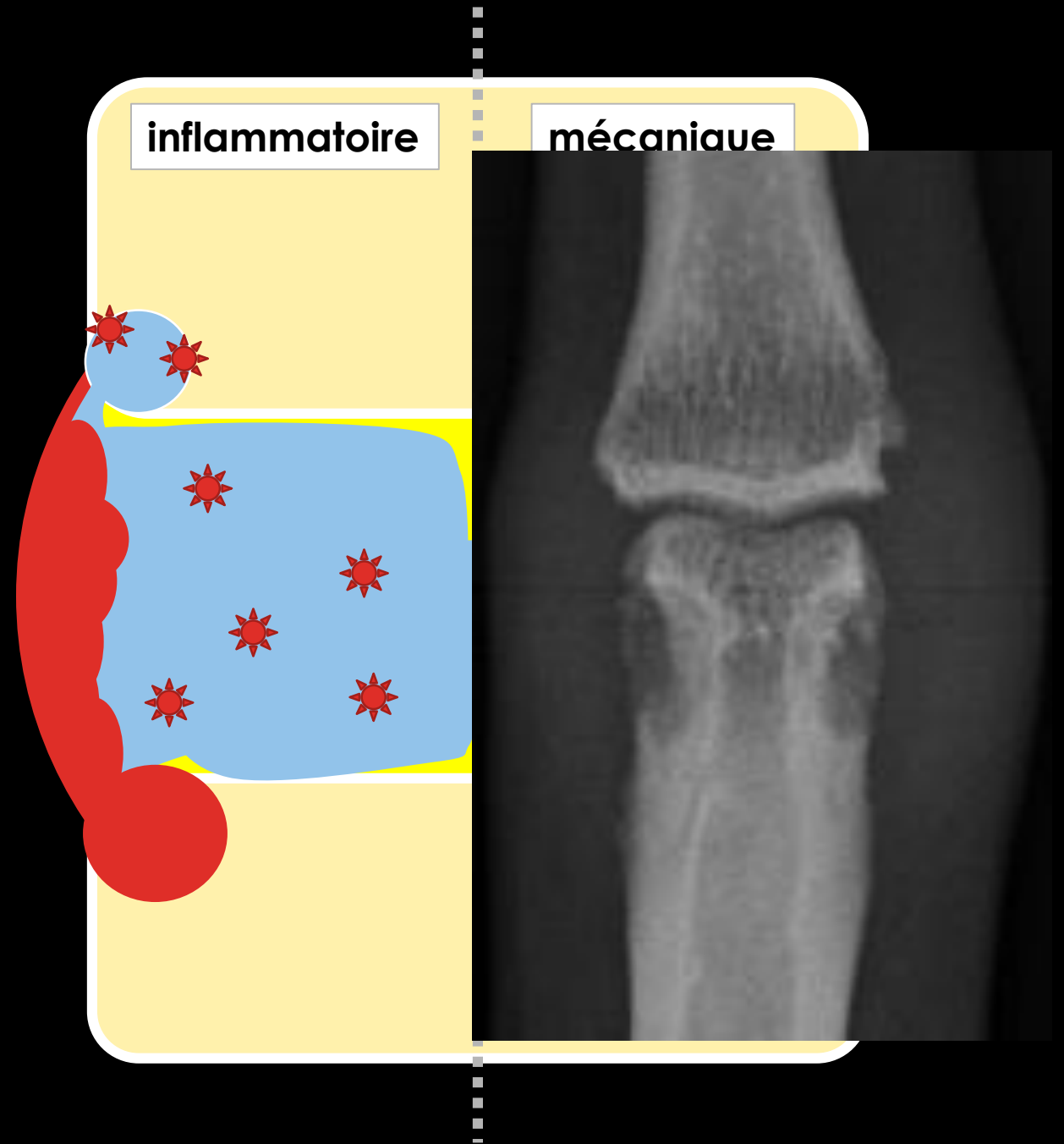
# EROSION MARGINALE

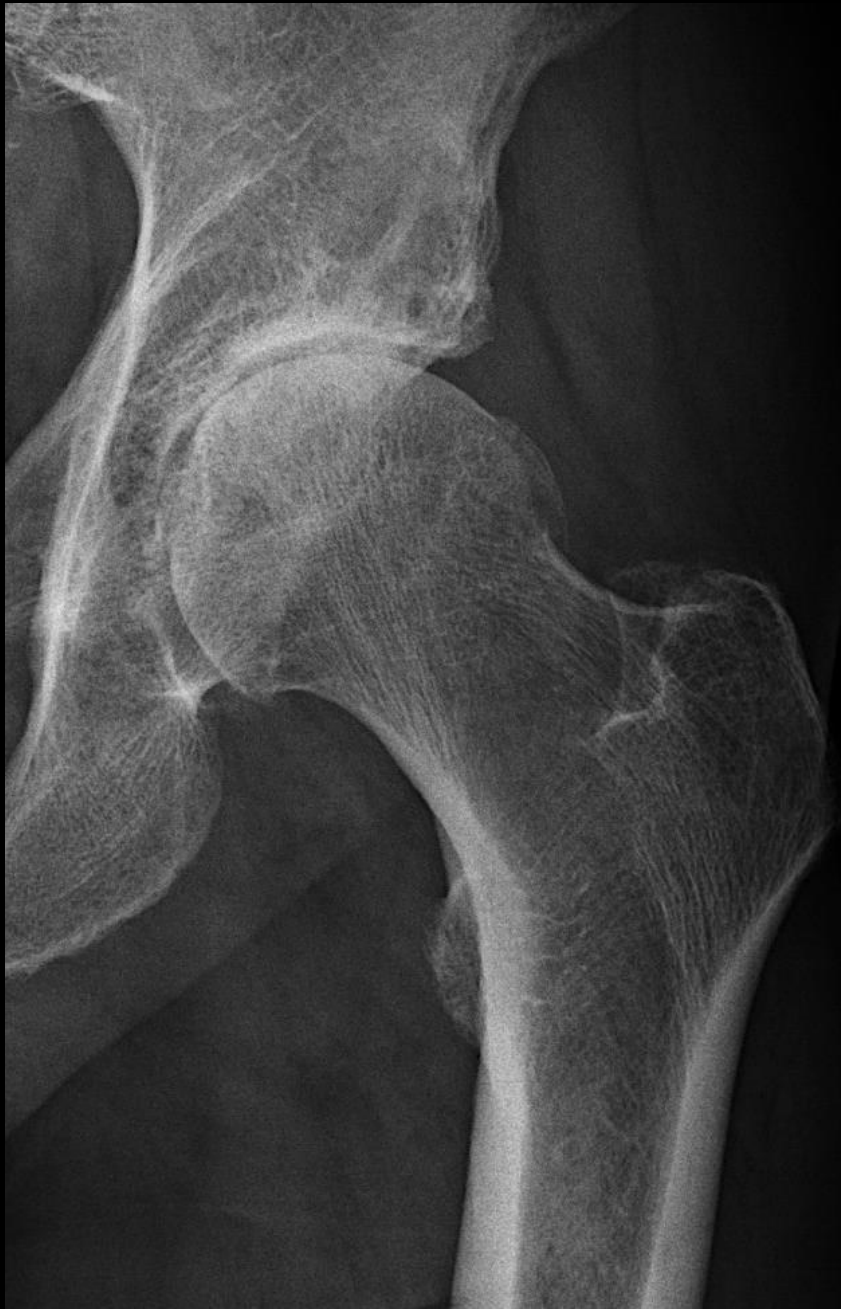- Pas de contact ni d'hyperpression
- Pathologie de la synoviale
- Localisée à l'os marginal non recouvert par le cartilage
- Spécifique (= non mécanique)



# EROSION MARGINALE

- Pas de contact ni d'hyperpression
- Pathologie de la synoviale
- Localisée à l'os marginal non recouvert par le cartilage
- Spécifique (= non mécanique)





Erosions

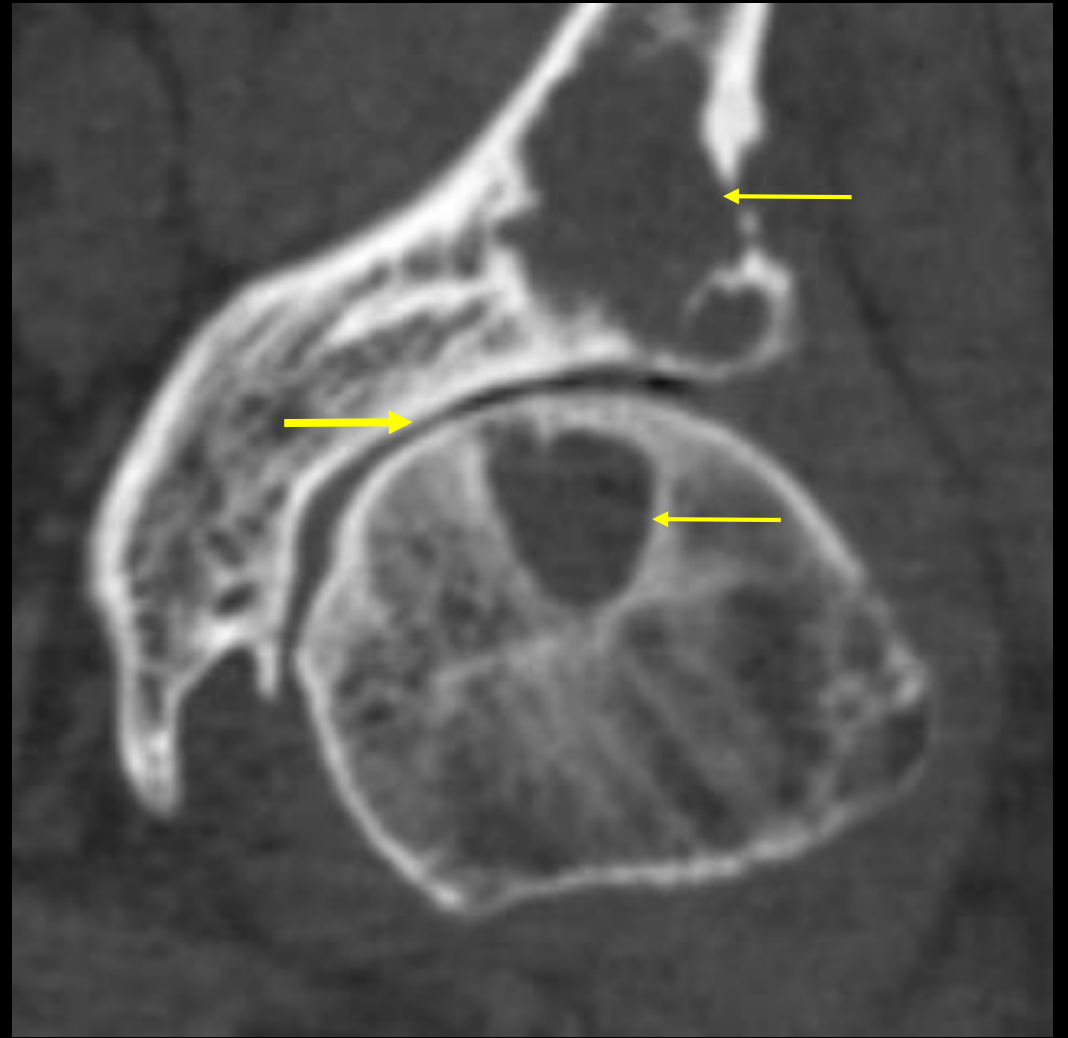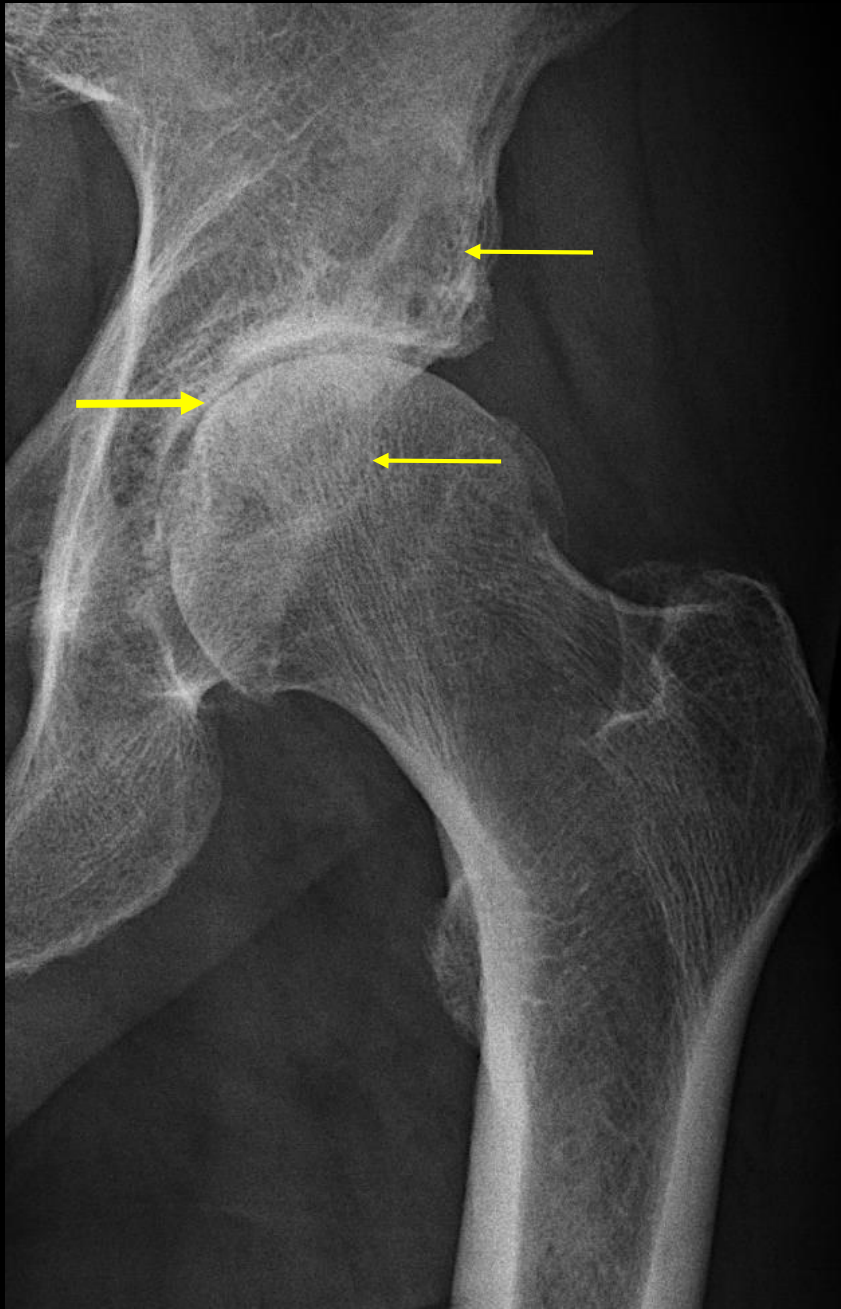
A – marginale?

B – sous-chondrale?

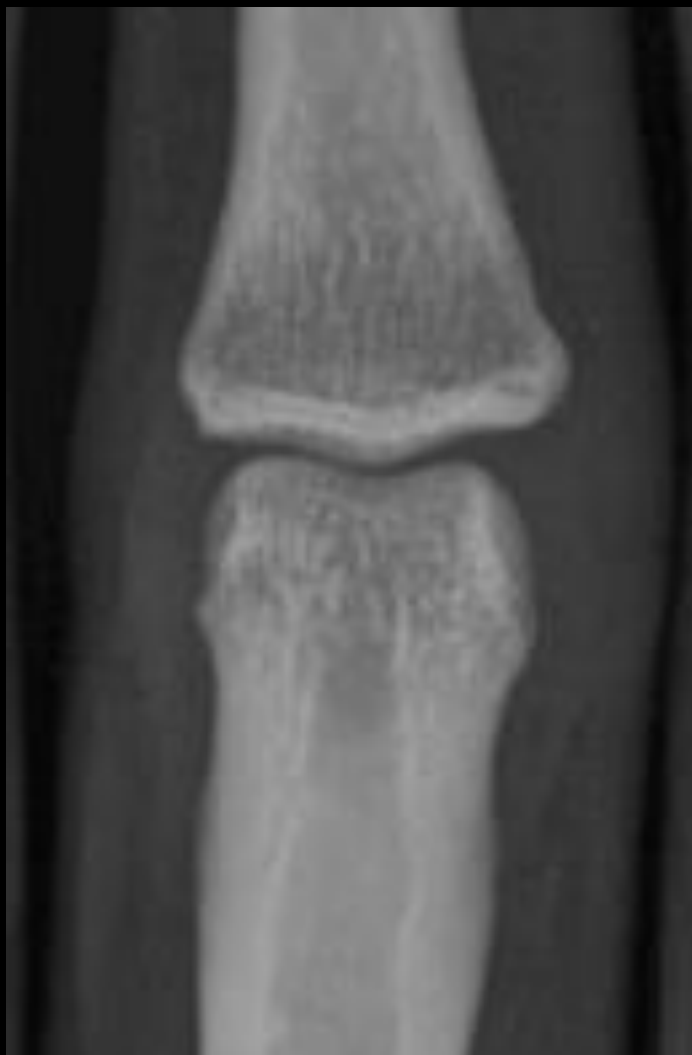Pincement

A – focal?

B – global?



Pincement focal  
Géodes sous-chondrales  
→ Coxarthrose



PR débutante < 1 an

A – tuméfaction?

B – érosion?

C – chondrolyse?

D – normal?



PR débutante < 1 an

A – tuméfaction?

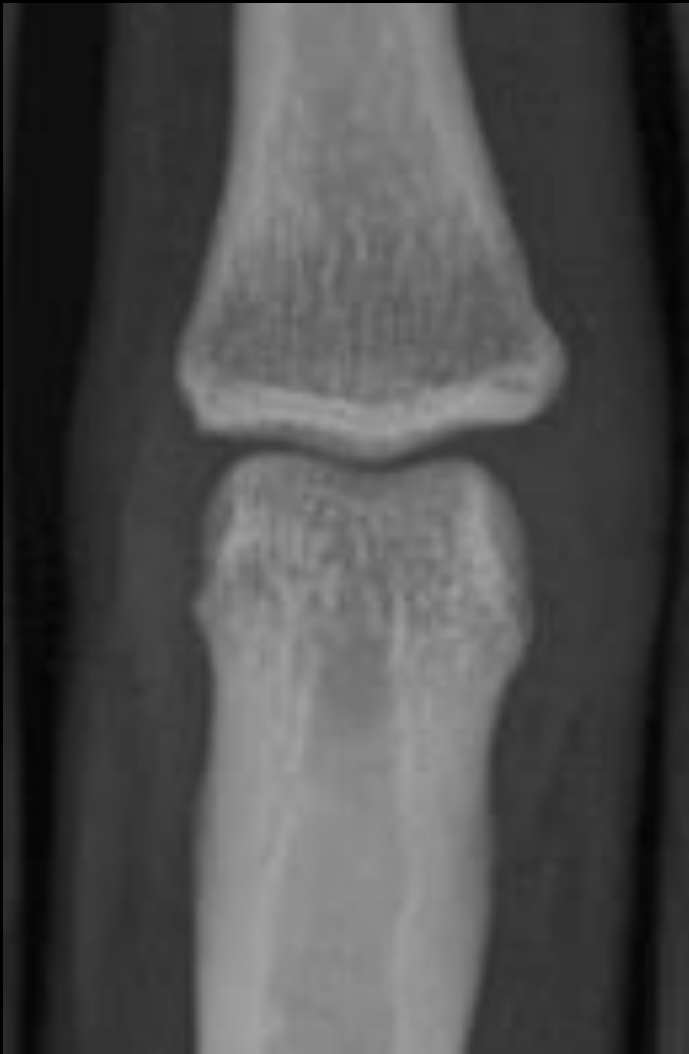B – érosion?

C – chondrolyse?

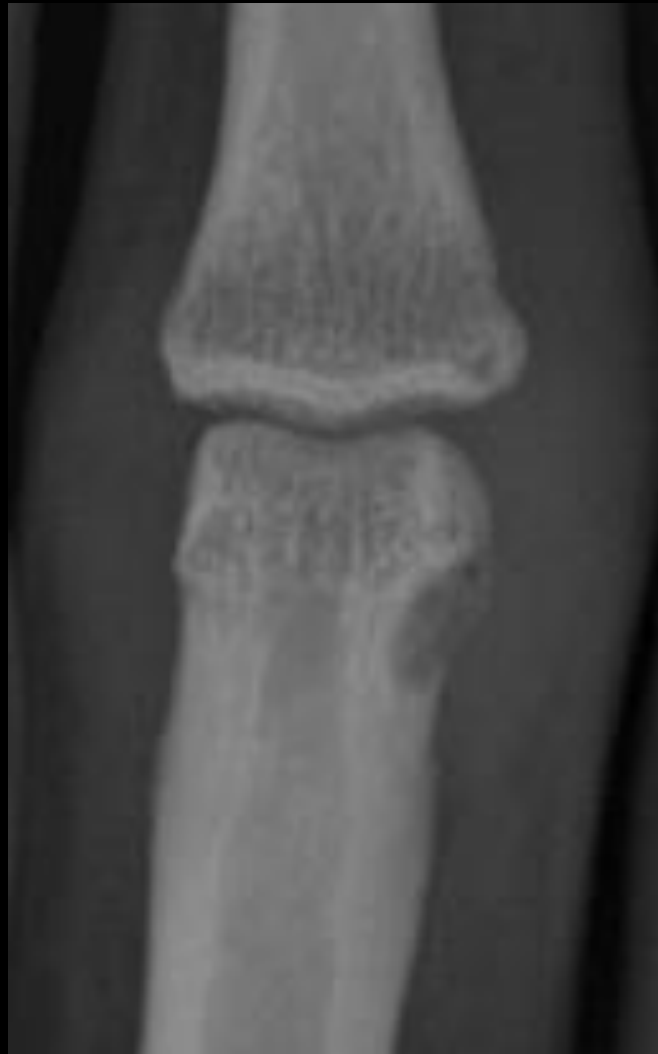D – **normal**

Y0





Y0



Y1

PR débutante < 1 an

A – tuméfaction?

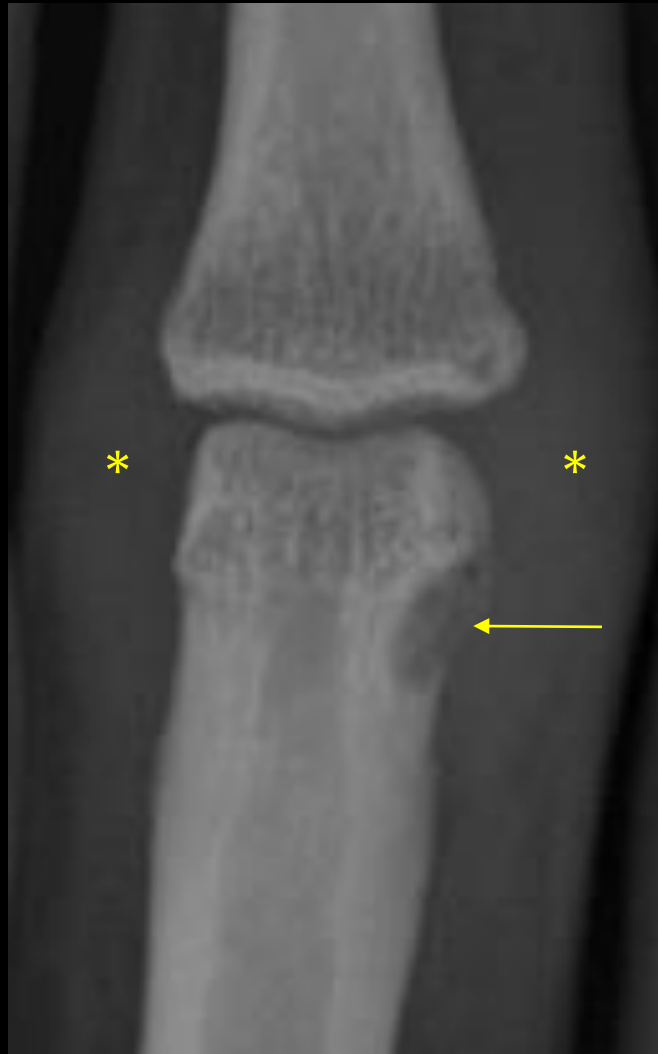B – érosion?

C – chondrolyse?

D – normal?



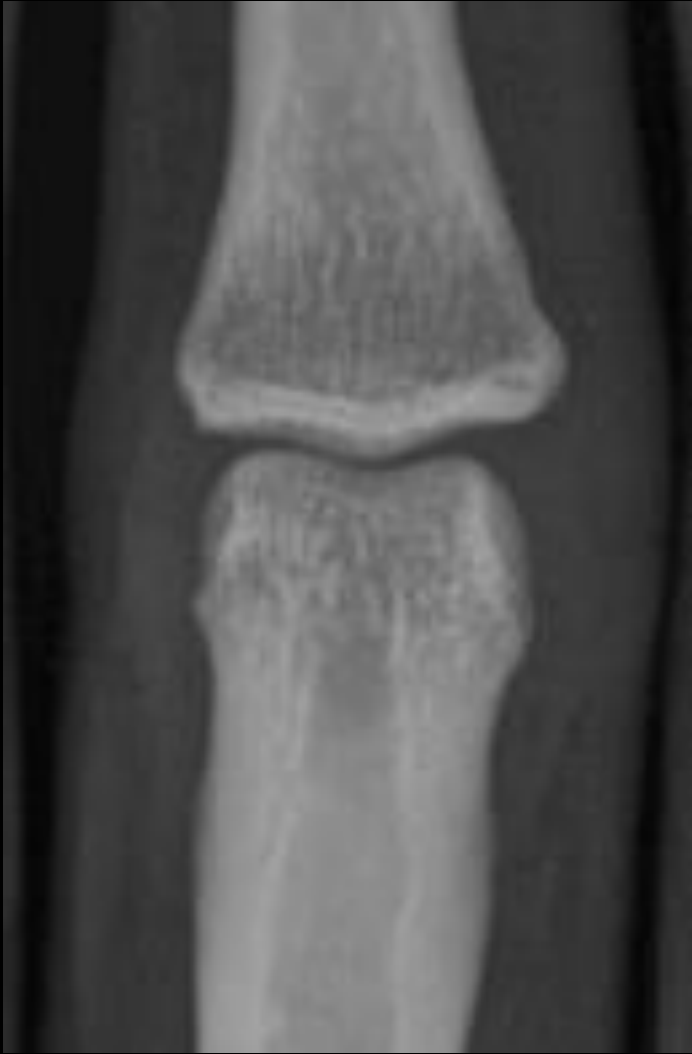Y0



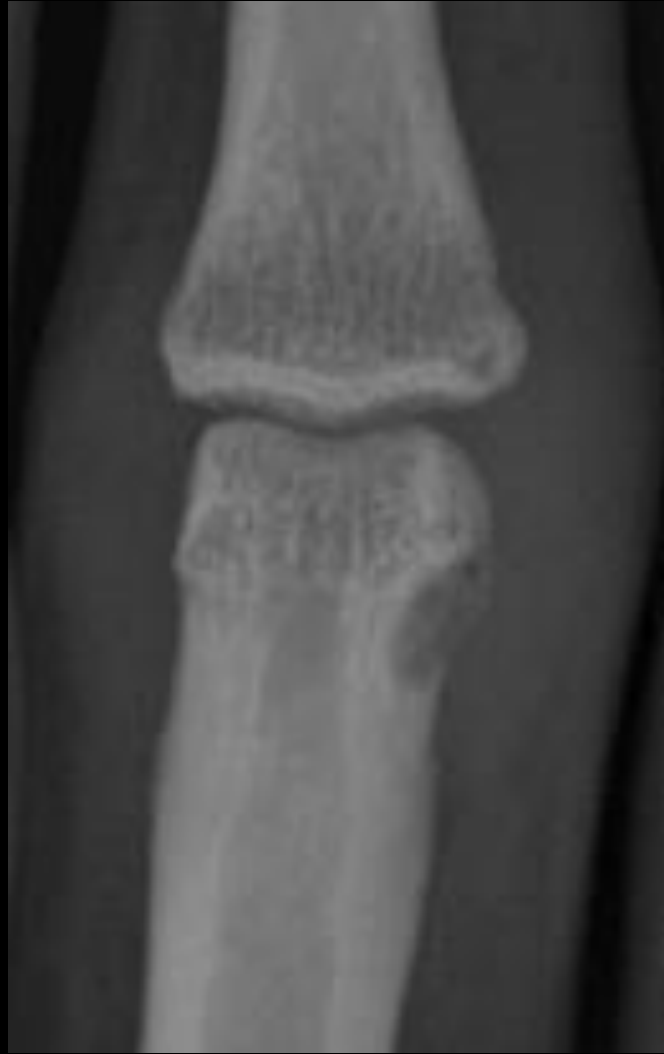Y1

PR débutante < 1 an

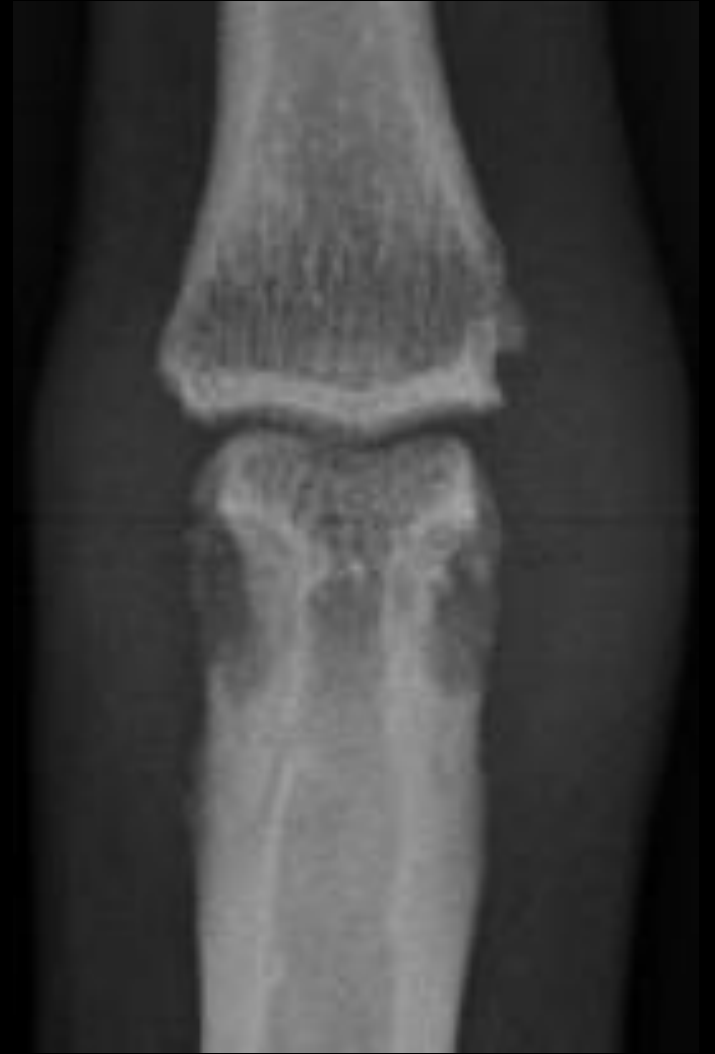- A – tuméfaction
- B – érosion marginale
- C – chondrolyse?
- D – normal?



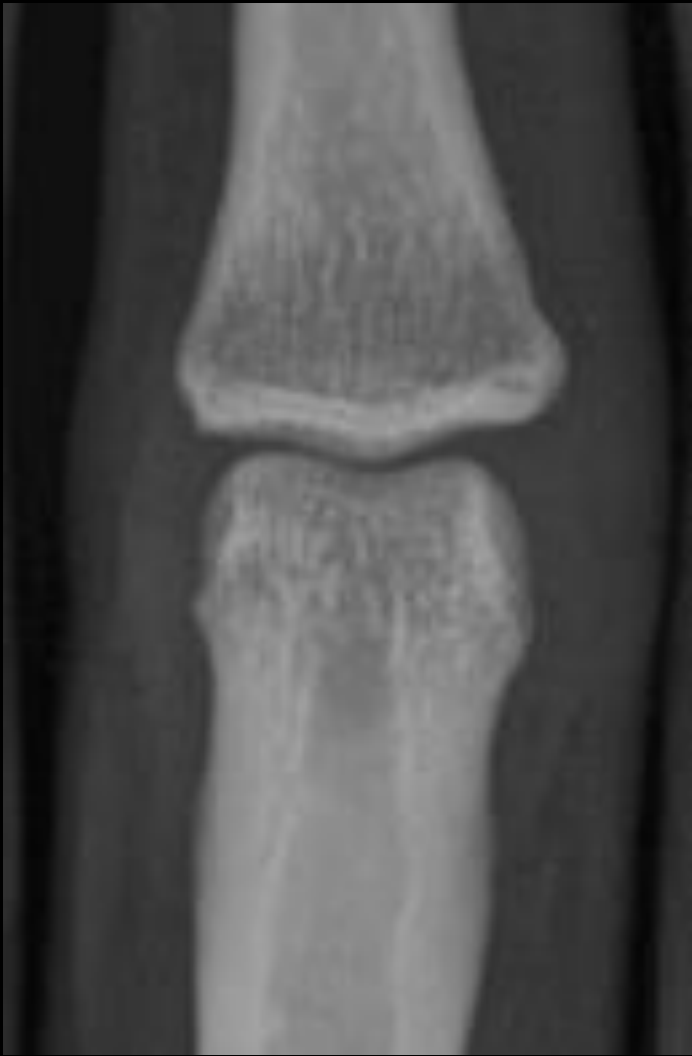Y0



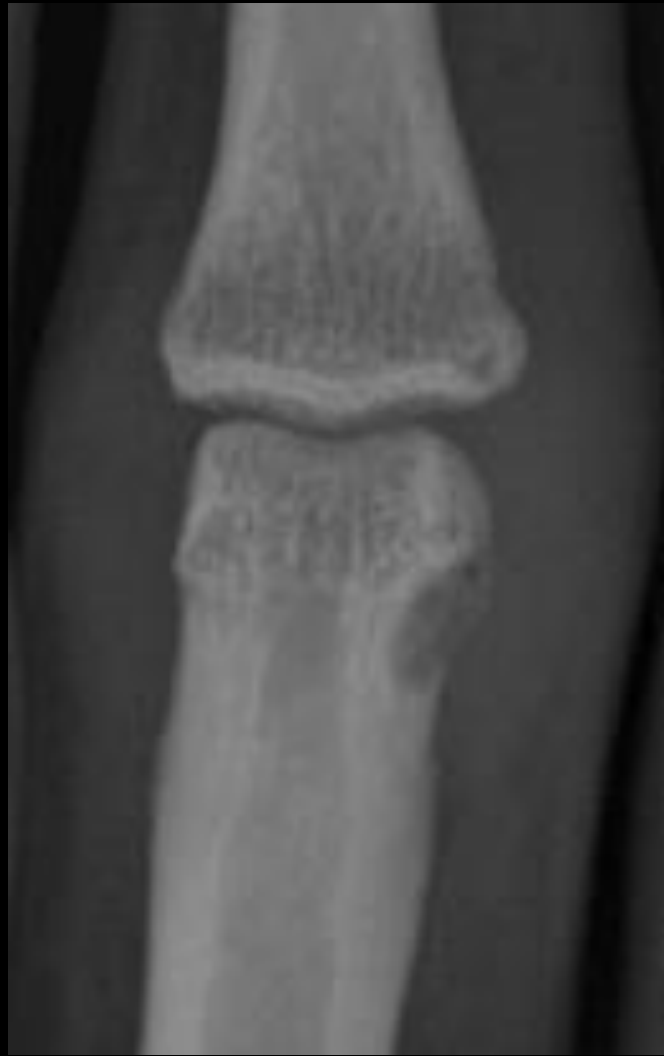Y1



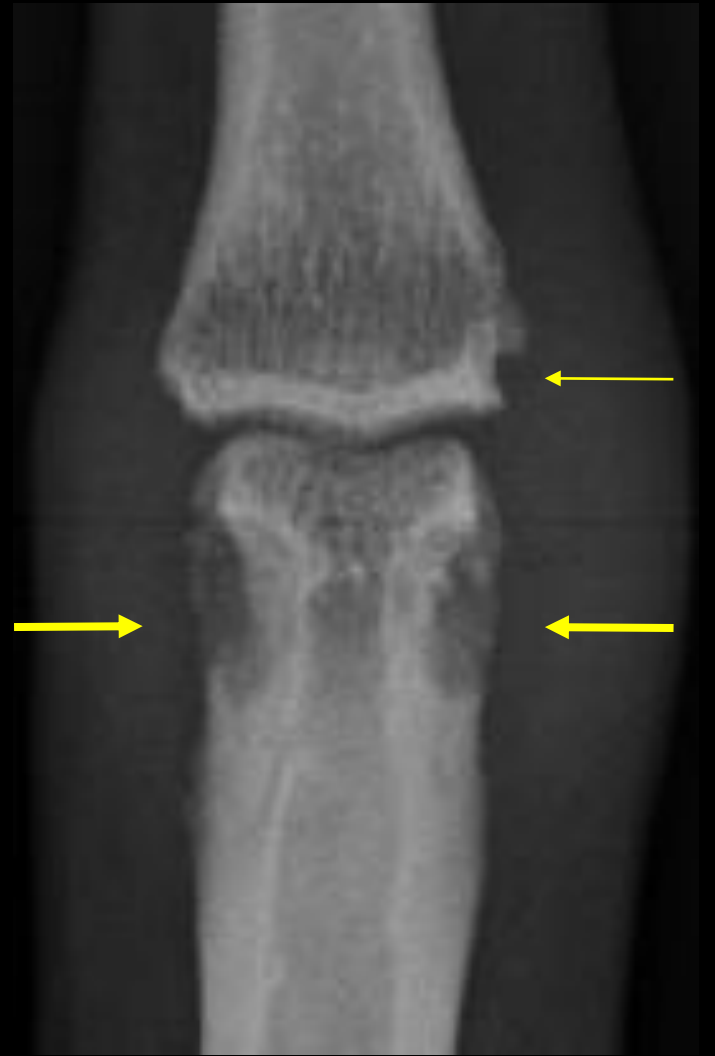Y2



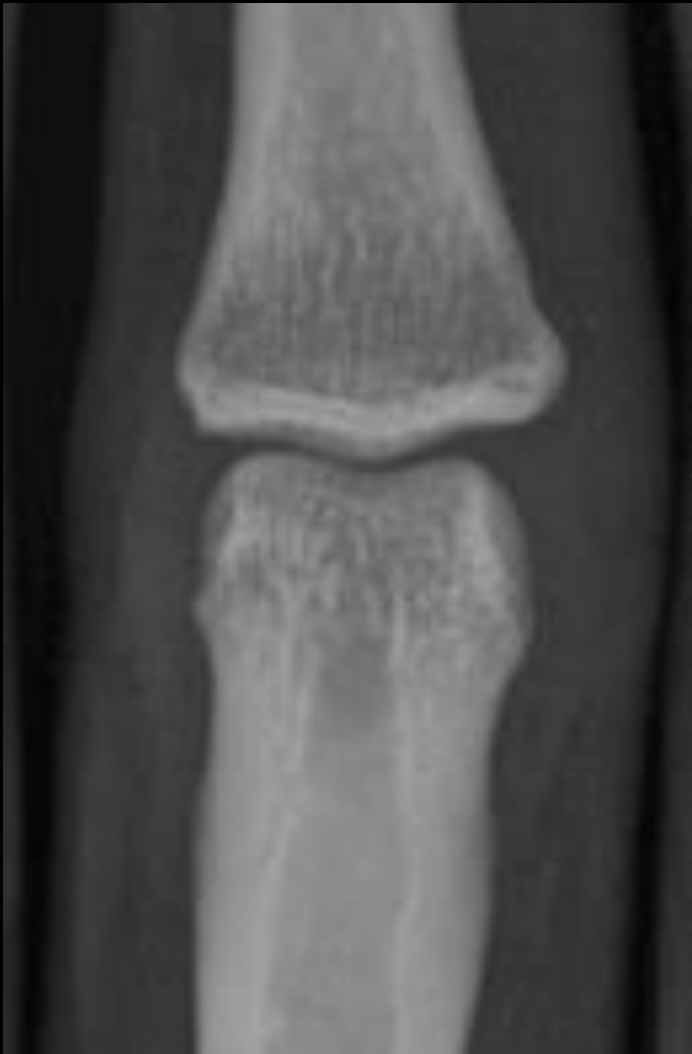Y0



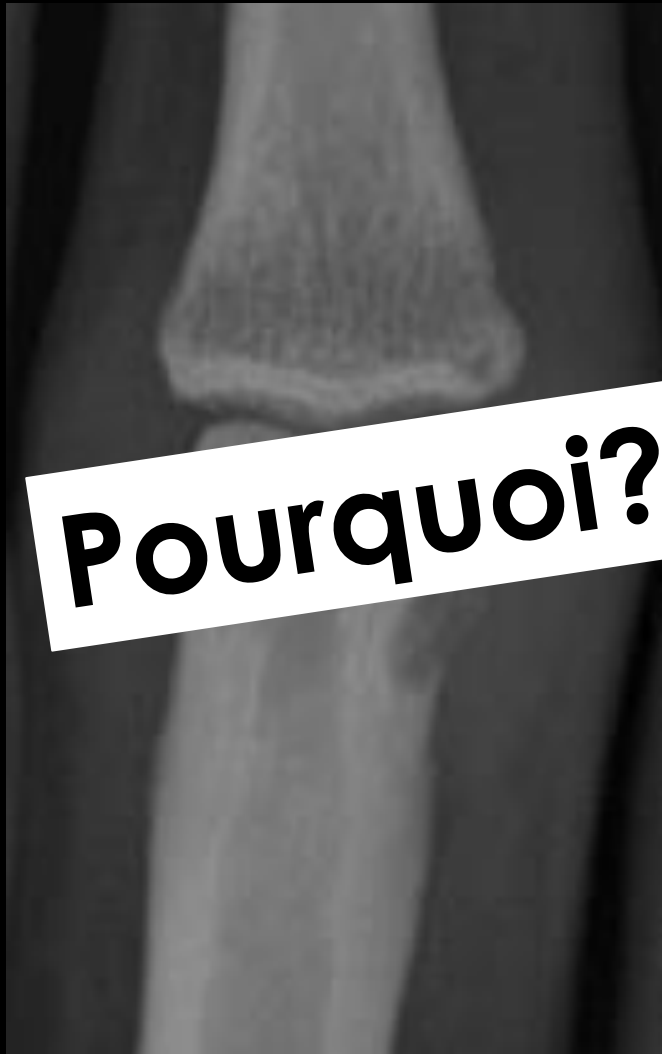Y1



Y2

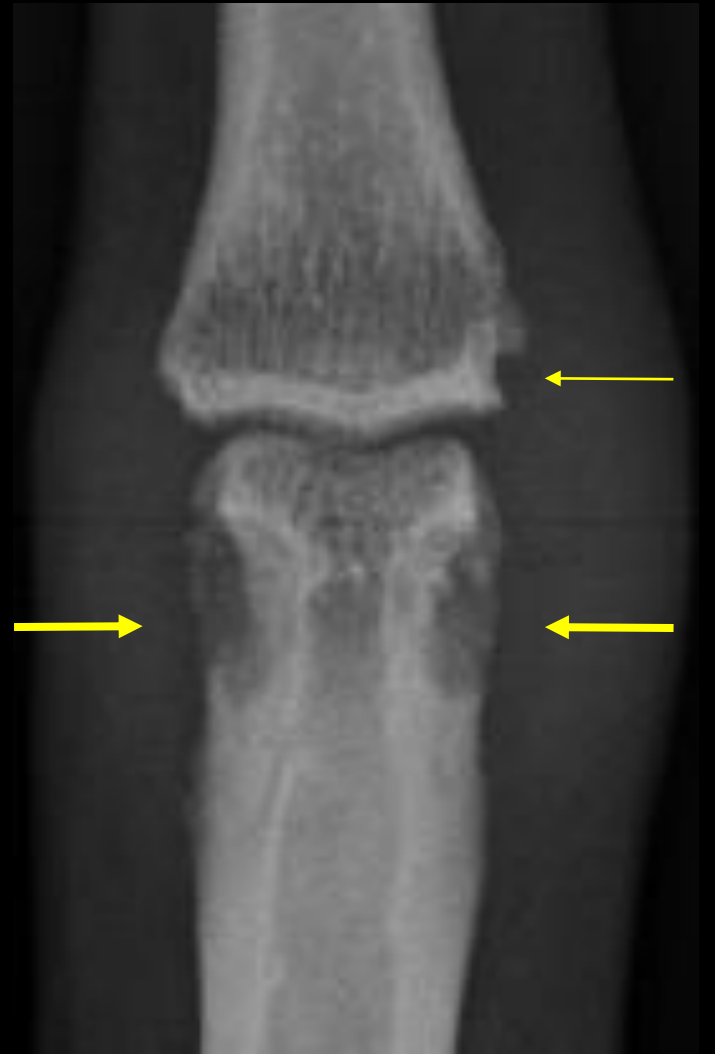

Y0

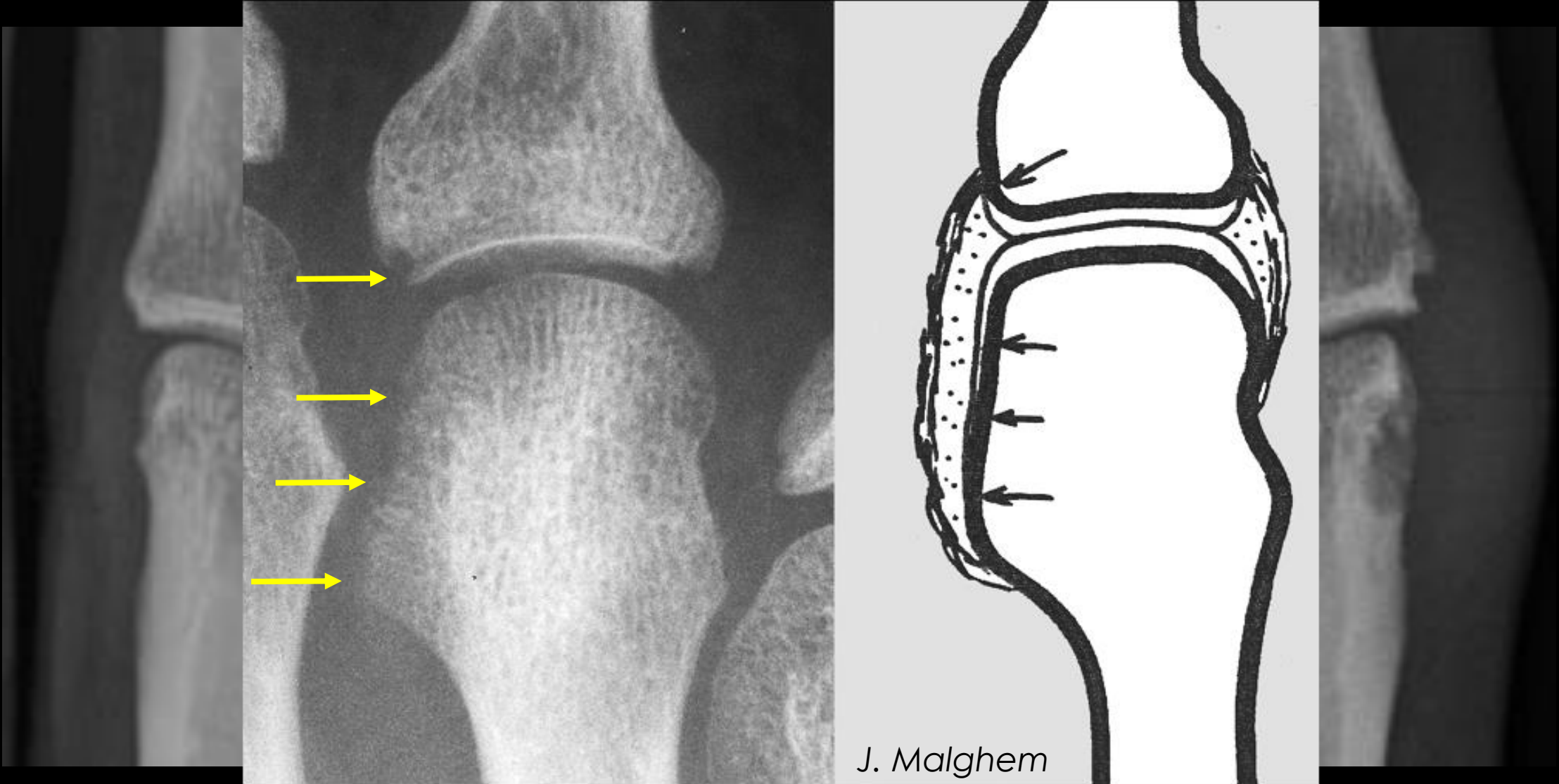


**Pourquoi?**

Y1



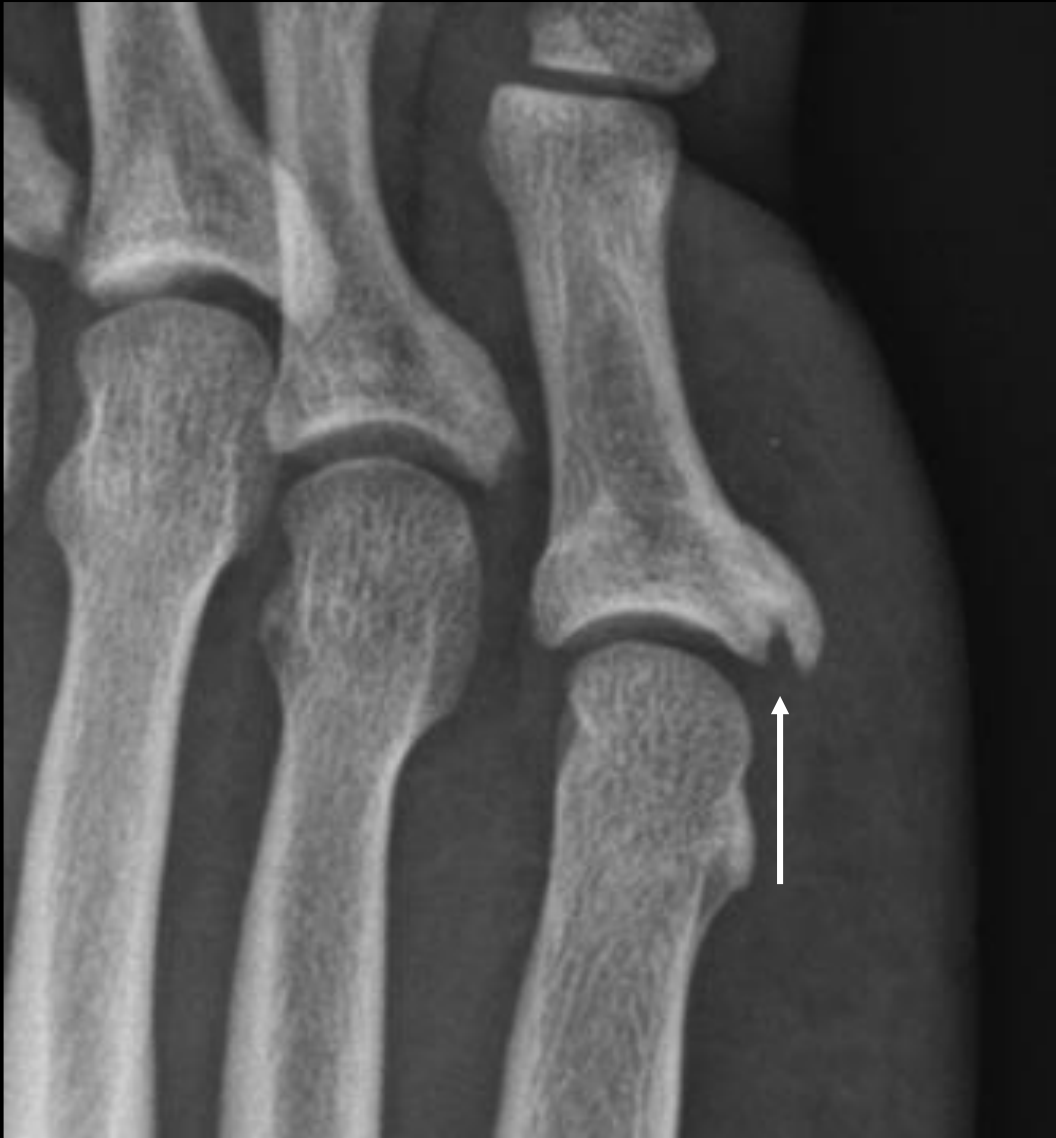Y2



Y0

Y1

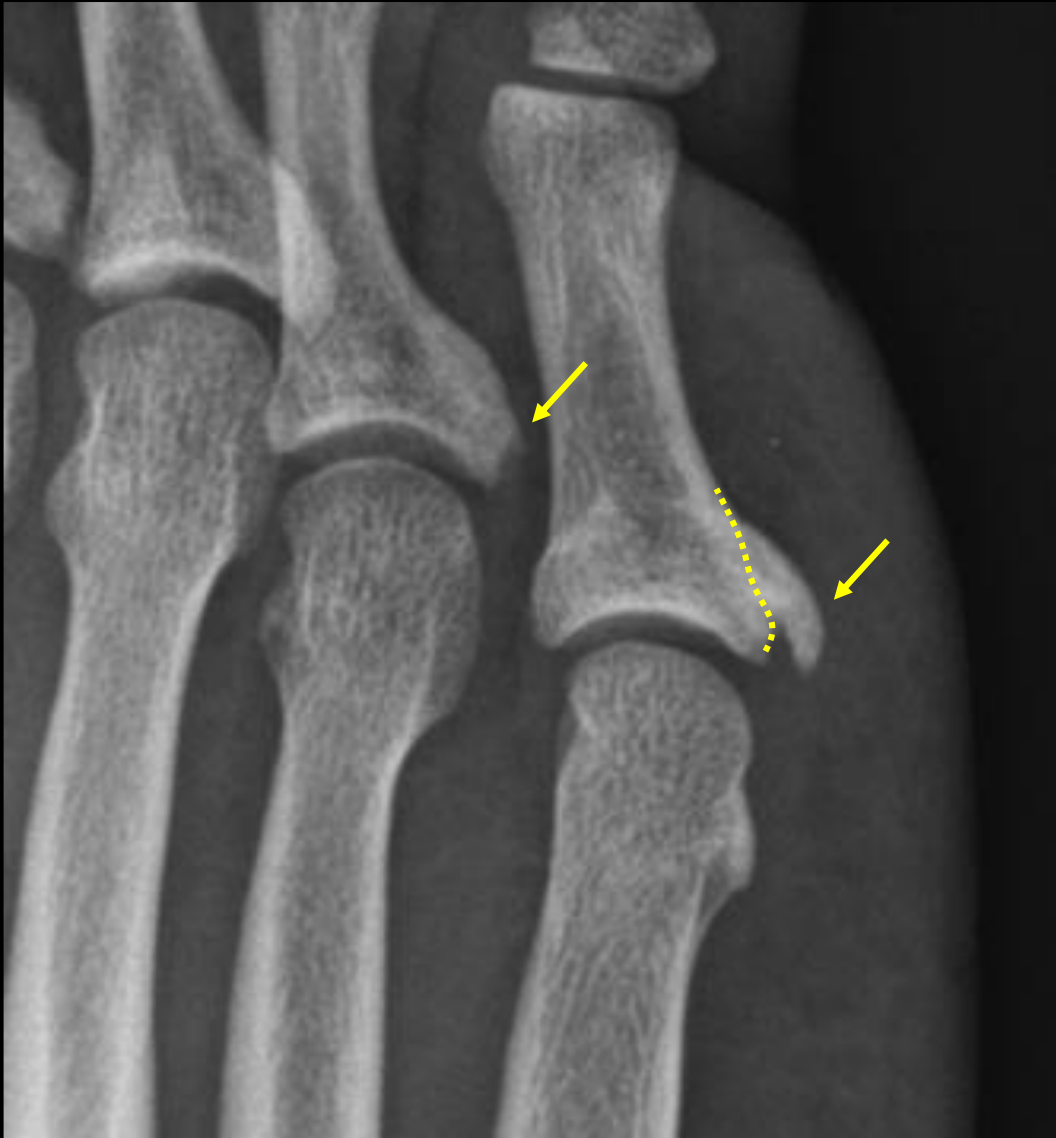Y2



Erosion marginale?

A – Oui

B – Non



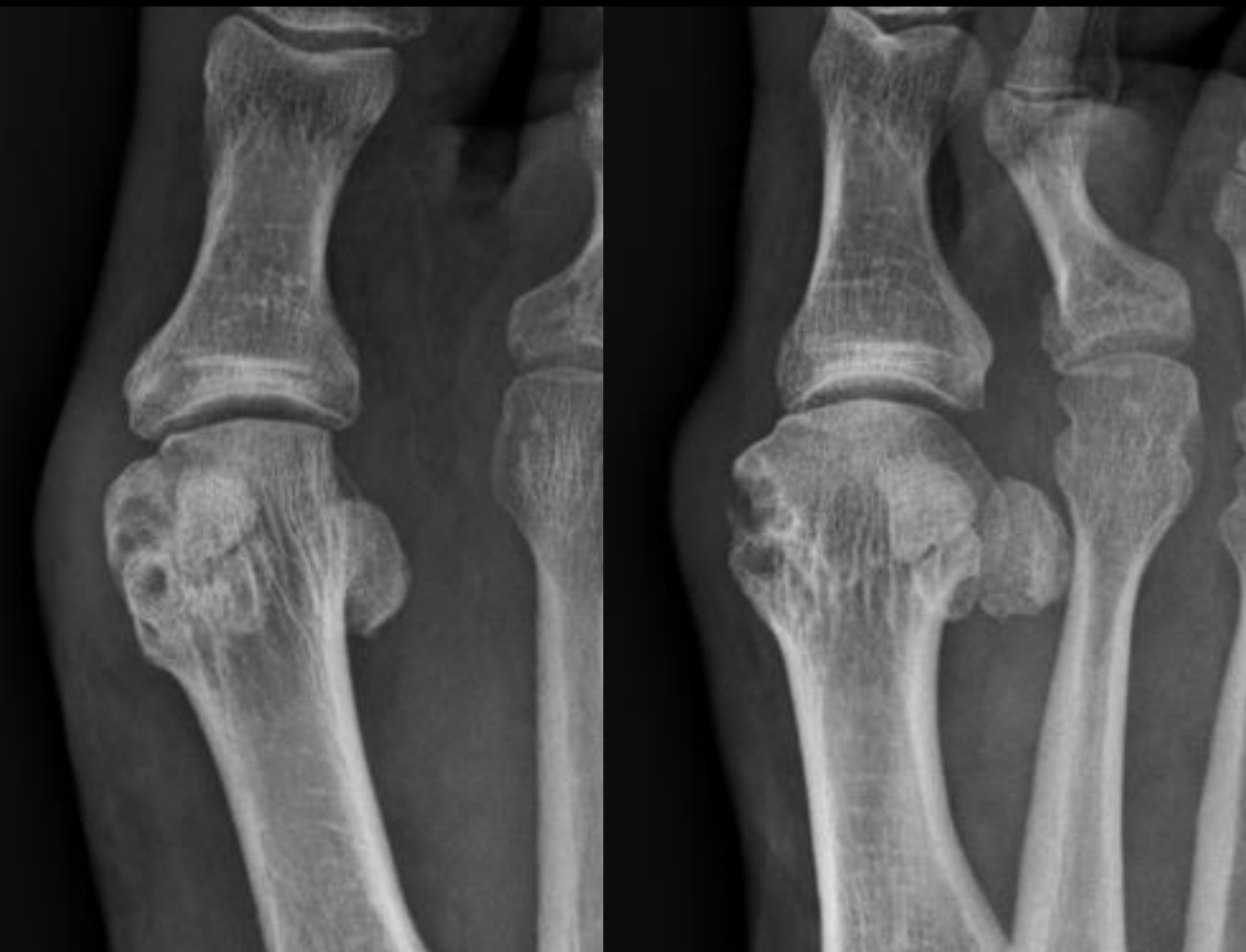Erosion marginale?

A – Oui

B – Non

*proliférations osseuses*





Tuméfaction des tissus mous?

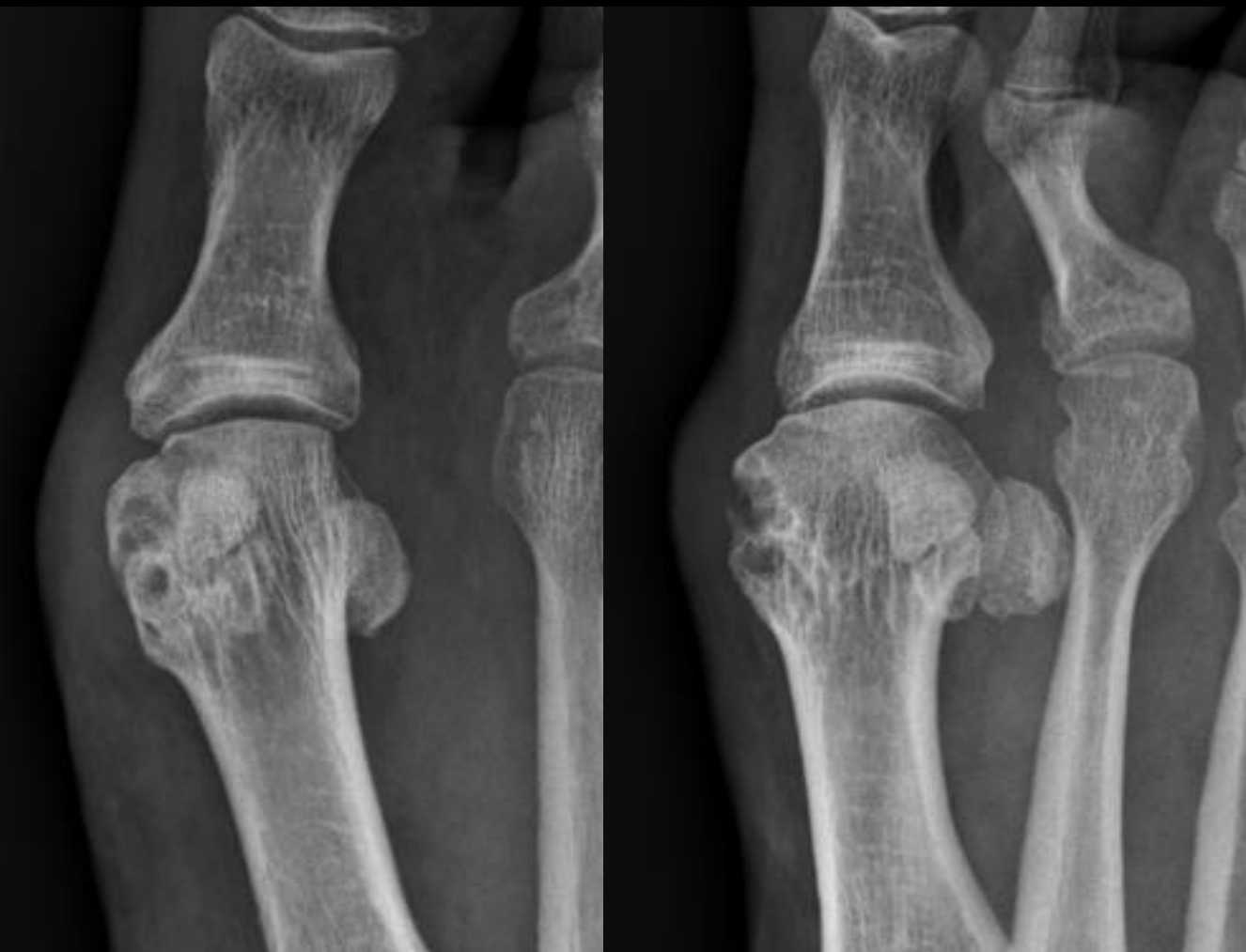A – Oui

B – Non

Topographie des érosions?

A – Marginale

B – Sous-chondrale



Tuméfaction des tissus mous?

A – Oui

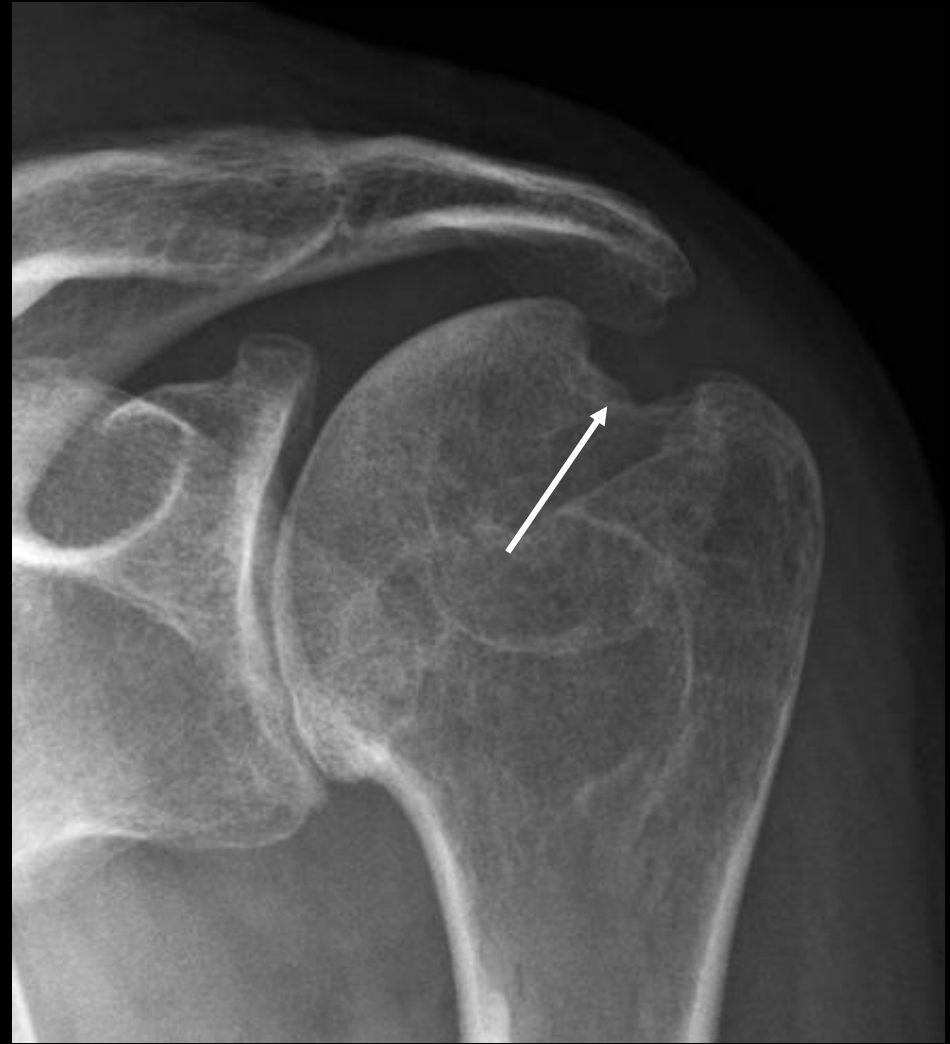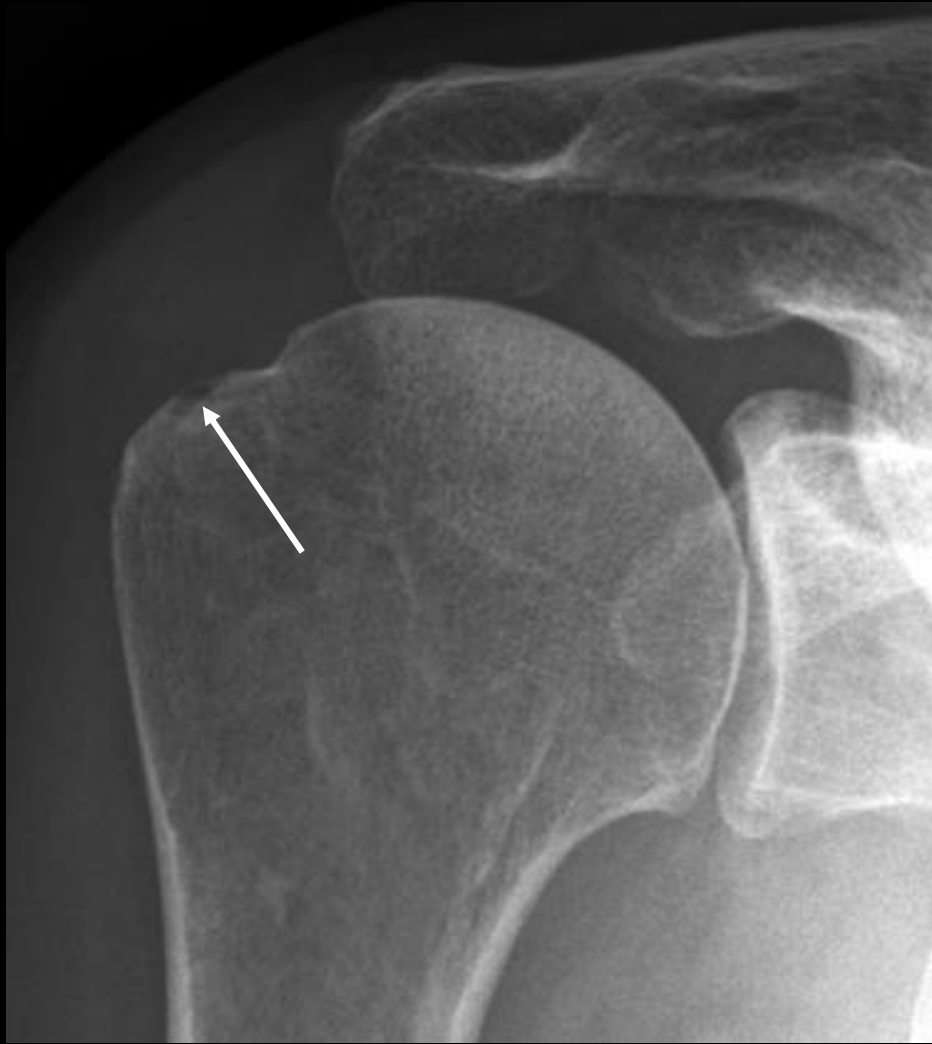B – Non

Topographie des érosions?

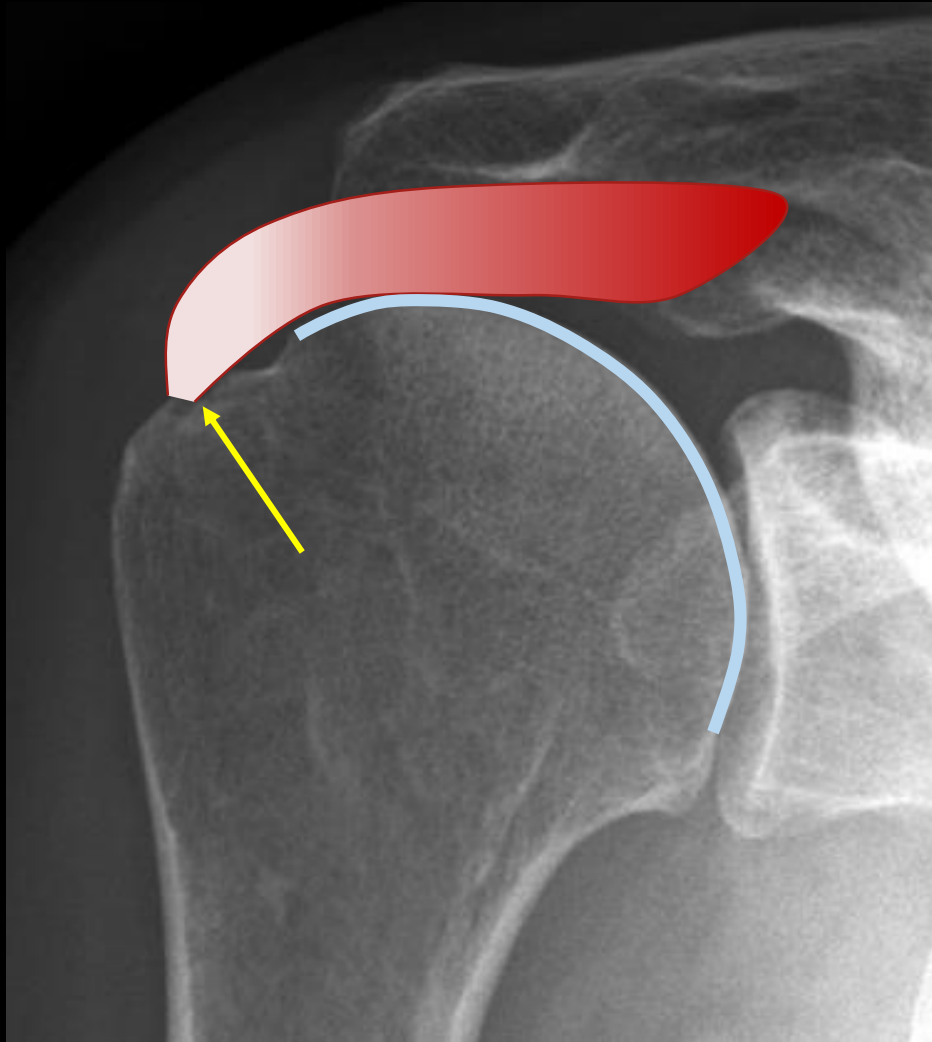
A – Marginale

B – Sous-chondrale

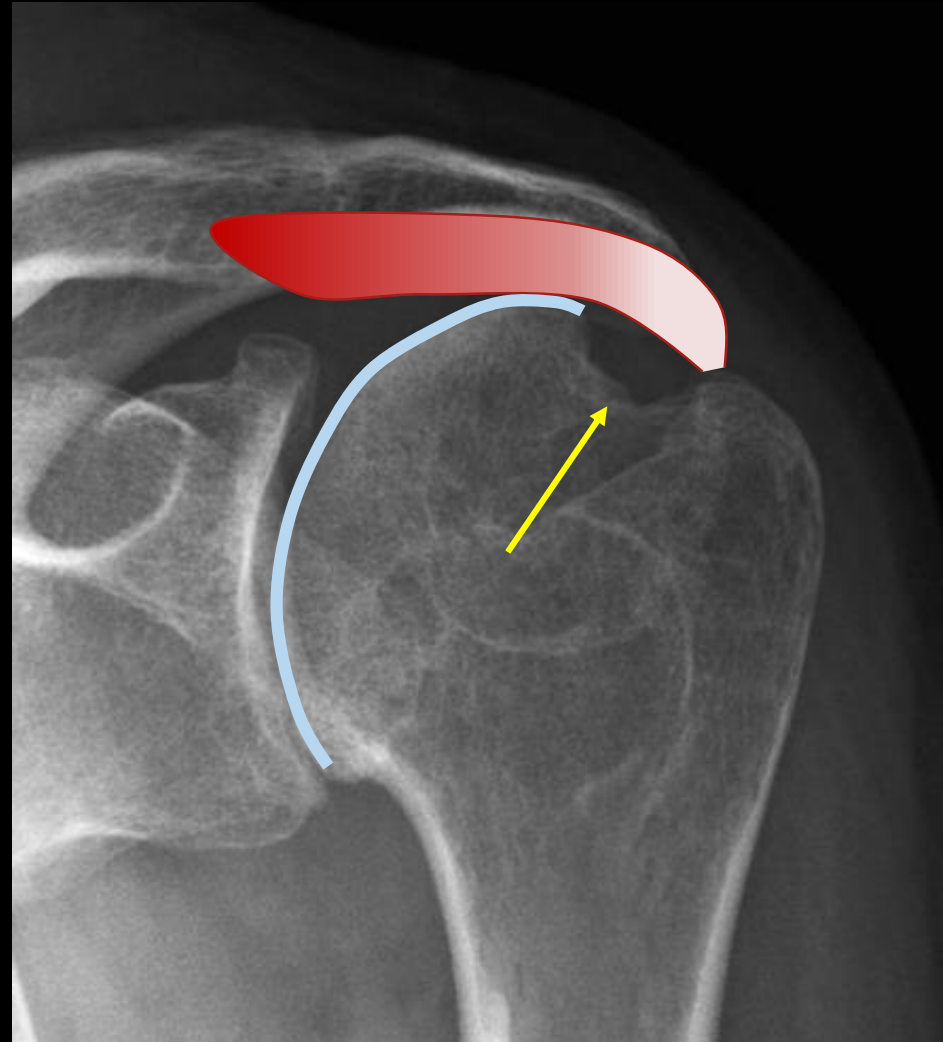
*remaniement mécanique  
conflit extrinsèque  
(chaussage)*



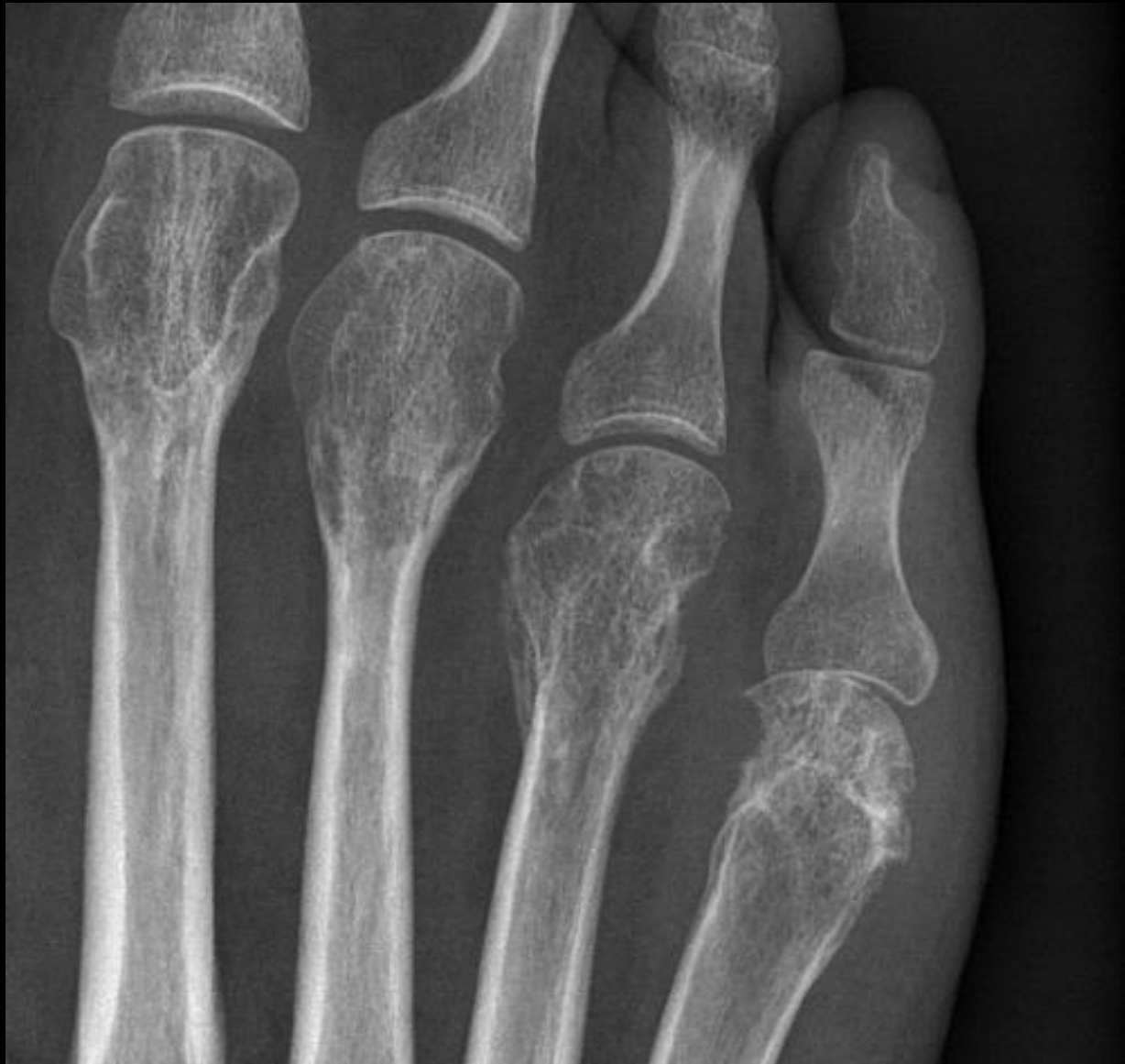Laquelle est mécanique? Laquelle est inflammatoire?



remaniement mécanique  
enthèse (supra-épineux)



remaniement inflammatoire  
os marginal (PR)



Erosion marginale?

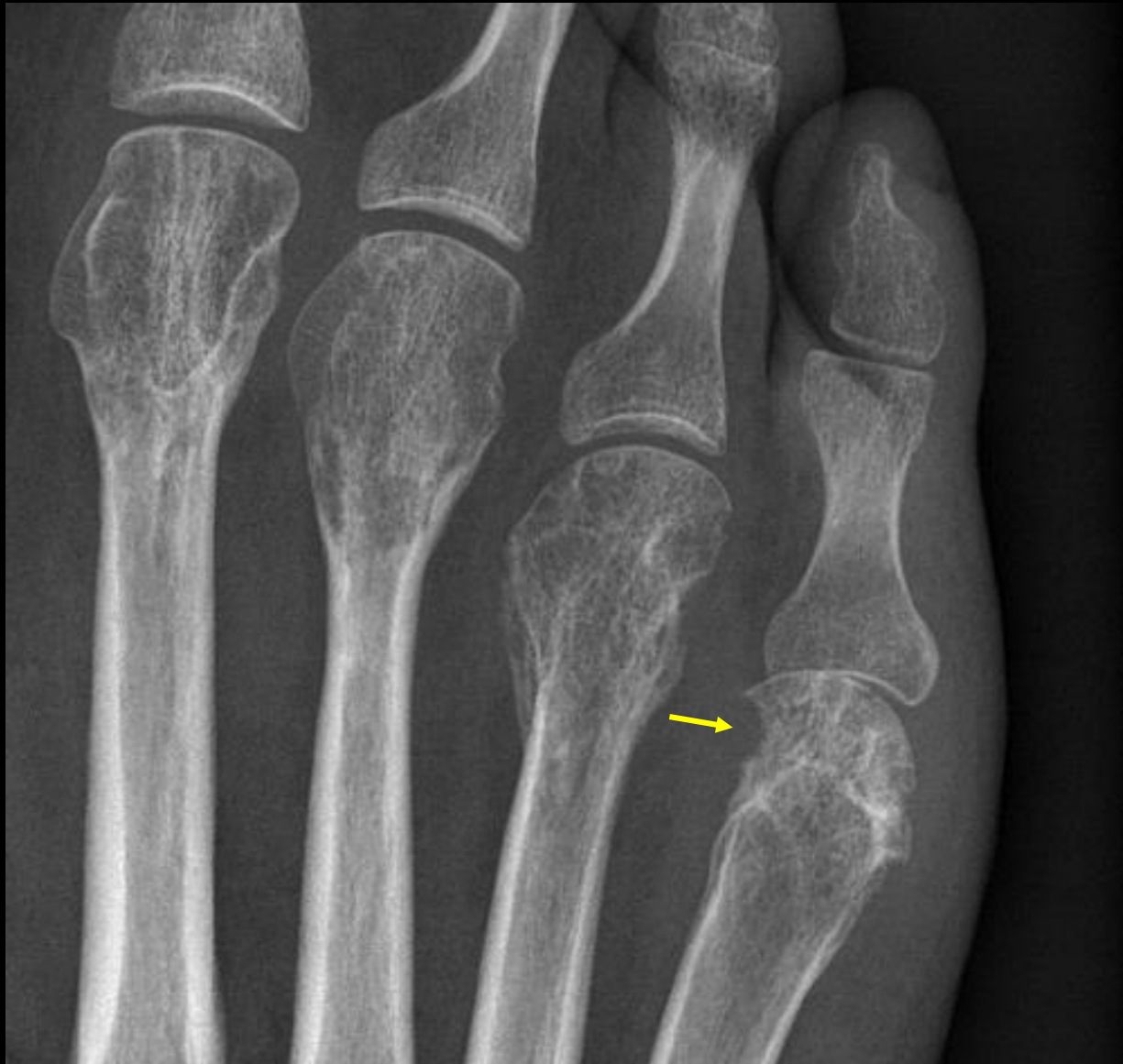A – Oui

B – Non

Pincement artriculaire?

A – Focal

B – Global



Erosion marginale?

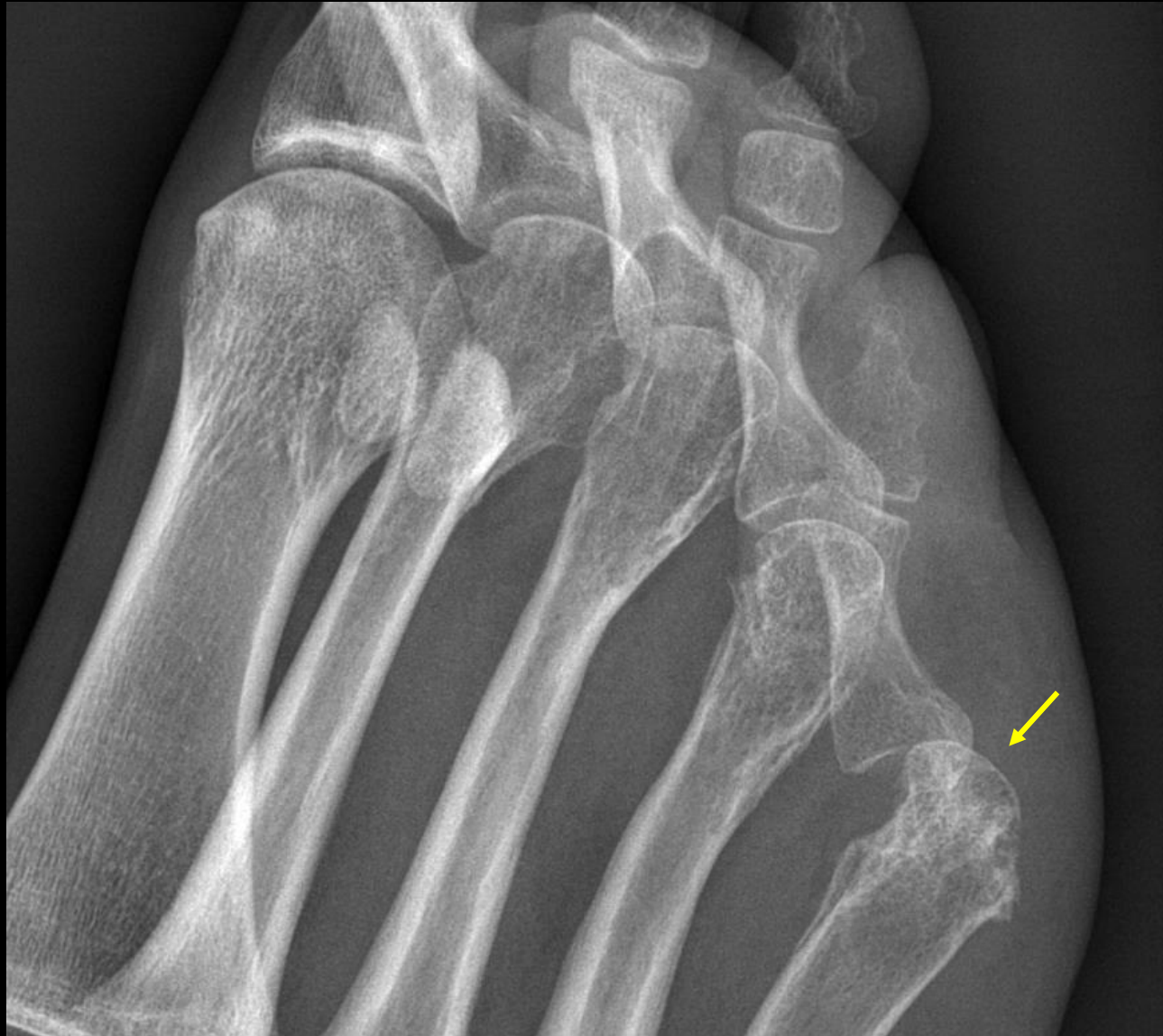A – Oui

B – Non

Pincement articulaire?

A – Focal

B – Global



Erosion marginale?

A – Oui

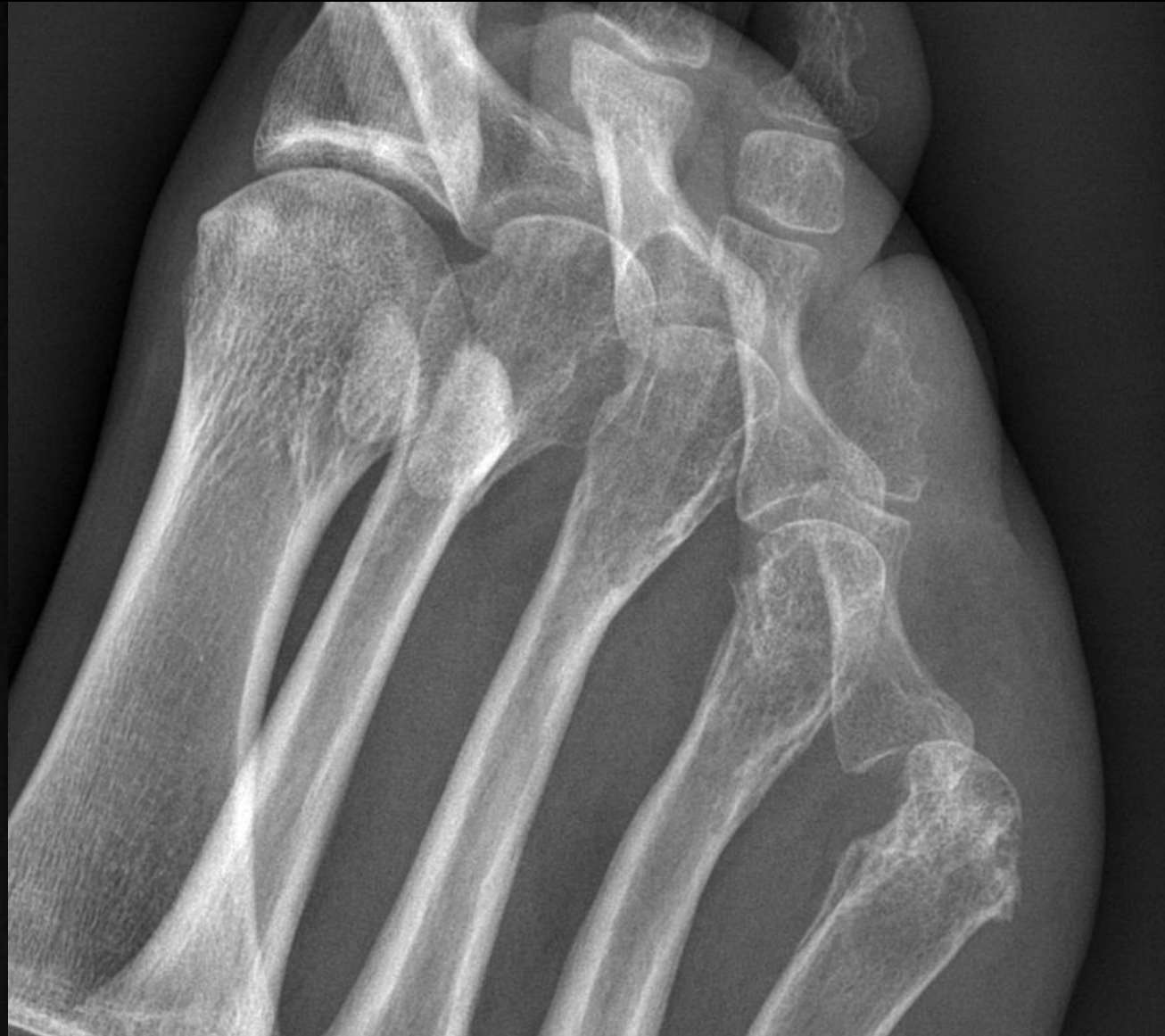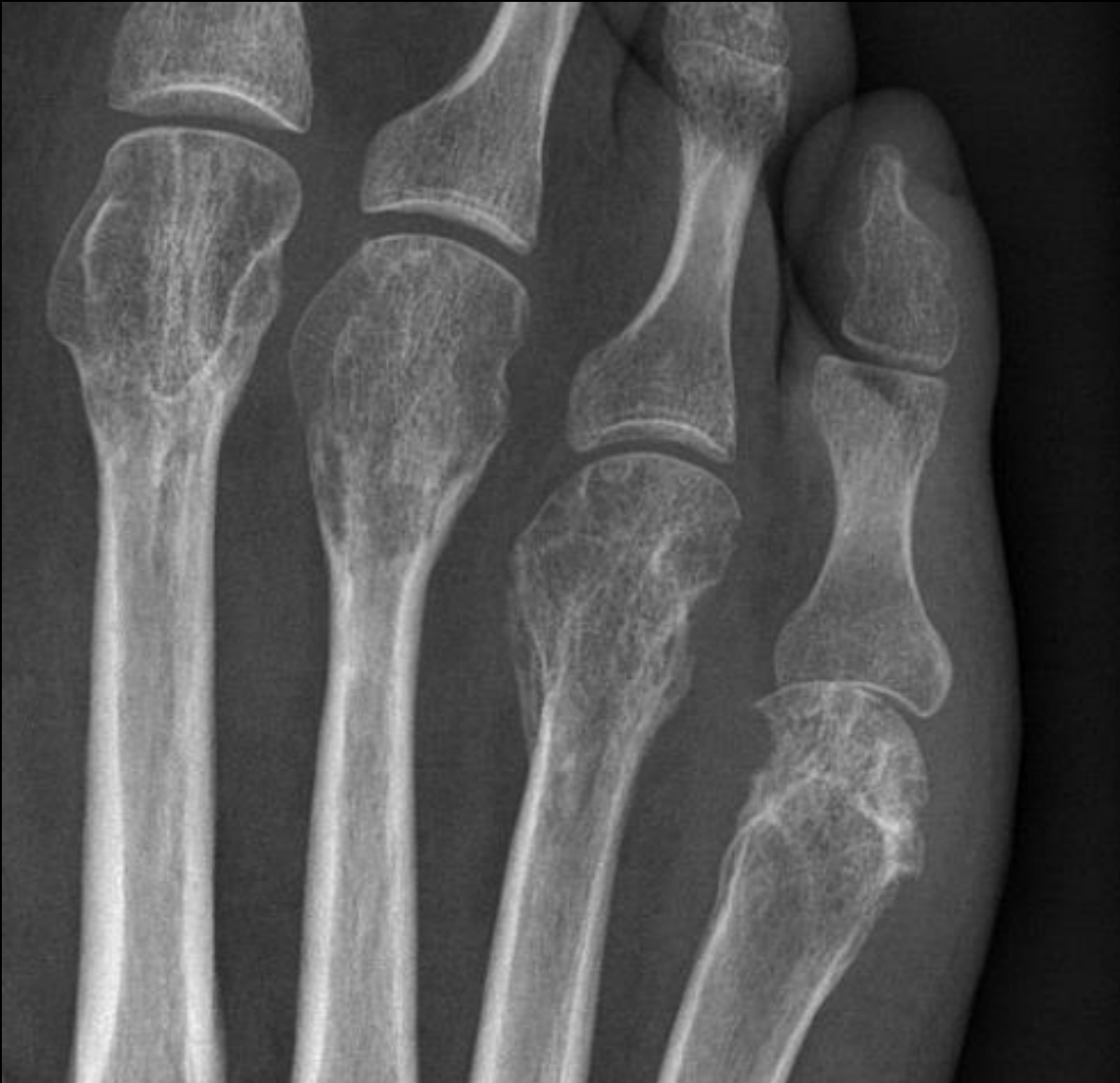B – Non

Pincement articulaire?

A – Focal

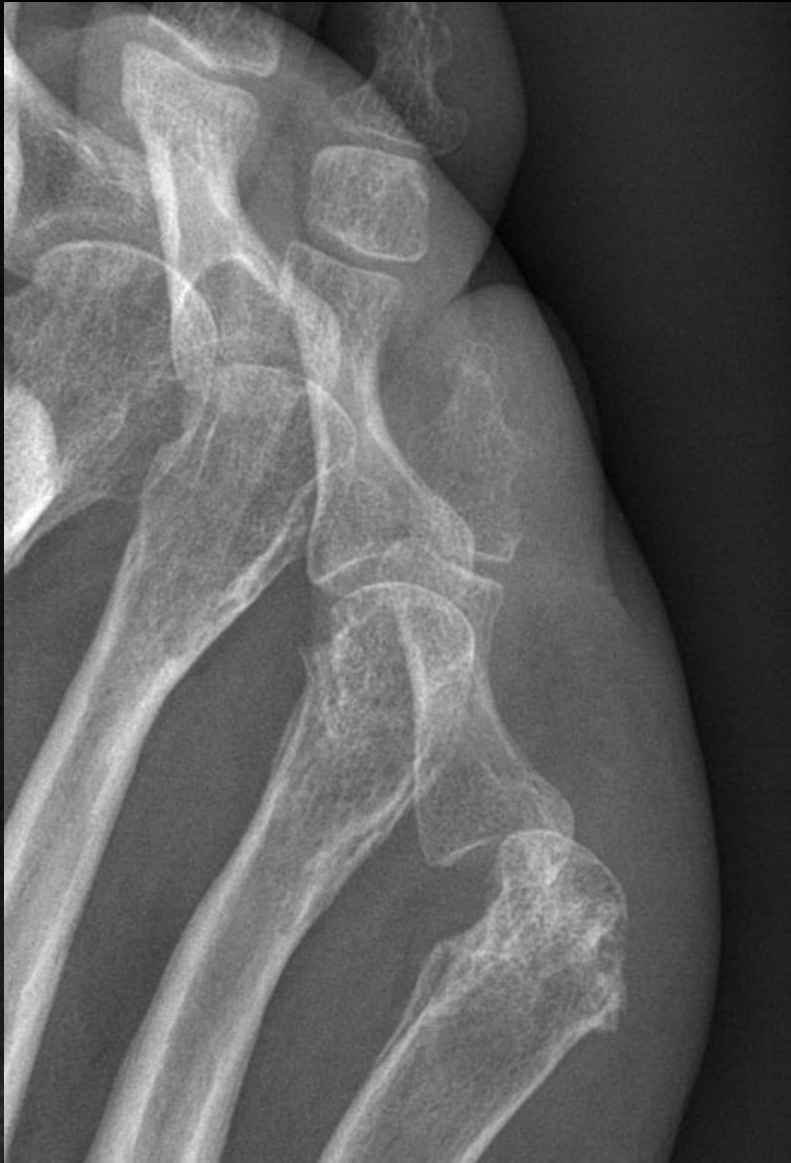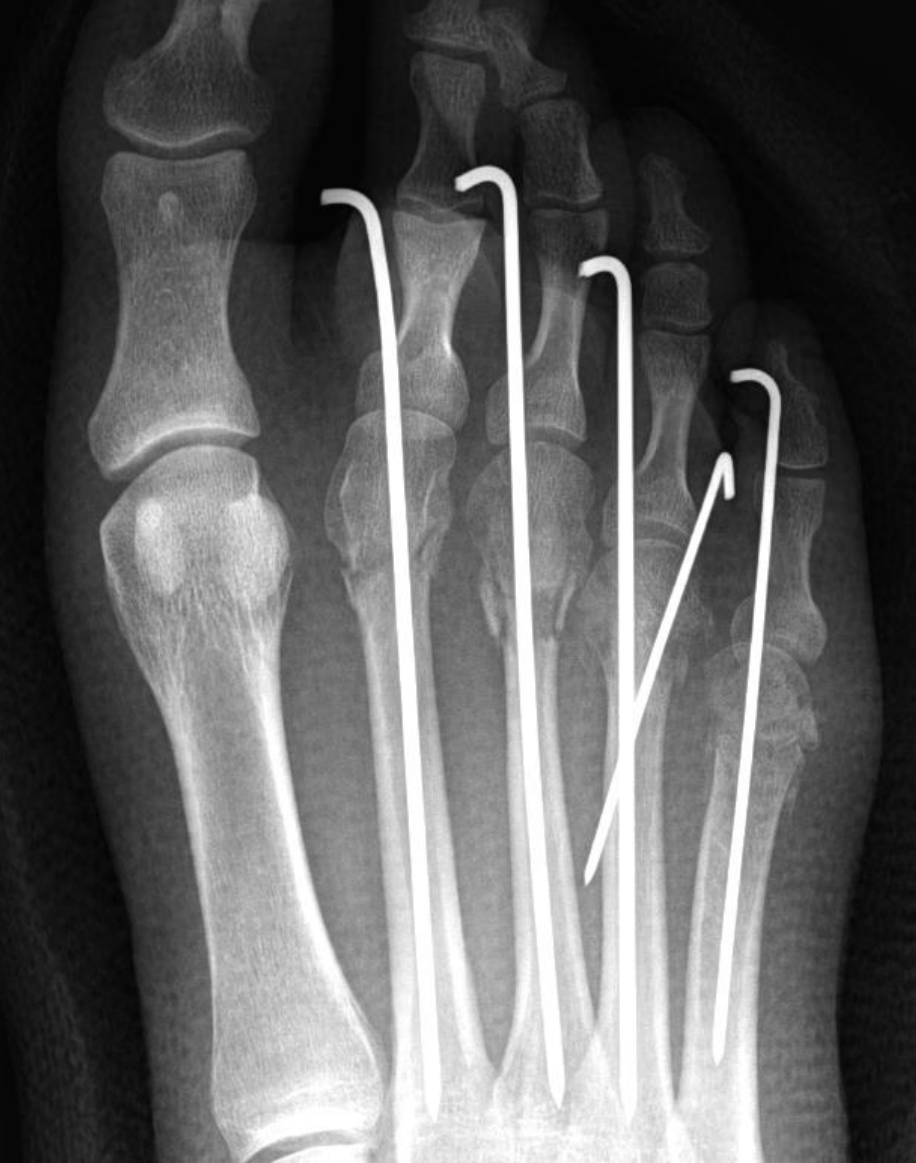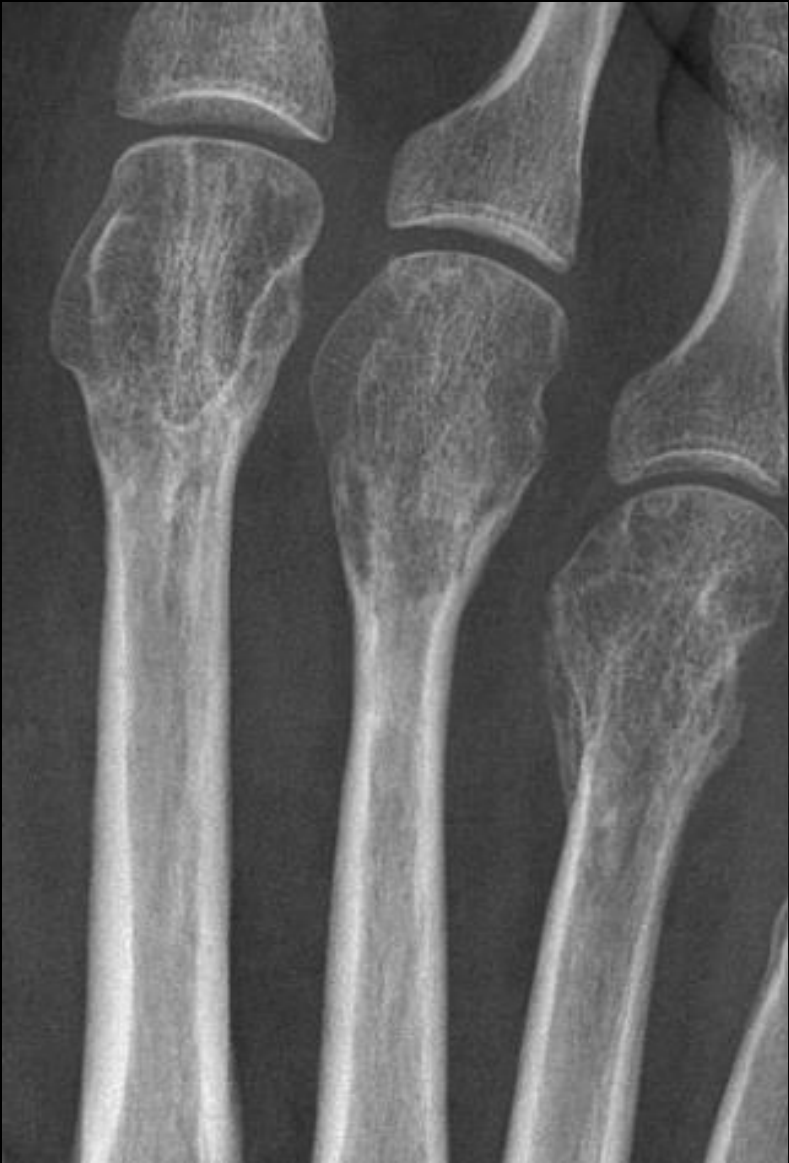B – Global

C – Subluxation



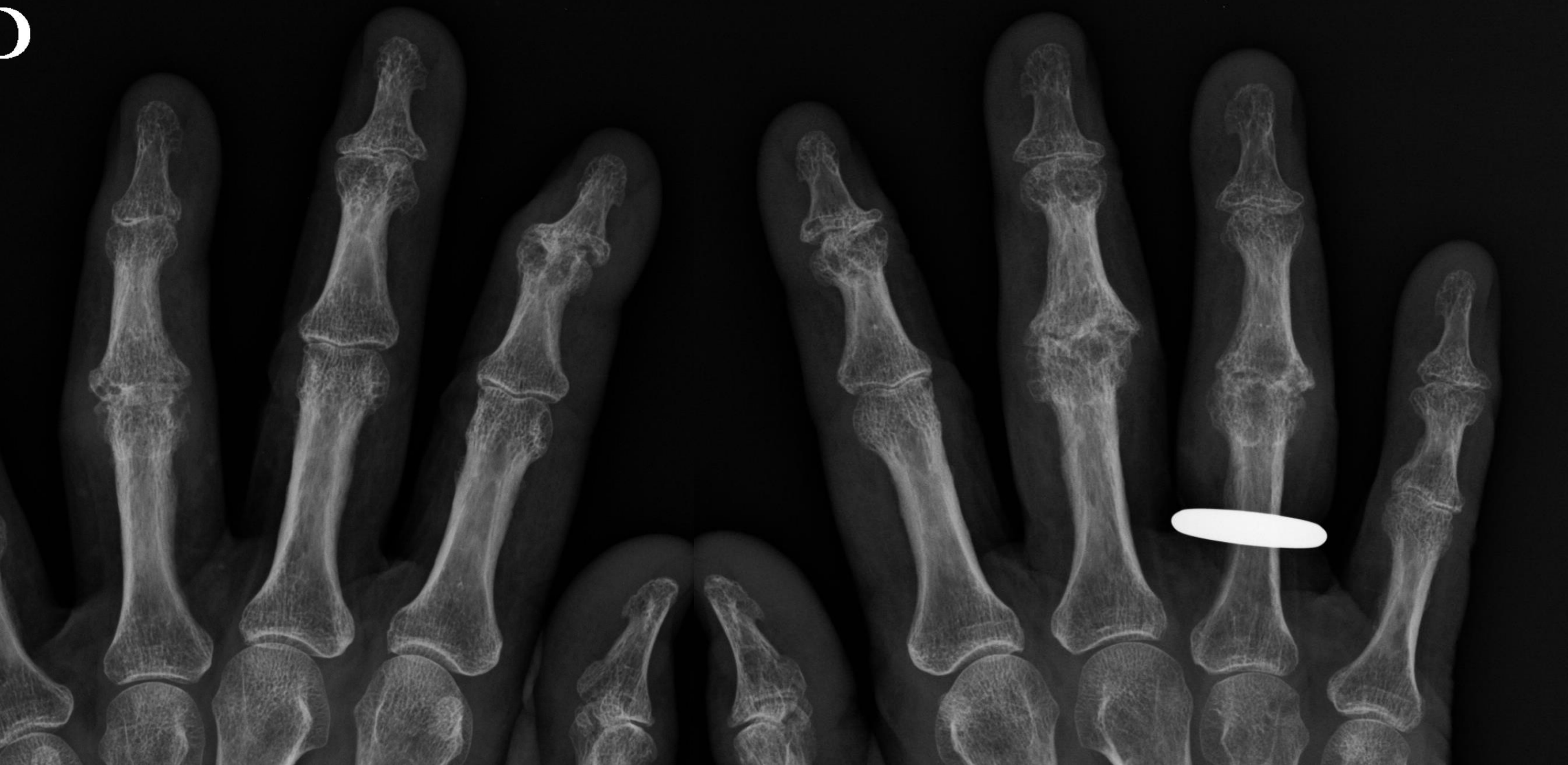Rhumatisme inflammatoire?





4 mois plus tôt...

3 CAS POUR TERMINER...



Pincement?

A – focal

B – global



Pincement?

A – focal

B – global

Erosions marginales?

A – oui

B – non



Pincement?

A – focal

B – global

Erosions marginales?

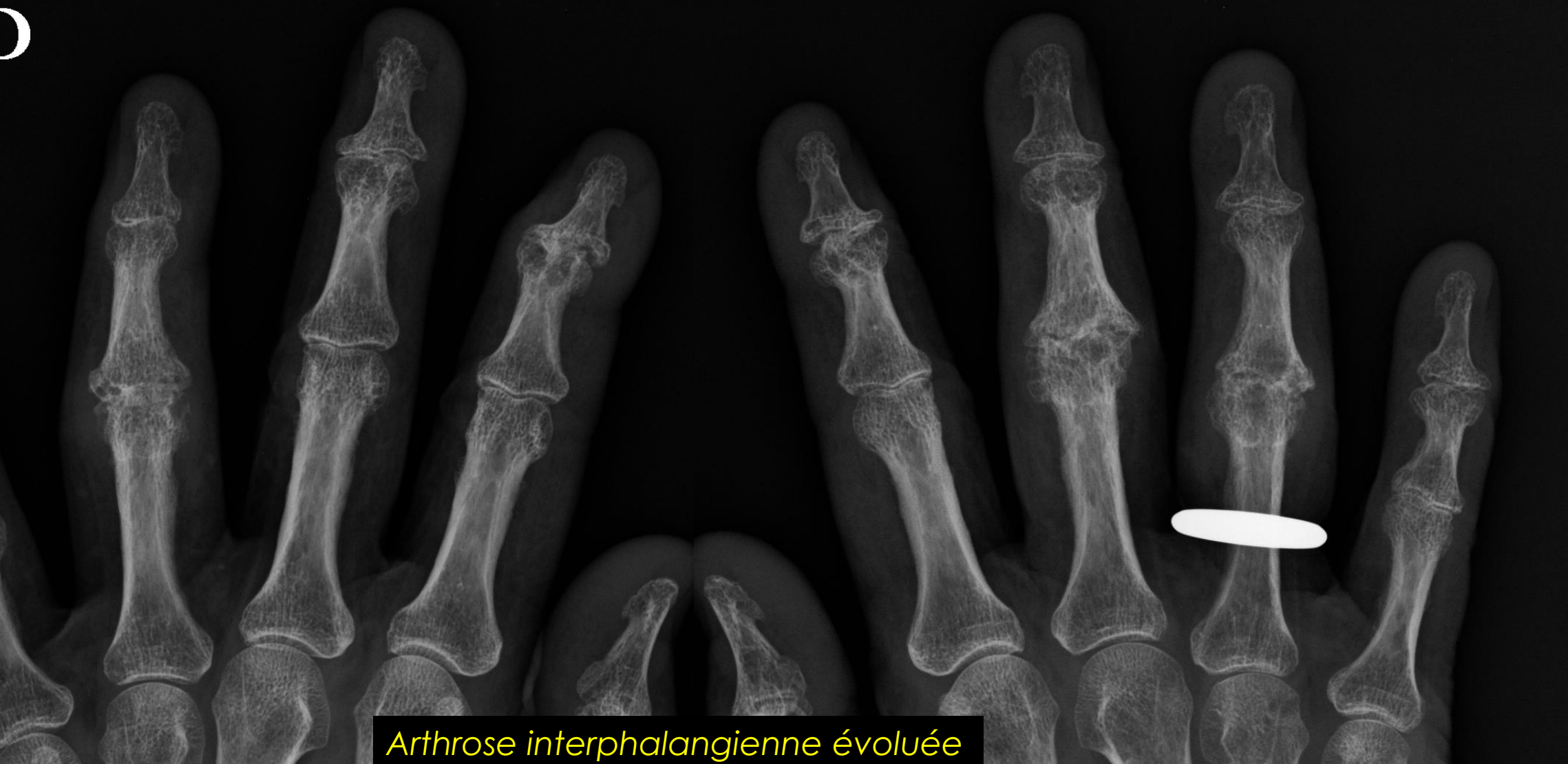A – oui

B – non

Arthropathie?

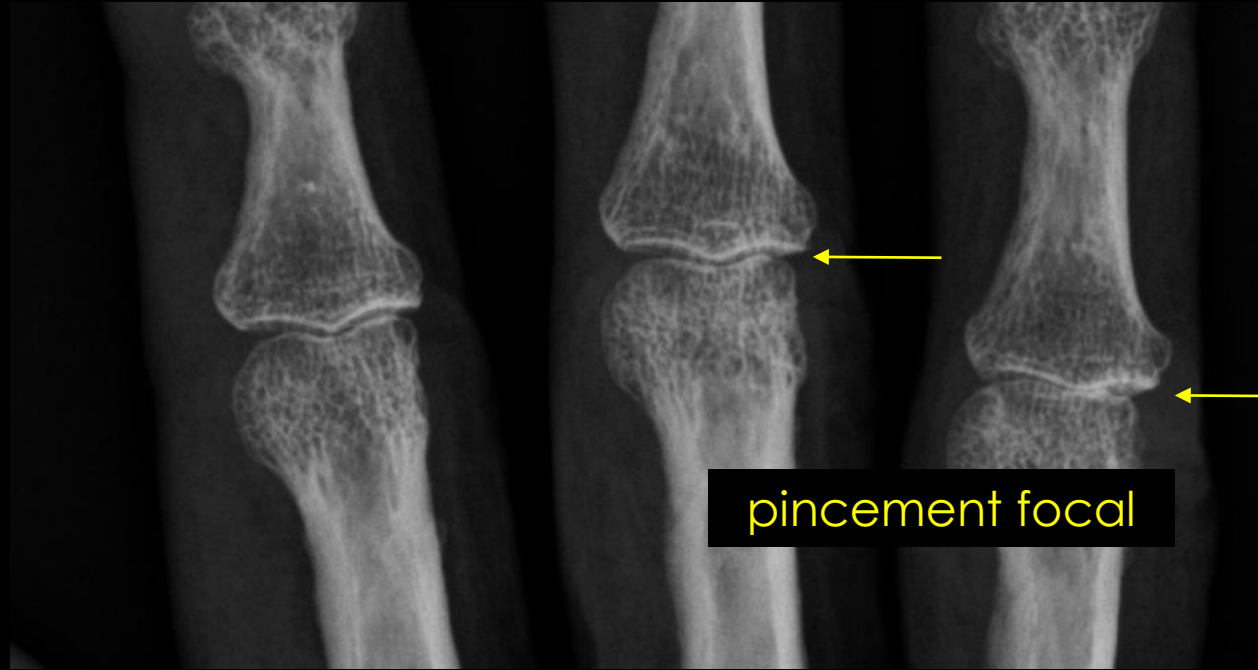
A – mécanique

B – inflammatoire



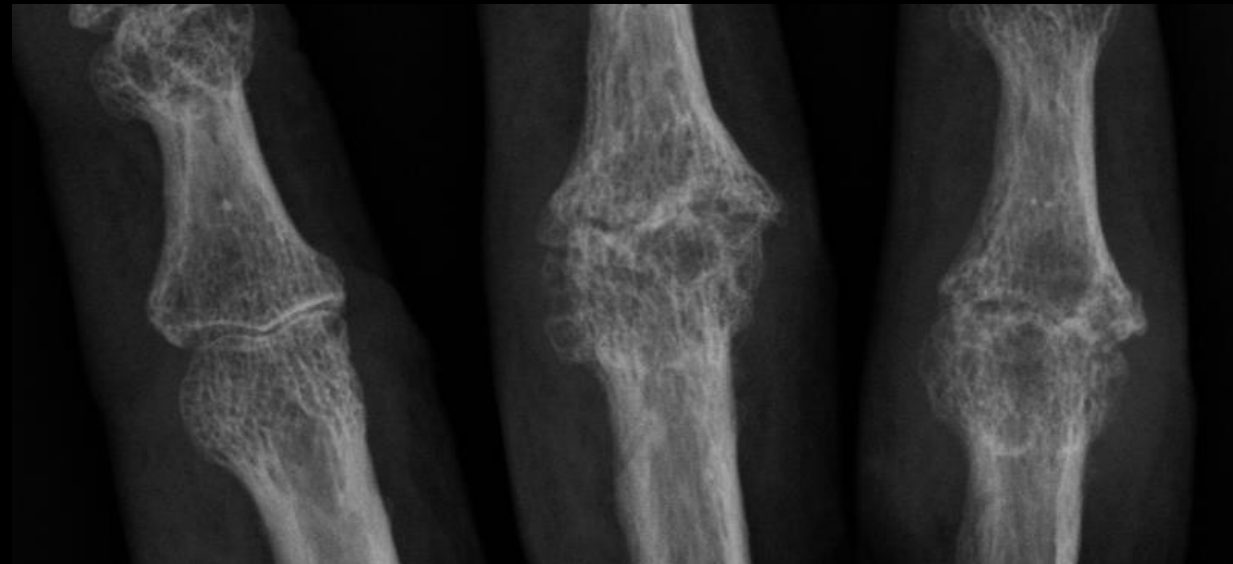
*Arthrose interphalangienne évoluée*

Pincement? A – focal B – <b>global</b>	Erosions marginales? A – oui B – <b>non</b>	Arthropathie? A – <b>mécanique</b> B – inflammatoire
--	---	--

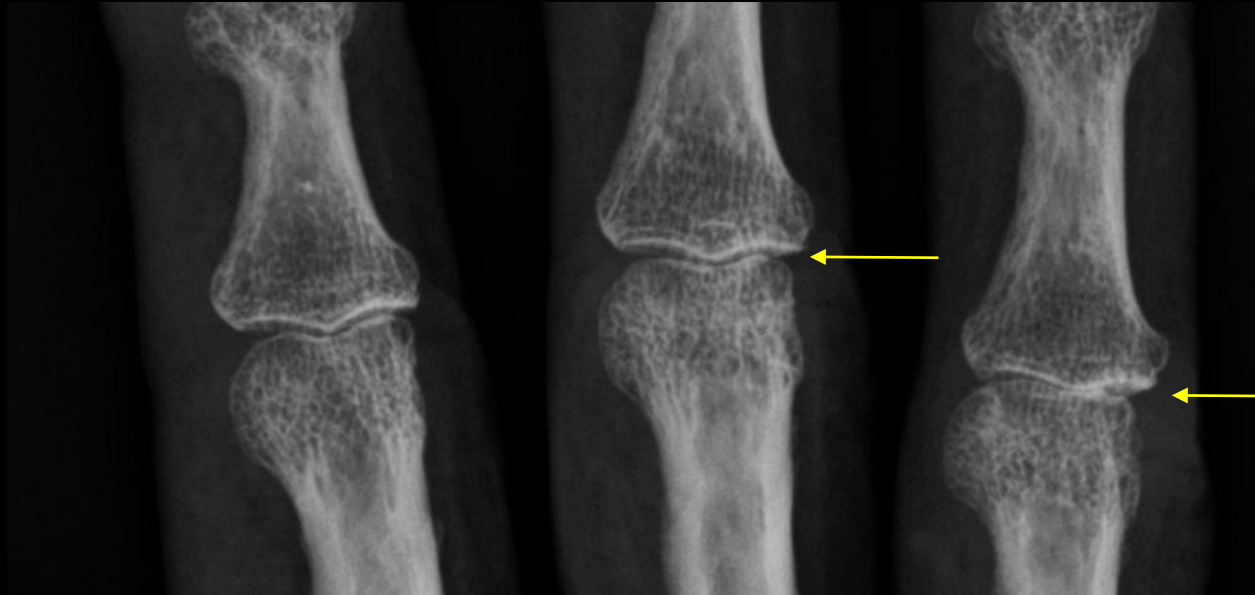


*8 ans plus tôt*

**pincement focal**

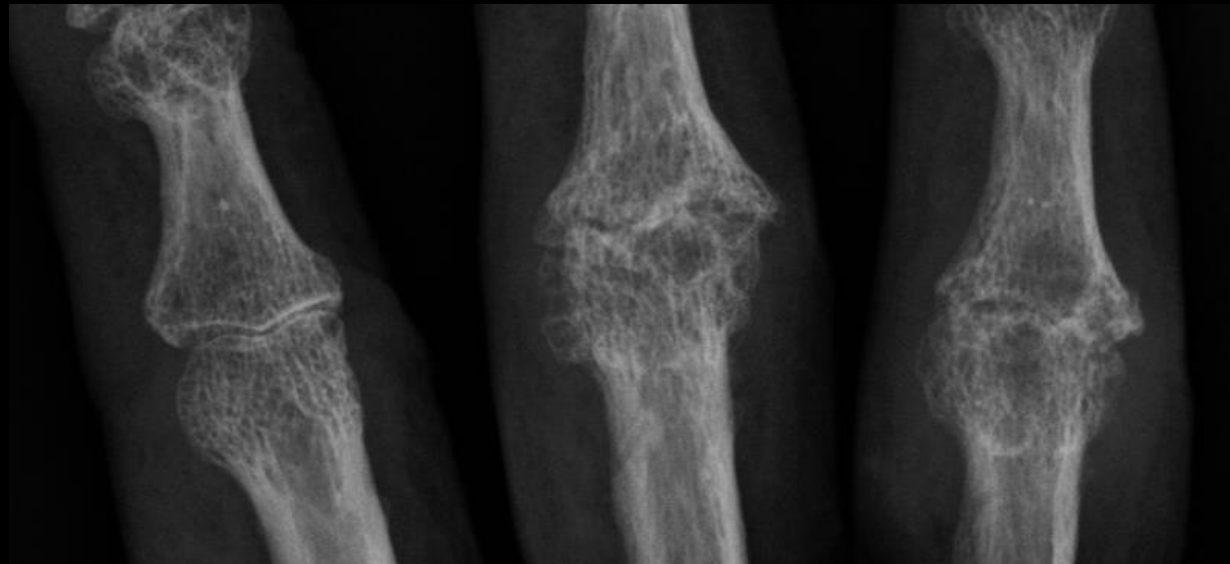


*aujourd'hui*



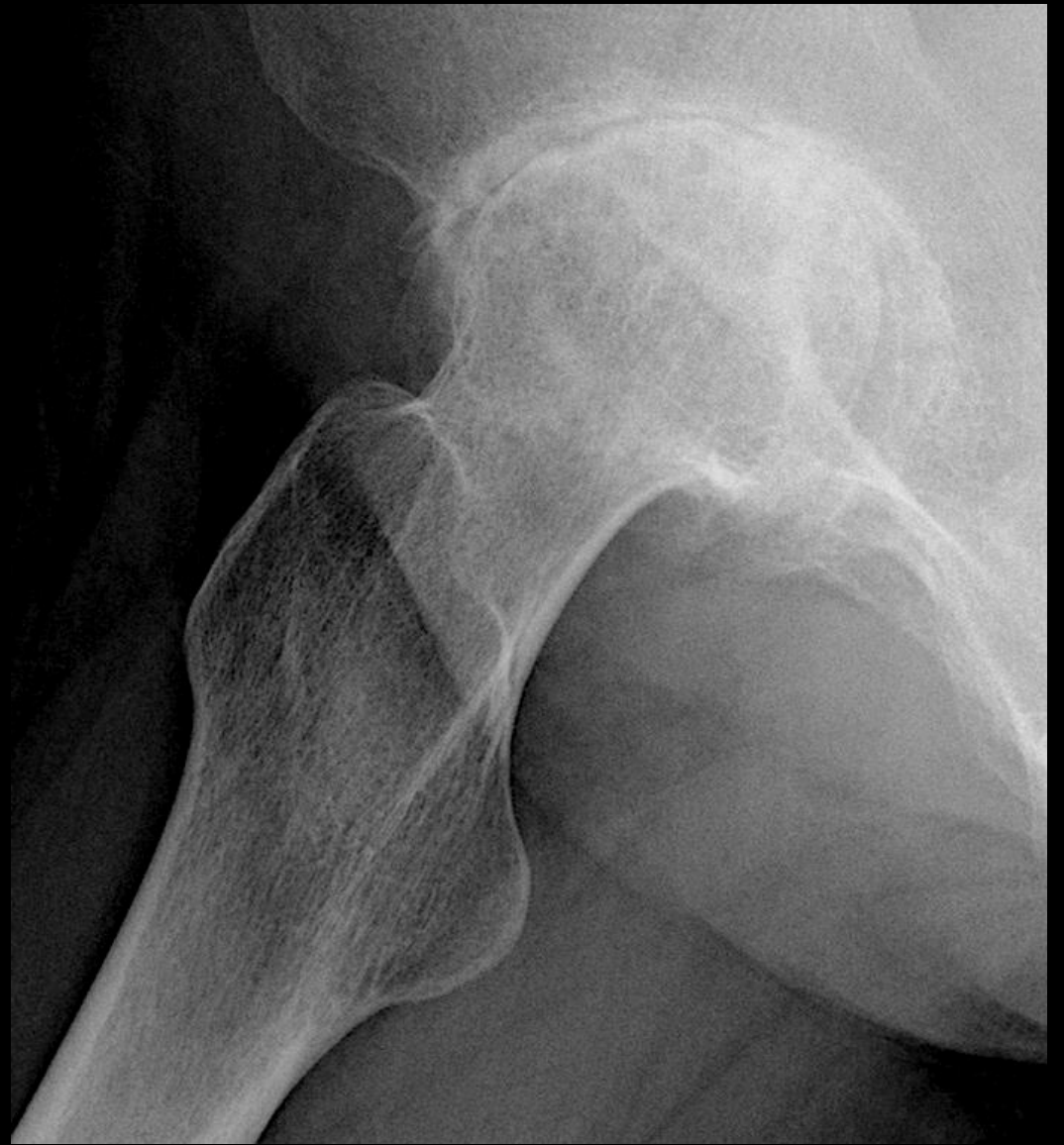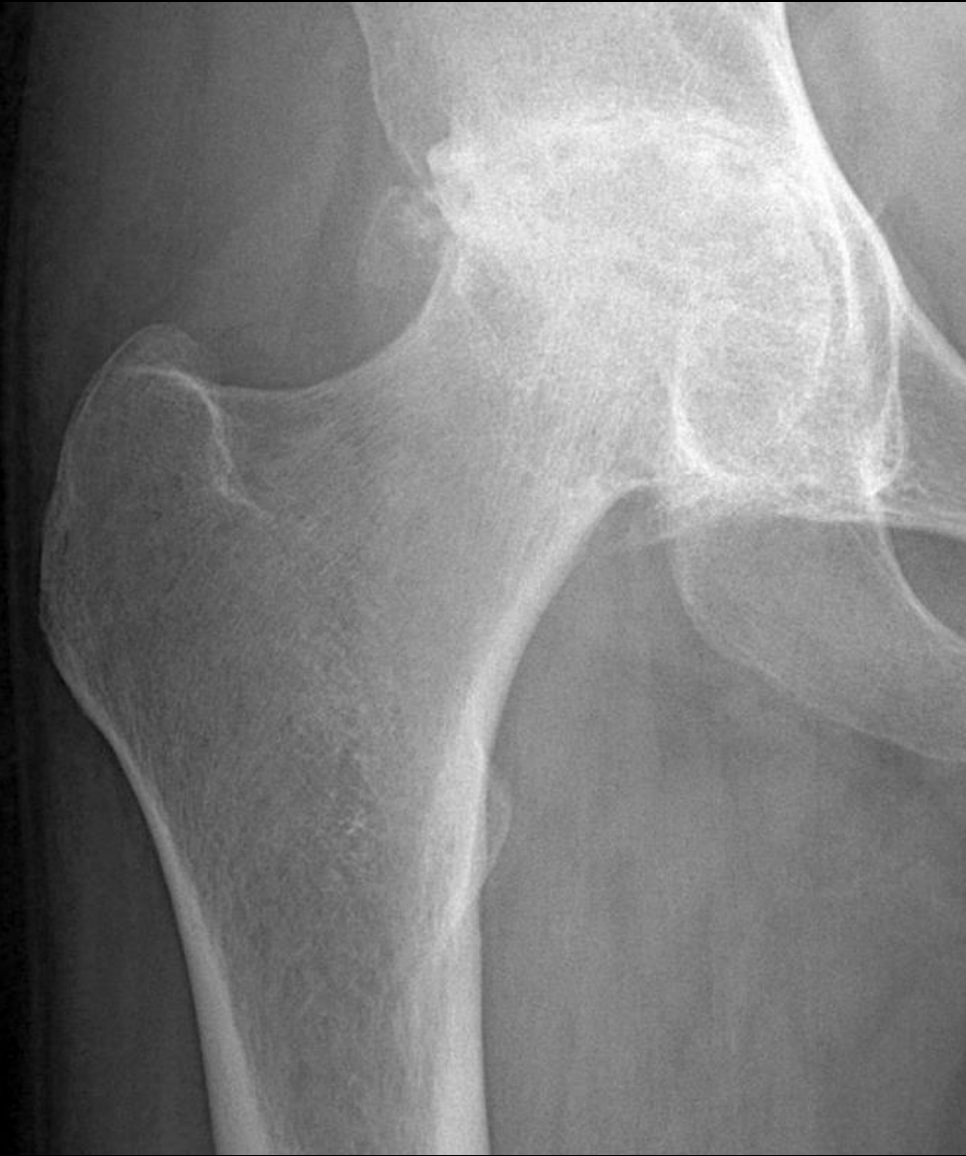*8 ans plus tôt*

**Pincement global ne veut pas toujours dire arthrite!**

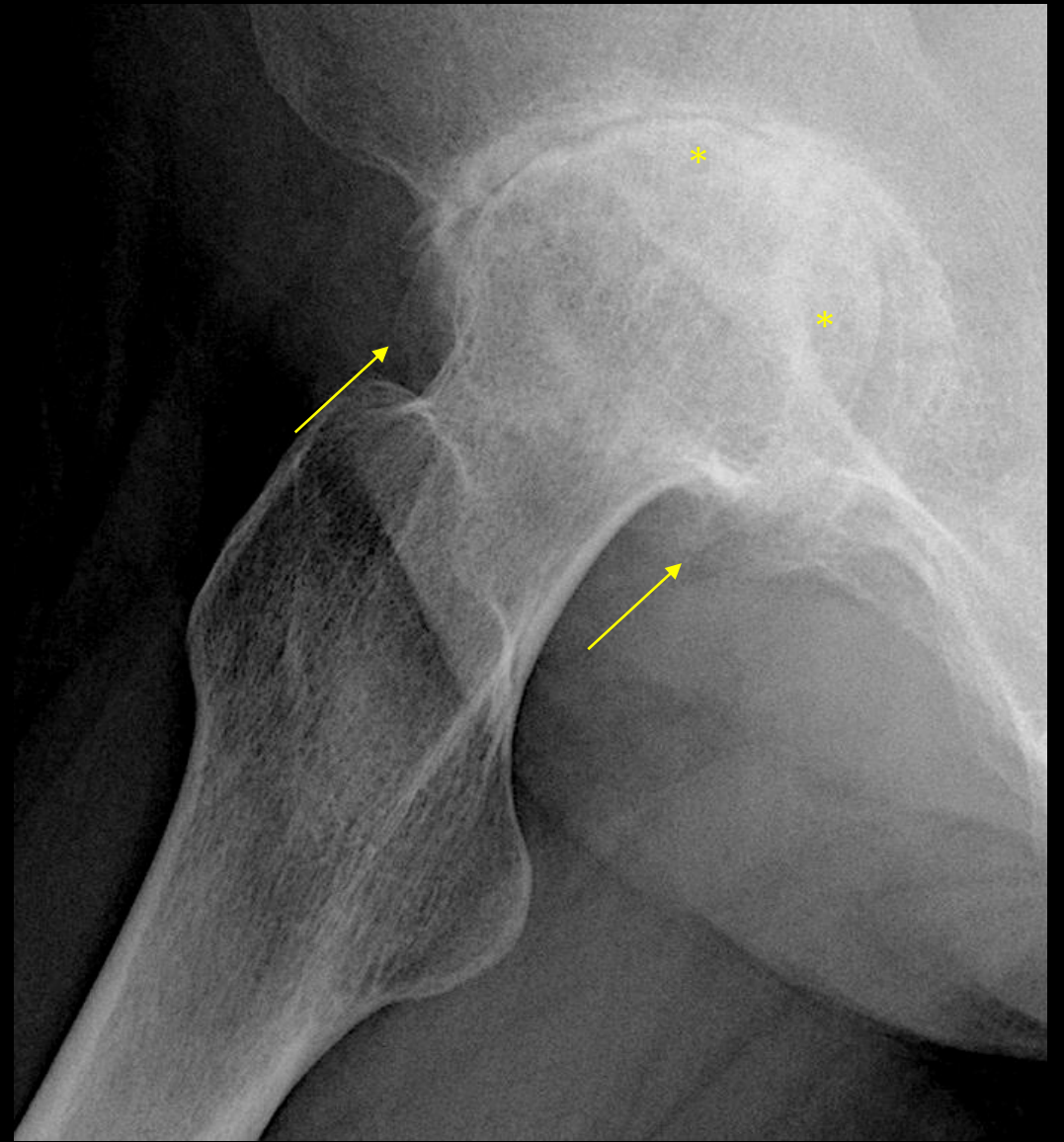
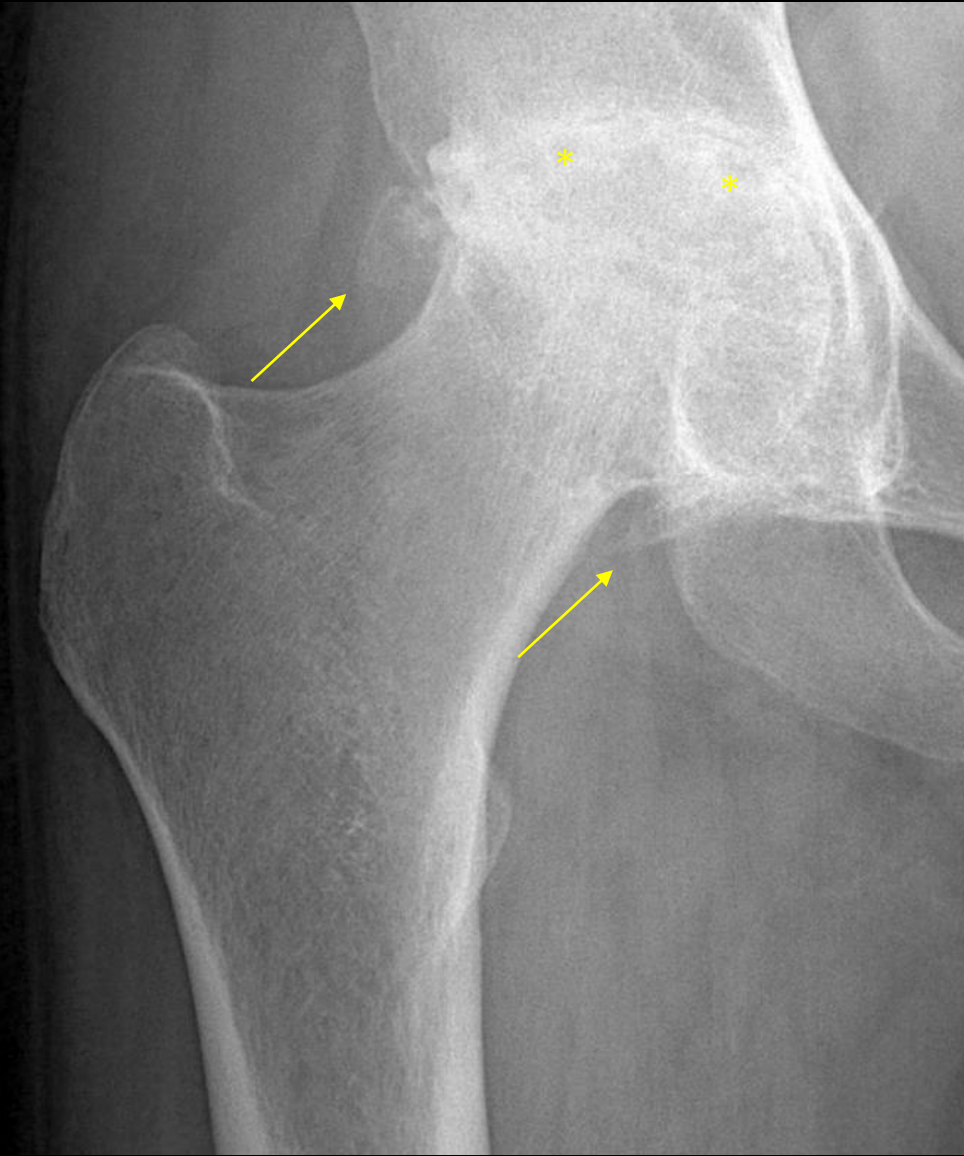


*aujourd'hui*

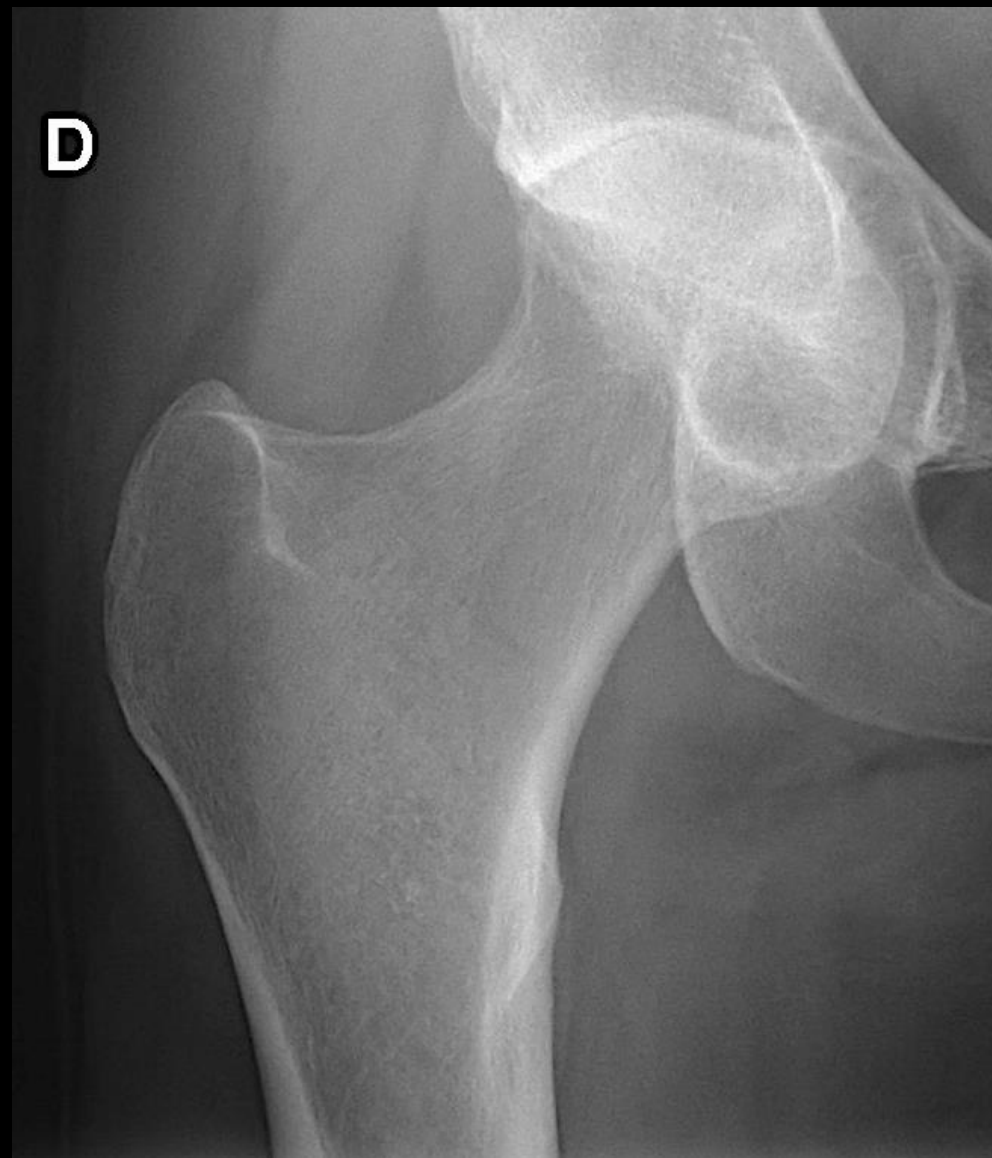
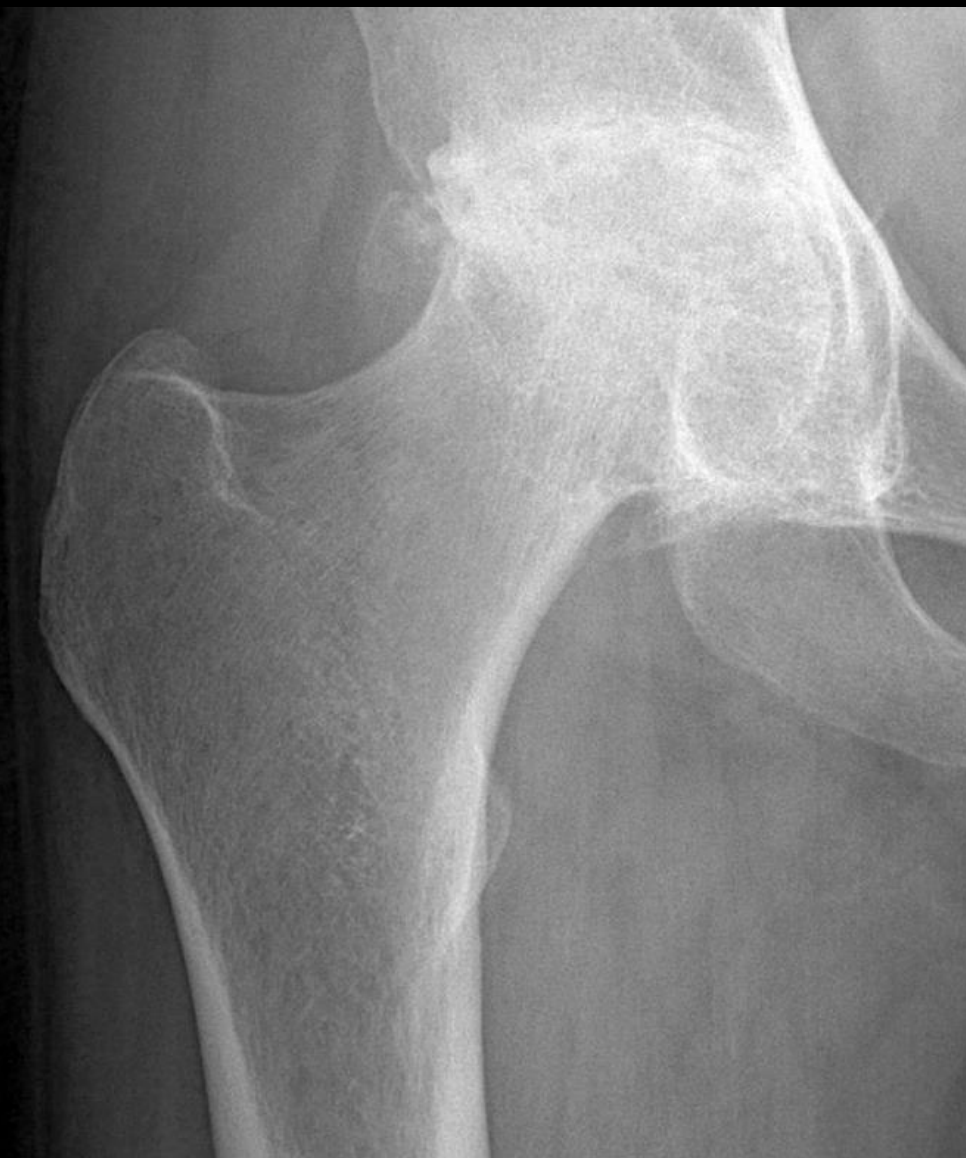



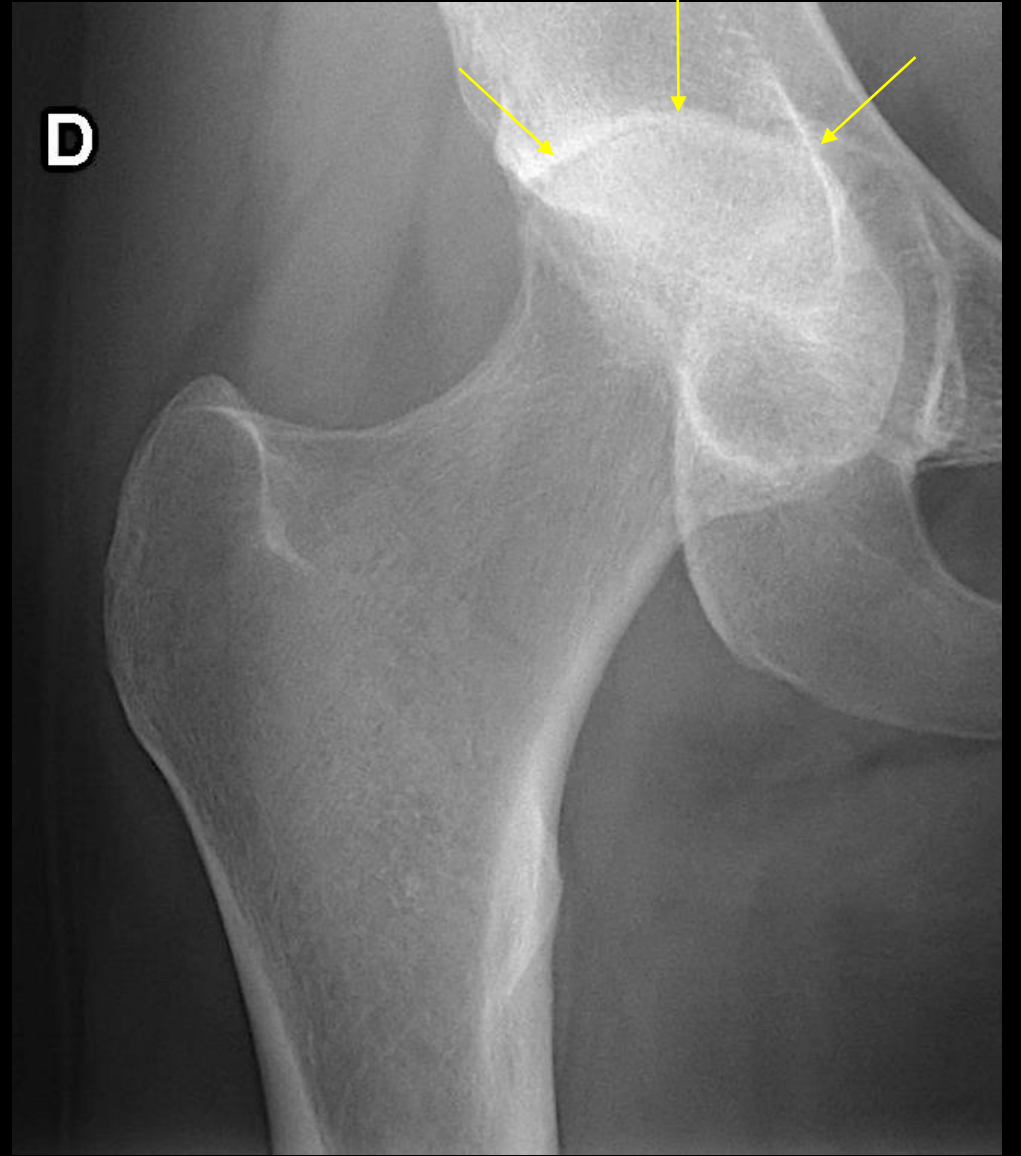
Arthrose? Arthrite?



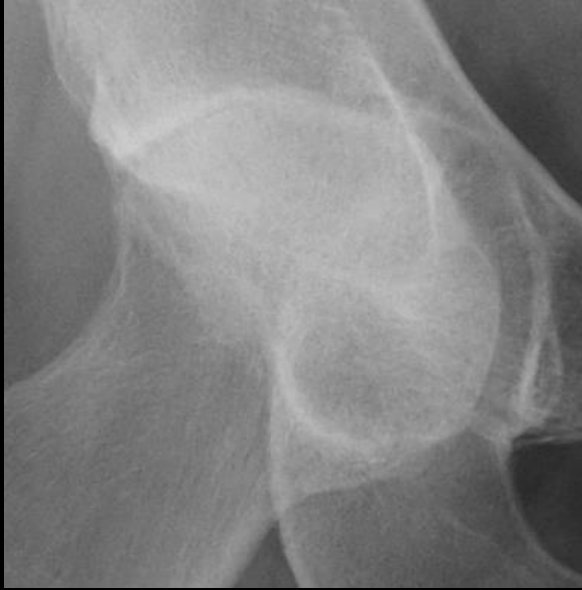pincement de l'interligne + géodes sous-chondrales + ostéophytose = arthrose



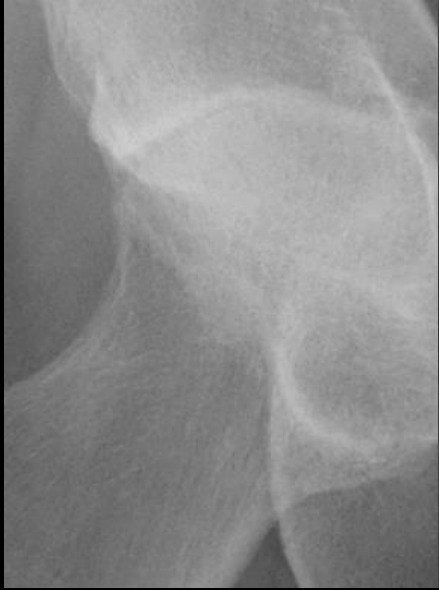9 ans plus tôt...



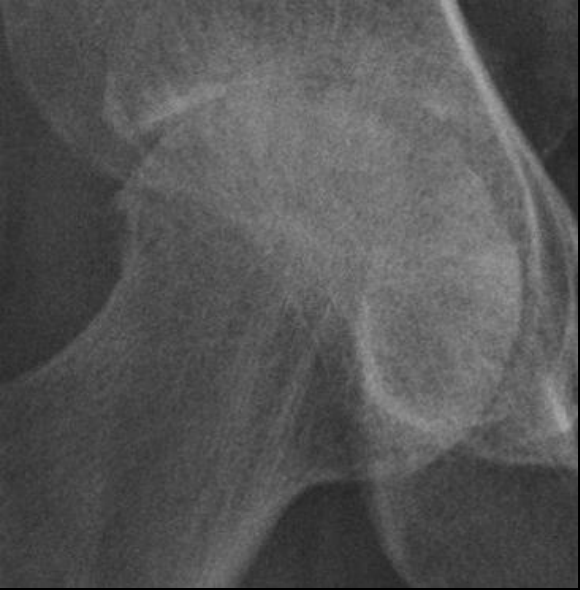coxite (pincement global)



2005



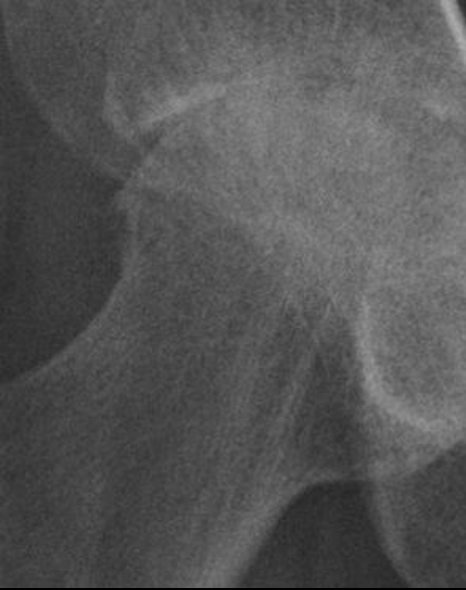2005



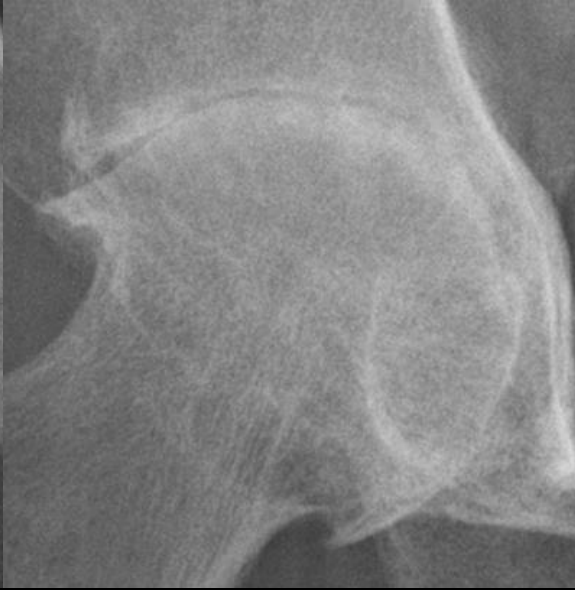2006



2005



2006



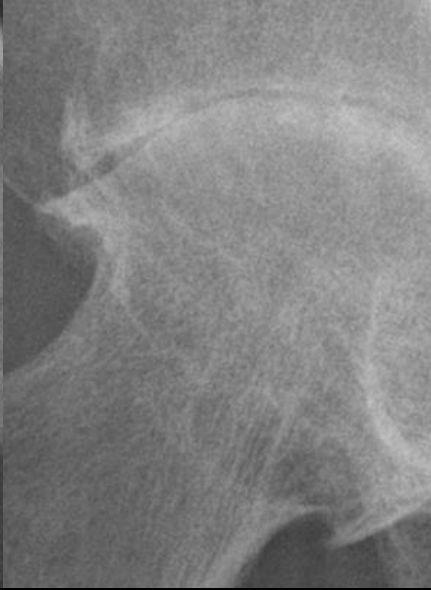
2009



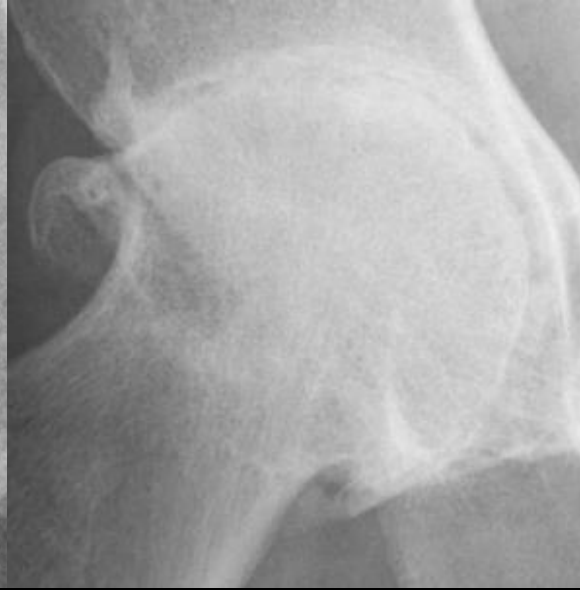2005



2006



2009



2013

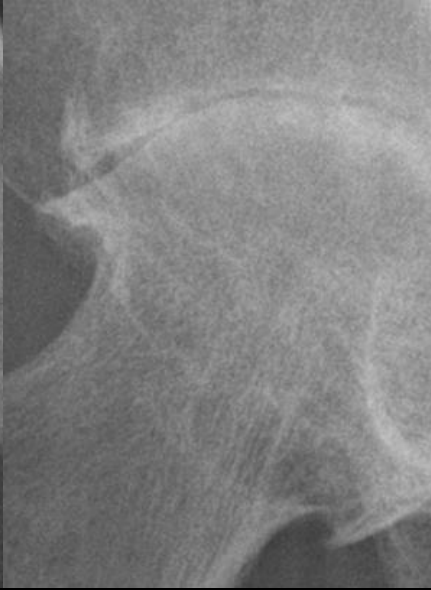




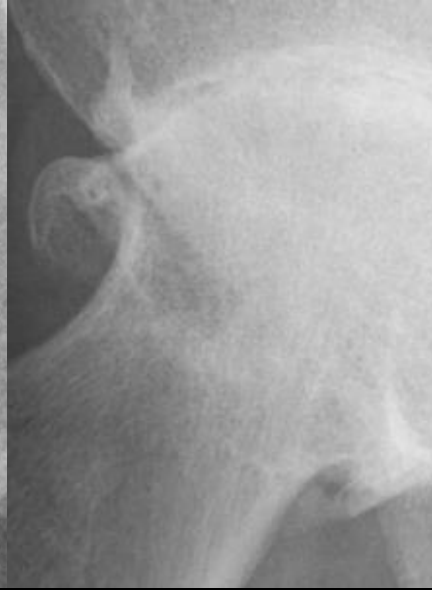
2005



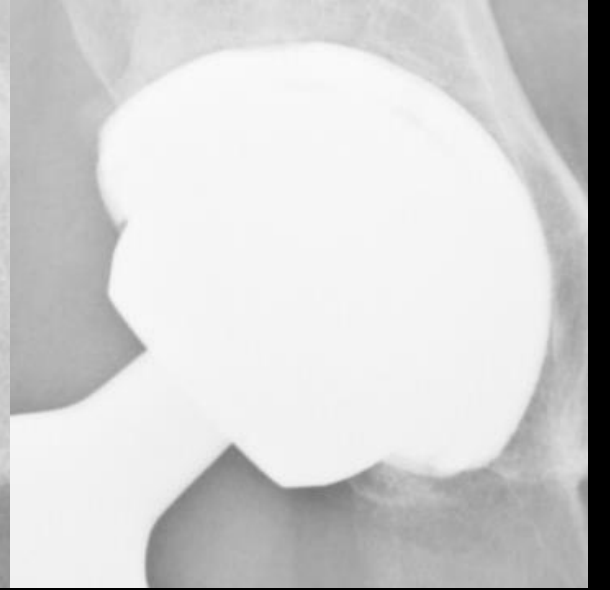
2006



2009



2013

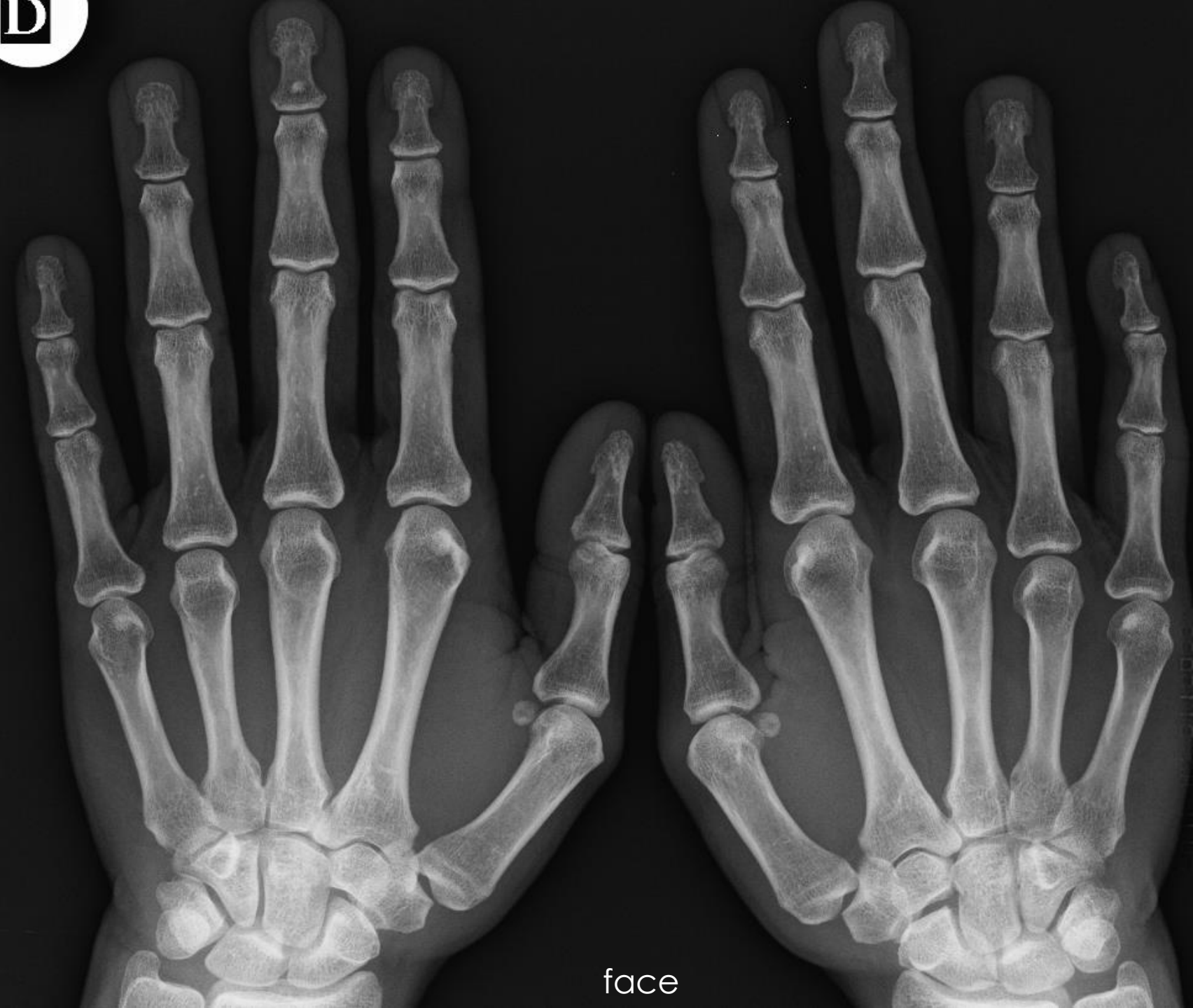

2015



**Avec le temps, une arthrite peut évoluer sur un mode dégénératif mécanique et une arthrose**

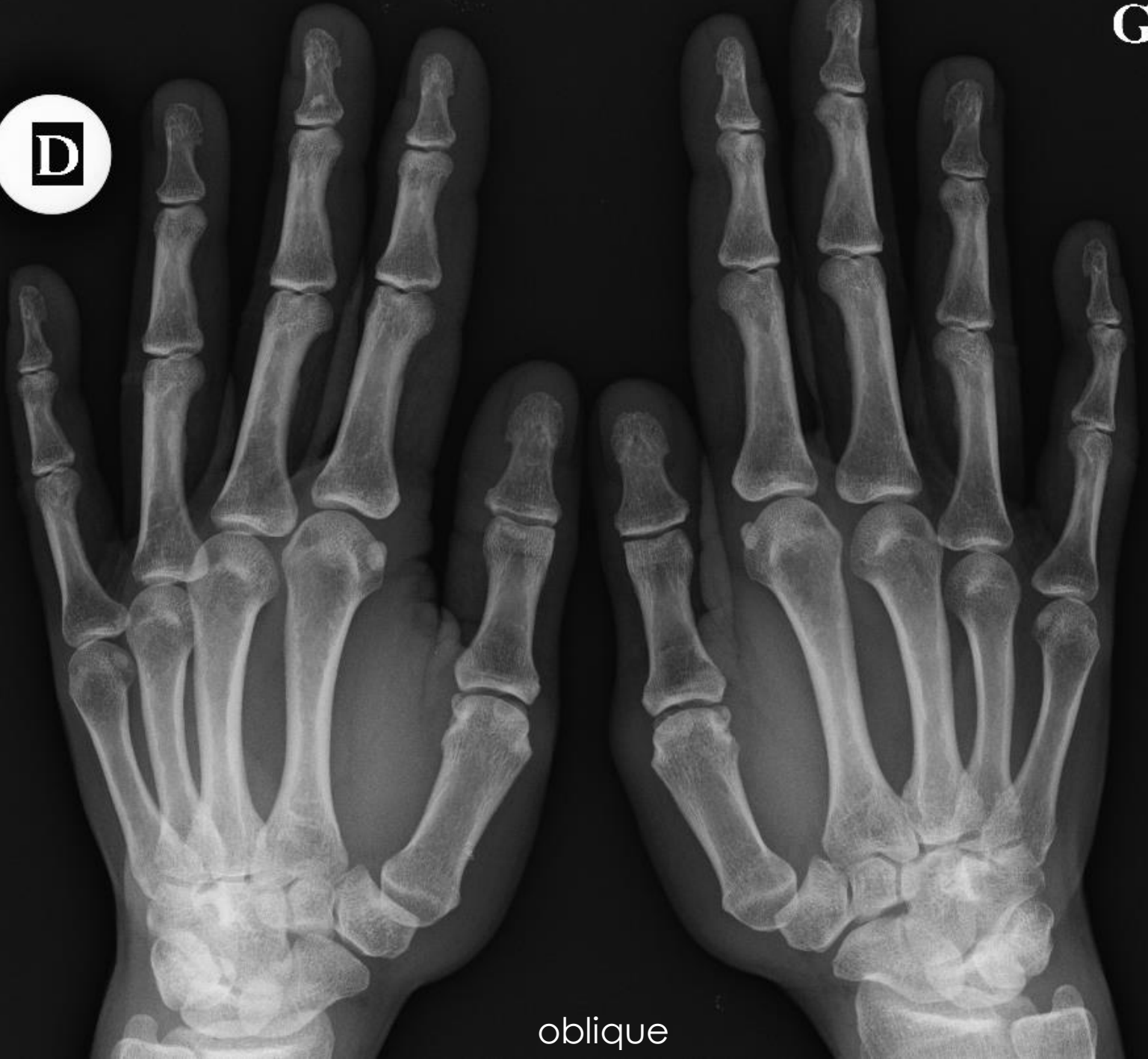arthrose secondaire à une arthrite



Suspicion de PR  
débutante

- A – Tissus mous?
- B – Erosion?
- C – Chondrolyse?

D



oblique

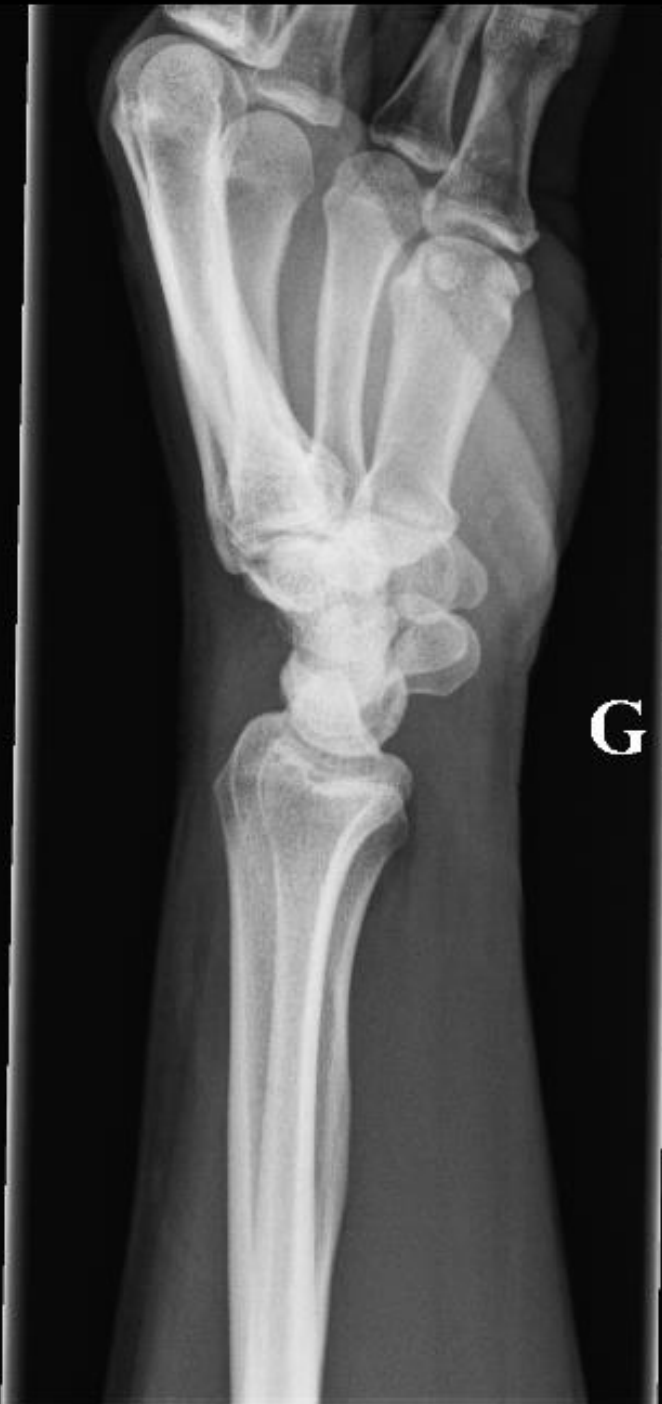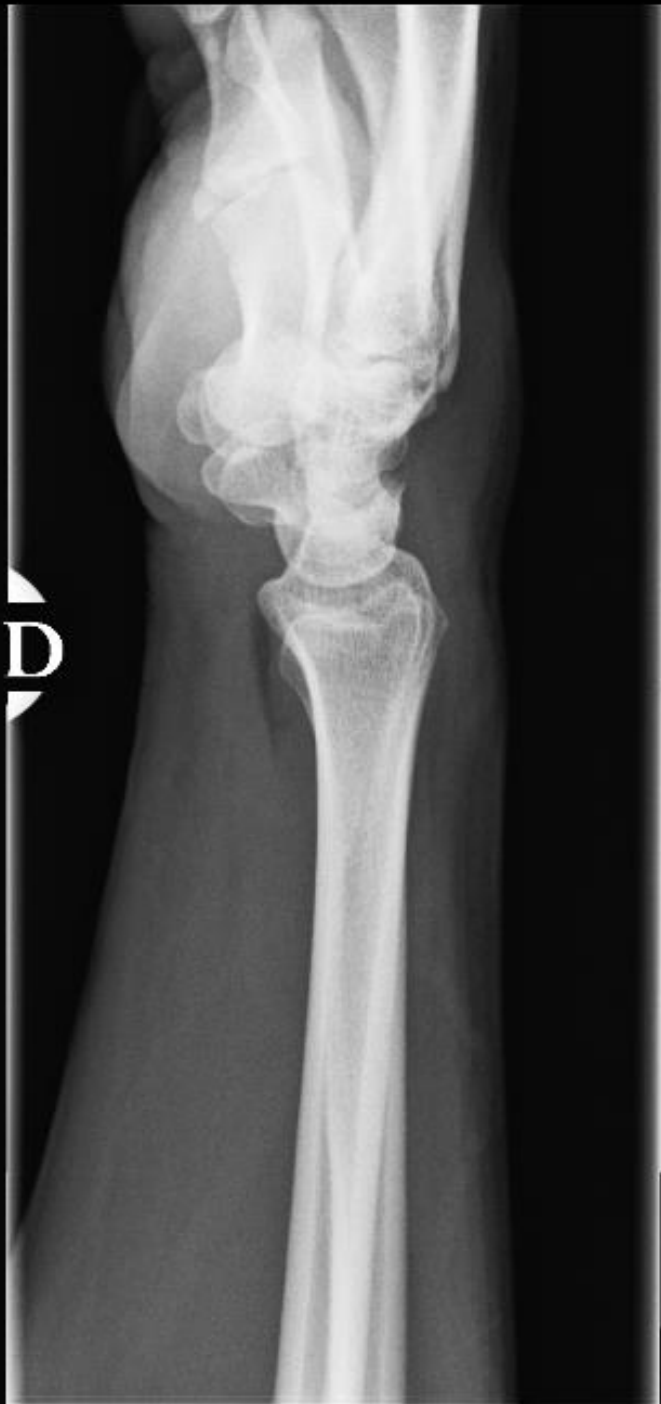G

Suspicion de PR  
débutante

A – Tissus mous?

B – Erosion?

C – Chondrolyse?


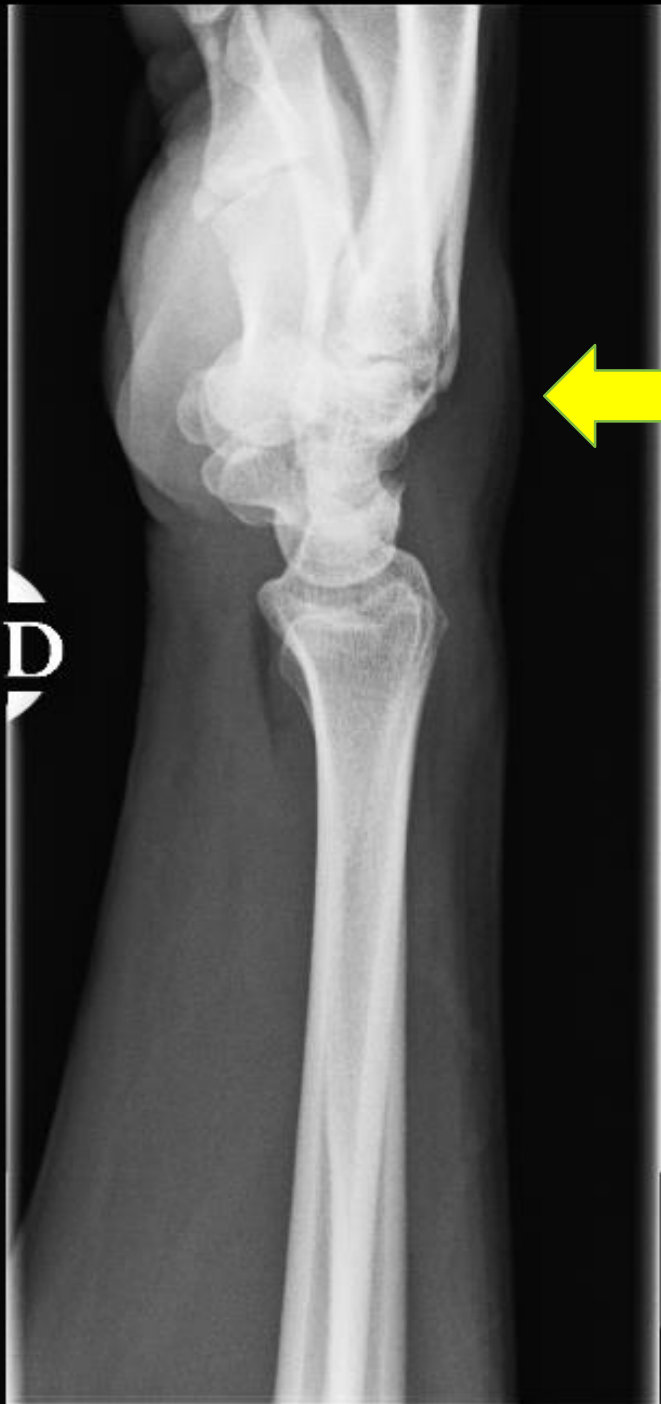
Suspicion de PR  
débutante

A – Tissus mous?

B – Erosion?

C – Chondrolyse?

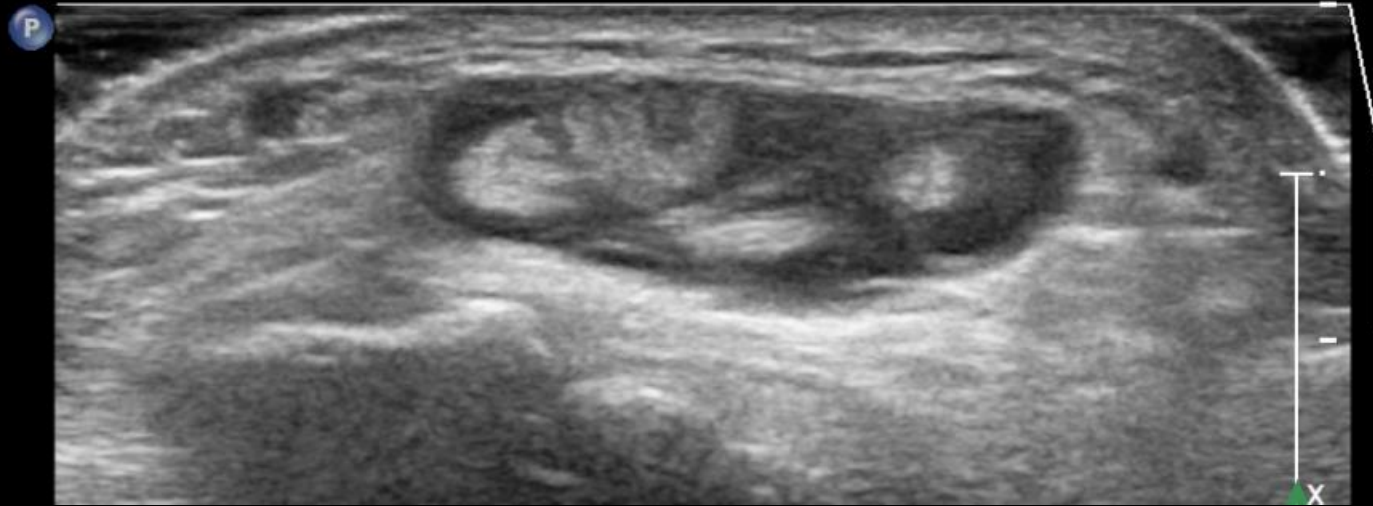


Suspicion de PR  
débutante

- A – Tissus mous
- B – Erosion
- C – Chondrolyse

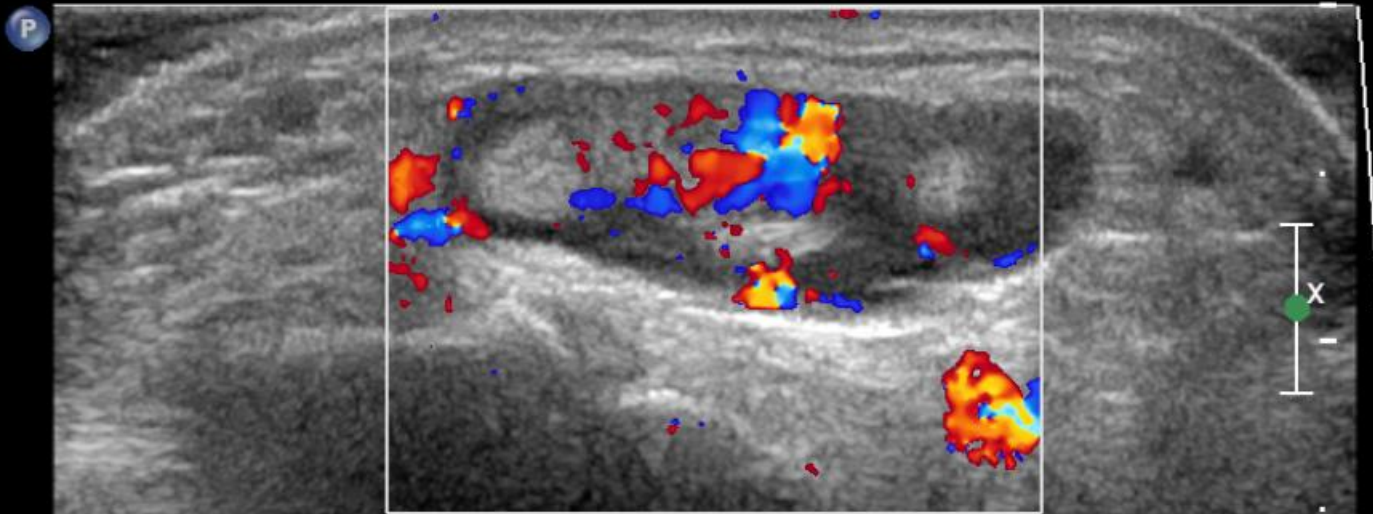
Face dorsale – plan axial – mode B

**2D**  
84%  
C 60  
P Moy  
Rés



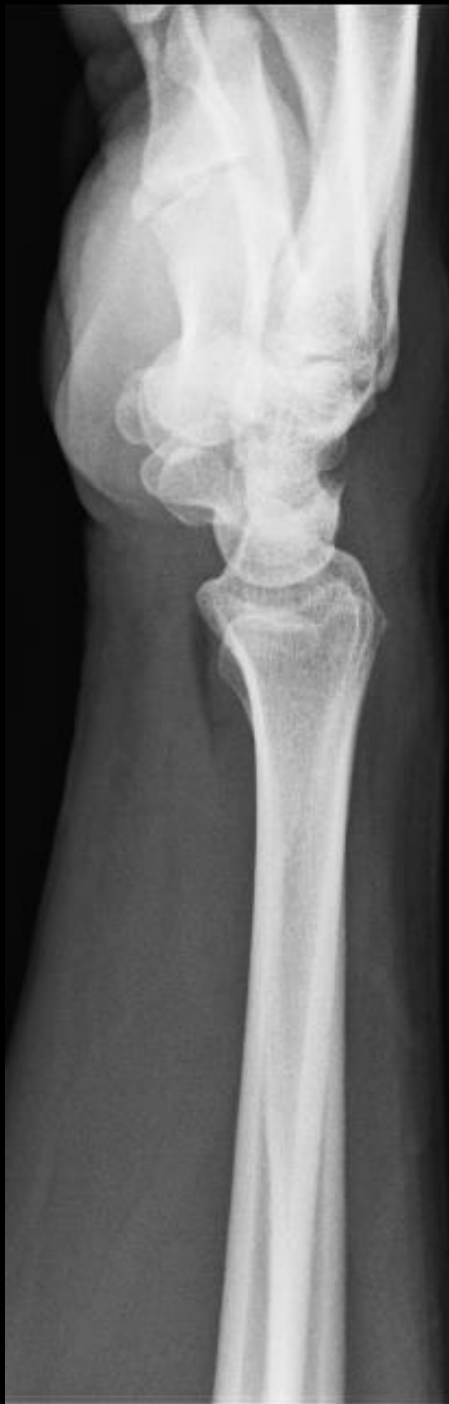**2D**  
87%  
C 60  
P Moy  
Rés

**Coul**  
75%  
541Hz  
FP 29Hz  
Bas



-2.3  
cm/s

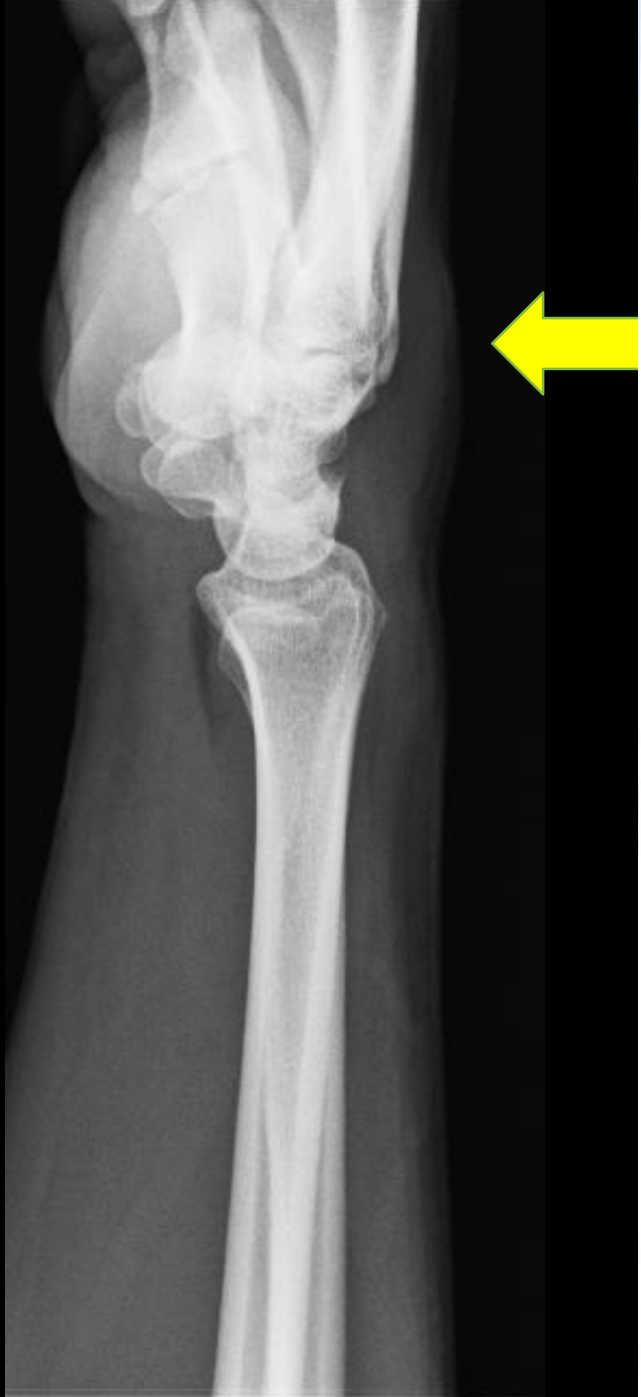Face dorsale – plan axial – mode Doppler couleur




Comment ne pas rater cette anomalie?

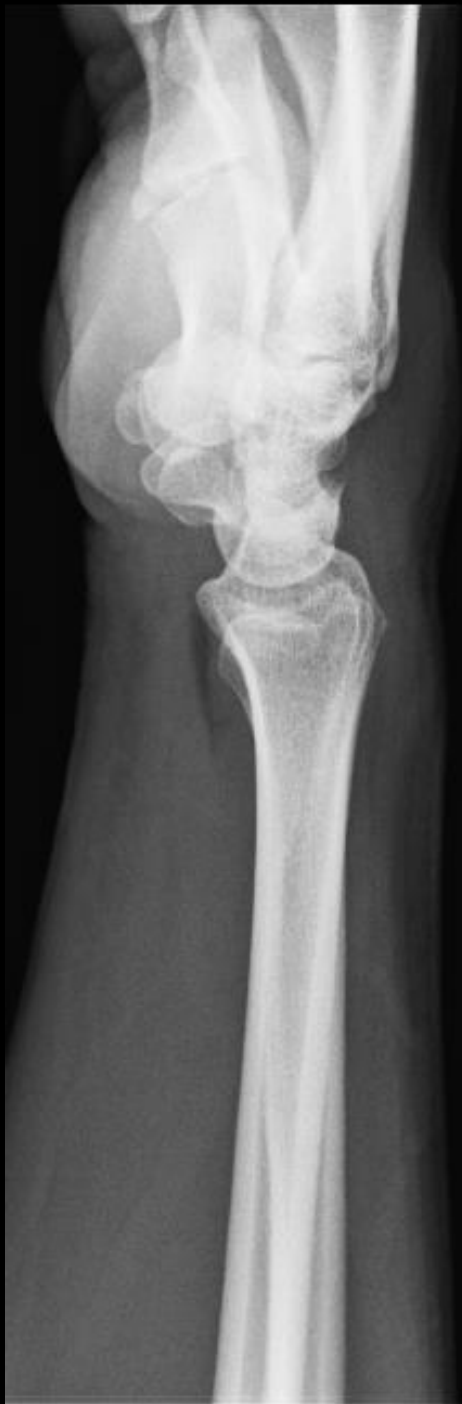
- A – Bien lire la demande d'examen
- B – Multiplier les incidences
- C – Autre





		DEPARTEMENT D'IMAGERIE MEDICALE 10 avenue ... <b>DEMANDE D'</b>		2016
<b>SERVICE PRESCRIPTEUR :</b>  <b>CACHET DU MEDECIN PRESCRIPTEUR</b> Nom : _____ Prénom : _____ N° INAMI : _____ Adresse : _____ ou Bip : _____		<b>IDEN</b> Nom _____ Prénom _____ Date _____ Numéro _____ Sexe : <input type="checkbox"/> Masculin <input type="checkbox"/> Féminin <b>Transport :</b> Volontariat : <input type="checkbox"/> ambulat <input type="checkbox"/> chaise Brancardier : <input type="checkbox"/> chaise + perfusion <input type="checkbox"/> lit <input type="checkbox"/> oxygène <input type="checkbox"/> pompe <input type="checkbox"/> A faire en chambre		
<b>INFORMATIONS OBLIGATOIRES (Annexe 82 - art. 17 et 17bis NPS)</b>				
<b>EXAMEN PROPOSE :</b> <i>Rx main - gauche</i> Informations cliniques pertinentes et explications de la demande de diagnostic <div style="text-align: center; font-size: 2em; margin-top: 10px;"><i>polyarthrite</i></div>				
RENDEZ-VOUS PREVU LE : _____				
<b>Examen(s) pertinent(s) précédent(s) relatif(s) à la demande de diagnostic :</b> <input type="checkbox"/> CT <input type="checkbox"/> IRM <input type="checkbox"/> ECHO <input type="checkbox"/> RX <input type="checkbox"/> AUTRES : _____ <input type="checkbox"/> INCONNU				
<b>Principales observations :</b>  <div style="text-align: right; font-size: 0.8em;">Joindre CD et/ou compte-rendu</div>				
<b>Informations supplémentaires pertinentes :</b> <input type="checkbox"/> GROSSESSE <input type="checkbox"/> ALLAITEMENT <input type="checkbox"/> DIABETE <input type="checkbox"/> IMPLANT <input type="checkbox"/> INSUFFISANCE RENALE <input type="checkbox"/> ALLERGIE <input type="checkbox"/> AUTRES				
<b>Pour tous les examens nécessitant une injection de produit de contraste :</b> <input type="checkbox"/> CREATININE : _____ <input type="checkbox"/> FILTRATION GLOMERULAIRE : _____ <input type="checkbox"/> ARRET DE LA MEDICATION ANTI-DIABETIQUE (glucophage, glucovance, metformine, metformax) 48h avant et après l'examen				

pour cette anomalie?  
 de d'examen  
 nces



Comment ne pas

A – Bien lire la den

B – Multiplier les inc

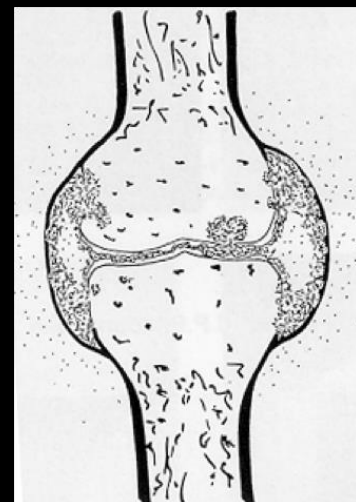
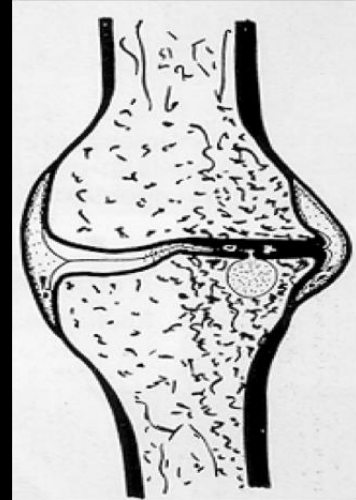
C – Autre




alie?

# TAKE HOME MESSAGE

- « Mécanique vs. Inflammatoire? »
- Arthrose : pincement focal
- Arthrite : érosions marginales
- Nombreux pièges
  - Interligne (technique, luxation...)
  - Erosion (inclusion synoviale, conflit mécanique...)





Gonflement inconstant	TISSUS MOUS	Gonflement fréquent
<b>Pincement focal</b>	INTERLIGNE ARTICULAIRE	<b>Pincement global</b>
Erosions Géodes Hyperostose	OS SOUS-CHONDRALE	Erosions Géodes
Ostéophytes	OS MARGINAL	<b>Erosions</b>

