

# **THORACIC TRAUMA**

## **(non-vascular)**

**Benoît Ghaye**  
**Cliniques Universitaires St Luc**

# THORACIC TRAUMA

- **TIME IS LIFE!**
- **Reach the correct diagnosis**
- **As soon as possible**
- **MDCT: 83% of additional lesions compared to Chest X-ray, requiring undelayed treatment**
- **Supine chest X-ray remains the most important initial test**
- **High sensitivity, low specificity (aortic lesion=15% of traumatic enlargement of mediastinum)**

*Wintermark and Schnyder 2003*

# THORACIC TRAUMA

- **Chest trauma: extrathoracic injuries in up to 80%**
- **Severe head trauma: 20% occult pneumothorax**  
**23% lung contusions**

# THORACIC TRAUMA

## Timing of MDCT in Lausanne (CHUV)

- Cerebral, cervical, thoracic and abdominal
- Average < 55 minutes
  - Transportation and installation: 18 min
  - CT data acquisition: 14 min
  - Data management (2-D, 3-D): 8 min
  - Radiologist interpretation: < 15 min

# THORACIC TRAUMA

- **Most frequent after head and neck injuries**
- **20% of trauma patients**
- **20% mortality**
- **Blunt, penetrating or mixed**
- **Aorta**
- **Lungs**
- **Heart**
- **Thoracic spine cord**

# THORACIC TRAUMA

## MDCT

- 2-D and 3-D are mandatory
  - **informations** for referring physicians
  - **diagnosis:**
    - flail chest, sternal and spine #
    - diaphragmatic rupture
    - tracheobronchial injuries
    - aortic injuries

# THORACIC TRAUMA

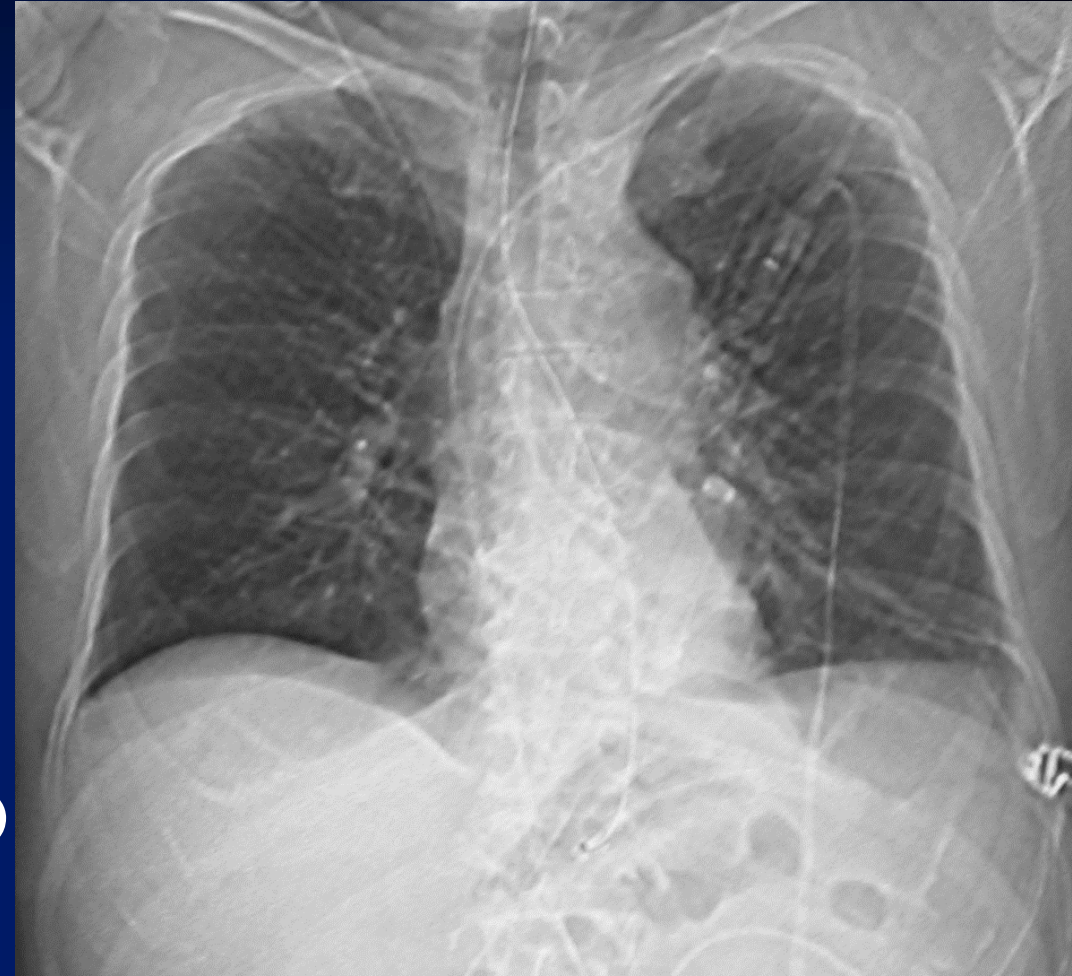## CT Technique

- **Position:** arms over the head whenever possible
- **Collimation:** 0.75 mm
- **Contrast medium:** 120 cc @ 3 cc/sec, SD 20 sec (trigger aorta)
- **Delayed acquisition** if active bleeding suspected (120 sec)
- **Slice reconstruction:** 1 / 0.7 mm, 5 / 5 mm
- **Kernel:** B 20 – B 50 (tissu mou – haute résolution spatiale)
- **Interpretation:** 1 mm
- **Reconstructions:**
  - VRT on bone systematically
  - 2D sagittal and coronal MPR on sternum and spine
  - 2D oblique MPR or VRT on aorta systematically
  - *2D oblique MPR or VRT on airways*

# Acute Traumatic Aortic Injuries

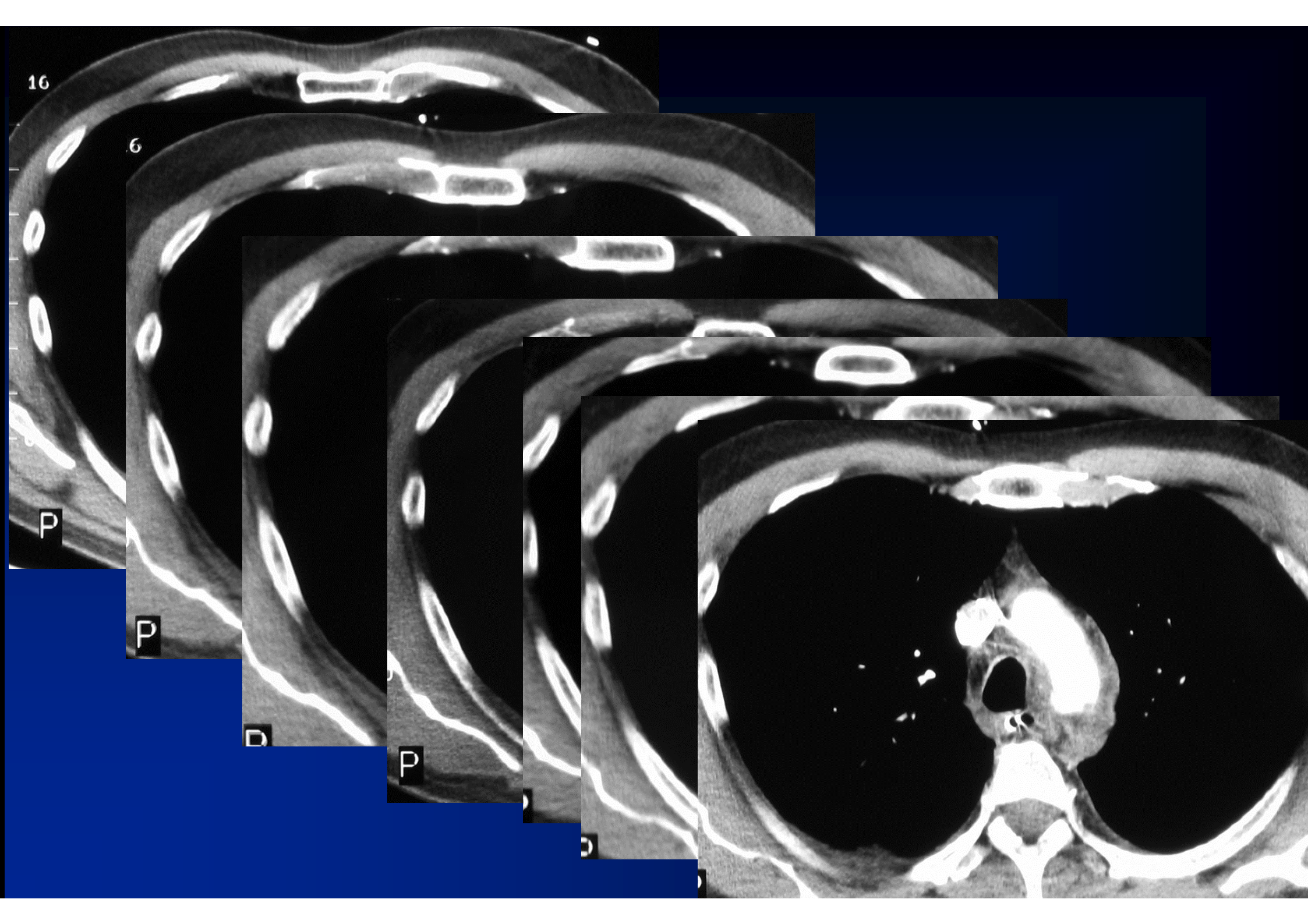
## Chest X-ray

- 90% sens, 25% spec, 95% NPV
- Widening of superior mediastinum
- Obscuration of aortic arch
- Abnormal aortic contour
- Loss of definition of AP window
- Caudal displacement of LM bronchus
- Rightward deviation of trachea
- Rightward displacement of NG tube
- Widening of paraspinal stripe (no spine #)
- Left apical cap and left pleural fluid



*Mirvis SE et al. Radiology 1987*





16

6

P

P

D

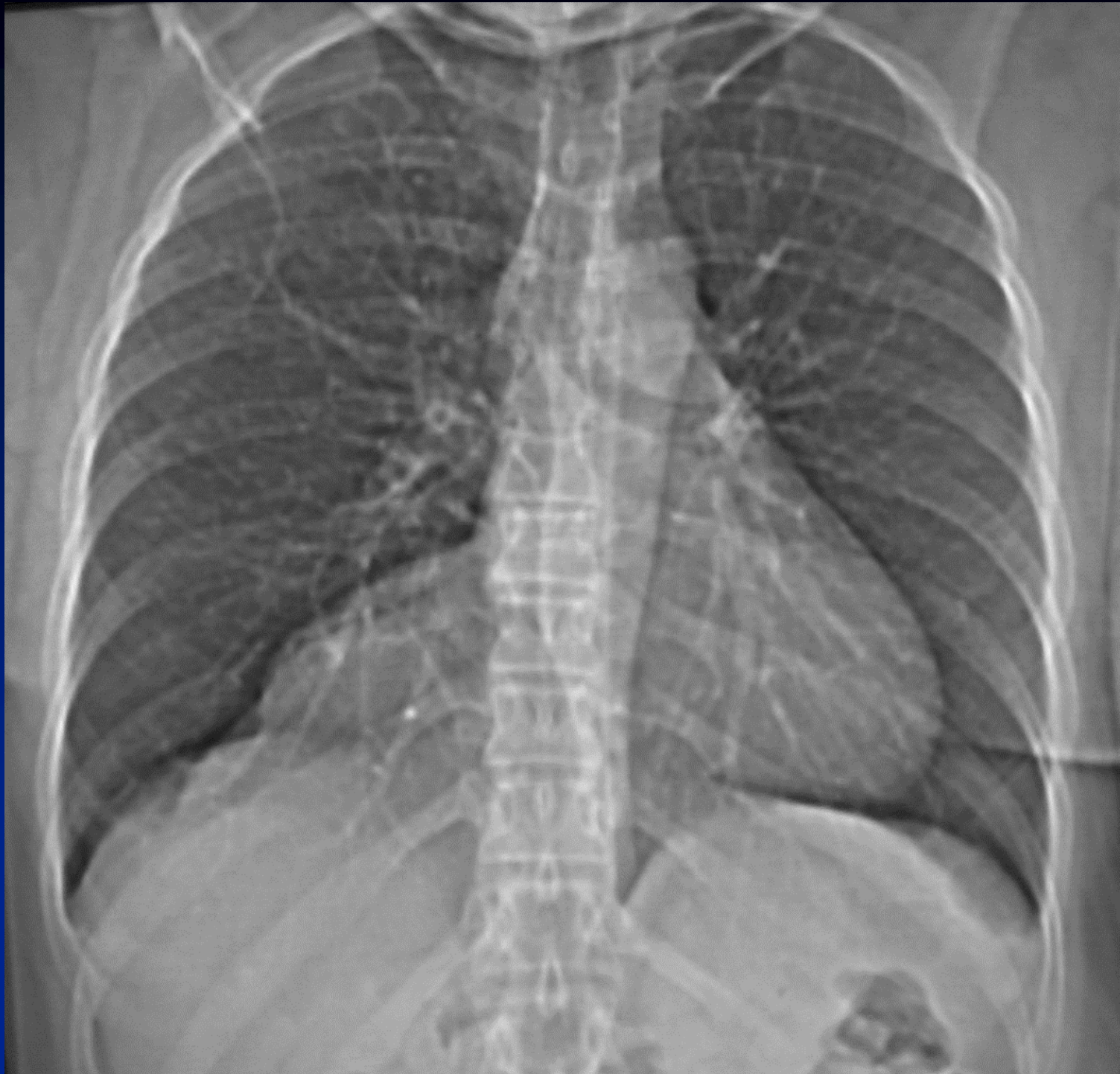P

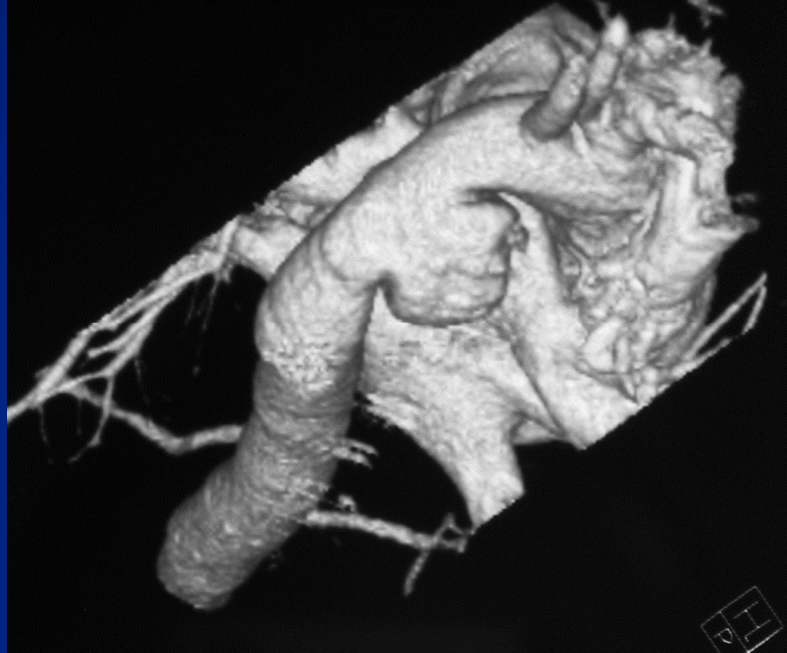
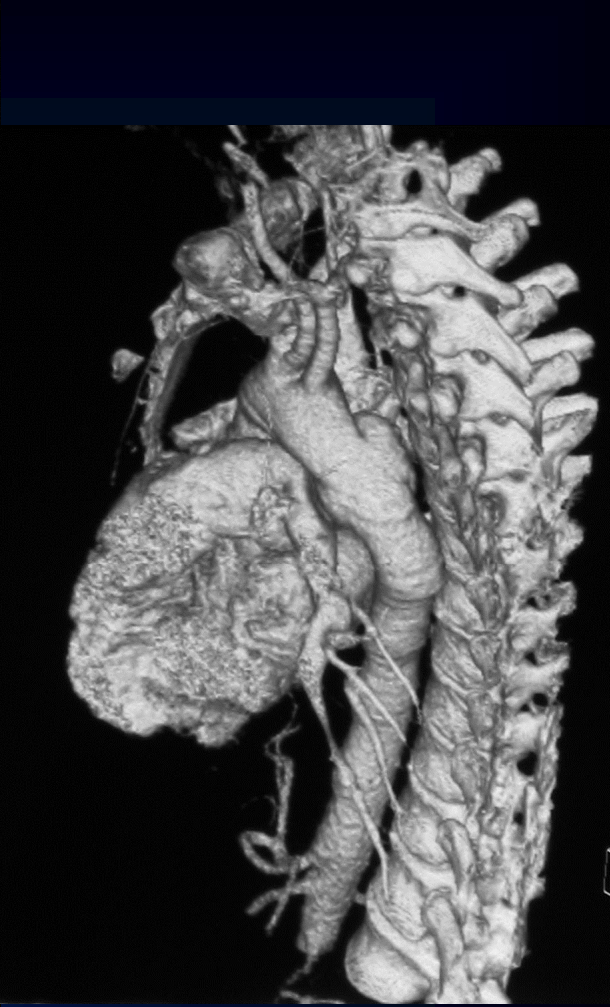
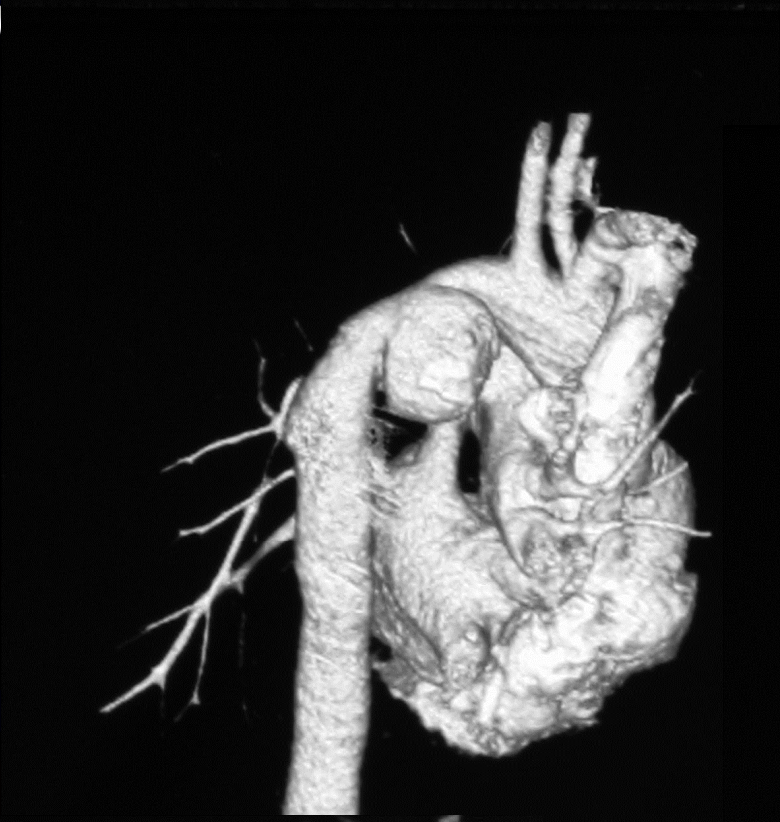
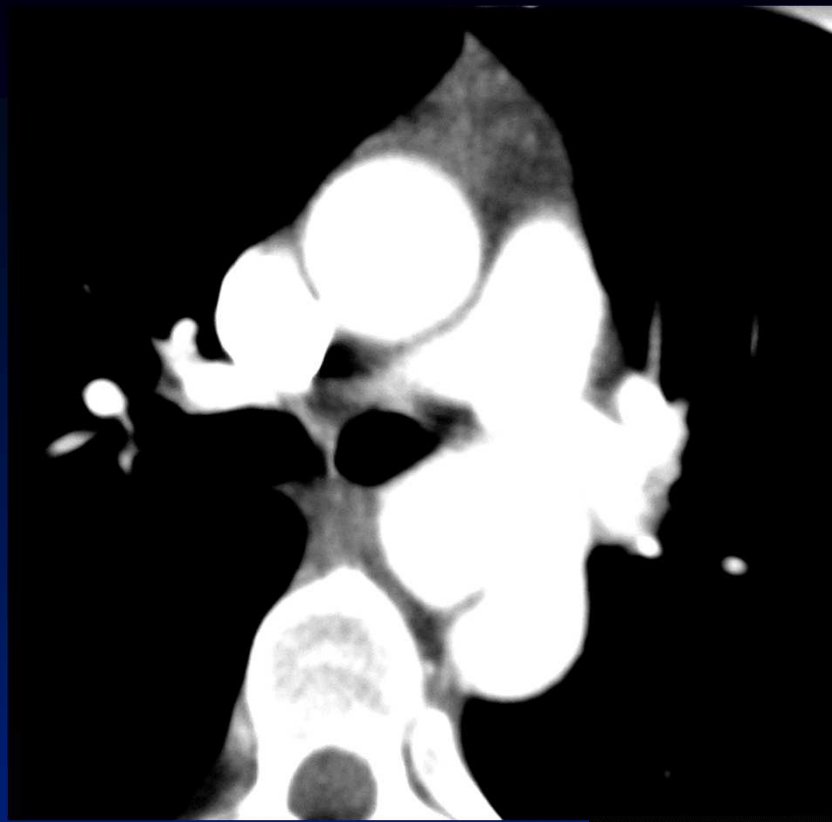
D

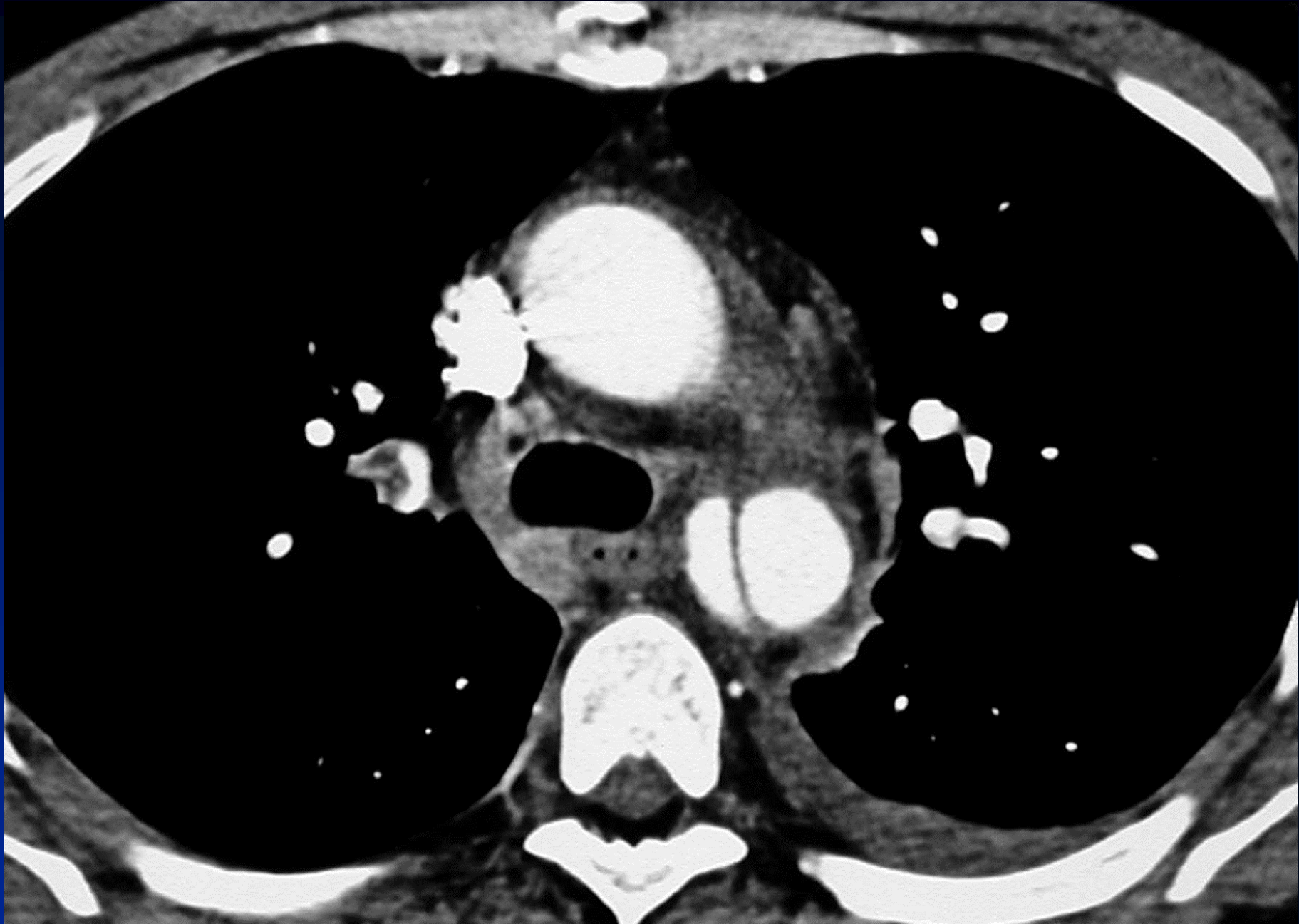
P

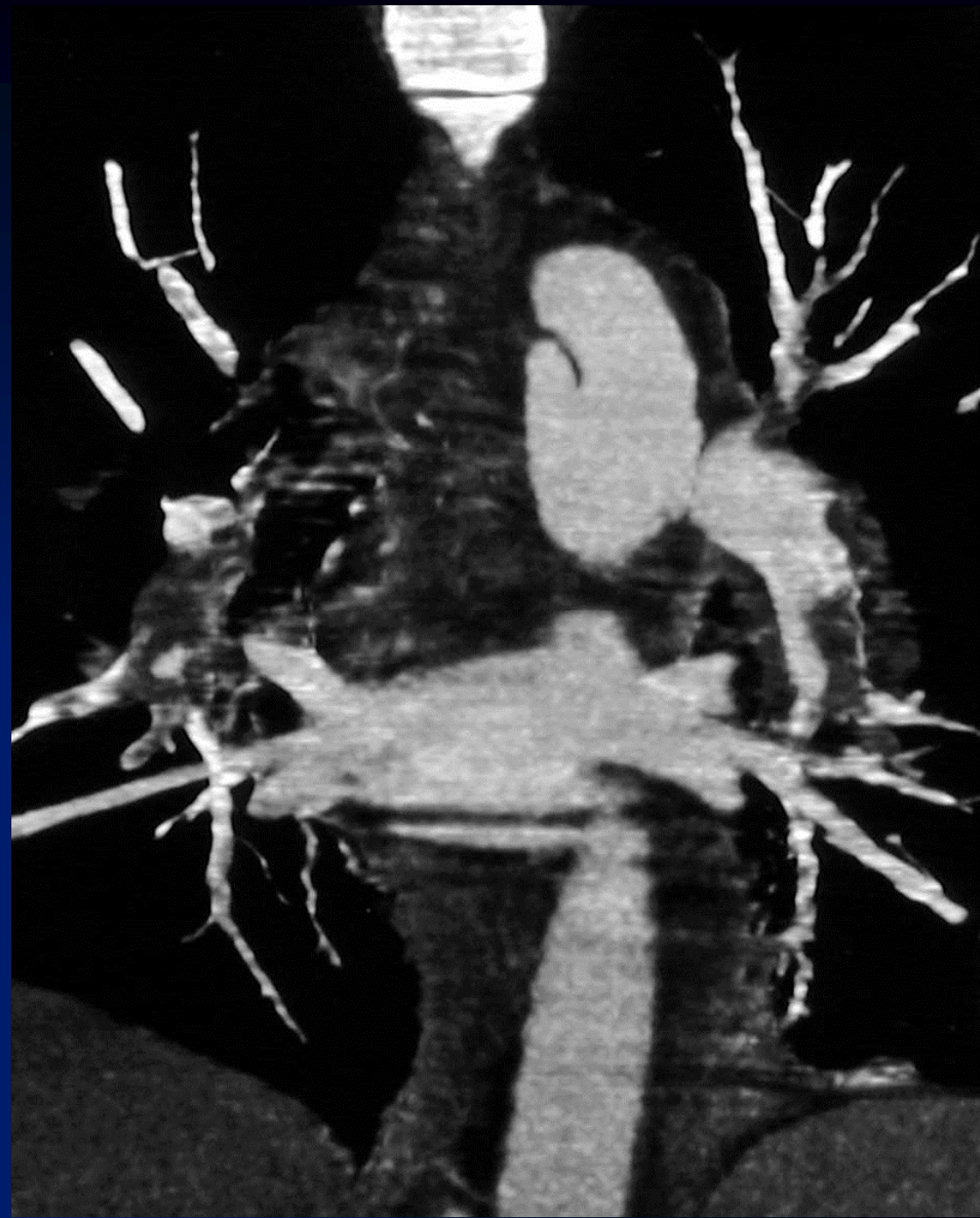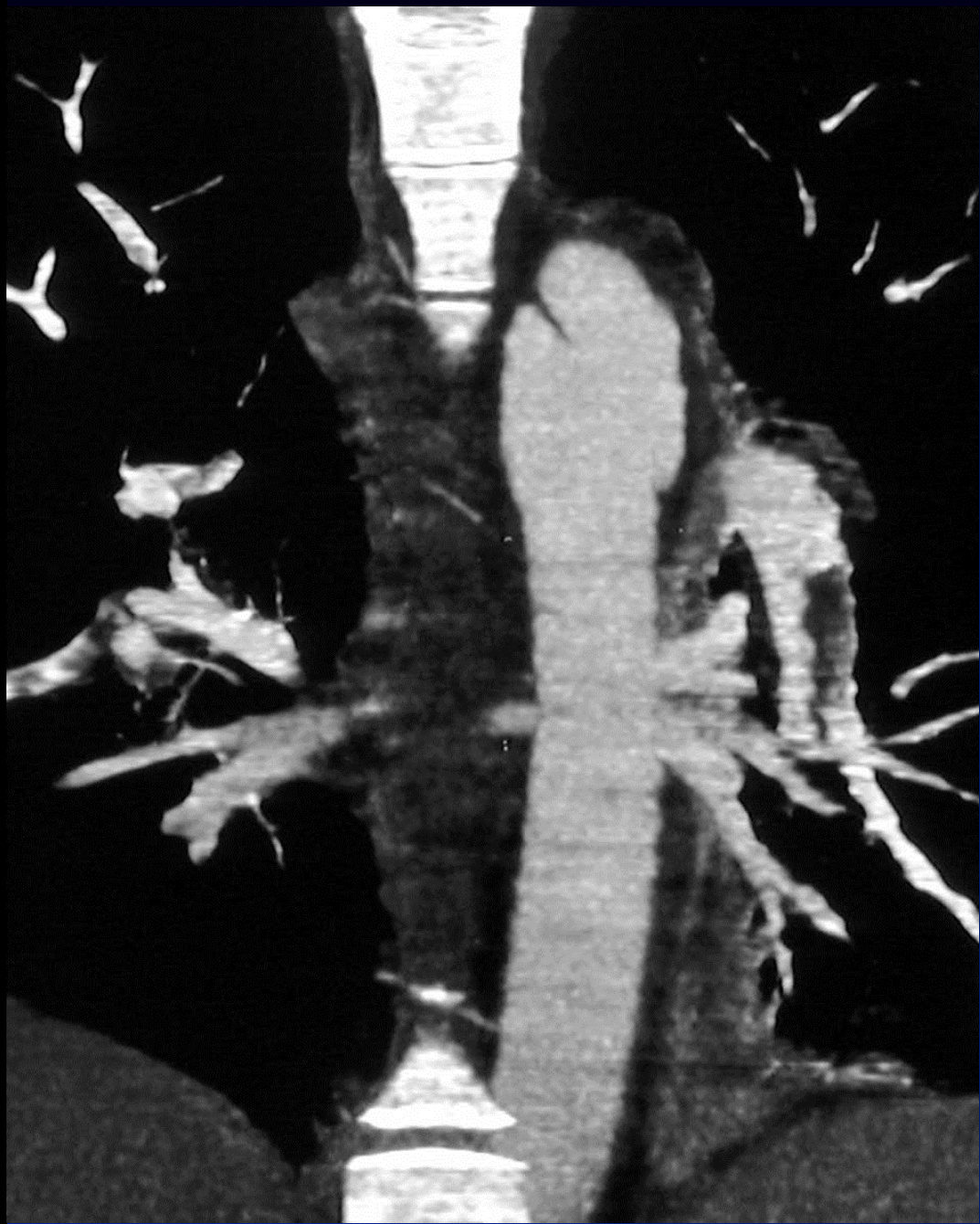# Acute Traumatic Aortic Injuries

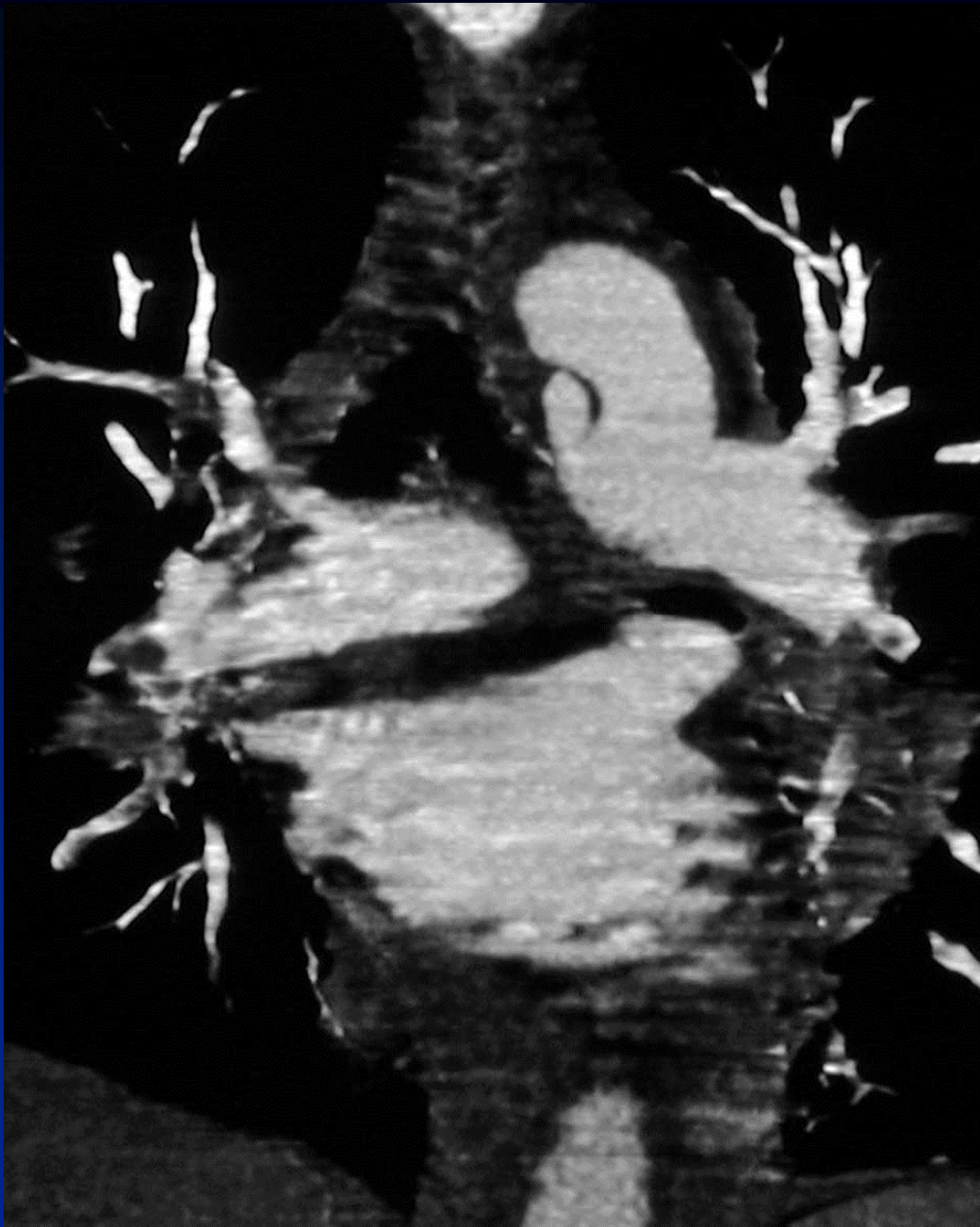
- **90%**      **Antero-medial aspect of isthmus**
- **7-8%**      **Ascending aorta above aortic valve**
  - **Aortic valve tears**
  - **Hemopericardium**
  - **Cardiac contusions or rupture**
  - **CA laceration**
- **2-3%**      **Descending aorta at the level diaphragm**
  - **10% with diaphragmatic ruptures**



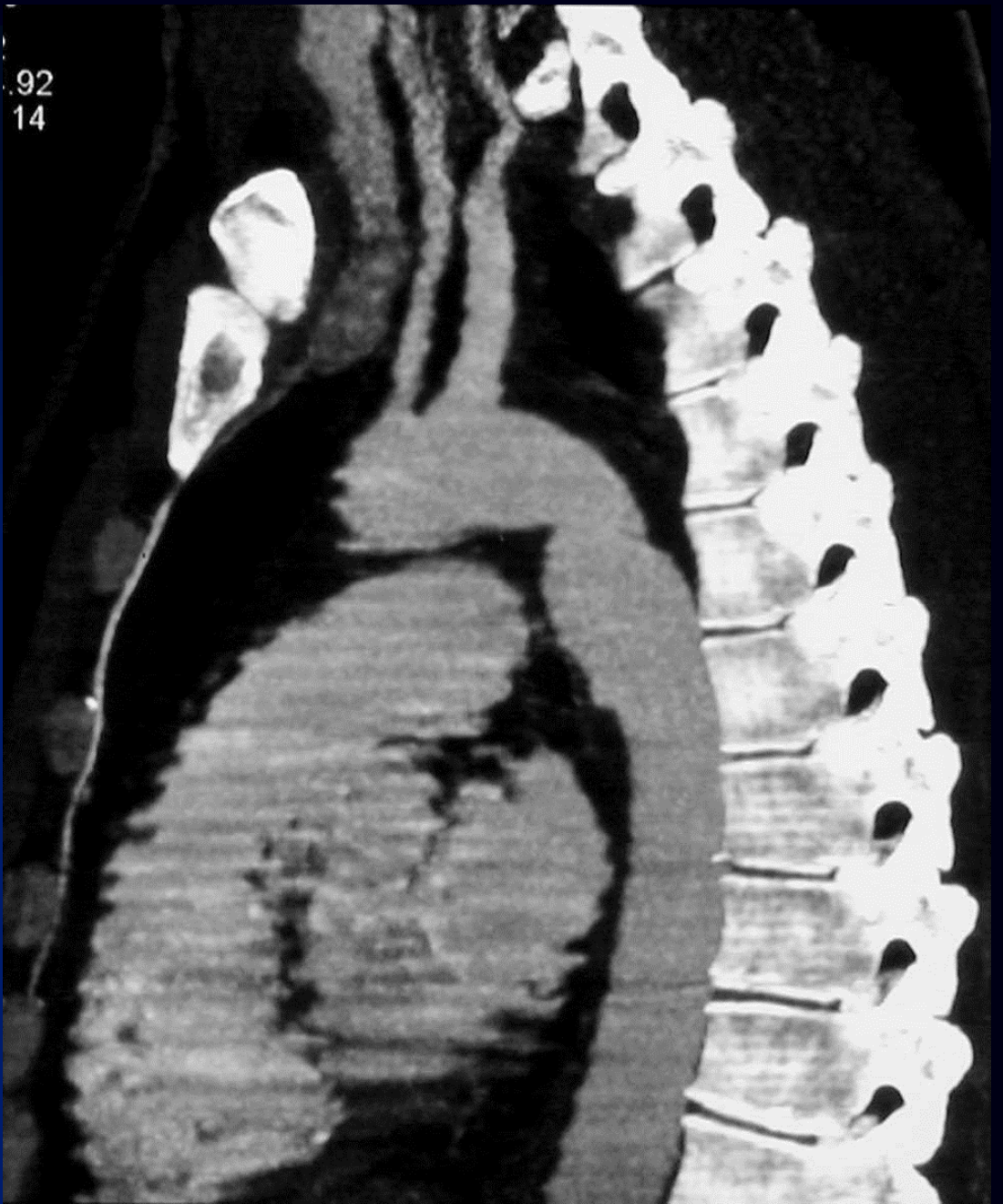


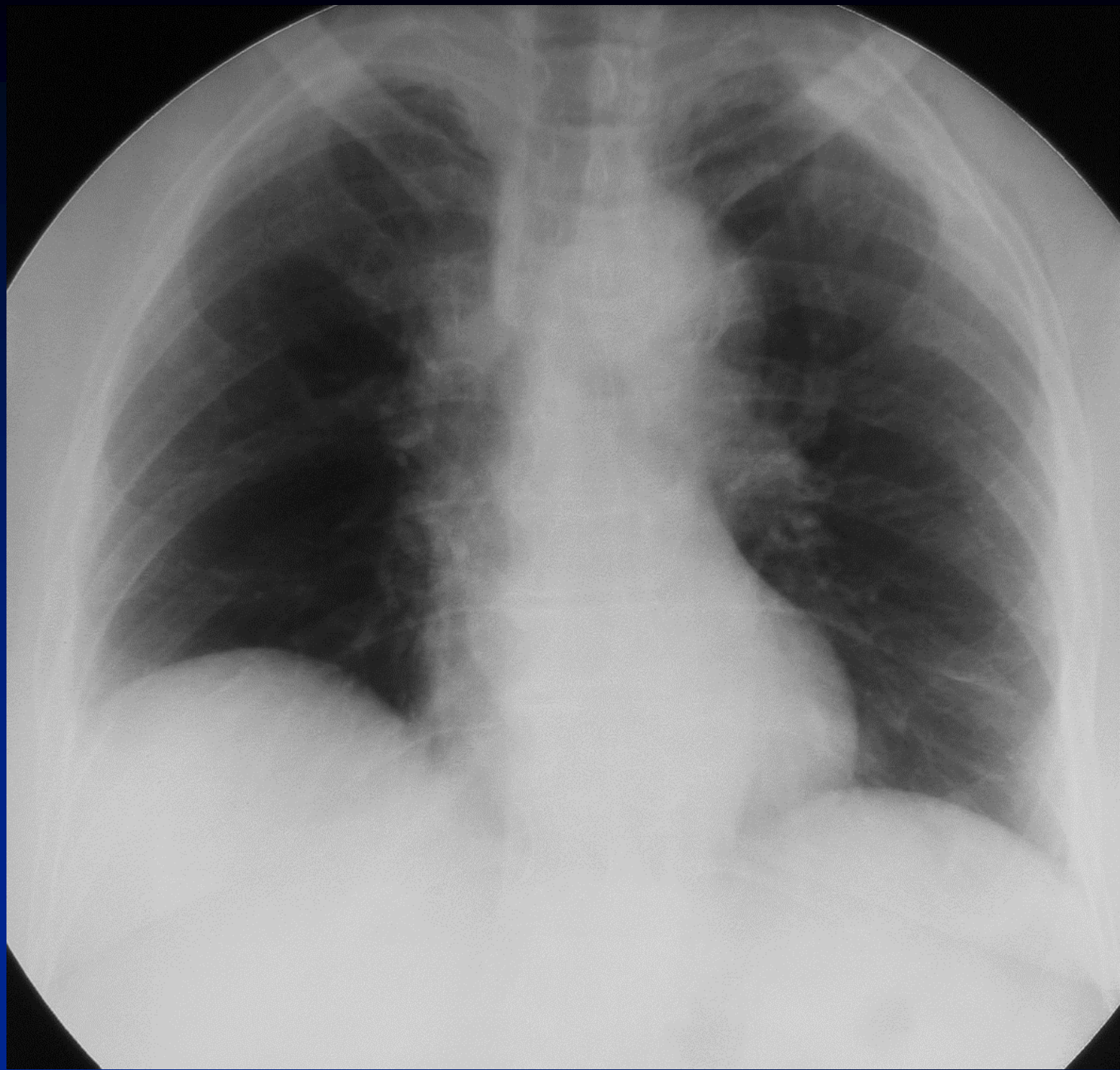




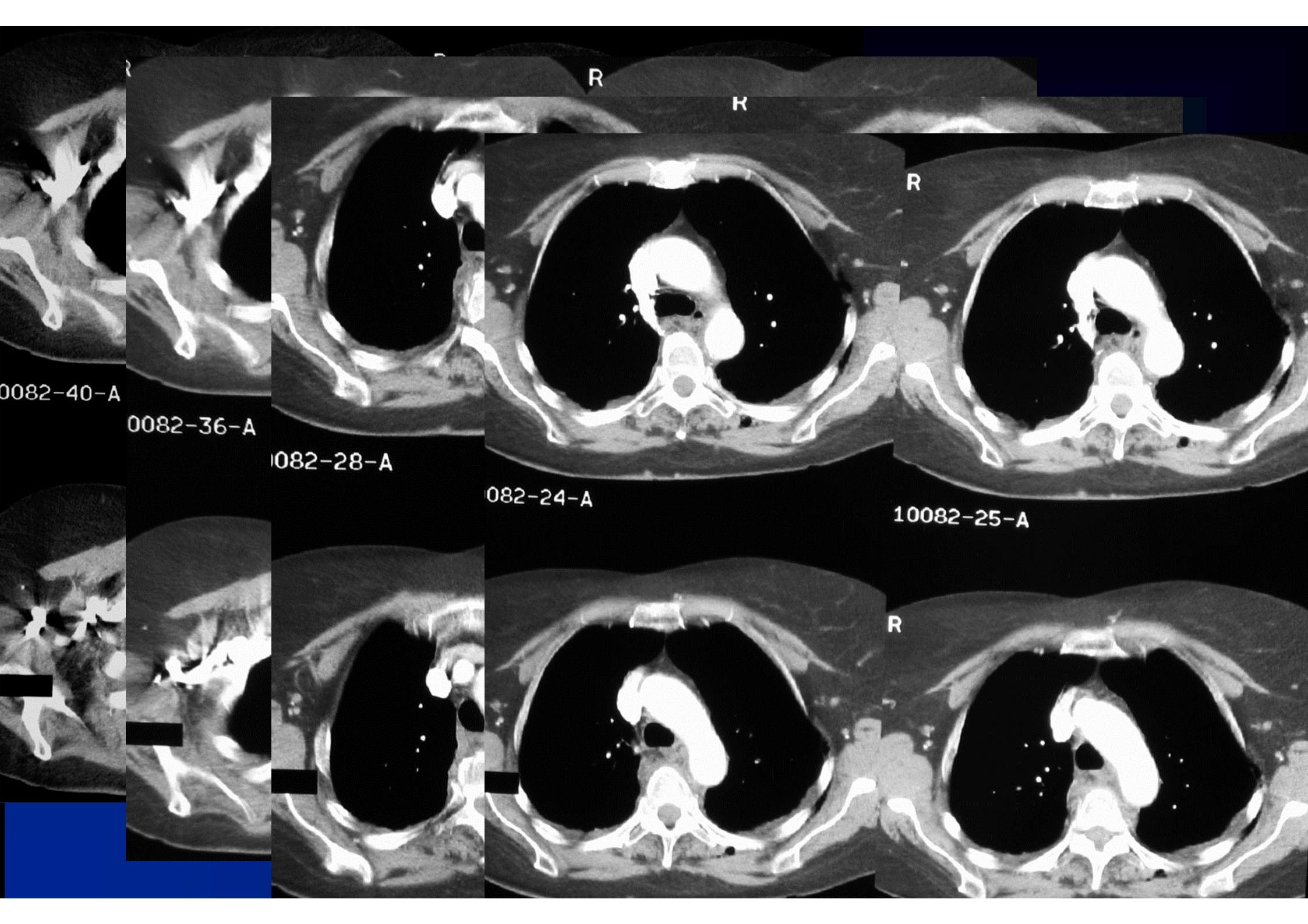


92  
14









0082-40-A

0082-36-A

0082-28-A

0082-24-A

10082-25-A

[Redacted]

[Redacted]

[Redacted]

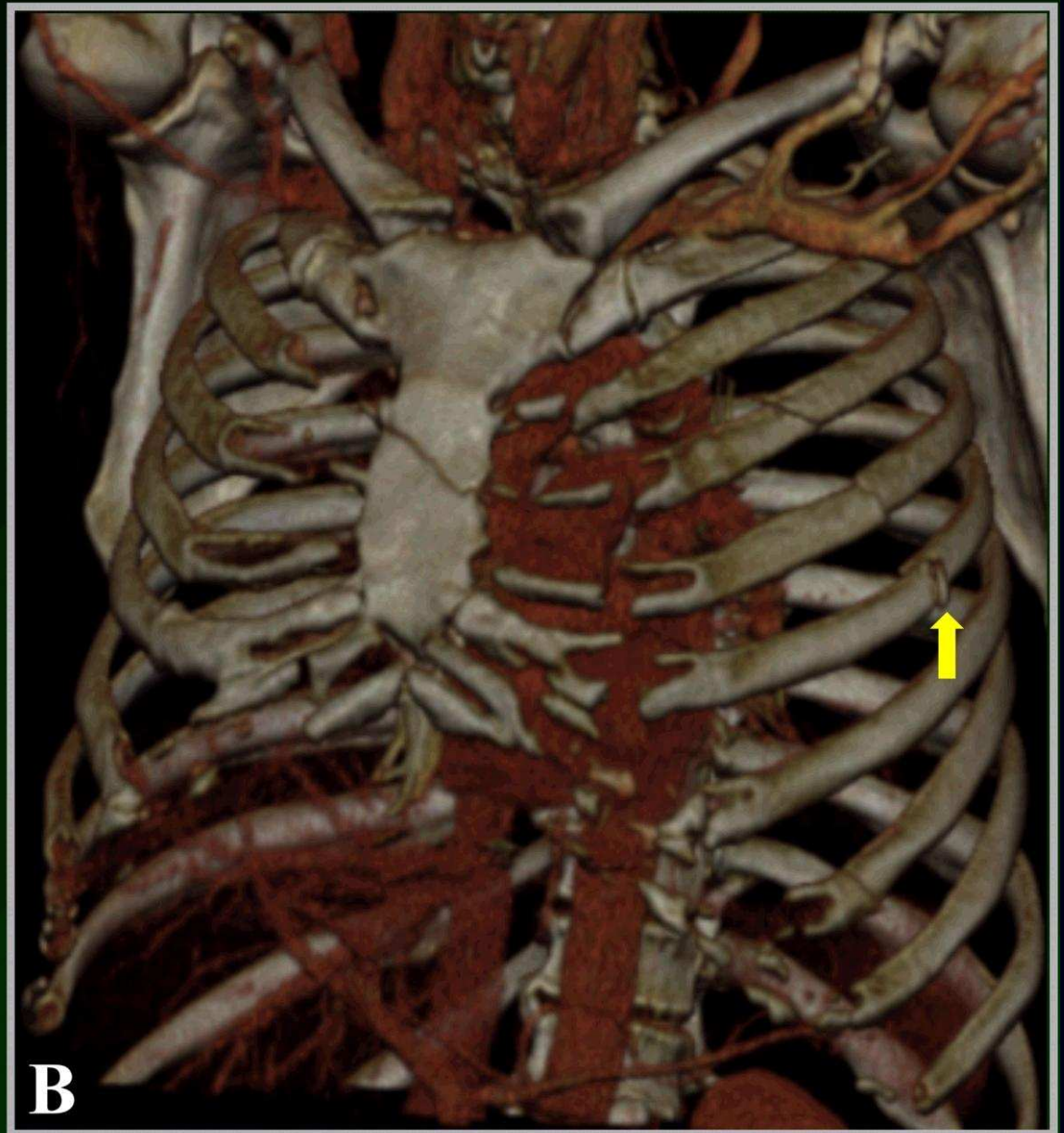
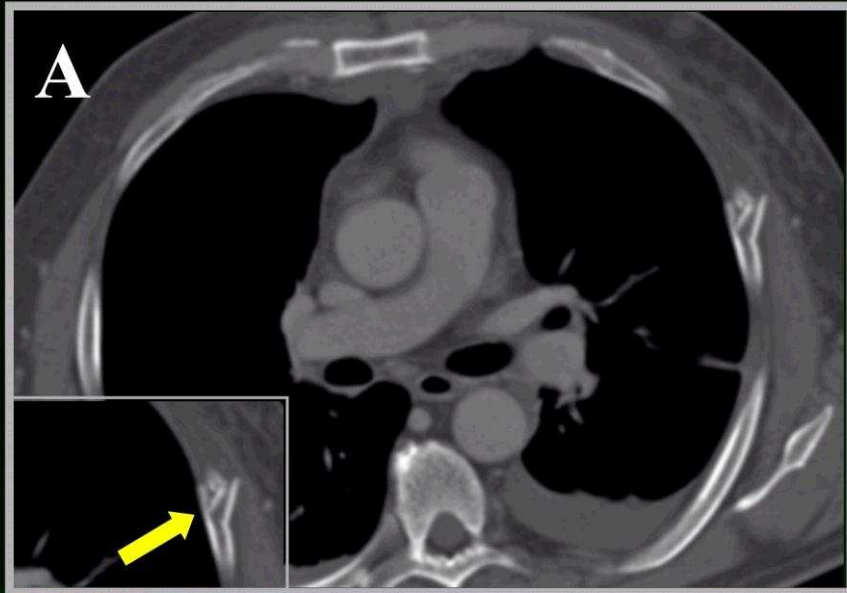
[Redacted]

R

# Osseous injuries

## Rib fractures

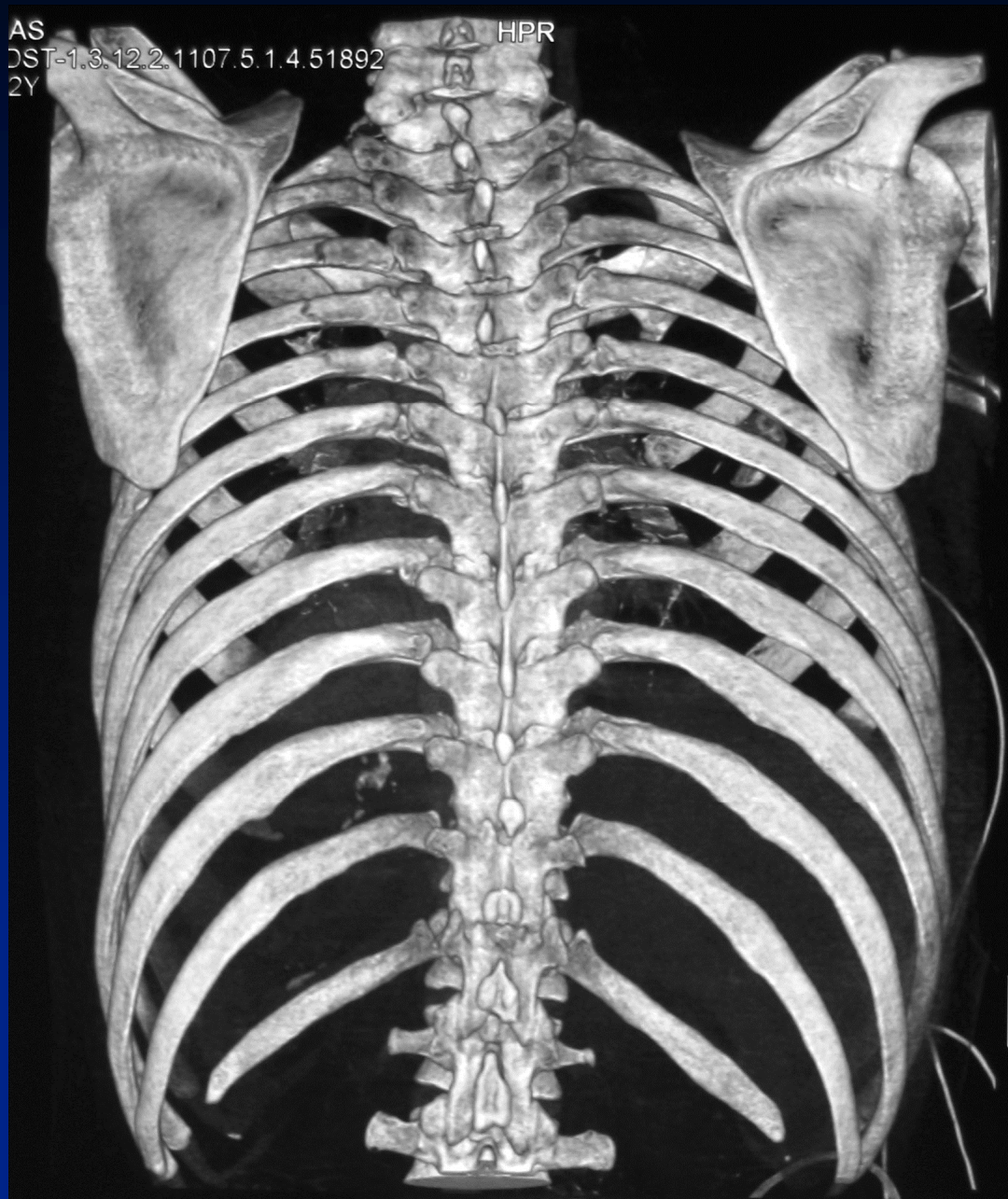- 50 % of blunt trauma
- Often undiagnosed at admission (nondisplaced, chondrosternal separation)
- **Complications:**
  - Hemothorax or extrapleural hematoma
  - Lung contusion or laceration
  - Pneumothorax and parietal emphysema
  - Flail chest

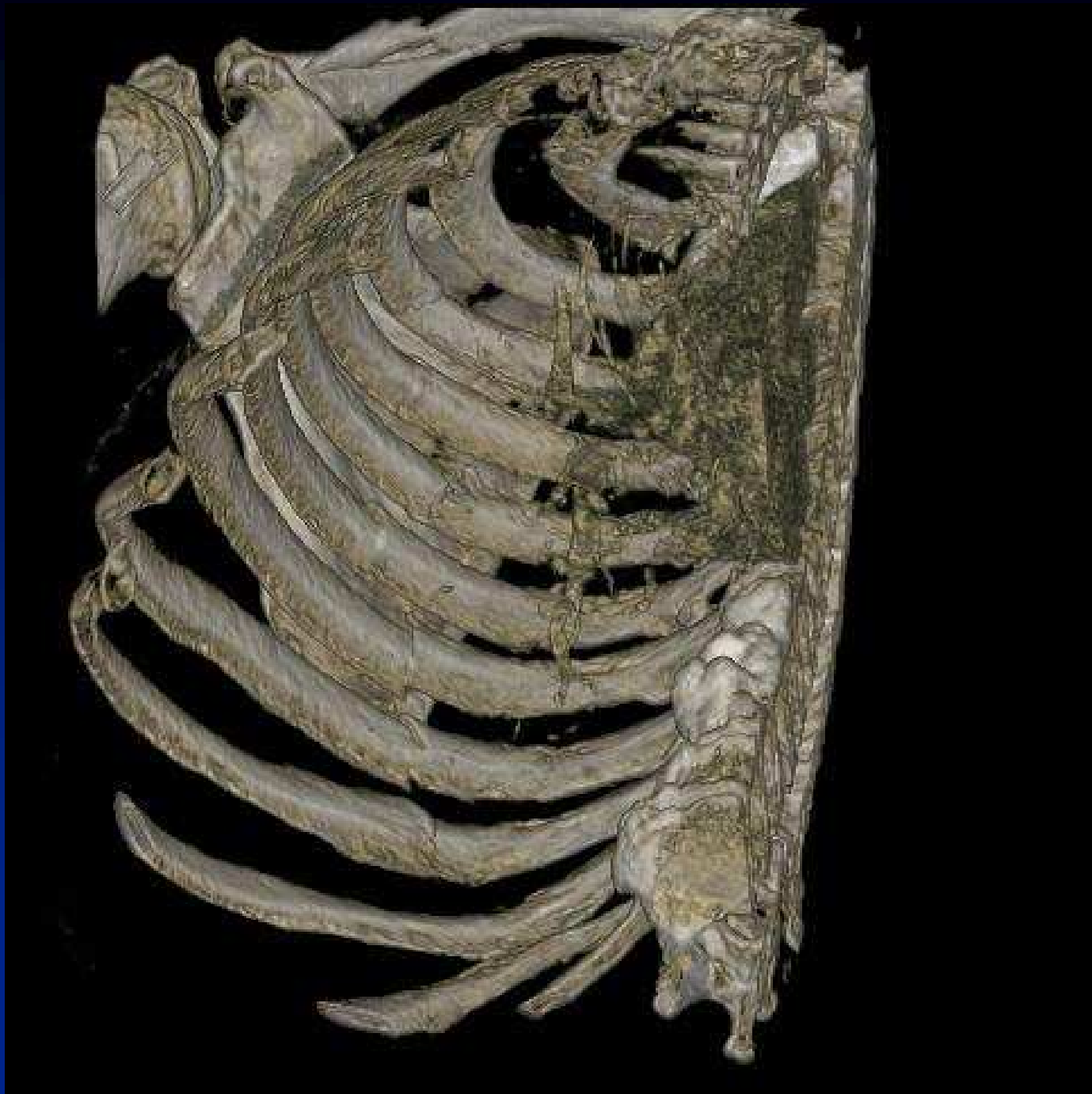


*Chavarri E et al. ECR 2004*

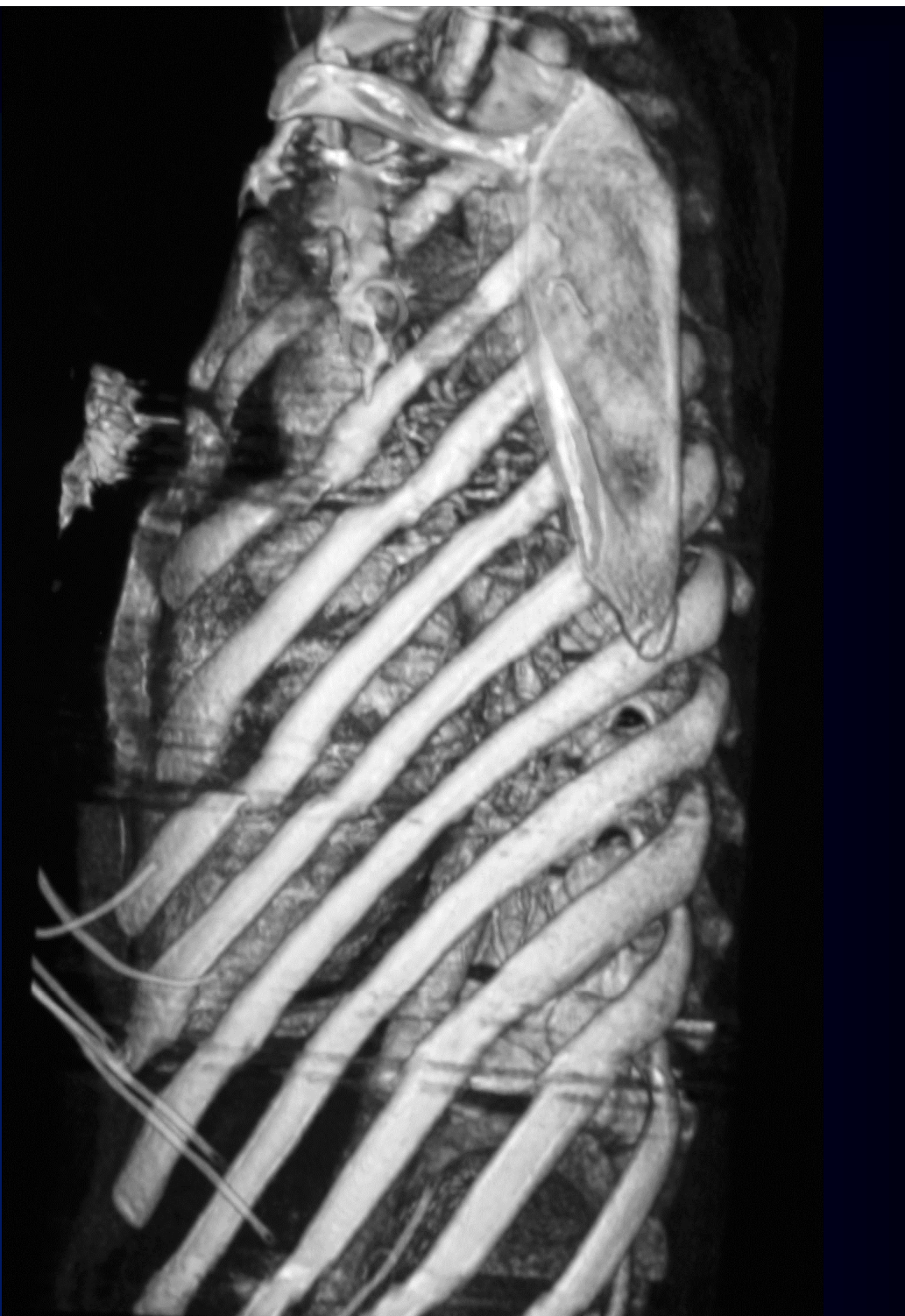
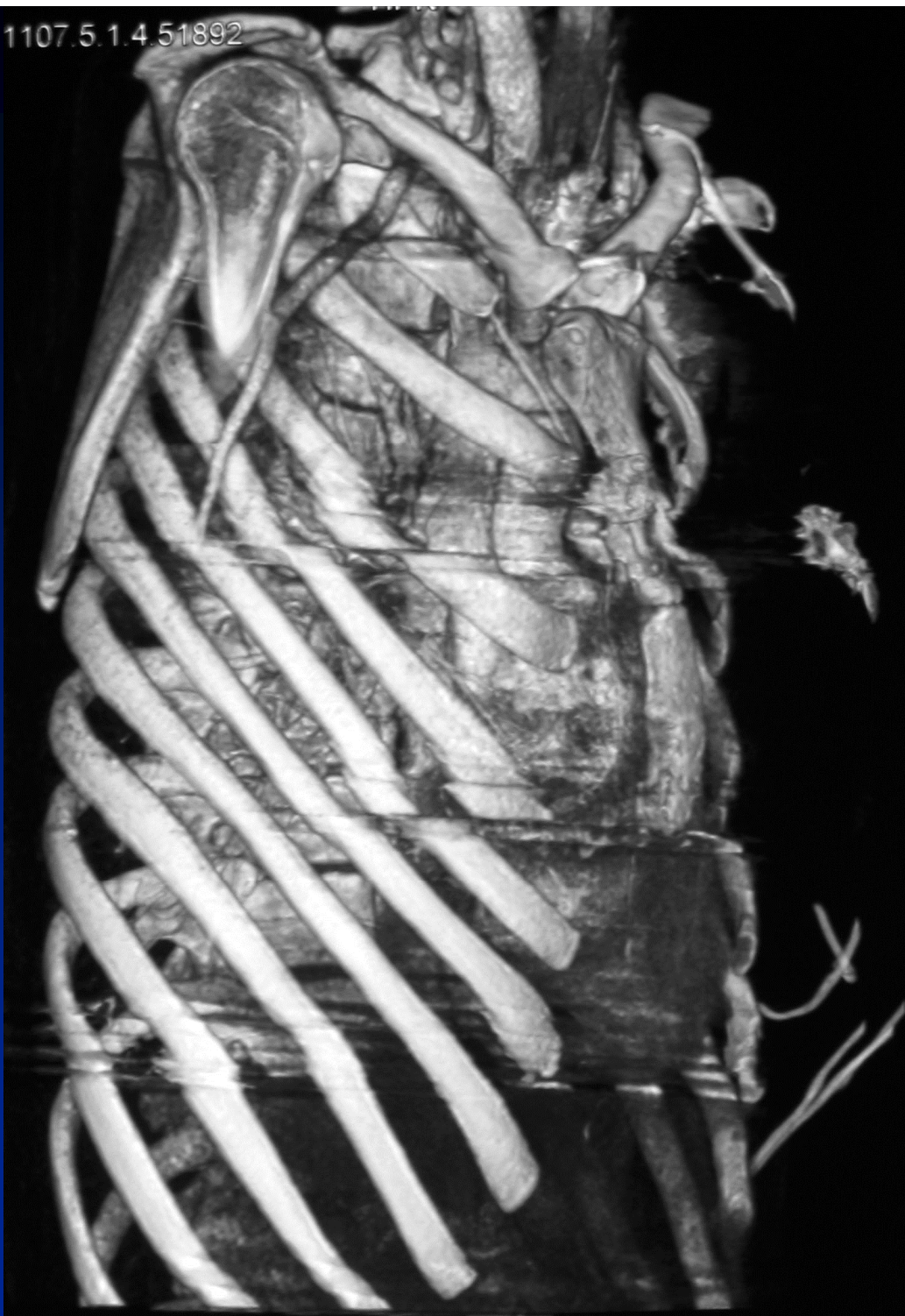
AS  
DST-1.3.12.2.1107.5.1.4.51892  
2Y

HPR





1107.5.1.4.51892

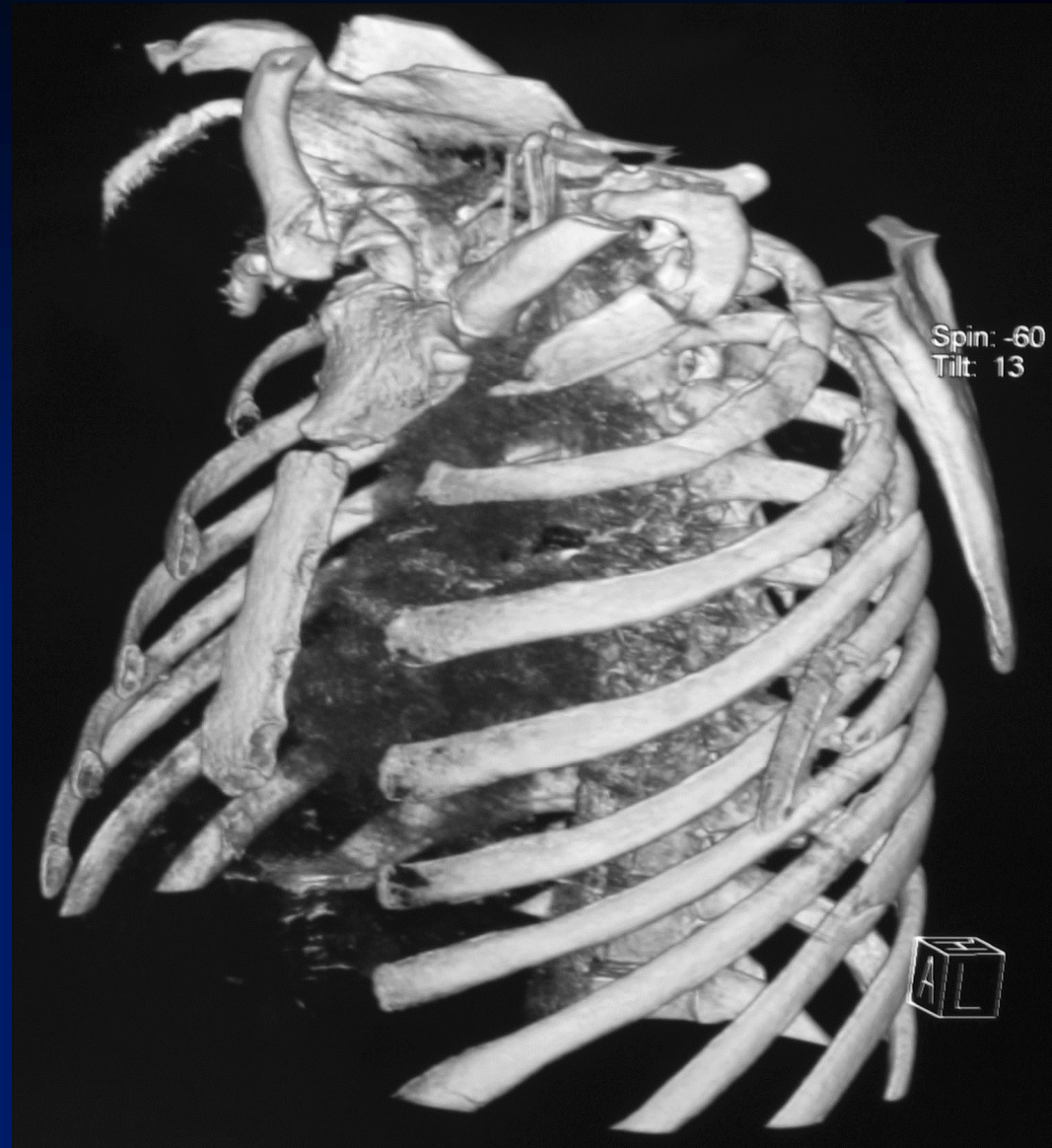
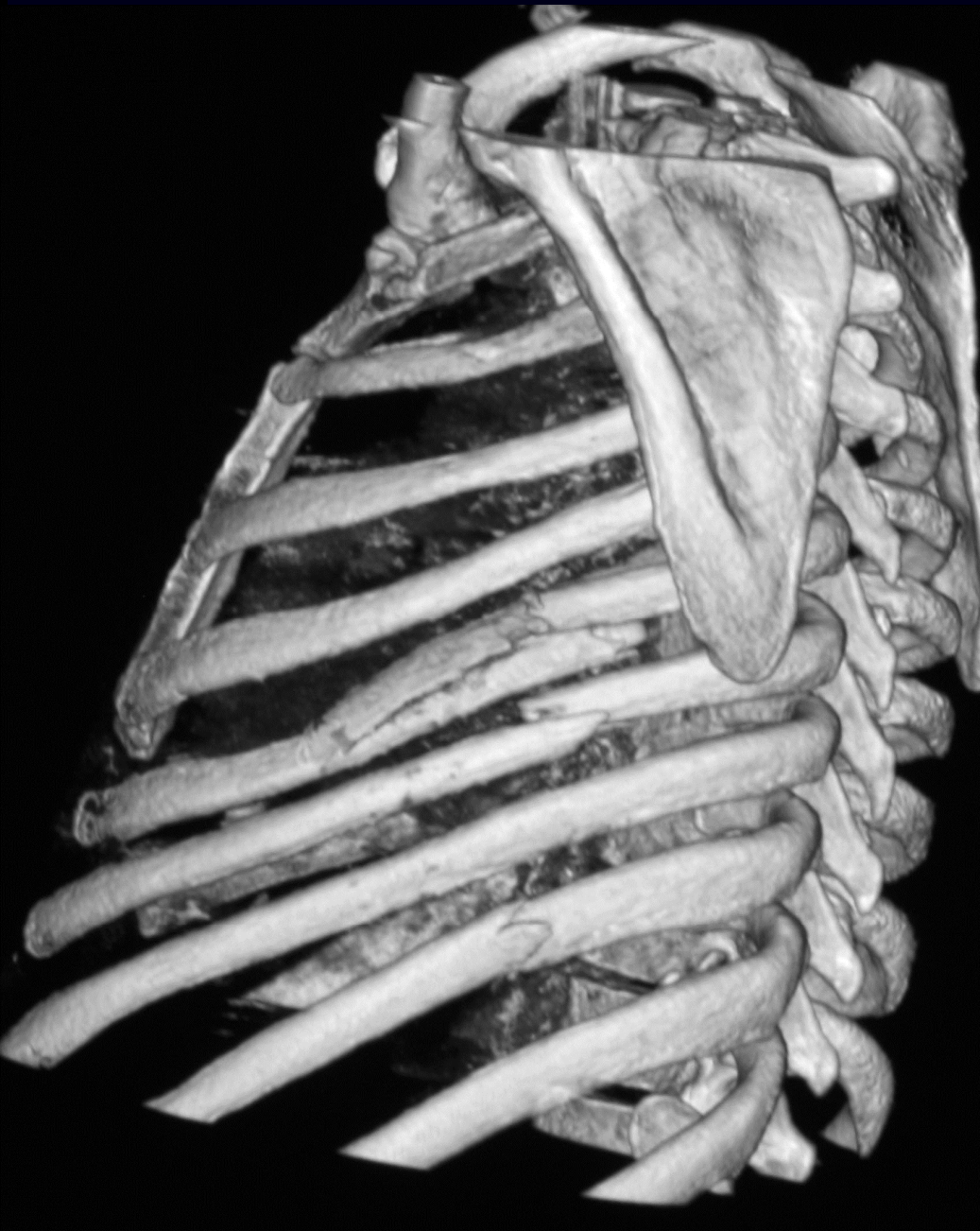


# Osseous Injuries

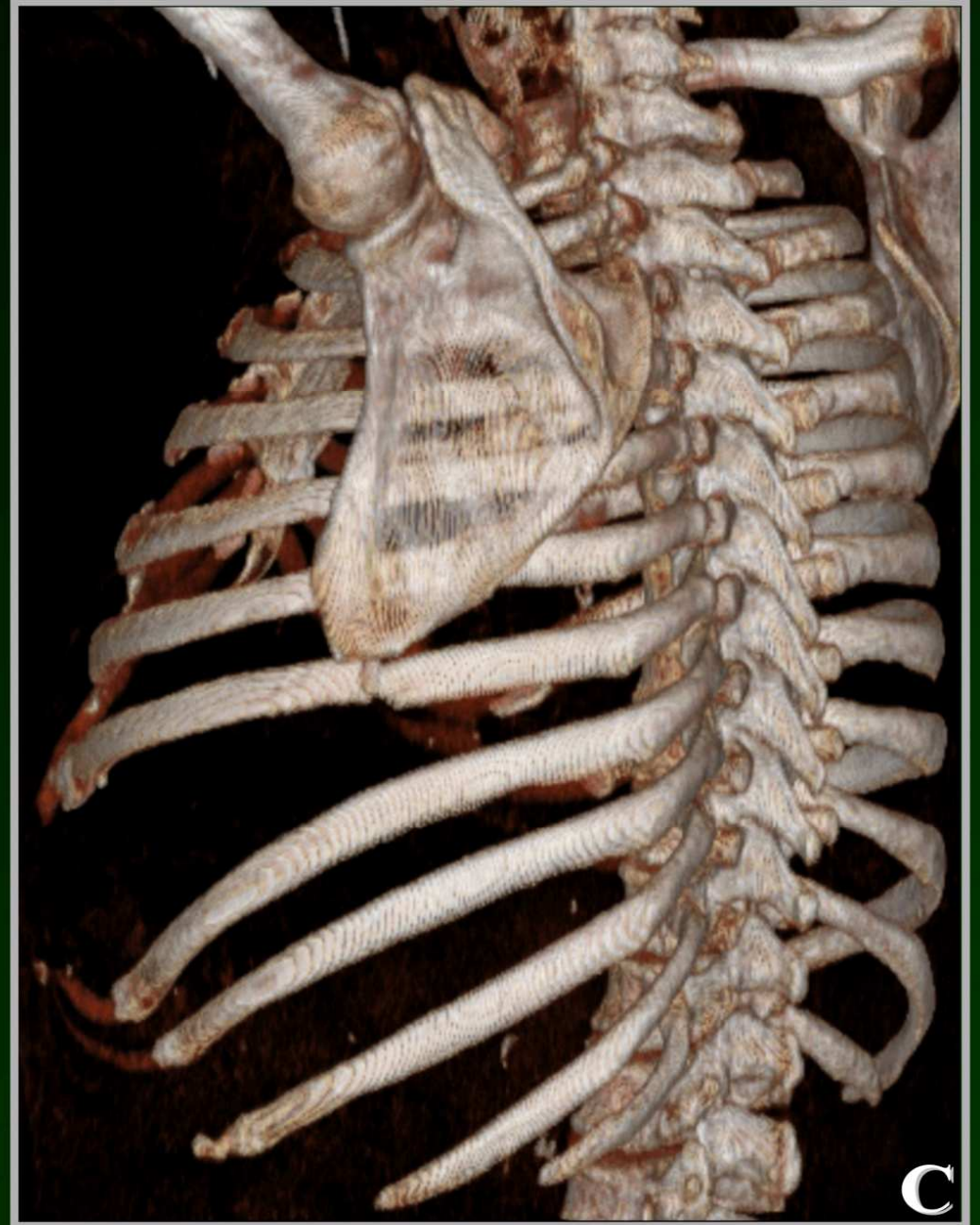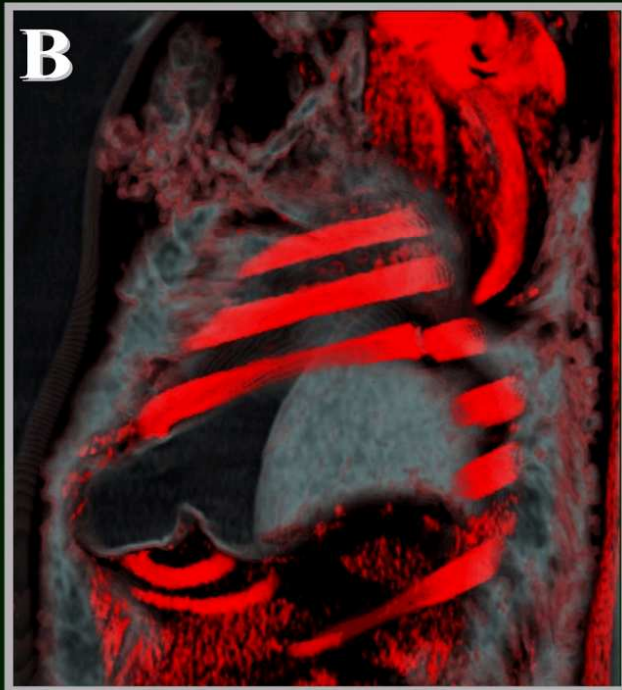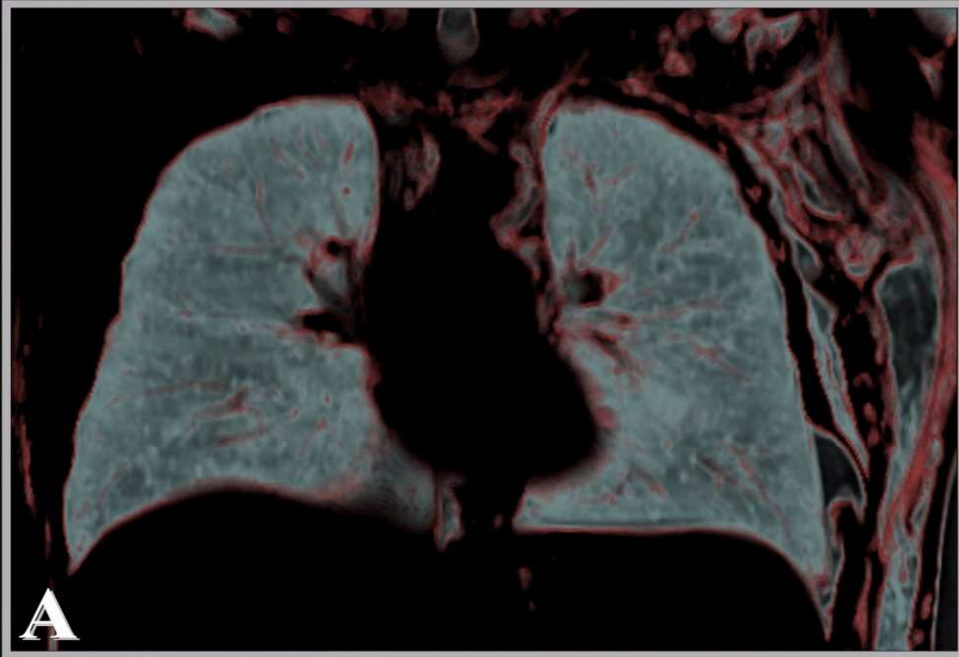
## Rib fractures

### Flail chest

- **>5 adjacent ribs # or >3 segmental ribs #**
- **Paradoxical move with respiration**
- **Respiratory failure**
- **Pendelluft**
- **At expiration, the flail hemithorax inhales**
- **Rebreathing of the same air**
- **Mechanical ventilation**







*Chavarri E et al. ECR 2004*

# Osseous injuries

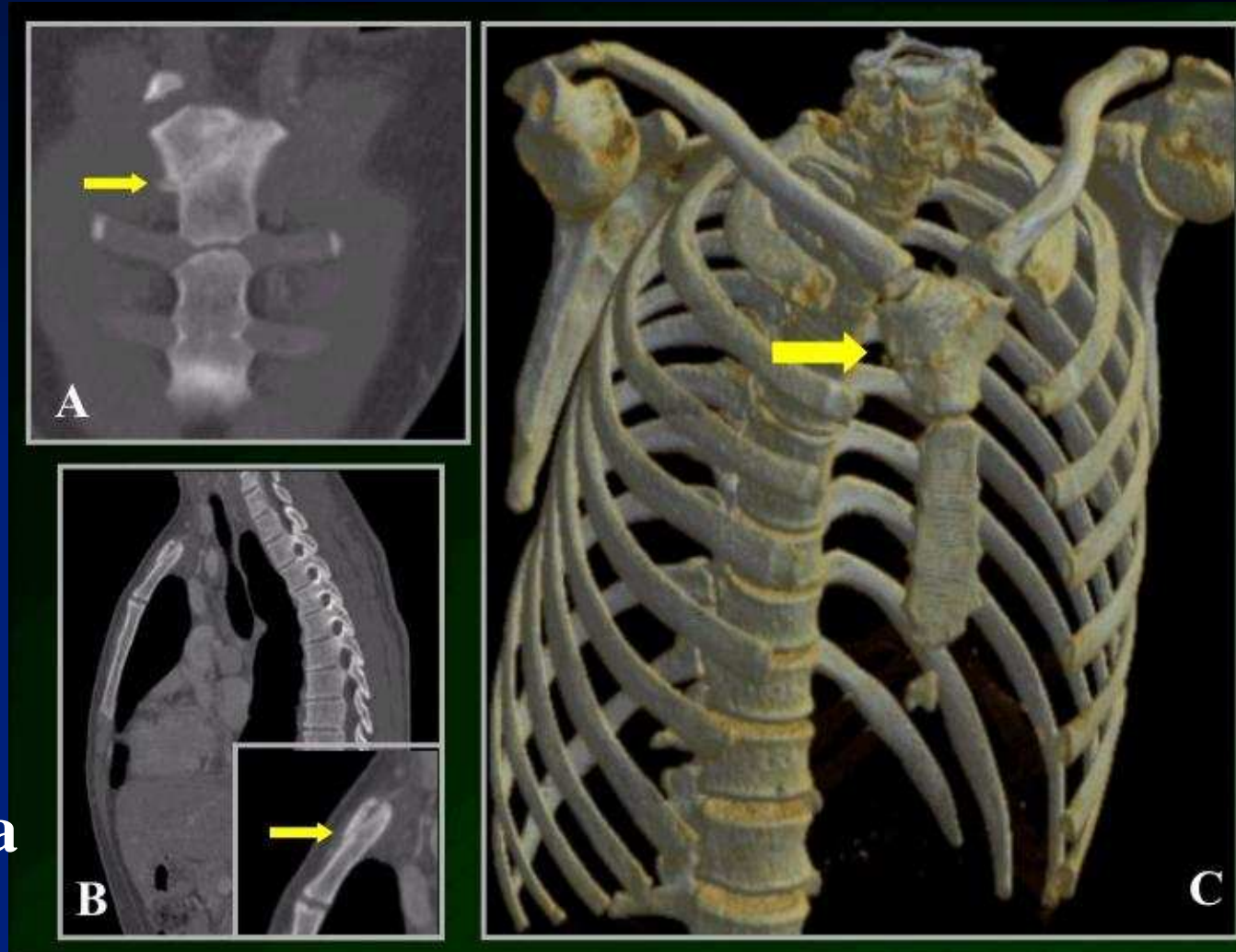
## Rib fractures

- # of the first 3 ribs → severe trauma
- Airway, spinal, vascular and brachial plexus injuries
- # of the lower 3 ribs → abdominal trauma

# Osseous injuries

## Sternal fractures

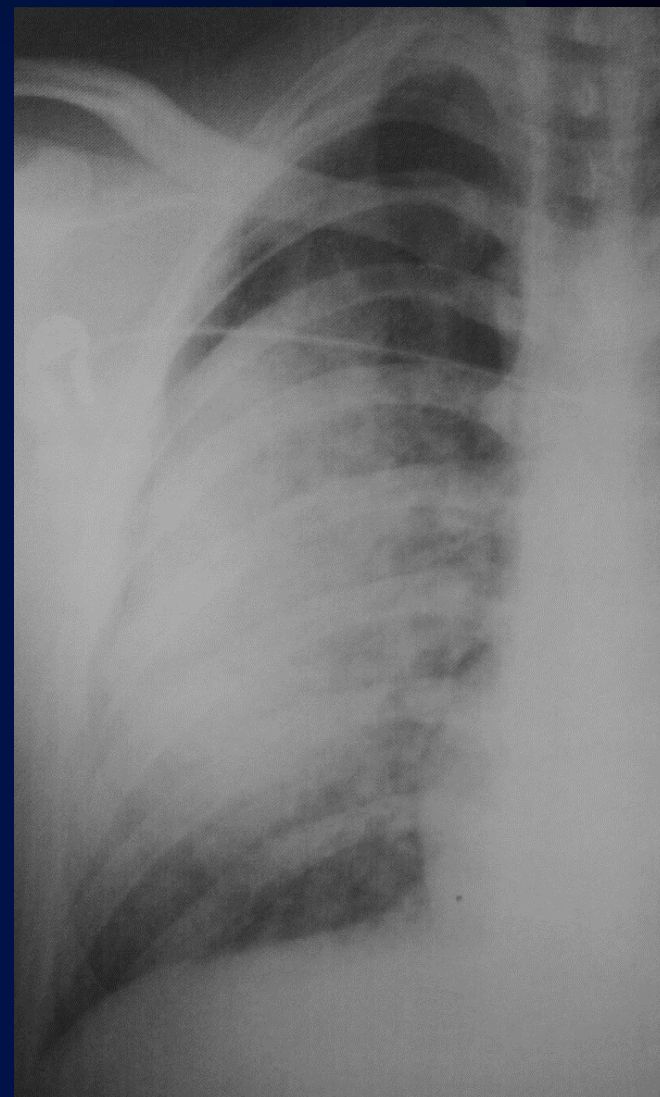
- Important as usually associated with mediastinal injuries
- Usually transverse
- Near the manubrium
- Lateral X-ray
- CT: sagittal or coronal reconstruction
- Retrosternal hematoma

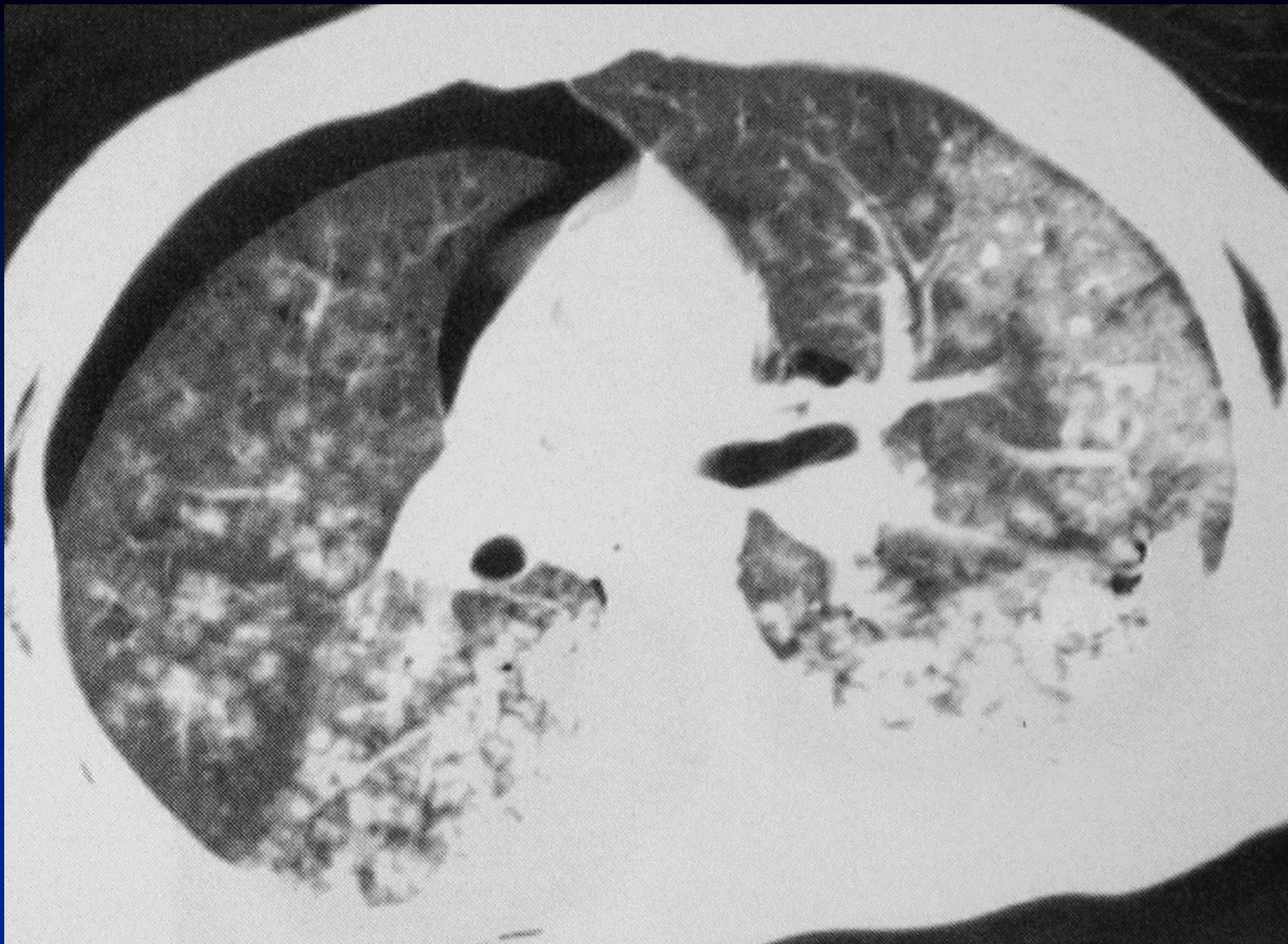


# Lung Injuries

## Contusions

- **Most common parenchymal injuries : 50 % ? (17-70%)**
- **Local compressive and recoil forces**
- **Appear rapidly and max in < 24 H**
- **Close to ribs, spine, heart or liver**
- **Various Rx presentation (CT)**
- **V/P mismatch, compliance ↓**
- **Require mechanical ventilation when > 1/3**
- **DD aspiration, edema, atelectasis**
- **Complete resolve within 1 to 2 weeks**

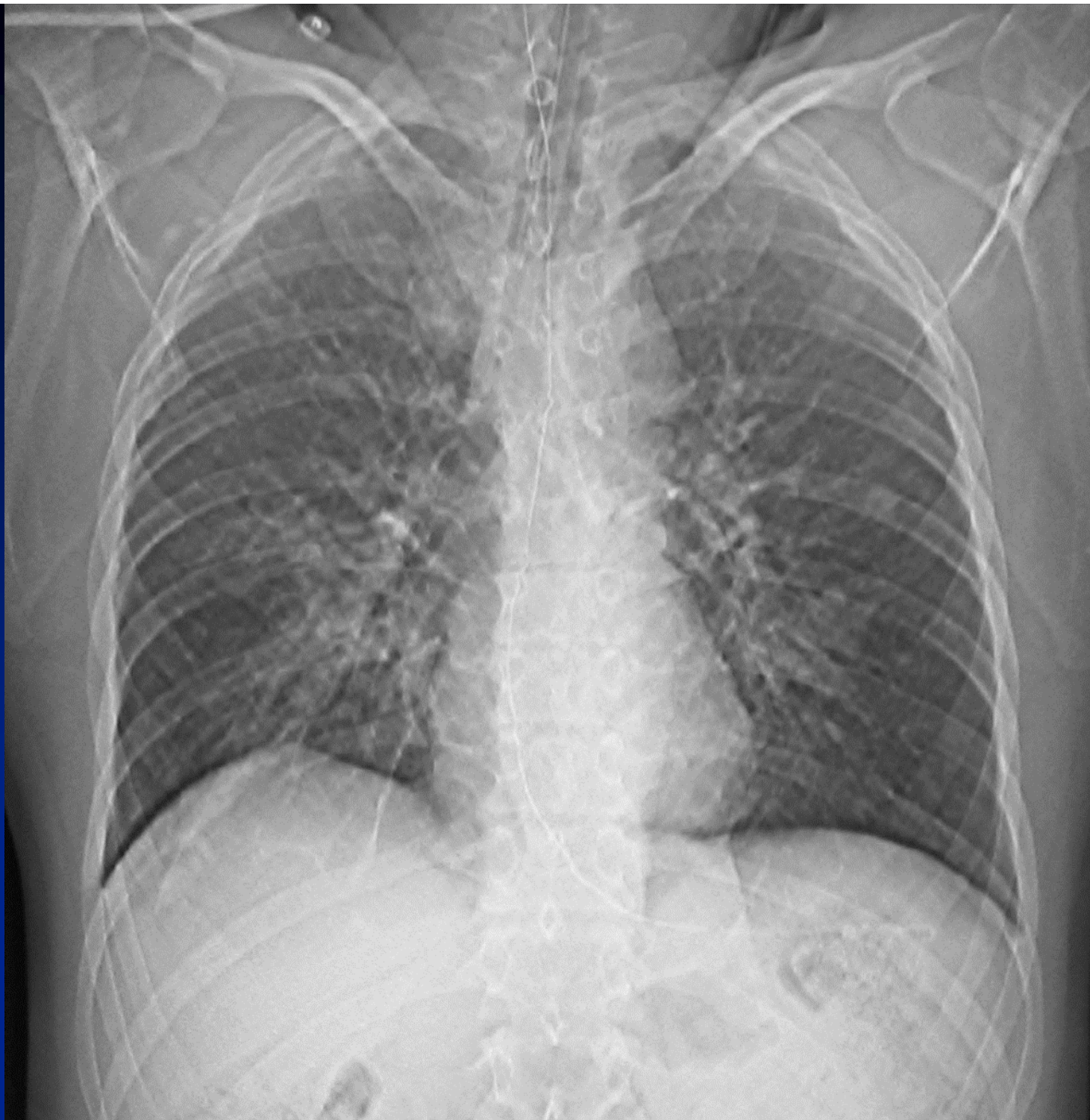

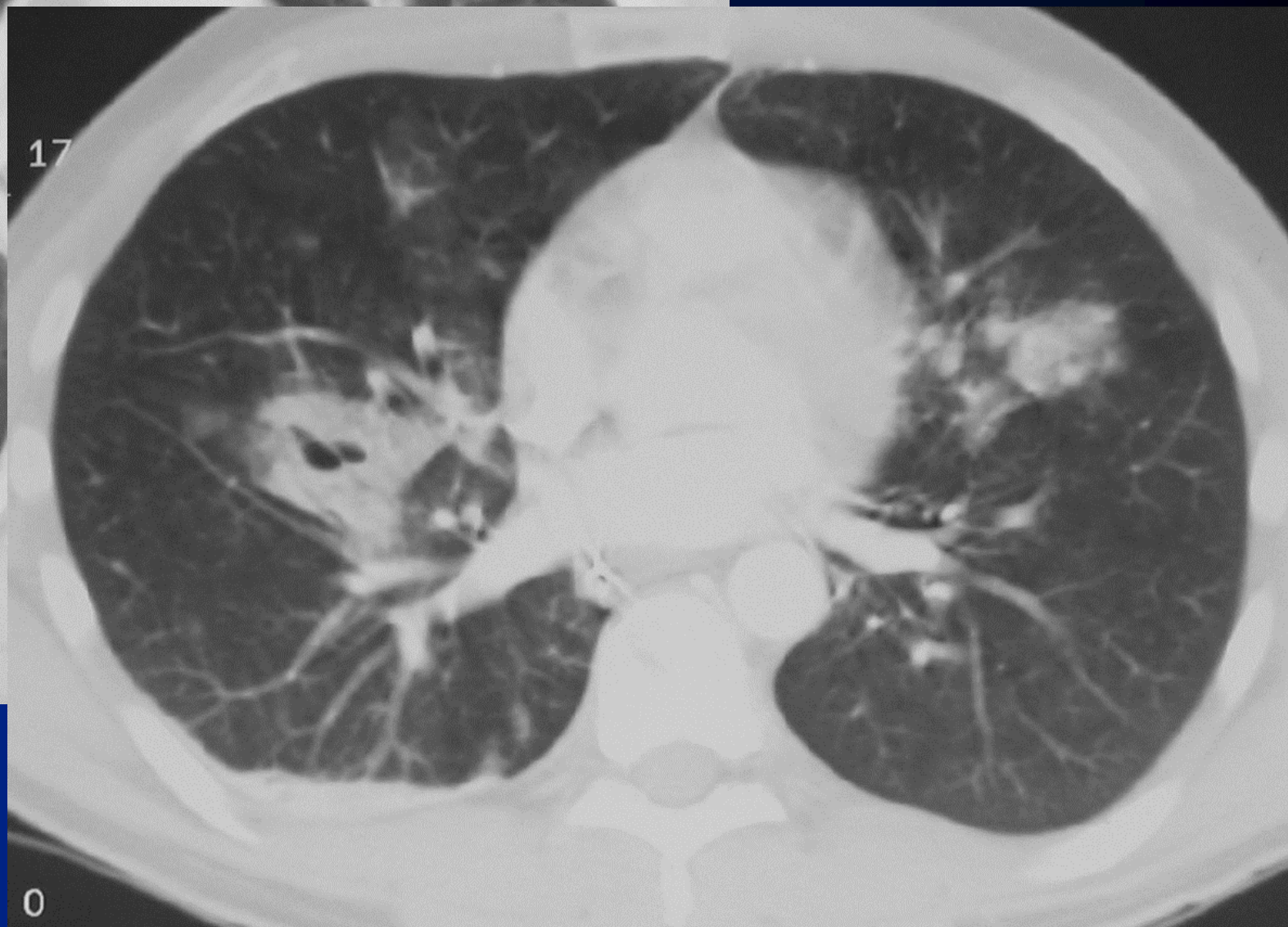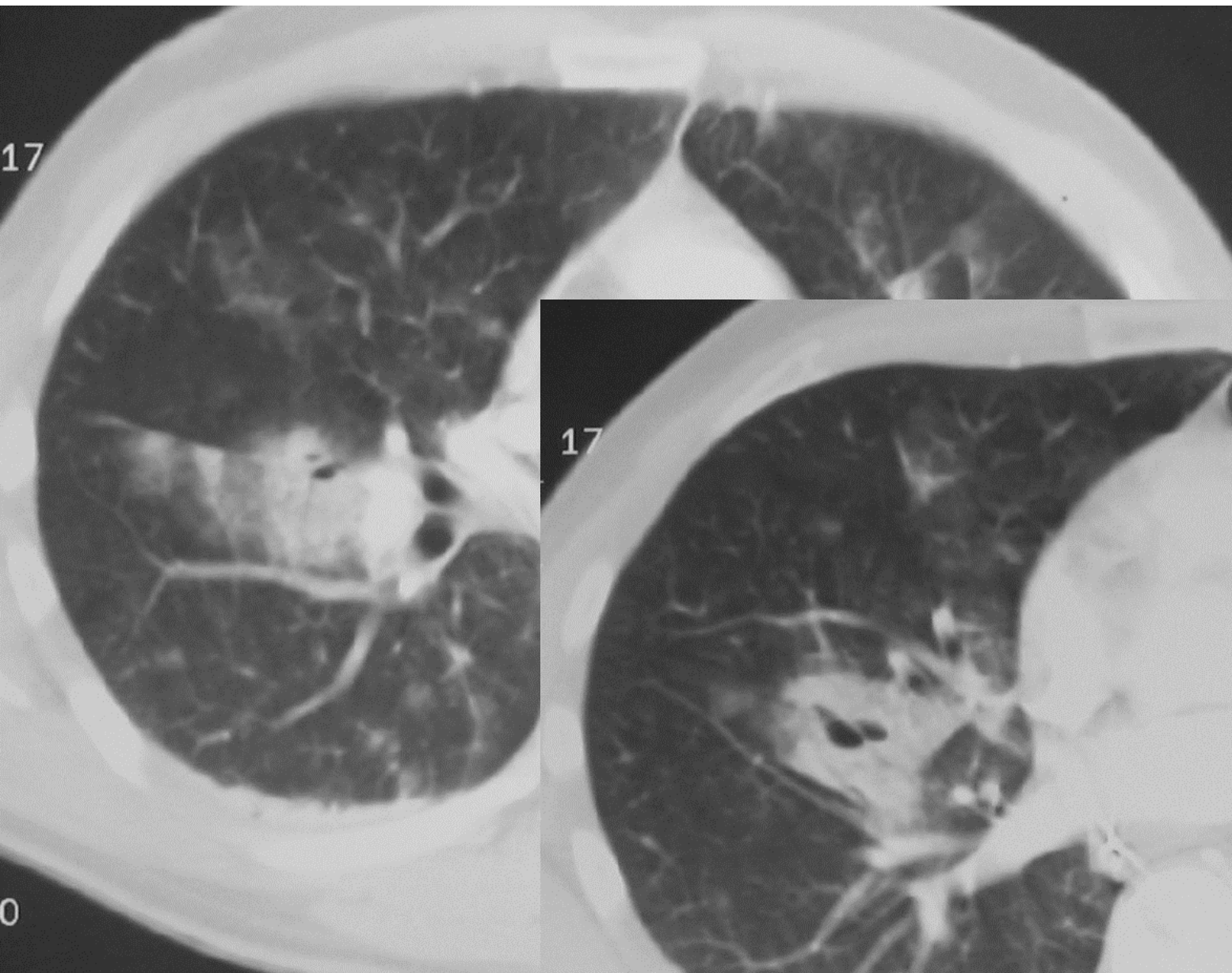


# Lung injuries

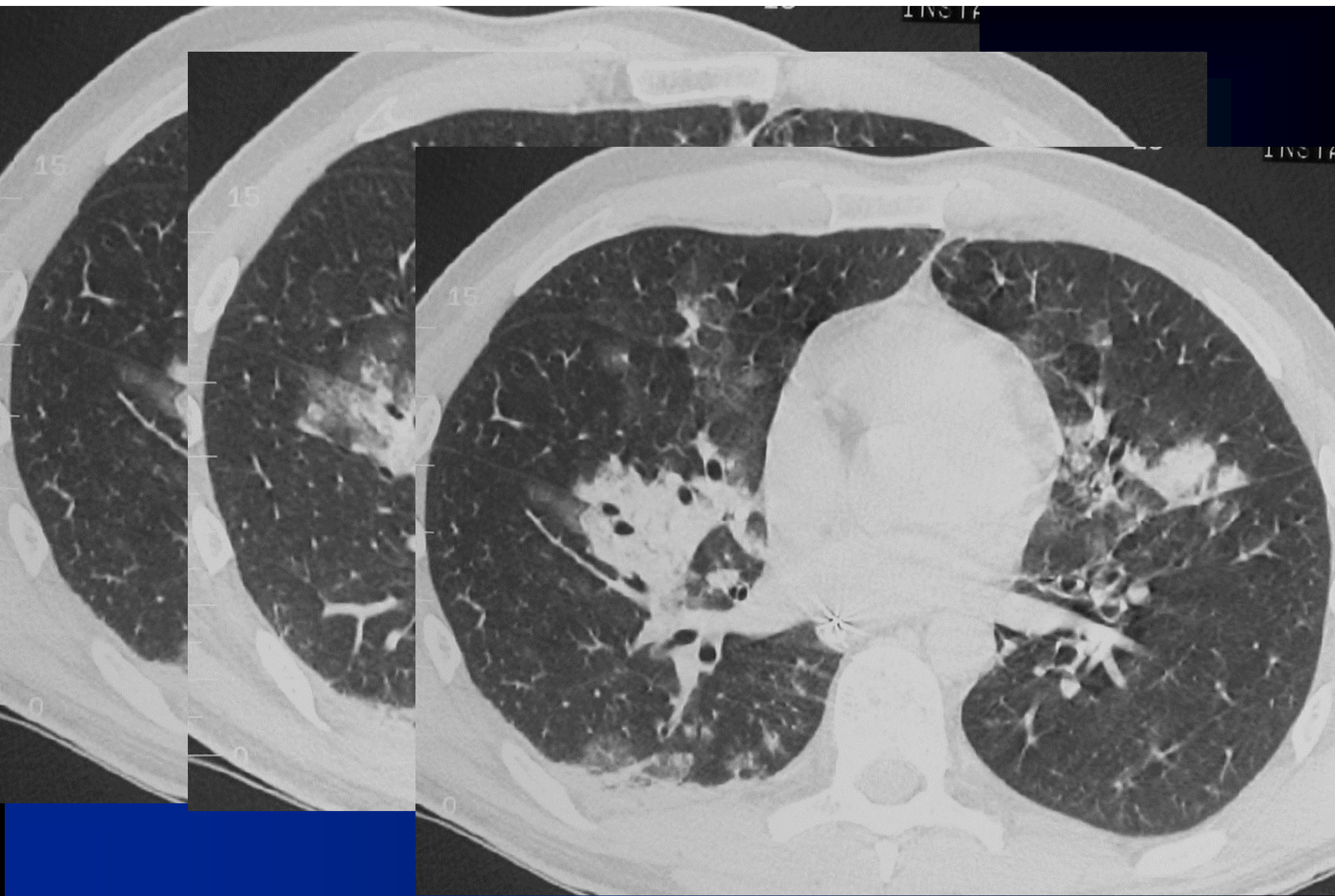
## Lacerations

- Shearing forces
- Initially linear, then rapidly ovoid (elastic recoil)
- May be obscured by surrounding contusions or subcutaneous emphysema
- May fill with blood → hematoma  
air → pneumatocele
- Resolve over weeks or months



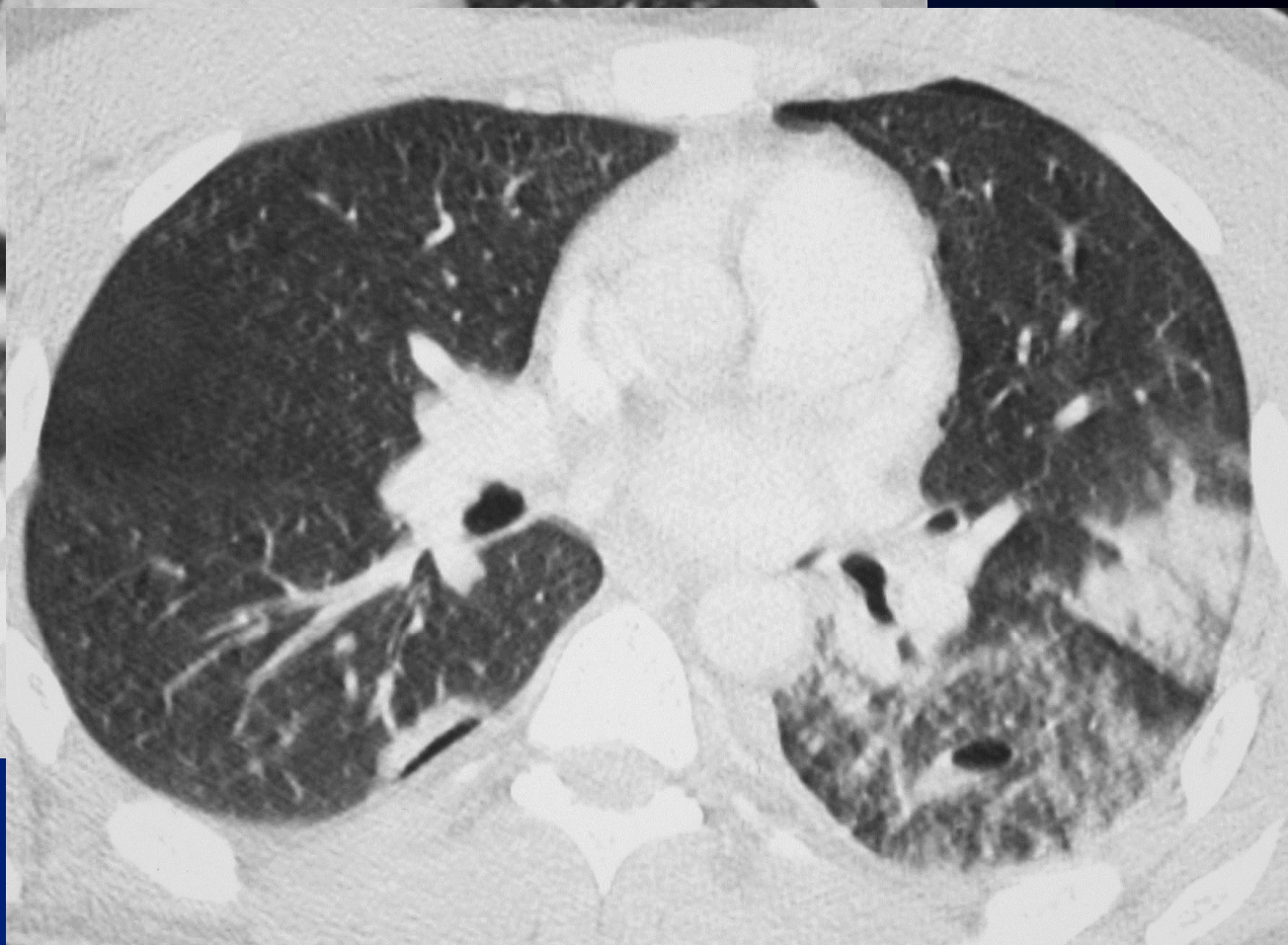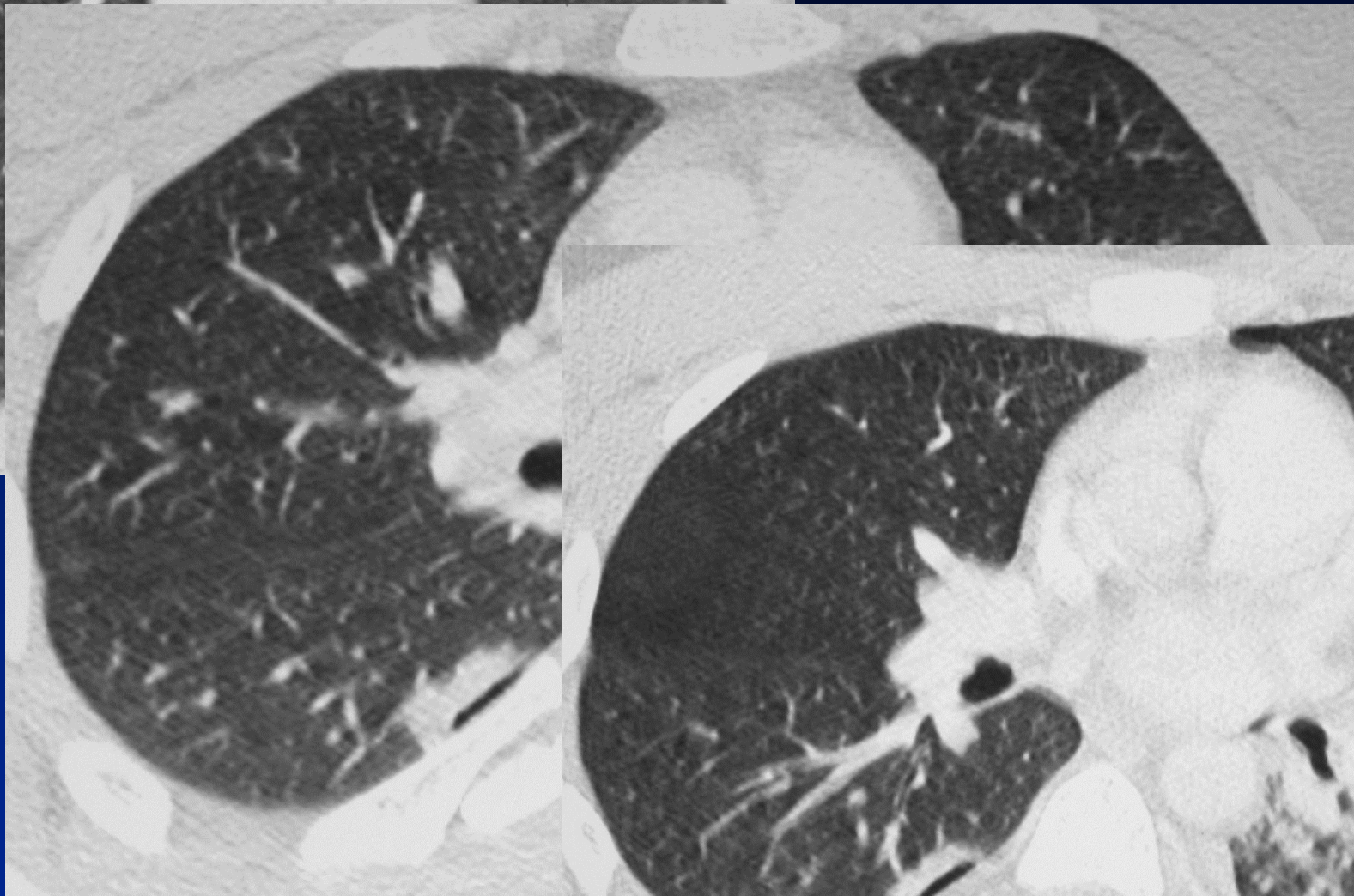
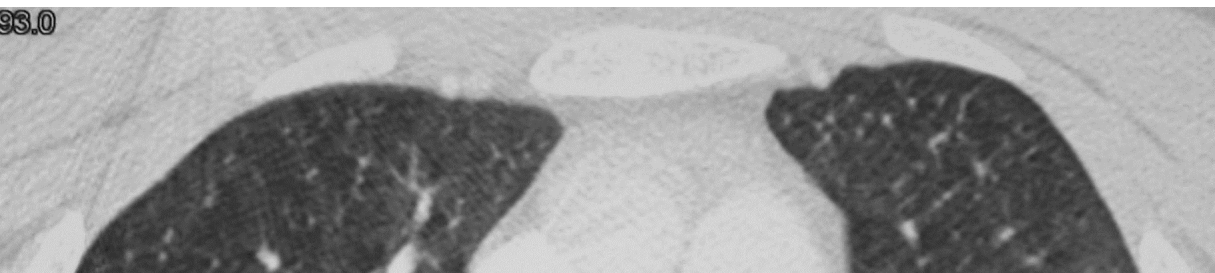





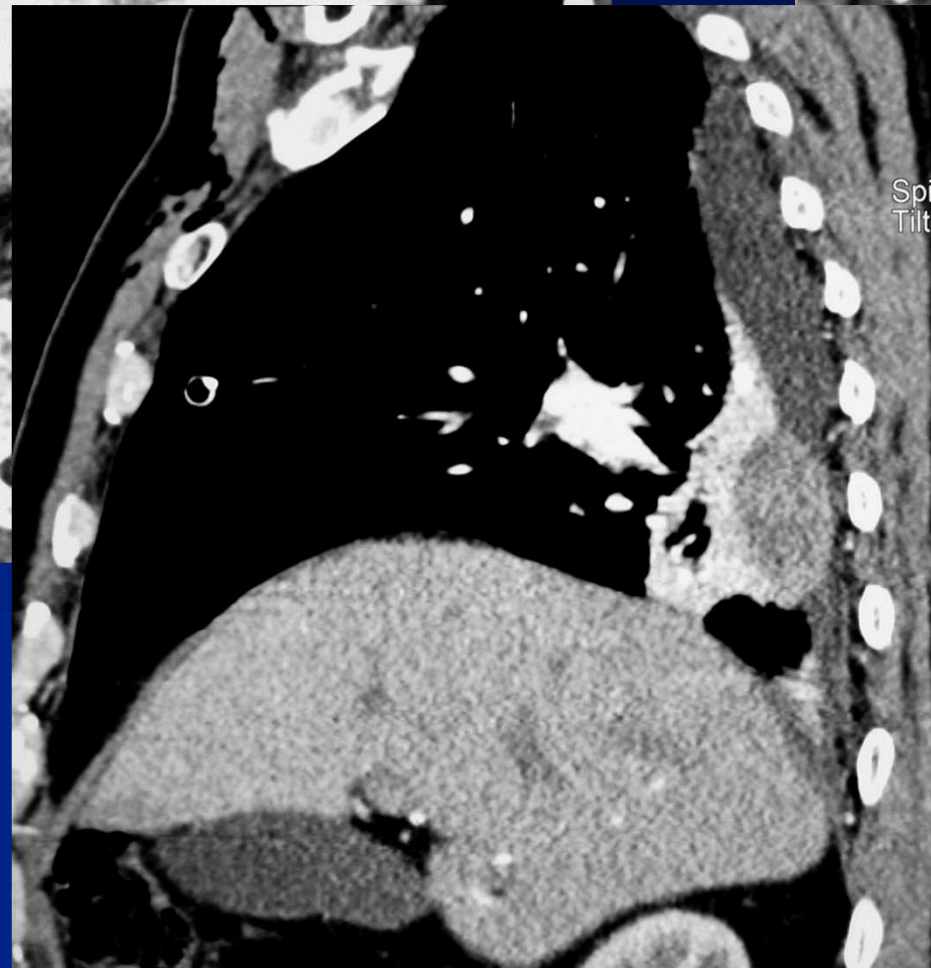
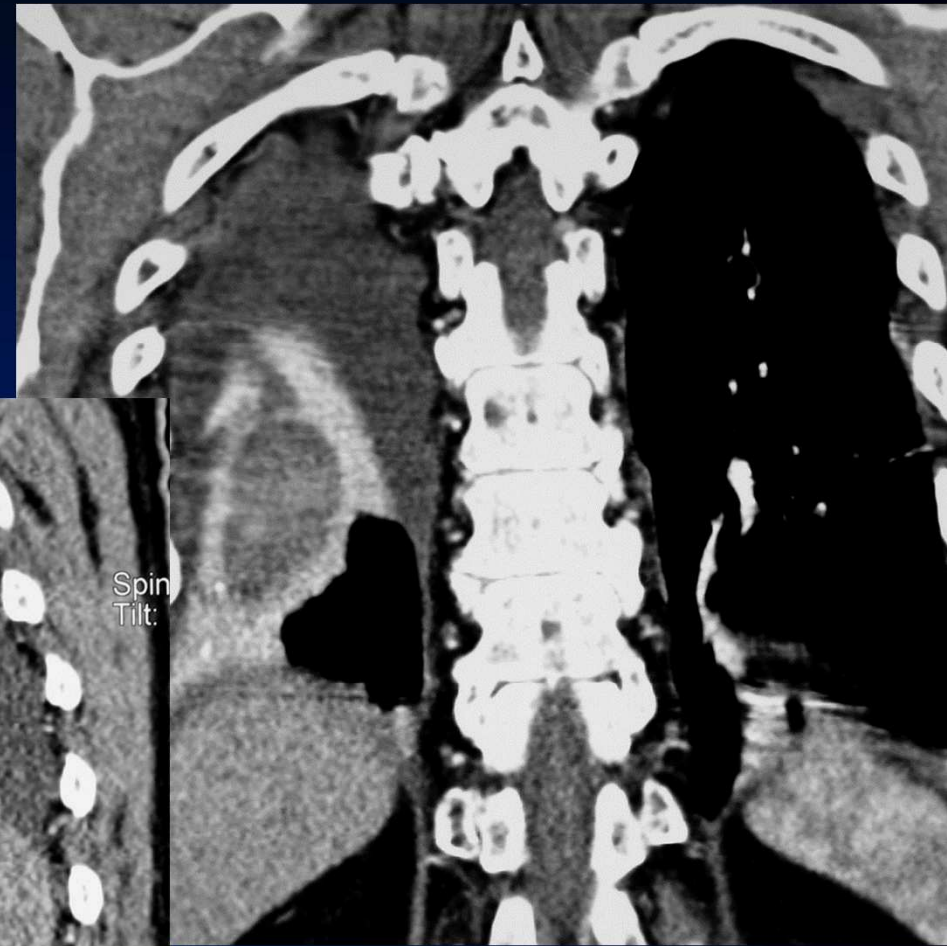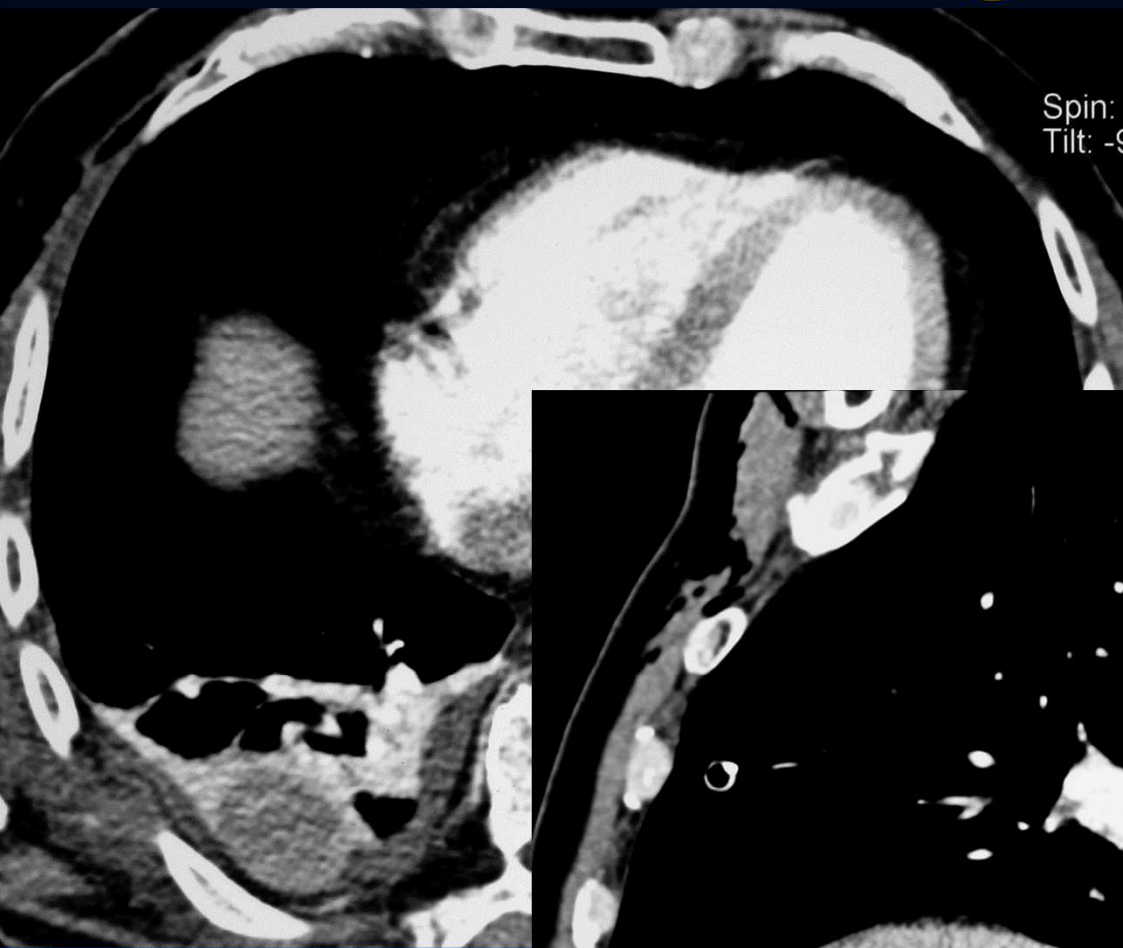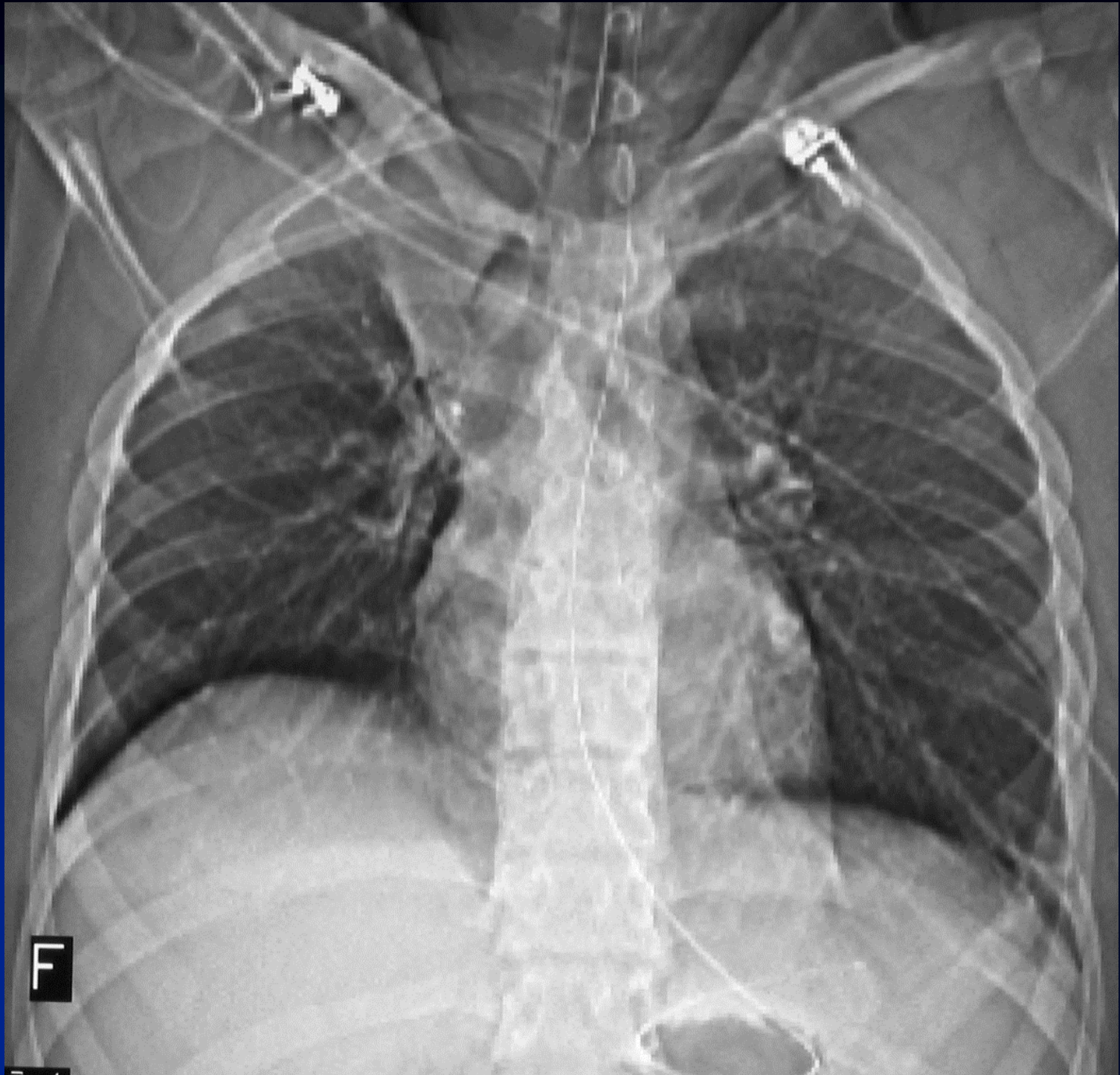
93.0

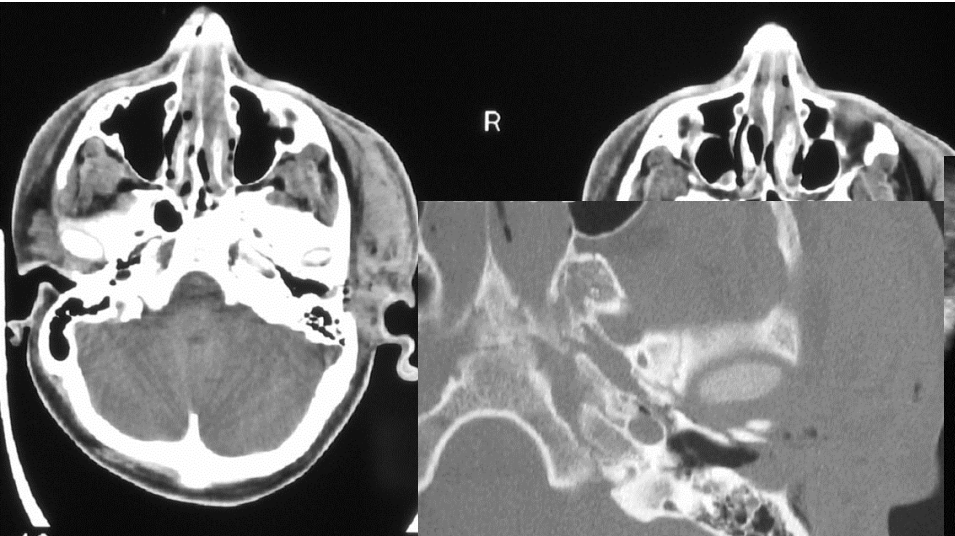
0  
s 176  
s 120



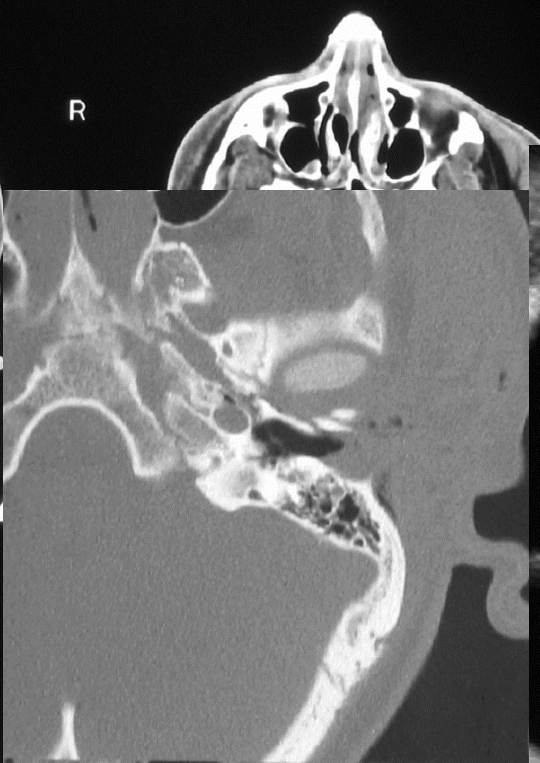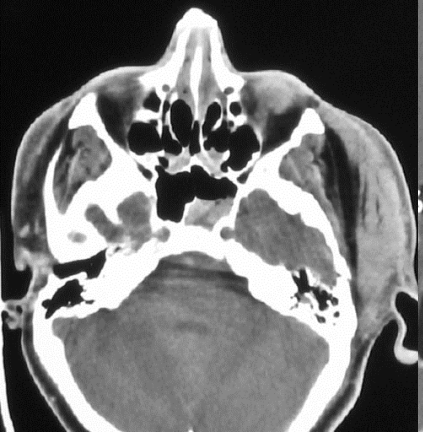# Lung hematoma



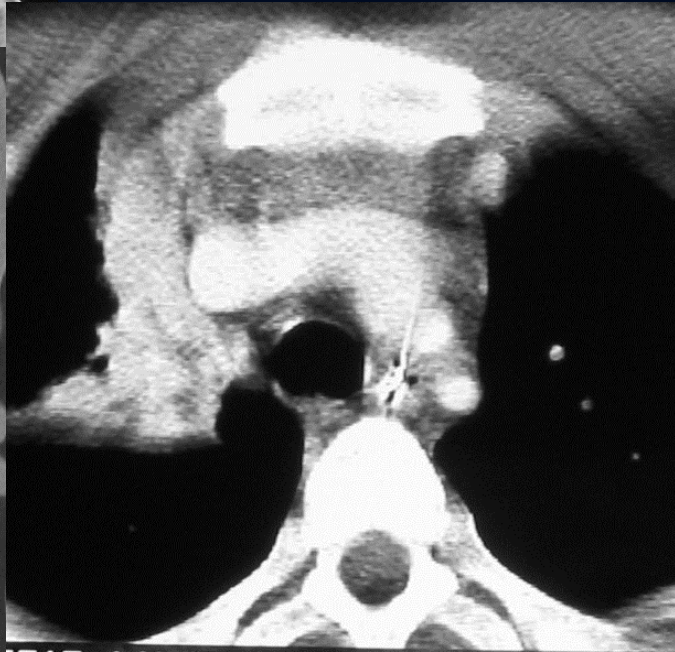
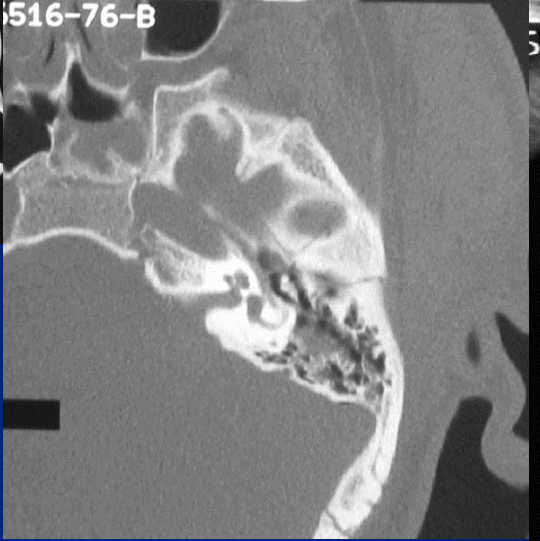




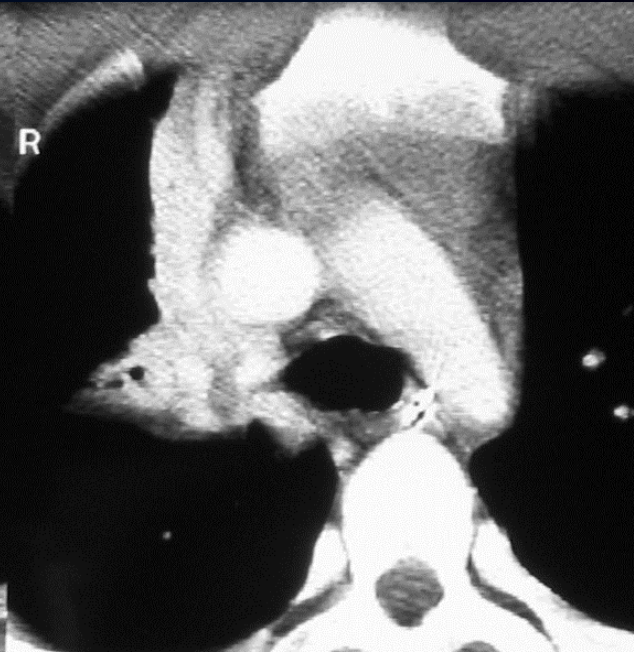-10



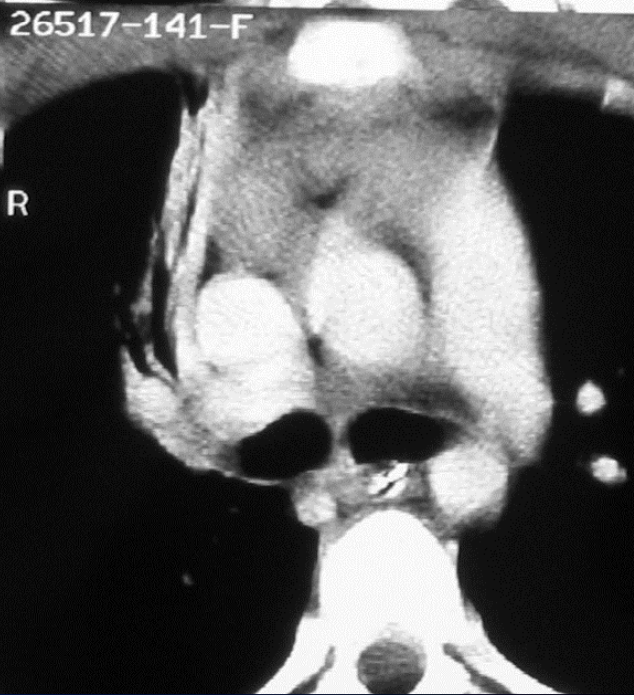
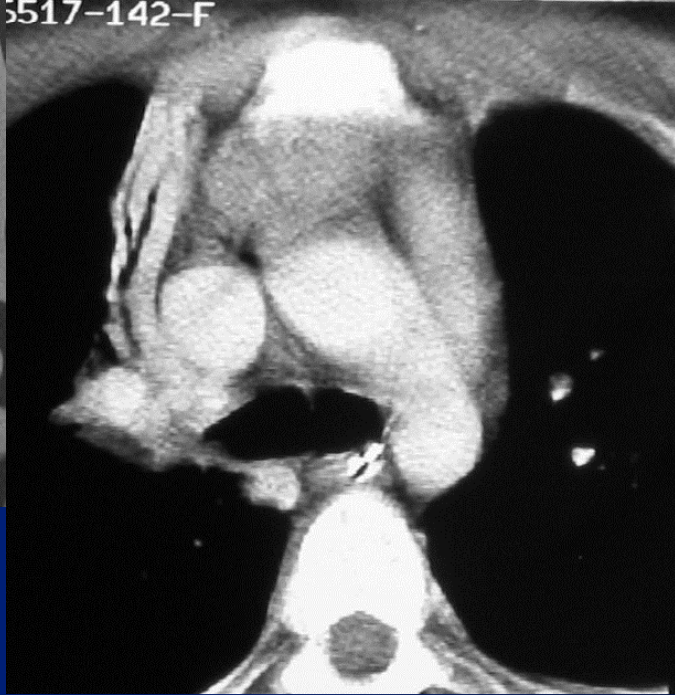516-76-B

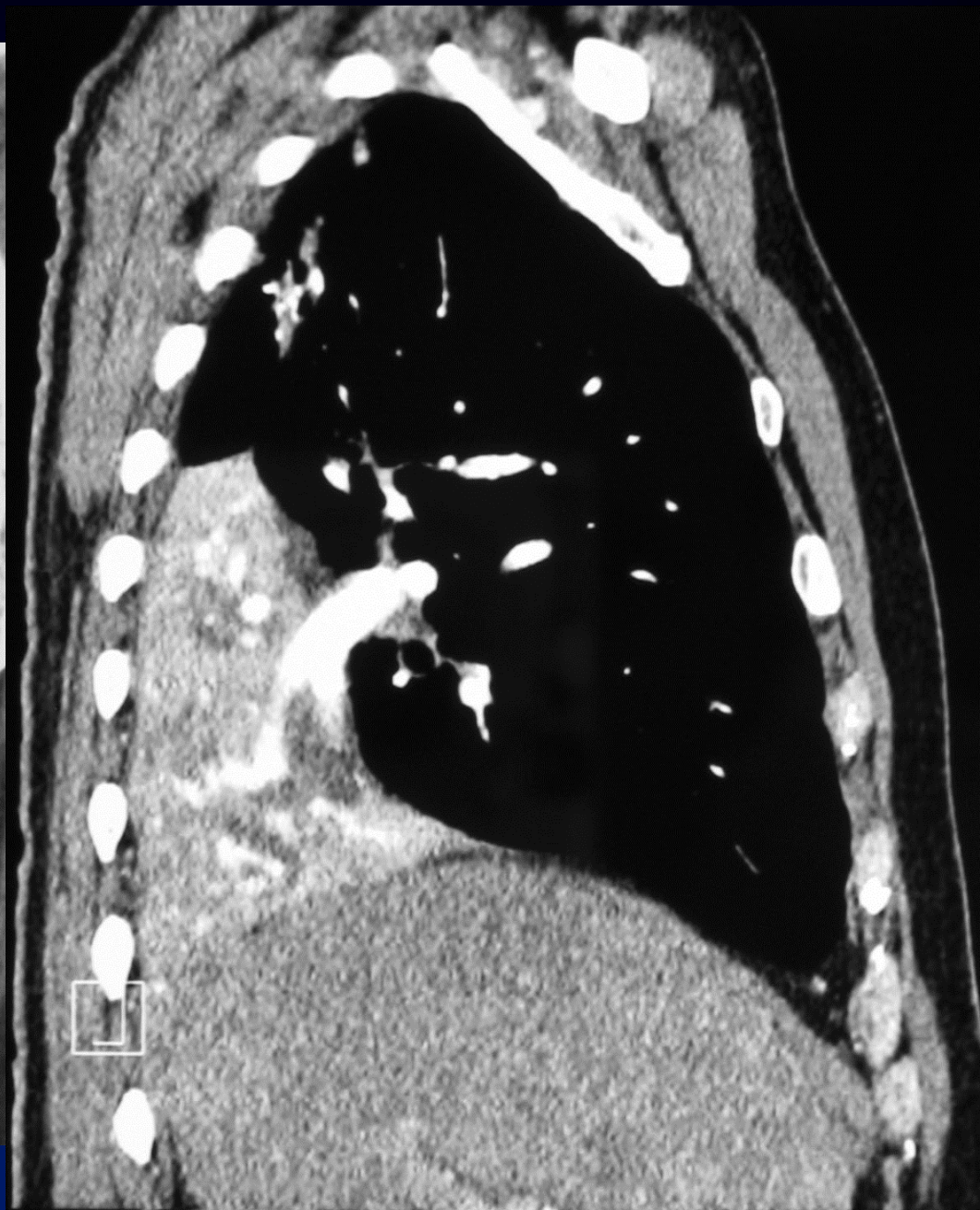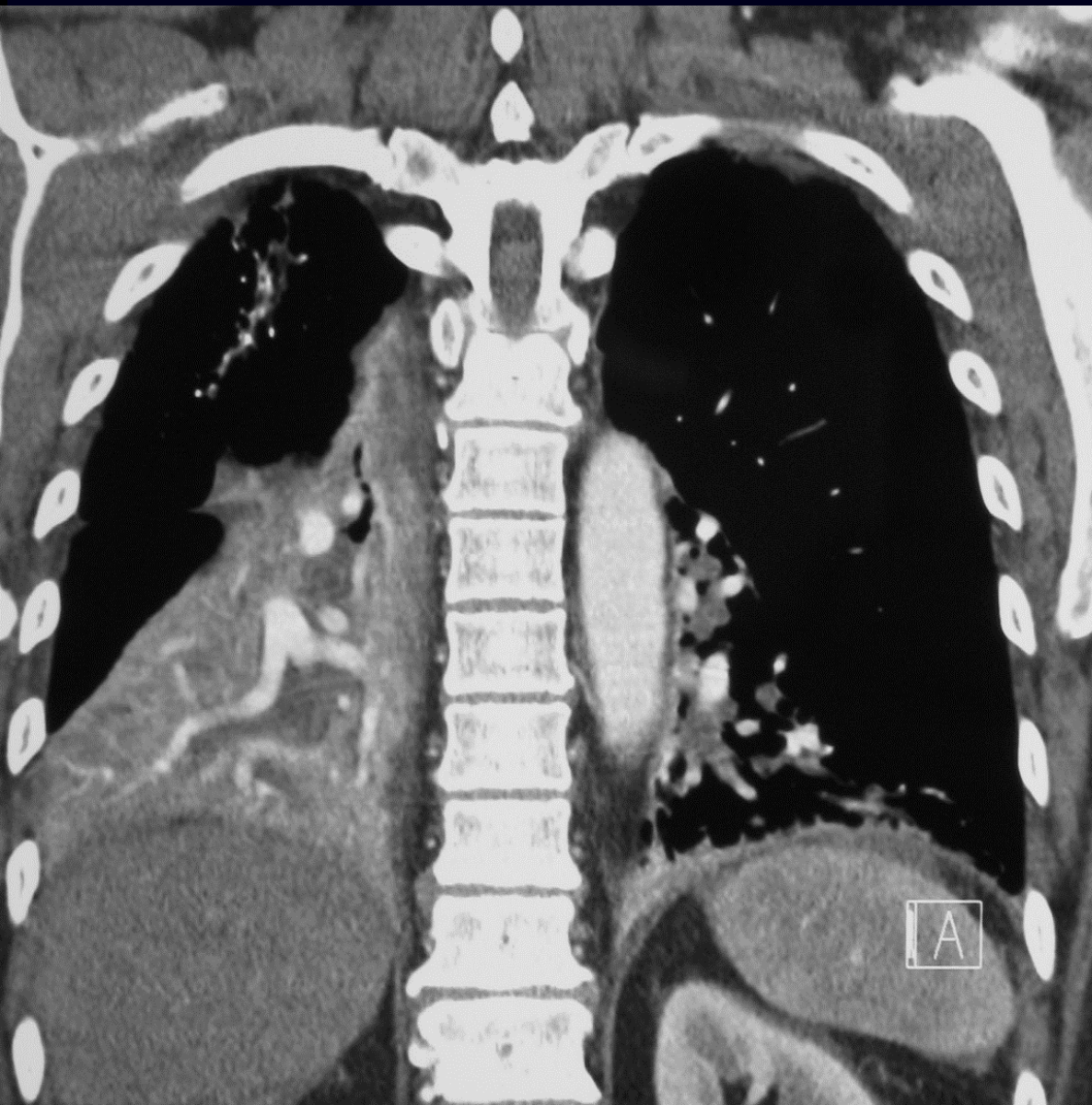


517-142-F



26517-141-F



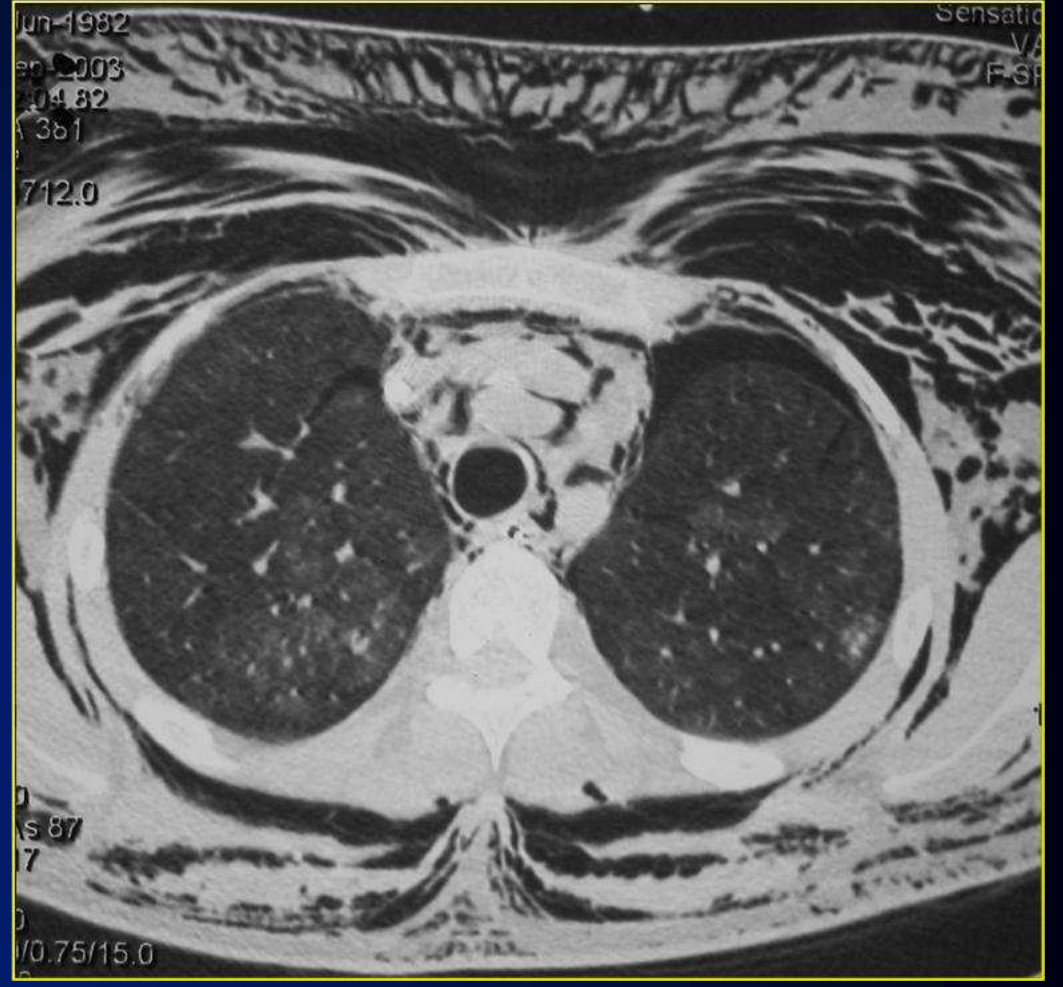
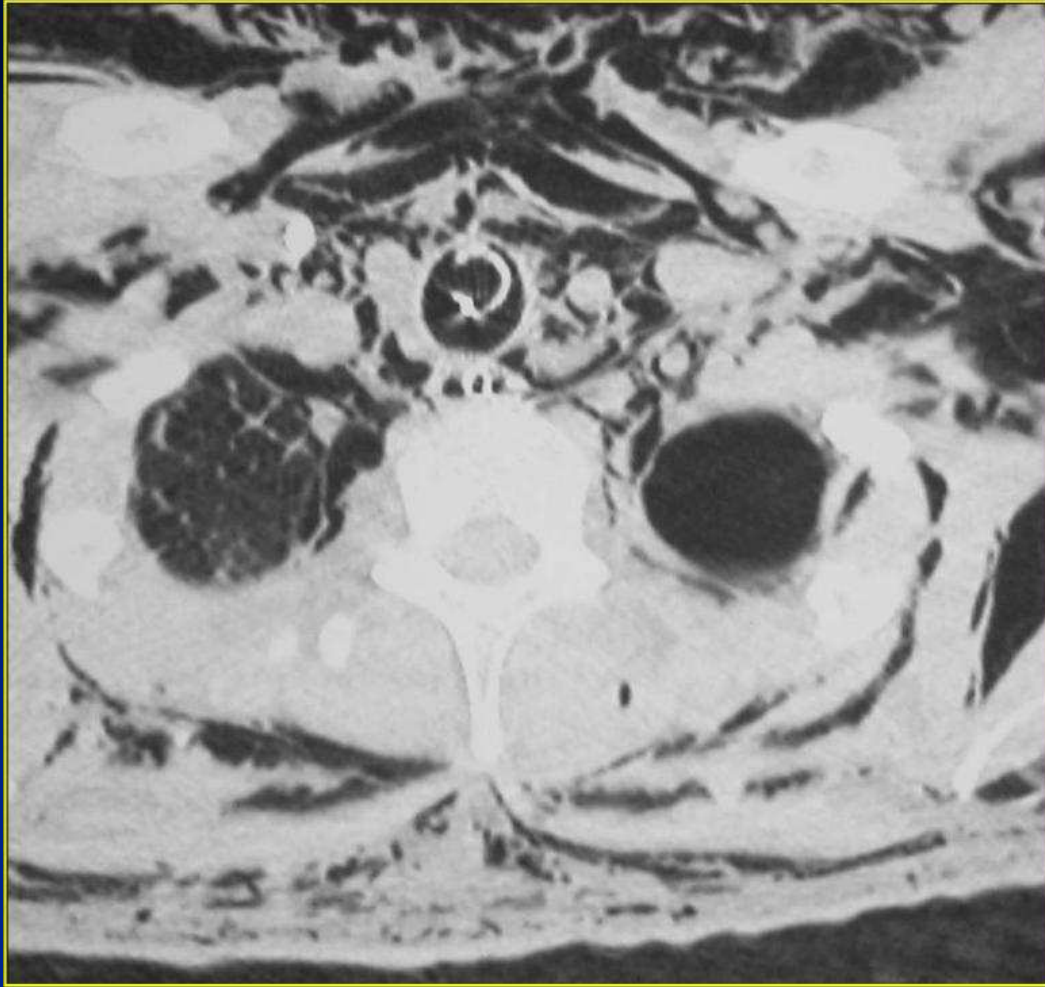


# Pneumomediastinum

**>10 % of severe blunt chest trauma**

- **<2 % results from blunt tracheobronchial lesions**
- **Rarely originates from esophageal injuries**
- **Extension of cervical or thoracic subcutaneous emphysema**
- **Extension of retroperitoneum consecutive to a hollow viscus rupture**

**In other cases → MACKLIN effect**





# The MACKLIN effect

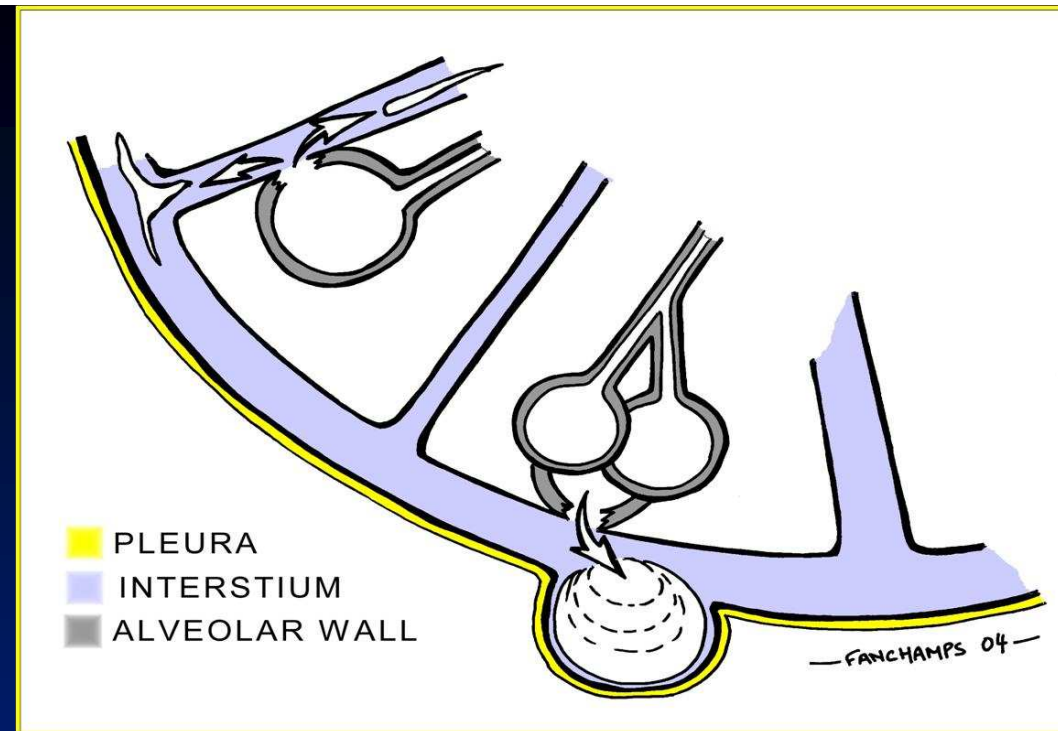
- Macklin (1939) → Overinflation of cat lungs
- High-pressure gradient between alveoli and pulmonary interstitium leads to

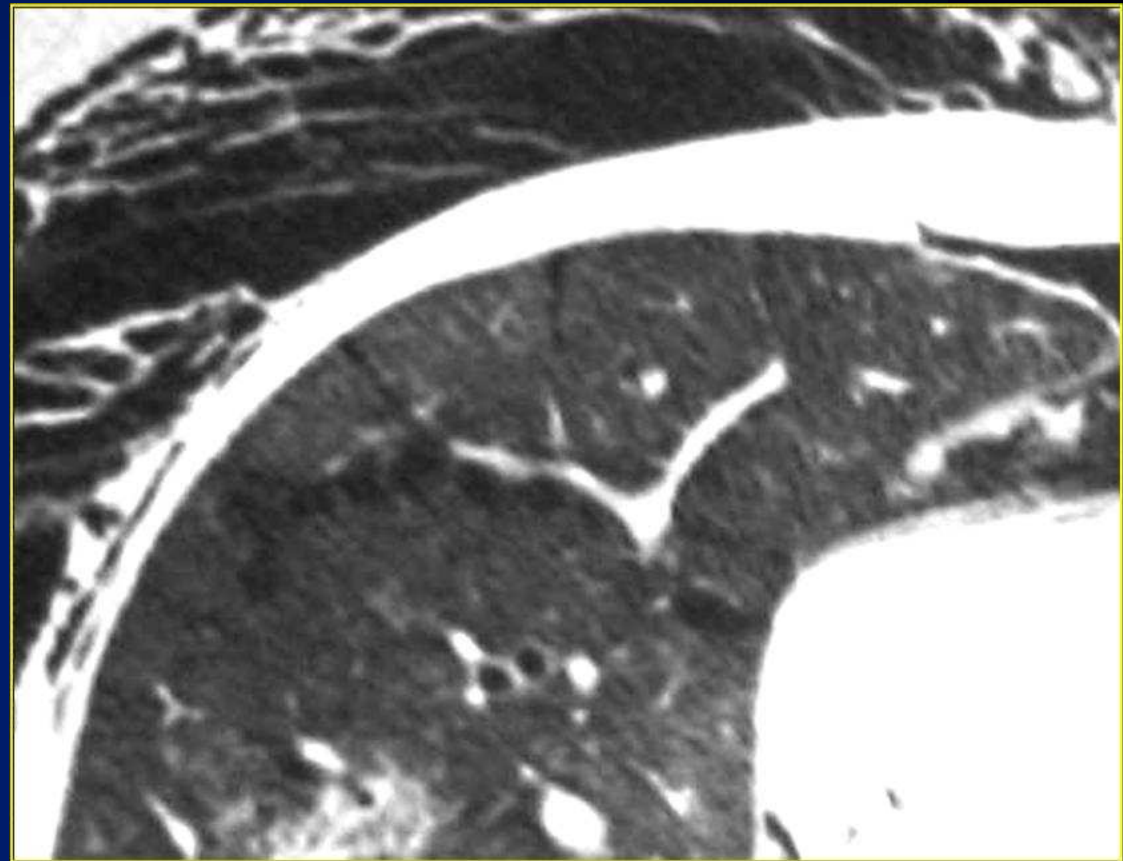
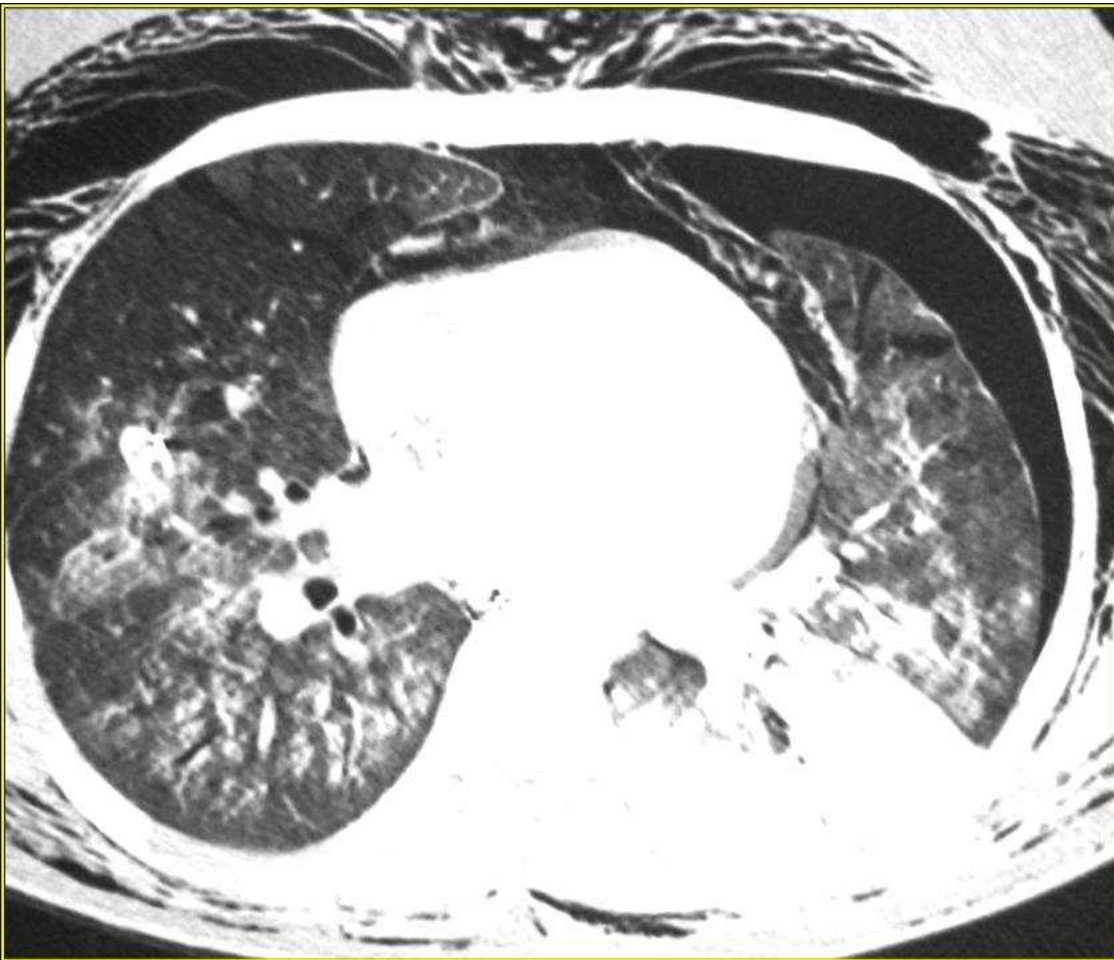
(1) alveolar rupture with

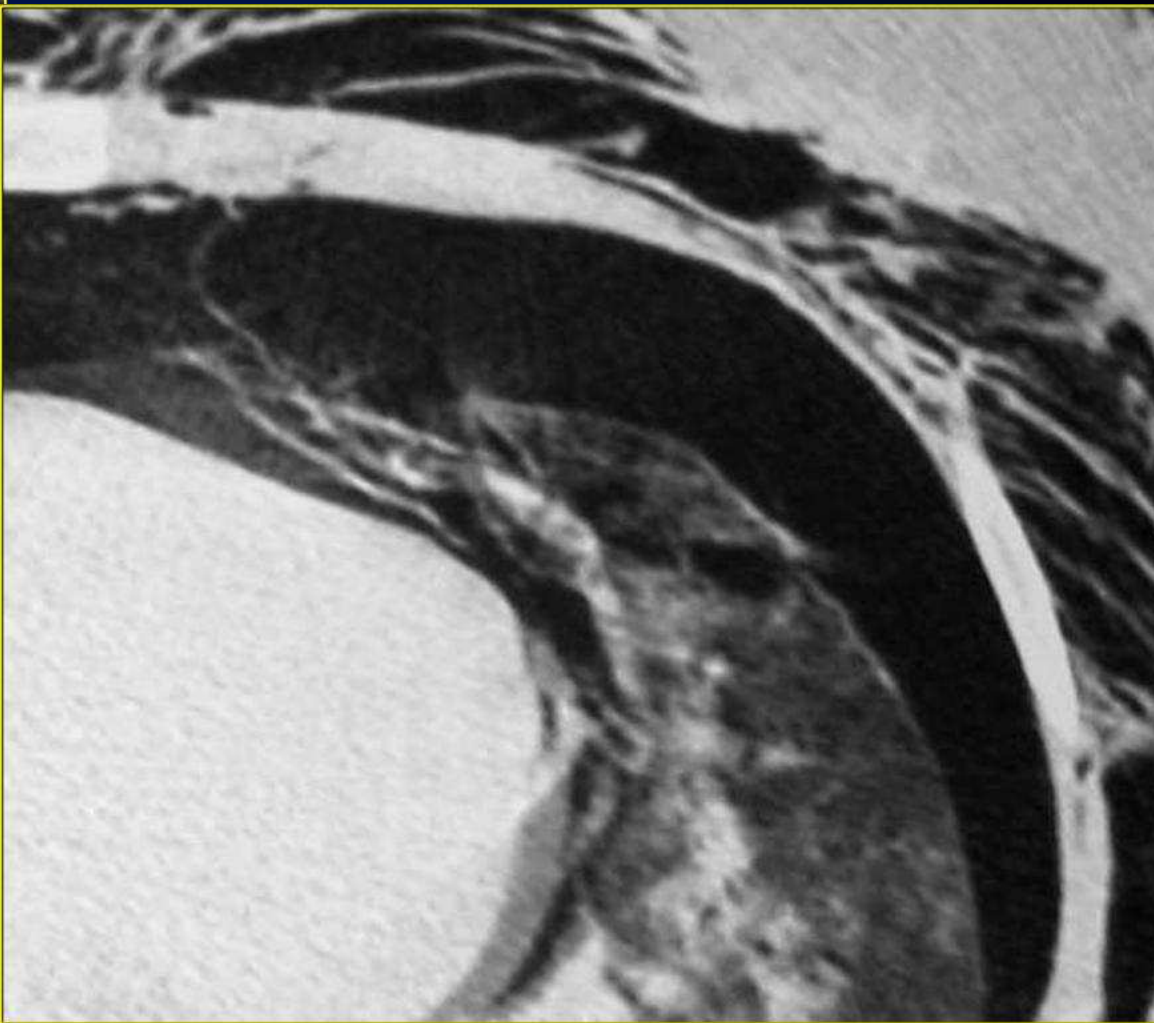
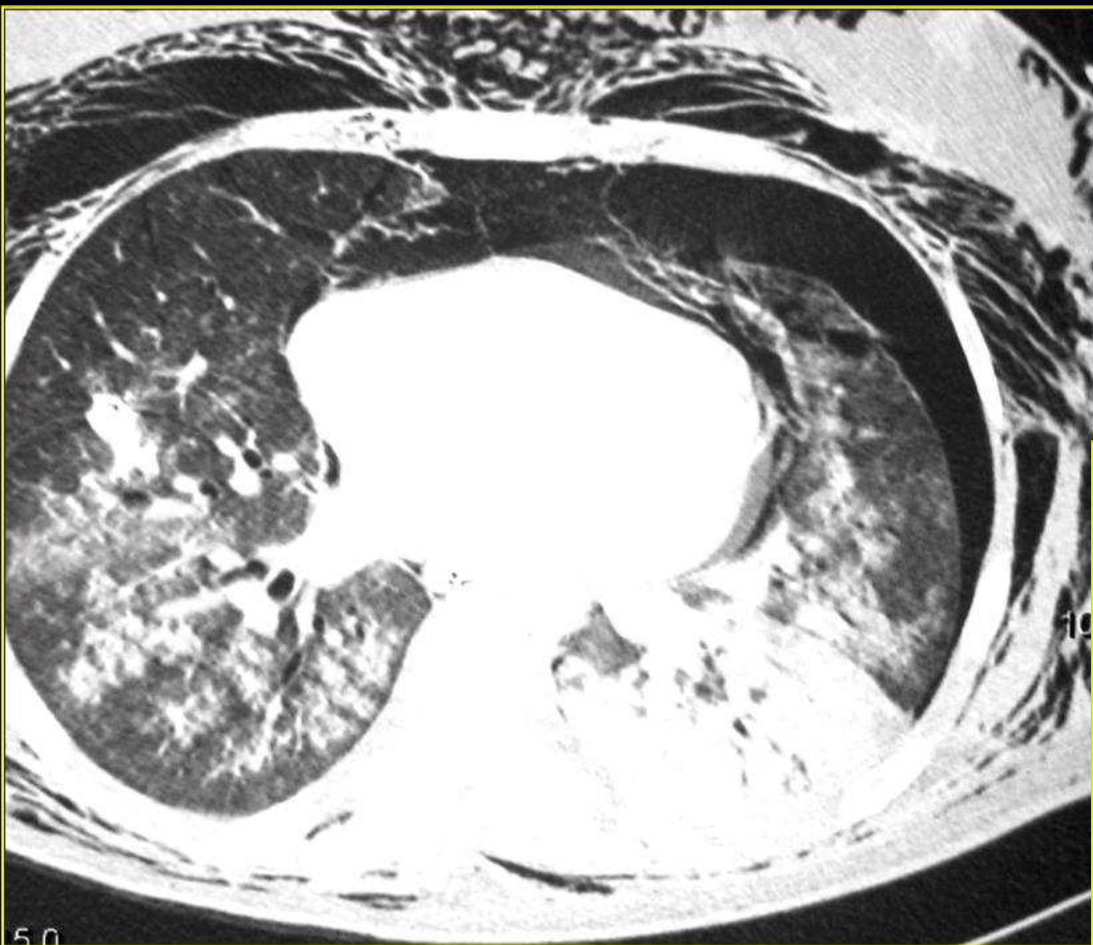(2) dissection and coursing of free interstitial air along the connective tissue surrounding the bronchi and pulmonary vessels

(3) toward the mediastinum

- Continuity between mediastinal and peribronchial facial planes (Marchand 1951)





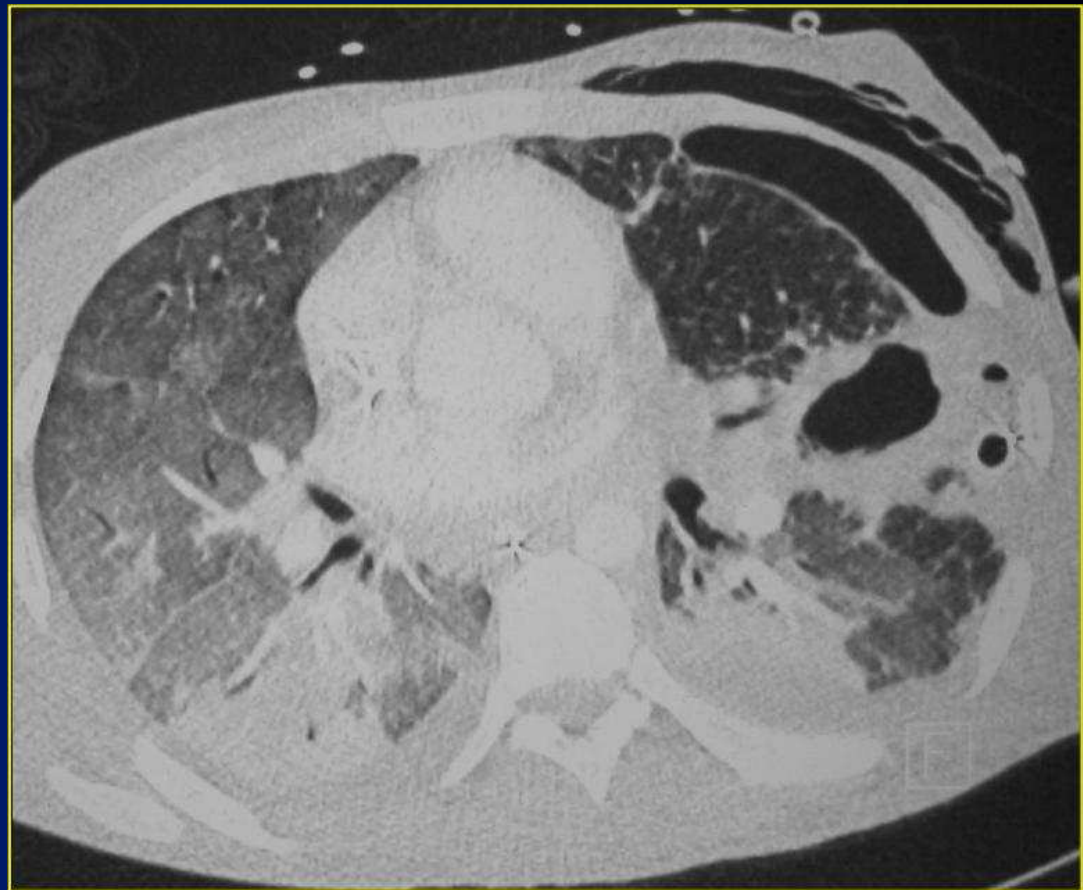
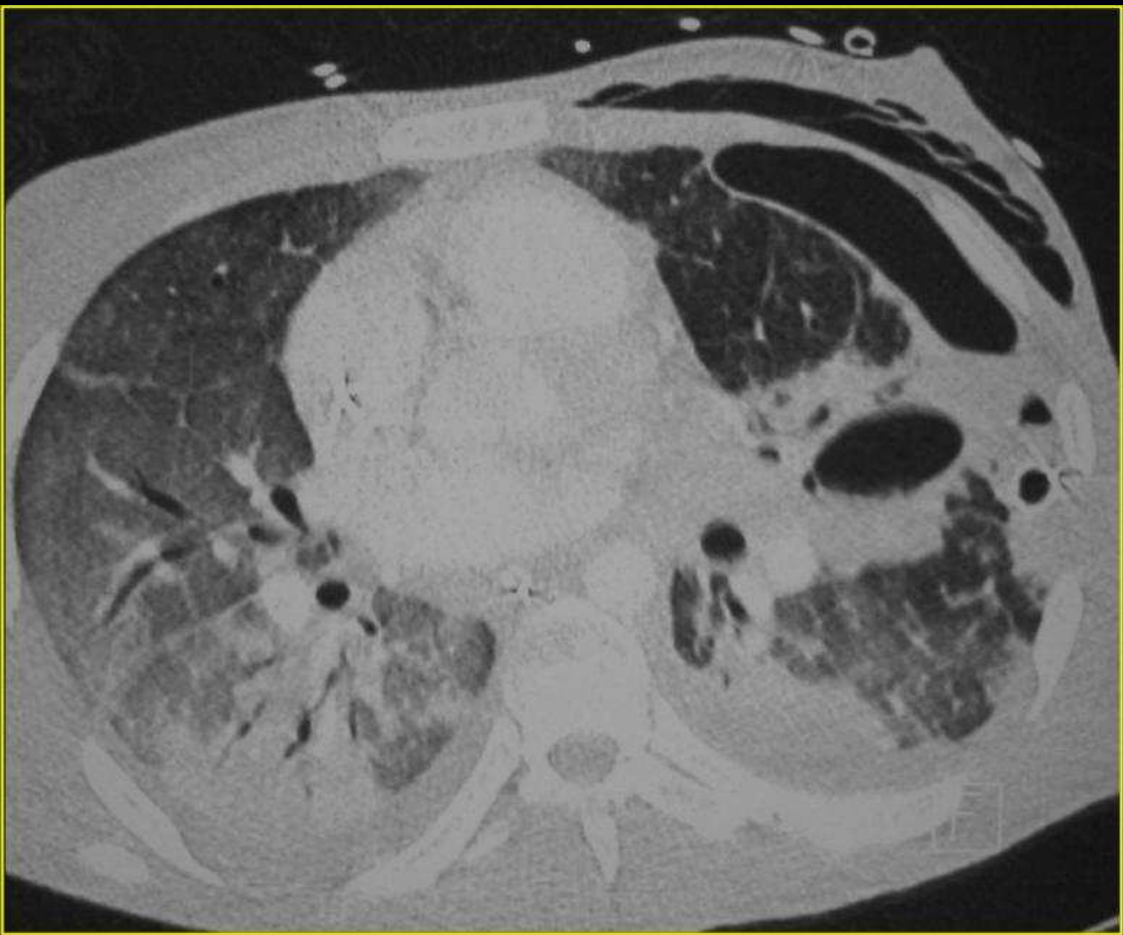
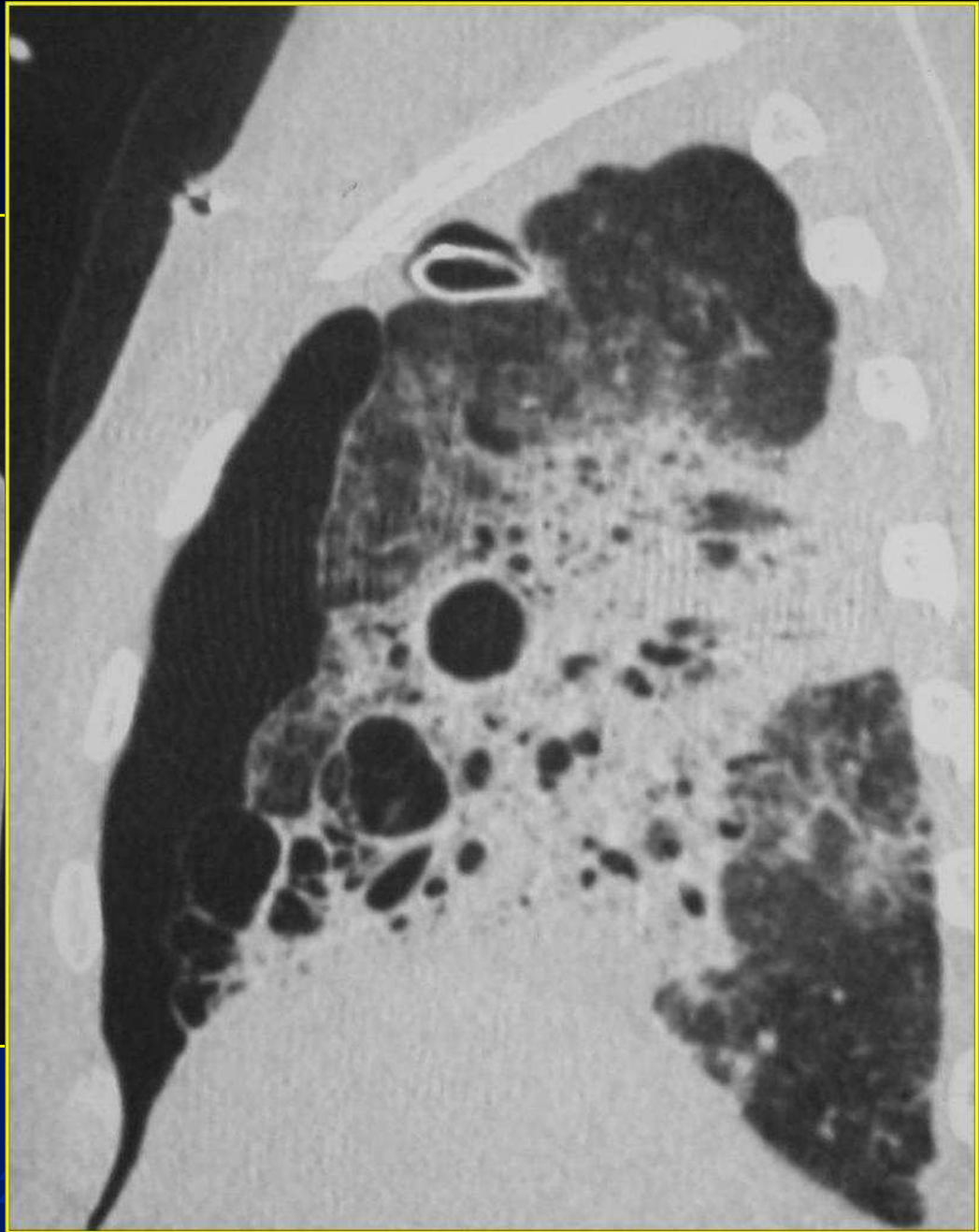
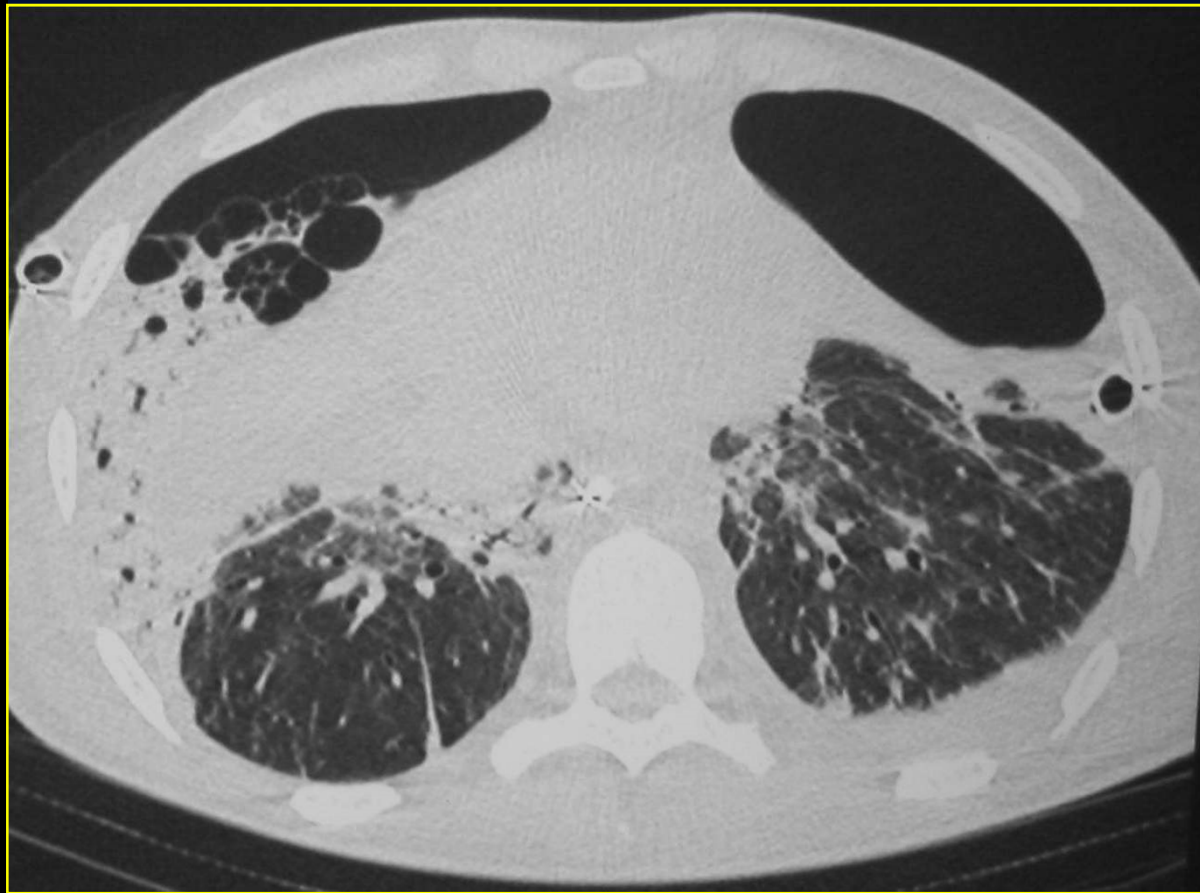
## **The MACKLIN effect**

### **Complications of the Macklin effect + mechanical ventilation**

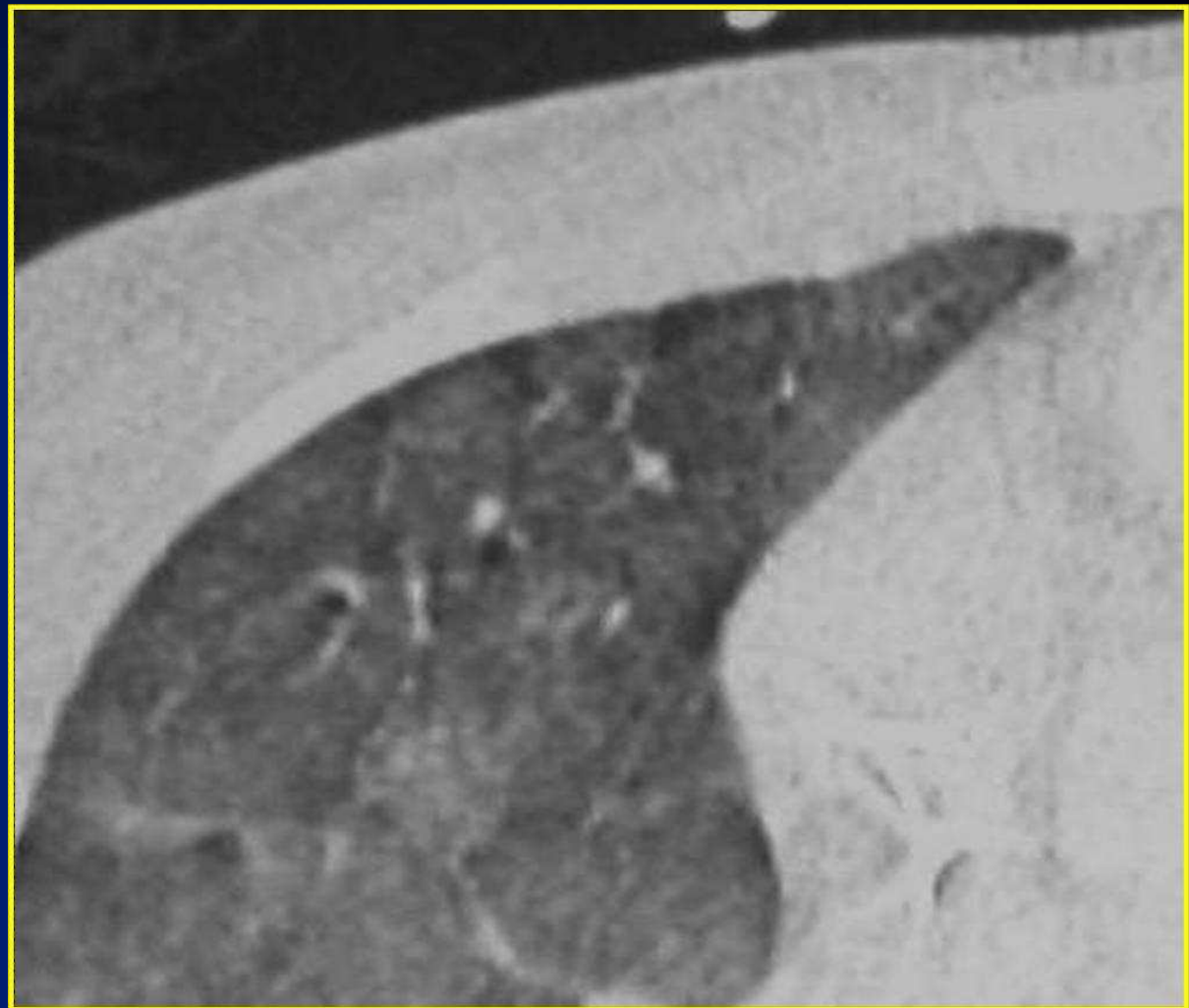
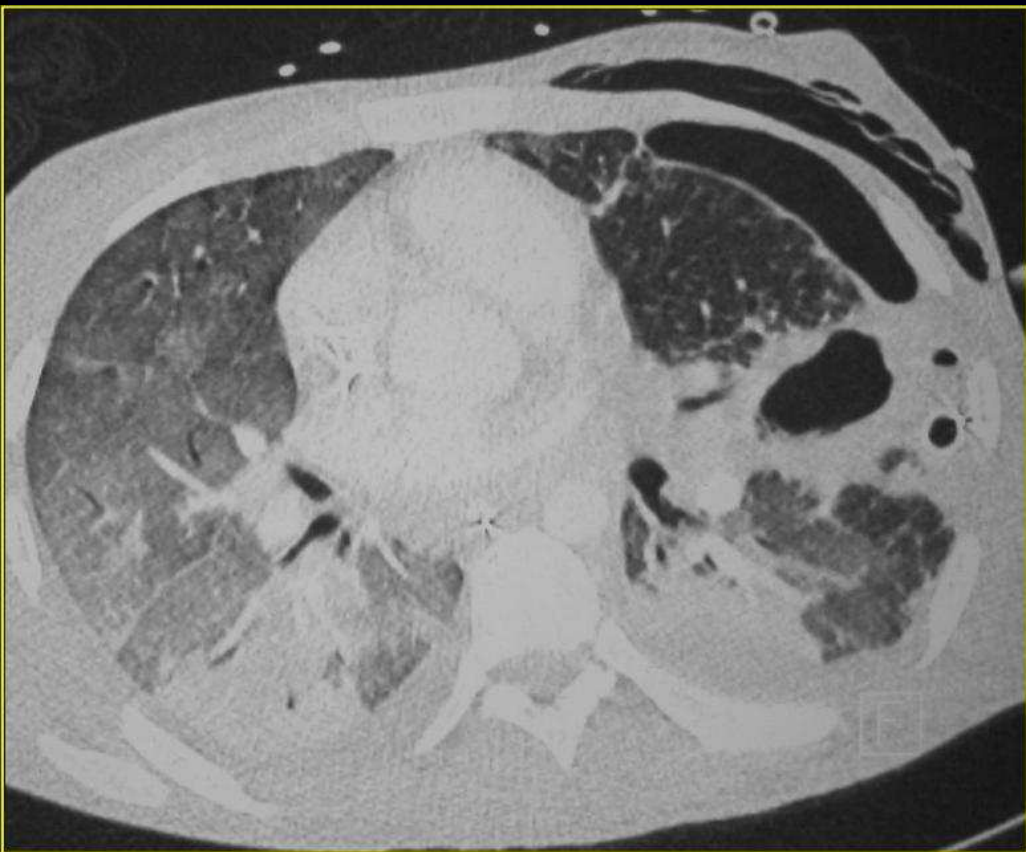**50% after > 4 days**

- (Tension) pneumomediastinum**
- (Tension) pneumothorax**
- (Tension) pneumopericardium**
- (Tension) pneumoperitoneum**
- Rarely gas embolism**





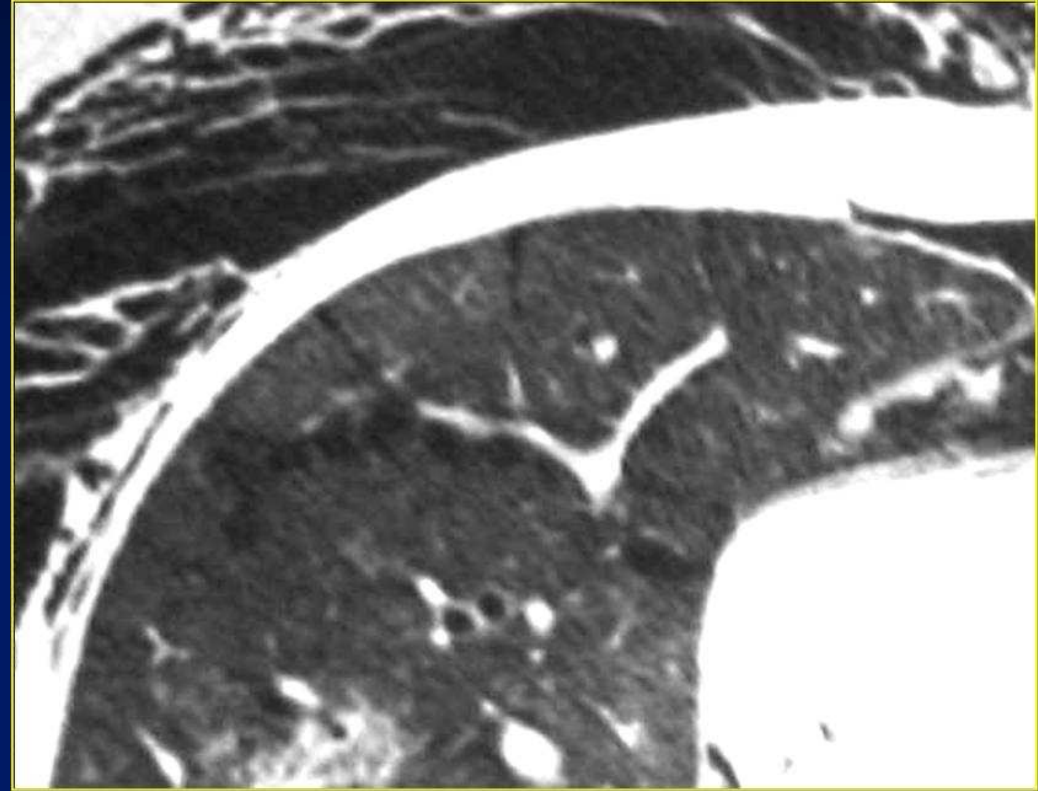
CT # 1



# Pulmonary Interstitial Emphysema

## Differential diagnosis between pulmonary interstitial emphysema and bronchus

- Localisation
- Not limited by a wall
- No diameter tapering from hilum to periphery
- Air on both sides of the vessel  
(bronchus : external side of vx in UL and internal side in LL, ML and lingula)
- Target sign (in perpendicular plane)

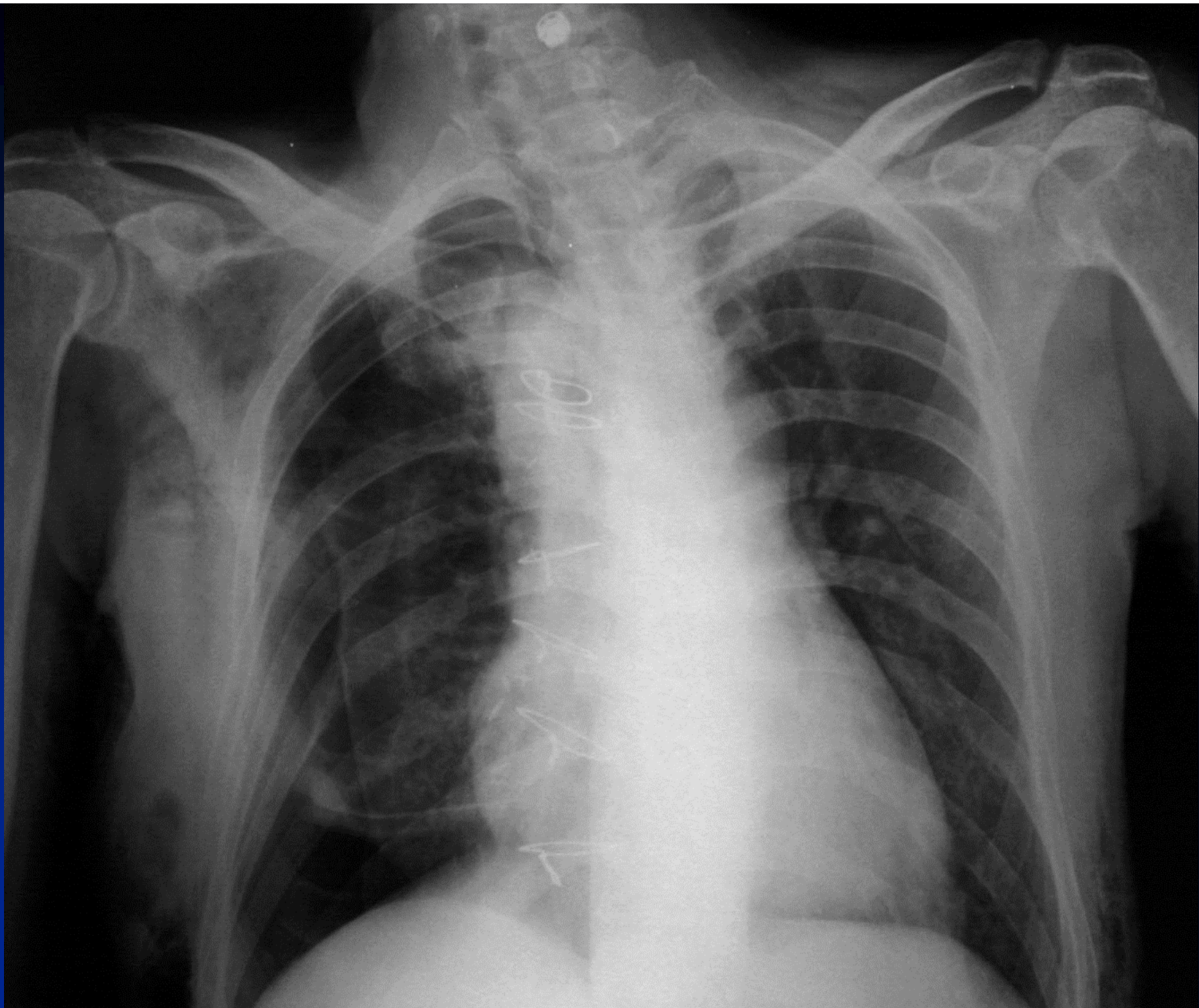


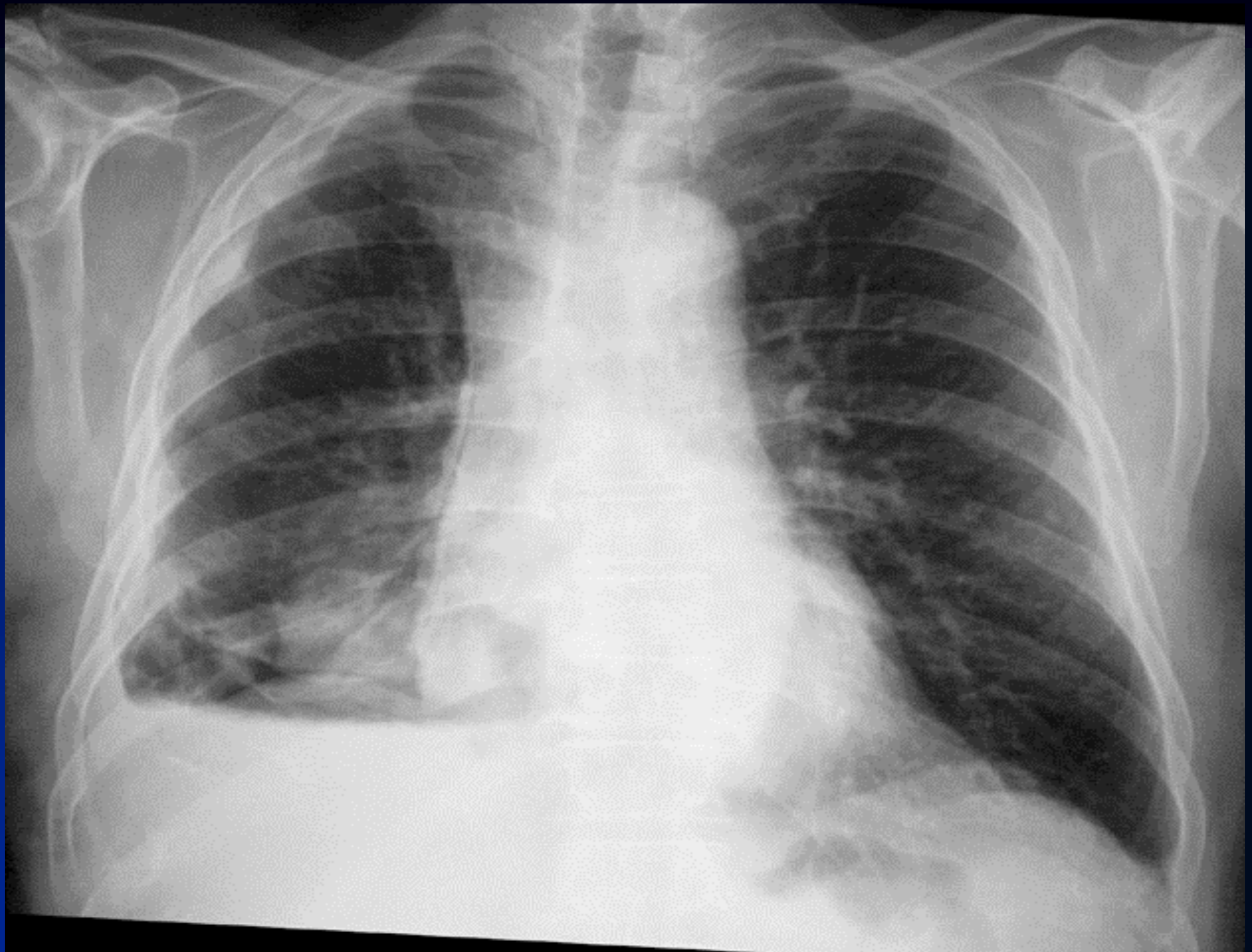


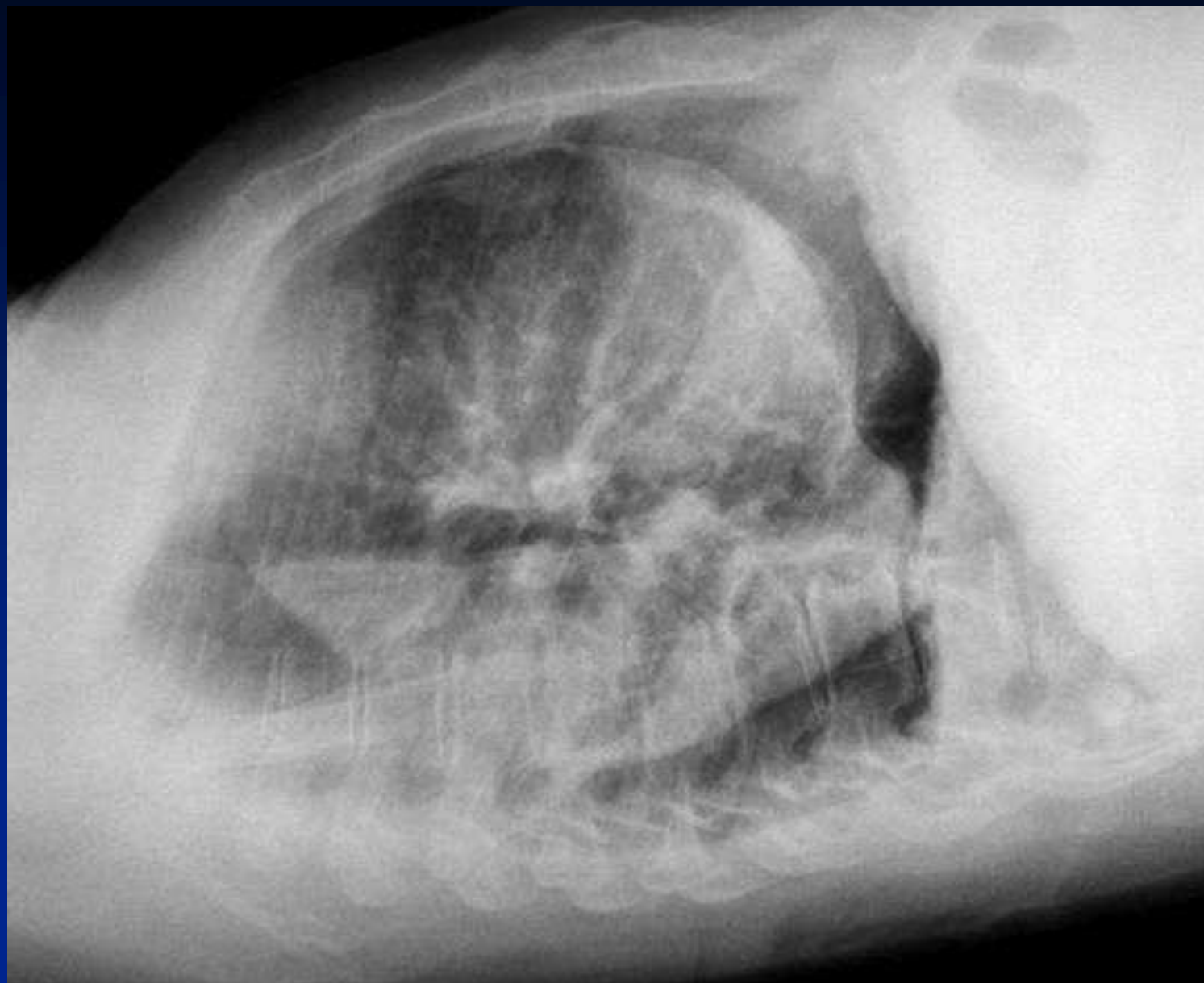
# CHEST IMAGING IN ICU

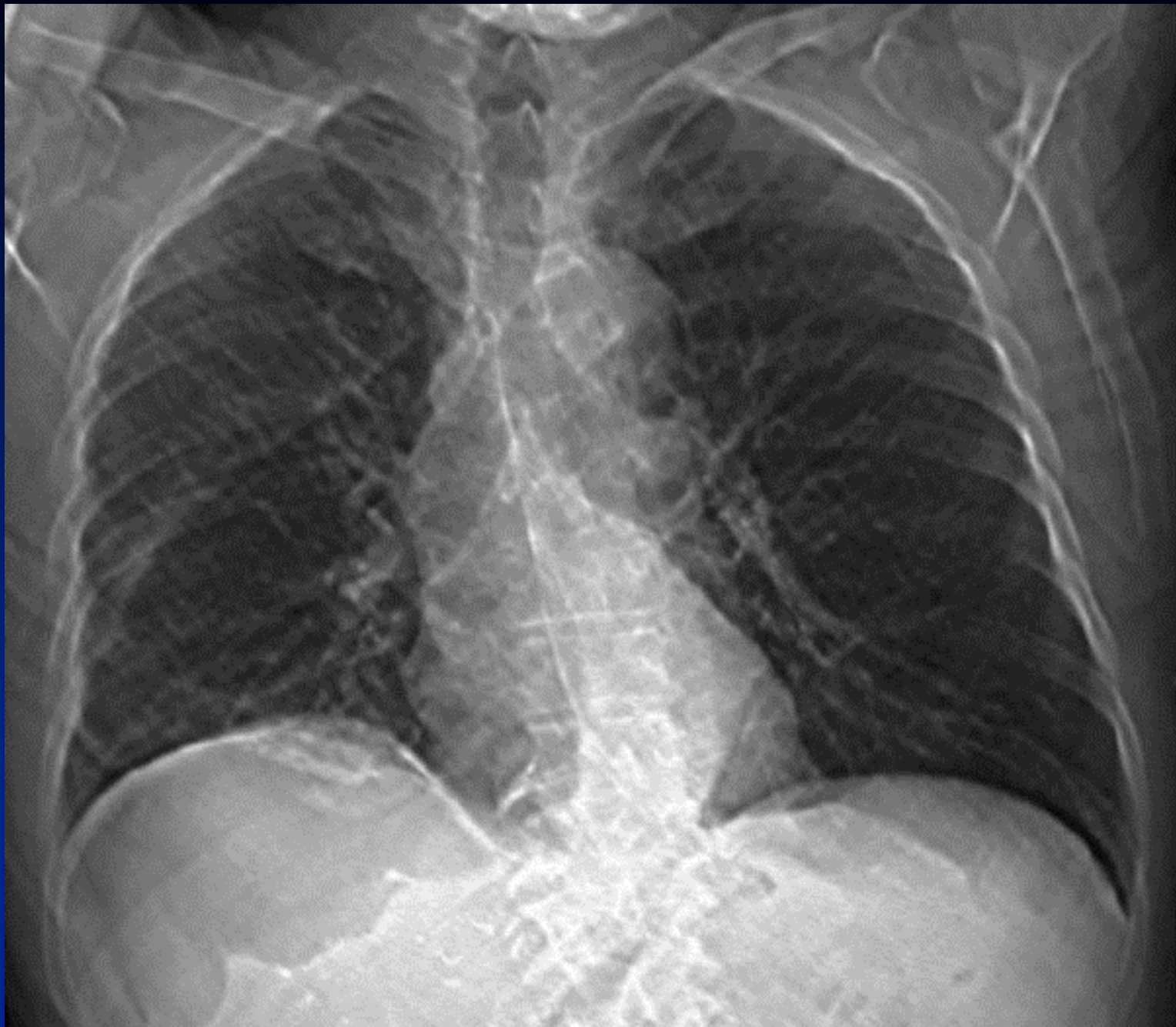## PNEUMOTHORAX

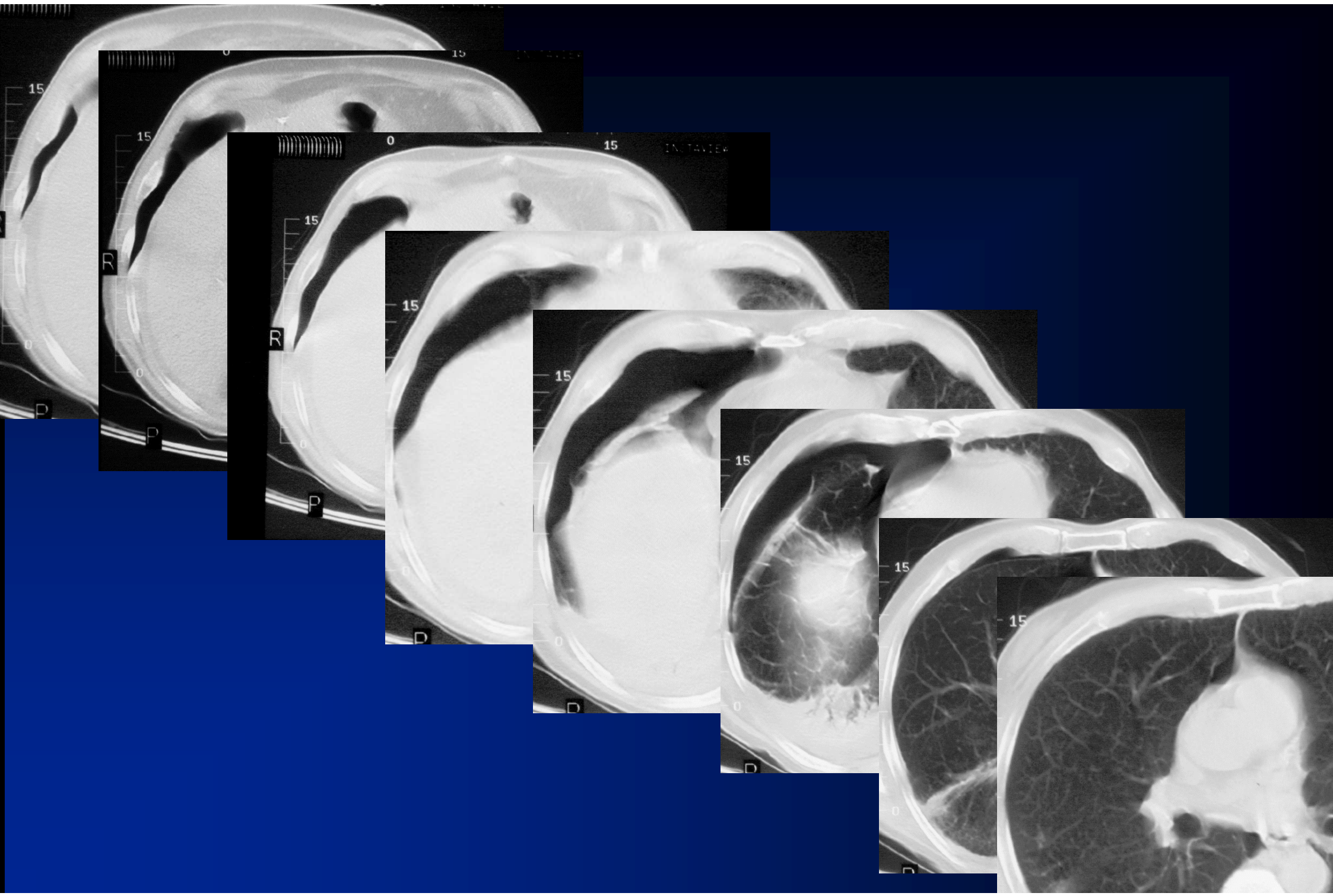
- **Position of the patient:**
  - supine** → anteromedial or subpulmonic recesses
    - basal hyperlucency
    - enhanced sharpness of adjacent structure
    - “double diaphragm sign”
    - “deep sulcus sign”
    - pericardial fat tags
    - inferior edge of collapsed lung
- **Underlying pleural or parenchymal disease**
  - pleural adhesions
  - collapsed or consolidated lung
  - alteration of chest wall recoil

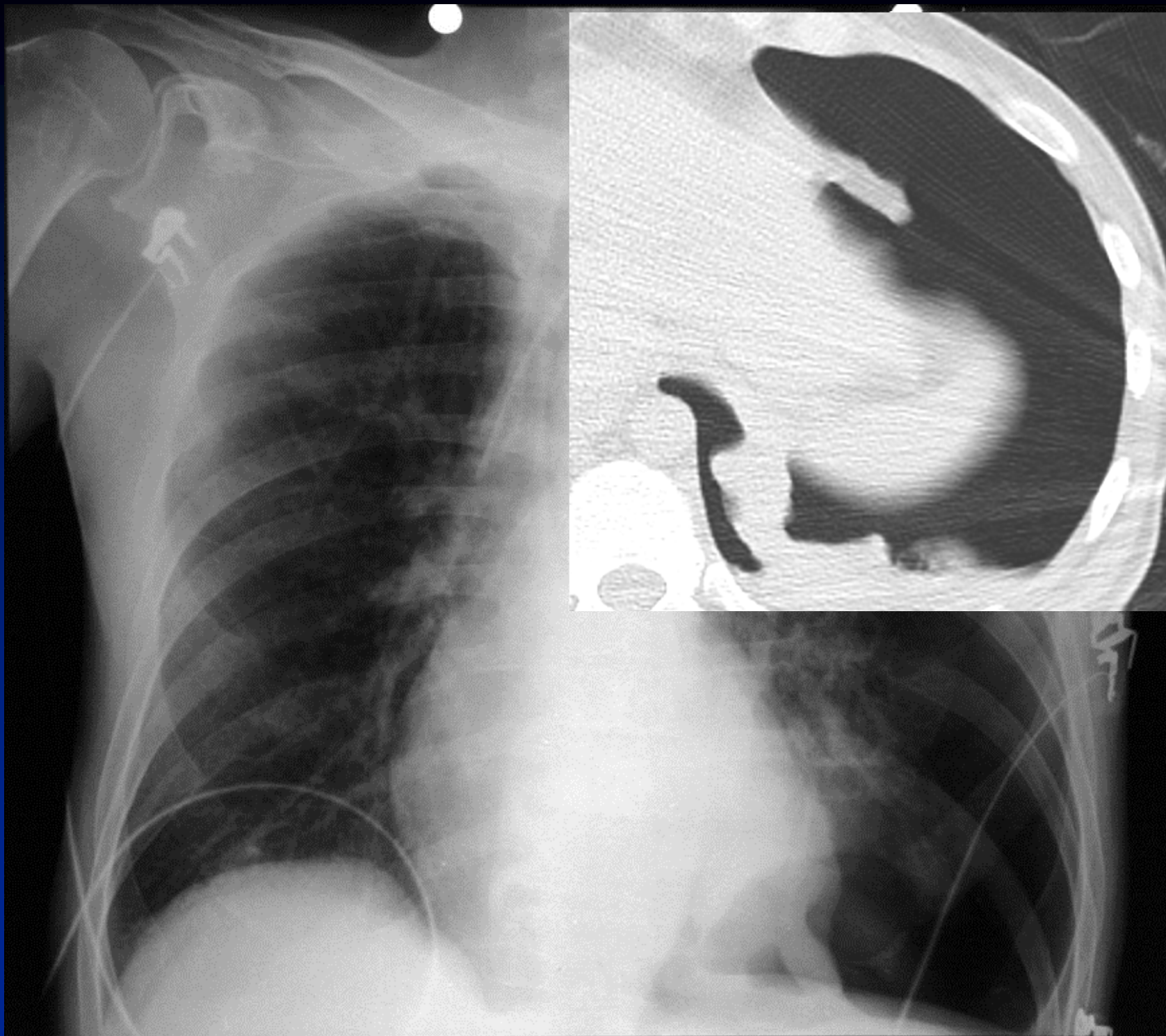


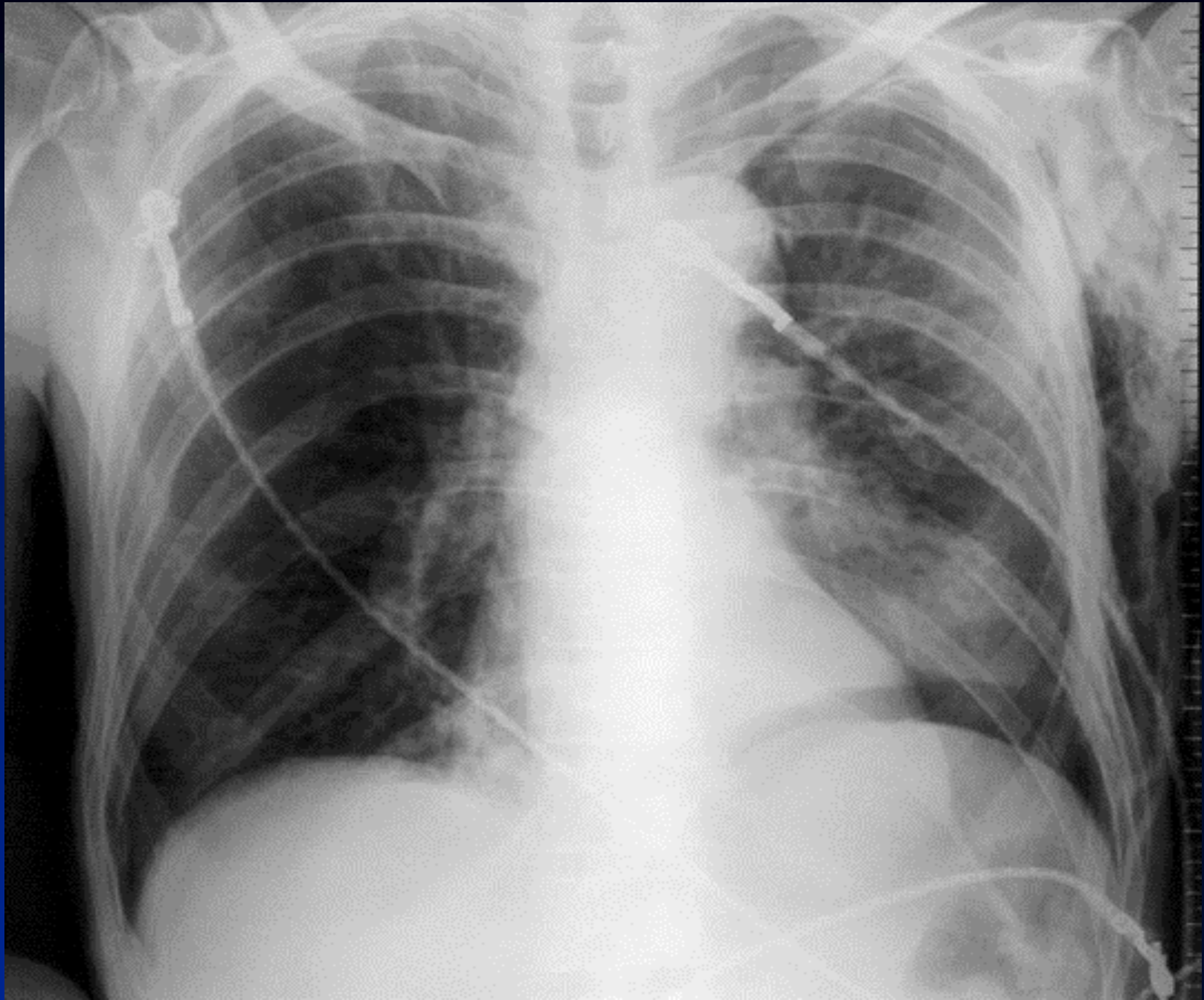








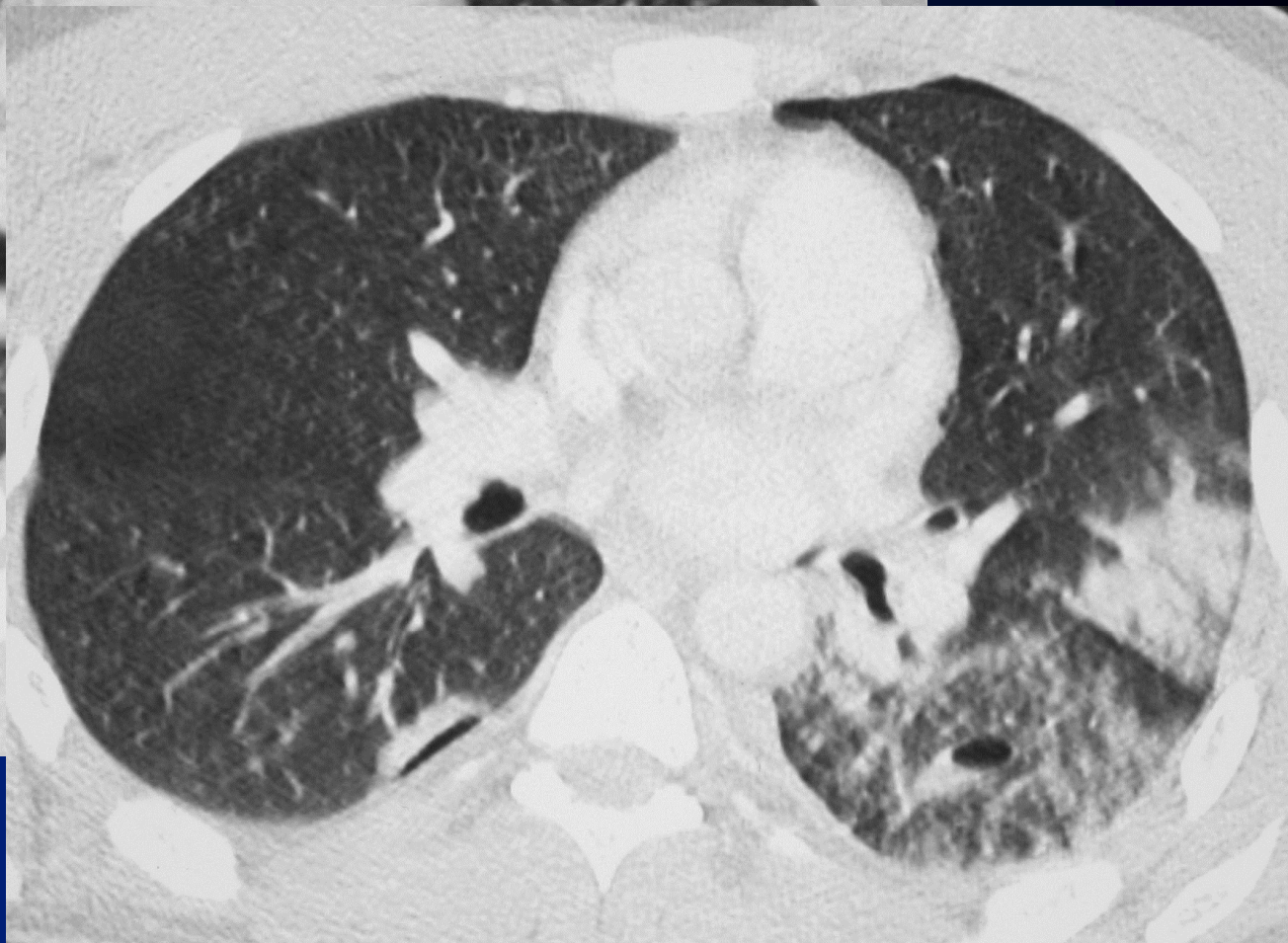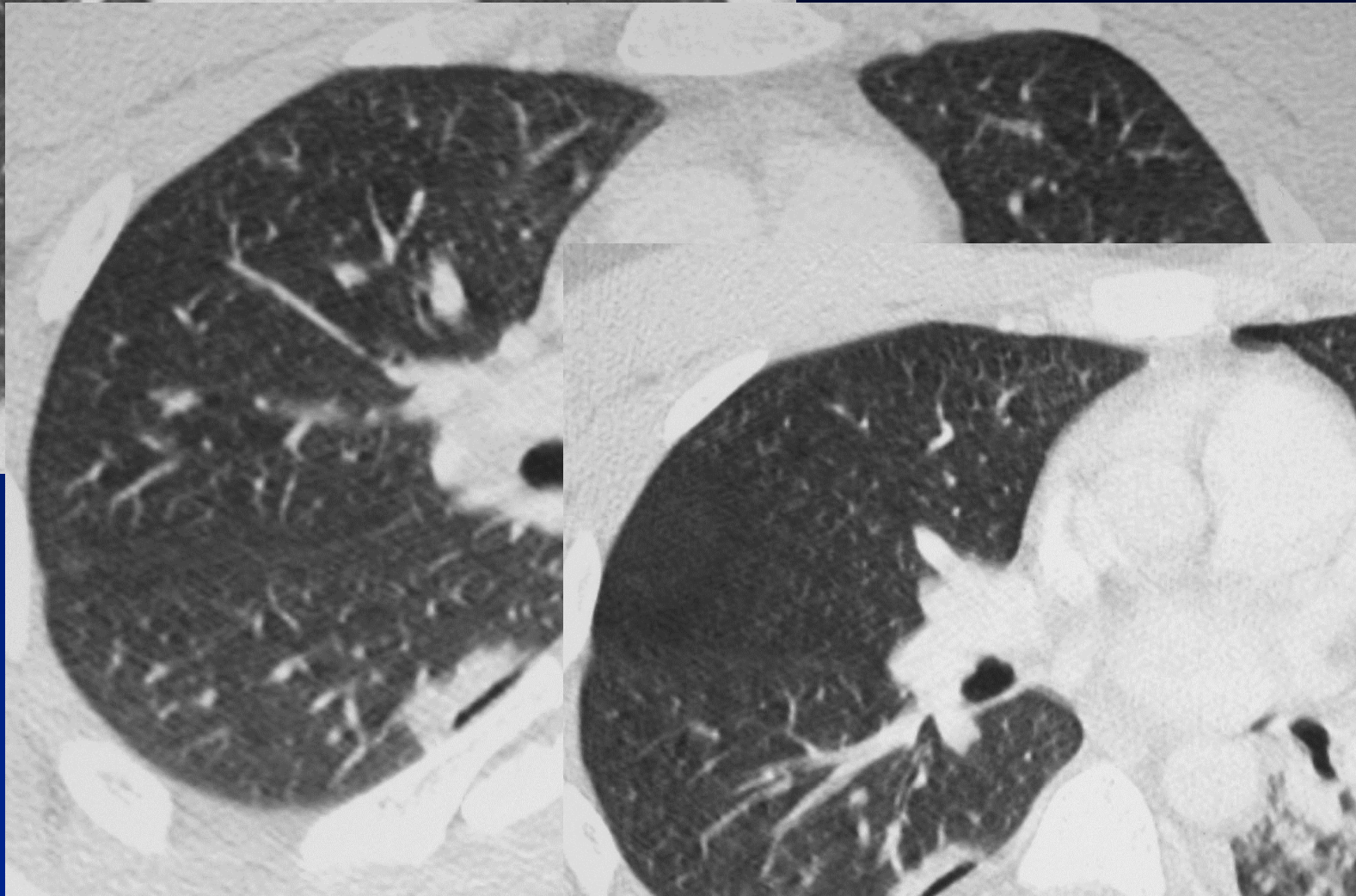
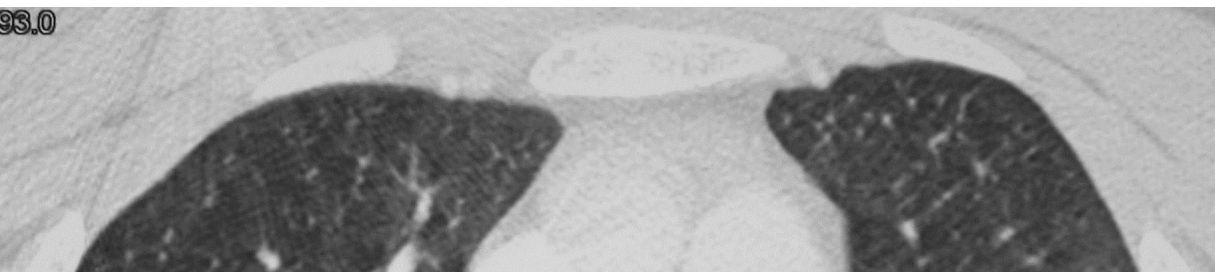






93.0

0  
s 176  
s 120

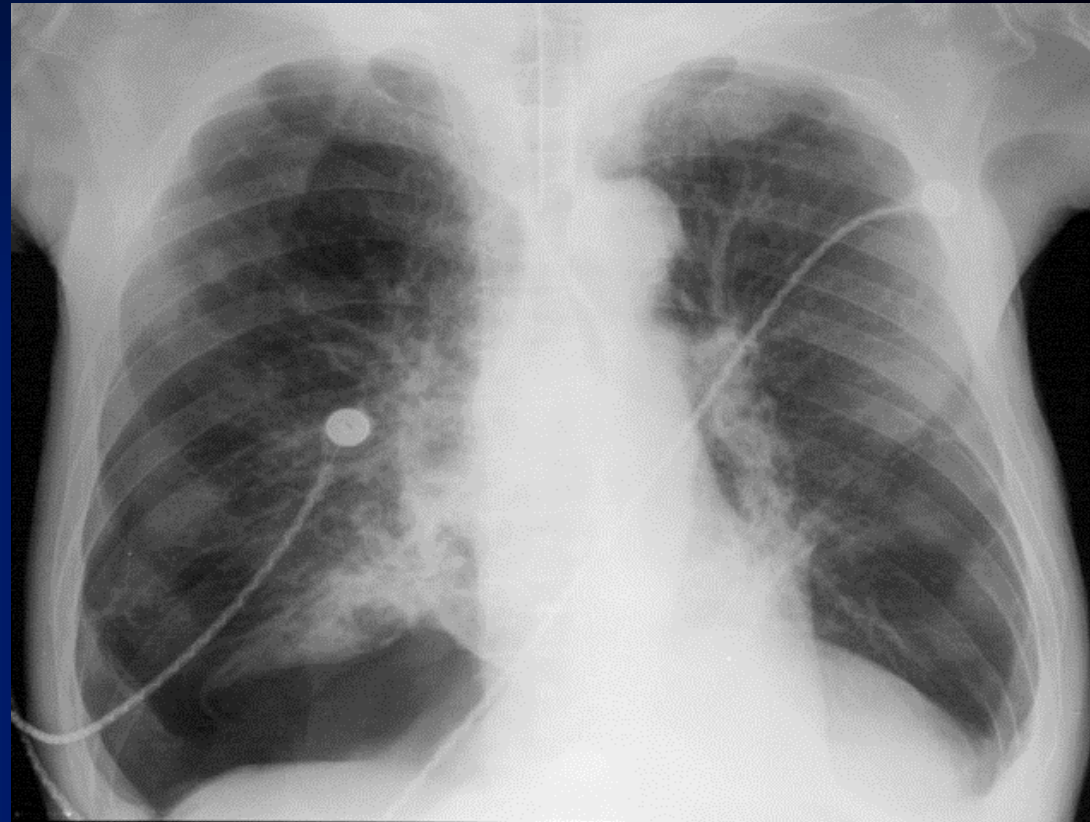


# CHEST IMAGING IN ICU

## PNEUMOTHORAX

### TENSION PNEUMOTHORAX

- **Striking collapse of the lung**
- **Contralateral mediastinal shift**
- **Straightened heart border**
- **Compressed SVC and IVC**
- **Widened intercostal spaces**
- **Flattening or inversion of hemidiaphragm**



# **Pleural injuries**

## **Fluid**

- **Blood or chyle**
- **Typically low-pressure and self-limited**
- **May appear for several hours after trauma**

# Pleural injuries

## Effusions

- **Radiographie du thorax**
  - opacité non systématisée
  - homogène, déclive, mobile
  - délimitée par une courbe concave vis à vis du poumon (courbe de Damoiseau)
  - en fonction du volume
    - localisation sous-basale ( $\leq 150$  ml)
    - comblement des culs de sacs postérieurs puis latéraux ( $>150$  à  $200$  ml)
    - opacité de type pleural avec courbe de Damoiseau

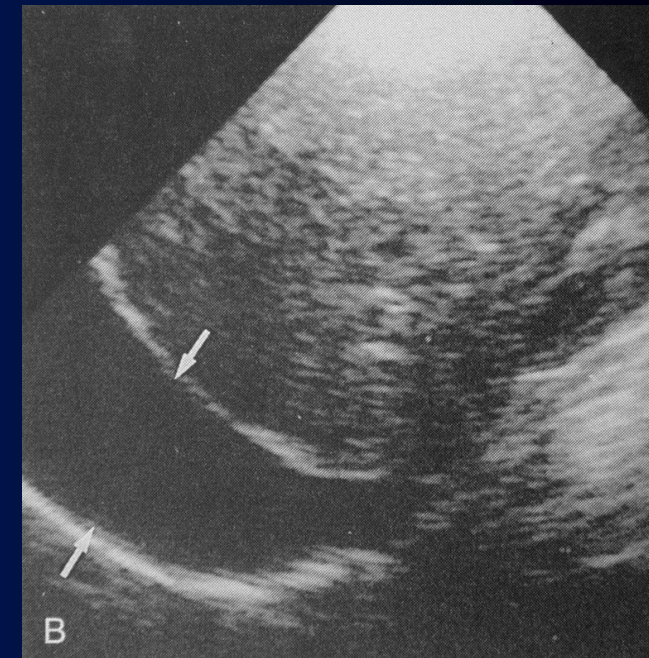
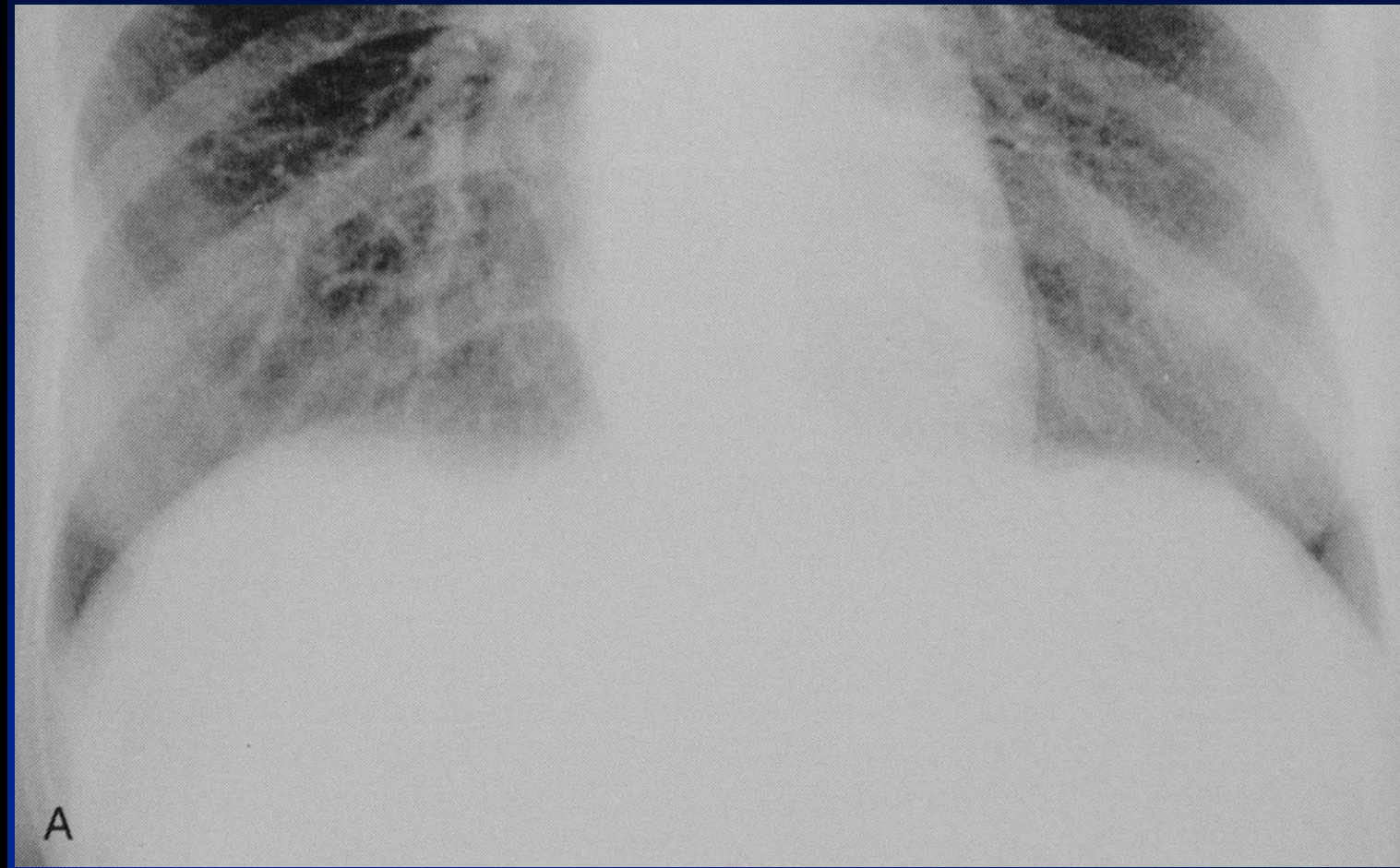
# **Pleural injuries**

## **Effusions**

- **Free fluid** → **most dependent areas**
  - **supine position**
    - **increased density of the hemithorax**
    - **preserved visibility of vessel margins**
    - **loss of limits of diaphragm**
    - **apical cap**
    - **meniscus sign**
    - **fluid in fissures**

# Pleural injuries

## Effusions



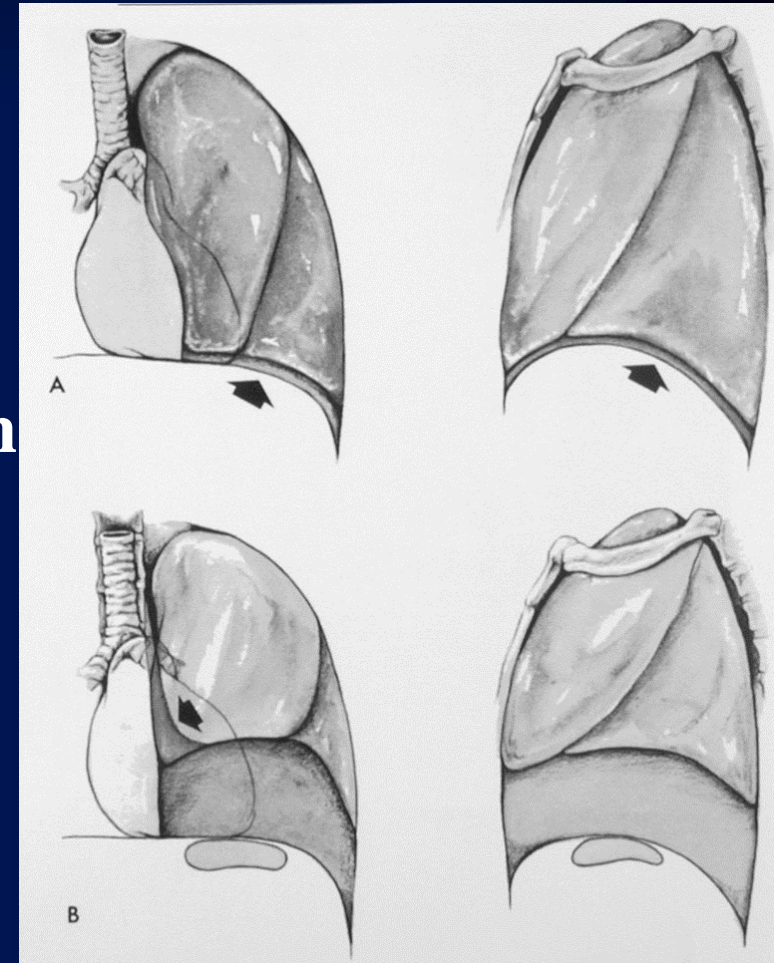
# Pleural injuries

## Effusions

**Semi-upright or upright position**

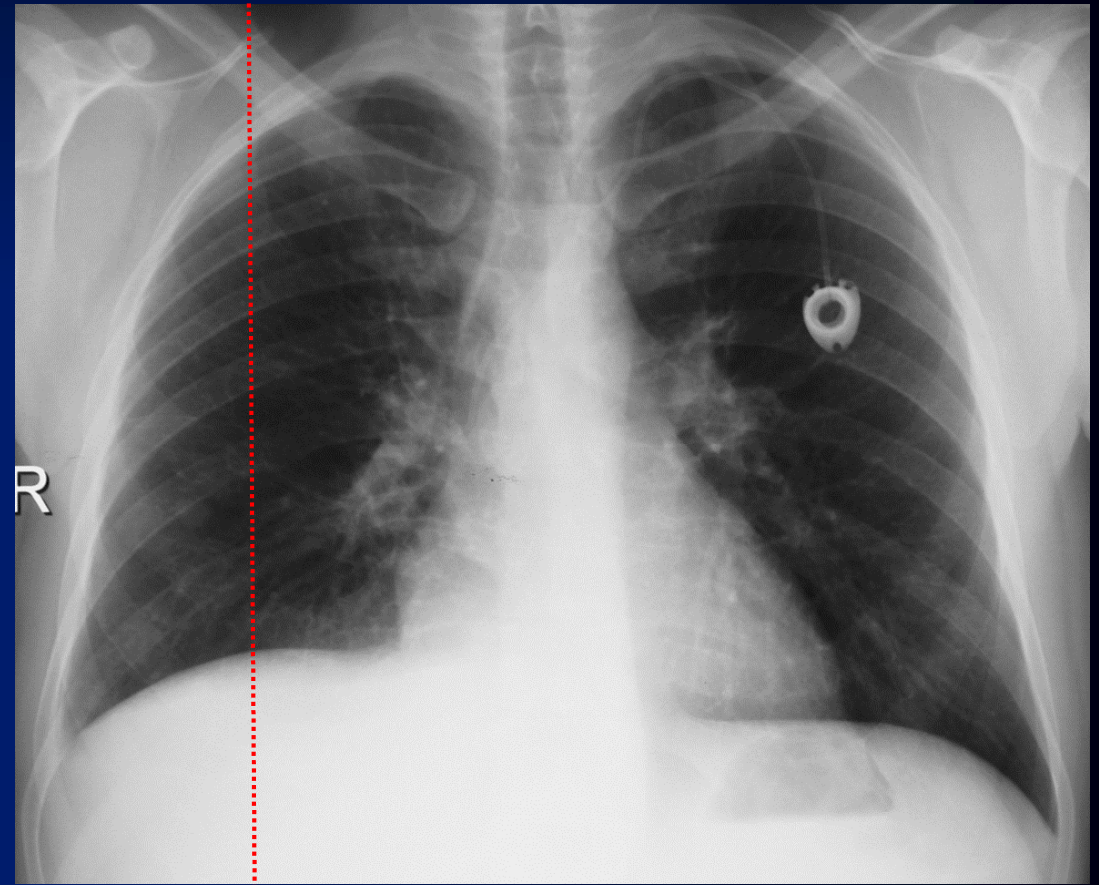
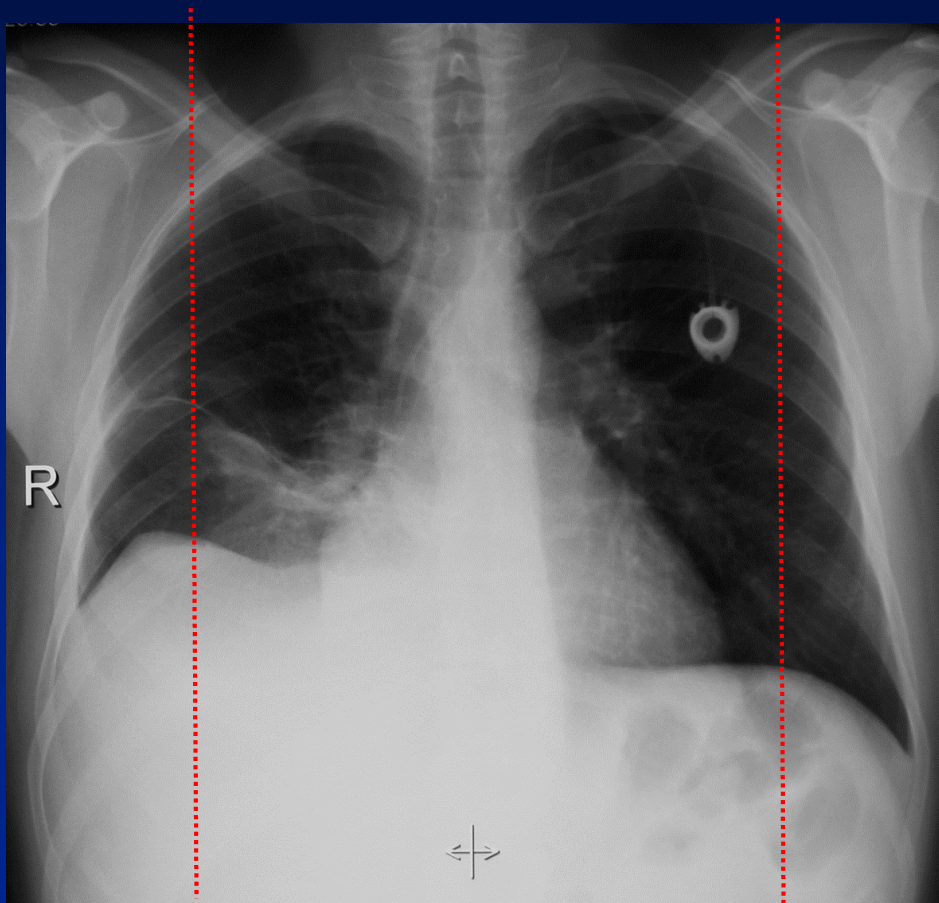
→ **subpulmonic effusion**

- apparent elevation of the hemidiaphragm
- lateral displacement of the hemidiaphragm
- visibility of lower lobe vascularity ↘
- density of liver or spleen ↗



# Epanchement sous-pulmonaire

1.



Après thoracocentèse

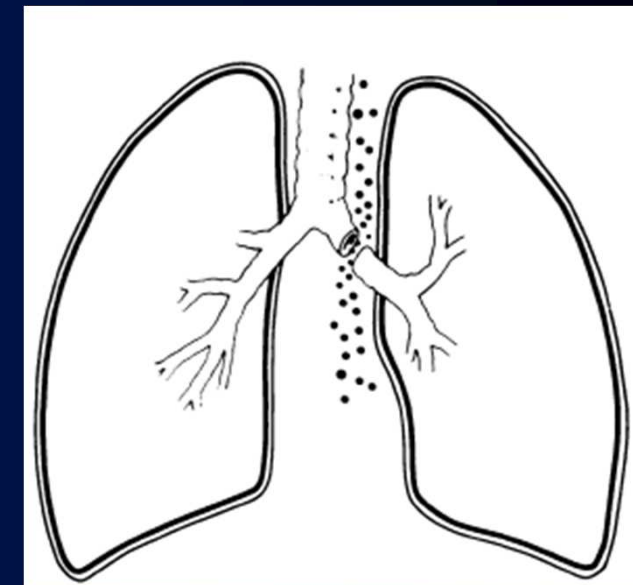
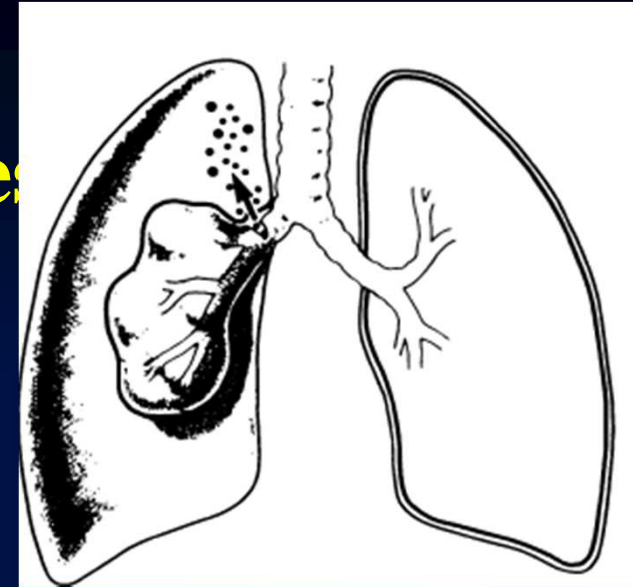


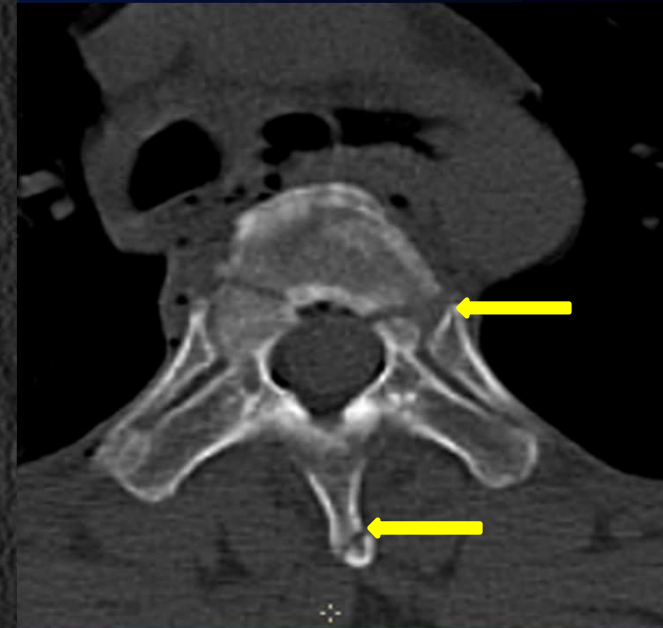
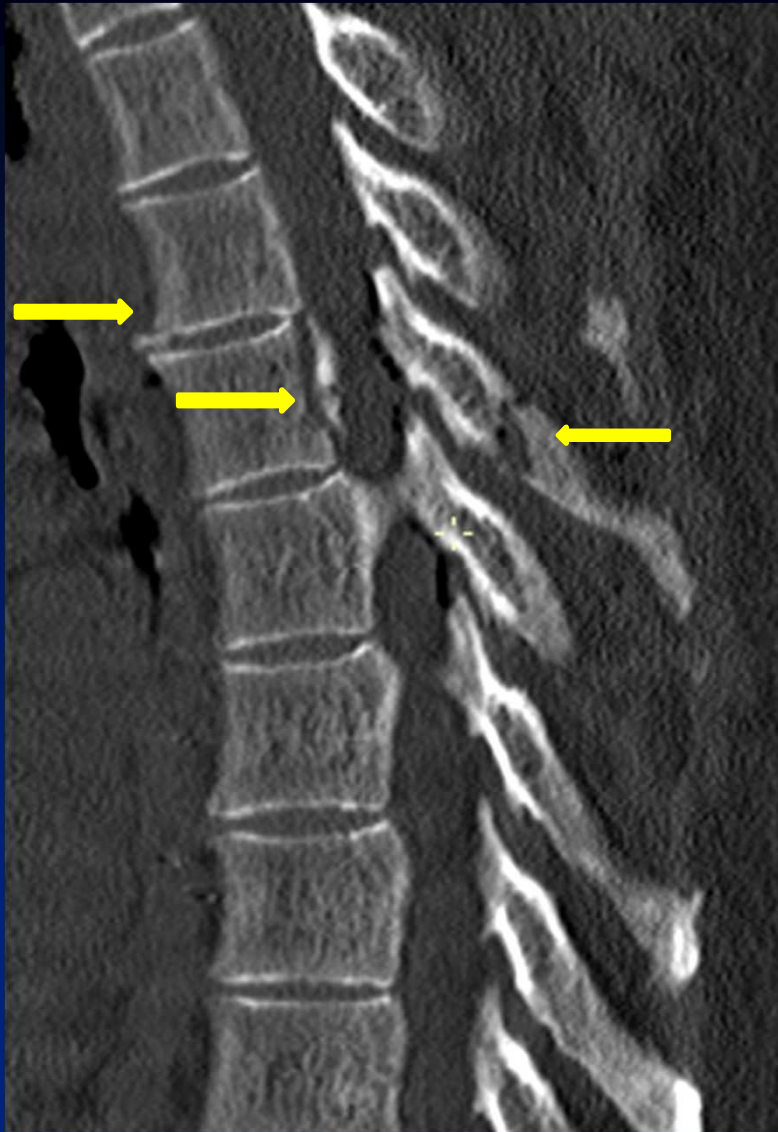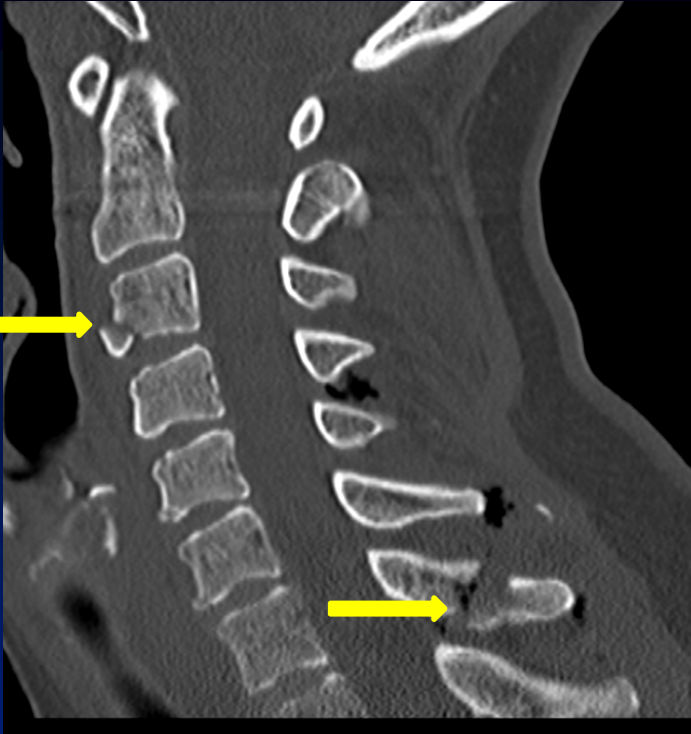# Tracheobronchial injuries

- 1 % of major chest trauma
- 30 % mortality
- Compression, shearing forces, ↗ intraluminal pressure
- 80 % within 2.5 cm from carina (RMB)
- Often associated with # (first three ribs)
- Partial or complete
- Clinical signs variable (mechanical ventilation!)
- Delayed diagnosis (increasing air in mediastinum, pleura, subcutaneous, stenosis, trapping, atelectasis, pneumonia)
- Bronchoscopy

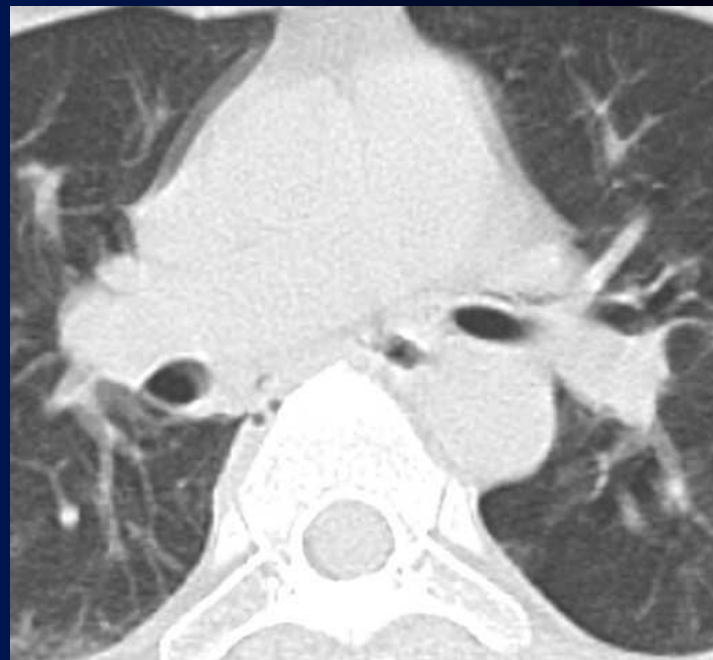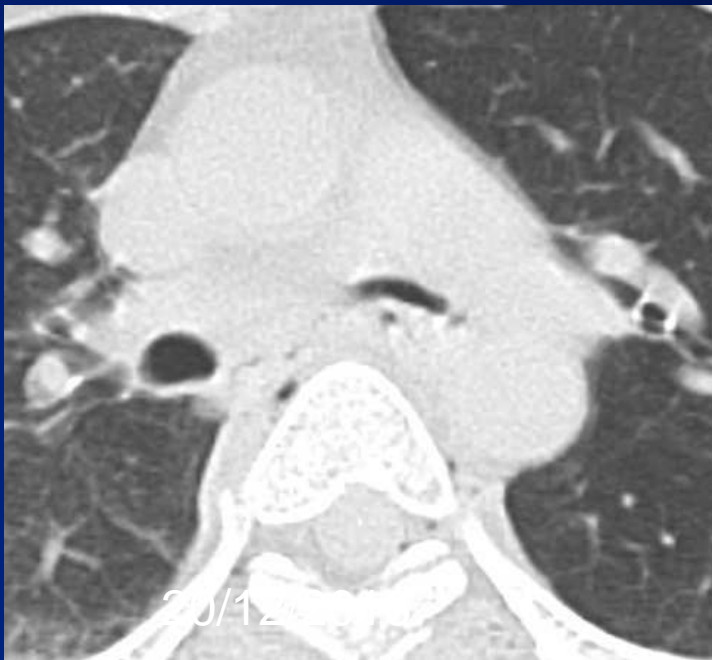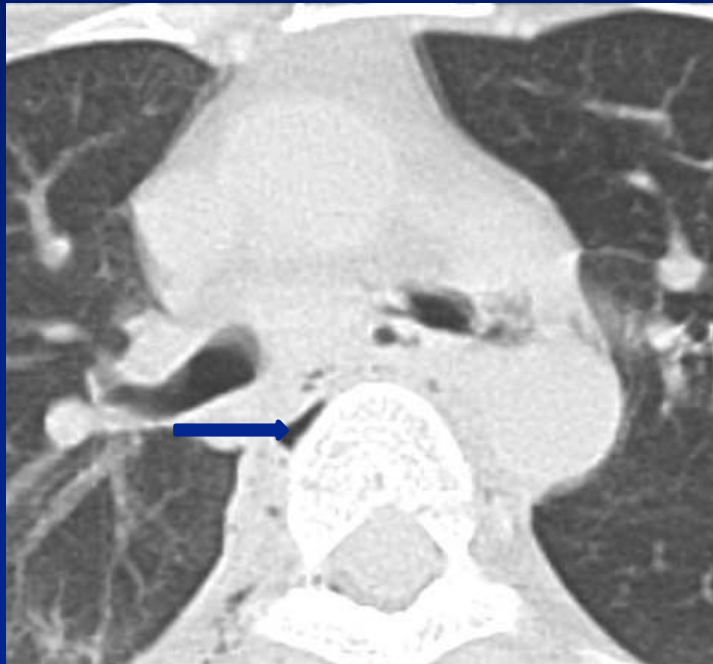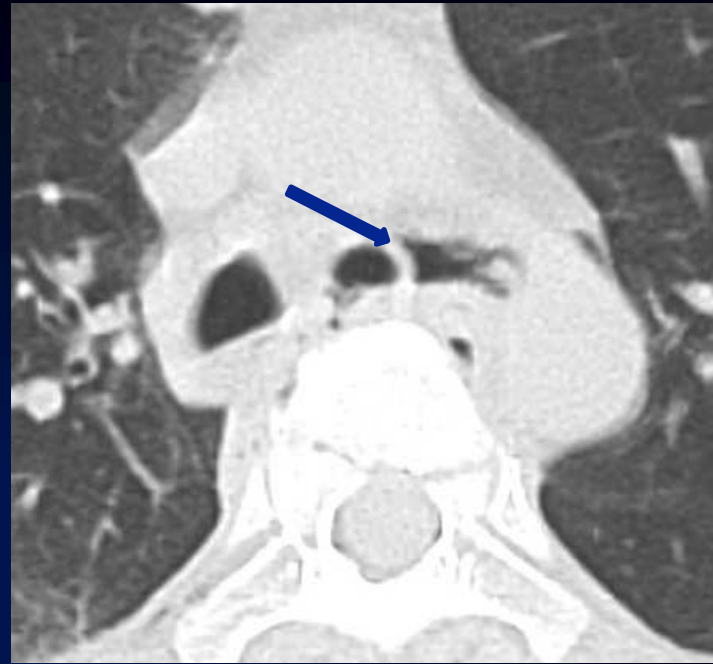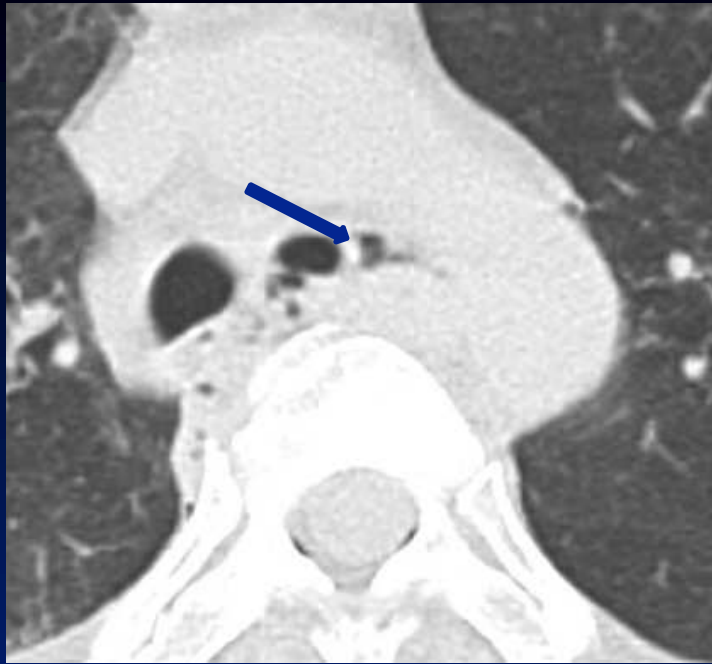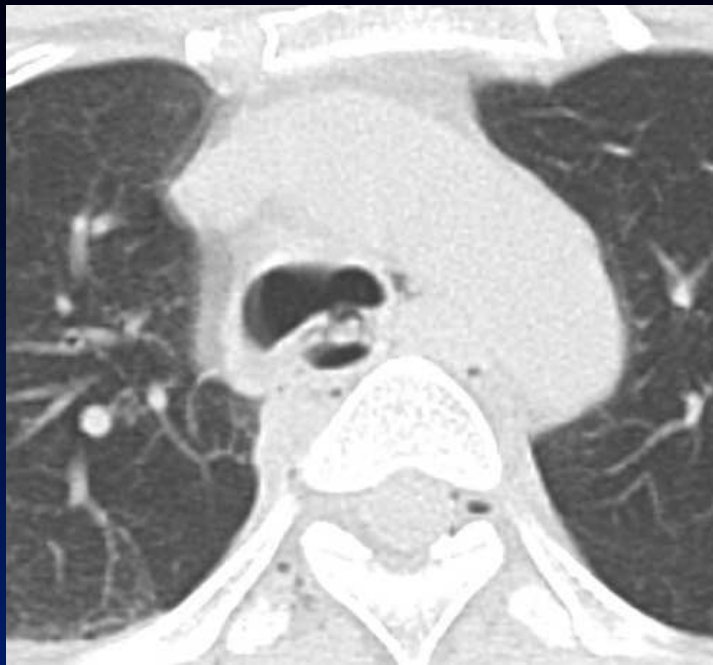## Tracheobronchial injuries

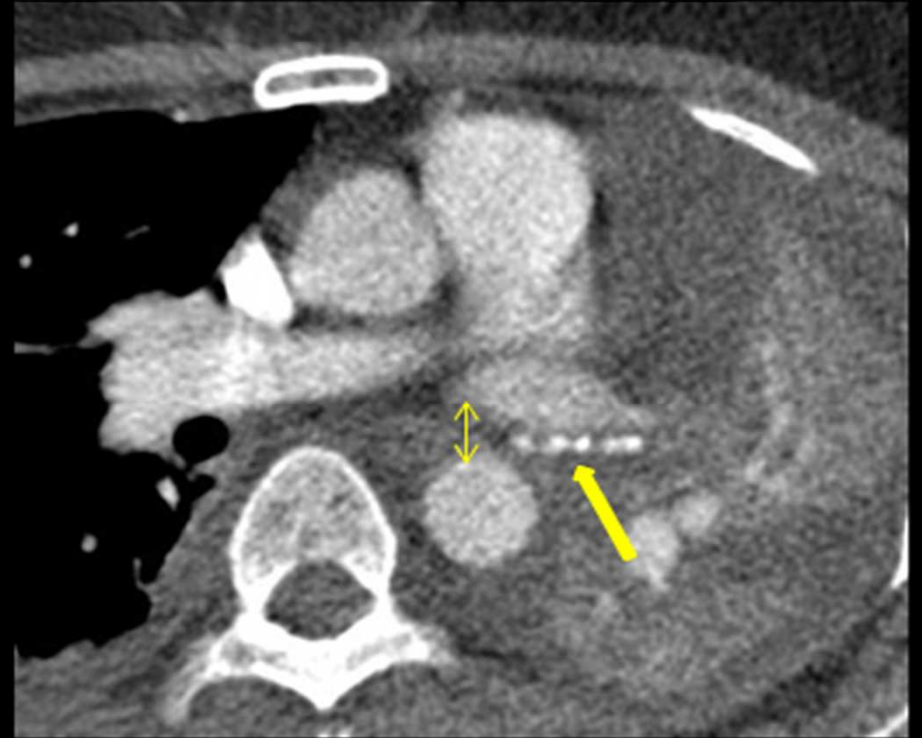
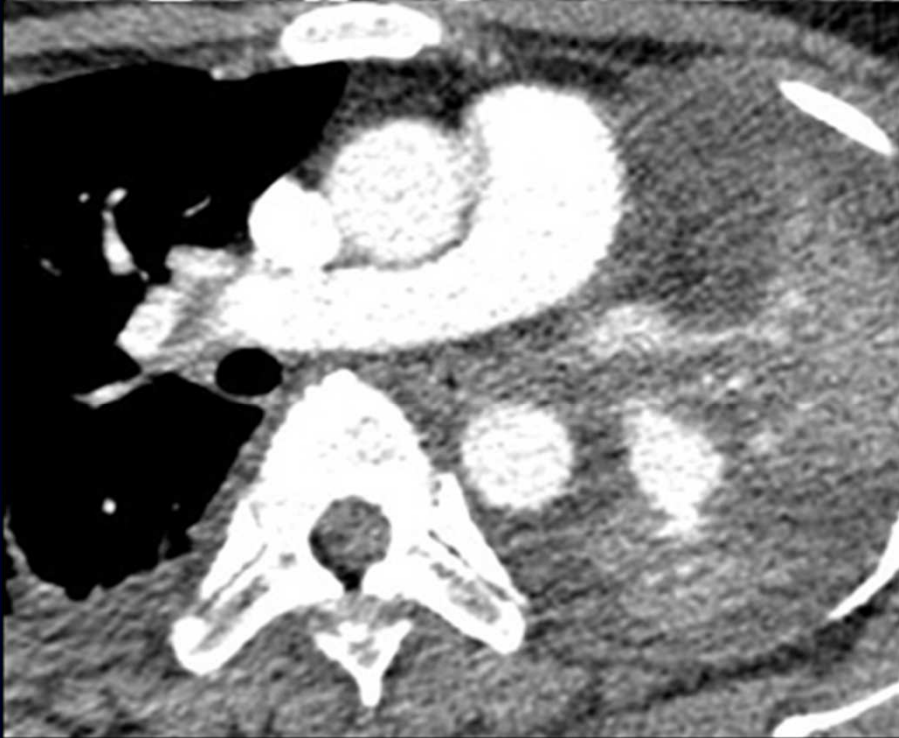
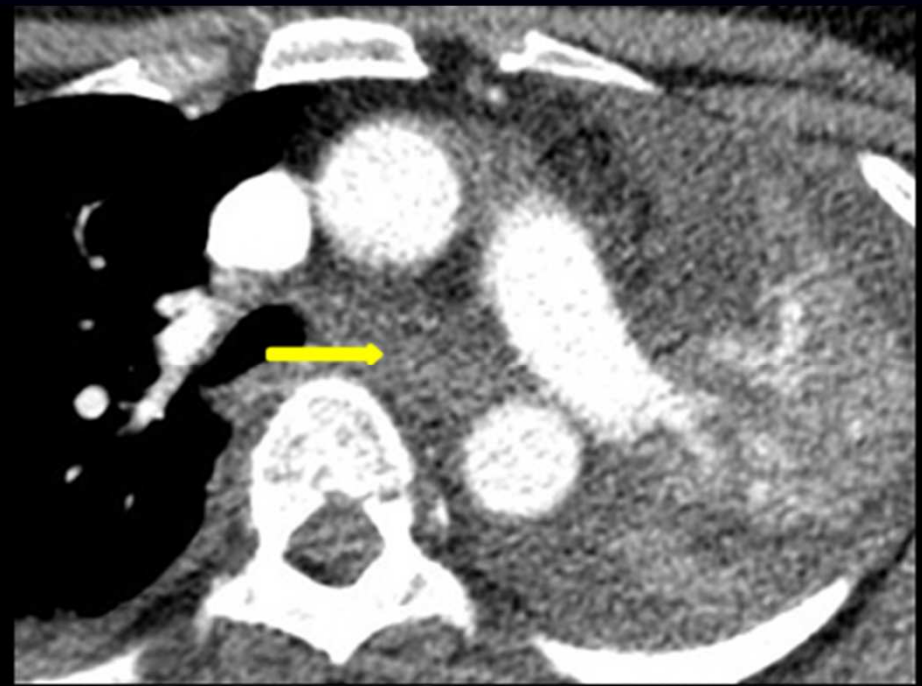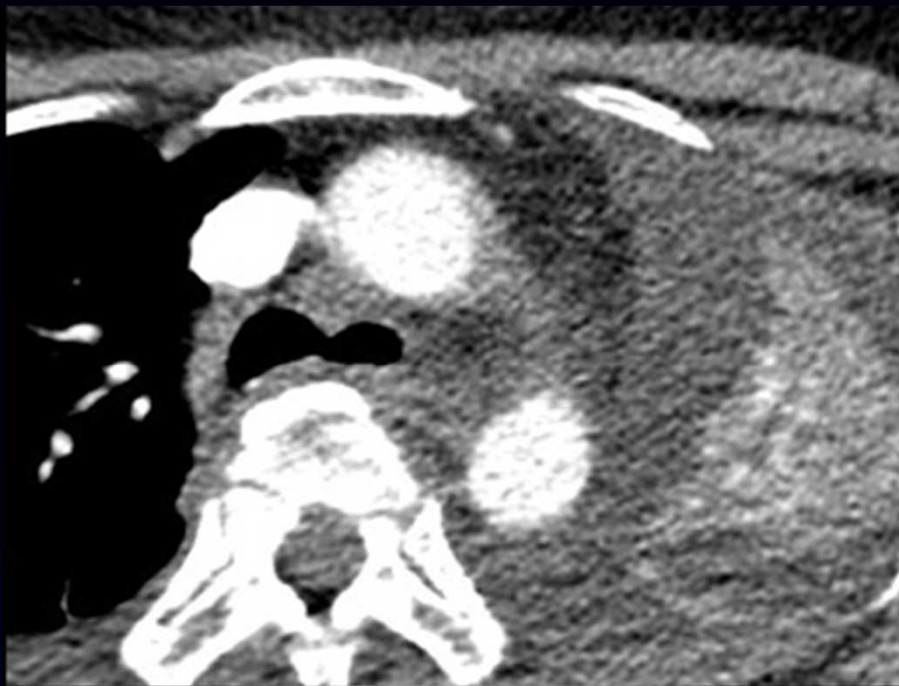
- Pneumomediastinum (pending on location)
- Pneumothorax (pending on location)
- « P » sign (pneumothorax/mediastinum, persistent, progressive)
- « Fallen lung » sign
- Interstitial air within airway wall
- Ectopic location of ET
- Overdistention of ET cuff balloon

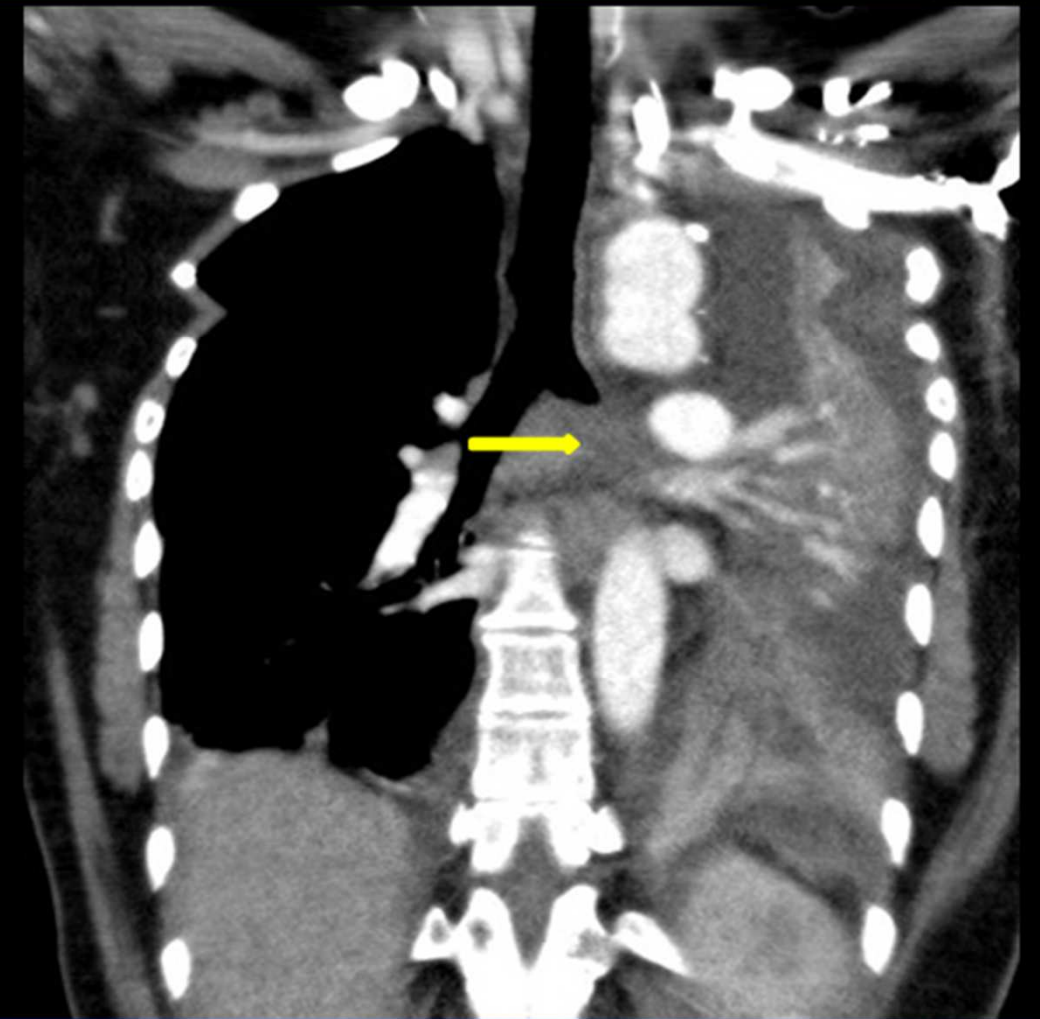
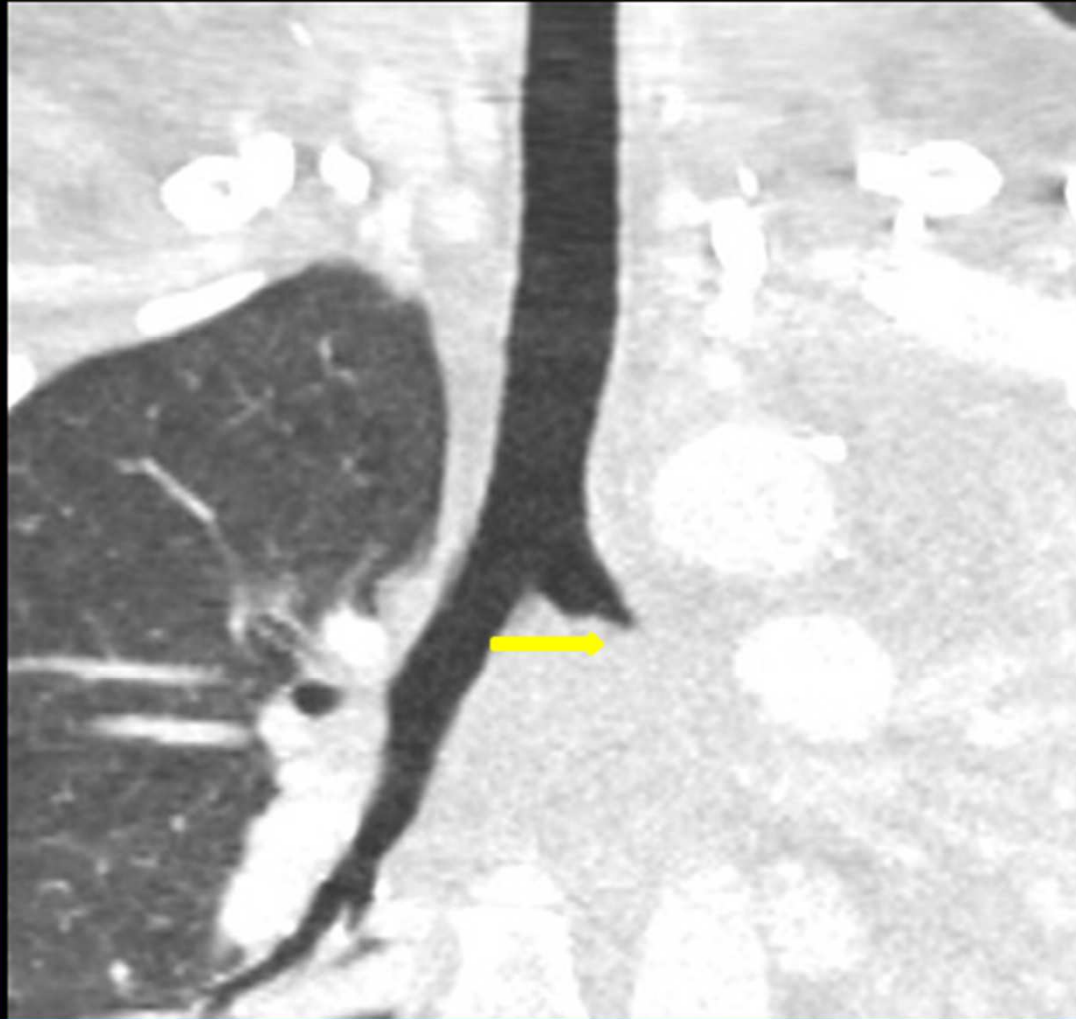


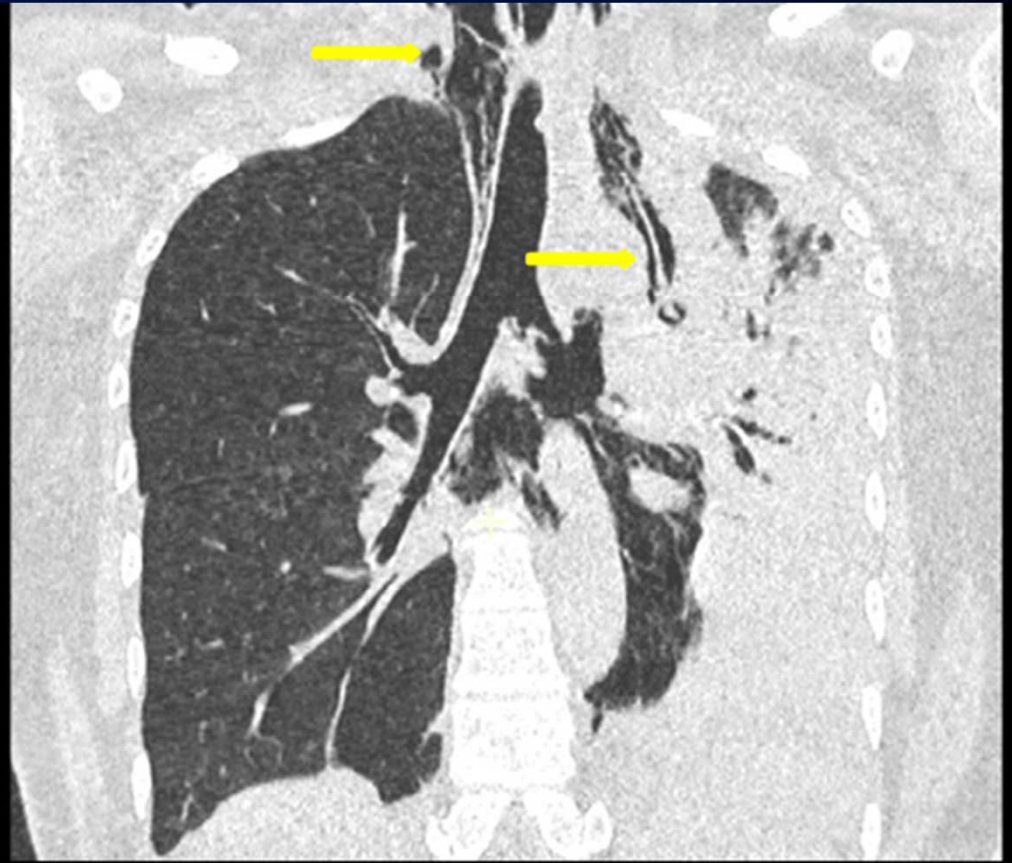
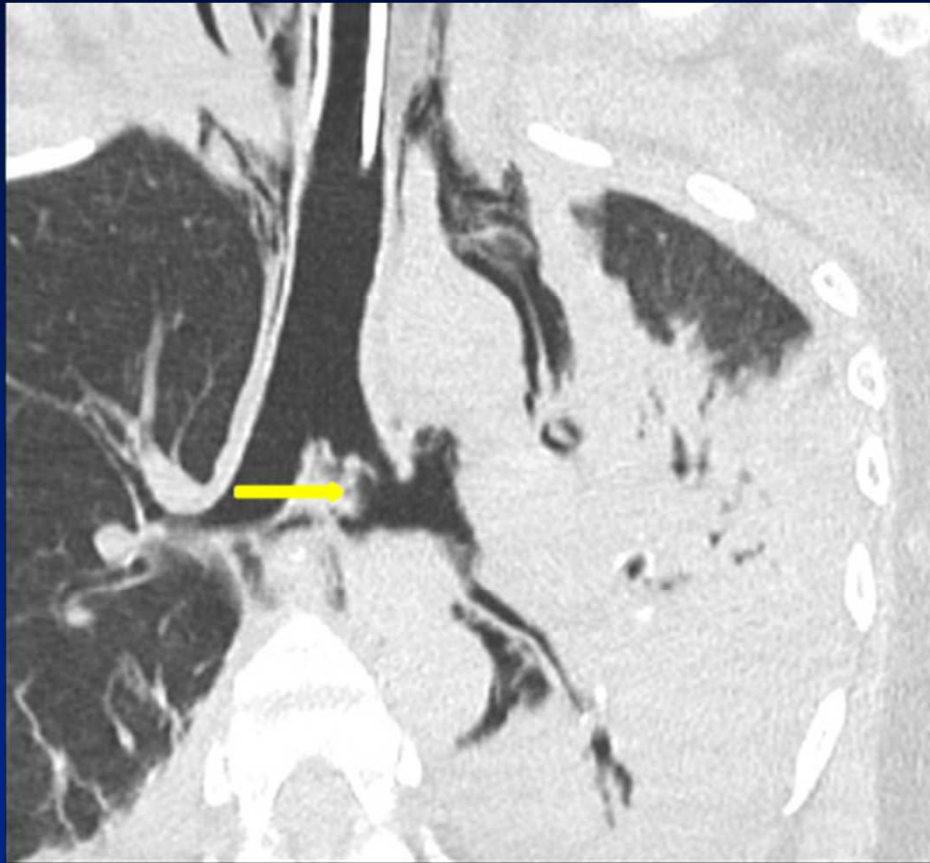


D5





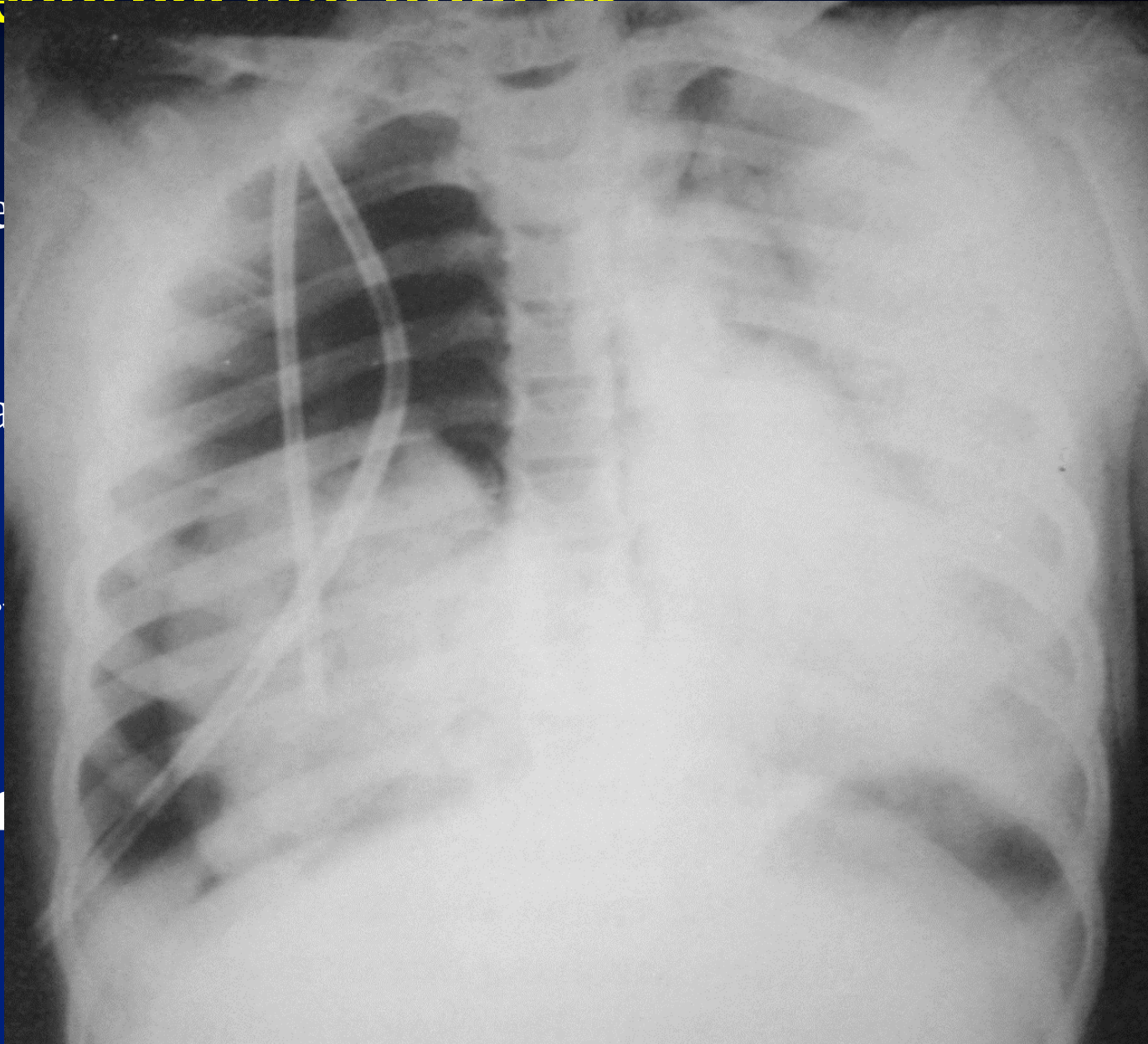




Après intubation

## Tracheobronchial injuries

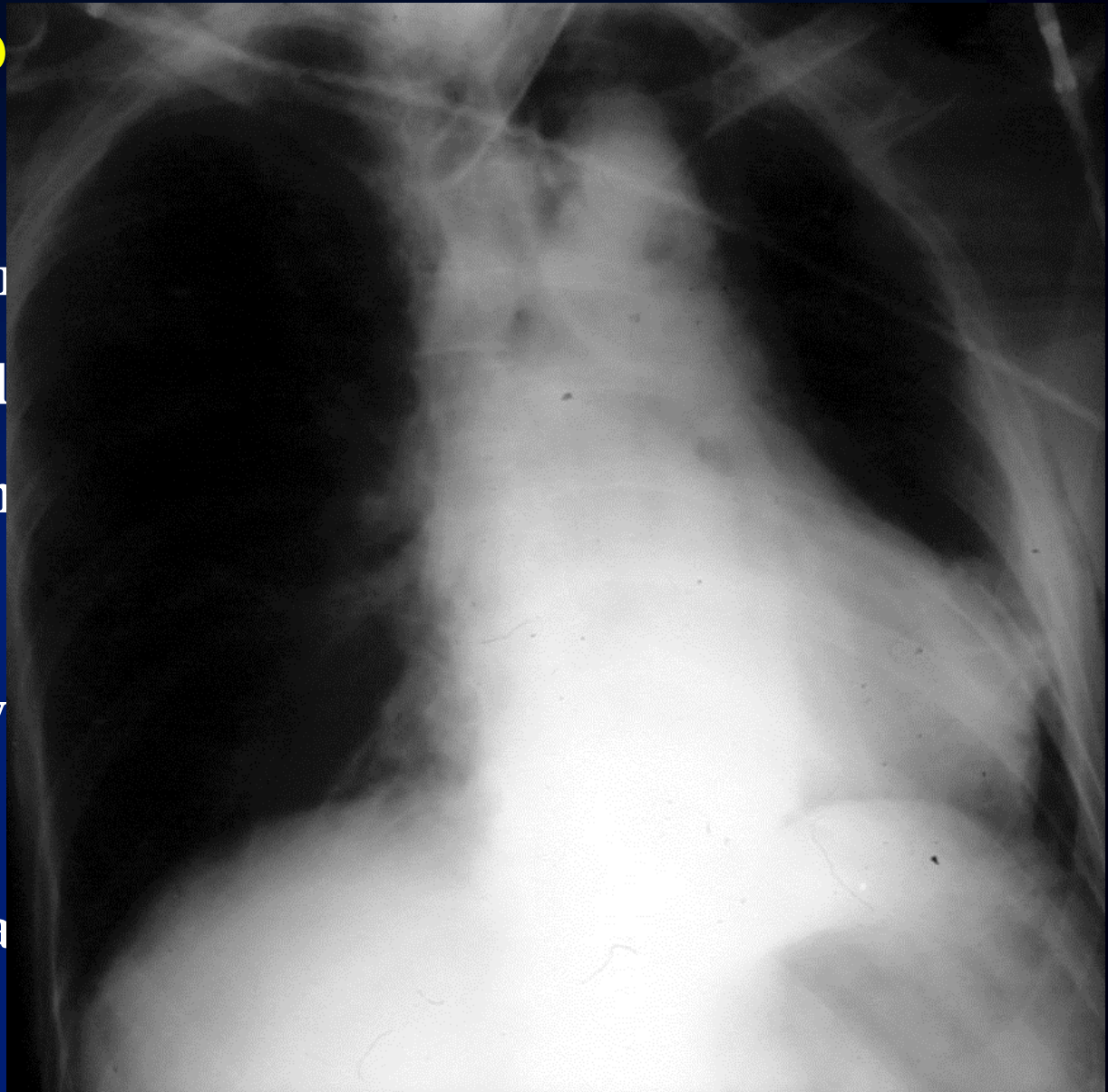
- Pneumomediastinum (pe
- Pneumothorax (pending
- « P » sign (pneumothora
- « Fallen lung » sign
- Interstitial air within air
- Ectopic location of ET
- Overdistention of ET cuff

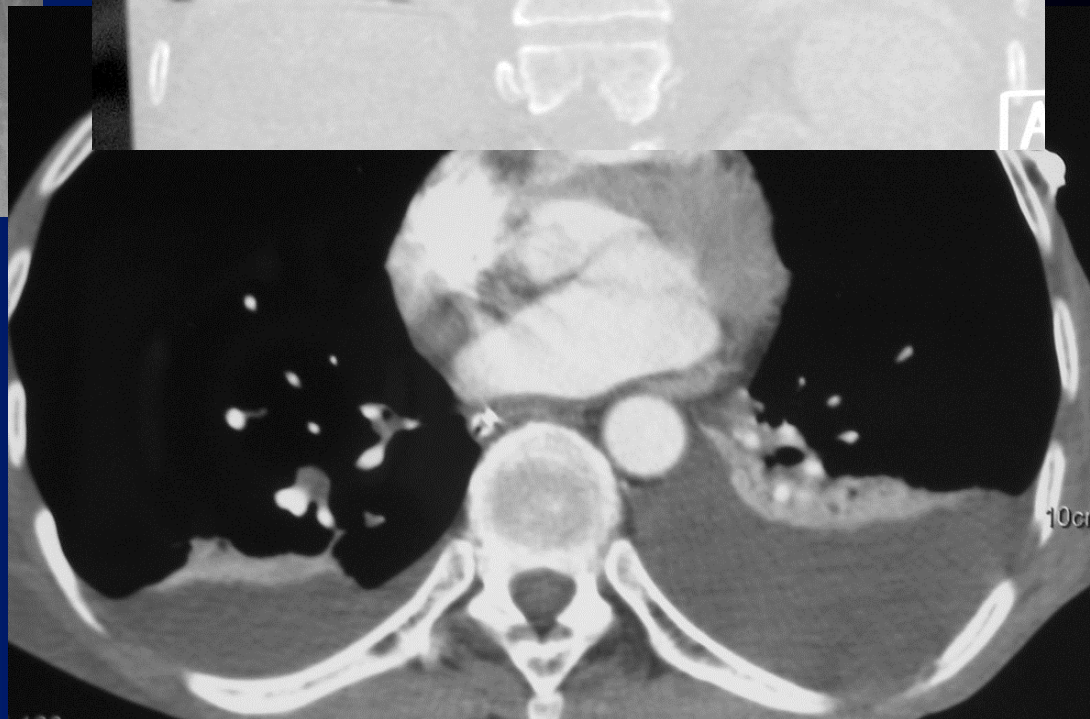
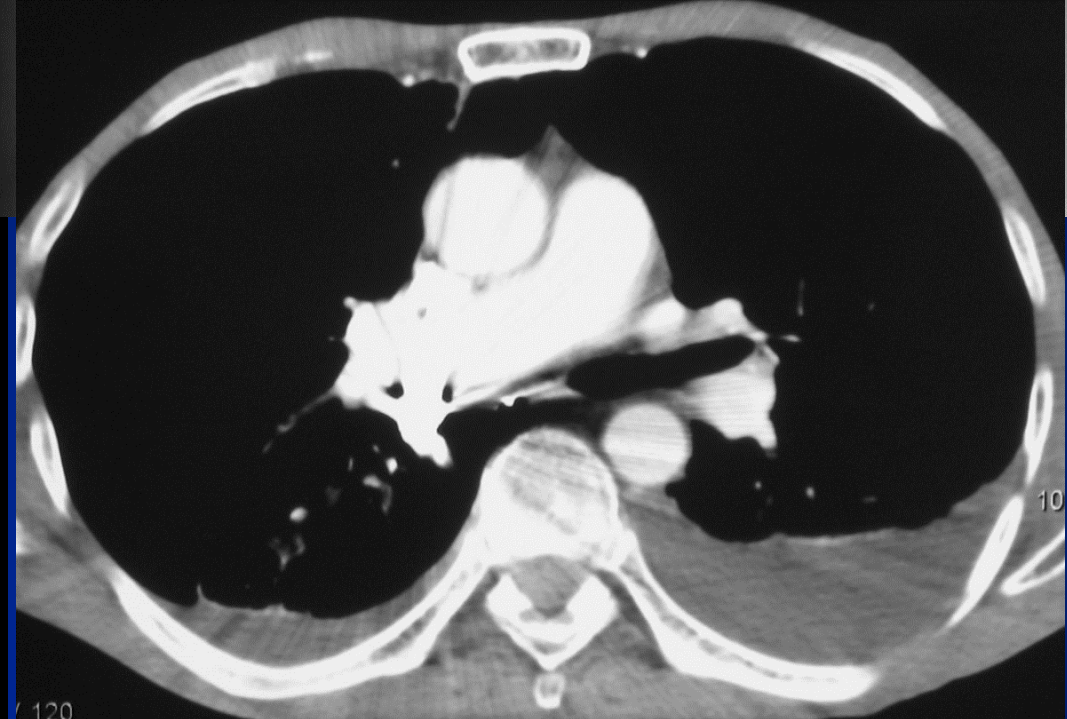
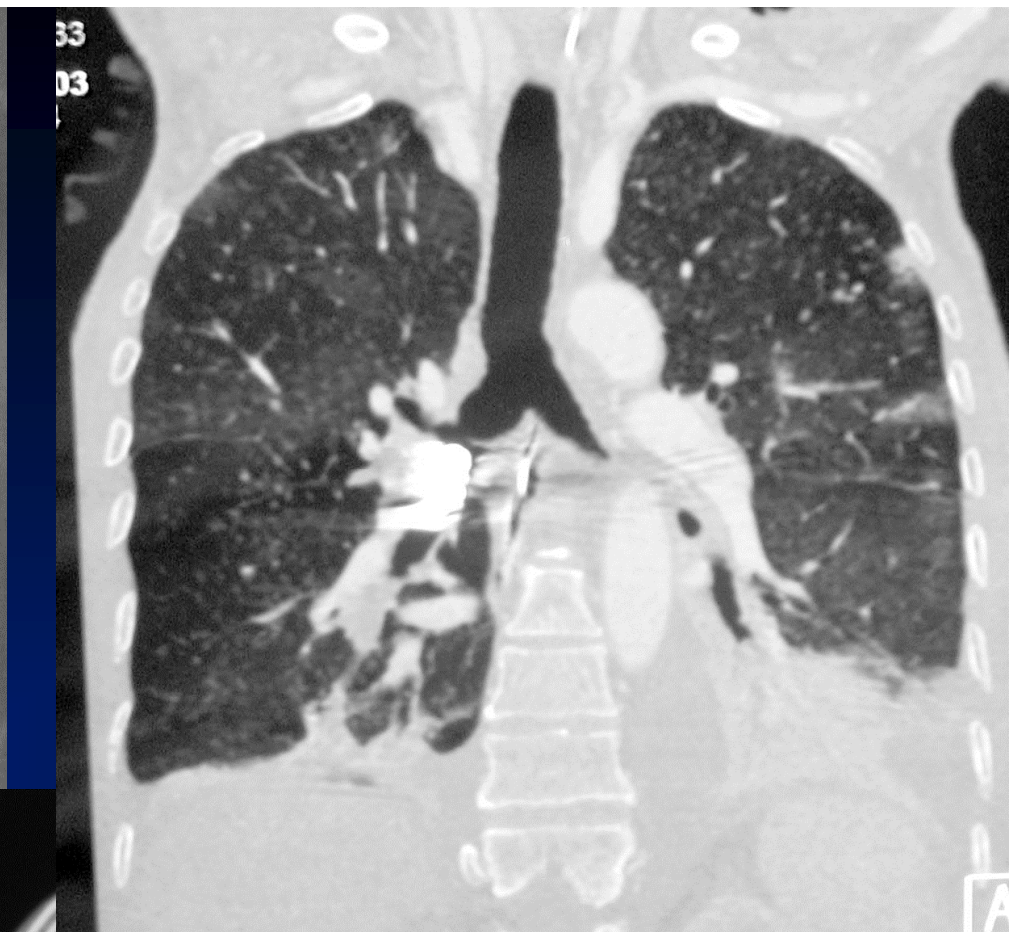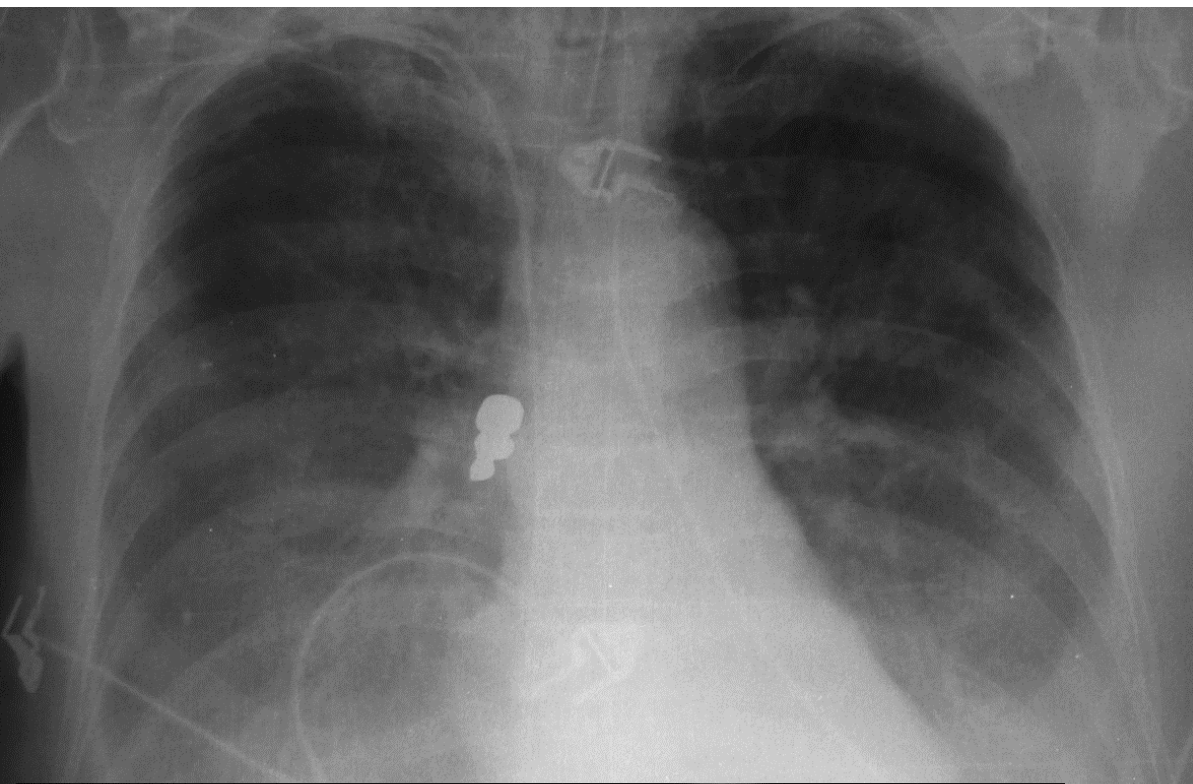




## Tracheob

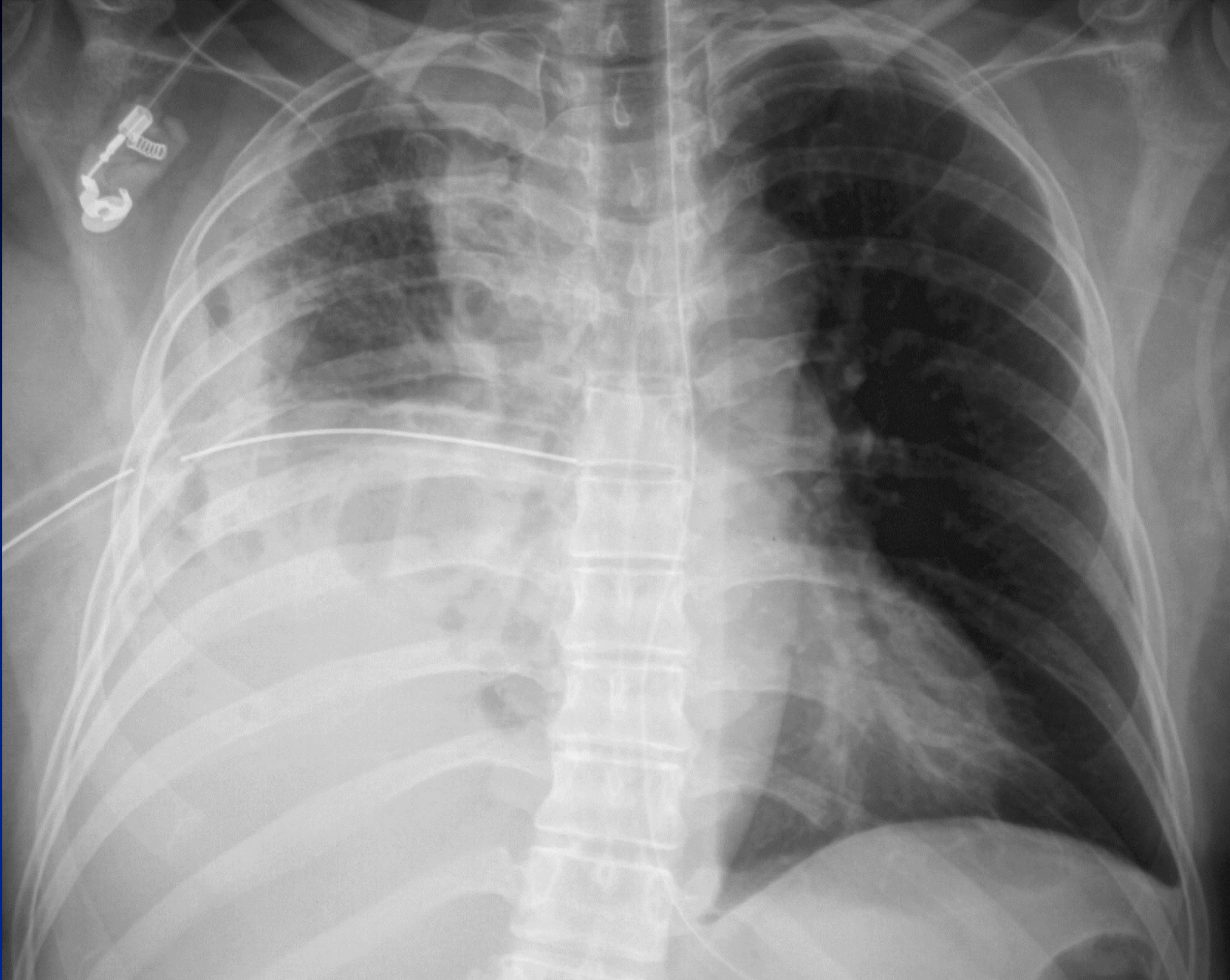
- Pneumomediastinum (pending)
- Pneumothorax (pending on l)
- « P » sign (pneumothorax/m)
- « Fallen lung » sign
- Interstitial air within airway
- Ectopic location of ET
- Overdistention of ET cuff ba

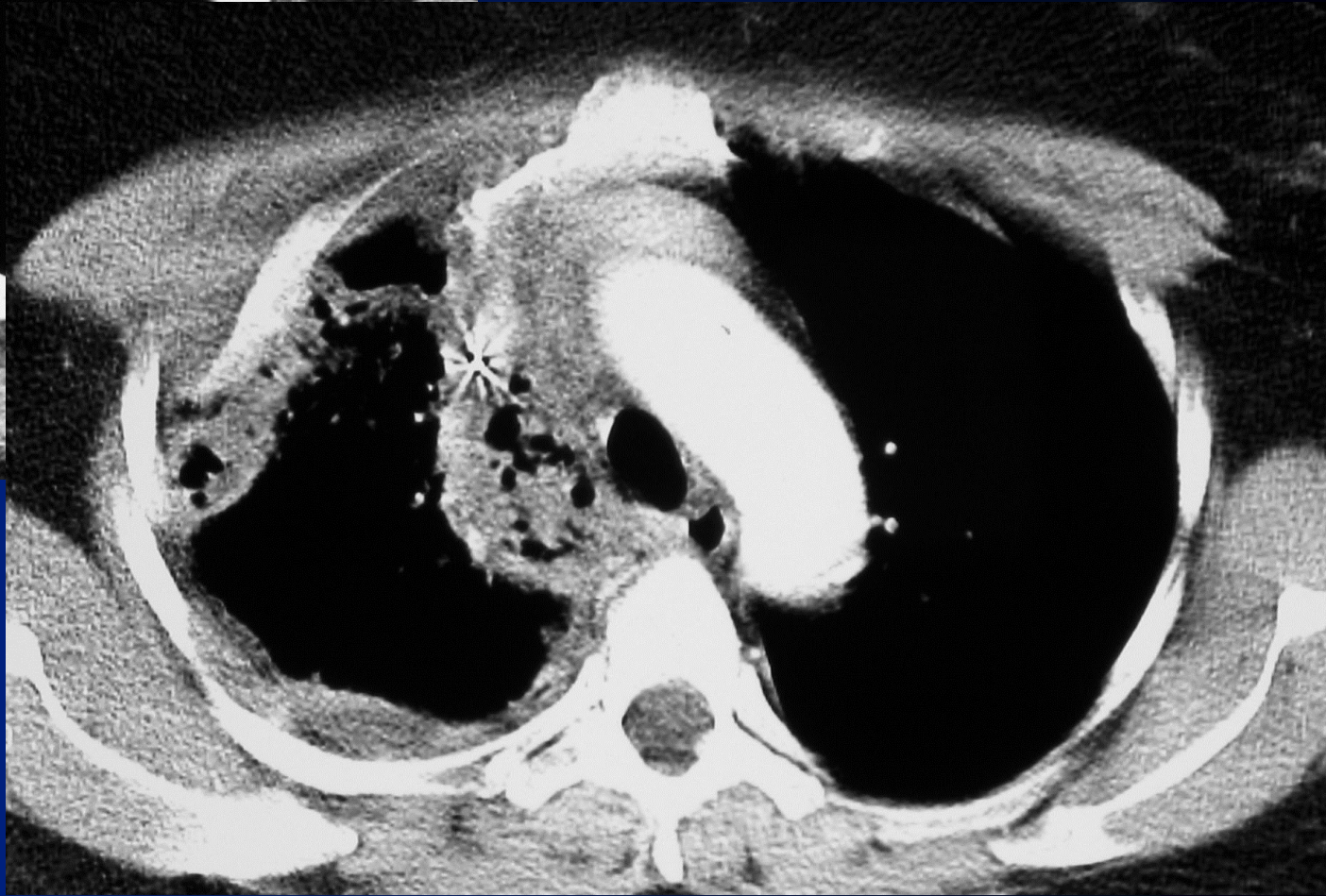
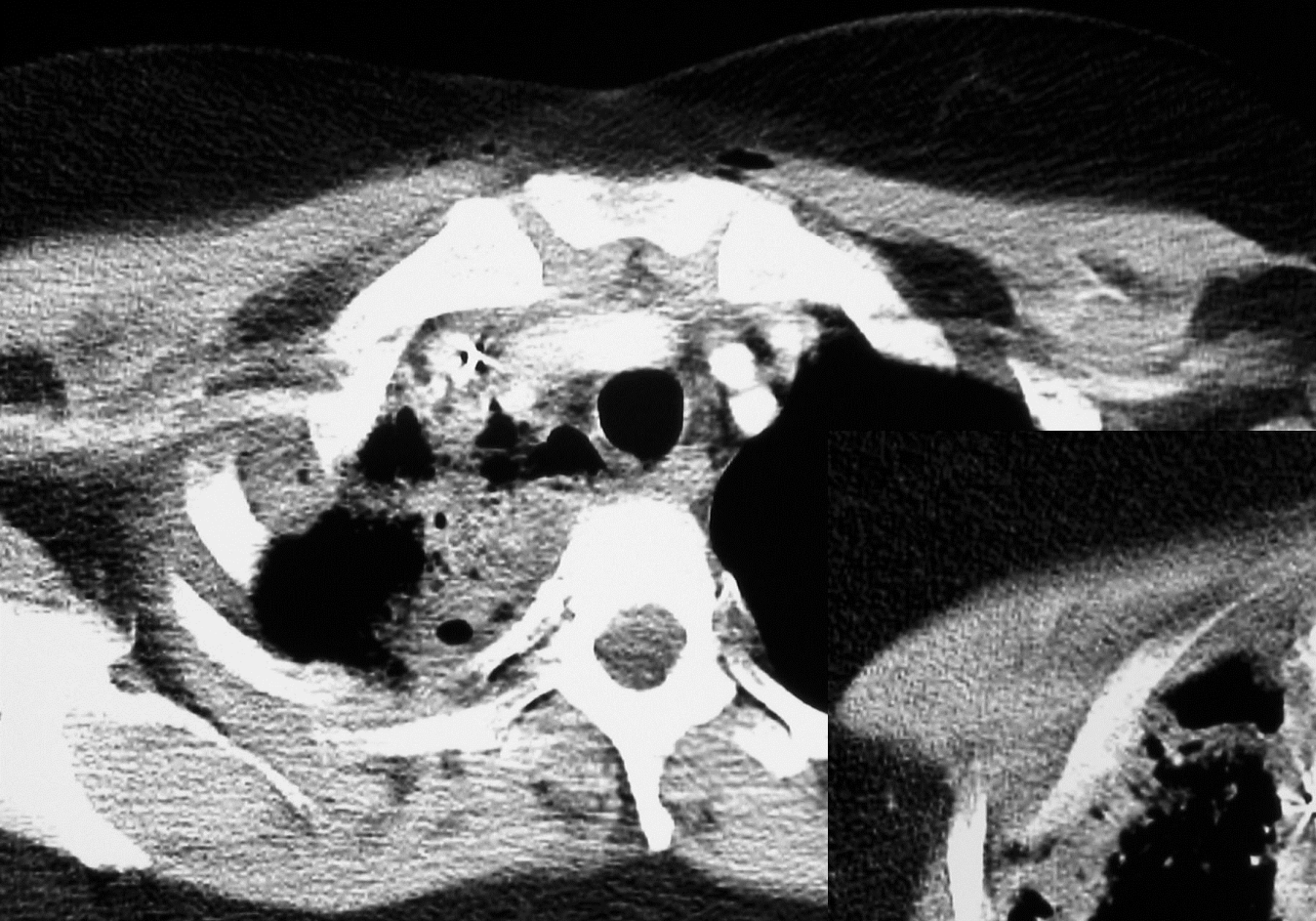



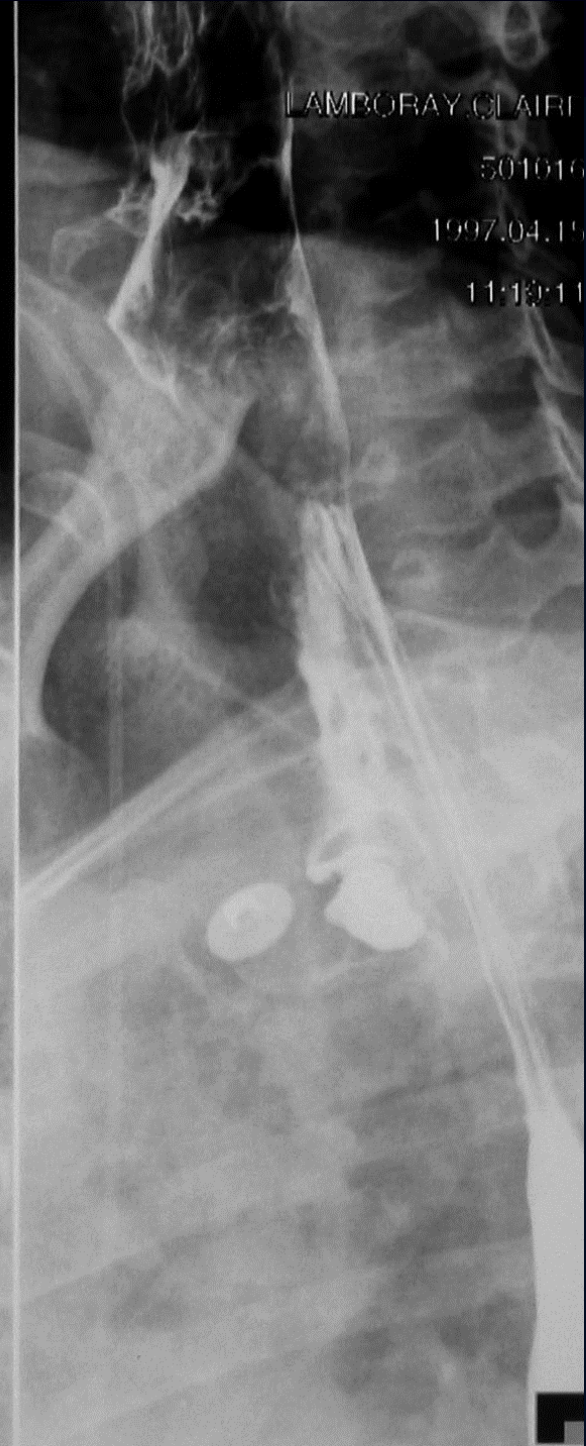
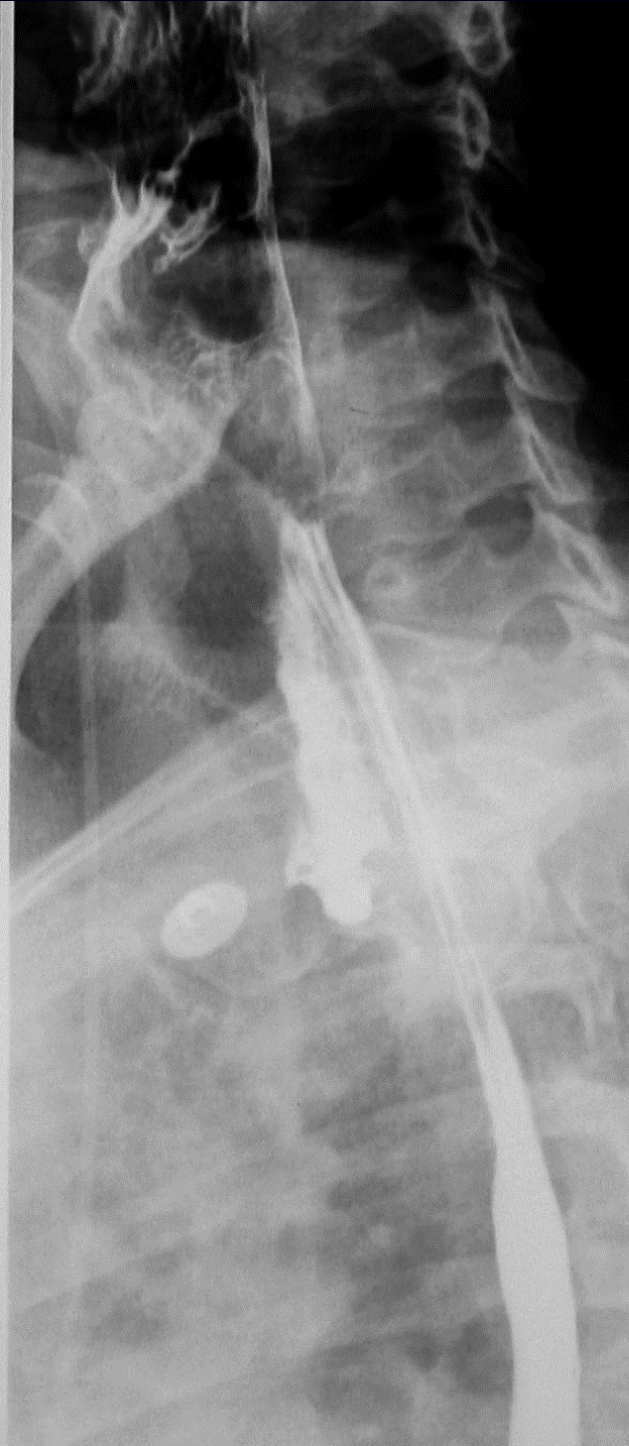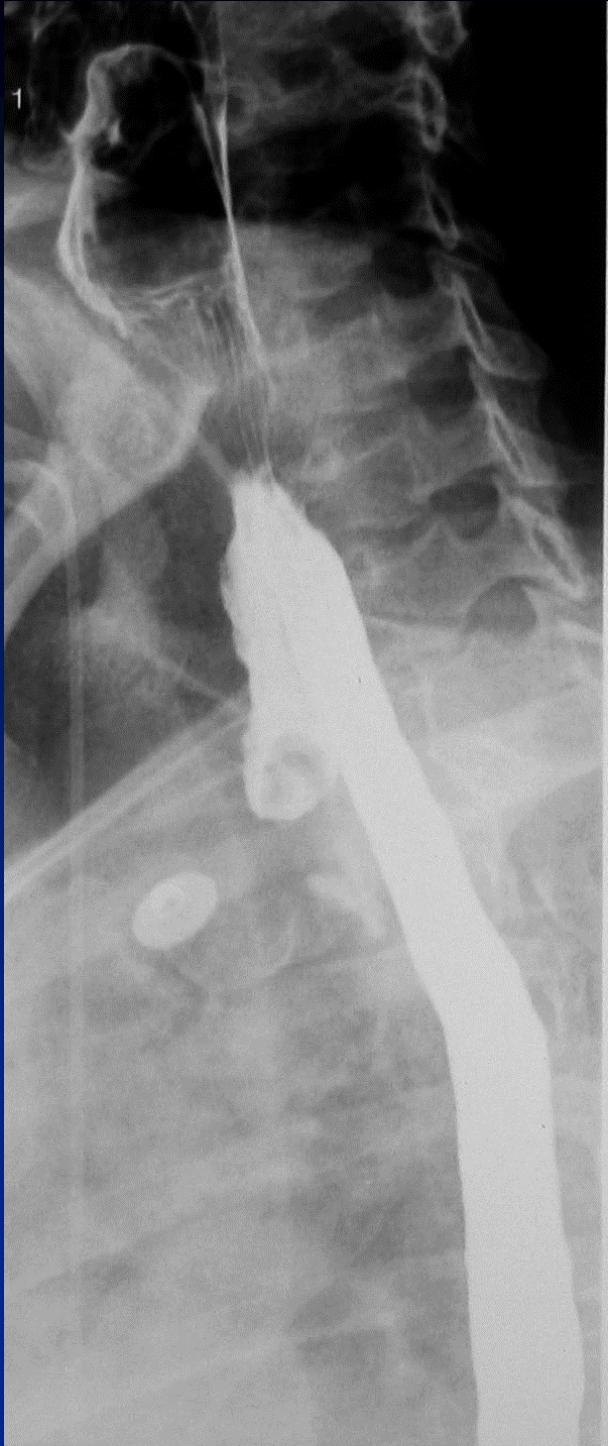
# Esophageal Injuries

- **< 1%**
- **Early diagnosis is imperative**
- **Mediastinitis**
- **Increase in esophageal pressure (stomach content)**
- **Tear: distal left postero-lateral wall**
- **Compression, traction, penetrating (bone #)**
- **Esophagram (non-ionic, barium)**
- **Endoscopy**





1



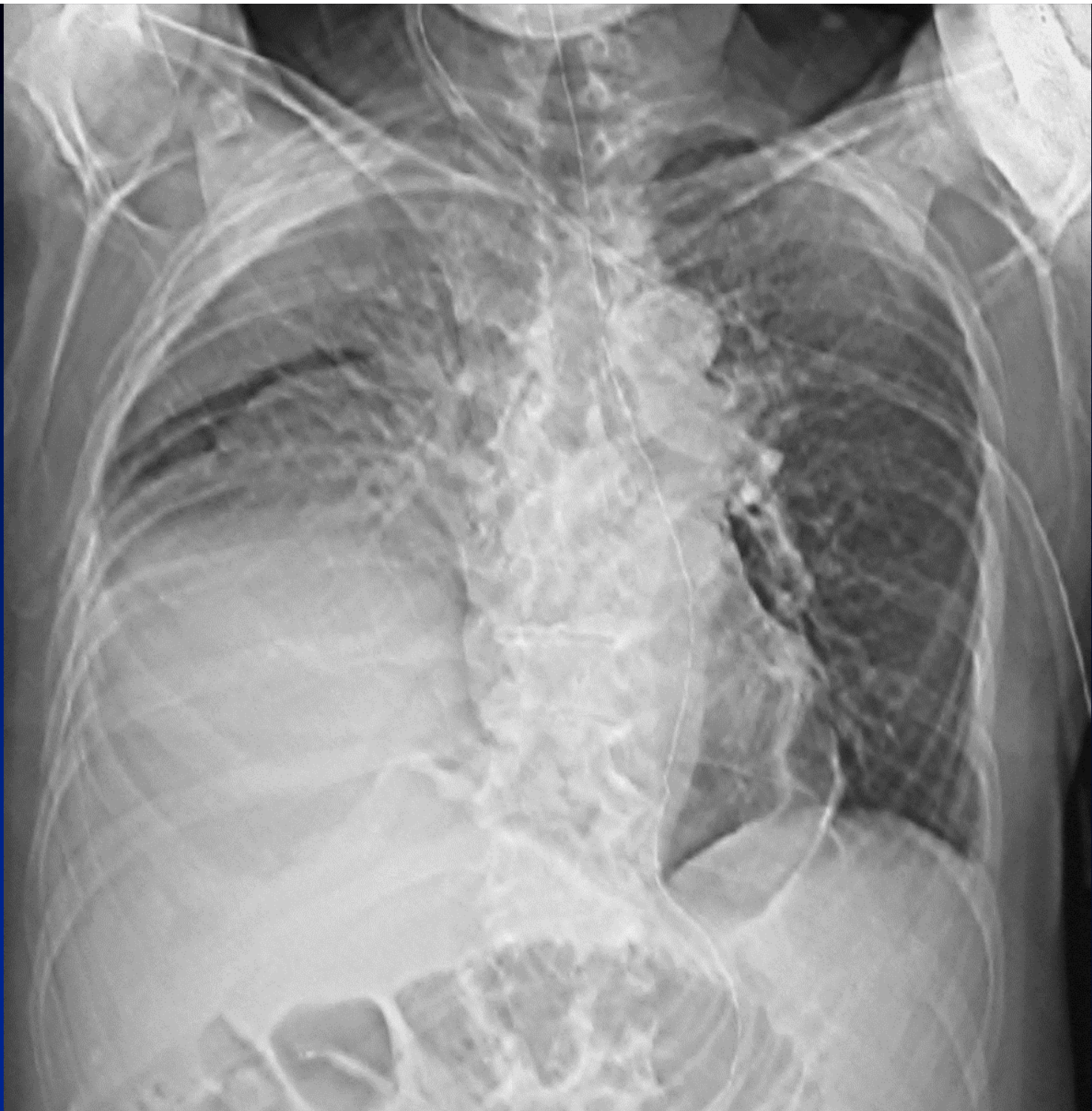# Esophageal Injuries

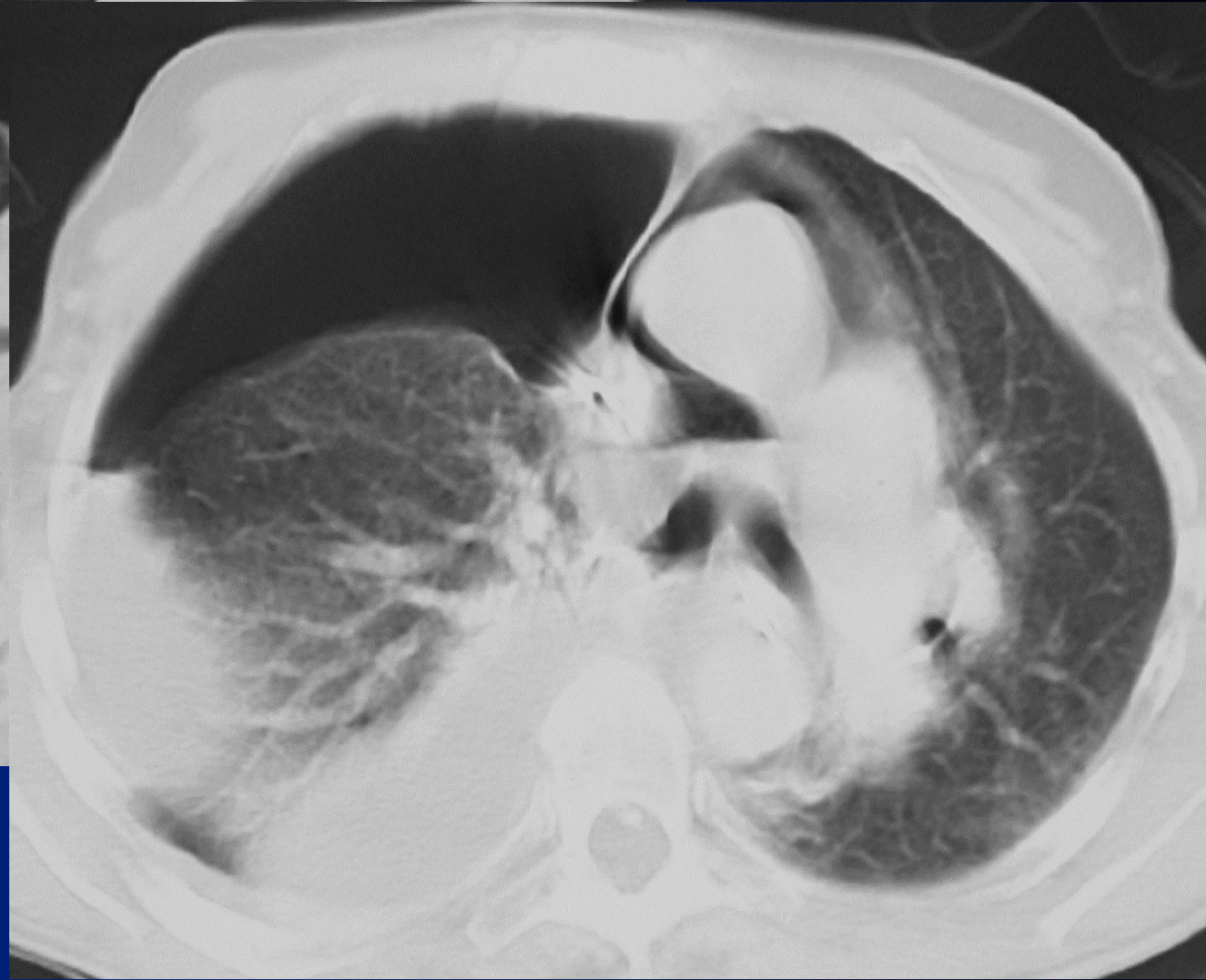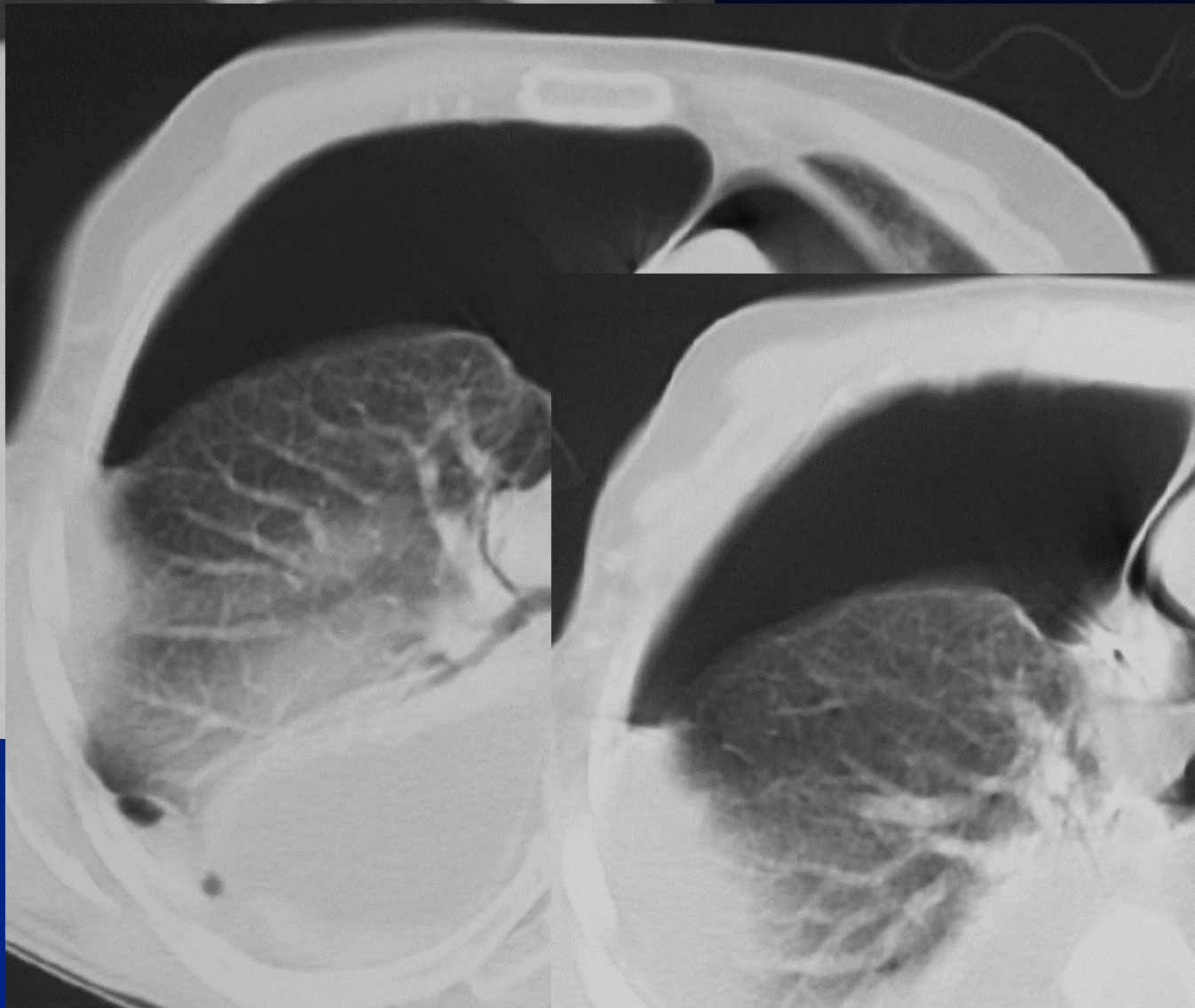
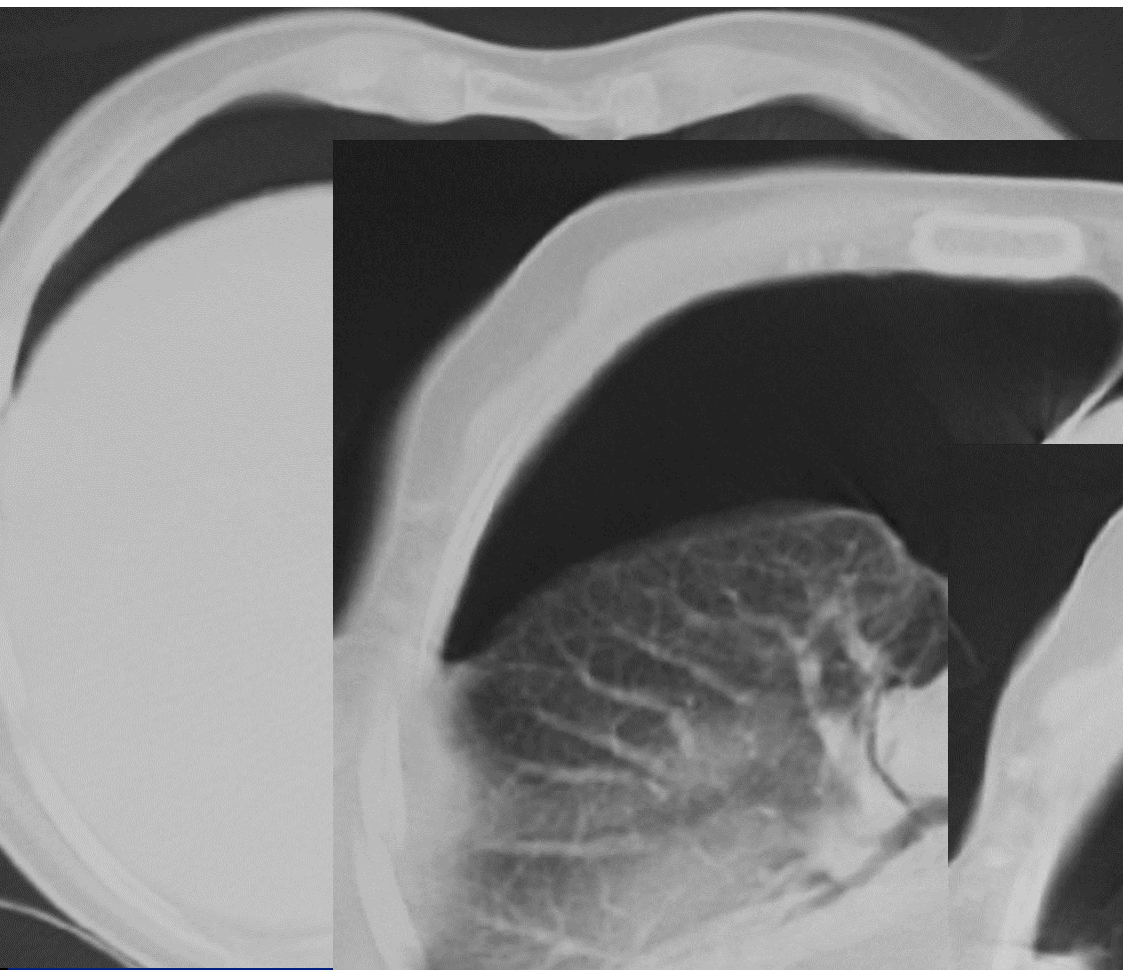
- **Pneumomediastinum**
- **Left pneumothorax**
- **Left pleural effusion**
- **Left lower lobe atelectasis**

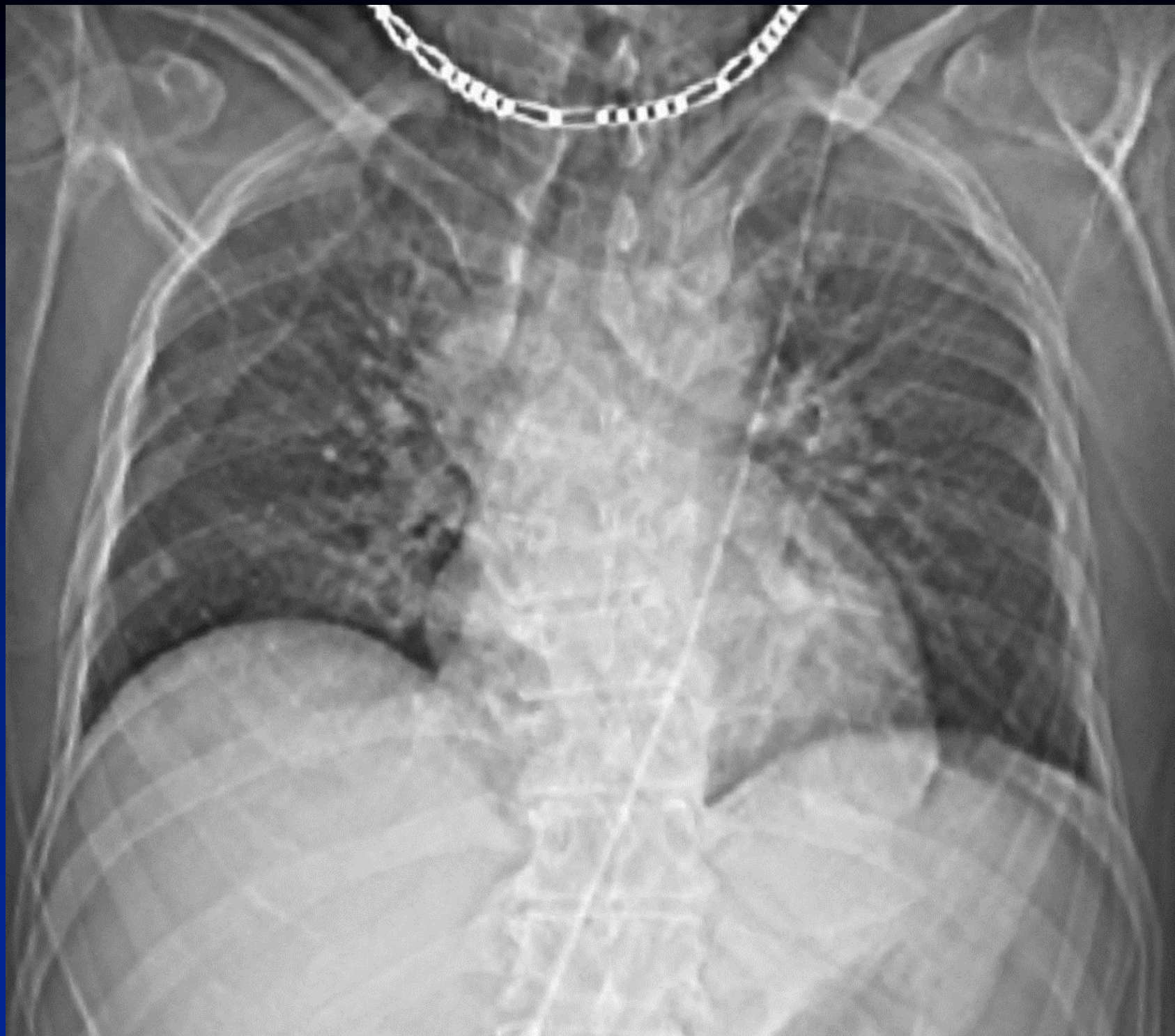# Cardiac Injuries

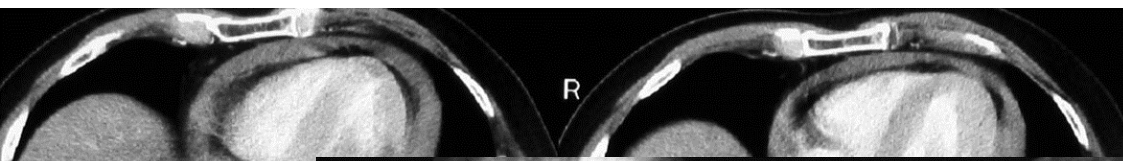
- **Myocardial contusion (common 76 %, RV, CK-MB ↑), infarction, laceration, rupture**
- **Pericardial tamponnade (IP or EP), tear, rupture**
- **Cardiac herniation or dislocation**
- **Damage to the valve apparatus**
- **Coronary artery occlusion**



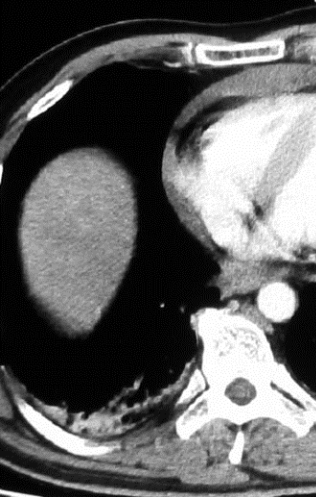








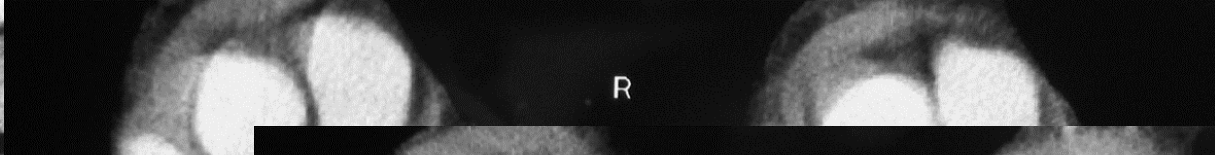832-82-B



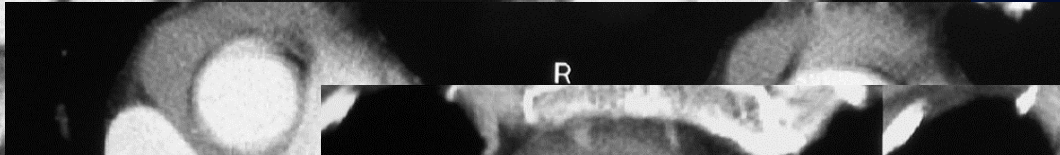
832-99-B



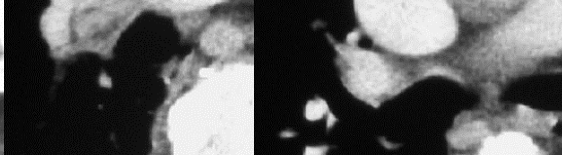
R




R



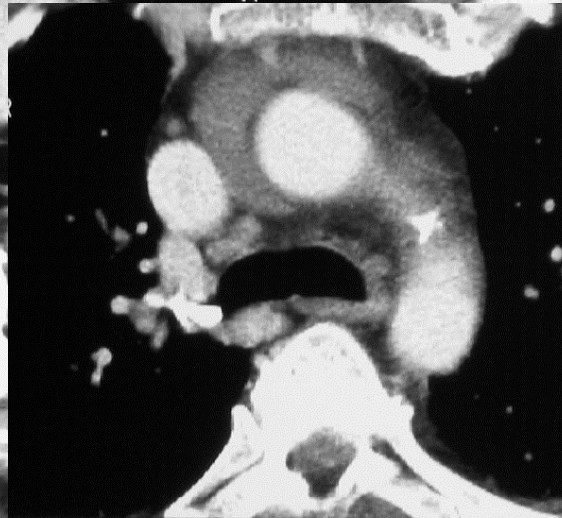R



832-103-B

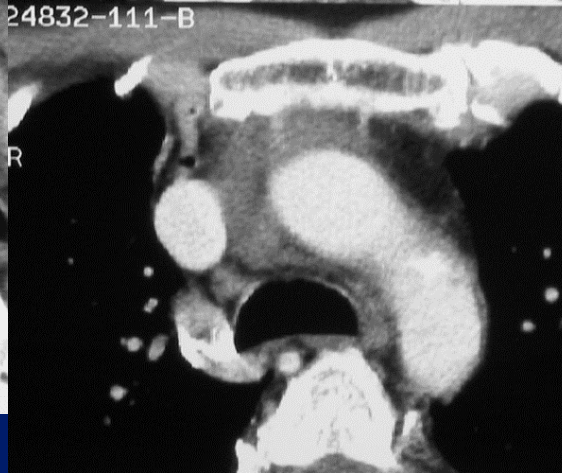


832-107-B



R

24832-115-B



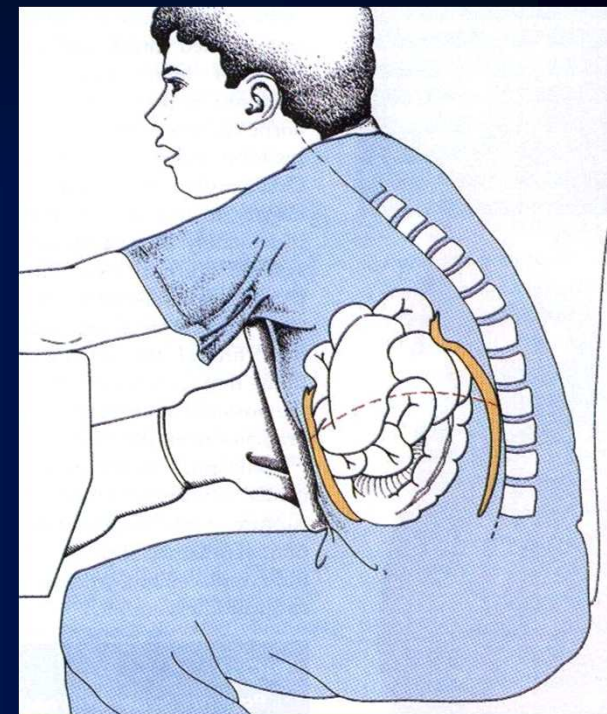
R

R

# Rupture diaphragmatique

## Incidence des lésions et ruptures

- Incidence réelle inconnue (patients aΣ)
- Prévalence croissante dans la littérature
- 3 - 8 % des laparotomies post-trauma
- Autopsies: 5 - 17 % des polytraumas
- Estimation: 5-10 % des traumas sévères
- Pénétrant / fermé: 2/1 (3/1 à 1/8)
- Enfants ≈ adultes
- Fermé: 90 % après accident de roulage  
G > D (3/1)  
rarement bilatéral (3 %)
- Pénétrant: lésions dans 10-75 % des blessures Th/abd  
90 % lorsque du côté G  
G = D (1/1)

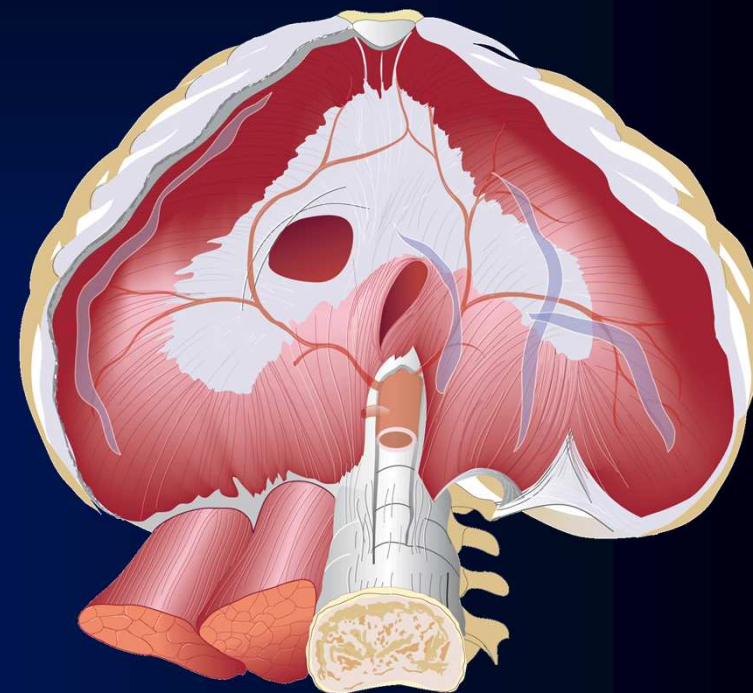


<http://02d9395.netsolhost.com/main/ce/chest/chesttrauma.htm>

# Rupture diaphragmatique

## Incidence des lésions et ruptures

- Incidence réelle inconnue (patients aΣ)
- Prévalence croissante dans la littérature
- 3 - 8 % des laparotomies post-trauma
- Autopsies: 5 - 17 % des polytraumas
- Estimation: 5-10 % des traumas sévères
- Pénétrant / fermé: 2/1 (3/1 à 1/8)
- Enfants ≈ adultes
- Fermé: 90 % après accident de roulage  
G > D (3/1)  
rarement bilatéral (3 %)
- Pénétrant: lésions dans 10-75 % des blessures Th/abd  
90 % lorsque du côté G  
G = D (1/1)



# Rupture diaphragmatique

## Complications

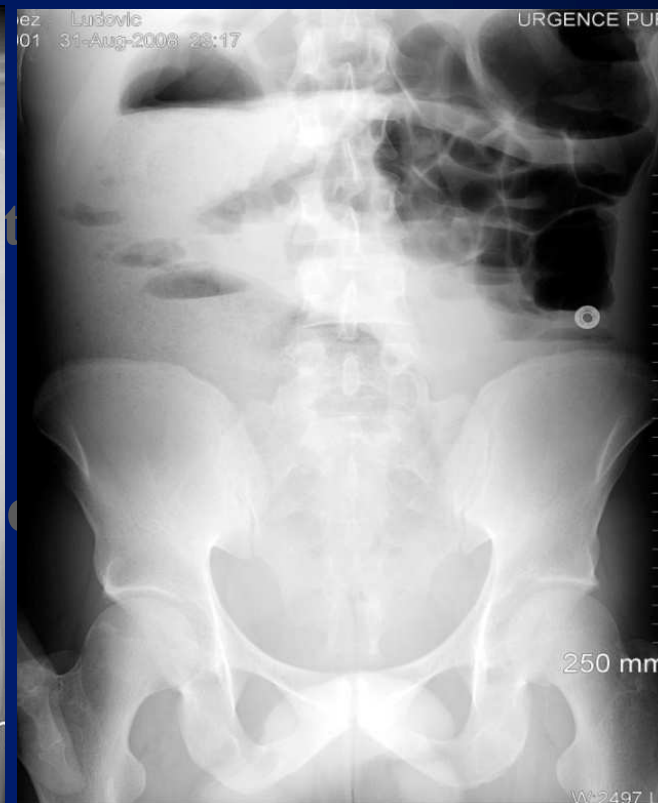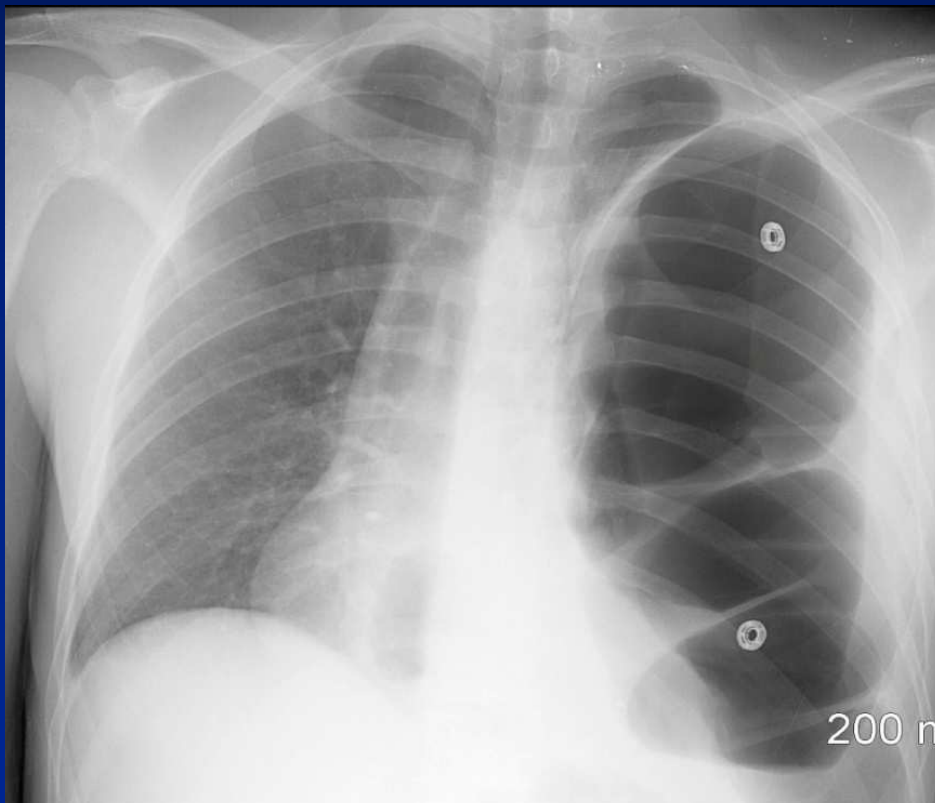
- **Hernie**
  - **Viscère creux** (obstruction ou strangulation GI (délai: 80% endéans 3 ans (1j-48a), volvulus gastrique, ischémie GI)
  - **Organes solide** (conséquences moindre, ischémie, troubles fonctionnels)
- **Pulmonaires**
  - **Compression** (CV ↓, infection)
  - **Pneumo/hémo/urino/bilo/pyothorax, pseudokyste**
- **Cardiovasculaires**
  - **Tamponnade cardiaque**
  - **Obstruction veineuse centrale**
- **Autres**
  - **Splenosis intrathoracique, ...**

# Rupture diaphragmatique

## Complications

- **Hernie**

- **Viscère creux** (obstruction ou strangulation GI (délai: 80% endéans 3 ans (1j-48a), volvulus gastrique, ischémie GI)
- **Organes solide** (conséquences moindre, ischémie, troubles fonctionnels)



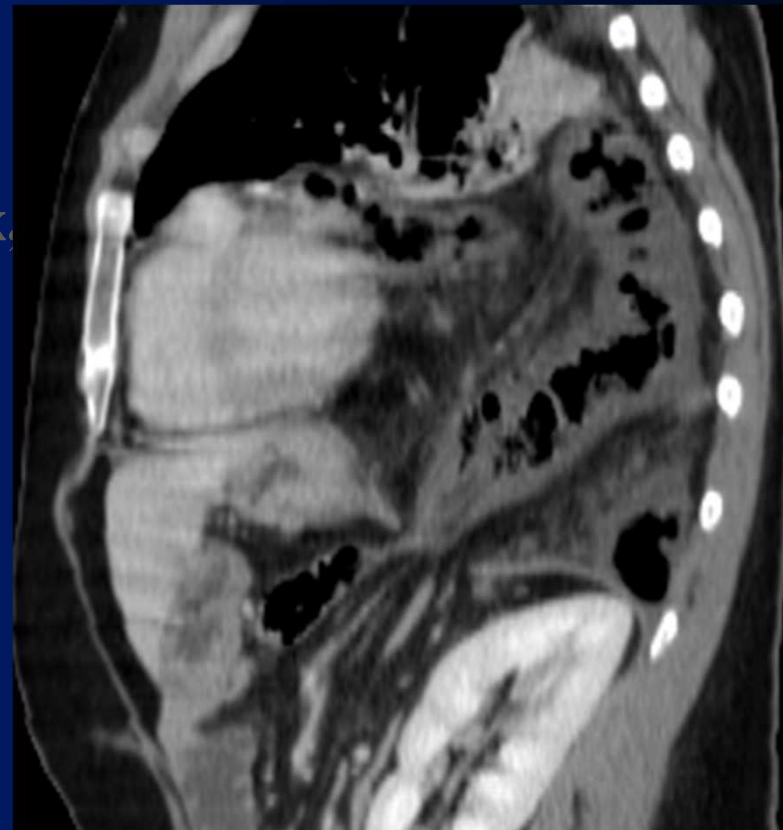
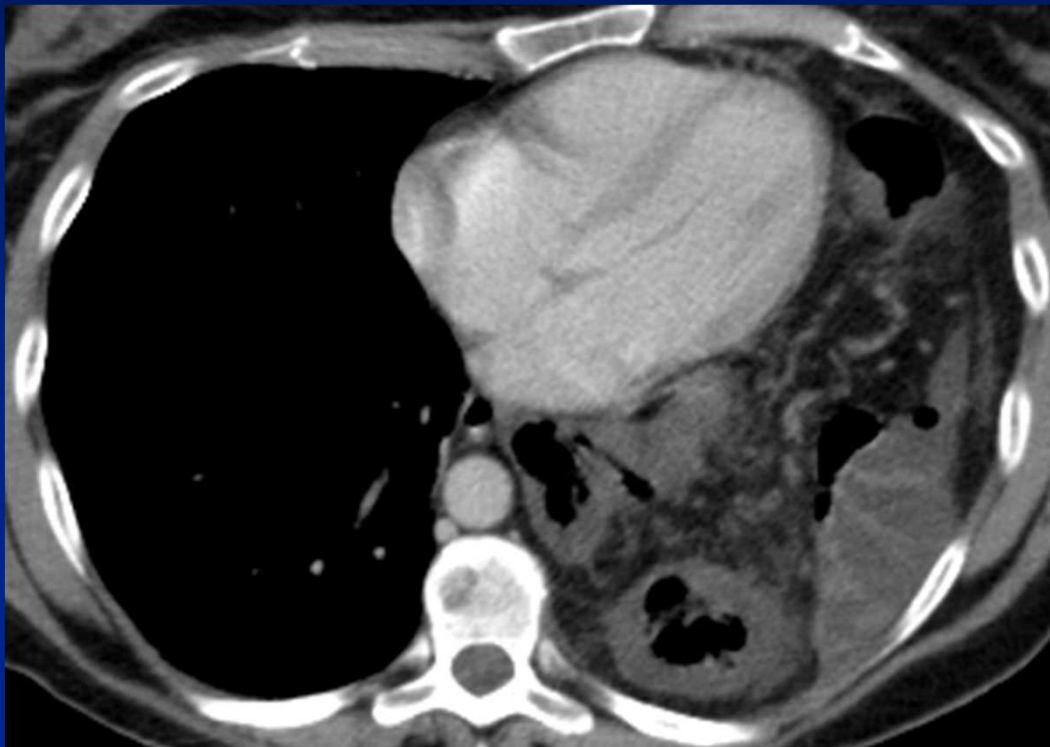

# Rupture diaphragmatique

## Complications

- **Hernie**

- **Viscère creux** (obstruction ou strangulation GI (délai: 80% endéans 3 ans (1j-48a), volvulus gastrique, ischémie GI)
- **Organes solide** (conséquences moindre, ischémie, troubles fonctionnels)



# Signes TDM des ruptures diaphragmatiques

## SIGNES DIRECTS

... un trou dans le diaphragme

1. Signe du défaut segmentaire
2. Signe du diaphragme ballant
3. Signe du diaphragme absent<sup>1</sup>

## SIGNES DIVERS

16. Signe du diaphragme épaissi<sup>5</sup>
17. Extravasation (péri-) diaphragmatique de produit de contraste
18. Signe du diaphragme hyporehaussant
19. Signe du fragment costal<sup>6</sup>

## SIGNES INDIRECTS

... liés à la hernie

4. Hernie à travers le défaut
5. Signe du collet<sup>2,3</sup>
6. Signe de la bosse
7. Signe de la bande
8. Signe du viscère dépendant
9. Signe de l'interruption du sinus
10. Contenu abdominal périphérique au diaphragme ou au poumon
11. Organes intra-abdominaux surélevés<sup>4</sup>

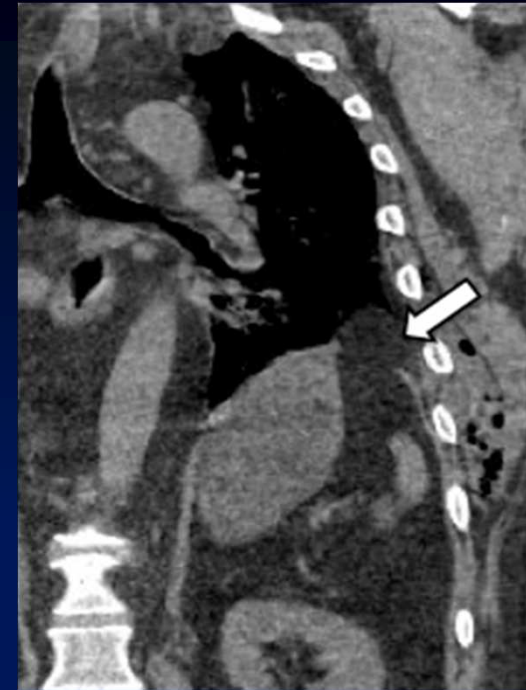
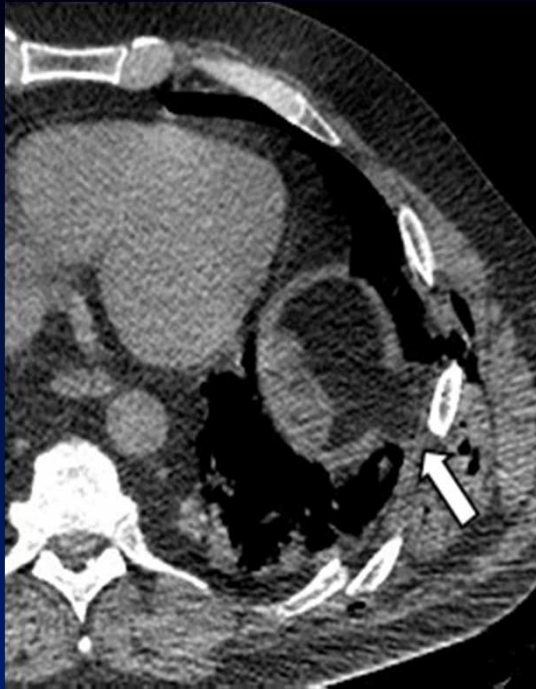## SIGNES INDIRECTS

...liés à l'absence de frontière entre le thorax et l'abdomen

12. Liquide abdominal en contact avec un élément thoracique
13. Liquide thoracique en contact avec un élément abdominal
14. Pneumothorax et -péritoine
15. Haemothorax et -péritoine

Egalement appelé:

1. Non visualisation segmentaire du diaphragme
2. Signe du sablier
3. Signe du champignon
4. Elévation apparente du diaphragme
5. Signe du diaphragme ondulé
6. Lacération du diaphragme par une côte



# 1. Signe du défaut segmentaire

Perte de continuité focale et abrupte du diaphragme

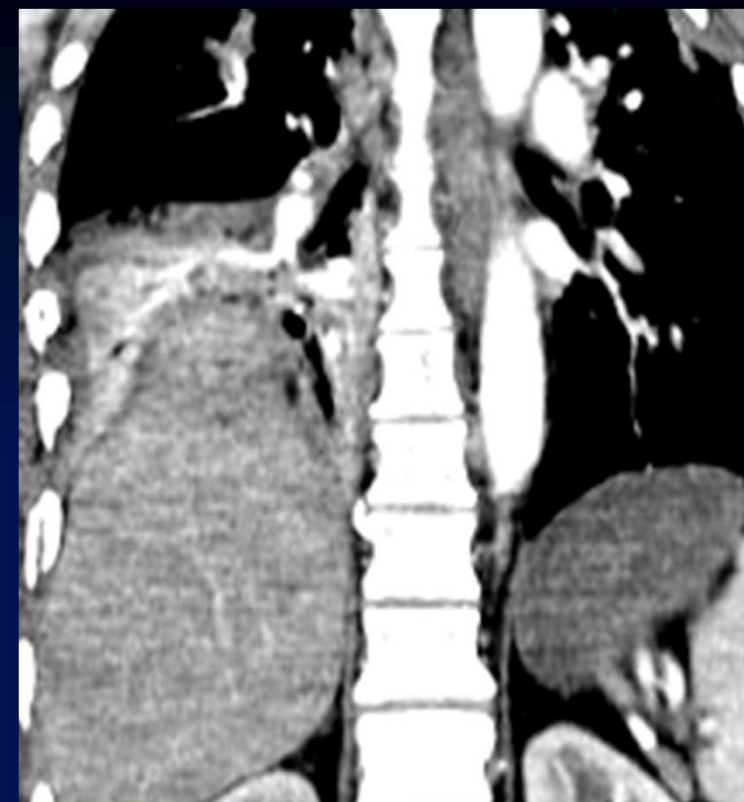
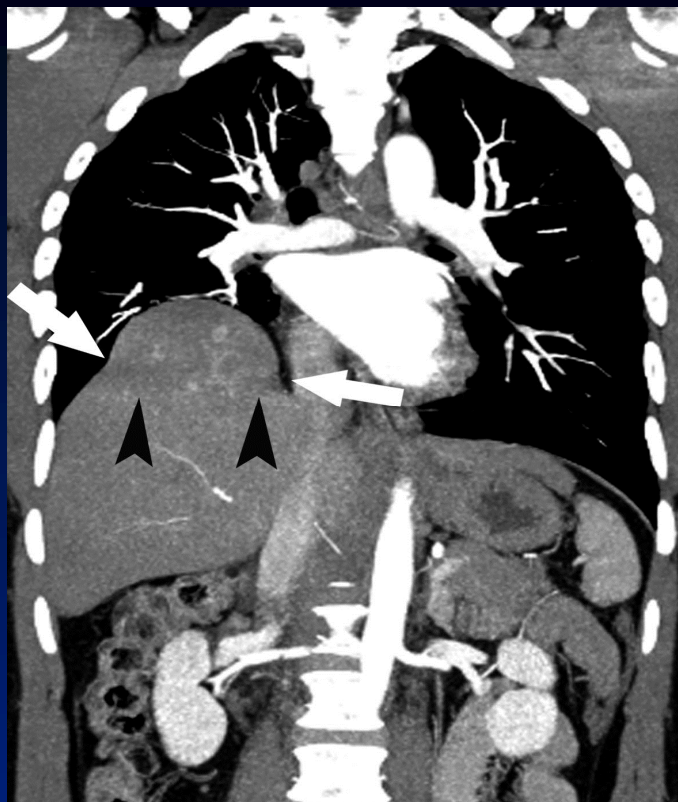
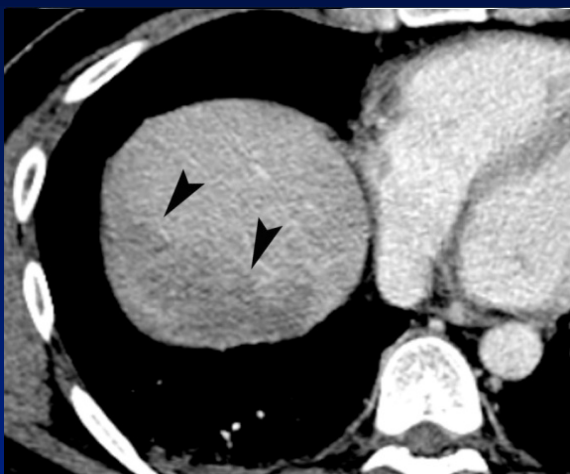
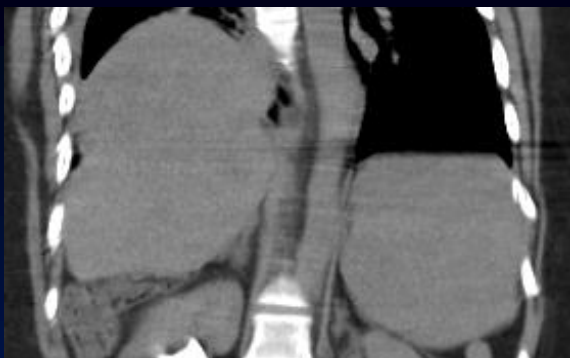Sens : 17-80% (D: 16-66% , G: 22-87%)

Spéc : 90-100%

Heiberg et al. AJR 1980;135:369-72

Holland et al. AJR 1991;157:17-8

Nchimi et al. AJR 2005;184:24-30



## 6. Signe de la bosse

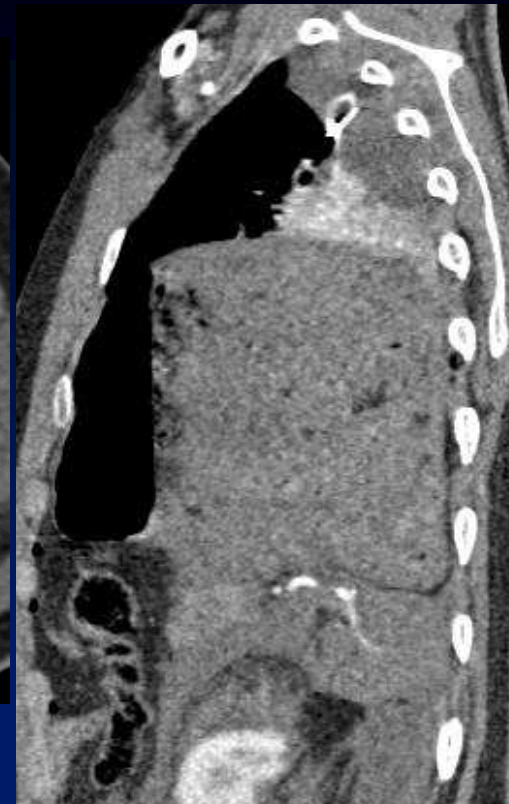
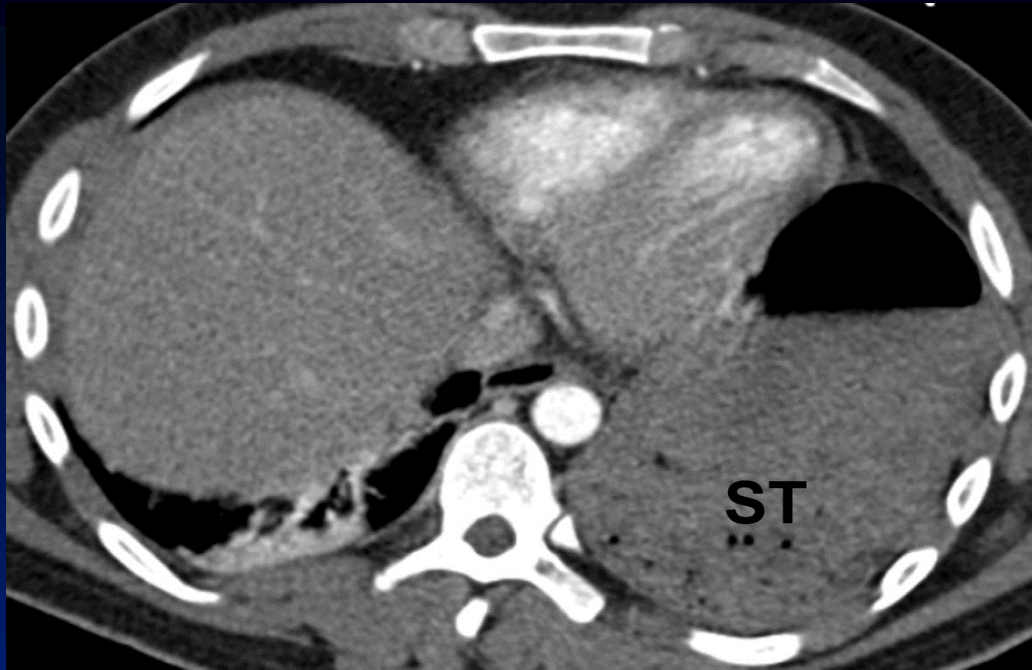Le signe bosse est une variation du signe de collet sur le côté D, la bosse terme faisant référence à la forme du foie hernié au-dessus du niveau du diaphragme

Le signe de la bande correspond à une zone hypodense transversale linéaire traversant le foie hernié, située entre les bords du diaphragm rompu.

Sens : 50-83%

## 7. Signe de la bande

Sens : 33-42%

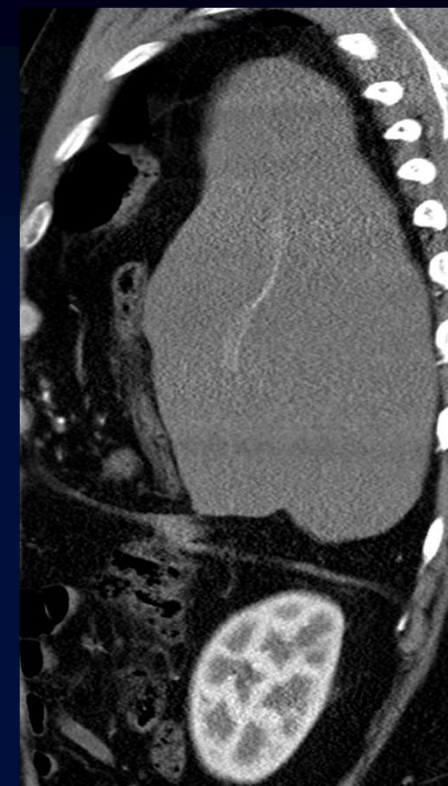
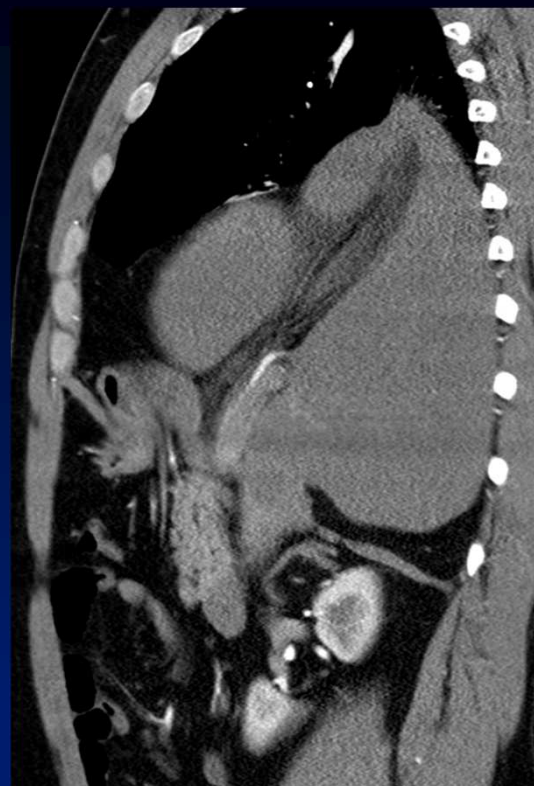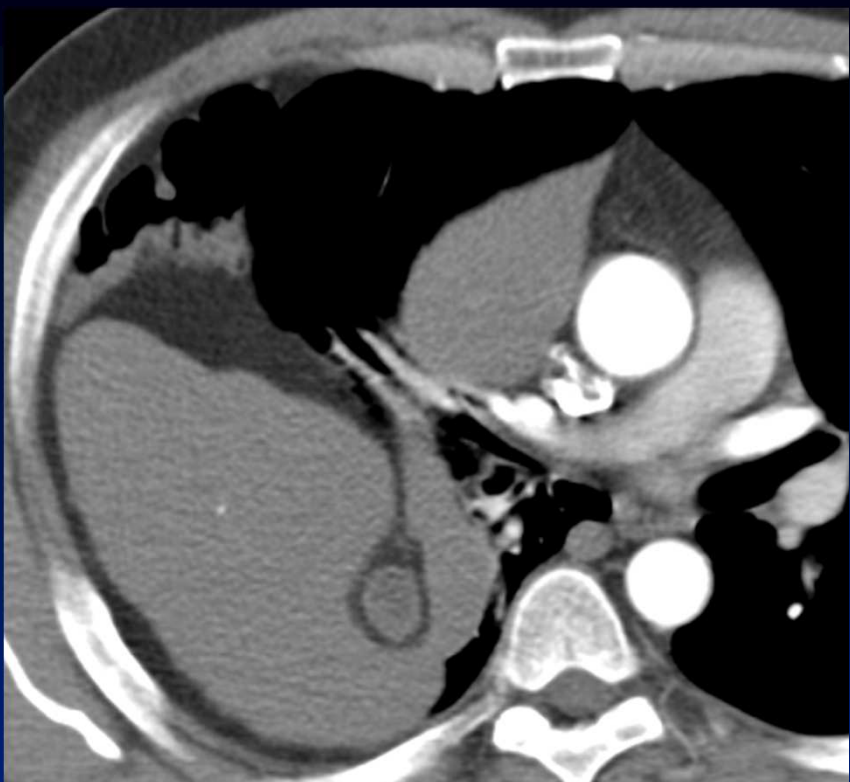


## 8. Signe du viscère dépendent

Contact direct des organes abdominaux herniés contre la paroi thoracique postérieure sans interposition de poumon.  
La perte du soutien diaphragmatique après une rupture peut conduire à la chute des organes abdominaux dans une position décline, à savoir contre la paroi thoracique postérieure lorsque le patient est en décubitus dorsal.

Sens : 54-90% (D: 33-83%, G: 64-100%)

Spéc : 98-100%

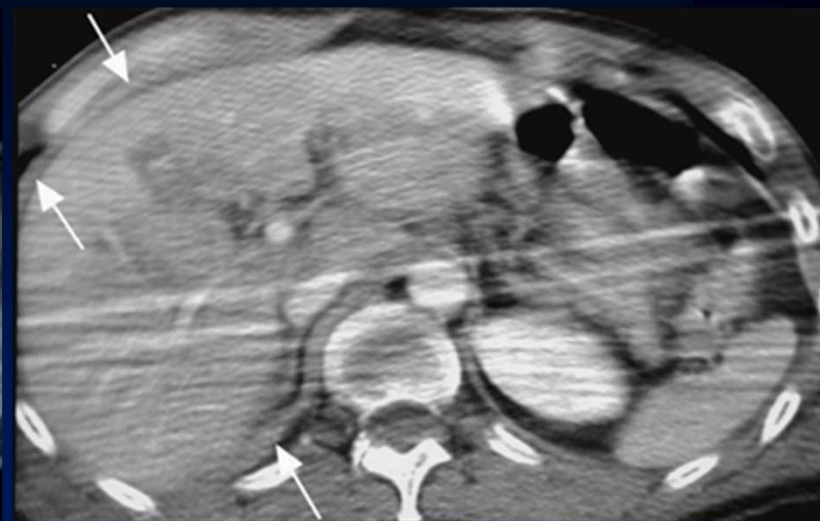
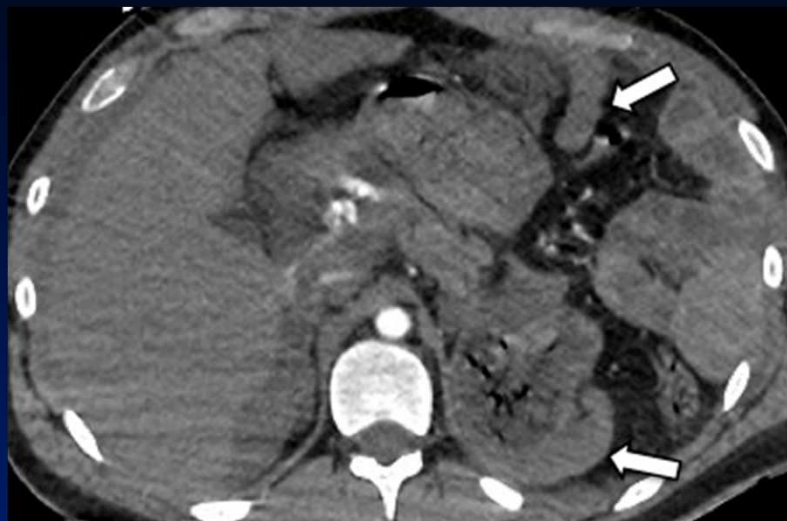
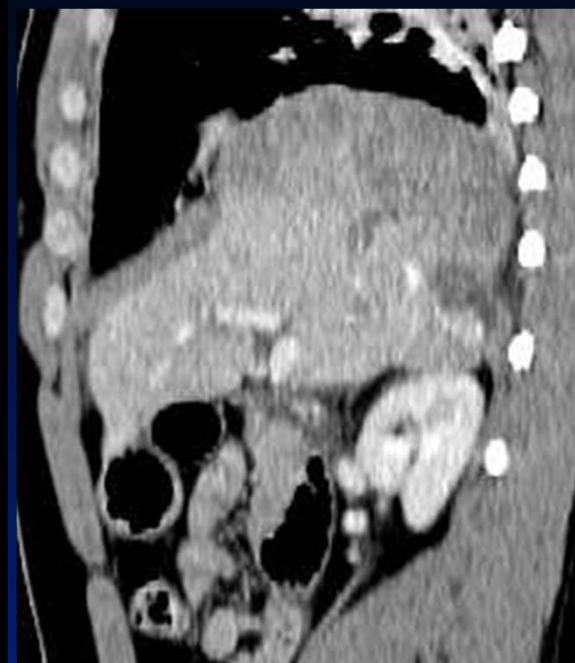

## 8. Signe du viscère dépendent

Contact direct des organes abdominaux herniés contre la paroi thoracique postérieure sans interposition de poumon.  
La perte du soutien diaphragmatique après une rupture peut conduire à la chute des organes abdominaux dans une position déclive, à savoir contre la paroi thoracique postérieure lorsque le patient est en décubitus dorsal.

Sens : 54-90% (D: 33-83%, G: 64-100%)

Spéc : 98-100%



## 16. Signe du diaphragme épaissi

Épaississement anormal régulier ou nodulaire, focal ou diffus du diaphragme  
Résultante de la rétraction des berges du diaphragme rompu

Sens : 56-75% (D: 50-100%, G: 36-68%)

Spéc : 95%

# Ruptures diaphragmatiques

## Difficultés diagnostiques

- **TDM séquentielle:**
  - sensibilité : 14-61 %
  - spécificité : 76-99 %
- **TDM hélicoïdale:**
  - sensibilité : 42-90 % (most retrospective)\*
  - R : 50-83 %
  - L : 78-100 %
  - spécificité : 77-100 %
- **TDM multidétecteurs:**
  - sensibilité : 77%\*\*
  - spécificité : 98%
- **Agrément interobservateur: K = 0.3-0.97%**

Killeen et al AJR 1999;173:1611-1616  
Bergin et al. AJR 2001;177:1137-1140  
Larici et al AJR 2002;179:451-457

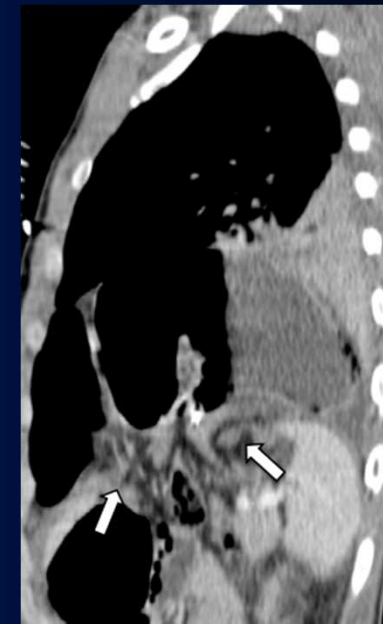
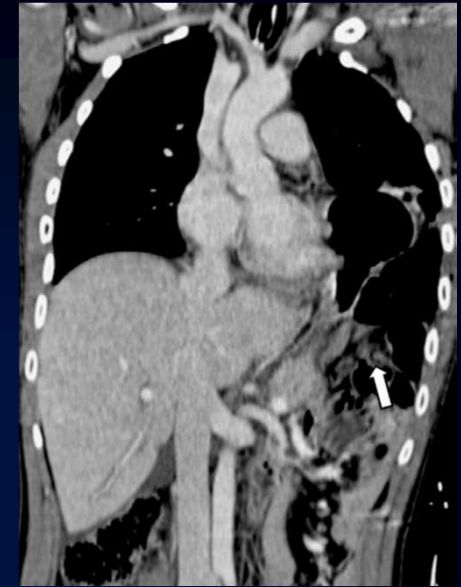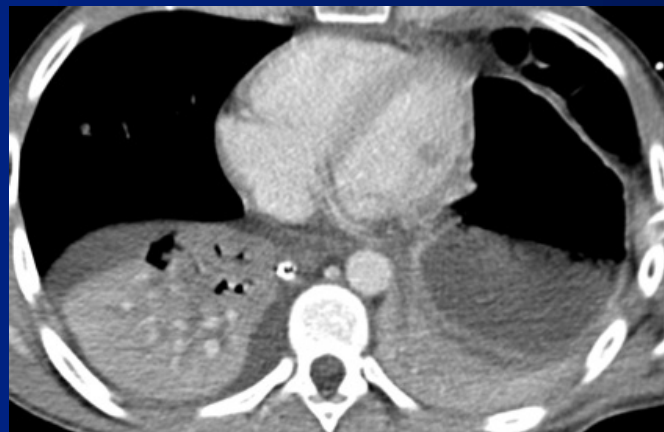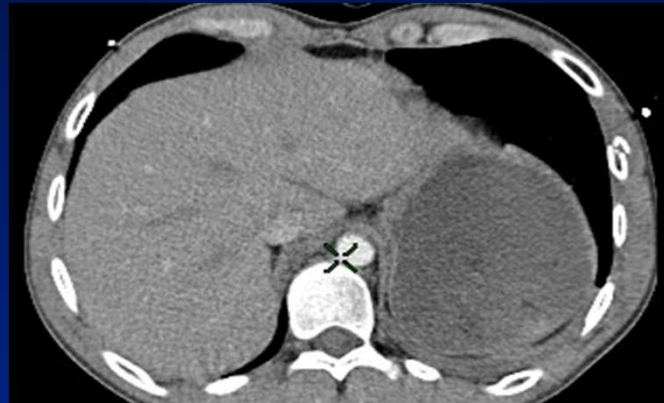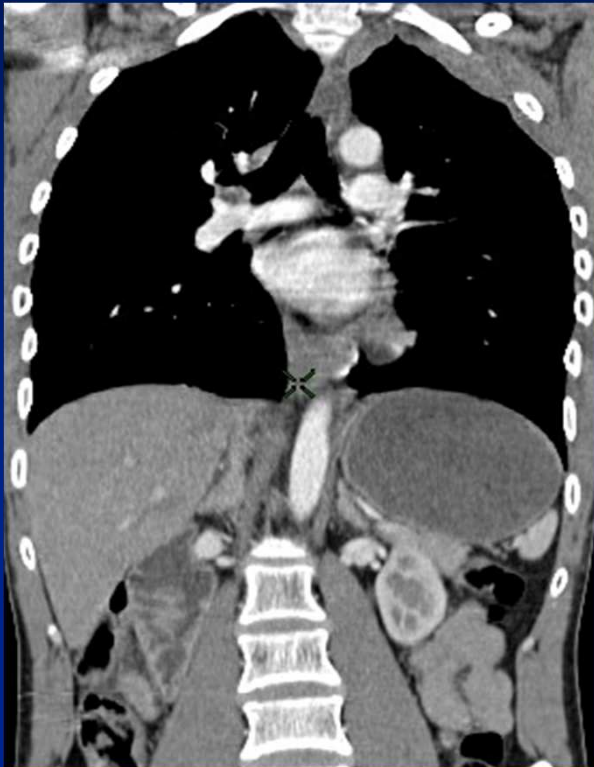\*Nchimi et al AJR 2005;184:24-30  
\*\*Desser et al Emerg Radiol 2010;17:37-44



# TDM multidétecteurs

## Résultats (n=42)

- Sensibilité de la TDM (16 à 256 rangées de détecteurs):
  - 41/42 (97,6%) >< 71-90% de la littérature
  - 1 cas de rupture diaph G non détectée

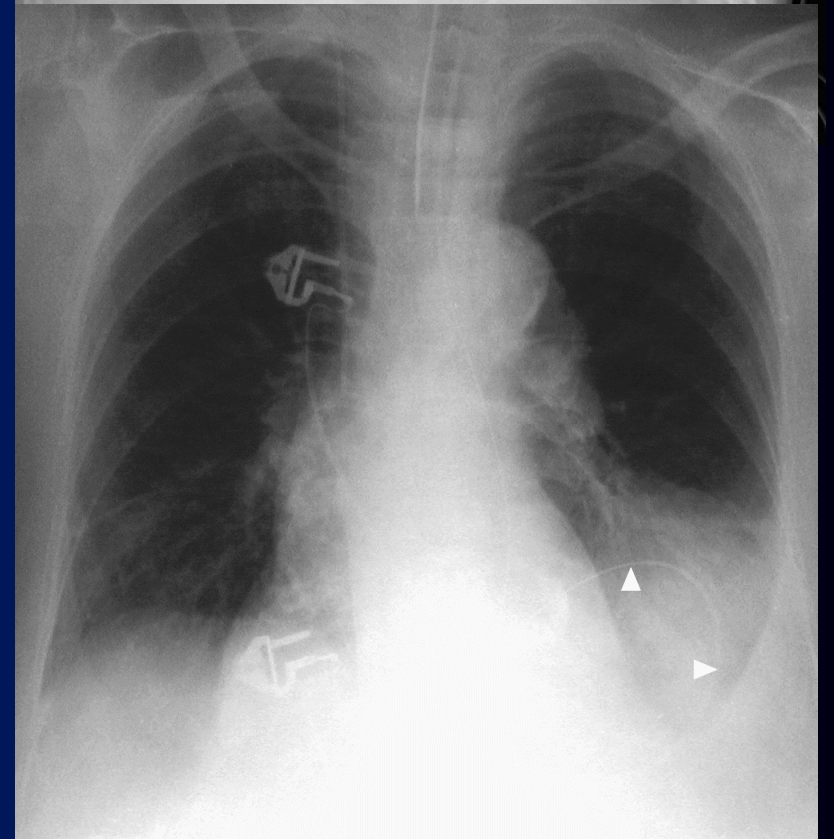
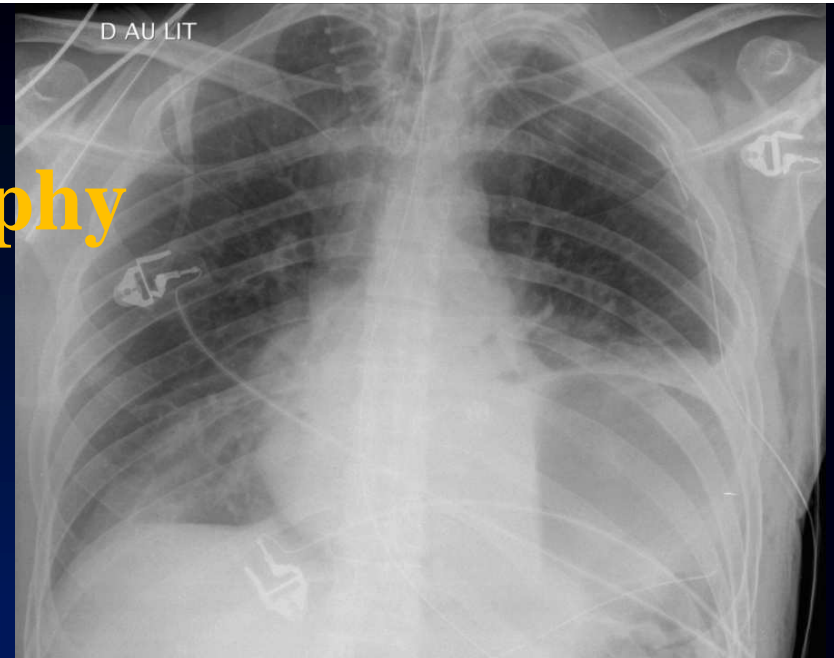


Desser TS, et al. Emerg Radiol 2010;17(1):37-44  
Bergin D, et al. AJR Am J Roentgenol 2001;177(5):1137-40  
Killeen KL, et al. AJR 1999;173(6):1611-6

# Imaging

## Plain radiography

- Full inspiration chest X-ray
- Insertion of nasogastric tube
- **Diagnostic or highly suggestive signs**
  - viscera above diaph
  - aN high diaph  $> 6$  cm
  - tip of NG above diaph
- **Suggestive signs**
  - aN high diaph  $< 6$  cm
  - obscuration of diaph
  - mediastinal shift, pleural effusion, aN heart shadow



# Imaging

## Plain radiography

- A normal or NS Chest XR does not rule out DR
- Intubated with P+ ventilation: FN !
- Positive in 46%, suspicious in 18% (L:27-62%, R:18-33%)
- Suspicion of DR: serial CXR or better CT

### SENSITIVITY OF CHEST X-RAYS FOR THE DIAGNOSIS OF BLUNT DR

Reference	Left-sided		Right-sided	
	Suggestive signs	Diagnostic or highly suggestive signs	Suggestive signs	Diagnostic or highly suggestive signs
German et al (1991)	14%	64%	16%	16%
Willsher and Cade (1991)	14%	78%	75%	25%
Guth et al (1991)	41%	54%	45%	0%
Shapiro et al (1996)	71%	NS	0%	NS
Nikoulis et al (2000)	13%	87%	NS	NS

# ABCs of Thoracic Trauma

- **A**    **Aortic injuries**
- **B**    **Bronchial and tracheal injuries**
- **C**    **Cord and spinal injuries**
- **D**    **Diaphragm injuries**
- **E**    **Esophageal injuries**
- **F**    **Fractures**
- **F**    **Flail chest**
- **G**    **Gas**
- **H**    **Heart and pericardium**
- **H**    **Hemothorax, hematoma, hemorrhage**
- **I**    **Iatrogenic injuries**

*Gurney JW et al. 1996  
www.chestx-ray.com*