Anomalies mammographiques (Introduction)

Dr Fellah Latifa

Cliniques Universitaires Saint-Luc

Plan

- Densité mammographique
- Localisation des lésions
- Caractéristiques des lésion

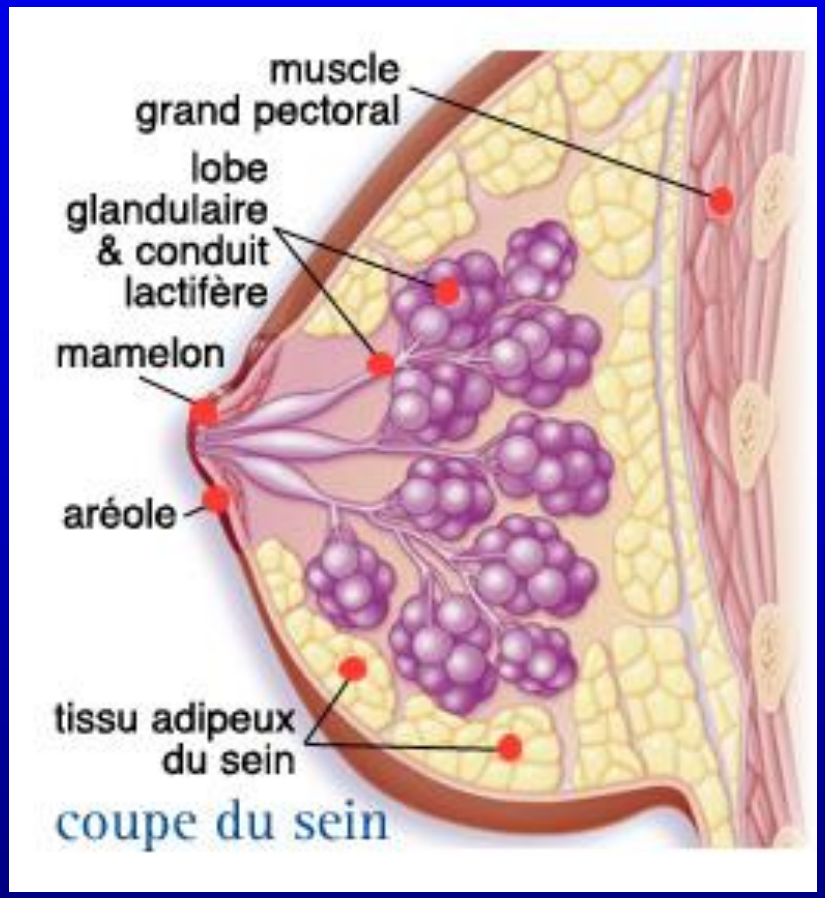
muscle
grand pectoral
lobe
glandulaire
& conduit
lactifère
mamelon
aréole
tissu adipeux
du sein
coupe du sein

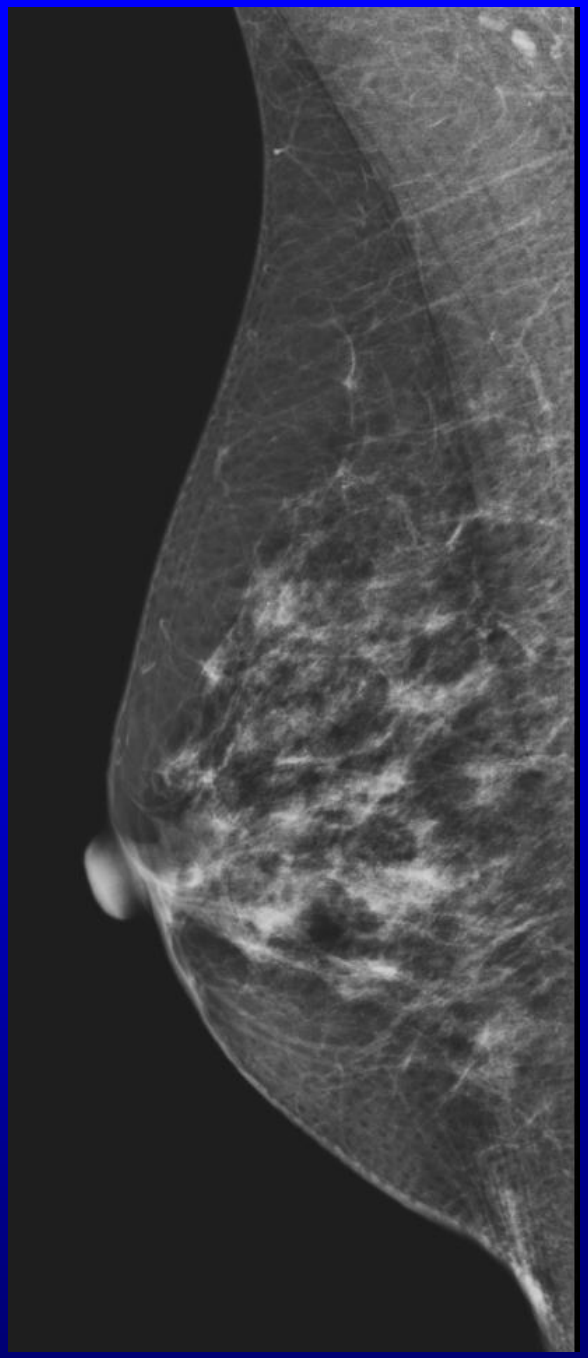

Densité glandulaire

- Classification en 4 catégories selon l'American College of Radiologie (ACR)
  - ACR 1: Sein graisseux ou involution lipomateuse prépondérente
  - ACR 2: Seins en involution lipomateuse partielle
  - ACR 3 : Seins hétéro-nodulaires
  - ACR 4: Seins denses

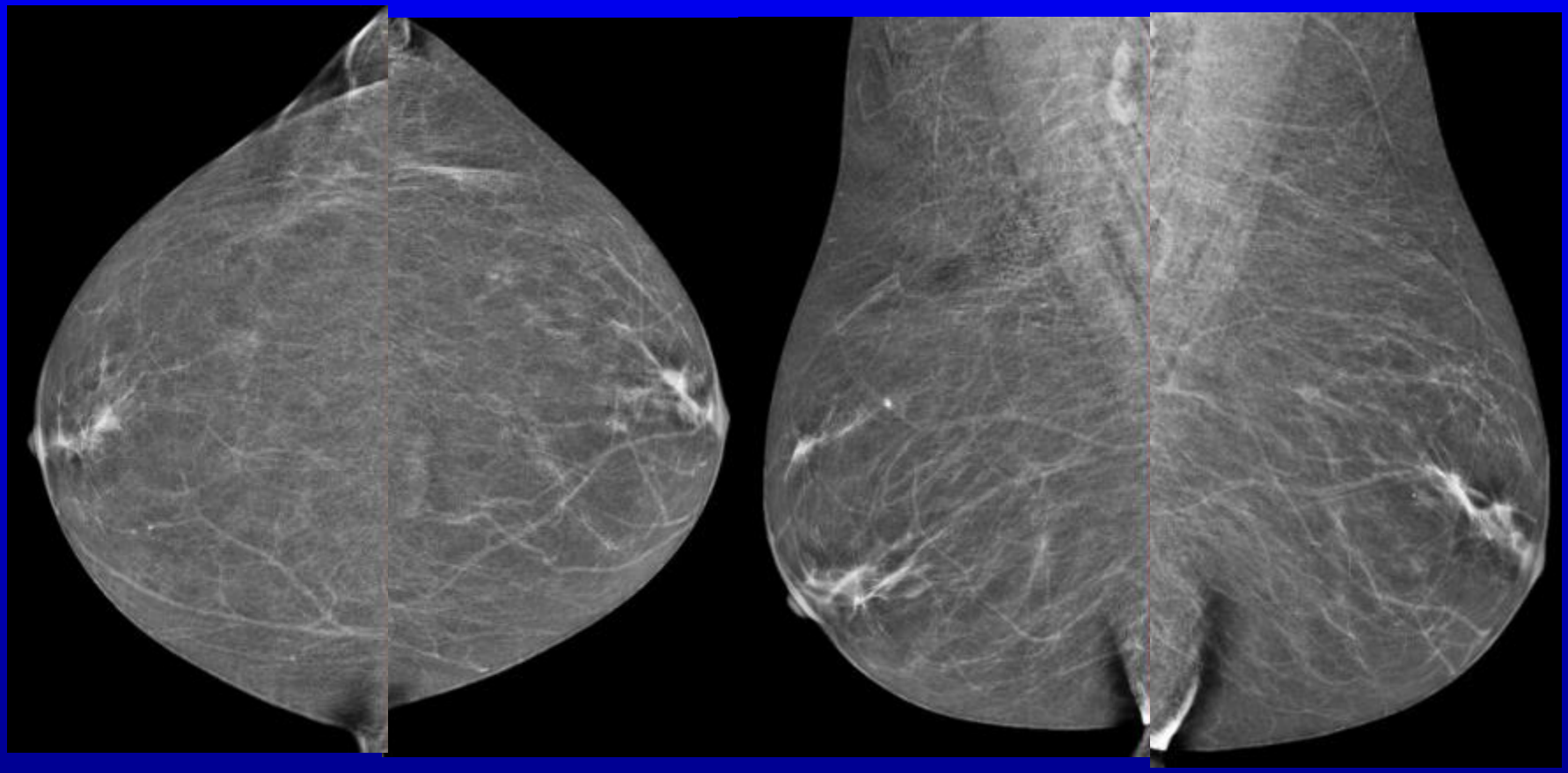

Graisseux => ACR 1

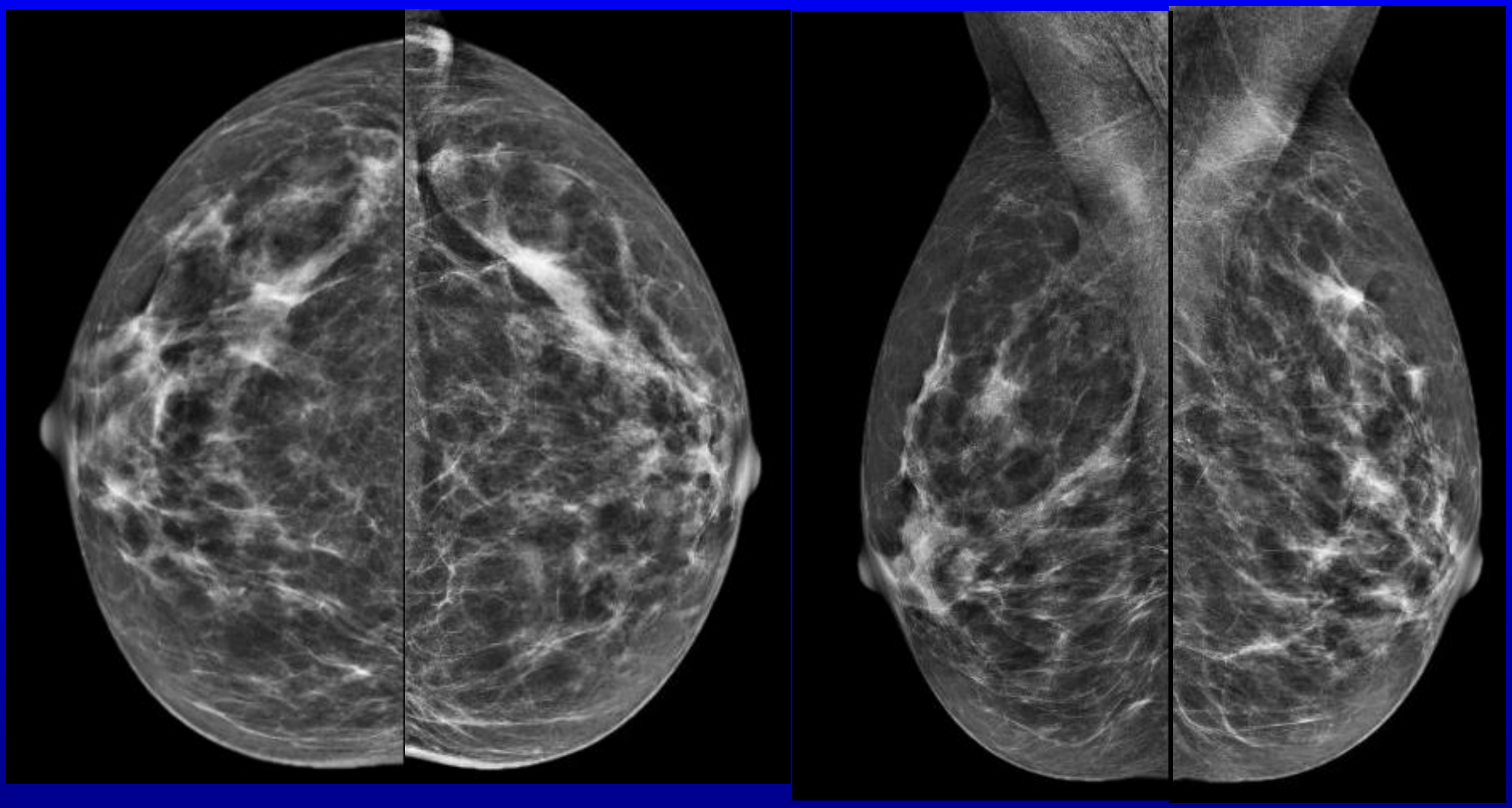

Seins involution lipomateuse partielle => ACR 2

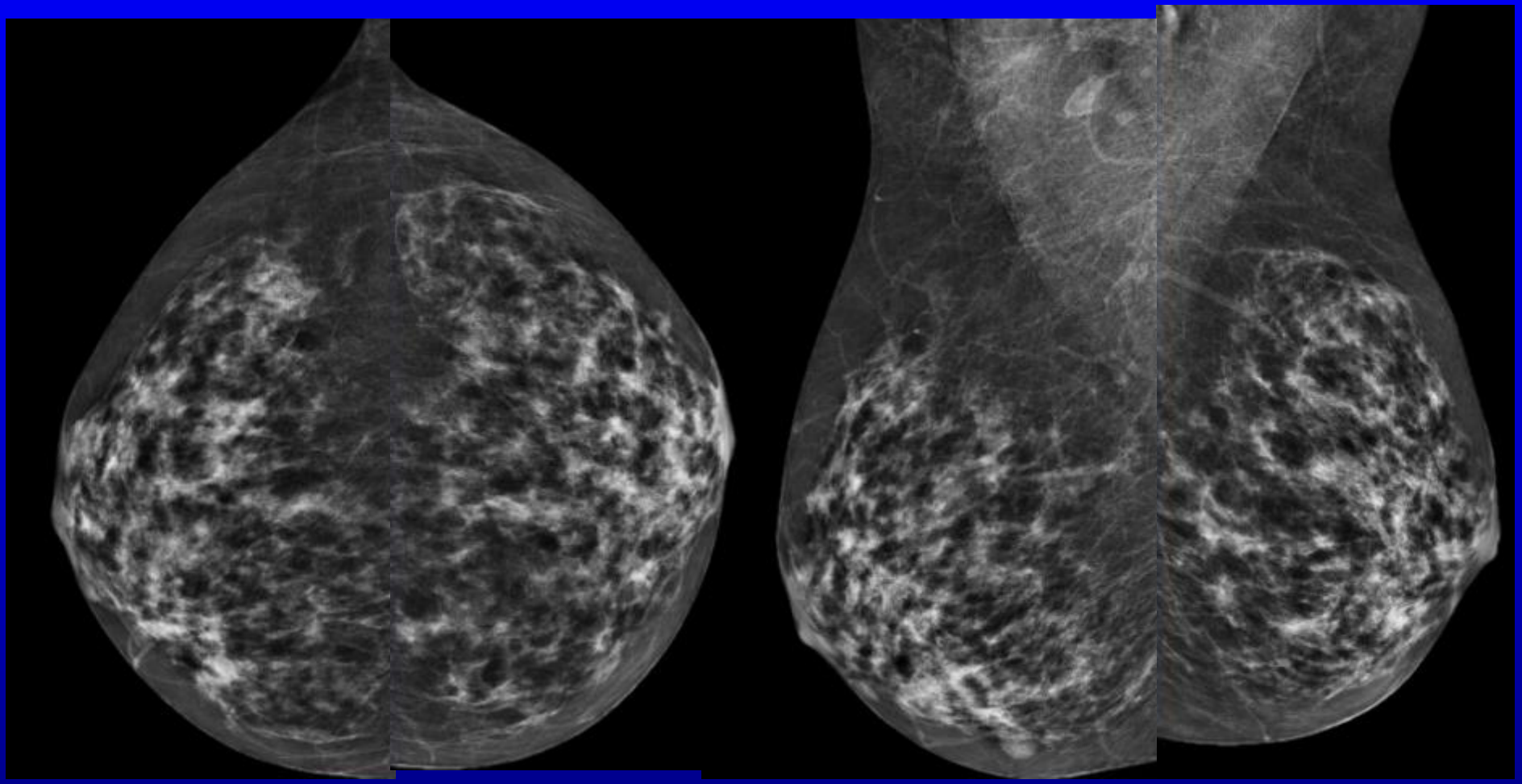

Seins hétéronodulaires => ACR 3

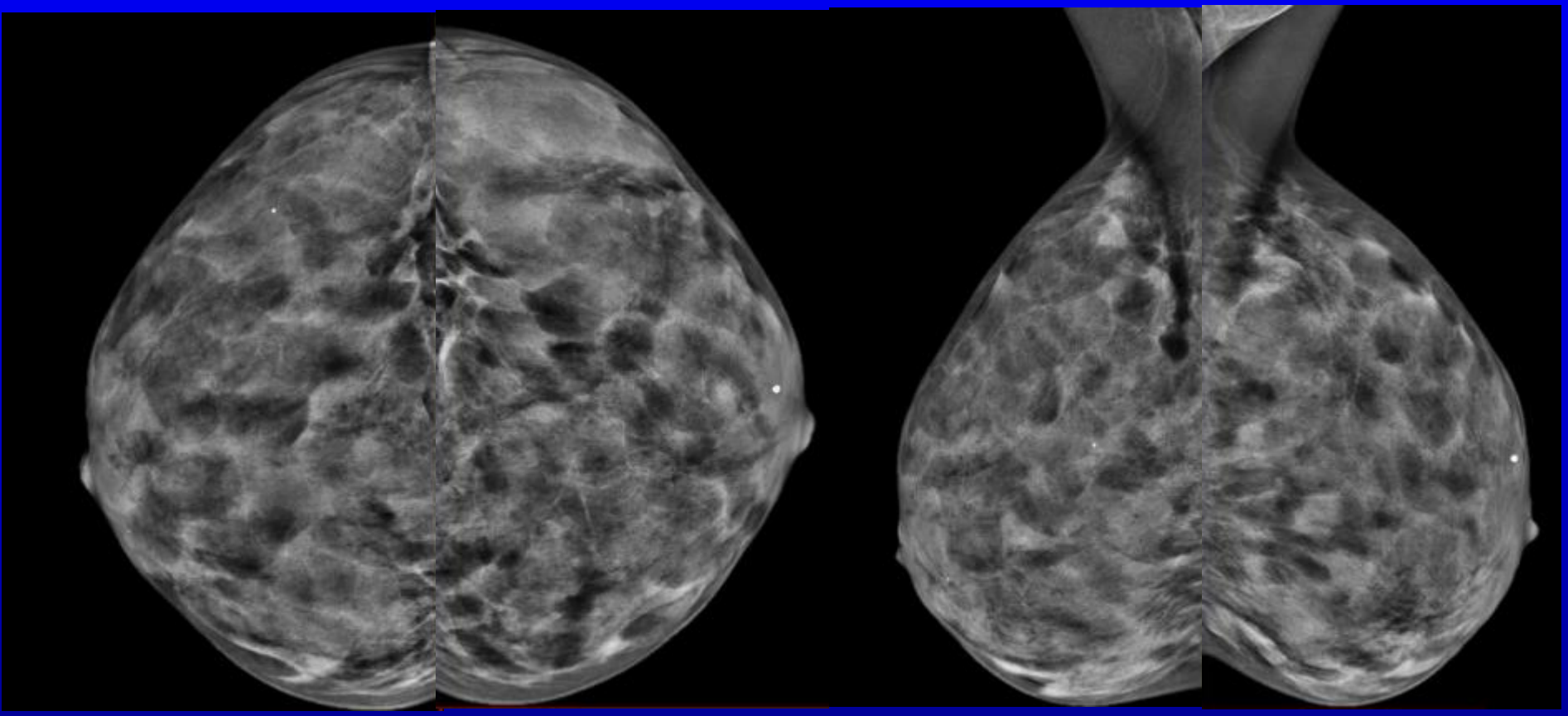

Seins denses => ACR 4

- Une lésion sera mieux visible dans des seins graisseux
- Sensibilité de la mammographie diminue (30%) dans les seins denses ACR 4

Raikhlin A. AJR 2015

EFFET de MASQUE

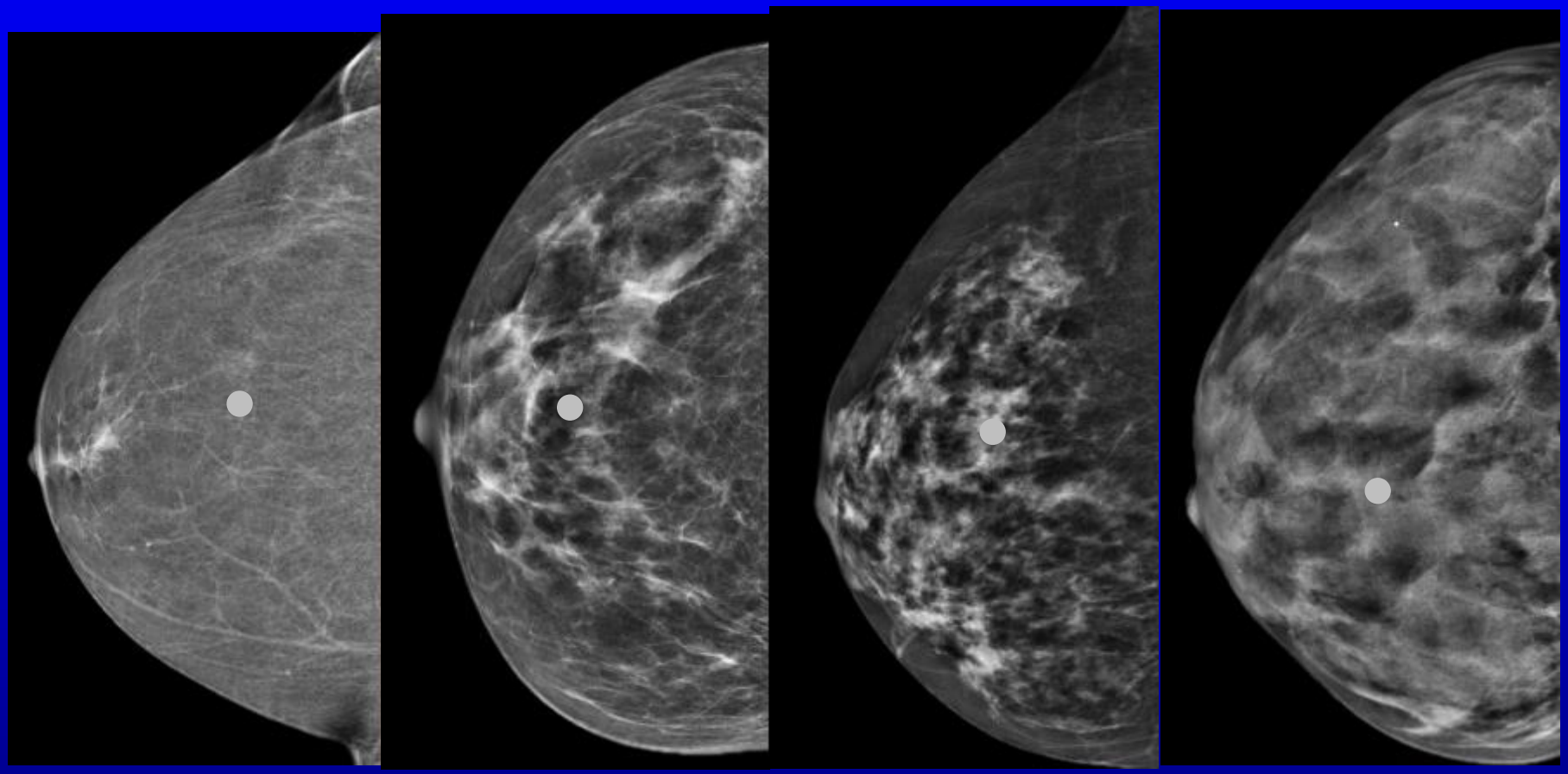

Localisation des anomalies

Quadrants mammaires

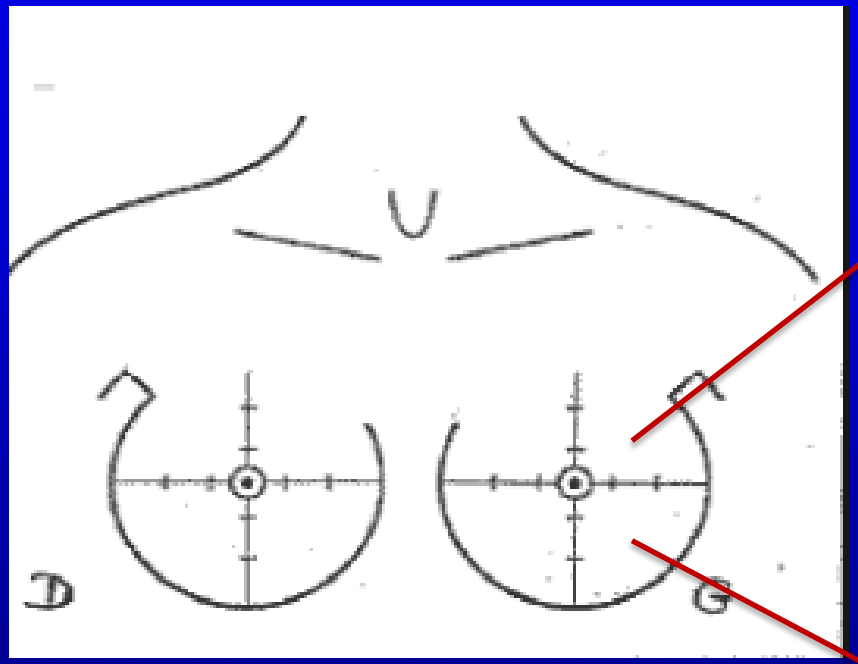

Supéro-externe

Inféro-externe

Quadrants mammaires

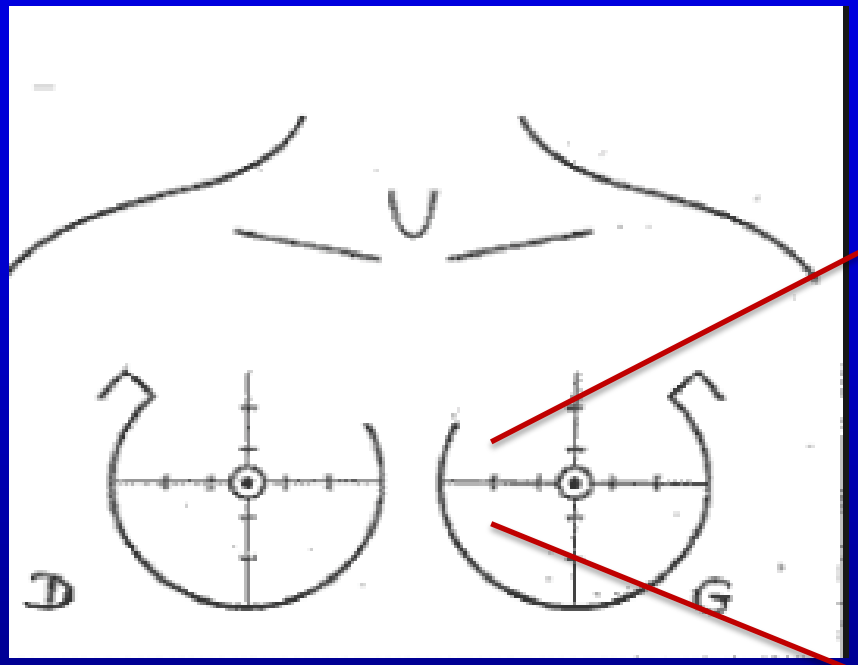

Supéro-interne

Inféro-interne

Quadrants mammaires

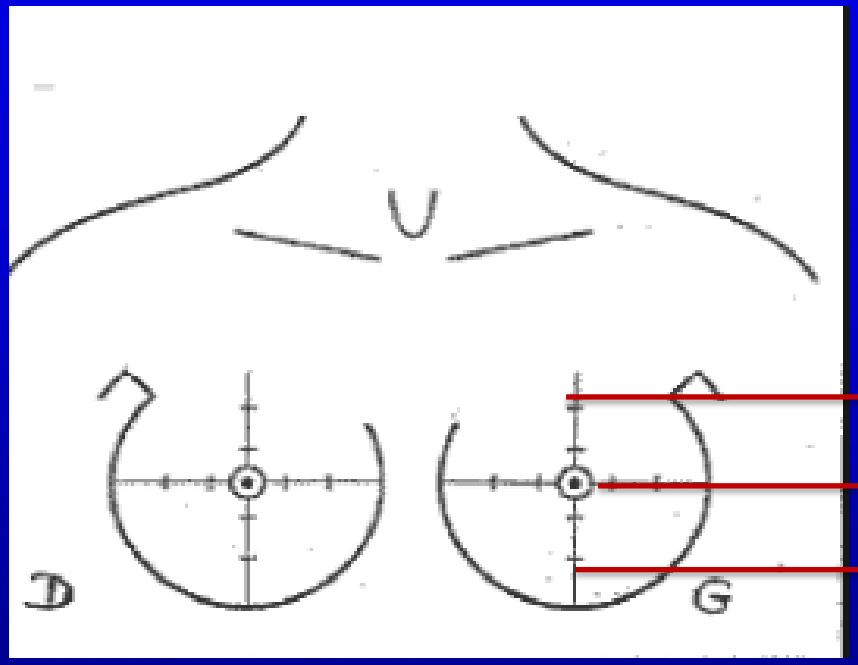

Supéro-médian

Rétro-aréolaire

Inféro-médian

Crânio-caudale

Externe

Médian

Interne

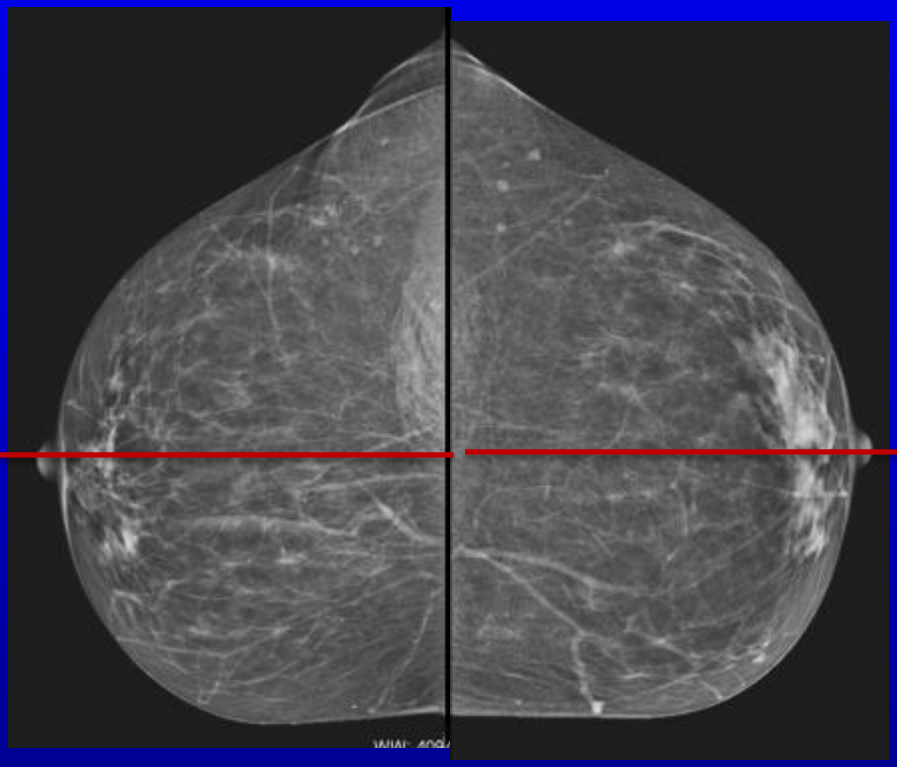

Externe

Médian

Interne

D

G

Incidence axillaire

Supérieure

Equatoriale

Inférieure

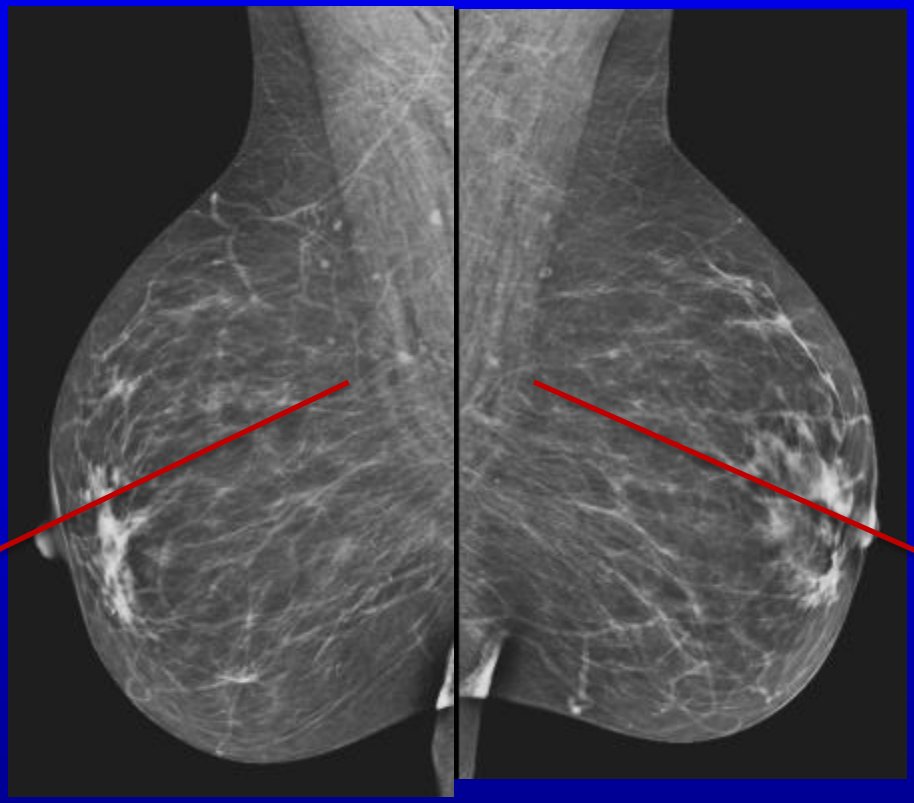

Supérieure

Equatoriale

Inférieure

D

G

Lésion inféro-externe droite

Crânio-caudal

axillaire

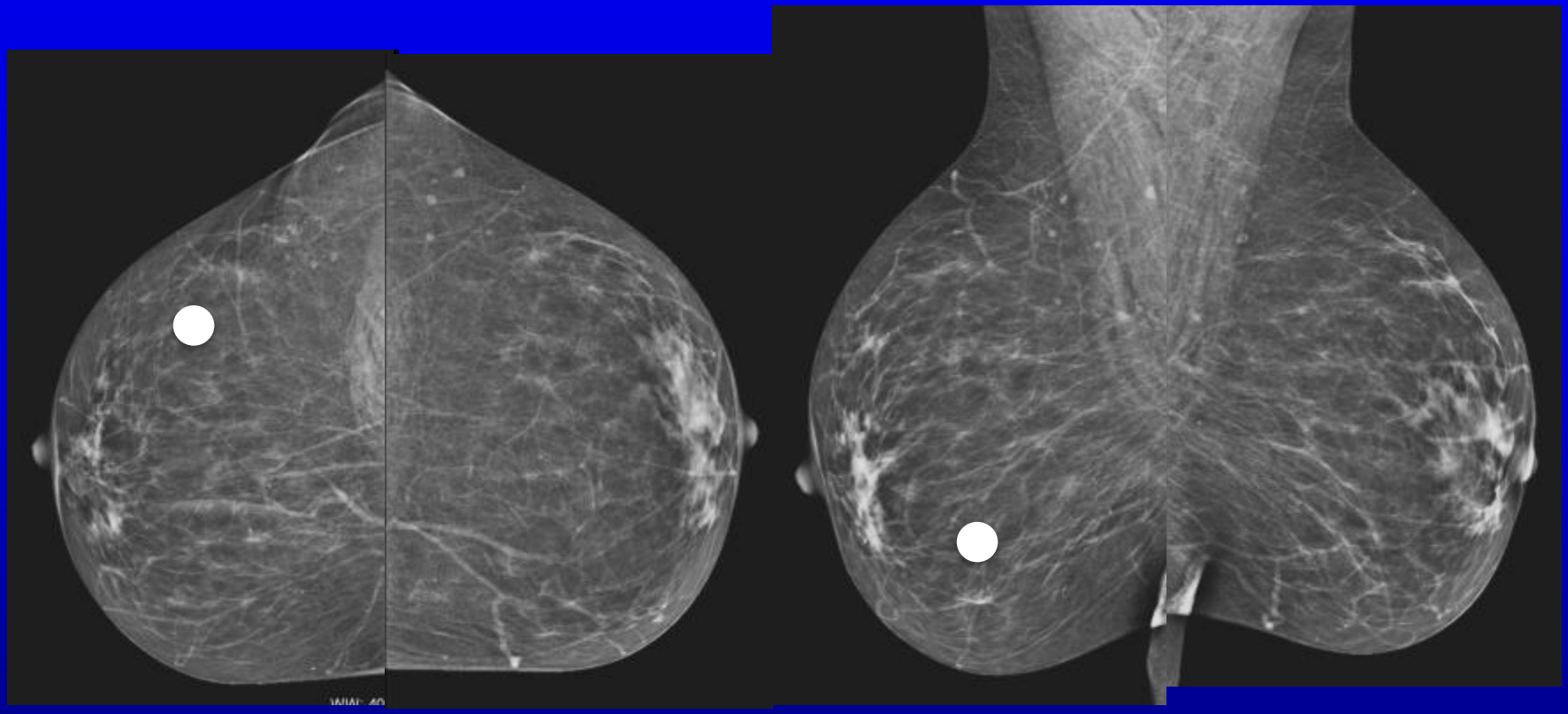

D G D G

Lésion supéro-interne gauche

Crânio-caudal

axillaire

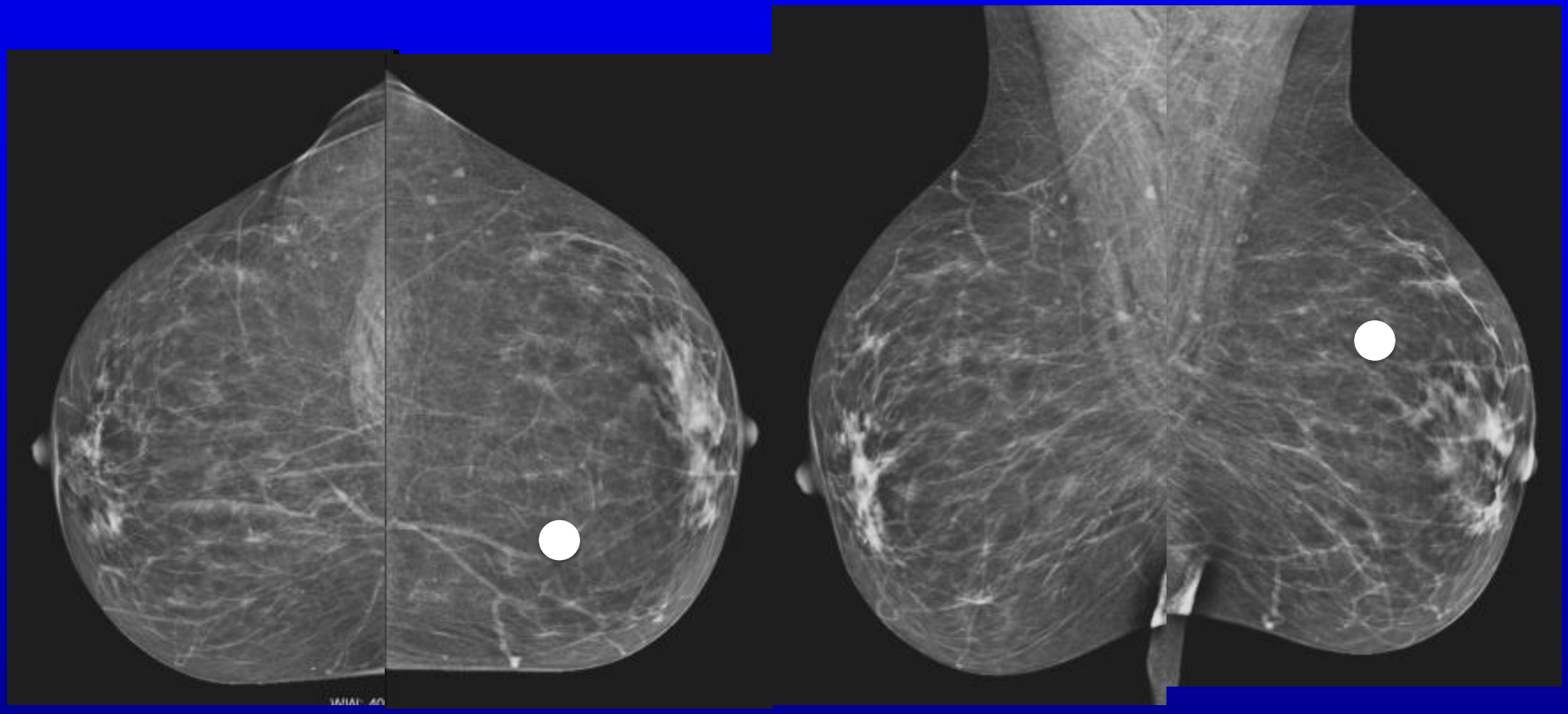

D G D G

Lésion équatoriale-interne gauche

Crânio-caudal

axillaire

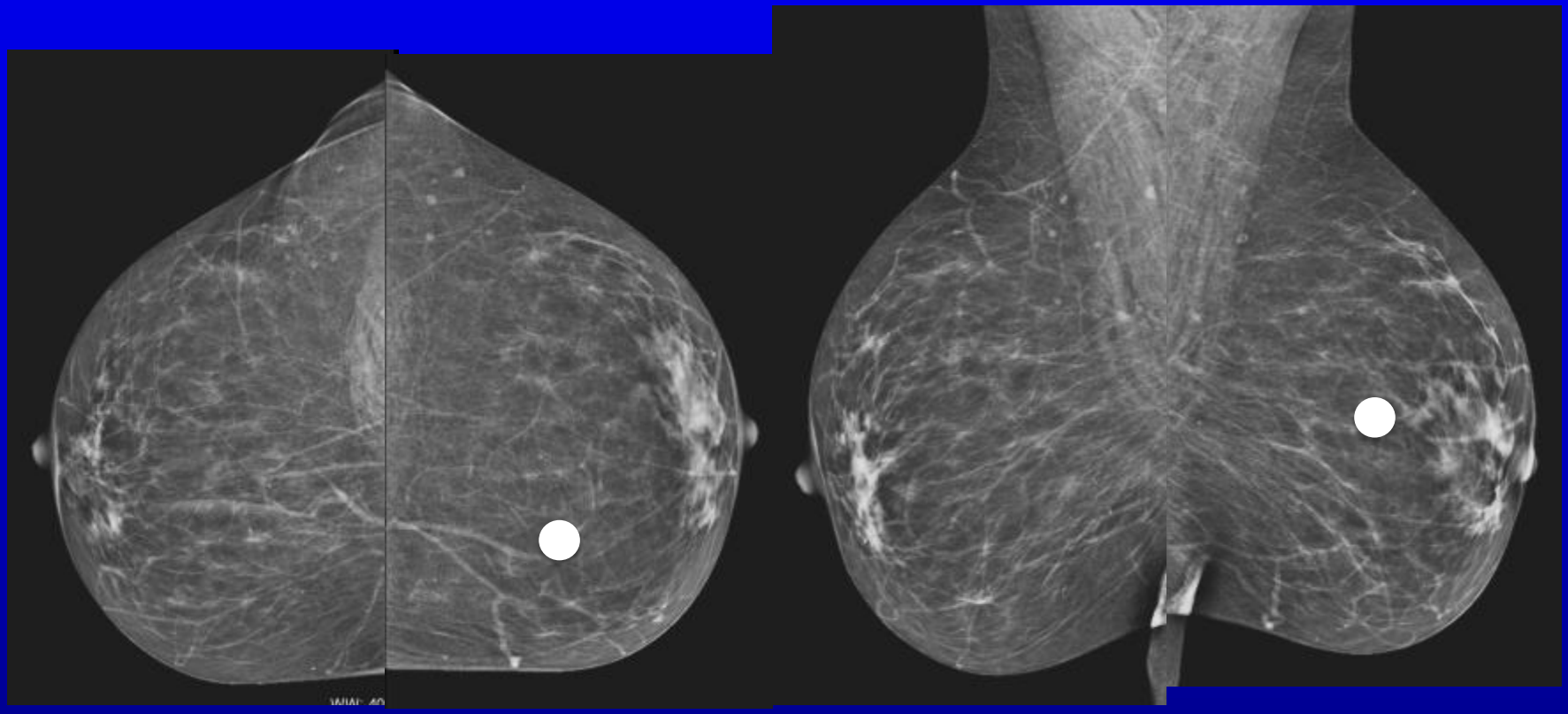

D G D G

Anomalies mammographiques

- Masse
- Microcalcifications
- Asymétrie de densité
- Désorganisation architecturale

BI-RADS Brest Imaging Reporting and Data System

BI-RADS:	Risque cancer (%)
• 1 Normal	0
• 2 Bénin	0
• 3 Indéterminé	≤ 2
• 4 a,b,c	3- 94
• 5 Malin	≥ 95

BI-RADS Brest Imaging Reporting and Data System

BI-RADS:	Risque cancer (%)	
• 1 Normal	0	Surveillance normale
• 2 Bénin	0	Surveillance normale
• 3 Indéterminé	≤ 2	Suivi à court terme
• 4 a,b,c	3- 94	Biopsie
• 5 Malin	≥ 95	Biopsie

Masse: critères à étudier

- Forme
- Contour
- Densité

En faveur d'une masse bénigne

- Forme régulière
- Contour bien délimité
- Contenant des zones radiotransparentes

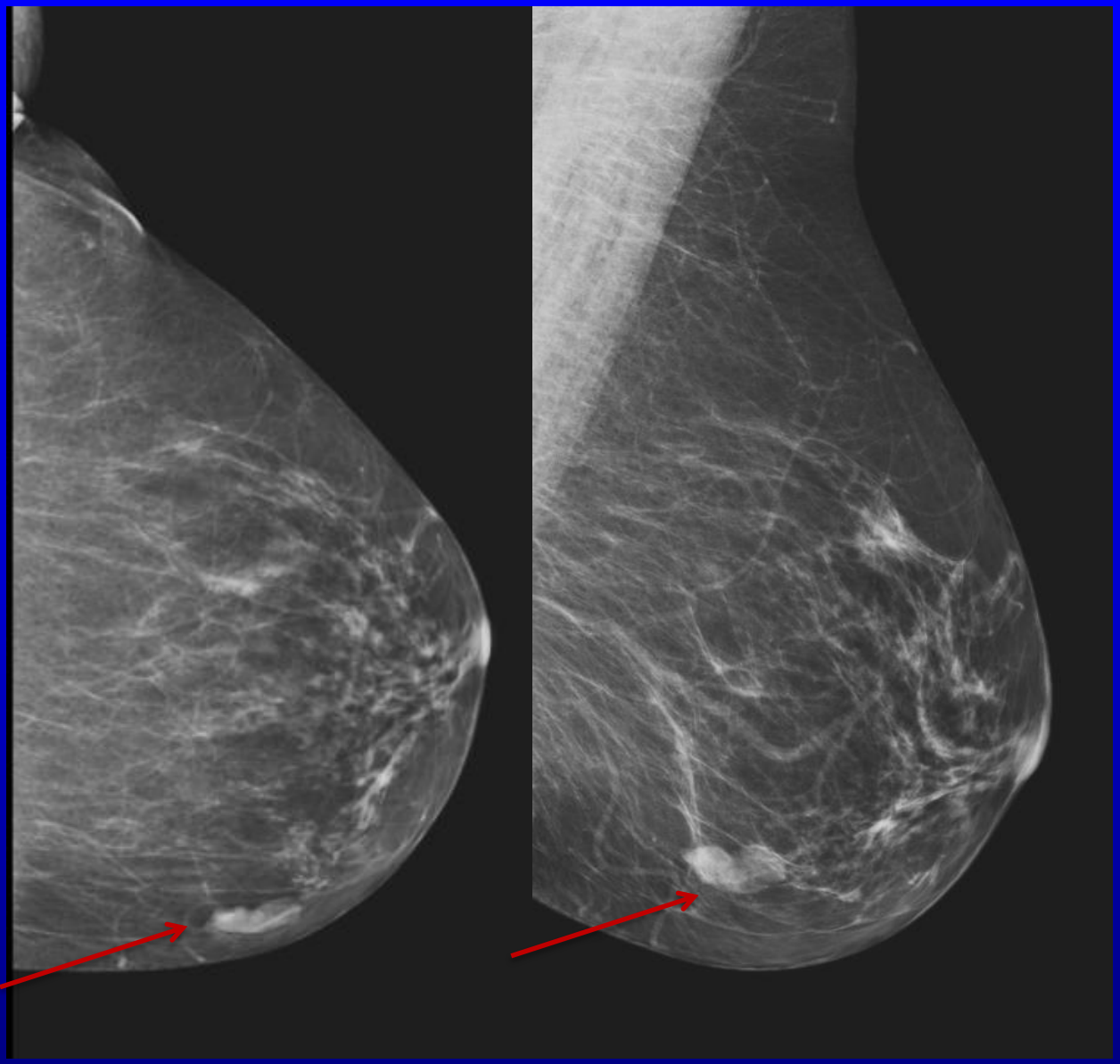

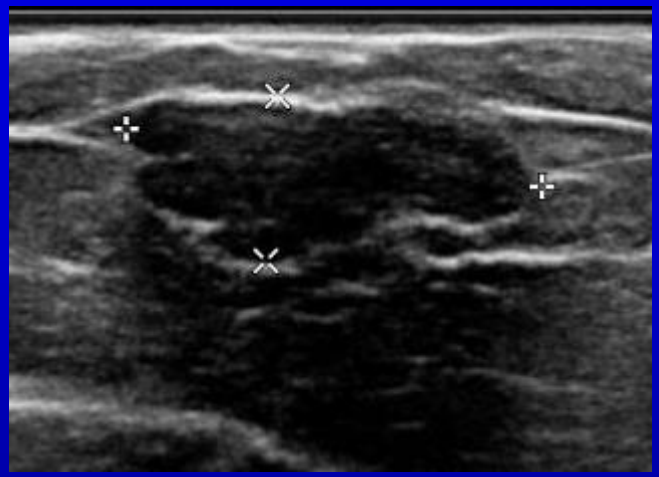

En faveur d'une masse maligne

- Forme irrégulière, microlobulée, spiculée
- Contour mal délimité

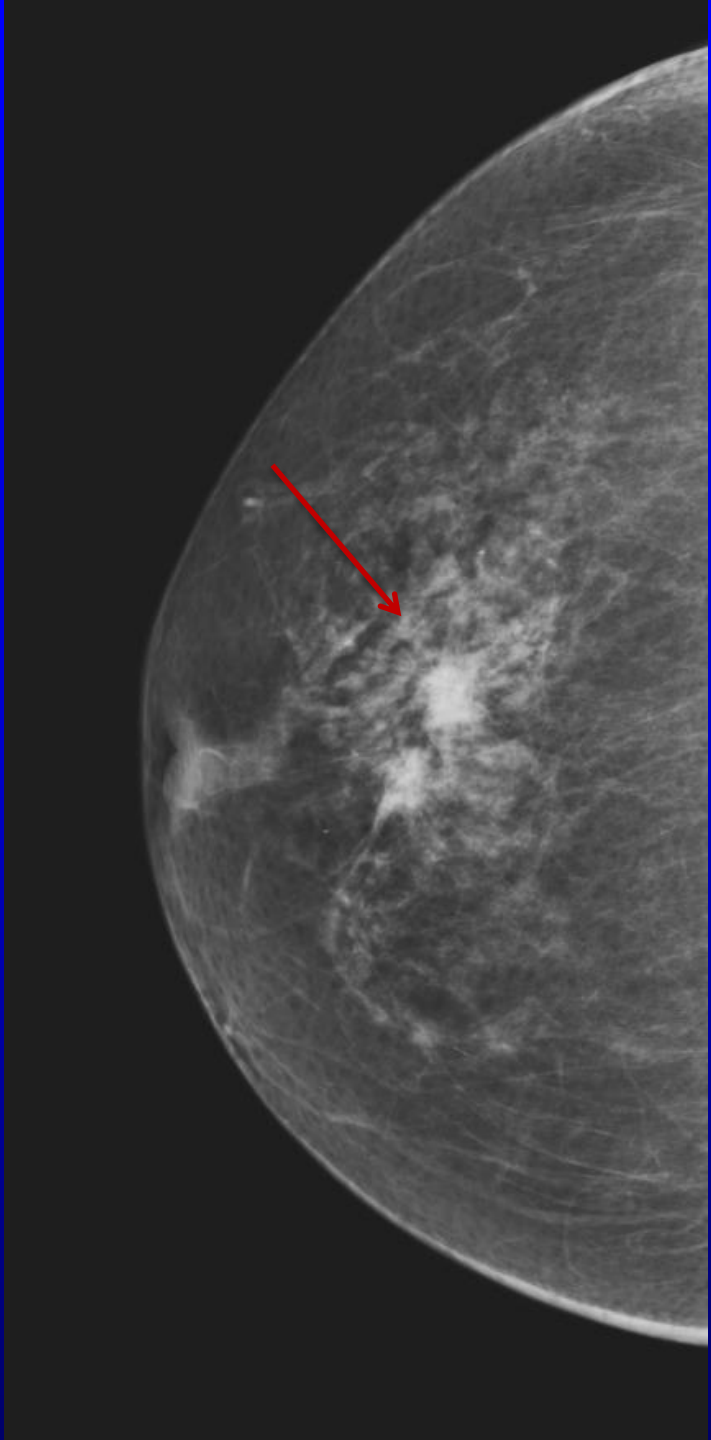

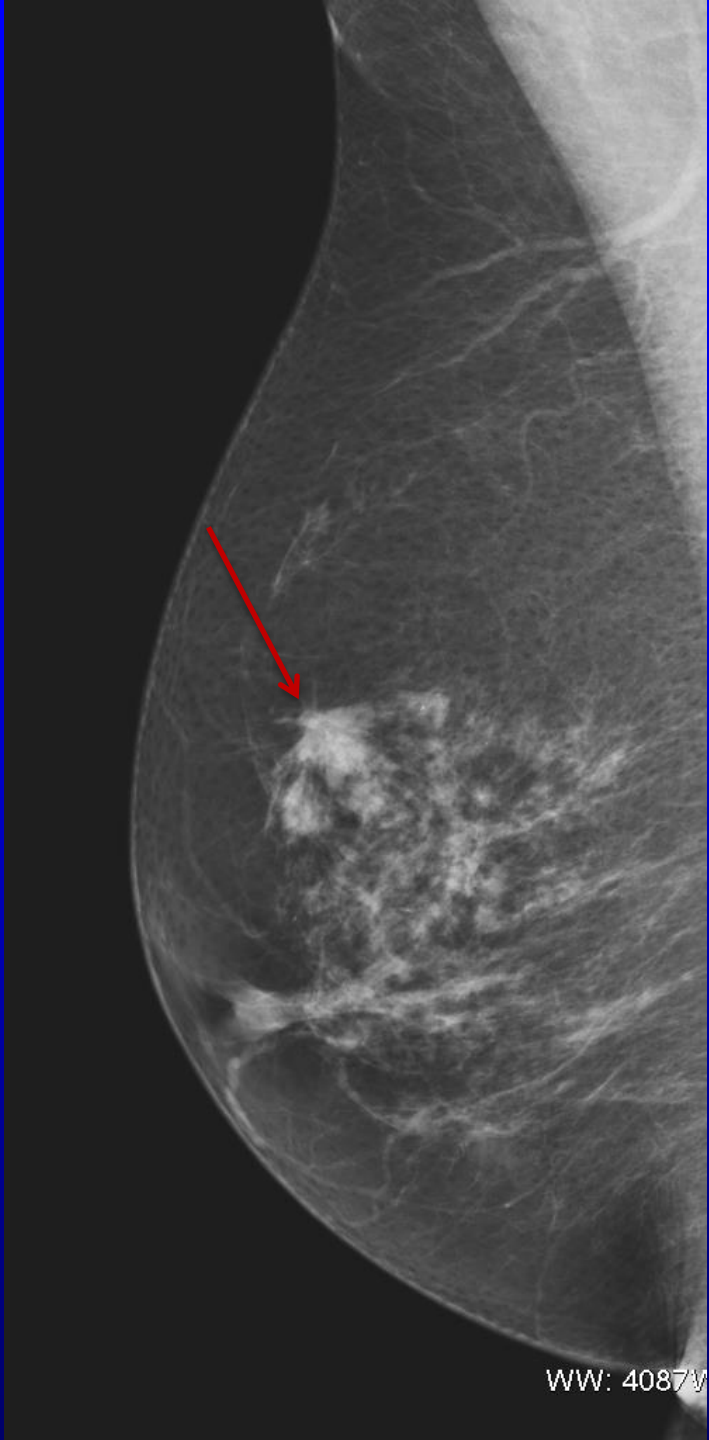
WW: 4087

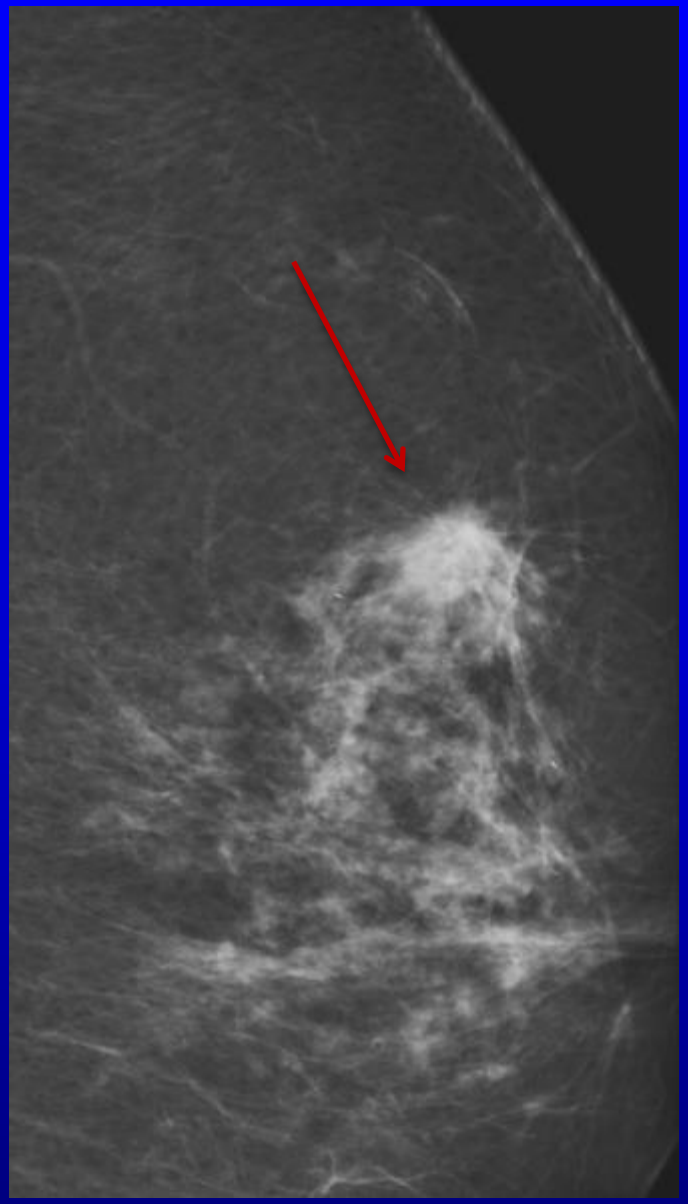

Calcifications

- Diffuses ou en foyer

Calcifications

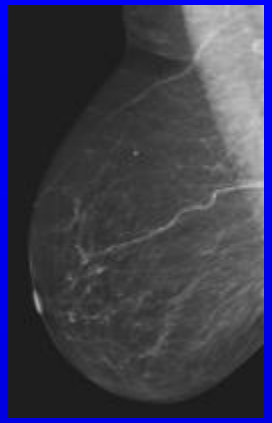

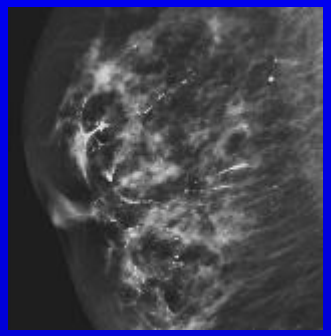

- Typiquement bénignes:
  - Vasculaires
  - En segment d'aiguille brisée (séquelles)
  - En « pop-corn »
  - Sédimentaires en « tasse de thé »
  - Sous cutanées
  - Microkystes calcifiés

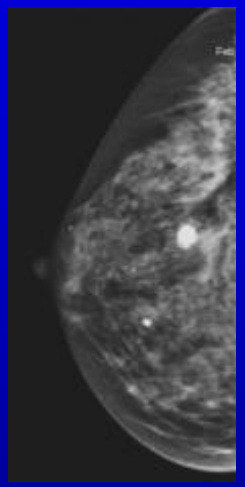

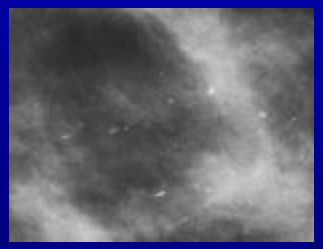

Foyer de microcalcifications

- Forme
- Nombre
- Distribution

En faveur d'un foyer malin

- Microcalcifications
  - Pléomorphes
  - Irrégulières
  - Branchées ou linéaires
  - Nombreuses
  - De densité différente
- Forme triangulaire

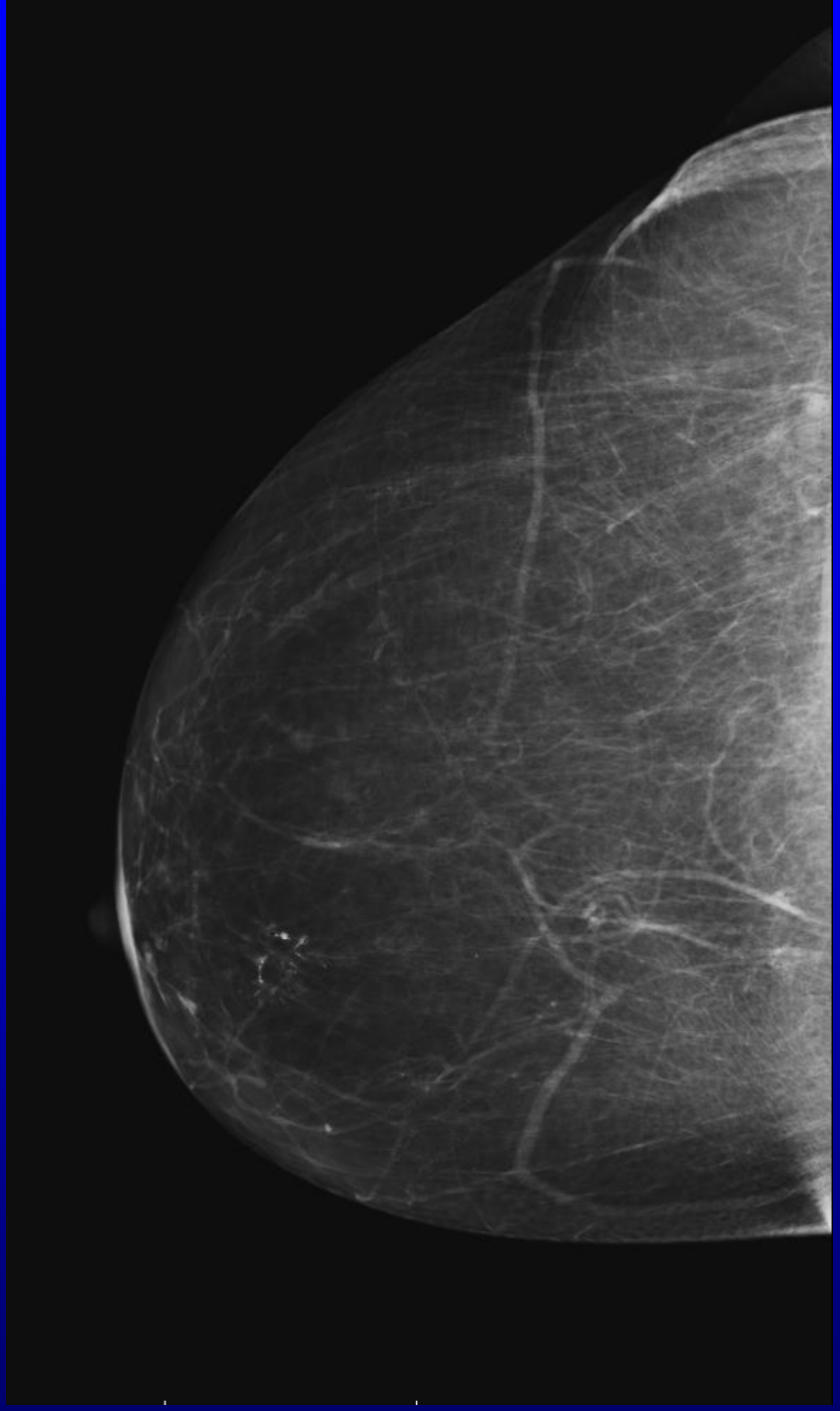

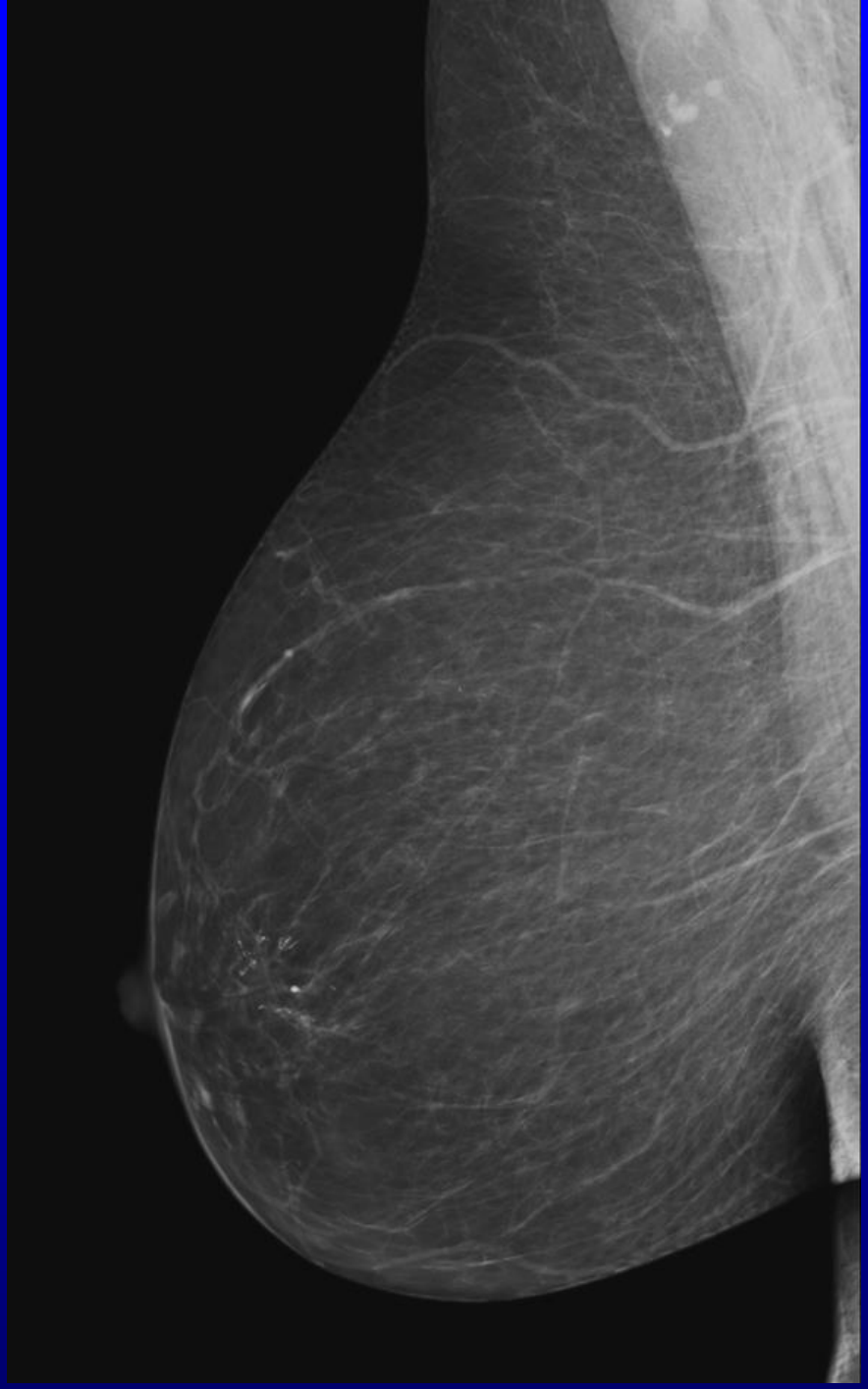

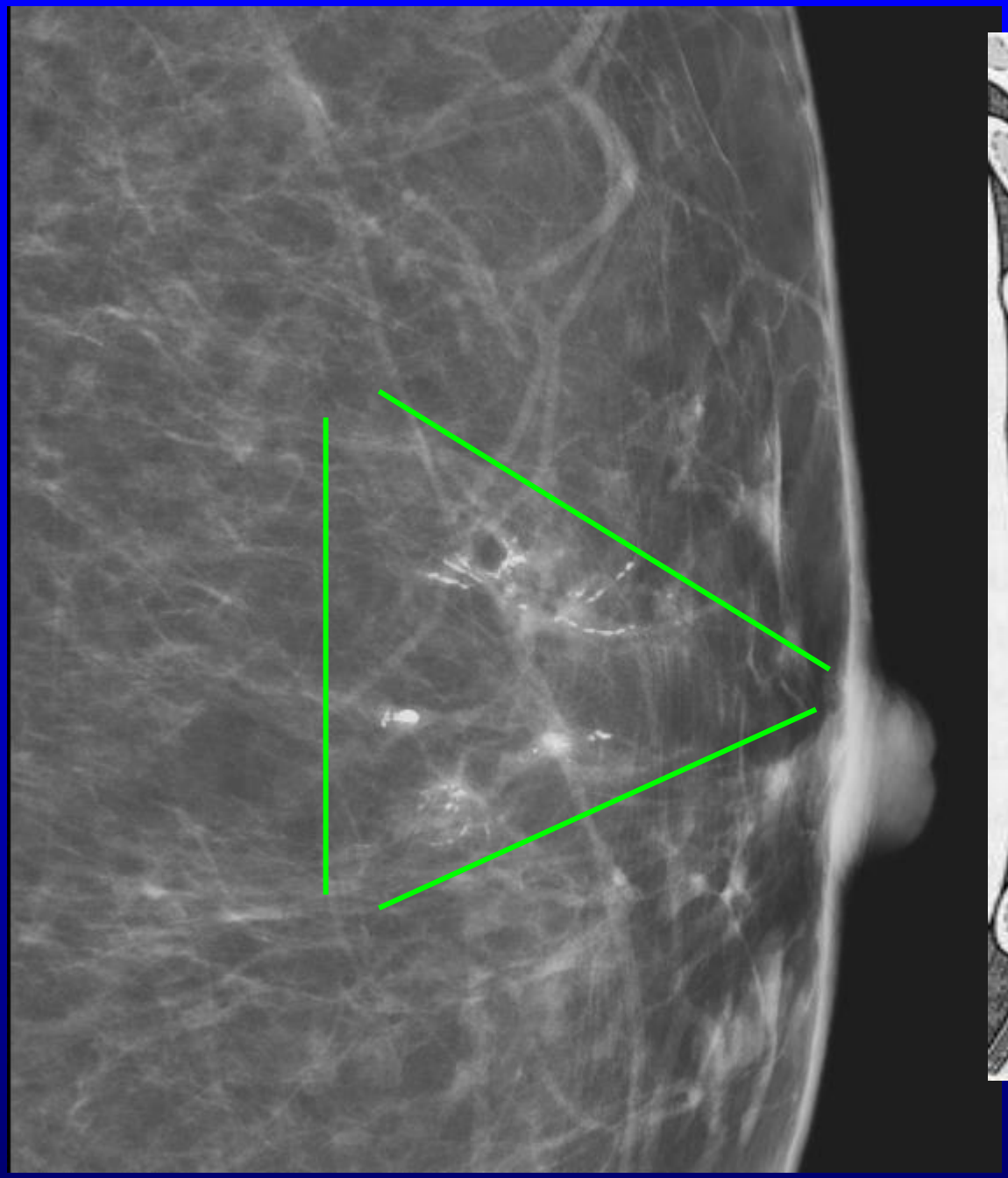

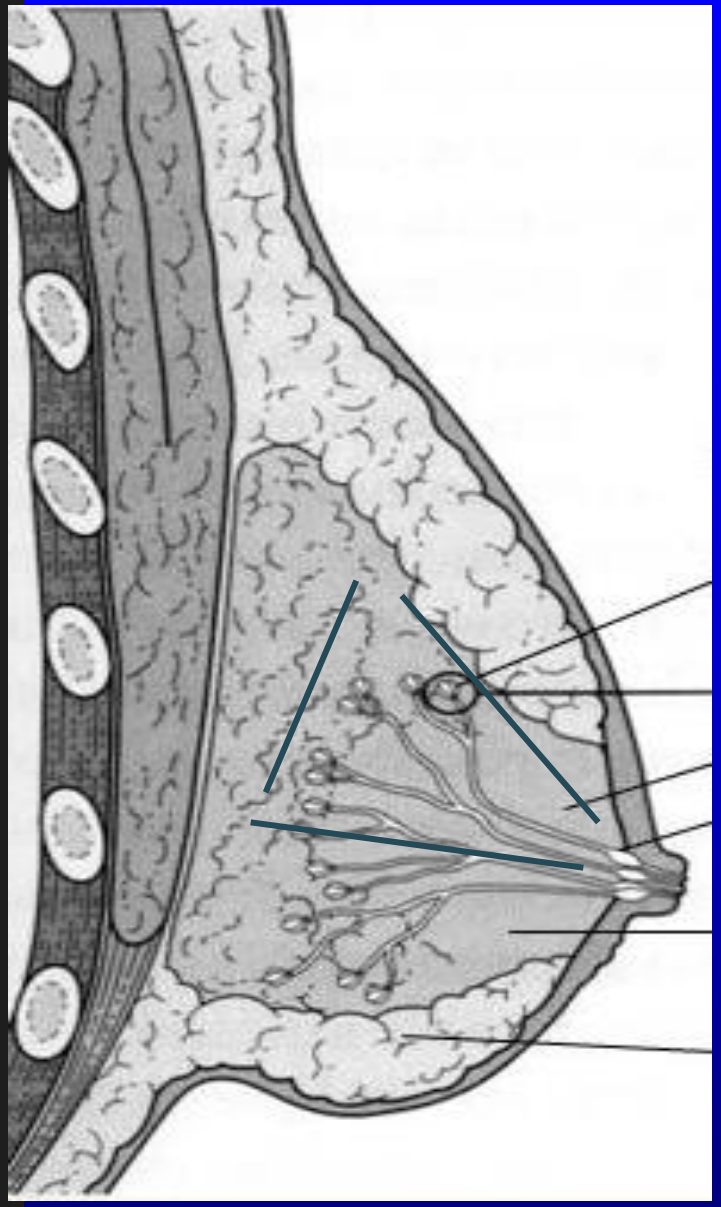

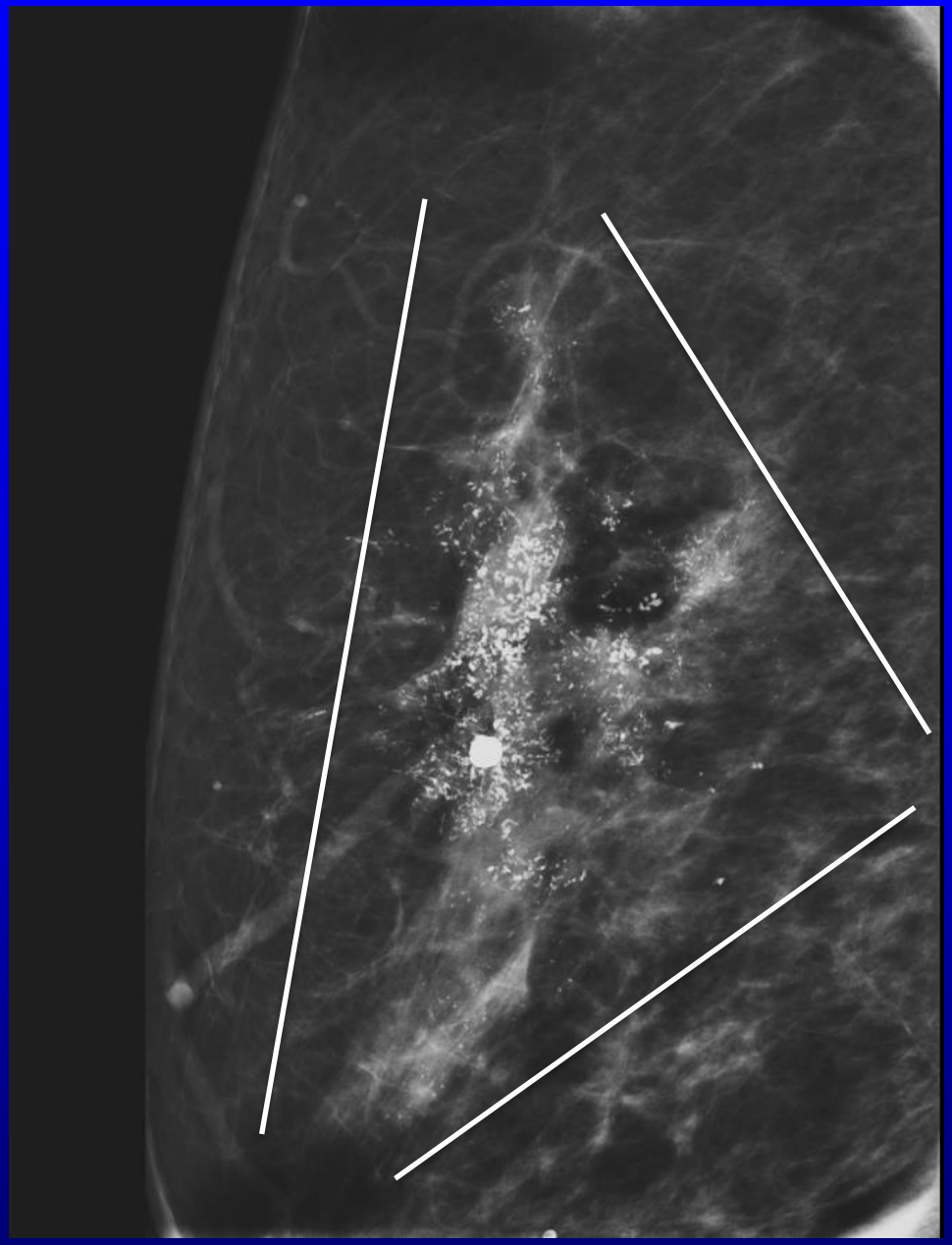

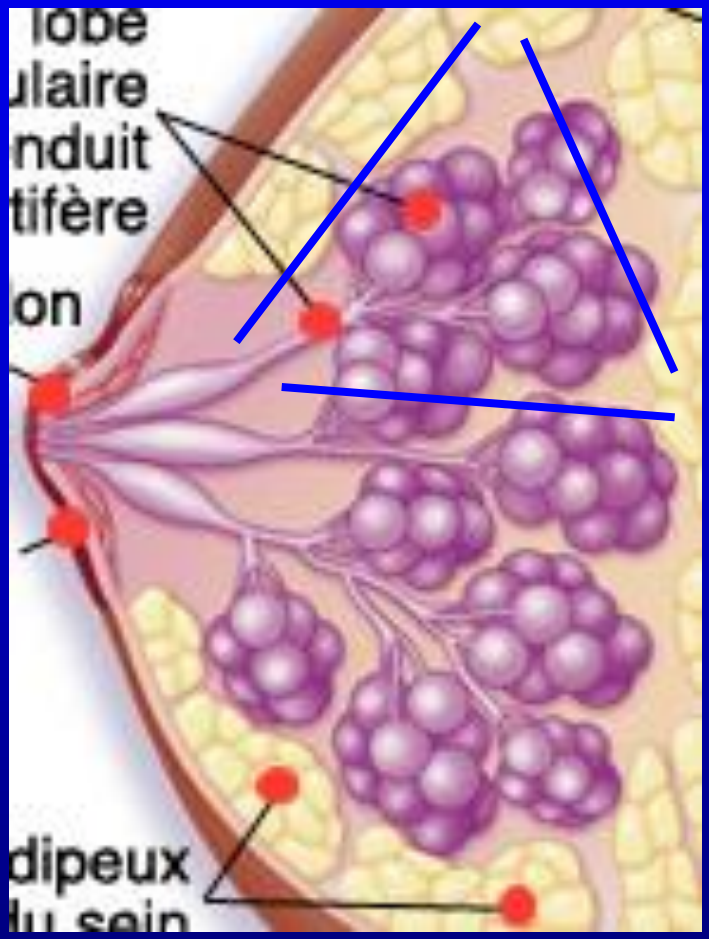
lobe
ulaire
nduit
tifère
on
dipeux
du sein