

Comment je réponds au clinicien
qui me demande de classer
(selon ISSVA) une tache de naissance?

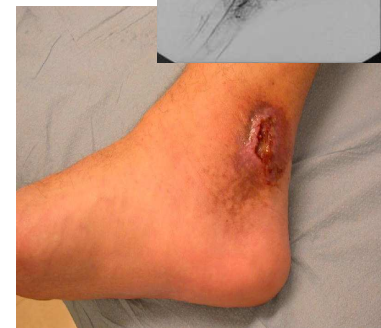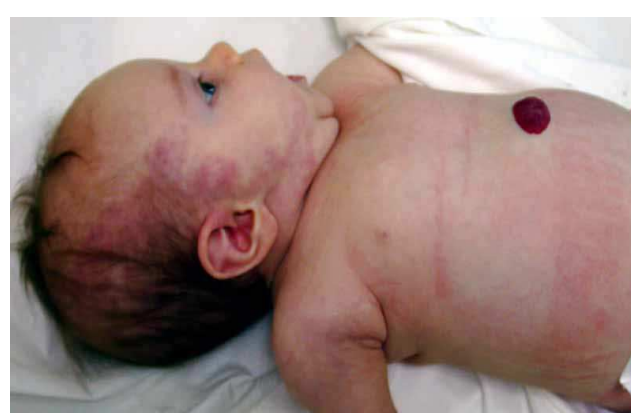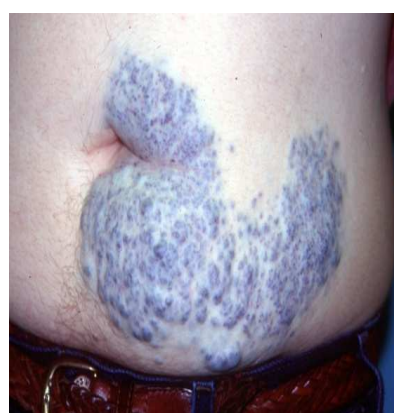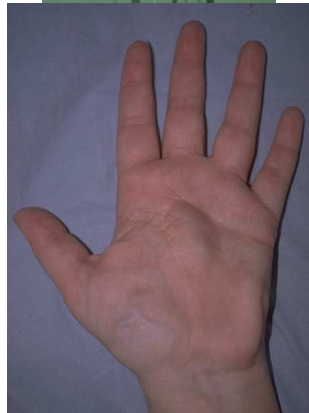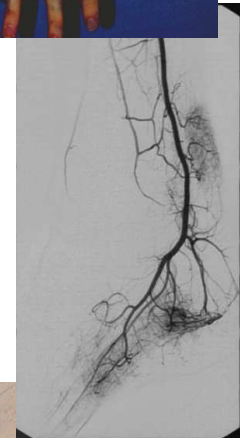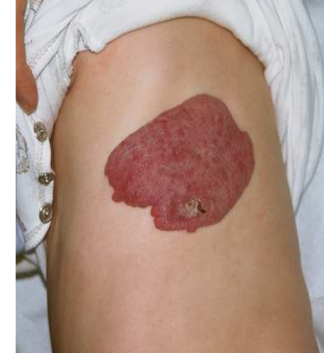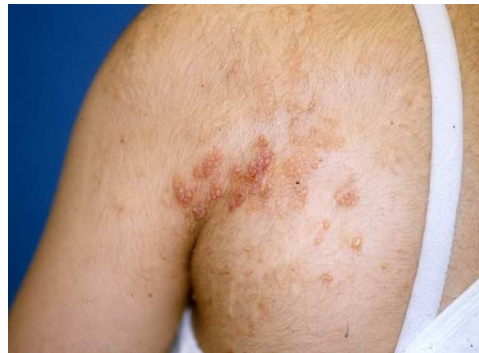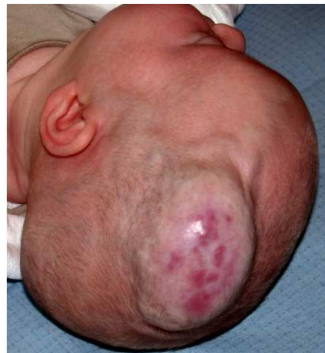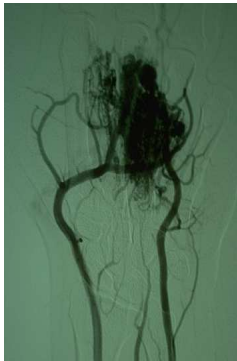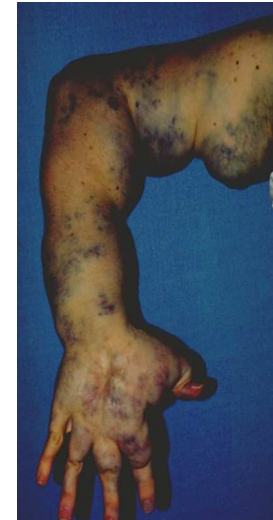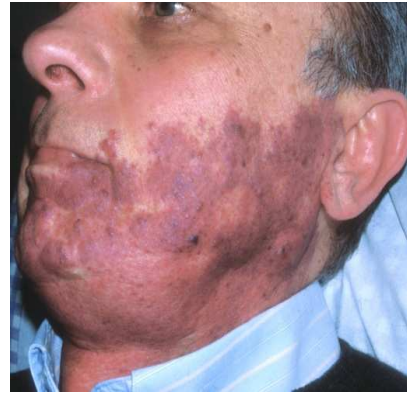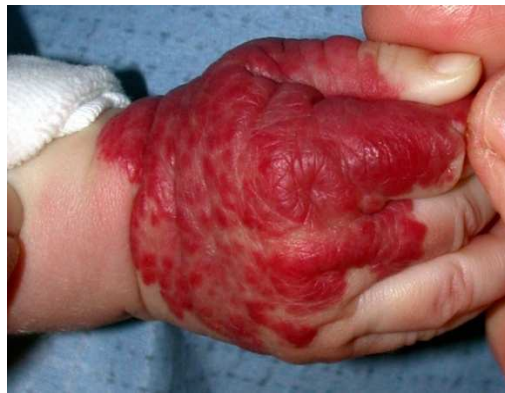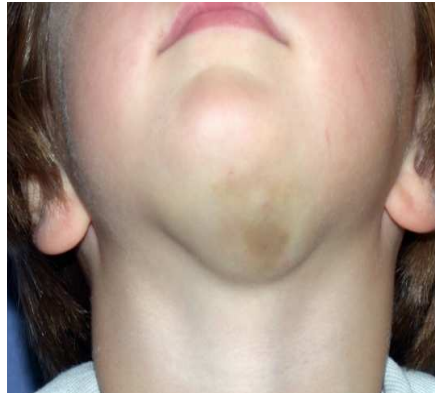Ph. Clapuyt, L. Boon

Cliniques universitaires saint Luc

Université catholique de Louvain

1200 Bruxelles

Les angiomes





ISSVA classification for vascular anomalies ©
 (Approved at the 20th ISSVA Workshop, Melbourne, April 2014)

Overview table

Vascular anomalies				
Vascular tumors	Vascular malformations			
	Simple	Combined °	of major named vessels	associated with other anomalies
Benign Locally aggressive or borderline Malignant	Capillary malformations Lymphatic malformations Venous malformations Arteriovenous malformations* Arteriovenous fistula*	CVM, CLM LVM, CLVM CAVM* CLAVM* others	See details	See list

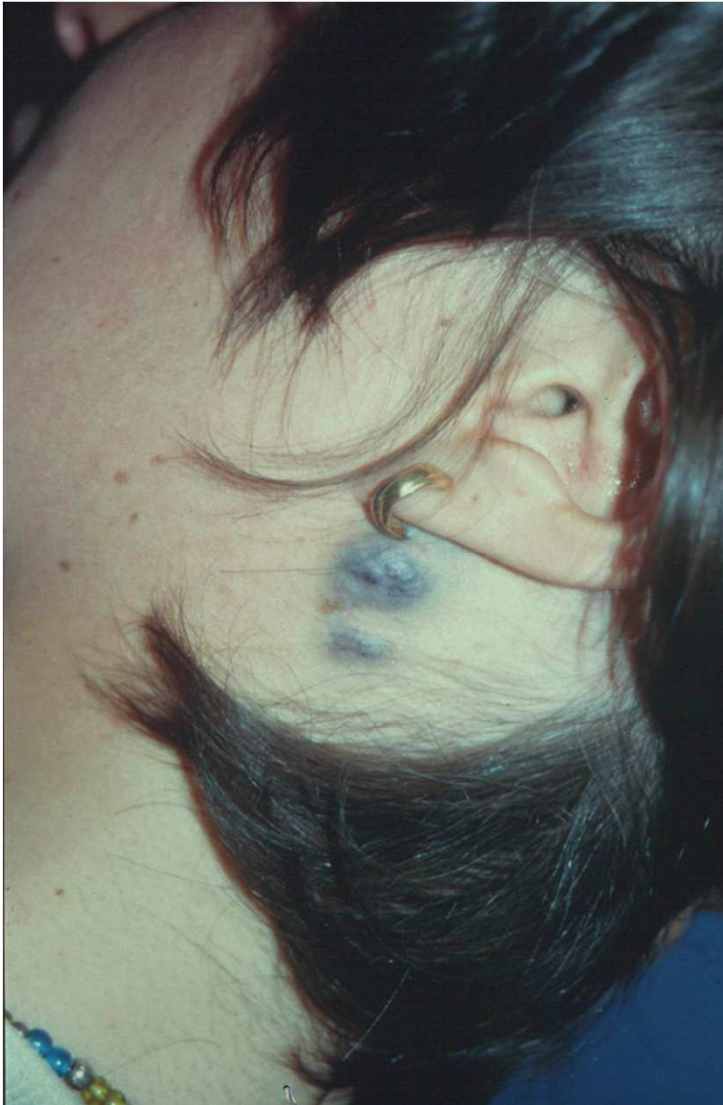° defined as two or more vascular malformations found in one lesion

* high-flow lesions

are imaging studies helpful for
diagnosis of vascular malformations?

in the vast majority : NO

in the vast majority : NO



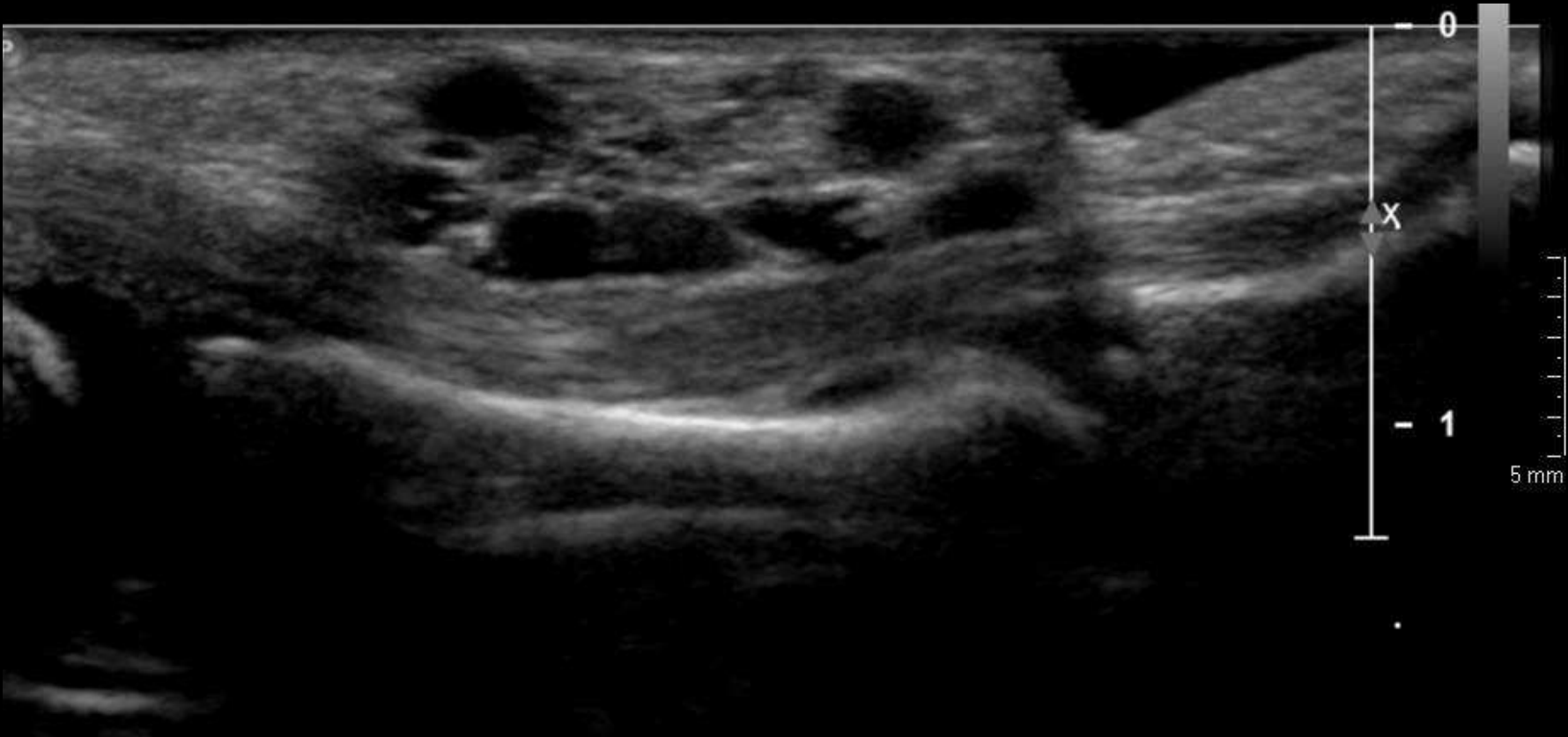
→ VM

caveats : differential diagnosis

- venous malformation ?
- lymphatic malformation ?

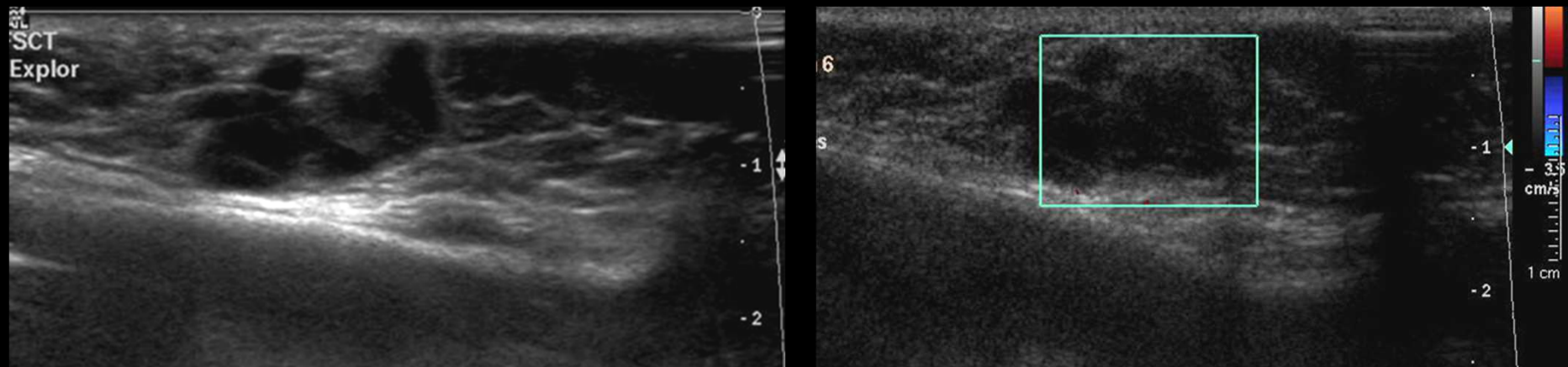
the radiologist is not always able
to answer the question !

LM ? - VM ?



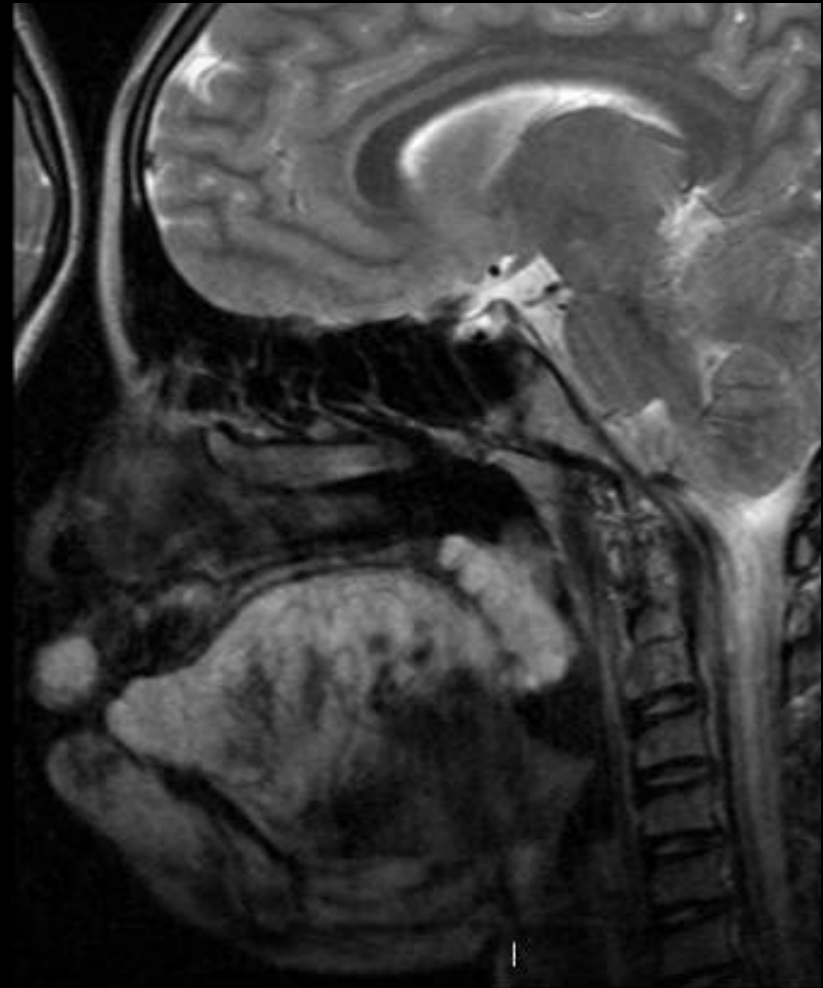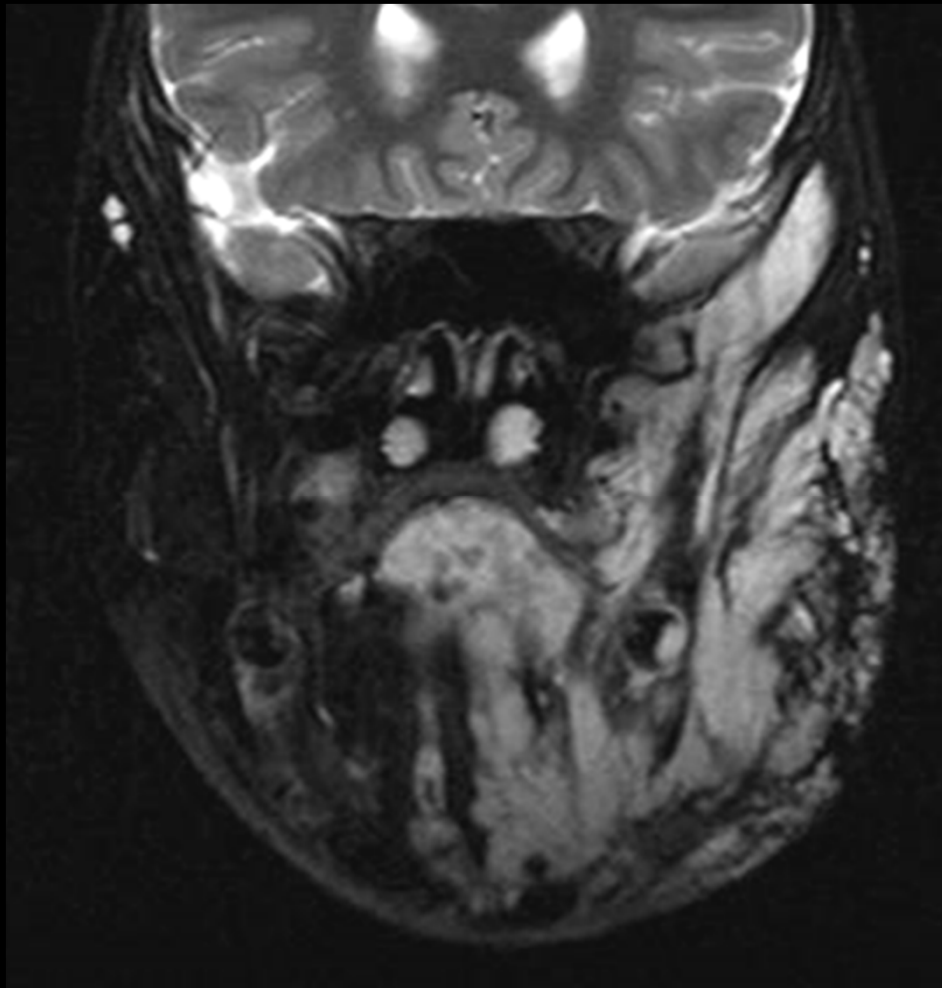
VM (finger)

LM ? - VM ?



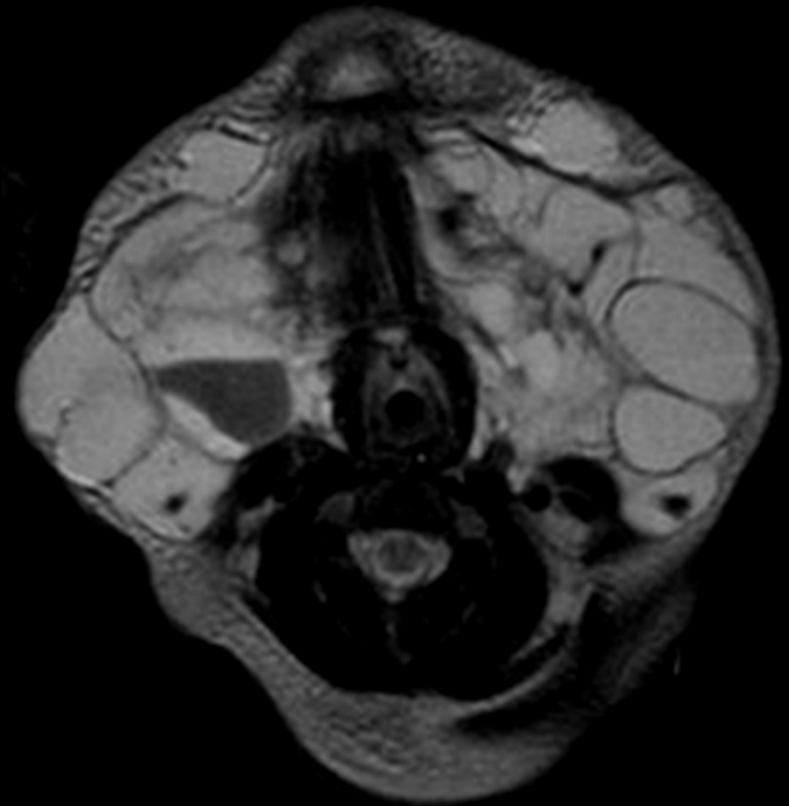
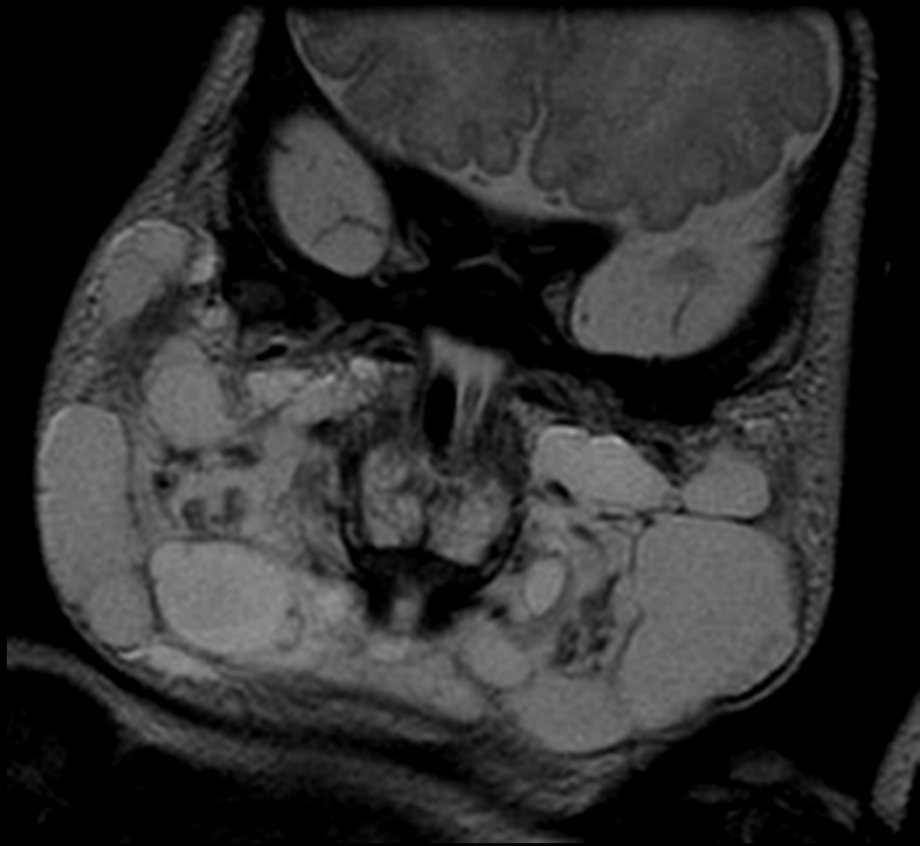
LM (leg)

LM ? - VM ?



VM

LM ? - VM ?



LM

VM / LM: differential diagnosis some clues

VM

- cyst-like
- channels
- draining vein(s)
- phlebolith(s)
- very slow flow
- filling during
compression/
decompression

VM / LM: differential diagnosis

some clues

VM

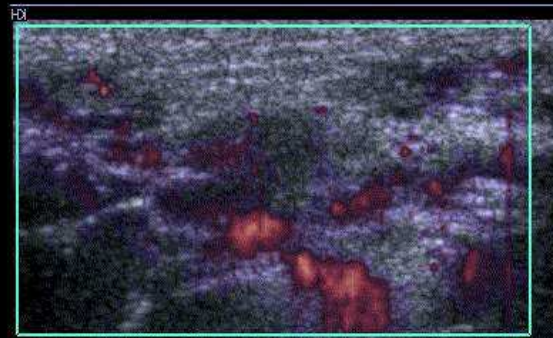
- cyst-like
- channels
- draining vein(s)
- phlebolith(s)
- very slow flow
- filling during compression/
decompression

LM

- variable sized cyst(s)
- frequent fluid/fluid
(debris) level
(hemorrhage)
- no flow into cyst
- vessels in septa
- not compressible

doubtful cases : Doppler US

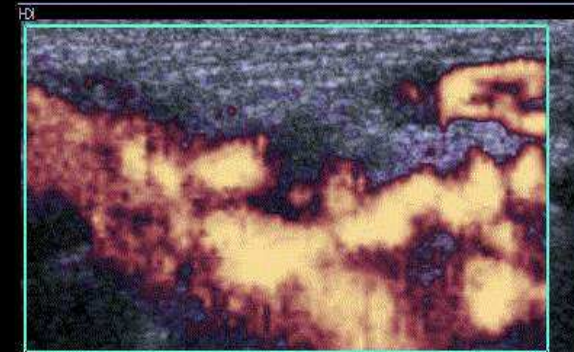
Echelle 6
Dynam 55dB
Persist Moy
CI Moy
Opt 2D:Rés
CPA 82% Echelle 1
FP Moy
PRF 1000 Hz
Opt Flux:V moy



VIDANGE

at rest

Echelle 6
Dynam 55dB
Persist Moy
CI Moy
Opt 2D:Rés
CPA 82% Echelle 1
FP Moy
PRF 1000 Hz
Opt Flux:V moy

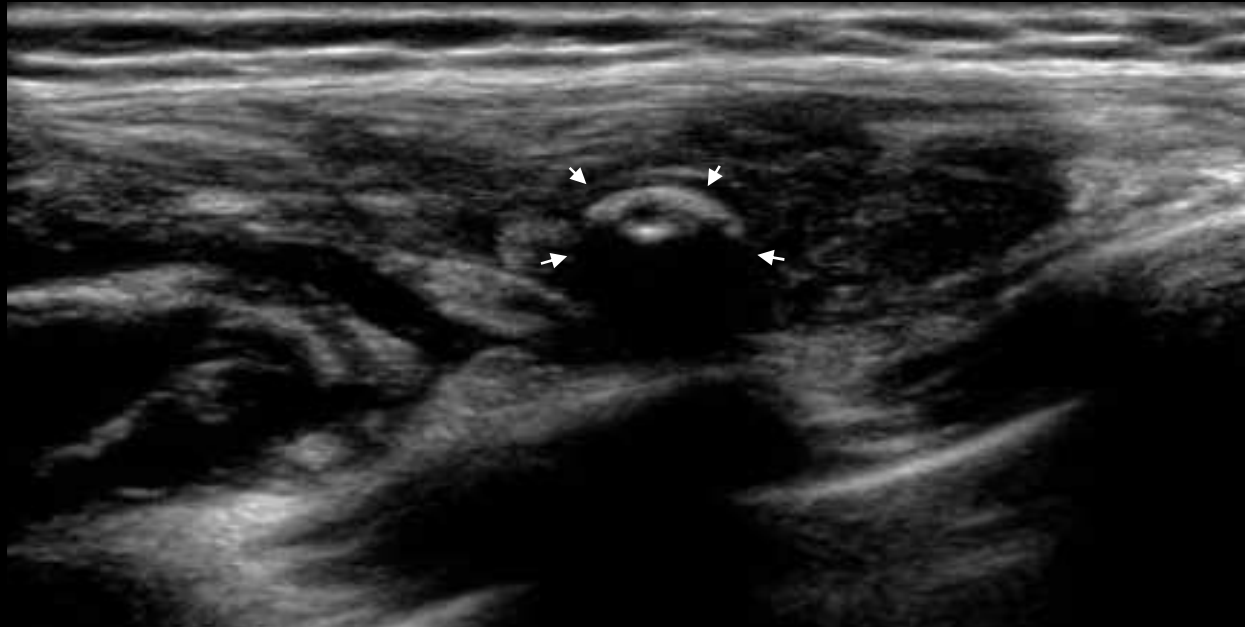

VIDANGE

compression

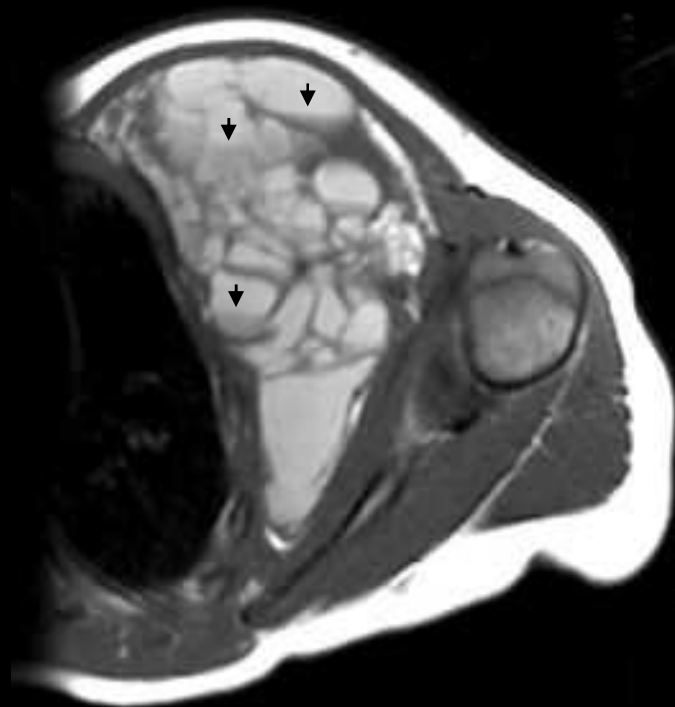
venous malformation

phlebolith



venous malformation

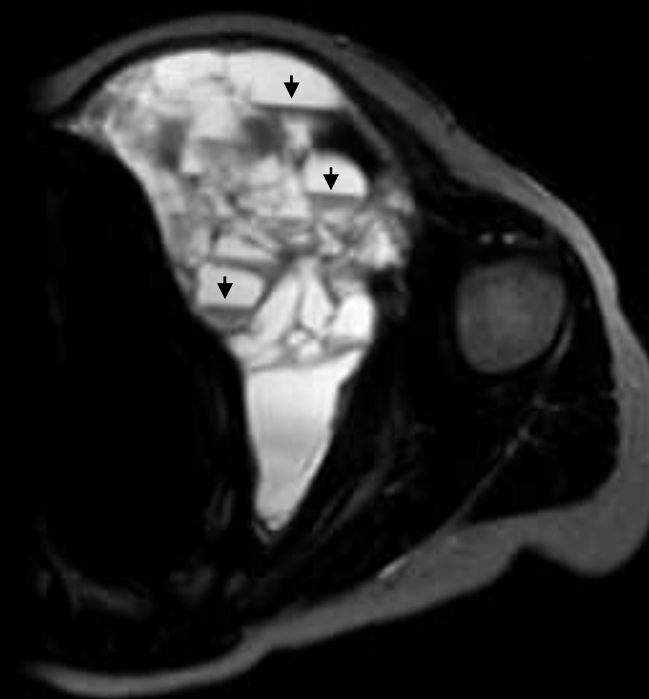
fluid-fluid levels



5 cm

a

T1



5 cm

b

T2

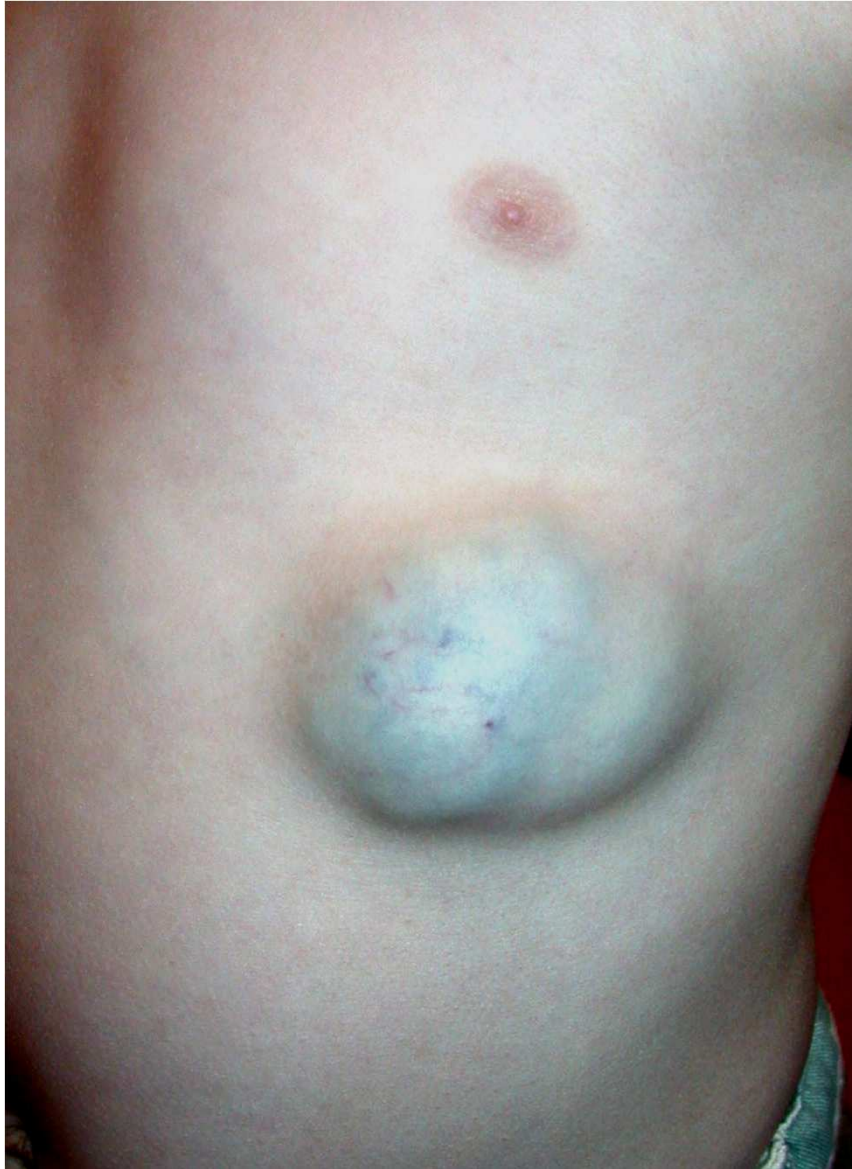lymphatic malformation

in the vast majority : NO



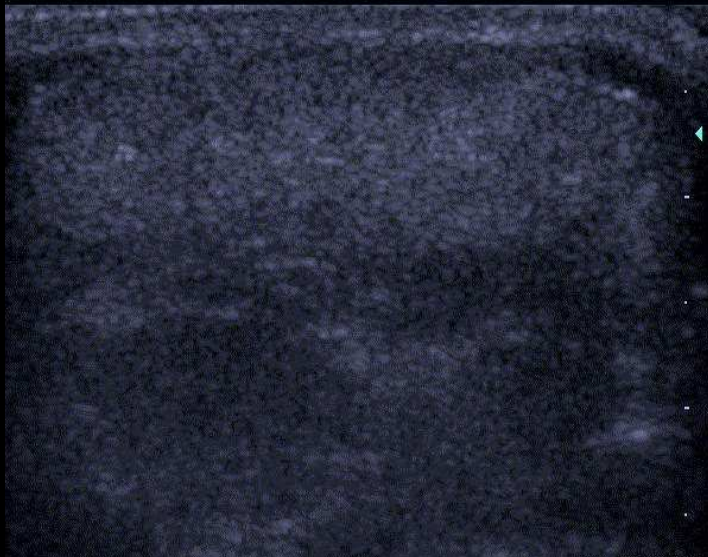
→ CM

doubtful cases : Doppler US

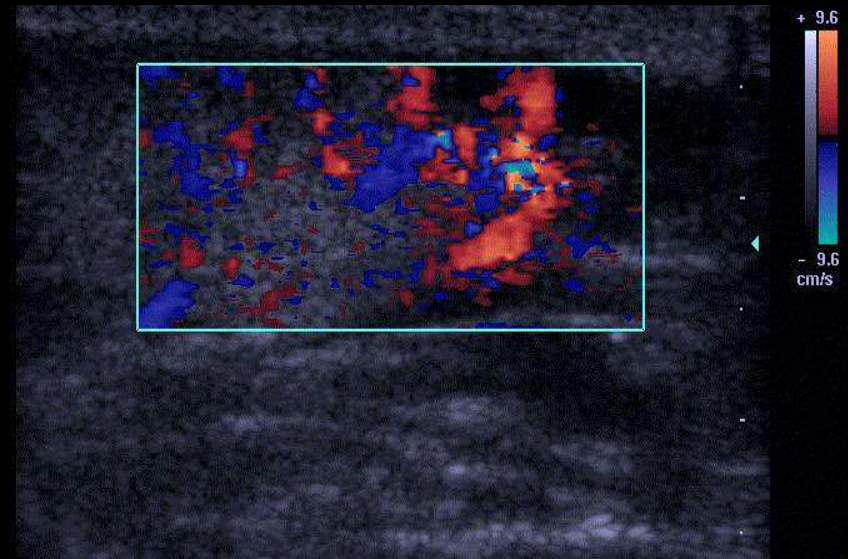


→ hemangioma ?

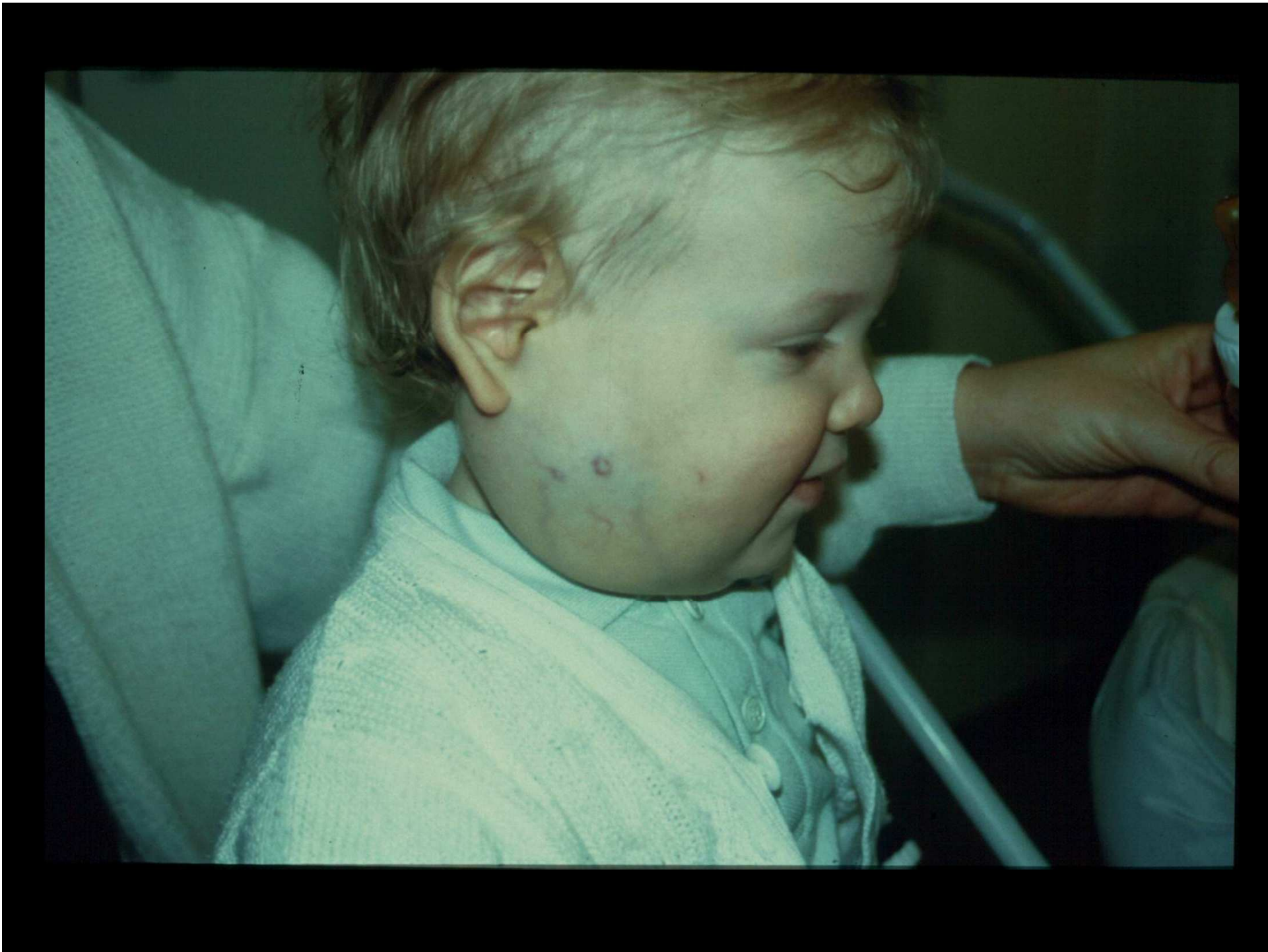hemangioma

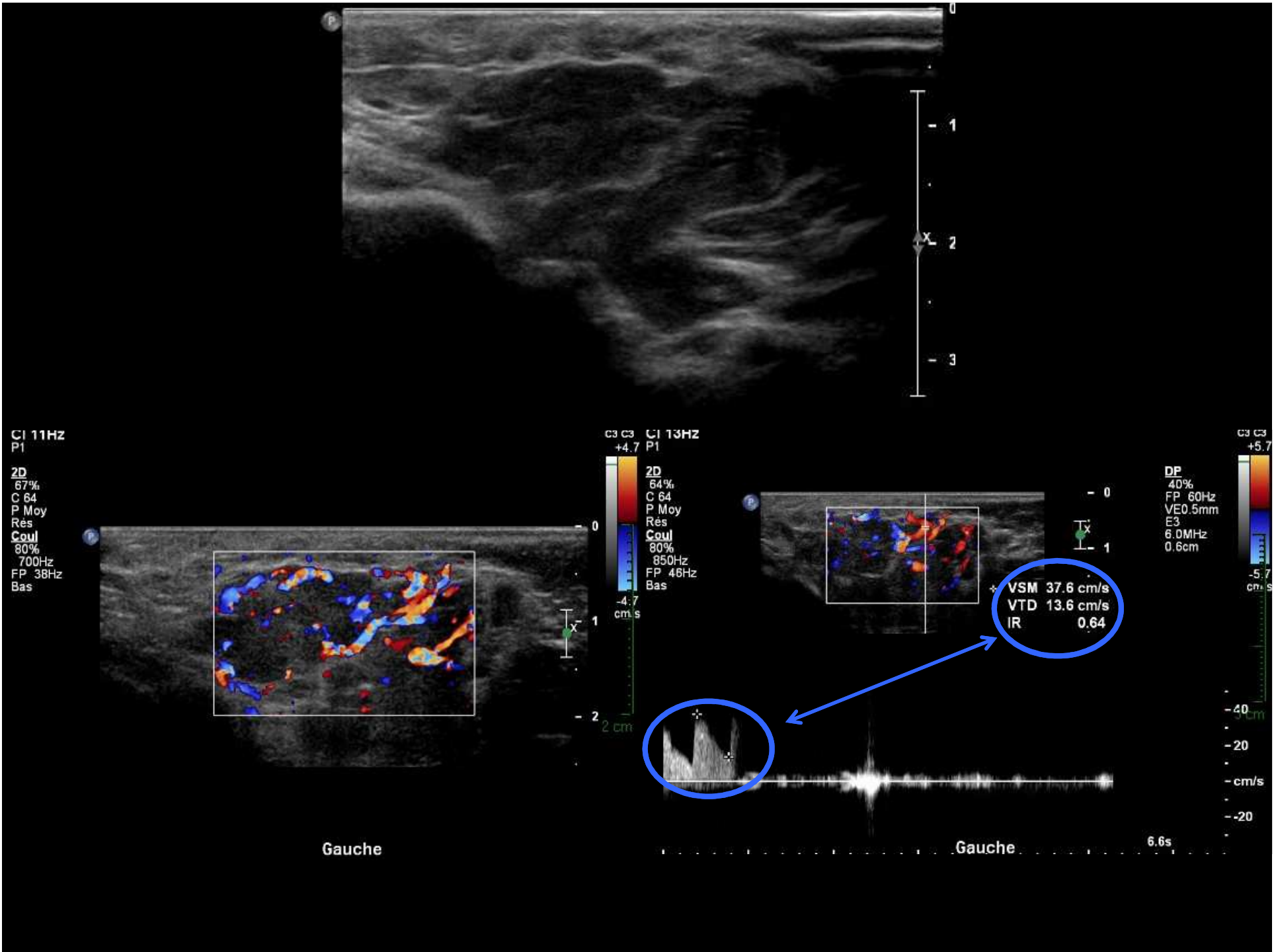


soft tissue mass



vascular network

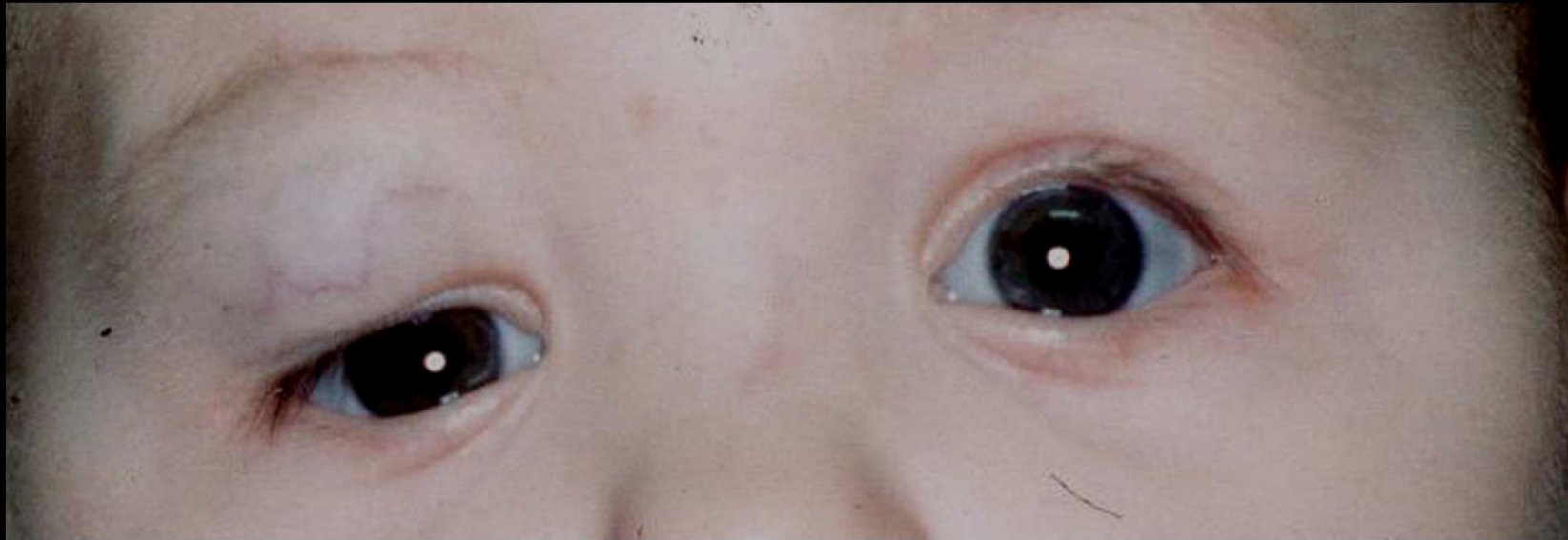



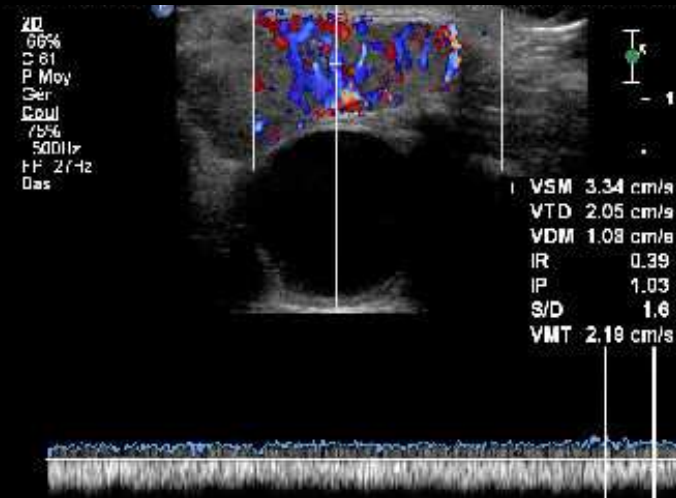
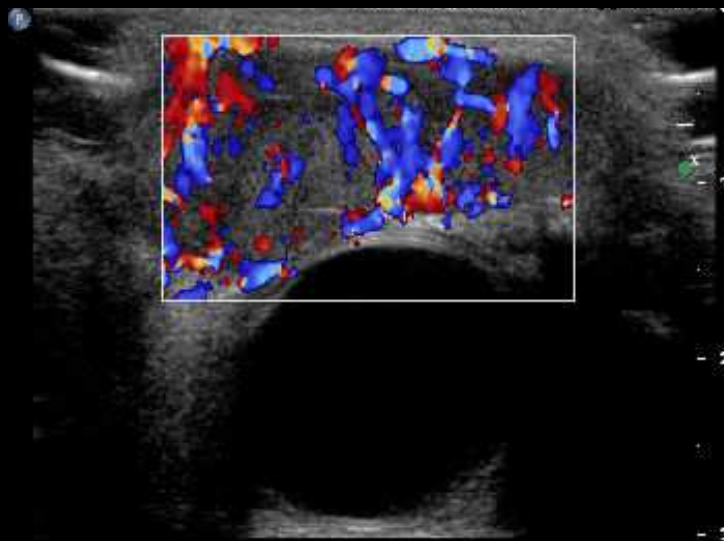
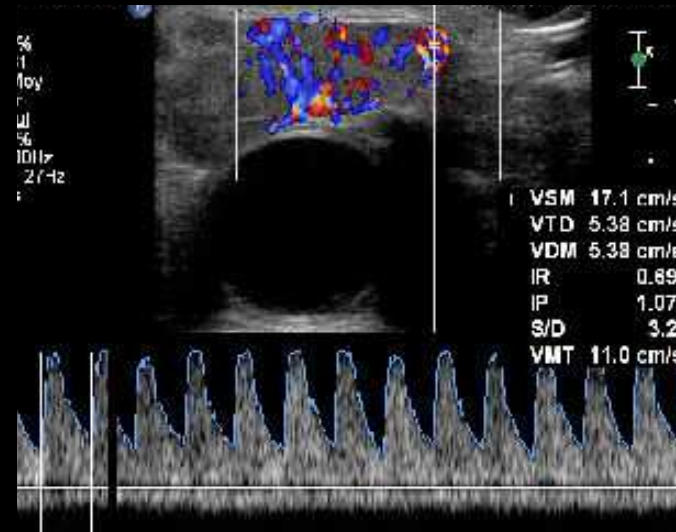
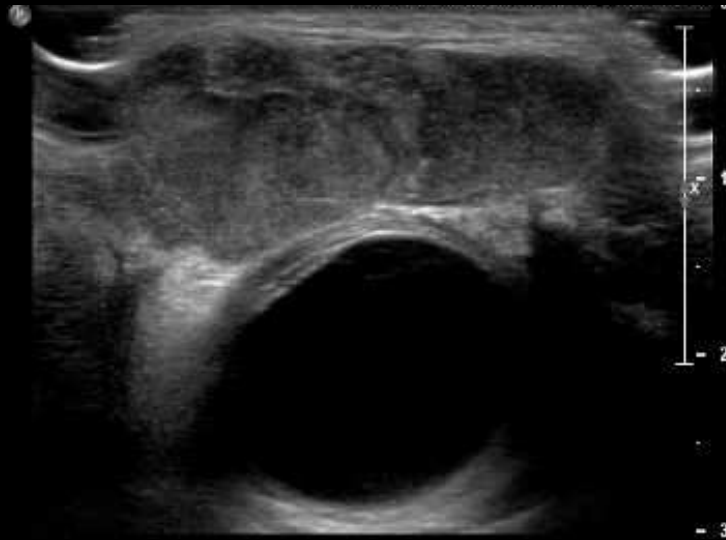
hemangioma

- soft tissue mass
- vascular network ++
 - low RI (often < 0.50)
 - fast flow in veins
- large feeding vessels and draining veins

hemangioma ?



hemangioma

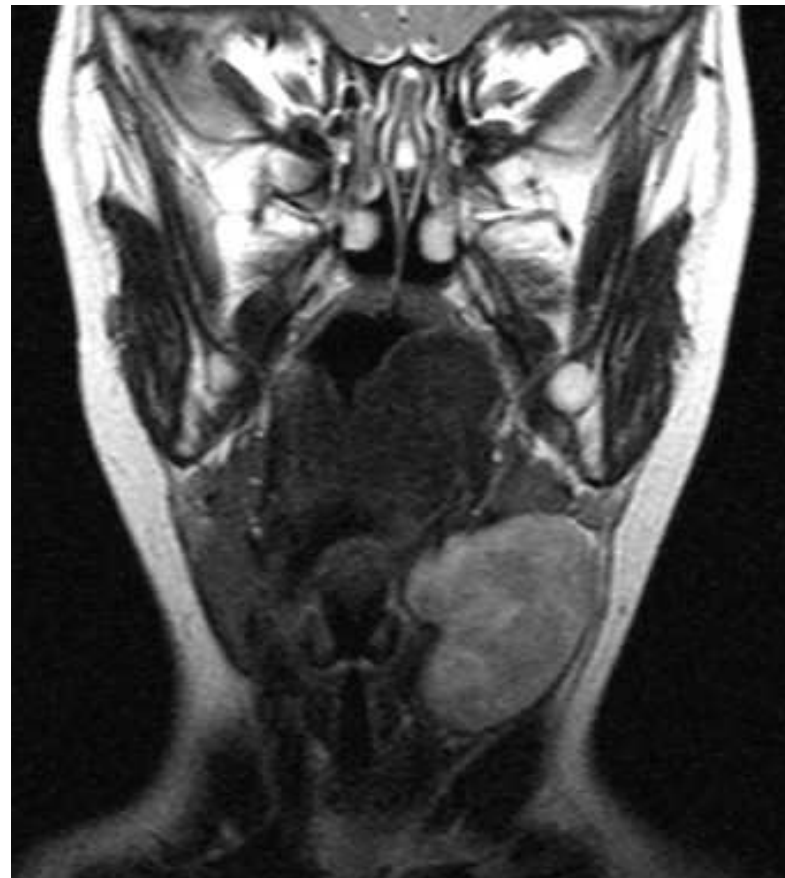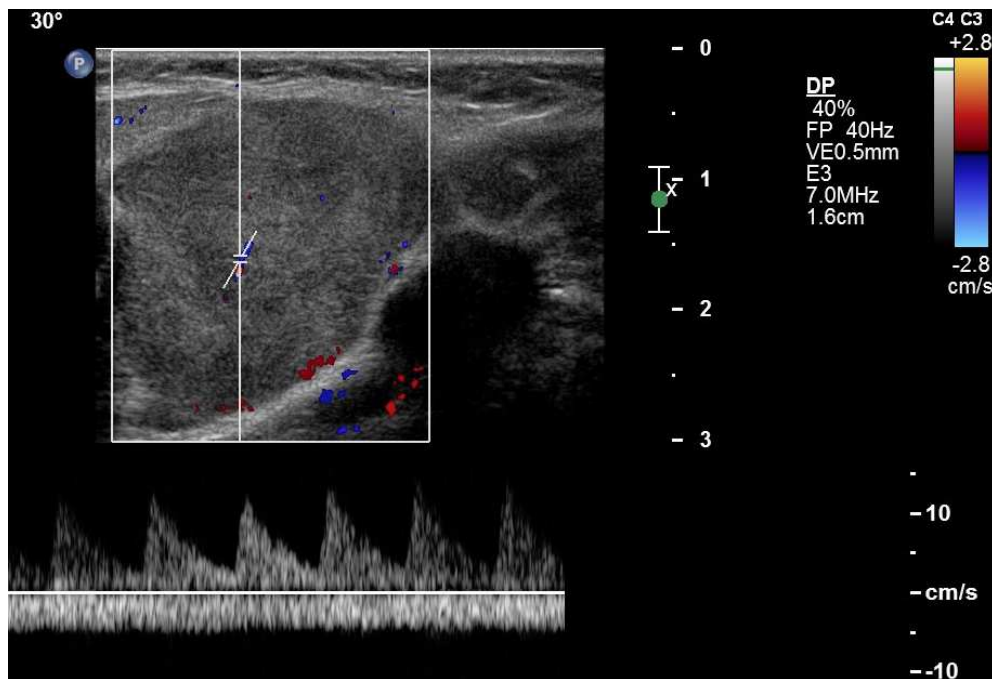


caveats : differential diagnosis

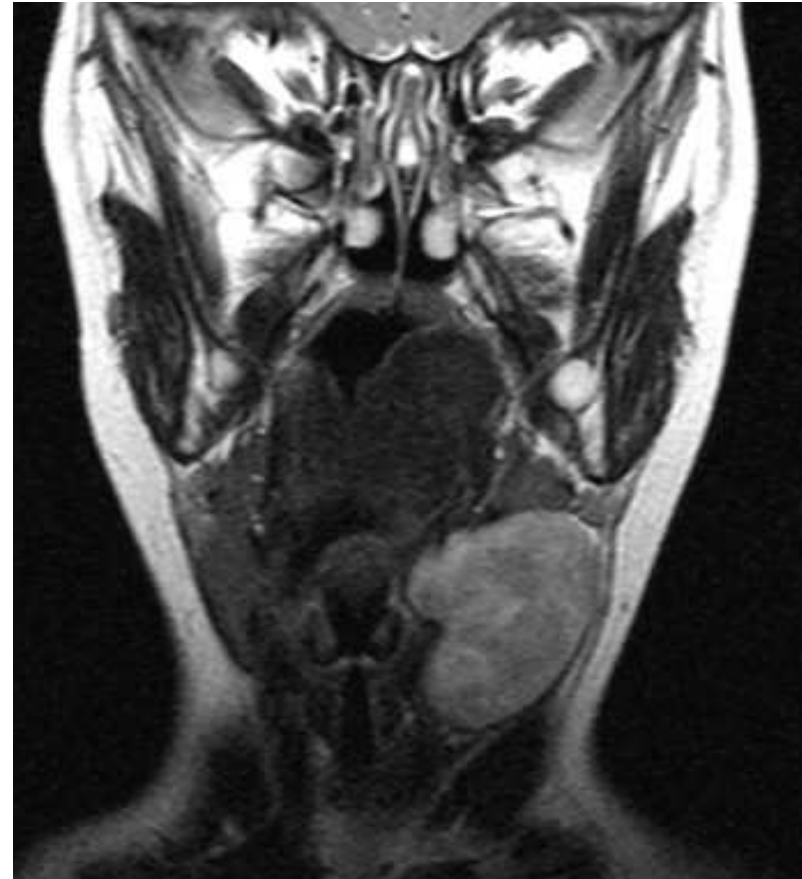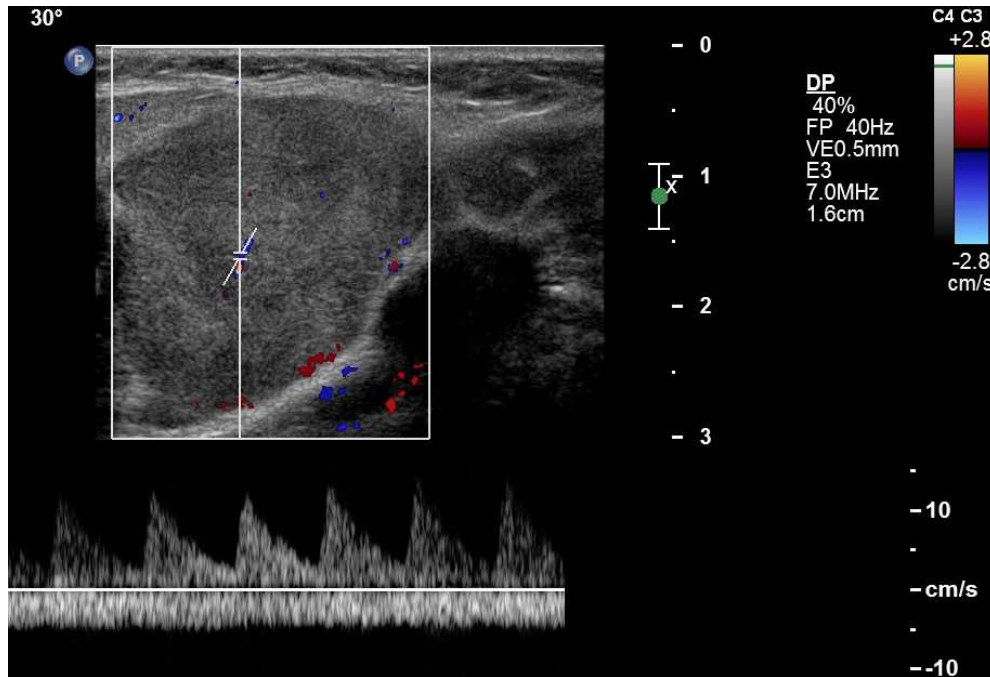
- soft tissue mass or swelling !

mandatory for precise
characterization and/or diagnosis

caveats : differential diagnosis

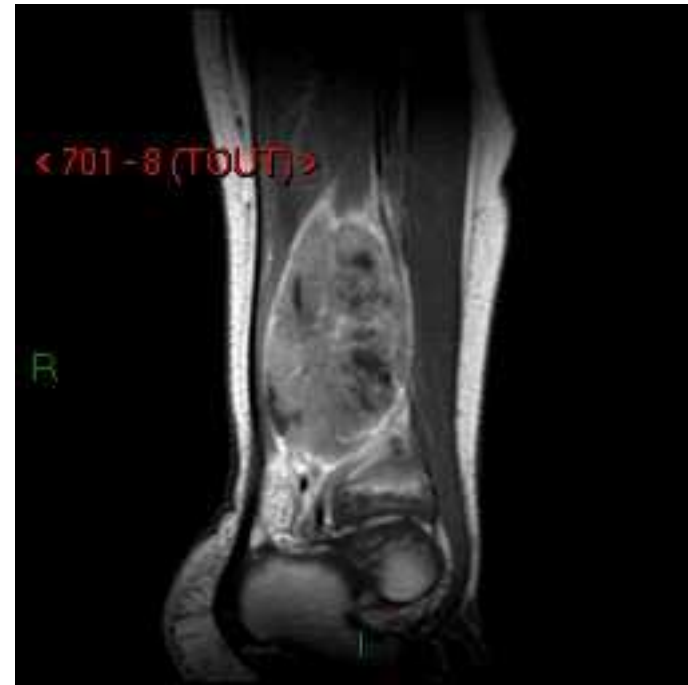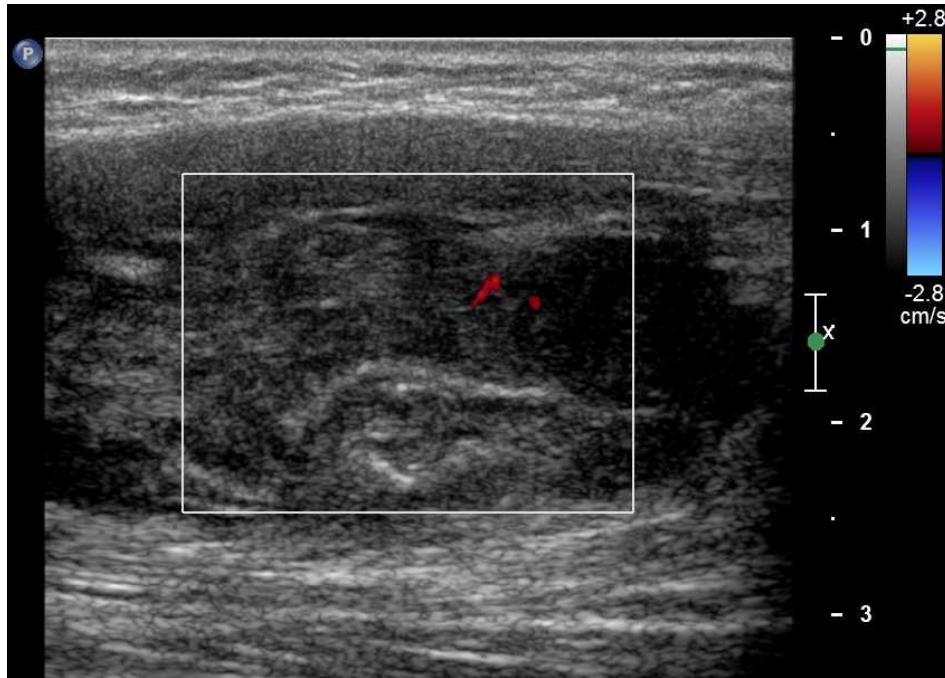


caveats : differential diagnosis



rhabdomyosarcoma

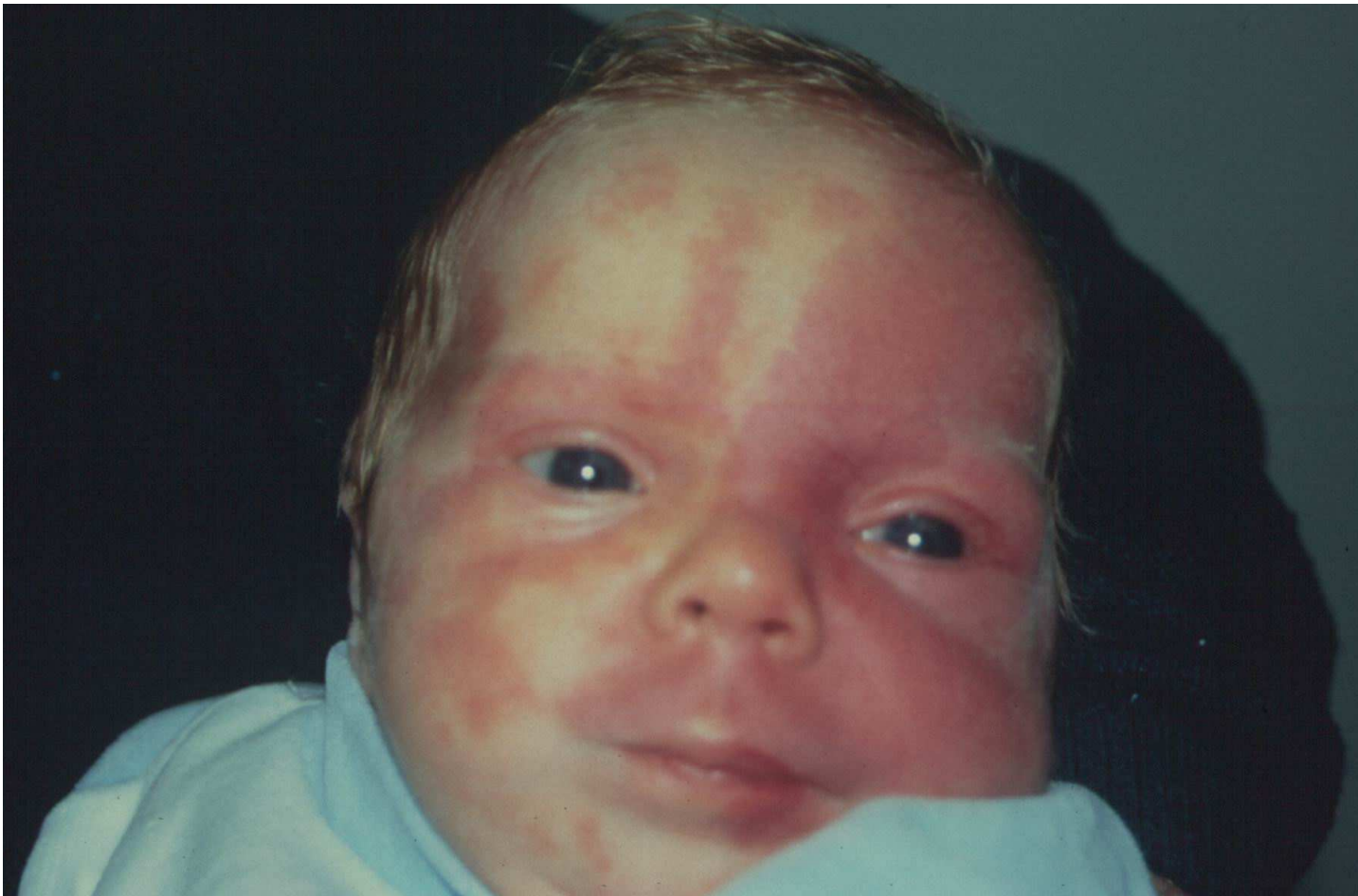caveats : differential diagnosis



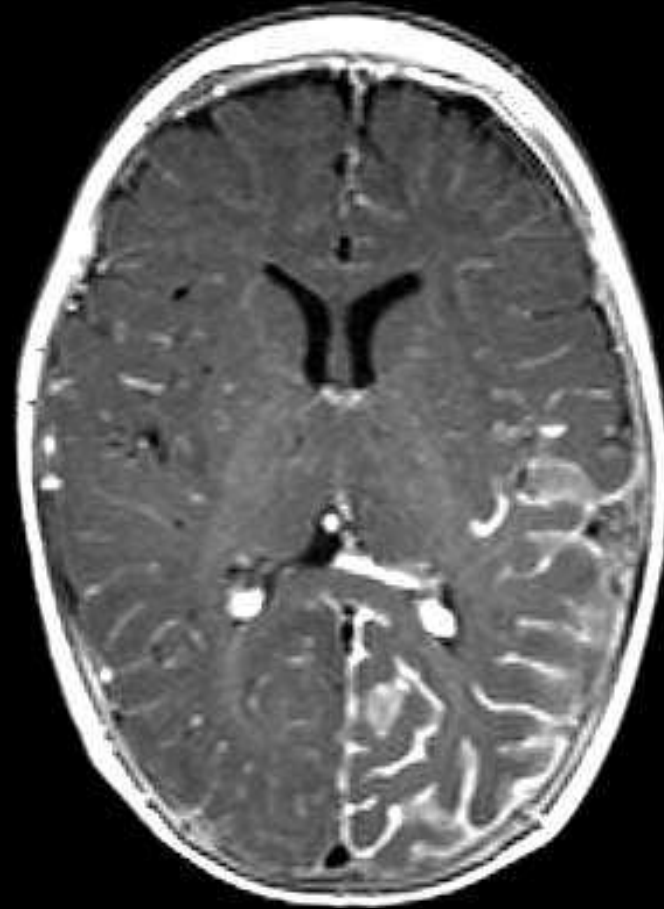
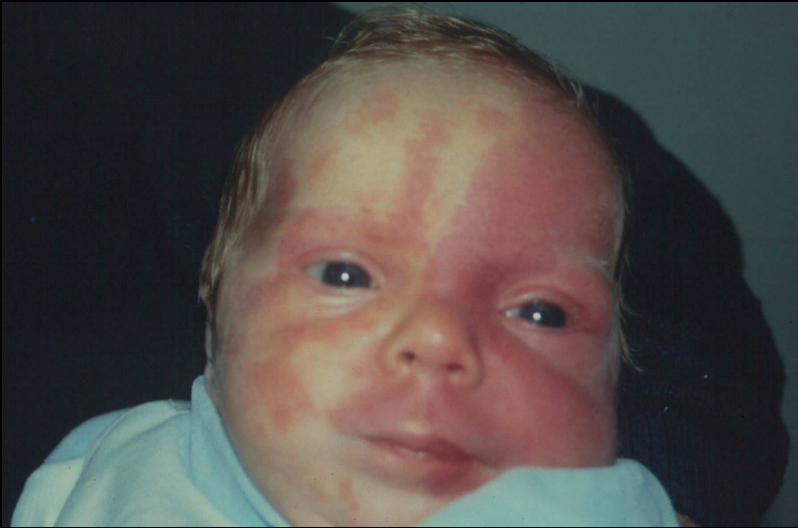are imaging studies helpful for
diagnosis of vascular malformations?

- in the vast majority : NO
- in particular cases : NO but additional information for follow-up and treatment

in particular cases : NO but
additional information for
follow-up and treatment

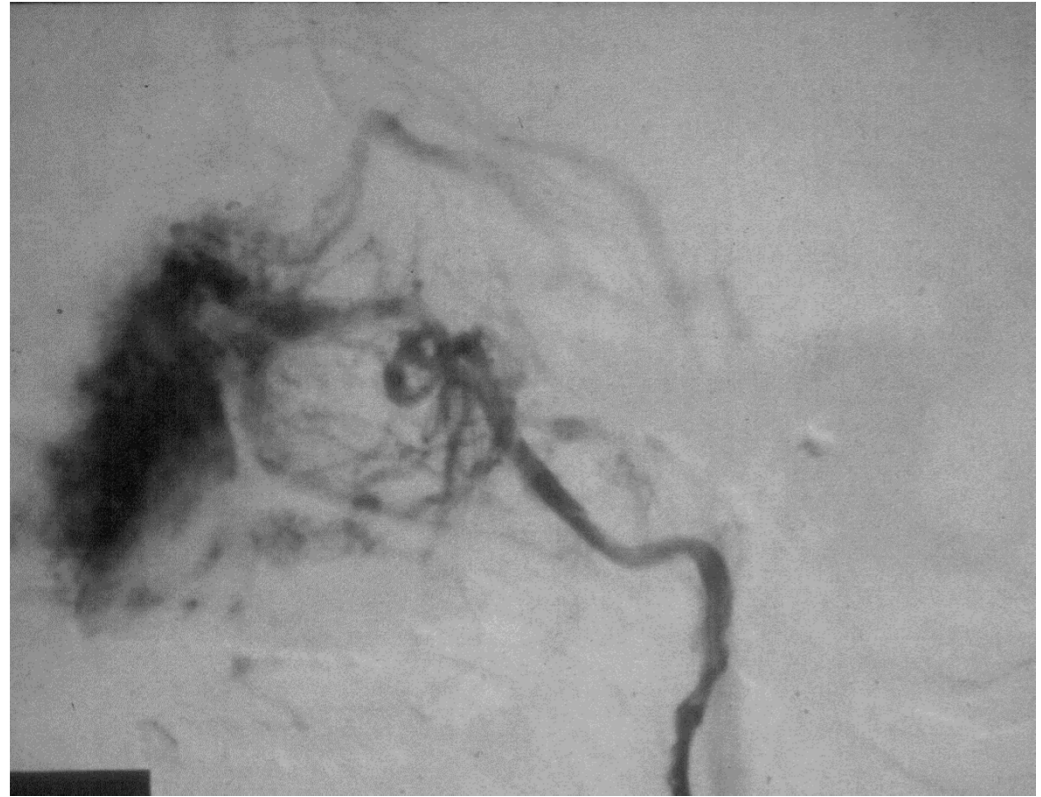
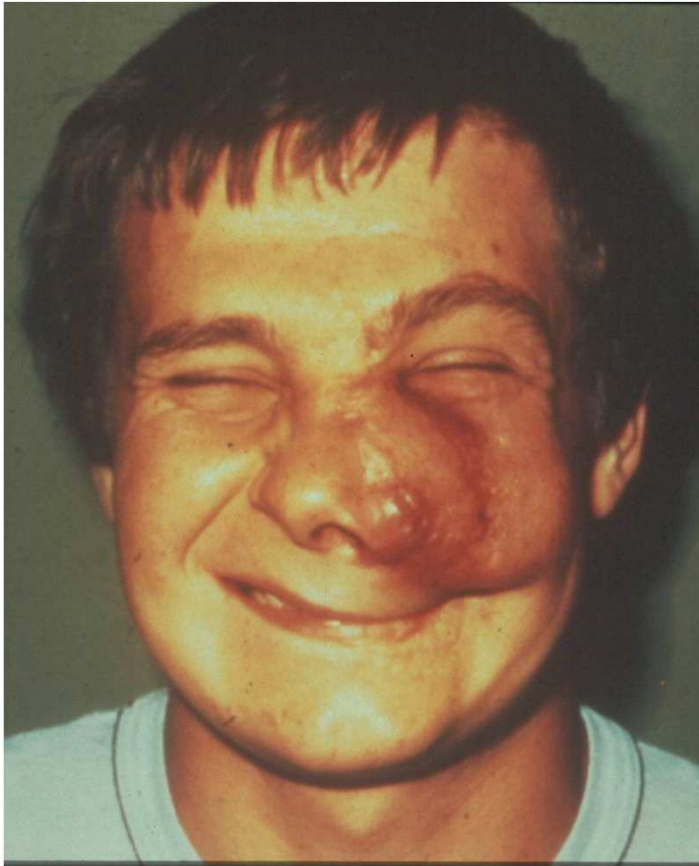

Sturge - Weber syndrome



T1 + injection

in particular cases : NO but
additional information for
follow-up and treatment



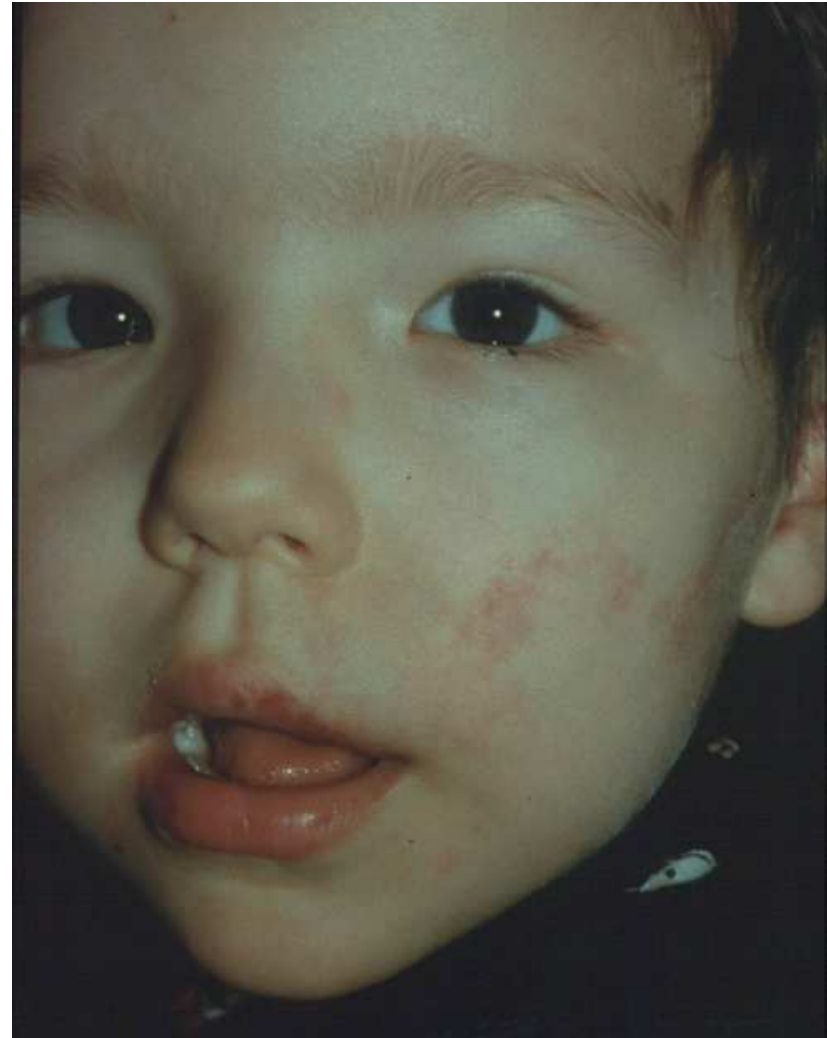are imaging studies helpful for
diagnosis of vascular malformations?

- in the vast majority : NO
- in particular cases : NO but additional information for follow-up and treatment
- in some cases : mandatory for precise characterization and/or diagnosis

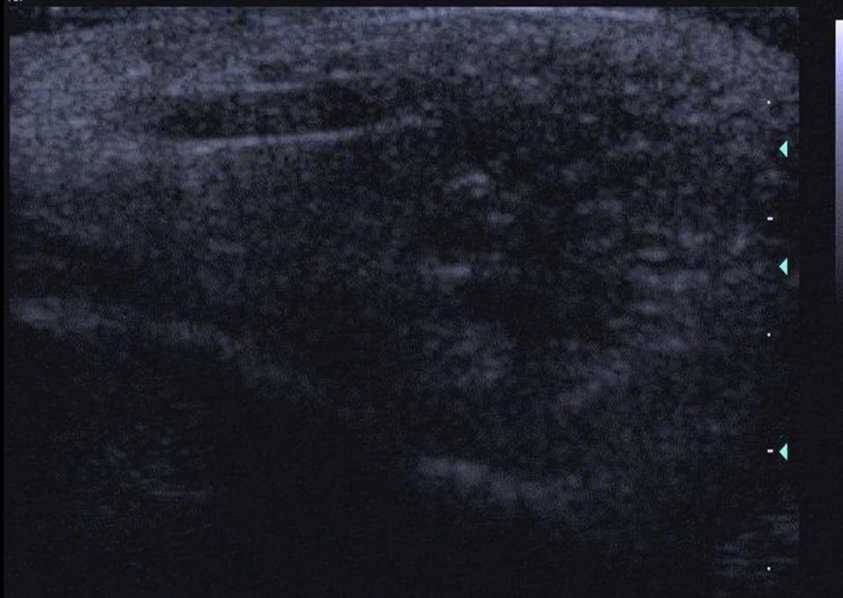
in some cases :

mandatory for precise
characterization and/or diagnosis

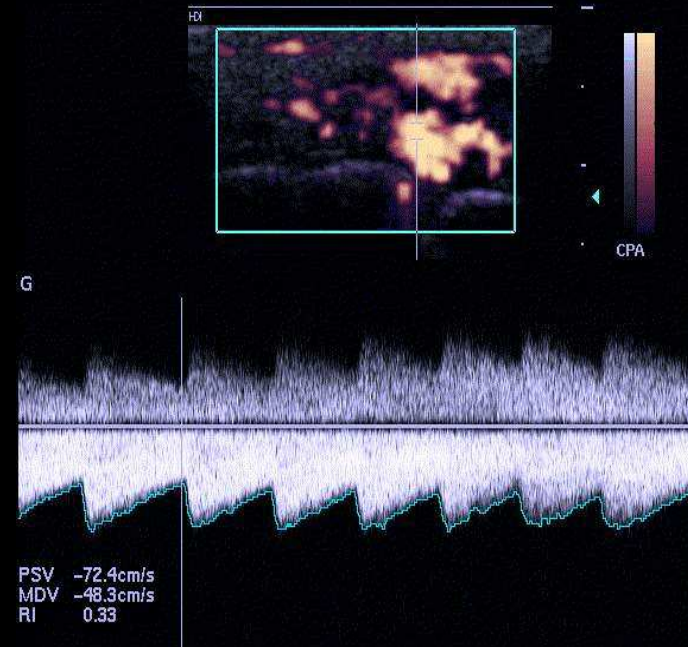
CM ? →



CM ?

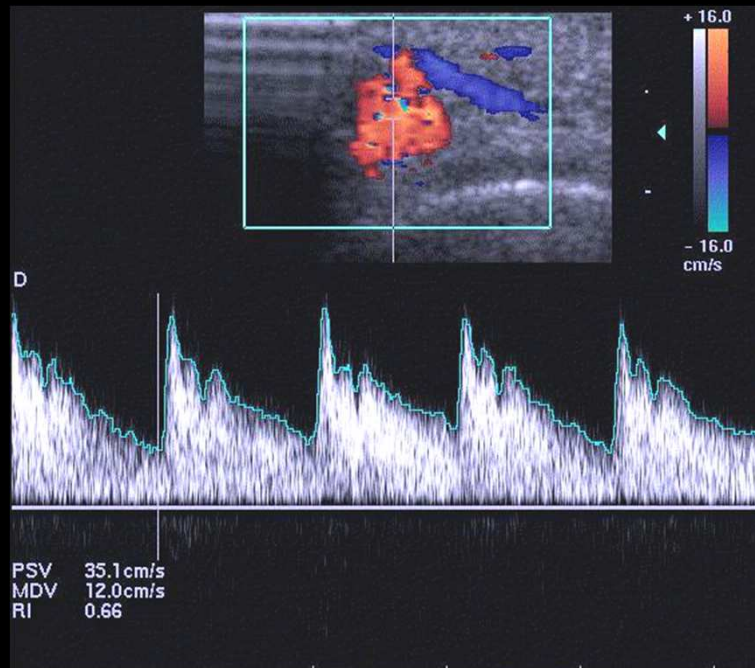


no mass !

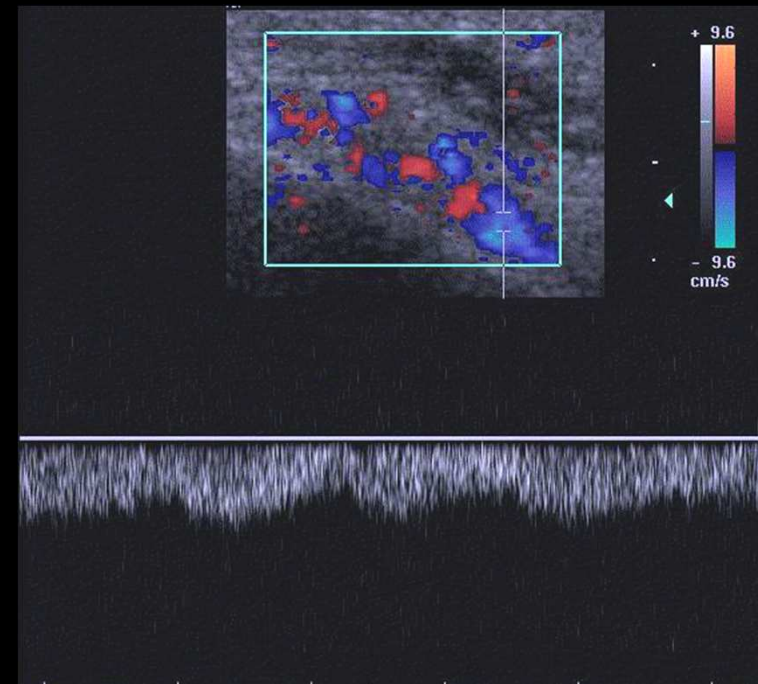


nidus

arterio-venous malformation

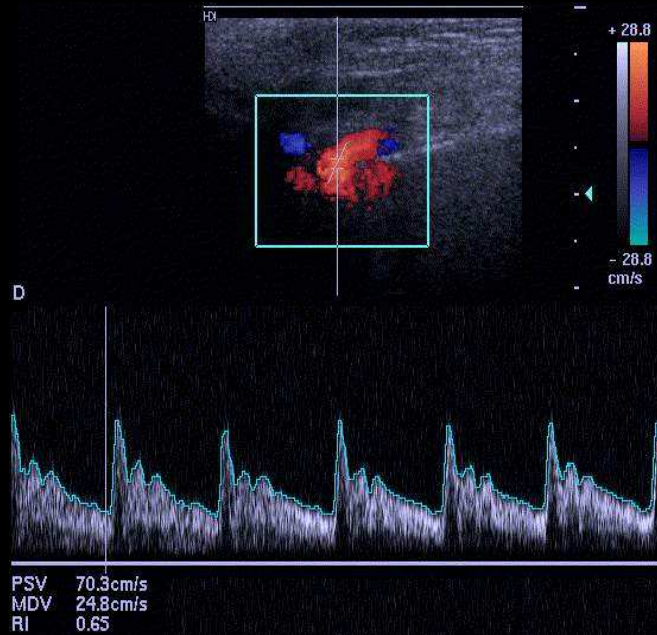


feeding artery
fast flow
low resistance ↘ RI

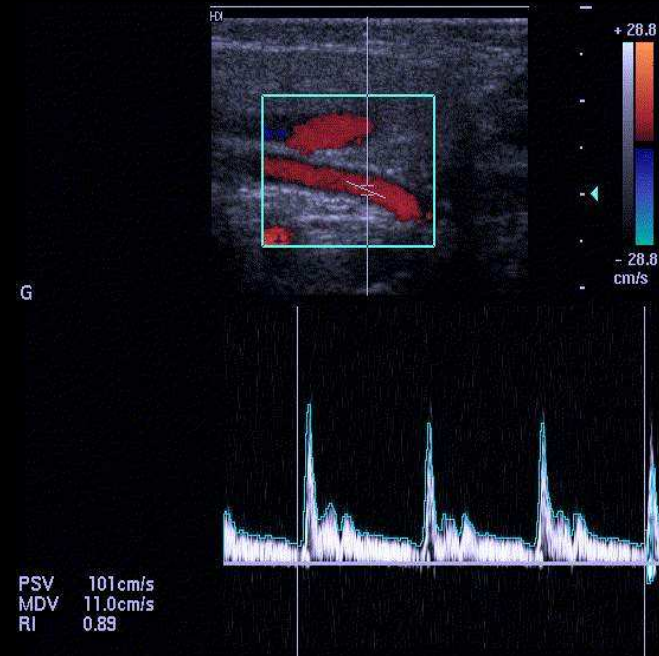


pulsatility in vein

arterio-venous malformation



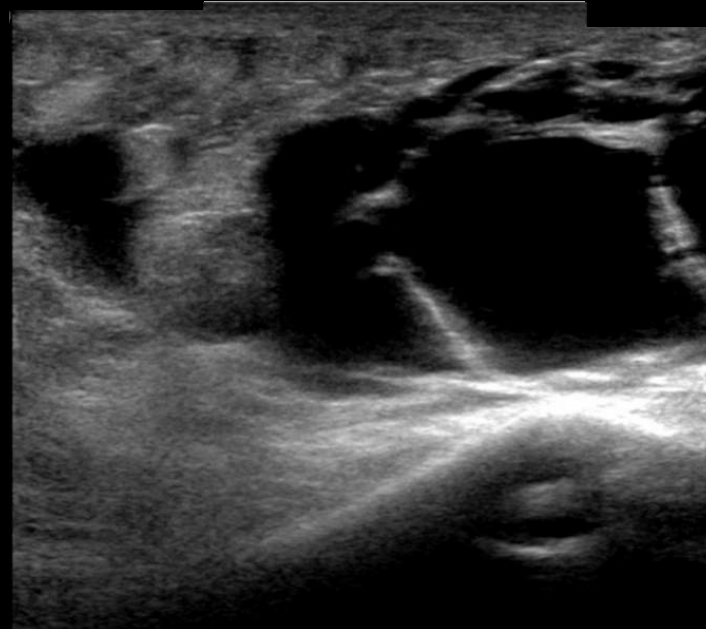
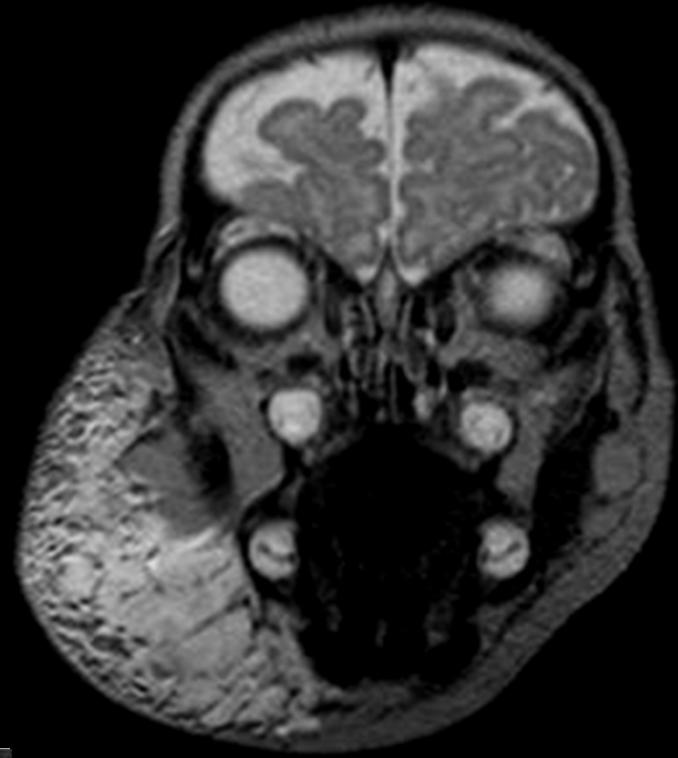
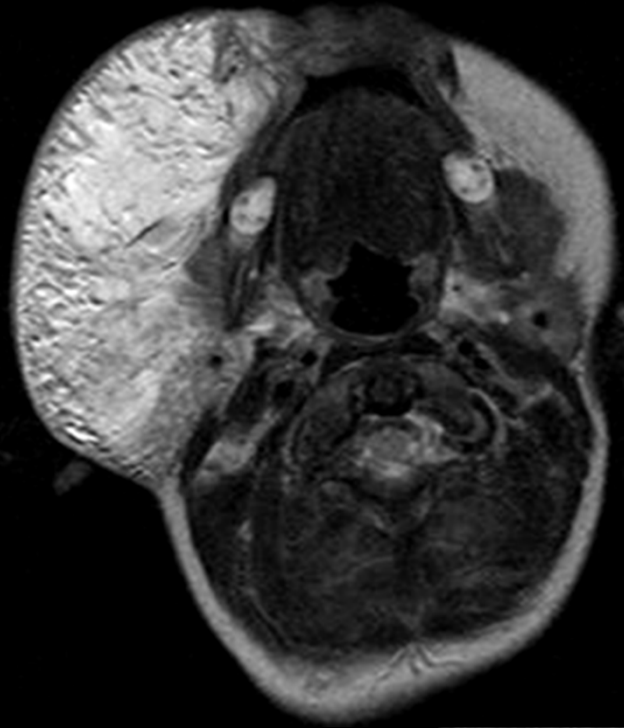
feeding artery
affected side



feeding artery
normal side

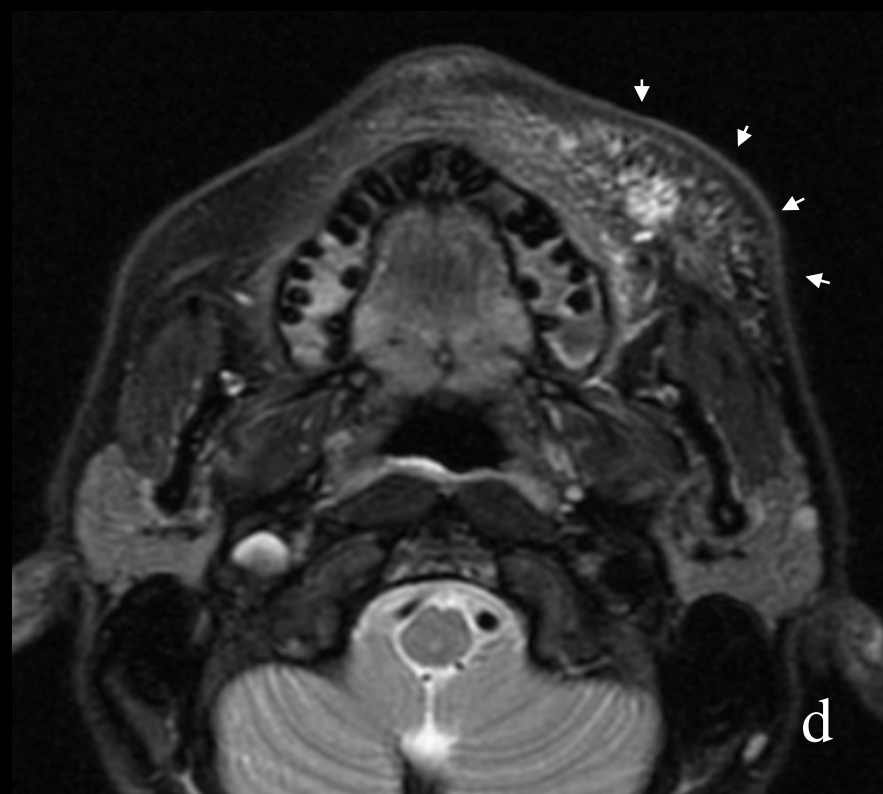
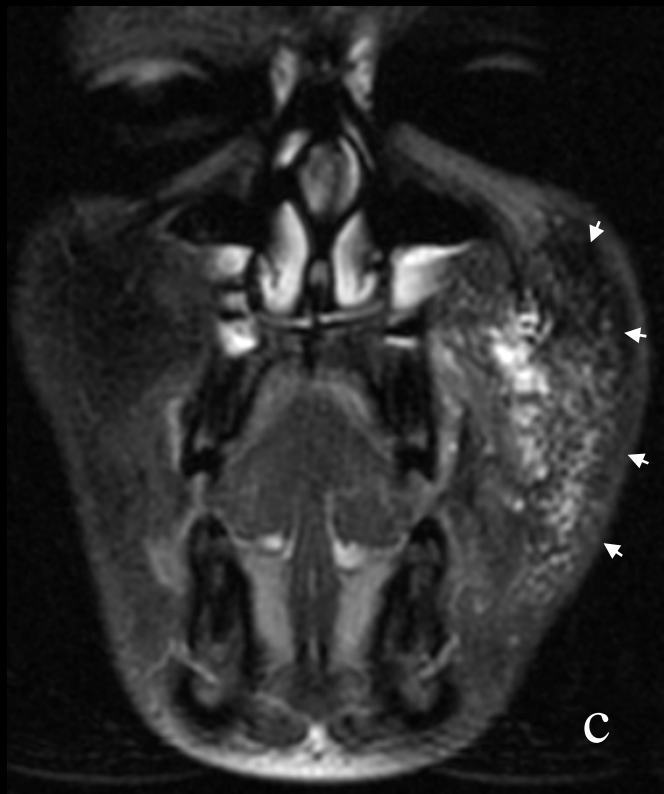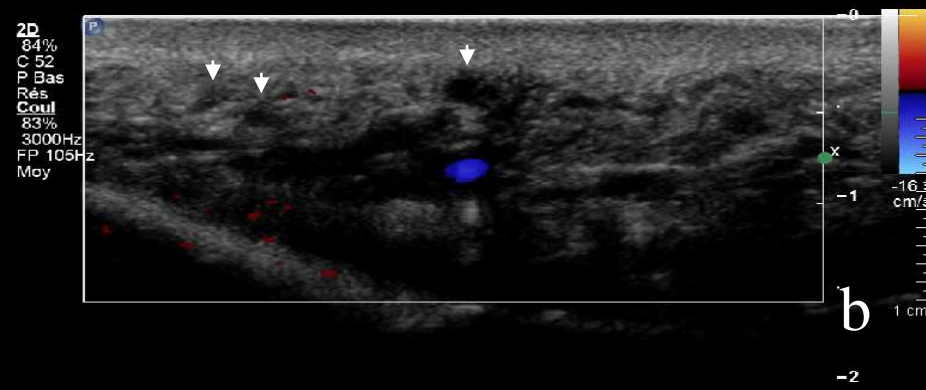
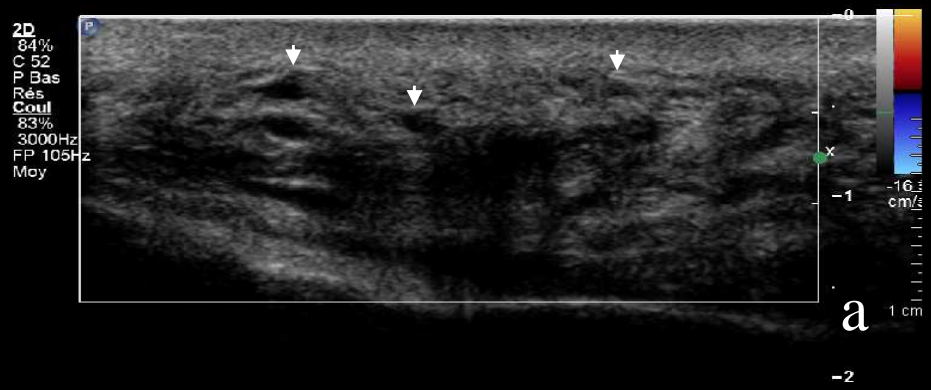
pre-therapeutic work-up

- sclerotherapy
 - LM
 - VM
- embolisation
- surgery



- 1
x
- 2
- 3

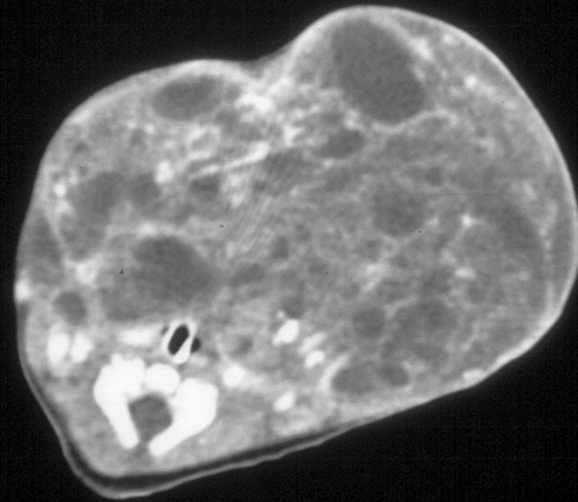
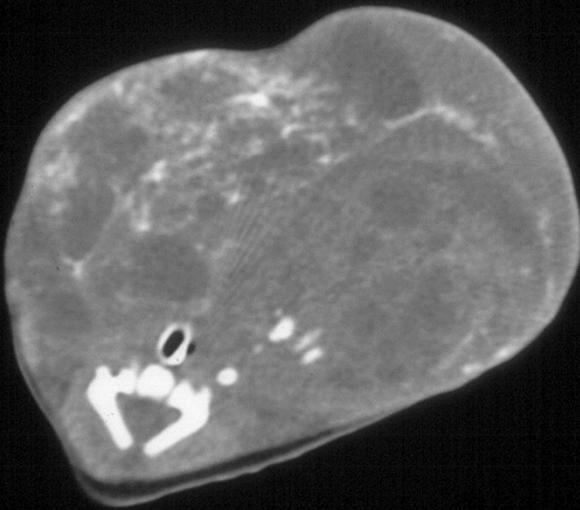
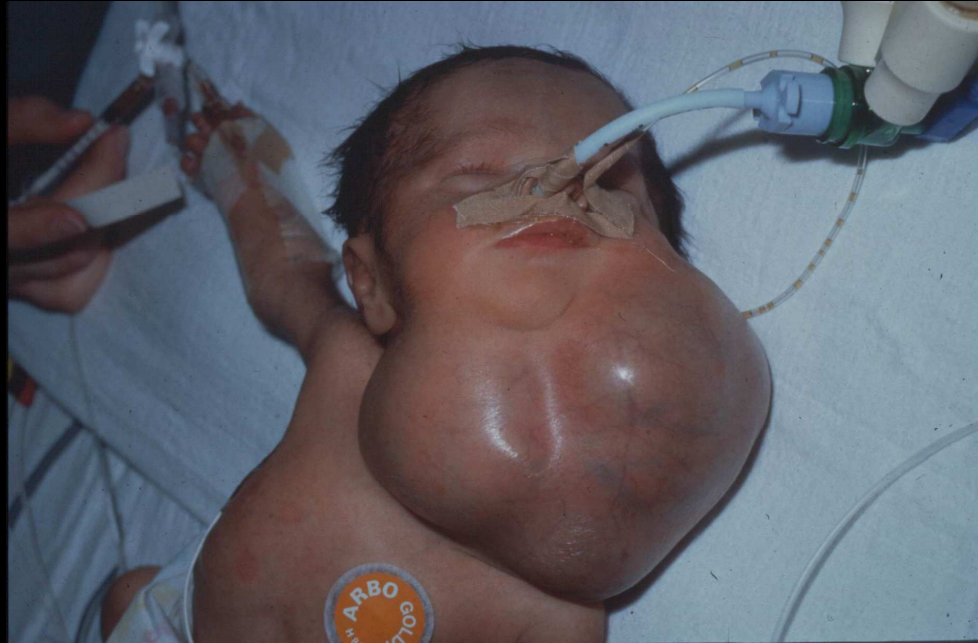LM
macrocysts



LM
microcysts

pre-therapeutic work-up

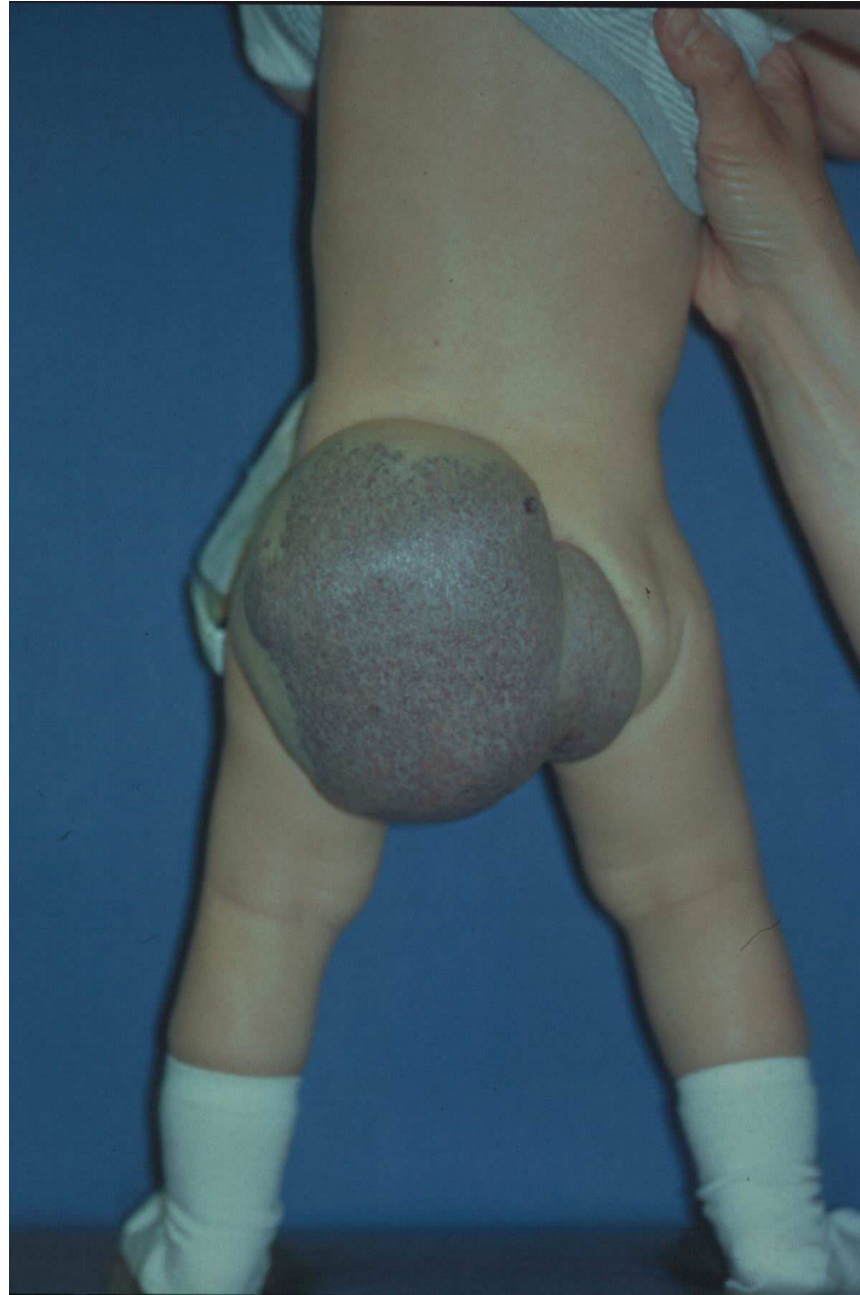- sclerotherapy
- embolisation
- surgery : anatomical landmarks



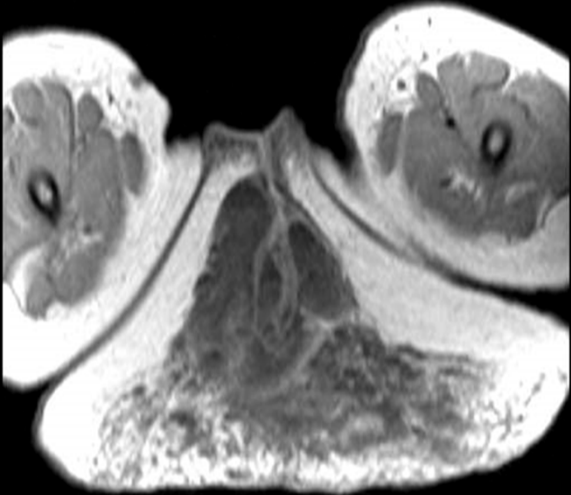
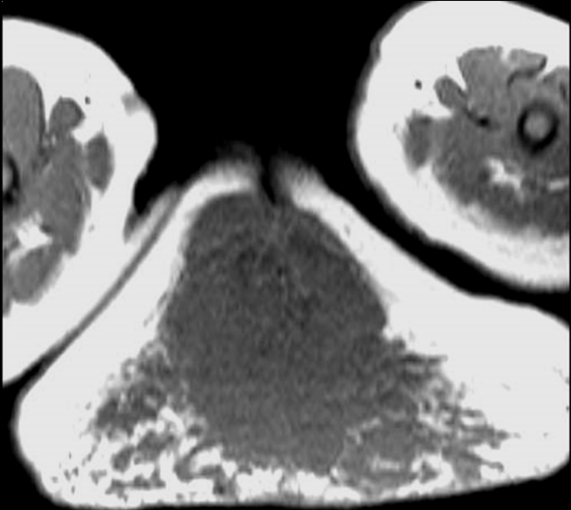
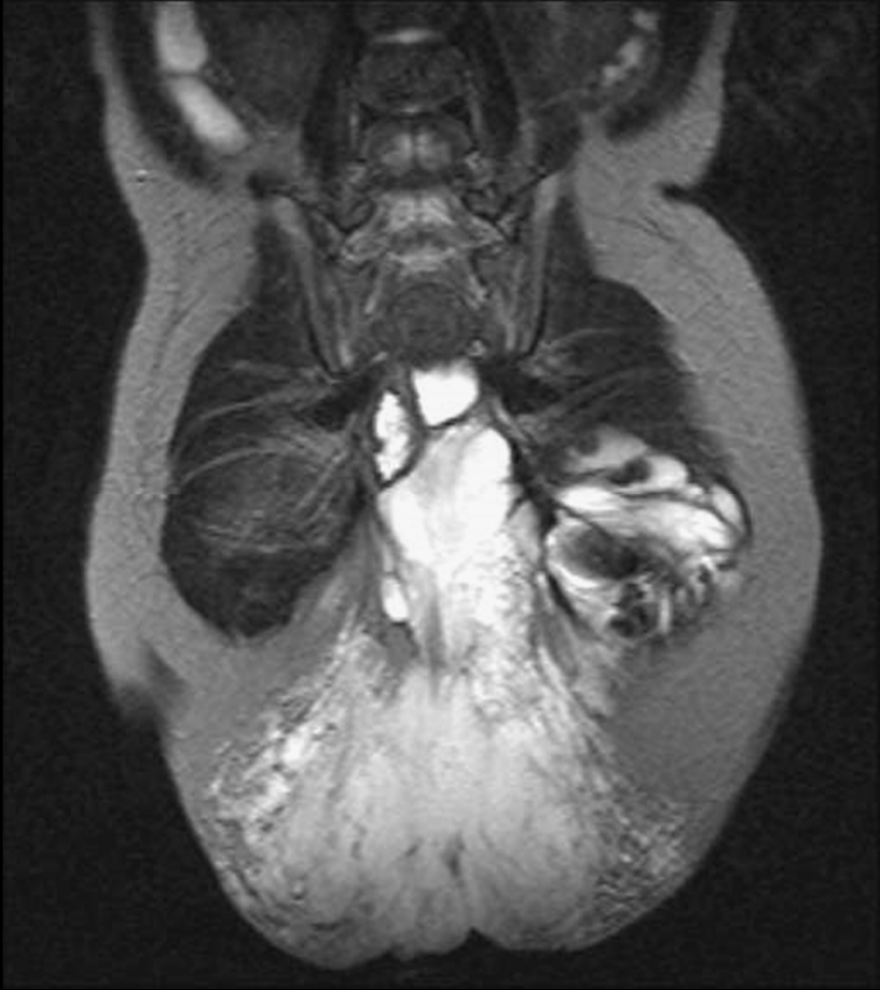LM

imaging tools

- ultrasound + Doppler
 - screening – first modality
 - morphology
 - flow – hemodynamic pattern
- MRI (or CT)
 - cross-sectional anatomy → depth extension
- arteriography
 - (pre-)therapeutic approach

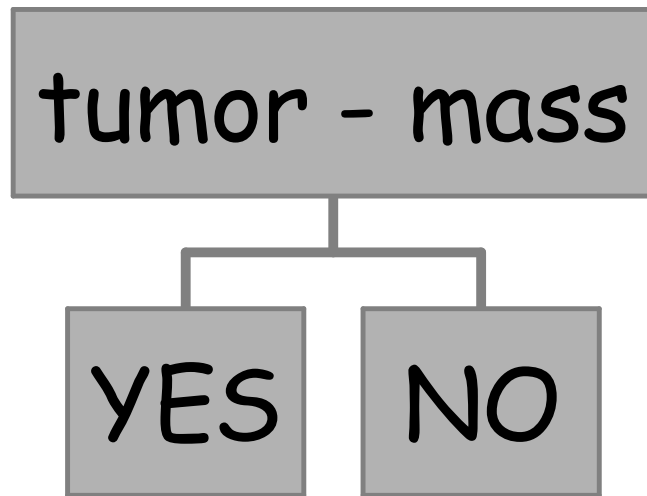


venous malformation

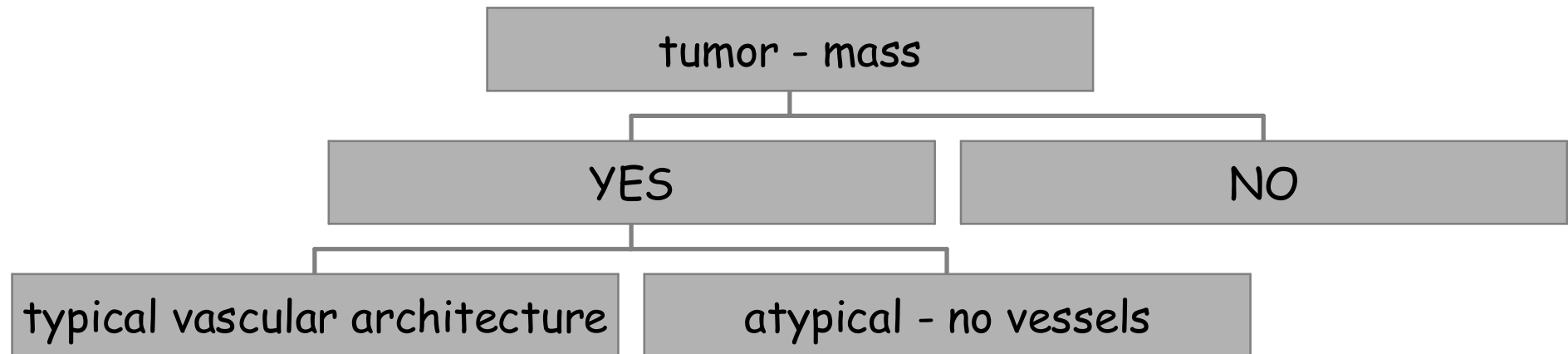


T1 pre
T1 post

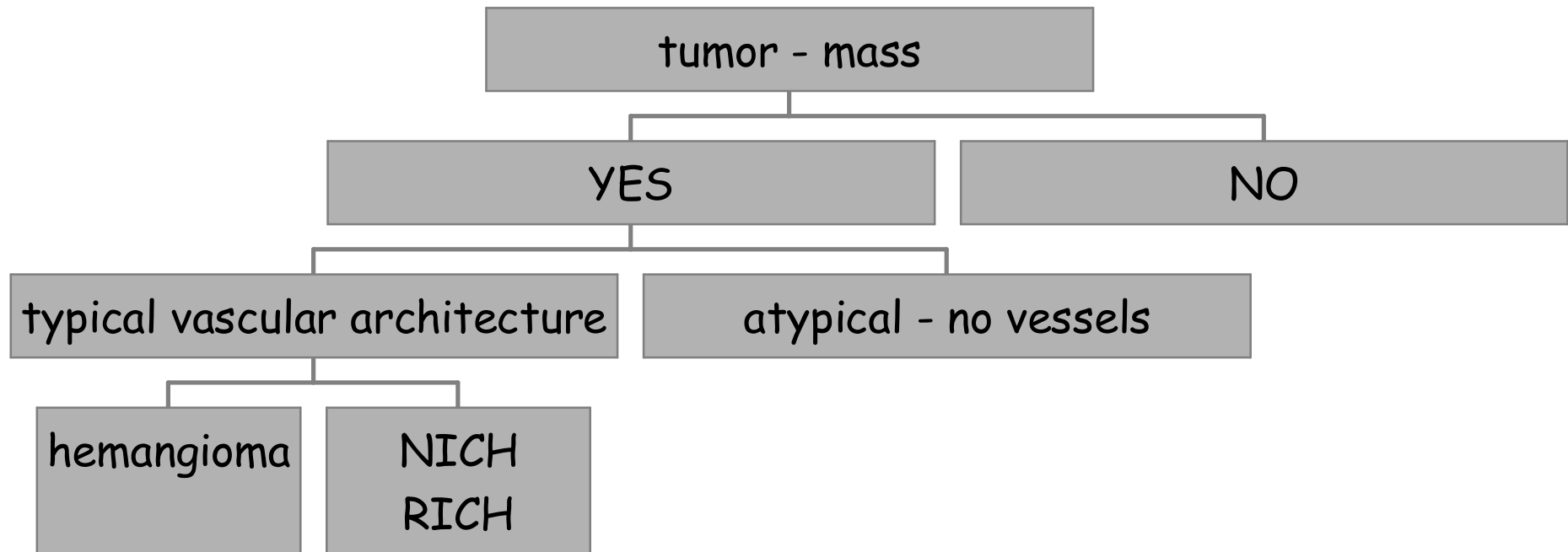
vascular birthmarks



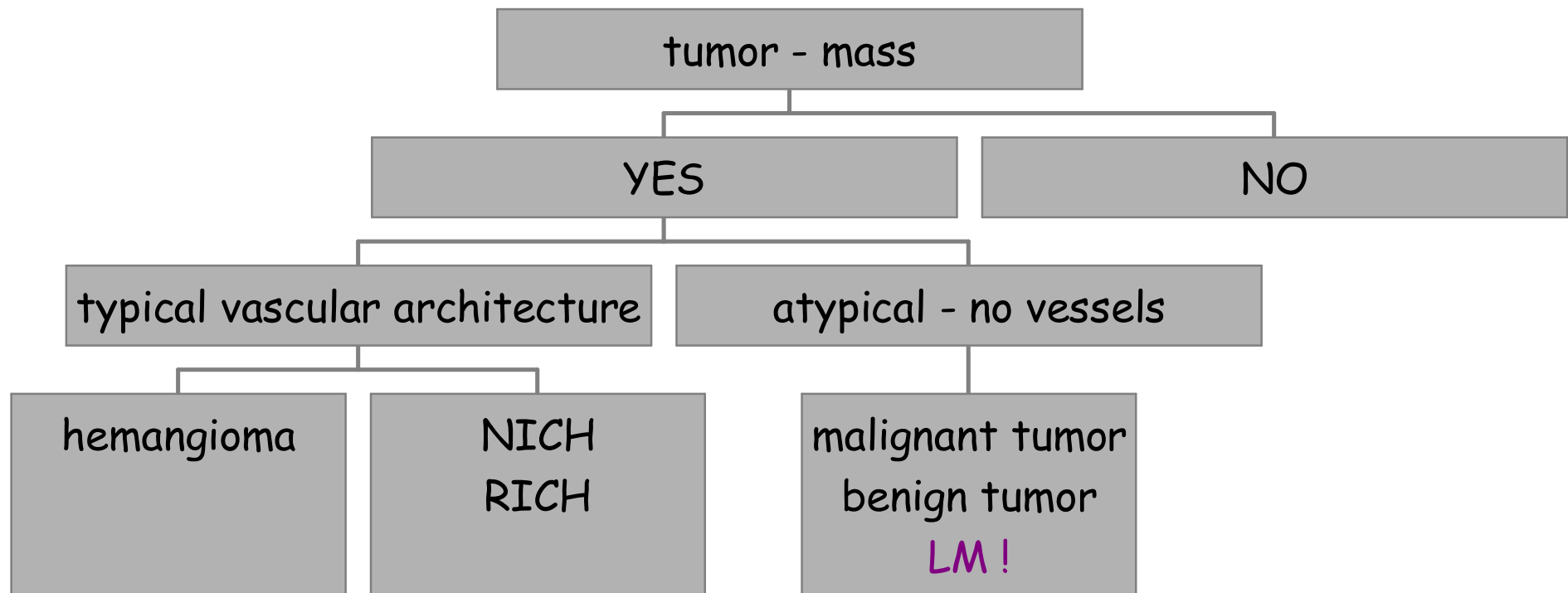
vascular birthmarks



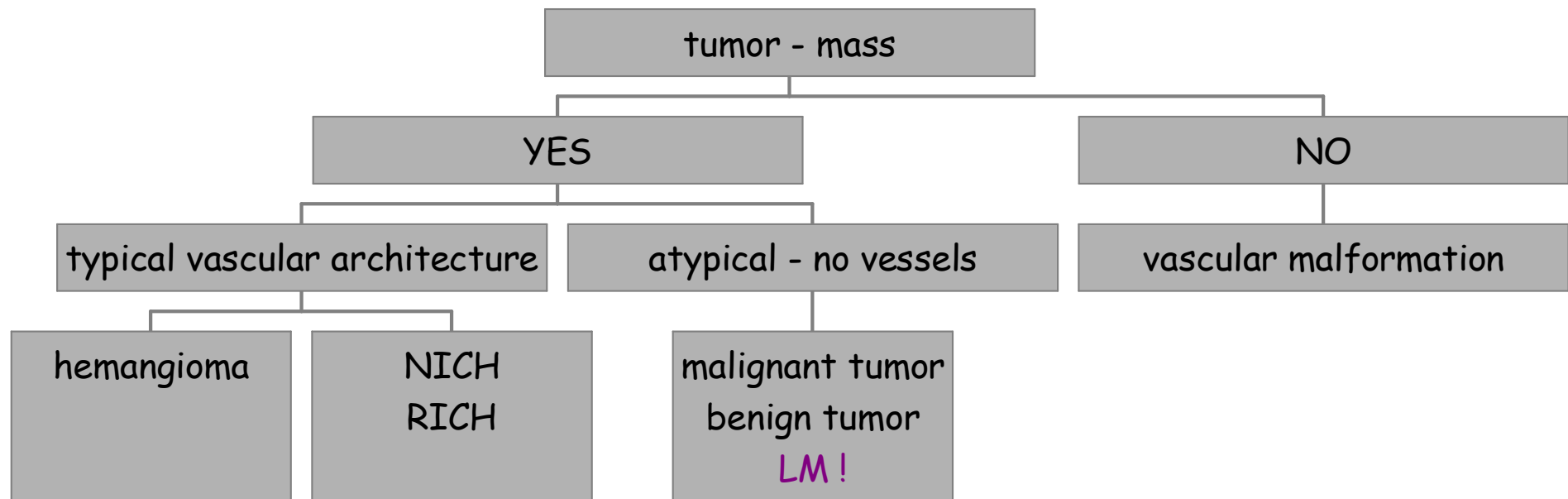
vascular birthmarks



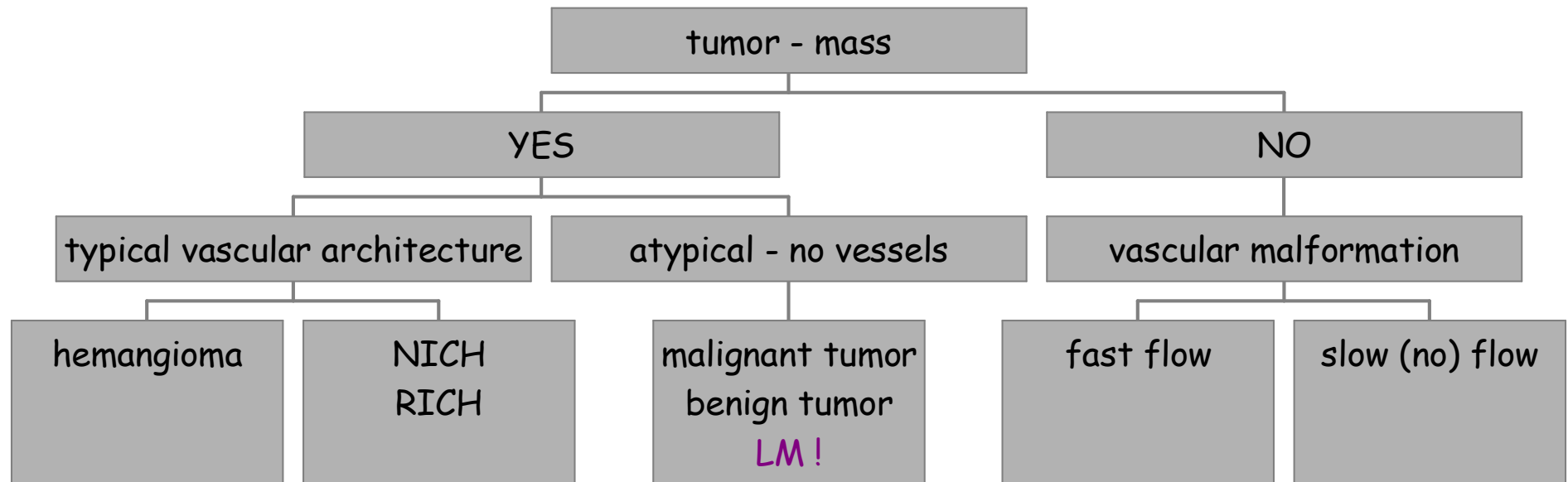
vascular birthmarks



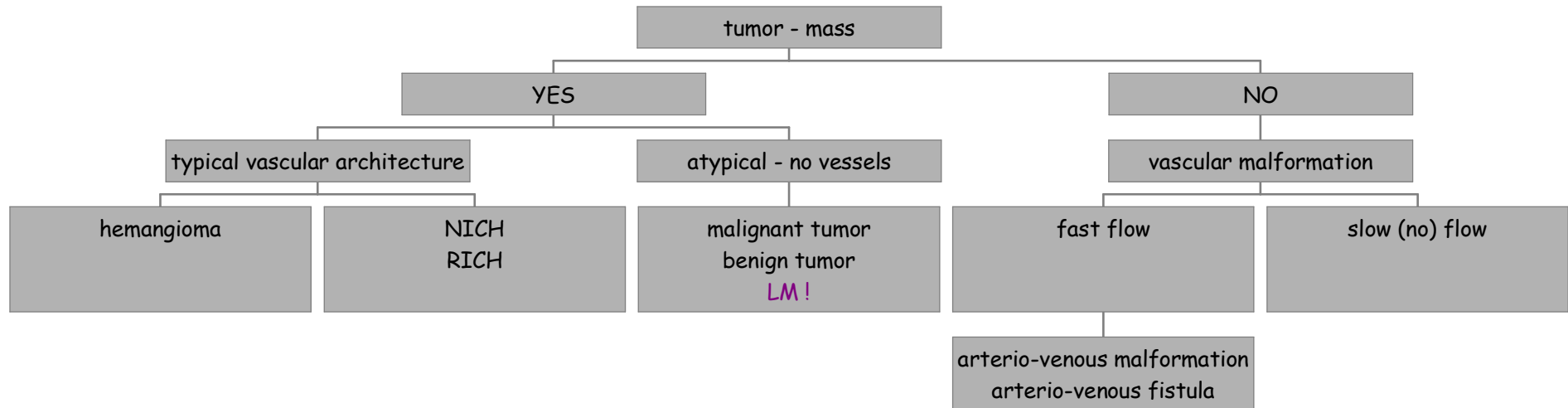
vascular birthmarks



vascular birthmarks



vascular birthmarks



vascular birthmarks

